

We are IntechOpen, the world's leading publisher of Open Access books Built by scientists, for scientists

6,900

Open access books available

186,000

International authors and editors

200M

Downloads

Our authors are among the

154

Countries delivered to

TOP 1%

most cited scientists

12.2%

Contributors from top 500 universities



WEB OF SCIENCE™

Selection of our books indexed in the Book Citation Index
in Web of Science™ Core Collection (BKCI)

Interested in publishing with us?
Contact book.department@intechopen.com

Numbers displayed above are based on latest data collected.
For more information visit www.intechopen.com



Specific Forms of Cardiomyopathy: Genetics, Clinical Presentation and Treatment

M. Obadah Al Chekakie

Additional information is available at the end of the chapter

<http://dx.doi.org/10.5772/55628>

1. Introduction

Ischemic heart disease is the most common cause of cardiomyopathy and has been the subject of intense research and study. However, other rare forms of cardiomyopathy exist and represent a diagnostic as well as a therapeutic challenge for the clinician. This chapter aims to review the rare forms of cardiomyopathy, from genetic abnormalities, clinical presentation to treatment and sudden death prevention.

2. Cardiac sarcoidosis

2.1. Introduction

Sarcoidosis is a multisystem disease characterized by noncaseating granulomas involving multiple organ systems. Cardiac involvement is relatively rare and ranges from 5 to 40%. Clinically, patients could have palpitations, atrioventricular block, syncope, shortness of breath, left ventricular dysfunction and sudden cardiac death. Early recognition and treatment is important since cardiac involvement portends a poor prognosis and is the second cause of death in patients with sarcoidosis [1].

2.2. Epidemiology

Sarcoidosis is common in Japan, Ireland, Scandanavia and the United States. Females are more commonly affected than males. In the United States, African Americans are more commonly affected and in general have more severe forms of the disease. The age adjusted annual incidence is highest for African American females in the age group of 30 to 39 years

and is at 107 per 100,000 [2]. Clinical cardiac involvement is reported to be 5%, while subclinical cardiac involvement detected by imaging studies is in the range of 30-40%, which matches autopsy series.

2.3. Environmental and genetic factors

The etiology of sarcoidosis remains unknown. The presence of noncaseating granulomas in the lungs, skin and eyes and clustering of cases in certain occupations (navy personnel, firefighters at the world trade center) point to an immunological response to environmental agents or infectious exposure [3, 4]. Mycobacterial DNA and RNA have been found in sarcoid tissue using polymerase chain reaction, especially the DNA of the mycobacterium tuberculosis catalase-peroxidase (mKatG) gene [5].

There is familial clustering of the disease, and patients are more likely to have an affected member but there is little concordance in organs involved. Class I HLA-B8 and Class II HLA-DRB1 and HLA-DQB1 alleles have been consistently associated with sarcoidosis [6, 7]. Genome-wide scans for loci associated with sarcoidosis showed the strongest signals in chromosomes 5p and 5q in African Americans [8]. The strongest signals in Germans were found in chromosome 6p, which helped identify the butyrophillin-like 2 (BTLN2) gene. This gene is a negative co-stimulatory molecule within the major histocompatibility complex region [9]. Chromosome 18q22 has a strong link to the presence of cardiac or renal sarcoidosis [10]. Likely there is an interaction between environmental exposure and certain susceptibility genes leading to the development of sarcoidosis. Further research is needed to clarify such interactions.

2.4. Pathology

The hallmark of sarcoidosis is the presence of noncaseating granulomas. These are compact collections of macrophages and epithelioid cells with minimal inflammation and multinucleated giant cells. Even though clinical involvement of the heart is reported to be 5%, autopsy series show cardiac involvement in 25 to 40% of patients [11, 12]. Several recent imaging studies show that delayed enhancement magnetic resonance imaging (DE MRI) in patients with histology proven extra-cardiac sarcoidosis could detect cardiac involvement even in patients with normal electrocardiograms, with cardiac involvement in these studies ranging from 26-32%, which matches autopsy series [13, 14]. The ventricles are commonly affected, especially the left ventricular (LV) free wall, basal LV, inter-ventricular septum and conduction system. The heart could be involved among other systems, but isolated cardiac disease does occur. Endomyocardial biopsy has a low yield (~20%) given the patchy involvement of the heart muscle. However, it is still needed at times in diagnosis especially when other diseases are suspected.

2.5. Clinical features of cardiac sarcoidosis

The heart could be the only organ affected or could be involved in combination with other systems. The degree of lung involvement does not predict cardiac involvement and cardiac

involvement can be subclinical without any apparent symptoms. Patients might have non-specific symptoms like shortness of breath and fatigue. Palpitations are common and could be due to atrial tachycardia, atrial fibrillation, premature ventricular contractions, sustained and non-sustained ventricular tachycardia. Rarely patients could present with pericarditis and cardiac tamponade. The most common criteria used for diagnosing cardiac sarcoidosis is the 2006 revised guidelines of the Japanese Ministry of Health and Wellness [15]. Table 1 gives a summary of these guidelines.

Advanced atrioventricular block in young patients should prompt search for cardiac sarcoidosis especially in females [16]. Patients with extra-cardiac sarcoidosis and abnormalities in the electrocardiogram (ECG) should have at least an echocardiogram performed to look for left ventricular function, especially when symptoms suggestive of heart failure are present. However, the JMHW guidelines are not very sensitive and cardiac involvement could be present even in patients with normal electrocardiograms [17]. There is no consensus about the best way to screen patients with sarcoidosis for cardiac involvement. In a recent Delphi study on diagnosing cardiac sarcoidosis, a survey of a group of sarcoidosis experts from different subspecialties including pulmonologists, cardiologist and electrophysiologists showed a wide range of practices with most experts utilizing history, physical examination and ECG for screening. About 75% of experts would not do any further testing in the absence of symptoms or signs of cardiac involvement along with normal ECG. But when Cardiac sarcoidosis is suspected, most experts would perform ECG, TTE and cardiac MRI and 67% would order Holter monitor and cardiac fluorodeoxy-glucose (FDG) PET scan [18]. This reflects the wide range of clinical practice and the fact that sarcoidosis in general can mimic other diseases and could stay subclinical. However, it is clear from recent cardiac MRI studies that cardiac involvement can be present in patients with no cardiac symptoms and a normal ECG in 30% of patients with biopsy proven extracardiac sarcoidosis [17]. Smedema et al study suggests that the combination of ECG and MRI is the most cost effective for screening [14]. It is important to diagnose cardiac sarcoidosis, as patients with cardiac involvement die for heart failure or sudden cardiac death.

2.6. Laboratory investigations

Laboratory testing in sarcoidosis is non-specific. Patient can have anemia and some might have hypercalcemia due to activation of vitamin D by macrophages present in granulomas [19]. Elevated angiotensin converting enzyme levels were proposed initially as a diagnostic test and to follow treatment response. However, there is a wide range of normal in healthy subjects and it is a poor therapeutic guide [20].

2.7. Electrocardiography (ECG)

The ECG has been used as a screening tool for cardiac involvement in patients with sarcoidosis. Abnormalities noted include right bundle branch block (RBBB), which can be seen in 20-25% of patients. Premature ventricular contractions (PVCs), non-sustained ventricular tachycardia (NSVT) and sustained ventricular tachycardia (VT) could also occur. Inflammation and scar formation lead to slow conduction and reentry, which is the mechanism of VT in these patients

Histologic diagnosis group	Cardiac sarcoidosis is confirmed when endomyocardial biopsy specimens demonstrate noncaseating epithelioid granulomas.
Clinical diagnosis group*	<p>Cardiac sarcoidosis is diagnosed in the absence of an endomyocardial biopsy specimen or in the absence of typical granulomas on cardiac biopsy when extracardiac sarcoidosis has been proven and a combination of majore or minor diagnostic criteria has been satisfied:</p> <ol style="list-style-type: none">1. More than 2 of the 4 major diagnostic criteria are met OR2. One of the 4 major criteria and 2 or more of the minor criteria are met. <p>Major Criteria:</p> <ol style="list-style-type: none">1. Advanced AV block2. Basal thinning of the ventricular septum3. Positive cardiac gallium uptake4. Left ventricular ejection fraction < 50%. <p>Minor Criteria:</p> <ol style="list-style-type: none">1. Abnormal electrocardiogram findings including ventricular tachycardia, multifocal frequent premature ventricular contractions, complete right bundle branch block, pathologic Q waves or abnormal axis deviation2. Abnormal echocardiogram demonstrating regional wall motion abnormalities, ventricular aneurysm or unexplained increase in wall thickness.3. Perfusion defects detected by myocardial scintigraphy4. Delayed gadolinium enhancement of the myocardium on cardiac MRI scanning5. Interstitial fibrosis or monocyte infiltration greater than moderate grade by endomyocardial biopsy.

Table 1. Modified Guidelines for the Diagnosis of Cardiac Sarcoidosis from the Japanese Ministry of Health and Wellness

[21]. Left bundle branch block and Q waves have been described [22]. Advanced atrioventricular block (AVB) and complete heart block could occur in up to 20-30% of patients due to the involvement of the basal LV septum as well as involvement of the AV nodal artery and they portend a poor prognosis [16]. In patients with symptomatic cardiac sarcoidosis, Shuller et al showed that fragmentation of the QRS occurs in up to 75% of patients and when combined with bundle branch block, has 90% sensitivity in detecting cardiac involvement, however, the study was limited to symptomatic patients [22]. Mehta et al showed that ECG sensitivity could be as low as 8%. Using 24 hours holter monitoring could help detect abnormalities including AV block, PVCs and NSVT and has more sensitivity compared to the 12 lead electrocardiogram (50% vs 8% respectively) [17].

2.8. Endomyocardial biopsy

The presence of noncaseating granulomas in endomyocardial biopsy is diagnostic of sarcoidosis. However, endomyocardial biopsy is not sensitive, since the disease is usually patchy and most commonly involves the left ventricle. Of the 28 patients with clinical

systematic sarcoidosis with documented cardiomyopathy who underwent endomyocardial biopsy at John Hopkins, only 7 had noncasesating granulomas. If sarcoidosis is suspected, it is often recommended to obtain biopsy from other organs like the paratracheal lymphnodes, skin and even the liver. PET scanning could help detect disease activity and potential sites for biopsy [23].

The main differential diagnosis to sarcoidosis histologically is giant cell myocarditis. In a series comparing 42 patients with cardiac sarcoidosis to 73 patients with giant cell myocarditis, nearly a third of the patients finally diagnosed with cardiac sarcoidosis had no extracardiac involvement. Underscoring the fact that isolated cardiac involvement does occur [24]. Table 2 lists the features that help differentiate cardiac sarcoidosis from giant cell myocarditis. Rarely, cardiac sarcoidosis could only be diagnosed at the time of heart transplantation, further scoring the difficulties of establishing the diagnosis [25].

	Sarcoidosis	Giant Cell Myocarditis
African American race	31%	4%
Syncope	31%	5%
AV block	50%	15%
Clinical Presentation	AV block or heart failure symptoms of > 9 weeks duration	Usually acute heart failure presentation
Histology	Granulomas and fibrosis	Eosinophils, myocyte damage and foci of lymphocytic myocarditis

Table 2. Clinical and Histological features comparing Sarcoidosis to Giant Cell Myocarditis.

2.9. Imaging studies in cardiac sarcoidosis

2.9.1. Chest x-ray

Bilateral hilar lymphadenopathy is the most common finding on chest x-ray (CXR). However, bilateral hilar fullness could be also a sign of pulmonary dilatation secondary to cardiac involvement or pulmonary hypertension. Cardiomegaly is sometimes noted. When bilateral hilar lymphadenopathy is found and sarcoidosis is suspected, then high resolution computed tomography scan is indicated to detect pulmonary parenchymal involvement [19].

2.9.2. Echocardiography

Transthoracic echocardiography (TTE) could be useful in detecting cardiac involvement in patients diagnosed with extracardiac sarcoidosis. Segmental wall motion abnormalities with thinning of the ventricular wall and LV dysfunction are common but non-specific findings. The presence of basal septal thinning in the LV should lead the clinician to consider sarcoidosis highly in the differential diagnoses especially in young patients with conduction abnormalities [26]. Aneurysms could be seen especially in the inferior wall. Regional hypertrophy could also

be found due to inflammation and edema. Right ventricular dysfunction is also seen and in later stages of pulmonary sarcoidosis, pulmonary hypertension and tricuspid regurgitation are seen. Mitral regurgitation and rarely pericardial effusion with tamponade physiology could be the first presentation in patients with sarcoidosis [27]. The sensitivity of TTE in detecting cardiac involvement in patients with extracardiac sarcoidosis is poor, and ranges from 14-25% [17, 28].

2.9.3. *Magnetic Resonance Imaging (MRI)*

Cardiac MRI has emerged as a sensitive modality to detect clinical and subclinical cardiac sarcoidosis. It has great spatial resolution and can help detect disease activity, presence or absence of fibrosis, wall motion abnormalities, pericardial involvement as well as right ventricular involvement. Increased signal intensity on T2 weighted images signifies edema and inflammation. Focal myocardial thickening can also be due to edema. Delayed enhancement using gadolinium is likely due to fibrosis. The basal and lateral LV walls are most commonly affected, especially the basal septum [29]. Delayed enhancement MRI is more sensitive than ^{201}Tl imaging and ^{67}Ga imaging in detecting subclinical cardiac sarcoidosis. In a study of 10 patients by Tadamura et al, only 50% of patients with sarcoidosis exhibited abnormalities on ^{201}Tl imaging and only 20% had ^{67}Ga uptake while a 100% of these patients had abnormalities detected by cardiac MRI [30]. Smedema et al studied 58 patients with biopsy proven extracardiac sarcoidosis using the JMHW 1993 criteria as gold standard. Other modalities studied included ECG, TTE, ^{201}Tl scintigrams and DE MRI. Cardiac MRI had a sensitivity of 78-100% and specificity of 64-89% in detecting cardiac involvement. Cardiac MRI was noted to detect cardiac involvement even in patients with normal ECG, Echocardiography and ^{201}Tl Scintigrams [14].

Mehta et al studied 62 patients with extracardiac sarcoidosis using a systematic approach including ECG, Holter monitoring, TTE, ^{18}F -FDG PET scanning and cardiac MRI. The prevalence of cardiac sarcoidosis was 39%. The modified JMHW criteria had a sensitivity of 33% and specificity of 97%. Holter monitoring was superior of ECG in detecting conduction system abnormalities as well as other ventricular arrhythmias. In the 22 patients who had both cardiac MRI and ^{18}F -FDG PET scans done, 32% had delayed enhancement and 5% had edema on T2 images while abnormalities on ^{18}F -FDG PET scan was observed in 86% of the patients. Cardiac MRI and PET scans can be reasonably done in patients with suspected cardiac sarcoidosis and can detect subclinical involvement and are more sensitive than the JWHW criteria [17]. Patel et al studied 81 patients with biopsy proven extracardiac sarcoidosis and used the JMHW modified criteria as well as DE MRI to look for cardiac involvement. The JMHW identified 10 patients (12%) with cardiac involvement while DE MRI identified cardiac involvement in 21 patients (26%), only 8 patients overlapped. The median extent of damage detected by DE MRI was 6.1% of the left ventricle. The basal and mid ventricular septum showed delayed enhancement in 76% of patients. Furthermore, of the 4 patients with positive endomyocardial biopsy, all the 4 patients (100%) had abnormalities detected by DE MRI, while only 2 patients (50%) met the diagnostic criteria of the JMHW. Patients with DE MRI had 11-fold increase risk of death compared to patients

without DE MRI findings [13]. Furthermore, delayed enhancement correlated with disease duration, regional wall motion abnormalities, ventricular function, severity of mitral regurgitation and presence of ventricular tachycardia [31].

2.9.4. Radionuclide scintigraphy

²⁰¹Thallium has been used to detect cardiac involvement in patients with sarcoidosis. Segmental areas of decreased perfusion at rest that improve with stress imaging (areas with reverse distribution) are seen in patients with cardiac sarcoidosis but are not necessarily specific, since they are also seen in other forms of cardiomyopathy. ²⁰¹Thallium is more sensitive than ⁶⁷Ga scanning in detecting cardiac sarcoidosis, but ⁶⁷Ga is more specific for sarcoidosis since it accumulates in inflamed areas and could be used to predict response to therapy and follow disease activity [32]. ⁶⁷Ga scanning has the advantage of detecting cardiac as well as extracardiac sarcoidosis and could guide to areas that are more amenable to biopsy [33]. Both modalities suffer from poor spatial resolution and both are less sensitive than DE MRI in detecting cardiac sarcoidosis [13, 30]. ^{99m}Tc-sestamibi has been used in combination with ⁶⁷Ga scanning and could help in showing that areas with increased ⁶⁷Ga uptake are due to cardiac as opposed to extracardiac involvement [34].

18-fluoro-2-deoxy-D-glucose PET scanning (¹⁸F-FDG PET) has been shown to be of great value in detecting cardiac involvement in patients with sarcoidosis. ¹⁸F-FDG PET is taken up by the macrophages, lymphocytes and epithelioid cells which are present in the granulomas and is helpful in detecting active inflammation and following response to corticosteroids treatment. In a series of 17 patients with biopsy proven extracardiac sarcoidosis, ¹⁸F-FDG PET was found to be the more sensitive in detecting cardiac involvement compared to both ²⁰¹Thallium and ⁶⁷Ga scintigraphy. While ⁶⁷Ga scintigraphy was the least sensitive modality in detecting cardiac involvement, possibly because of it has a lower spatial resolution compared to ¹⁸F-FDG PET. Most of the abnormalities noted on ¹⁸F-FDG PET were found in the basal, mid anteroseptal and lateral walls and disappeared after treatment with corticosteroids [35]. In another study, PET and DE MRI were performed in patients with biopsy proven extracardiac sarcoidosis. In these series, 22 patients had both ¹⁸F-FDG PET and DE MRI performed. Of these, abnormalities in ¹⁸F-FDG PET were observed in 86% of the patients while MRI abnormalities were observed in 36% of the patients. It is possible that the apparent high sensitivity of ¹⁸F-FDG PET is due to its ability to detect active inflammation while DE MRI could only detect edema and scar and is unable to detect active inflammation [17].

2.10. Therapy

Therapy for cardiac sarcoidosis aims at treating and preventing heart failure, treatment of conduction system disease and prevention of sudden cardiac death. It is important to recognize cardiac involvement in patients with sarcoidosis, since sudden cardiac death could be the first presentation and is the second leading cause of death in patients with sarcoidosis [1].

2.10.1. Medical therapy

Similar to other forms of cardiomyopathy, treatment with angiotensin converting enzyme inhibitors and angiotensin receptor blockers is important since they have anti-fibrotic properties and have been shown to improve survival. β -blockers were also shown to improve survival in patients with heart failure. Since the initial cardiac lesions are due to granuloma formation which could progress with time to fibrosis, early recognition and initiation of corticosteroid treatment is important and could lead to improvement in LV function as well as achieve control of the arrhythmias [36]. In a Japanese retrospective study of 48 patients with cardiac sarcoidosis, only patients with pretreatment LVEF > 30% had improvement in their LV function with corticosteroid therapy, while those with pretreatment LVEF of < 30% showed little improvement [37]. The exact dose of corticosteroids and the duration of therapy are not well defined due to the absence of randomized controlled trials. In general, initial dose of 30 to 60 milligrams/day of prednisone is started for 8-12 weeks; with gradual taper to a daily dose of 5-10 mgs/day of prednisone over 6-12 months is recommended. Relapses could occur in up to 25% of patients [19, 38]. Use of Methotrexate, cyclosporine or hydroxychloroquine has been described and could be considered especially in patients with side effects to corticosteroids or who are not responding to therapy [38].

2.10.2. Device based therapy and the role of electrophysiology study

Patients presenting with heart block due to cardiac sarcoidosis could see improvement with corticosteroids therapy [36]. However, permanent pacemaker implantation is recommended even if there is a transient improvement in heart block with corticosteroids therapy [39]. Patients with depressed LVEF < 35% who do not improve with steroid therapy and patients who present with VT or survive cardiac arrest should undergo defibrillator (ICD) implantation [39]. Some experts advocate ICD implantation in patients with AVB due to cardiac sarcoidosis with extensive cardiac involvement on imaging studies even if the LVEF is still preserved [40]. The 2008 guidelines for device based therapy recommend consideration for defibrillator implantation to be based on LV function, presence of spontaneous or induced ventricular tachycardia, heart failure status and syncope. Patients with depressed LVEF < 35%, NYHA Class II-IV heart failure and wide QRS of > 120 milliseconds are candidates for biventricular defibrillator implantation (BiV ICD) [39].

For patients with LVEF of 35-55%, programmed electrical stimulation (PES) could help in the risk stratification of these patients. In a study by Mehta et al, PES helped identify patients at risk of ventricular arrhythmias and only 1 of the 68 patients with negative PES died over 5 yrs [41]. In another series by Aizer et al, PES was predictive of arrhythmic events and ICD therapy; however 2 of the 20 patients with negative PES died or had spontaneous sustained VT during follow up [42]. Currently, PES is used for risk stratification, but the negative predictive value of programmed electrical stimulation needs further study and the clinician needs to utilize knowledge of the published literature as well as clinical judgment when considering ICD therapy for primary prevention of SCD in sarcoidosis patients with LVEF of 35-55%.

There are no randomized trials for the prevention of sudden cardiac death in patients with cardiac sarcoidosis, and most of the efficacy is obtained from the experience of tertiary care

centers. In a retrospective study of patients with sarcoidosis who received ICD therapy, inappropriate shocks were low (13.3%) and appropriate shocks occurred in 37.8%, with an annual incidence of 15% per year. Most of the event occurred in the first 3 years post implantation [43]. In another study of 112 patients with cardiac sarcoidosis that had ICD implantation, 32% had appropriate ICD therapy and 14% had VT storm. Inappropriate therapies occurred in 11% of patients [44]. Depressed LVEF, Depressed RVEF and complete heart block were important predictors of appropriate ICD therapies [44].

For patients who have frequent shocks due to ventricular tachycardia, catheter ablation could be used for treatment of these VTs. The mechanism of VT in patients with sarcoidosis is mostly due to reentry or triggered activity. Reentry is the most common mechanism and could be due to slow conduction from active inflammation or from scar formation. Most of these circuits are near the basal right ventricle near the tricuspid valve area and most patients have a dramatic decrease in the VT burden or complete elimination of the VTs following ablation [45].

Some patients with cardiac sarcoidosis progress to advanced heart failure and might need heart transplantation. Patients with sarcoidosis have a good 1 and 5-year survival rates post transplantation [46]. Some of the patients were only diagnosed with cardiac sarcoidosis at the time of transplantation, underscoring the difficulties clinicians face in establishing the diagnosis of cardiac sarcoidosis [25].

3. Arrhythmogenic Right Ventricular Dysplasia/ Cardiomyopathy (ARVD/C)

3.1. Epidemiology

Arrhythmogenic right ventricular Dysplasia/ Cardiomyopathy (ARVD/C) is an inherited myopathy characterized by fibrofatty infiltration of the right ventricular (RV) wall, with left ventricular involvement over time in some patients [47, 48]. Males are more commonly affected than females. The true prevalence of the disease is unknown, but familial involvement is seen in up to 50%, which means screening family members is essential. The overall incidence is thought to be 1:1000 to 1:5000, with certain regions in Greece and Italy having increased prevalence compared to the rest of the world [49].

3.2. Environmental and genetic factors

There is no clear environmental cause of ARVD/C, and the etiology is not fully understood. Family members of patients with ARVD/ C are affected in 30-50% of the time, and the disease has autosomal dominant inheritance with variable penetrance. Several genetic loci have been identified, and mostly are mutations in cardiac desmosomes. Desmosomes are membrane structures composed of plasma cell membrane proteins that are responsible for force transmission between the cells. Abnormal function of these structures leads to cell detachment, death and inflammatory reaction leading to fibrosis and fatty infiltration. The most common mutation involves the PKP2 gene, encoding the plakophilin 2. Other desmosomal mutations

were identified in DSP gene, encoding desmoplakin, DSG2 gene, encoding desmoglein 2 and DSC2 gene, encoding desmocollin 2. Desmosomal mutations occur in 52% of North Americans with ARVD/C and are associated with ventricular tachycardia and younger age of presentation [50]. There is genetic variability that occurs in healthy subjects, and has been noted to be as high as 16%. However, certain mutations make the diagnosis of ARVD/C more likely, including radical mutations as well as certain missense mutations that are rare in Caucasians [51]. The autosomal recessive form is associated with woolly hair and palmoplantar keratosis, the so-called Naxos disease, since it was discovered in the Greek island of Naxos. This gene encodes plakoglobin and desmoplakin. This autosomal recessive form has been mapped to chromosome 17q21. In addition, the cardiac ryanodine receptor gene RyR2 may be involved in the disease and causes juvenile sudden death with minimal RV wall motion abnormalities [52]. Mutations in the transforming growth factor B3 (TGF-B3) were also found in a large family in ARVD/C [53].

3.3. Pathology

The hallmark of ARVD/C is fibrofatty infiltration of the RV wall. This occurs in the epicardial layers first and moves endocardially. The RV inflow, RV apex and RV outflow are typically affected, forming what is called the triangle of dysplasia. With time, the interventricular septum is affected too. LV involvement has been described and could be seen in up to 76% of patients [54]. It usually parallels right ventricular involvement and is associated with worse prognosis [55]. Table 3 shows the major and minor pathological criteria used by the Task Force for diagnosis [56]. Endomyocardial biopsy doesn't have high sensitivity, since it is usually performed in the interventricular septum rather than the RV free wall. However, endomyocardial biopsy might help exclude other disease that could mimic ARVD/C, especially sarcoidosis. [57]

3.4. Clinical presentation

The clinical course is variable and most patients present before age 40. Patients with ARVD/C can be asymptomatic for years. The most common clinical presentation is with palpitations (due to frequent ventricular ectopy and ventricular tachycardia), chest pain, syncope and sudden cardiac death. In fact sudden cardiac death could be the first manifestation of the disease [54]. With time patients might develop RV dilatation leading to symptoms and signs of right-sided heart failure including fatigue, abdominal fullness and lower extremity edema. LV involvement leads to systolic heart failure and is associated with worse prognosis [58].

3.5. Electrocardiographic changes in ARVD/C

Patients with ARVD usually have sinus rhythm. The Task force criteria specify some depolarization abnormalities as major criteria for diagnosis, namely the presence of Epsilon wave (which could be seen in up to 30%, very specific but is not sensitive). If the ECG is highly amplified, Epsilon potentials could be detected in as many as 77% of patients with ARVD [59]. Repolarization abnormalities considered to be major criteria are inverted T waves in V1 to V3 or beyond in the absence of right bundle branch block (RBBB) [56, 60]. T wave inversion in V1

to V4 in the presence of RBBB is considered minor criteria for diagnosis. QRS fragmentation, defined as deflections at the beginning of the QRS, on top of the R wave or at the nadir of the S wave, could be found in as many as 85% of patients with ARVD/C and it correlates with LV involvement [59]. Signal average electrocardiography is simple and non-invasive method that could be used for screening. Abnormalities on signal average ECG considered to be minor criteria are listed in Table 3.

Patients with ARVD/C can have ventricular tachycardia and frequent premature ventricular contractions (PVCs). Ventricular tachycardia in general has left bundle branch morphology and is caused by macro-reentry. There is evidence that adrenergic stimulation acts as a trigger for these arrhythmias [61]. Exercise testing can induce these arrhythmias in 50-60% of ARVD/C patients. These arrhythmias could lead to syncope and SCD. In fact, ARVC/D accounts for 3 to 10% of death occurring in patients younger than 65 years [62] and is one of the causes of sudden cardiac death in athletes [63]. Patients with ARVD/D should not participate in moderate to high intensity exercise [64].

Ventricular tachycardia with left bundle branch (LBB) morphology and inferior axis is considered minor criteria, while VT with LBB morphology and superior axis is considered major criteria. Hoffmayer et al proposed criteria to differentiate idiopathic right ventricular outflow tract VT from ventricular tachycardia caused by ARVD/C. Since both conditions could present with ventricular tachycardia with left bundle branch morphology with inferior axis. In multivariate analysis, prolonged QRS duration in Lead I > 120 msec and transition in V5 or later predicted ARVD/C as the cause of VT [65]. Table 3 lists major and minor electrocardiographic and arrhythmia criteria for diagnosis of ARVD/C [56].

	Major Criteria	Minor Criteria
Global and/or regional dysfunction and structural alterations	By 2D echo:	By 2D echo:
	1) Regional RV akinesia, dyskinesia, or aneurysm	1) Regional RV akinesia or dyskinesia
	2) and 1 of the following (end diastole):	2) and 1 of the following (end diastole):
	<ul style="list-style-type: none"> • PLAX RVOT ≥ 32 mm (corrected for body size [PLAX/BSA] ≥ 19 mm/m²) • PSAX RVOT ≥ 36 mm (corrected for body size [PSAX/BSA] ≥ 21 mm/m²) • fractional area change $\leq 33\%$ 	<ul style="list-style-type: none"> • PLAX RVOT ≥ 29 to < 32 mm (corrected for body size [PLAX/BSA] ≥ 16 to < 19 mm/m²) • PSAX RVOT ≥ 32 to < 36 mm (corrected for body size [PSAX/BSA] ≥ 18 to < 21 mm/m²) • fractional area change $> 33\%$ to $\leq 40\%$
	By MRI:	By MRI:
	1) Regional RV akinesia or dyskinesia or dyssynchronous RV contraction	1) Regional RV akinesia or dyskinesia or dyssynchronous RV contraction
	2) and 1 of the following:	2) and 1 of the following:
	<ul style="list-style-type: none"> • Ratio of RV end-diastolic volume to BSA ≥ 110 mL/m² (male) or ≥ 100 mL/m² (female) • RV ejection fraction $\leq 40\%$ 	<ul style="list-style-type: none"> • Ratio of RV end-diastolic volume to BSA ≥ 100 to < 110 mL/m² (male) or ≥ 90 to < 100 mL/m² (female) • RV ejection fraction $> 40\%$ to $\leq 45\%$
	By RV angiography:	

	Major Criteria	Minor Criteria
	Regional RV akinesia, dyskinesia, or aneurysm	
Tissue characterization of walls	1) Residual myocytes <60% by morphometric analysis (or <50% if estimated), with fibrous replacement of the RV free wall myocardium in ≥ 1 sample, with or without fatty replacement of tissue on endomyocardial biopsy	1) Residual myocytes 60% to 75% by morphometric analysis (or 50% to 65% if estimated), with fibrous replacement of the RV free wall myocardium in ≥ 1 sample, with or without fatty replacement of tissue on endomyocardial biopsy
Repolarization abnormalities	1) Inverted T waves in right precordial leads (V_1 , V_2 , and V_3) or beyond in individuals >14 years of age (in the absence of complete right bundle-branch block QRS ≥ 120 ms)	1) Inverted T waves in leads V_1 and V_2 in individuals >14 years of age (in the absence of complete right bundle-branch block) or in V_4 , V_5 , or V_6 2) Inverted T waves in leads V_1 , V_2 , V_3 , and V_4 in individuals >14 years of age in the presence of complete right bundle-branch block
Depolarization/conduction abnormalities	1) Epsilon wave (reproducible low-amplitude signals between end of QRS complex to onset of the T wave) in the right precordial leads (V_1 to V_3)	1) Late potentials by SAECG in ≥ 1 of 3 parameters in the absence of a QRS duration of ≥ 110 ms on the standard ECG 2) Filtered QRS duration (fQRS) ≥ 114 ms 3) Duration of terminal QRS <40 μV (low-amplitude signal duration) ≥ 38 ms 4) Root-mean-square voltage of terminal 40 ms ≤ 20 μV 5) Terminal activation duration of QRS ≥ 55 ms measured from the nadir of the S wave to the end of the QRS, including R' , in V_1 , V_2 , or V_3 , in the absence of complete right bundle-branch block
Arrhythmias	1) Nonsustained or sustained ventricular tachycardia of left bundle-branch morphology with superior axis (negative or indeterminate QRS in leads II, III, and aVF and positive in lead aVL)	1) Nonsustained or sustained ventricular tachycardia of RV outflow configuration, left bundle-branch block morphology with inferior axis (positive QRS in leads II, III, and aVF and negative in lead aVL) or of unknown axis 2) >500 ventricular extrasystoles per 24 hours (Holter)
Family history	1) ARVC/D confirmed in a first-degree relative who meets current Task Force criteria 2) ARVC/D confirmed pathologically at autopsy or surgery in a first-degree relative 3) Identification of a pathogenic mutation [†] categorized as associated or probably	1) History of ARVC/D in a first-degree relative in whom it is not possible or practical to determine whether the family member meets current Task Force criteria 2) Premature sudden death (<35 years of age) due to suspected ARVC/D in a first-degree relative

Major Criteria	Minor Criteria
associated with ARVC/D in the patient under evaluation	3) ARVC/D confirmed pathologically or by current Task Force Criteria in second-degree relative

PLAX indicates parasternal long-axis view; RVOT, RV outflow tract; BSA, body surface area; PSAX, parasternal short-axis view

Table 3. Revised Task Force Criteria for the diagnosis of ARVD/C.

3.6. Imaging in ARVD/C

3.6.1. Right ventricular contrast angiography

Right ventricular angiography could detect wall motion abnormalities, RV dilatation and even aneurysm formation in patients with ARVD/C. However, due to its invasive nature, difficulty in visually assessing RV wall motion abnormalities especially in the presence of premature contractions makes it less attractive as a diagnostic modality.

3.6.2. Echocardiography

In patients with ARVD/C, the RV could be dilated with RV wall motion abnormalities and decreased RV function. Aneurysms could form in the RV free wall but also could be found in the inferior wall and apex. If adequate visualization of the walls is not possible because of poor windows, contrast injection could help overcome difficulties in delineating the RV wall. Right ventricular outflow (RVOT) enlargement is the most common abnormality found on TTE in patients with ARVD, and RVOT long axis dimension > 30 mm has the best sensitivity (89%) and specificity (86%) for diagnosing ARVD/C. Trabecular derangement, sacculations and hyper-reflective moderator band are less commonly found. Attention to regional RV wall motion abnormalities is important and could be seen in up to 80% of patients. Impaired RV function is seen in up to 67% of patients [66]. Occasionally, trans-esophageal echocardiography and intracardiac echocardiography could be used for diagnosis in patients with difficult images; however, they are more invasive. TTE is widely available, simple and non-invasive which makes it suitable as a primary diagnostic modality and should be performed in patients with PVCs and VT with left bundle branch block and inferior axis. Major and minor echocardiographic criteria for diagnosing ARVD/C are listed in Table 3 [56].

3.6.3. Radioisotope imaging

Cardiac sympathetic innervation is decreased in patients with ARVD/C, and radioisotopes with specific affinity to the β receptors in the heart could help in early diagnosis. However, it has poor spatial resolution and the sensitivity and specificity of this modality is not well established [67]. Myocardial perfusion imaging could show decreased areas of radioisotope uptake in the RV, which could help in patients presenting with RVOT type VT. However, it is not widely used and doesn't have high sensitivity or specificity. Because of all this, radioisotope imaging is not considered as first line diagnostic imaging in patients with ARVD/C.

3.6.4. Magnetic resonance imaging

Cardiac MRI has high resolution and helps in assessment of anatomy, function and hemodynamics of the right and left ventricle in patients with ARVD/C. Dilatation of the RVOT area, RV wall motion abnormalities, RV aneurysms, depress RV function and presence of fat infiltration of the RV wall all have been described in patients with ARVD/C [68-70]. However, MRI cannot be used in patients who have defibrillators and it depends on the experience of the center and reader [69]. Tagged MRI helps detect regional wall motion abnormalities in the RV and LV walls. Jain et al found that regional wall motion in the LV parallels the degree of RV function and is present in patients with grossly normal LV function [55]. LV abnormalities include intramyocardial fat as well as wall motion abnormalities, and could be seen in up to 27% of patients (Figure 1). Delayed enhancement MRI (DE MRI) has great sensitivity and could show increased signal in the RV (most commonly the basal sub-tricuspid region extending anteriorly to the RV outflow) in up to 67% of patients with ARVD/C. It is important to differentiate epicardial fat from fat infiltration of the RV wall. In patients with ARVD/C, areas of fat infiltration are most commonly dyskinetic. Relying on fat infiltration alone without wall motion or quantitative assessment of the RV and without adequate testing and attention to the task force criteria could lead to over diagnosis of ARVD/C [69]. Fat infiltration is very sensitive (84%) but has low specificity (79%) while regional RV wall motion abnormalities and RV enlargement are very specific but less sensitive [71]. Table 3 lists the major and minor MRI criteria used for diagnosing ARVD/C.

3.7. Electrophysiology study and three dimensional electro-anatomical mapping

Electrophysiologic testing with programmed electrical stimulation (PES) is used for risk stratification of sudden cardiac death in patients with ARVD/C but it has poor positive predictive value (35 to 49%) and limited negative predictive value (49 to 74%) in predicting arrhythmias and appropriate ICD shocks [72-74]. Electroanatomical mapping could help in detecting areas of scar in patients with ARVD/C. Corrado et al demonstrated that scar could accurately be localized in patients with ARVD/C and usually correlates with areas with wall motion abnormalities and fibrofatty infiltration at endomyocardial biopsy. Areas with low voltage of < 0.5 mV are considered scar areas, while healthy tissue usually has a voltage of > 1.5 mV [75]. Areas with voltage between 0.5 and 1.5 mV are considered transitional zone. It is important to insure appropriate contact using either fluoroscopy or intracardiac echocardiography and to obtain multiple points in the same area to confirm that it is a low voltage area. Furthermore, fractionated signals can be found in areas with low voltage and is evidence of slow conduction and could be part of the ventricular tachycardia circuit. Voltage mapping can help delineate the substrate for macro-reentrant VT in patients with ARVD [75]. Low voltage areas indicating scar are noted in the anterolateral RV free wall, apex, and inflow and outflow tracts of the RV and correlate with MRI findings [76]. Even in patients with ARVD and minimal scar, prolonged endocardial activation could be noted. In a study of 25 patients with left bundle branch VT, Tandri et al showed that patients with ARVD/C had prolonged endocardial activation > 65 msec while none of the patients with idiopathic RVOT VT had prolonged endocardial activa-

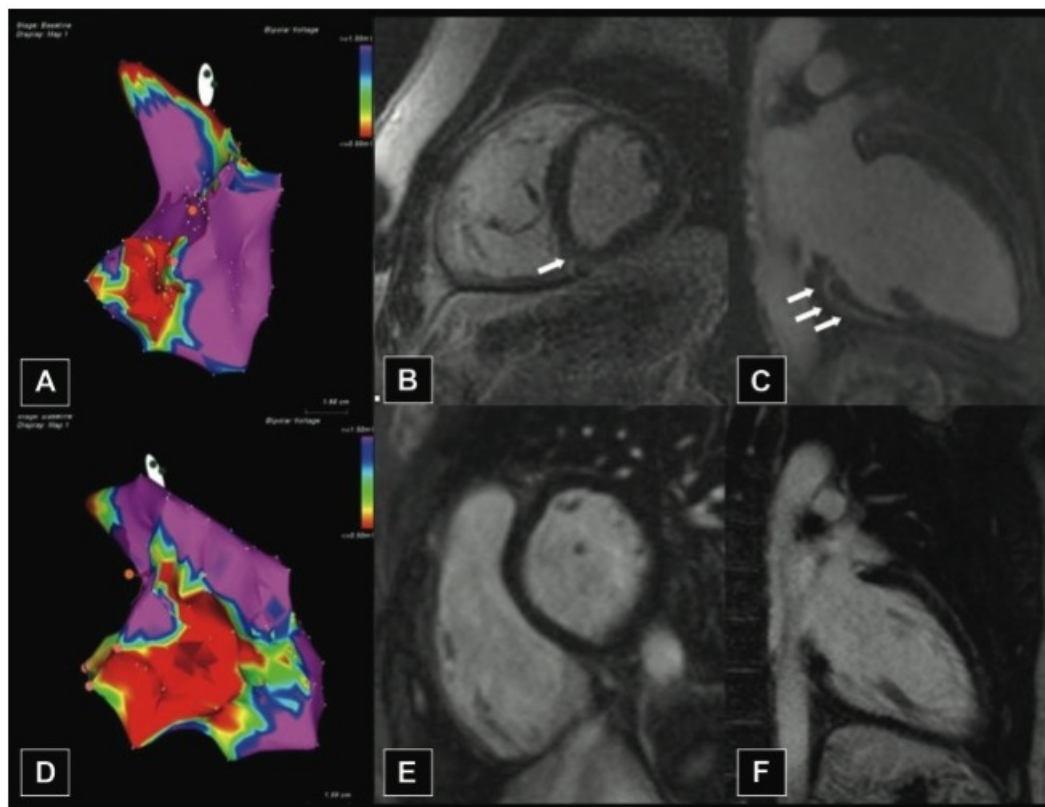


Figure 1. Representative cases of discordance between endocardial voltage mapping (EVM) and contrast-enhanced magnetic resonance (DE-MRI). **A**, Lateral view of the right ventricular (RV) EVM showing electroanatomical scar (EAS) in the RV inferobasal region and outflow tract. **B** and **C**, Basal short- and long-axis views of DE-MRI sequences showing no signs of delayed contrast enhancement (DE) in the RV free wall. Subepicardial DE is visible in the inferior and inferoseptal regions of the left ventricle (LV; white arrows). **D**, Lateral view of EVM showing a large EAS affecting the inferobasal, anterolateral, and, partly, RV outflow tract region. **E** and **F**, Basal short- and long-axis views of DE MRI showing neither RV nor LV DE. (From Martina Perazzolo Marra, MD, PhD et al "Imaging Study of Ventricular Scar in Arrhythmogenic Right Ventricular Cardiomyopathy / Clinical Perspective : Comparison of 3D Standard Electroanatomical Voltage Mapping and Contrast-Enhanced Cardiac Magnetic Resonance" *Circulation: Arrhythmia and Electrophysiology*. 2012; 5: 91-100, With Permission)

tion [77]. Electroanatomical mapping is actually more sensitive than DE MRI in detecting areas with scar, (Figure 1). especially if the scar area is < 20% of the total RV area [78].

3.8. Diagnosis of ARVD/C

Diagnosis of ARVD/C is based on the Modified Task Force Criteria published in 2010 [56]. These criteria are specific and rely on the demonstration of structural, functional and electrophysiological changes to diagnose the disease. To diagnose ARVD/C, 2 major criteria, one major and two minor criteria or 4 minor criteria need to be fulfilled. The modified criteria are more sensitive in detecting the disease in first-degree relatives of affected members without compromising specificity and incorporate certain pathogenic mutations as major criteria for diagnosis. Furthermore, it offers more quantitative parameters in imaging studies for diagnosis compared to the original 1994 criteria. Table 3 lists the modified criteria.

3.9. Therapy

Therapy of ARVD/C aims at suppressing ventricular arrhythmias, prevention of sudden cardiac death and treatment of right and/or left ventricular heart failure. Family members should be screened for the disease since most of the cases have autosomal dominant inheritance.

Patients with ARVD/C should not participate in competitive sports and should avoid moderate to high intensity exercise. And since the occurrence of ventricular tachycardia is related to adrenergic stimulation, most of the patients with ARVD/C with sustained and NSVT are typically treated with β -blockers and given antiarrhythmic drugs. Sotalol was thought to suppress ventricular arrhythmias in patients with ARVD/C and is widely used in this population [79]. However, a recent publication from the North American ARVD/C registry showed that sotalol did not suppress ventricular arrhythmias or prevent ICD therapies while amiodarone had a better efficacy but only 10 patients received amiodarone in this registry [80]. In patients with heart failure, β -blockers, angiotensin converting enzyme inhibitors and angiotensin receptor blockers are indicated. Catheter ablation for ventricular arrhythmias is used to treat sustained ventricular tachycardia that lead to syncope and ICD shocks in patients with ARVD/C. Both activation mapping as well as substrate mapping could be used to delineate the VT circuit [81]. The success rate of catheter ablation ranges from 32 to 88%, and most patients require two or three ablation procedures [82, 83]. For prevention of sudden cardiac death, implantable cardioverter defibrillators (ICDs) are clearly indicated in patients with ARVD/C who survive cardiac arrest or have sustained VT. It is considered a class IIa indication in ARVD/C patients with one or more risk factors of sudden cardiac death (unexplained syncope, presence of nonsustained VT on ambulatory monitoring, extensive RV involvement, LV involvement and positive EPS study) [39]. However, there is no clear consensus on the risk factors for SCD in patients with ARVD/C, and the physician needs to utilize knowledge, experience and clinical judgment when considering ICD implantation for patients with this disease.

Since this is a young population, they are also likely to experience inappropriate shocks due to sinus tachycardia or other supraventricular arrhythmias especially atrial fibrillation. Inappropriate shocks occur frequently and could happen in 16 to 24% of patients [72-74]. Appropriate ICD shocks occur in 25 to 50% of patients with no prior VT or VF [74, 84]. Most therapies are clustered early, especially in the first 2 years [43]. Syncope, inducibility at EP study, left ventricular involvement, presence of non-sustained ventricular tachycardia or > 1000 PVCs at holter monitoring are important predictors of appropriate ICD therapy [73, 84]. Furthermore, due to the progressive nature of the disease, lead complications could occur late and lead repositioning or implantation of a new lead are not uncommon and could occur in 14% to 21% of patients [72, 73]. In general ICD therapy is life saving and is well tolerated and has become accepted standard of care in patients with ARVD/C who experience cardiac arrest, sustained VT, unexplained syncope or marked RV dilatation or LV involvement [39].

Prognosis is dependent on the rate of progression of the disease, presence of heart failure and the degree of LV involvement [85]. The diagnosis of ARVD/C should prompt genetic testing

to identify the mutation involved and guide the screening of family members. Heart Transplantation is indicated in patients with advanced right and/or left sided heart failure.

4. Isolated left ventricular non-compaction

4.1. Introduction

Noncompaction of the left ventricular myocardium is a rare disorder that occurs in isolation or with other congenital cardiac defects. It is caused by the arrest of compaction of the myocardial fibers, leading to prominent trabeculations giving the myocardium a spongy appearance. Patients can be asymptomatic and could present with syncope, chest pain, palpitations, shortness of breath and sudden cardiac death. Management of patients with isolated left ventricular non-compaction (ILVNC) involves treating heart failure, protection from sudden cardiac death, anticoagulation to prevent thromboembolic events, and screening of family members.

4.2. Epidemiology

The true prevalence of isolated LV noncompaction is unknown, as most cases are referred to tertiary care centers. In clinical series, the prevalence ranges from 0.05 to 0.25%. The median age at diagnosis ranges from 90 days to 45 years and males are more commonly affected than females [86-89].

4.3. Pathology

Noncompaction of the left ventricular myocardium is caused by the arrest of intrauterine compaction of the myocardial fibers, leading to prominent trabeculations giving the myocardium a spongy appearance [90]. It is often associated with other congenital cardiac anomalies, especially obstruction of the right or left ventricular outflow tracts. However, the deep intertrabecular recesses that persist in these cases are in communication with the ventricular cavity and the coronary circulation [87]. In contrast, the intertrabecular recesses in isolated LV noncompaction are in communication with the LV cavity only and not with the coronary circulation. Histologically, there is myocardial thickening as well as interstitial and subendocardial fibrosis [91]. Microcirculatory dysfunction is present in both compacted and noncompacted segments which might explain the subendocardial scar noted on biopsies as well as the wall motion abnormalities noted in imaging [92].

4.4. Genetics

Familial involvement was high in initial reports describing isolated LV noncompaction [93] In later series involving adults, the familial recurrence ranged from 12 to 44%. Some mutations involving the G4.5 gene have X linked Inheritance [94, 95]. However, autosomal dominant inheritance has also been reported with mutations in chromosome 11p15 [95, 96].

Sarcomere protein gene defects are also found in patients with ILVNC. Mutations in cipher/ZASP, a gene encoding for the Z-band, can cause dilated cardiomyopathy as well as ILVNC [97]. In a study of 63 unrelated patients with ILVNC, mutations in genes encoding sarcomere proteins were identified in 11 patients. These genes include β myosin heavy chain (MYH7), α -cardiac actin and cardiac troponin T. Similar sarcomere gene mutations, especially in MYH7 are also found in patients with hypertrophic and dilated cardiomyopathies [98]. These sarcomere mutations could account for up to 29% of mutations in ILVNC, but they do not predict clinical outcome [99].

4.5. Clinical presentation

Patients with isolated LV noncompaction can be asymptomatic for years and eventually could present with heart failure, arrhythmias, embolic events and sudden cardiac death. The clinical course is variable, with patients who are asymptomatic having a more stable clinical course, while patients presenting with heart failure having a progressive clinical course with heart failure and ventricular arrhythmias [100]. Most patients have some degree of LV dysfunction, which has been reported in up to 60% of patients in the four largest reports of LV noncompaction [86, 87, 93, 101]. However, presentation as congestive heart failure with dyspnea on exertion has ranged from 30–68%. Patients could have systolic as well as diastolic dysfunction. Microcirculatory dysfunction could lead to ischemia and scar causing wall motion abnormalities and systolic heart failure. While impaired filling and abnormal relaxation from prominent trabeculations could lead to diastolic heart failure [92]. Several arrhythmias have been reported with ILVNC, including atrial fibrillation (5–29% in major reports), atrial tachycardia, premature ventricular complexes and ventricular tachycardia (18–47% in major reports). Sudden cardiac death accounted for 50% of deaths in ILVNC. Presence of subendocardial scar can act as a substrate of reentry in these patients. Embolic complications in ILVNC could be due to thrombus formation in the recesses of the trabeculations, due to stagnant flow from severely depressed LV function or from atrial fibrillation. These emboli can go to the cerebrovascular circulation, peripheral circulation, or pulmonary circulation. The incidence of embolization has ranged from 21–38%. Anticoagulation to prevent thromboembolic complications is very important in ILVNC [91].

4.6. Electrocardiogram

Abnormalities noted in the electrocardiogram in patients with ILVNC include left bundle branch block, right bundle branch block, left ventricular hypertrophy with repolarization abnormalities, and AV block. Wolff-Parkinson-White syndrome has been described in children with ILVNC. Atrial fibrillation, frequent premature ventricular contractions with sustained and non-sustained ventricular tachycardia could be present and could be the first presentation of the disease. There is a high prevalence of early repolarization in patients with ILVNC, especially in those patients who present with malignant arrhythmias [86, 87, 102].

4.7. Imaging in isolated left ventricular non-compaction

4.7.1. Echocardiography

Transthoracic echocardiography is the modality most commonly used to diagnose ILVNC [103]. The most common criteria used for diagnoses have been proposed by Jenni et al, with a ratio of noncompacted to compacted LV myocardium of 2 to 1 considered diagnostic [104]. This is typically measured at end systole in the parasternal short axis view. Deep intertrabecular recesses that are supplied from the LV cavity and absence of other congenital anomalies are part of Jenni's criteria. However, some experts suggest the ratio of noncompacted to compacted myocardium should be measured but in the parasternal short axis view at end diastole [103]. Chin et al proposed a measurement of compacted myocardium (C) to the total thickness of both compacted and noncompacted layers (C + NC) at end diastole, with the ratio of C/(NC+C) of <0.5 considered diagnostic. However, there is poor agreement between readers when it comes to the ratio of noncompacted to compacted myocardium, with only 74% of agreement noted and there is poor agreement between these two criteria for diagnosis [105]. Jenni's criteria are more specific while Chin's criteria are more sensitive. In general the noncompacted segments most commonly involve the apex more than the base, and are seen mostly in the inferior wall and also in the lateral wall [104]. Multiple segments are usually involved (Figure 2). The right ventricle is involved in 40% of the cases [89, 105]. Wall motion abnormalities, impaired diastolic filling as measured from mitral inflow velocities are also seen. Depressed LV ejection fraction is noted in a lot of patients with LV noncompaction, and patients with severe LV dysfunction have a poor prognosis. It is important to differentiate ILVNC from hypertrophic cardiomyopathy (especially the apical variant), dilated cardiomyopathy, arrhythmogenic right ventricular dysplasia and endocardial fibroelastosis. But in isolated LVNC, perfused recesses and hypokinetic segments are very specific, and the wall thickening noted is confined to certain walls of the LV. Visualization of the trabecular recesses could be enhanced using contrast. Transesophageal echocardiography could also be used in diagnoses in patients with difficult windows.

4.7.2. Magnetic Resonance Imaging (MRI)

Magnetic resonance imaging (MRI) has been also used for diagnosis. Delayed gadolinium enhancement has been seen in both compacted and noncompacted myocardium. In compacted myocardium, delayed enhancement correlated well with fibrosis, while in the noncompacted segments, delayed enhancement correlated with fibrosis as well as mucoid degeneration of the endocardium [106]. MRI offers better spatial resolution and can help assess LV and RV functions, wall motion abnormalities, as well as the ratio of compacted and noncompacted segments, which has been shown to be an important predictor of major adverse cardiac events, including heart failure, ventricular arrhythmias and thromboembolism. A ratio of noncompacted to compacted myocardium of > 2.3 at end diastole had the best sensitivity (86%) and specificity (99%) in diagnosing ILVNC [107]. However, 140 patients (43%) of 323 patients in the MESA cohort had at least one area with trabeculated to compact ratio of > 2.3 and the authors advised caution in using these criteria alone for diagnosis of ILVNC [108]. The

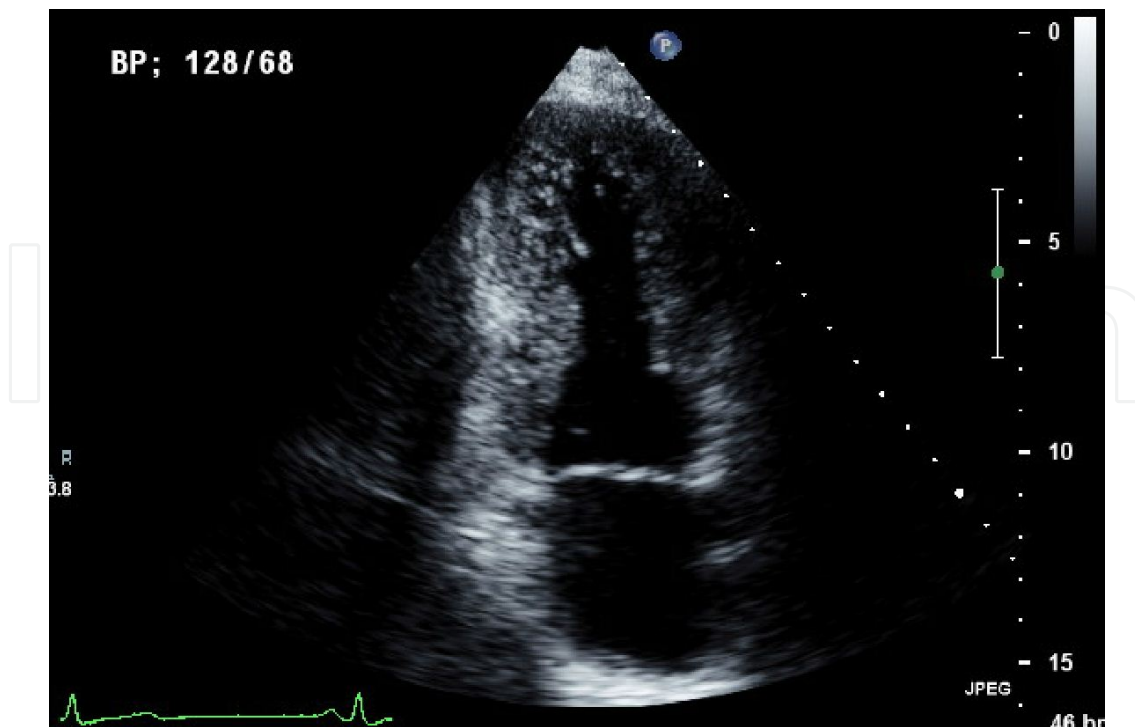


Figure 2. Apical 2 chamber view showing prominent trabeculations in the apex and inferior walls consistent with Isolated Left Ventricular Non-Compaction.

calculation of trabeculated LV mass using MRI could help also in the diagnosis of ILVNC, with trabeculated LV mass of $>20\%$ of the total LV mass having the highest sensitivity and specificity (93.7%) in diagnosing ILVNC [109].

4.7.3. Other imaging modalities

Computed tomography scan could be used to diagnose ILVNC and has high spatial resolution. Prominent trabeculations as well as deep intertrabecular recesses are typically seen [103]. Contrast ventriculography could also be used but is invasive. PET scan could show decreased myocardial flow reserve in noncompacted areas as well as microcirculatory dysfunction in both compacted and noncompacted myocardium but this has limited utility in establishing the diagnosis [92, 110]. To date, Echocardiography and MRI remain the most common modalities used for diagnosing ILVNC.

4.8. Therapy

Management of patients with ILVNC involves treating heart failure, protection from sudden cardiac death, anticoagulation to prevent thromboembolic events, and screening of family members. β -blockers, angiotensin converting enzyme inhibitors and angiotensin receptor blockers are used and have been reported to improve symptoms and the LVEF [111]. Anticoagulation with coumadin is recommended in all patients, even if they don't have atrial fibrillation. Electrophysiology testing to predict the risk of sudden cardiac death has not

yielded great results. Currently, the decision to implant a defibrillator (ICD) or biventricular defibrillator (BiV ICD) is clear in patients who have survived a cardiac arrest or in patients with LVEF <35% who qualify for an ICD or BiV ICD according to the current guidelines [39]. In a series of 30 patients with ILVNC who received ICDs or BiV ICDs according to the current guidelines, Kobza et al showed that appropriate ICD therapy (either shocks or antitachycardia pacing) occurred in 37% of cases with a mean follow up of 21 ± 16 months. Inappropriate shocks occurred in 13% of cases. In patients who received ICD therapy for primary prevention, 33% had appropriate ICD therapy with mean follow up of 27 ± 33 months. There were no predictors of appropriate ICD therapy [112].

The prognosis of ILVNC varies. Initial reports were based on the experience in tertiary care centers led to the belief that the prognosis is poor, with progressive heart failure leading to death or transplantation in 47% of adults with ILVNC followed for 44 ± 39 months [91]. However, recent reports challenge this and asymptomatic patients in general have a good prognosis [113]. Certain clinical characteristics are more common in non-survivors compared to survivors, including higher LV end-diastolic diameter, New York Heart Association class III–IV heart failure, left bundle branch block, and persistent atrial fibrillation. Patients with such clinical characteristics need frequent follow up, with strong consideration for more aggressive treatment [86]. Family screening is important, with transthoracic echocardiography being the most common screening modality. Family members may have other forms of cardiomyopathy, like dilated or hypertrophic cardiomyopathy [113]. Recent advances in genetic testing will allow identification of the genetic mutation in the proband and help narrow the search for the genetic mutations.

5. Conclusion

Cardiac Sarcoidosis, arrhythmogenic right ventricular dysplasia and isolated left ventricular noncompaction are rare forms of cardiomyopathy that affect young patients and put them at risk of sudden cardiac death. Early recognition and treatment is important. In the absence of clear guidelines to prevent sudden cardiac death in this young population, the clinician should use current knowledge, clinical judgment and expertise when treating these patients. Advances in diagnostic imaging as well as genetic testing will help early diagnosis and identification of affected family members.

Author details

M. Obadah Al Chekatie

University of Colorado, Cheyenne Regional Medical Center, Cheyenne, Wyoming, USA

References

- [1] Gideon NM, Mannino DM. Sarcoidosis mortality in the United States 1979-1991: an analysis of multiple-cause mortality data. *Am J Med.* 1996;100(4):423-427.
- [2] Rybicki BA, Major M, Popovich J, Jr., Maliarik MJ, Iannuzzi MC. Racial differences in sarcoidosis incidence: a 5-year study in a health maintenance organization. *Am J Epidemiol.* 1997;145(3):234-241.
- [3] Morgenthau AS, Iannuzzi MC. Recent advances in sarcoidosis. *Chest.* 139(1):174-182.
- [4] Izbicki G, Chavko R, Banauch GI, Weiden MD, Berger KI, Aldrich TK, et al. World Trade Center "sarcoid-like" granulomatous pulmonary disease in New York City Fire Department rescue workers. *Chest.* 2007;131(5):1414-1423.
- [5] Song Z, Marzilli L, Greenlee BM, Chen ES, Silver RF, Askin FB, et al. Mycobacterial catalase-peroxidase is a tissue antigen and target of the adaptive immune response in systemic sarcoidosis. *J Exp Med.* 2005;201(5):755-767.
- [6] Rossman MD, Thompson B, Frederick M, Maliarik M, Iannuzzi MC, Rybicki BA, et al. HLA-DRB1*1101: a significant risk factor for sarcoidosis in blacks and whites. *Am J Hum Genet.* 2003;73(4):720-735.
- [7] Iannuzzi MC, Maliarik MJ, Poisson LM, Rybicki BA. Sarcoidosis susceptibility and resistance HLA-DQB1 alleles in African Americans. *Am J Respir Crit Care Med.* 2003;167(9):1225-1231.
- [8] Iannuzzi MC, Iyengar SK, Gray-McGuire C, Elston RC, Baughman RP, Donohue JF, et al. Genome-wide search for sarcoidosis susceptibility genes in African Americans. *Genes Immun.* 2005;6(6):509-518.
- [9] Schurmann M, Reichel P, Muller-Myhsok B, Schlaak M, Muller-Quernheim J, Schwinger E. Results from a genome-wide search for predisposing genes in sarcoidosis. *Am J Respir Crit Care Med.* 2001;164(5):840-846.
- [10] Rybicki BA, Sinha R, Iyengar S, Gray-McGuire C, Elston RC, Iannuzzi MC. Genetic linkage analysis of sarcoidosis phenotypes: the sarcoidosis genetic analysis (SAGA) study. *Genes Immun.* 2007;8(5):379-386.
- [11] Silverman KJ, Hutchins GM, Bulkley BH. Cardiac sarcoid: a clinicopathologic study of 84 unselected patients with systemic sarcoidosis. *Circulation.* 1978;58(6):1204-1211.
- [12] Roberts WC, McAllister HA, Jr., Ferrans VJ. Sarcoidosis of the heart. A clinicopathologic study of 35 necropsy patients (group 1) and review of 78 previously described necropsy patients (group 11). *Am J Med.* 1977;63(1):86-108.
- [13] Patel MR, Cawley PJ, Heitner JF, Klem I, Parker MA, Jaroudi WA, et al. Detection of myocardial damage in patients with sarcoidosis. *Circulation.* 2009;120(20):1969-1977.

- [14] Smedema JP, Snoep G, van Kroonenburgh MP, van Geuns RJ, Dassen WR, Gorgels AP, et al. Evaluation of the accuracy of gadolinium-enhanced cardiovascular magnetic resonance in the diagnosis of cardiac sarcoidosis. *J Am Coll Cardiol.* 2005;45(10):1683-1690.
- [15] Dubrey SW, Falk RH. Diagnosis and management of cardiac sarcoidosis. *Prog Cardiovasc Dis.* 52(4):336-346.
- [16] Kandolin R, Lehtonen J, Kupari M. Cardiac sarcoidosis and giant cell myocarditis as causes of atrioventricular block in young and middle-aged adults. *Circ Arrhythm Electrophysiol.* 4(3):303-309.
- [17] Mehta D, Lubitz SA, Frankel Z, Wisnivesky JP, Einstein AJ, Goldman M, et al. Cardiac involvement in patients with sarcoidosis: diagnostic and prognostic value of outpatient testing. *Chest.* 2008;133(6):1426-1435.
- [18] Hamzeh NY, Wamboldt FS, Weinberger HD. Management of cardiac sarcoidosis in the United States: a Delphi study. *Chest.* 141(1):154-162.
- [19] Iannuzzi MC, Rybicki BA, Teirstein AS. Sarcoidosis. *N Engl J Med.* 2007;357(21):2153-2165.
- [20] Studdy PR, Bird R. Serum angiotensin converting enzyme in sarcoidosis--its value in present clinical practice. *Ann Clin Biochem.* 1989;26 (Pt 1):13-18.
- [21] Soejima K, Yada H. The work-up and management of patients with apparent or sub-clinical cardiac sarcoidosis: with emphasis on the associated heart rhythm abnormalities. *J Cardiovasc Electrophysiol.* 2009;20(5):578-583.
- [22] Schuller JL, Olson MD, Zipse MM, Schneider PM, Aleong RG, Wienberger HD, et al. Electrocardiographic characteristics in patients with pulmonary sarcoidosis indicating cardiac involvement. *J Cardiovasc Electrophysiol.* 22(11):1243-1248.
- [23] Ardehali H, Howard DL, Hariri A, Qasim A, Hare JM, Baughman KL, et al. A positive endomyocardial biopsy result for sarcoid is associated with poor prognosis in patients with initially unexplained cardiomyopathy. *Am Heart J.* 2005;150(3):459-463.
- [24] Okura Y, Dec GW, Hare JM, Kodama M, Berry GJ, Tazelaar HD, et al. A clinical and histopathologic comparison of cardiac sarcoidosis and idiopathic giant cell myocarditis. *J Am Coll Cardiol.* 2003;41(2):322-329.
- [25] Milman N, Andersen CB, Mortensen SA, Sander K. Cardiac sarcoidosis and heart transplantation: a report of four consecutive patients. *Sarcoidosis Vasc Diffuse Lung Dis.* 2008;25(1):51-59.
- [26] Uemura A, Morimoto S, Kato Y, Hiramitsu S, Ohtsuki M, Kato S, et al. Relationship between basal thinning of the interventricular septum and atrioventricular block in patients with cardiac sarcoidosis. *Sarcoidosis Vasc Diffuse Lung Dis.* 2005;22(1):63-65.

- [27] Cross B, Nicolarsen J, Bullock J, Sugeng L, Bardo D, Lang R. Cardiac sarcoidosis presenting as mitral regurgitation. *J Am Soc Echocardiogr.* 2007;20(7):906 e909-913.
- [28] Burstow DJ, Tajik AJ, Bailey KR, DeRemee RA, Taliercio CP. Two-dimensional echocardiographic findings in systemic sarcoidosis. *Am J Cardiol.* 1989;63(7):478-482.
- [29] Vignaux O. Cardiac sarcoidosis: spectrum of MRI features. *AJR Am J Roentgenol.* 2005;184(1):249-254.
- [30] Tadamura E, Yamamuro M, Kubo S, Kanao S, Saga T, Harada M, et al. Effectiveness of delayed enhanced MRI for identification of cardiac sarcoidosis: comparison with radionuclide imaging. *AJR Am J Roentgenol.* 2005;185(1):110-115.
- [31] Smedema JP, Snoep G, van Kroonenburgh MP, van Geuns RJ, Cheriex EC, Gorgels AP, et al. The additional value of gadolinium-enhanced MRI to standard assessment for cardiac involvement in patients with pulmonary sarcoidosis. *Chest.* 2005;128(3):1629-1637.
- [32] Okayama K, Kurata C, Tawarahara K, Wakabayashi Y, Chida K, Sato A. Diagnostic and prognostic value of myocardial scintigraphy with thallium-201 and gallium-67 in cardiac sarcoidosis. *Chest.* 1995;107(2):330-334.
- [33] Alavi A, Palevsky HI. Gallium-67-citrate scanning in the assessment of disease activity in sarcoidosis. *J Nucl Med.* 1992;33(5):751-755.
- [34] Nakazawa A, Ikeda K, Ito Y, Iwase M, Sato K, Ueda R, et al. Usefulness of dual ⁶⁷Ga and ^{99m}Tc-sestamibi single-photon-emission CT scanning in the diagnosis of cardiac sarcoidosis. *Chest.* 2004;126(4):1372-1376.
- [35] Yamagishi H, Shirai N, Takagi M, Yoshiyama M, Akioka K, Takeuchi K, et al. Identification of cardiac sarcoidosis with (13)N-NH(3)/(18)F-FDG PET. *J Nucl Med.* 2003;44(7):1030-1036.
- [36] Kato Y, Morimoto S, Uemura A, Hiramitsu S, Ito T, Hishida H. Efficacy of corticosteroids in sarcoidosis presenting with atrioventricular block. *Sarcoidosis Vasc Diffuse Lung Dis.* 2003;20(2):133-137.
- [37] Winters SL, Cohen M, Greenberg S, Stein B, Curwin J, Pe E, et al. Sustained ventricular tachycardia associated with sarcoidosis: assessment of the underlying cardiac anatomy and the prospective utility of programmed ventricular stimulation, drug therapy and an implantable antitachycardia device. *J Am Coll Cardiol.* 1991;18(4):937-943.
- [38] Hamzeh NY, Wamboldt FS, Weinberger HD. Management of cardiac sarcoidosis in the United States: a Delphi study. *Chest.* 2012;141(1):154-162.
- [39] Epstein AE, DiMarco JP, Ellenbogen KA, Estes NA, 3rd, Freedman RA, Gettes LS, et al. ACC/AHA/HRS 2008 Guidelines for Device-Based Therapy of Cardiac Rhythm Abnormalities: a report of the American College of Cardiology/American Heart Association Task Force on Practice Guidelines (Writing Committee to Revise the

ACC/AHA/NASPE 2002 Guideline Update for Implantation of Cardiac Pacemakers and Antiarrhythmia Devices): developed in collaboration with the American Association for Thoracic Surgery and Society of Thoracic Surgeons. *Circulation*. 2008;117(21):e350-408.

- [40] Kim JS, Judson MA, Donnino R, Gold M, Cooper LT, Jr., Prystowsky EN, et al. Cardiac sarcoidosis. *Am Heart J*. 2009;157(1):9-21.
- [41] Mehta D, Mori N, Goldbarg SH, Lubitz S, Wisnivesky JP, Teirstein A. Primary prevention of sudden cardiac death in silent cardiac sarcoidosis: role of programmed ventricular stimulation. *Circ Arrhythm Electrophysiol*. 2011;4(1):43-48.
- [42] Aizer A, Stern EH, Gomes JA, Teirstein AS, Eckart RE, Mehta D. Usefulness of programmed ventricular stimulation in predicting future arrhythmic events in patients with cardiac sarcoidosis. *Am J Cardiol*. 2005;96(2):276-282.
- [43] Betensky BP, Tschabrunn CM, Zado ES, Goldberg LR, Marchlinski FE, Garcia FC, et al. Long-term follow-up of patients with cardiac sarcoidosis and implantable cardioverter-defibrillators. *Heart Rhythm*. 2012;9(6):884-891.
- [44] Schuller JL, Zipse M, Crawford T, Bogun F, Beshai J, Patel AR, et al. Implantable cardioverter defibrillator therapy in patients with cardiac sarcoidosis. *J Cardiovasc Electrophysiol*. 2012;23(9):925-929.
- [45] Jelic D, Joel B, Good E, Morady F, Rosman H, Knight B, et al. Role of radiofrequency catheter ablation of ventricular tachycardia in cardiac sarcoidosis: report from a multicenter registry. *Heart Rhythm*. 2009;6(2):189-195.
- [46] Zaidi AR, Zaidi A, Vaitkus PT. Outcome of heart transplantation in patients with sarcoid cardiomyopathy. *J Heart Lung Transplant*. 2007;26(7):714-717.
- [47] Sen-Chowdhry S, Lowe MD, Sporton SC, McKenna WJ. Arrhythmogenic right ventricular cardiomyopathy: clinical presentation, diagnosis, and management. *Am J Med*. 2004;117(9):685-695.
- [48] Gemayel C, Pelliccia A, Thompson PD. Arrhythmogenic right ventricular cardiomyopathy. *J Am Coll Cardiol*. 2001;38(7):1773-1781.
- [49] Thiene G, Basso C. Arrhythmogenic right ventricular cardiomyopathy: An update. *Cardiovasc Pathol*. 2001;10(3):109-117.
- [50] den Haan AD, Tan BY, Zikusoka MN, Llado LI, Jain R, Daly A, et al. Comprehensive desmosome mutation analysis in north americans with arrhythmogenic right ventricular dysplasia/cardiomyopathy. *Circ Cardiovasc Genet*. 2009;2(5):428-435.
- [51] Kapplinger JD, Landstrom AP, Salisbury BA, Callis TE, Pollevick GD, Tester DJ, et al. Distinguishing arrhythmogenic right ventricular cardiomyopathy/dysplasia-associated mutations from background genetic noise. *J Am Coll Cardiol*. 2011;57(23):2317-2327.
- [52] Tiso N, Stephan DA, Nava A, Bagattin A, Devaney JM, Stanchi F, et al. Identification of mutations in the cardiac ryanodine receptor gene in families affected with arrhythmogenic right ventricular dysplasia/cardiomyopathy. *Circulation*. 2008;117(21):e350-408.

- mogenic right ventricular cardiomyopathy type 2 (ARVD2). *Hum Mol Genet.* 2001;10(3):189-194.
- [53] Nattel S, Schott JJ. Arrhythmogenic right ventricular dysplasia type 1 and mutations in transforming growth factor beta3 gene regulatory regions: a breakthrough? *Cardiovasc Res.* 2005;65(2):302-304.
- [54] Corrado D, Basso C, Thiene G, McKenna WJ, Davies MJ, Fontaliran F, et al. Spectrum of clinicopathologic manifestations of arrhythmogenic right ventricular cardiomyopathy/dysplasia: a multicenter study. *J Am Coll Cardiol.* 1997;30(6):1512-1520.
- [55] Jain A, Shehata ML, Stuber M, Berkowitz SJ, Calkins H, Lima JA, et al. Prevalence of left ventricular regional dysfunction in arrhythmogenic right ventricular dysplasia: a tagged MRI study. *Circ Cardiovasc Imaging.* 3(3):290-297.
- [56] Marcus FI, McKenna WJ, Sherrill D, Basso C, Bauce B, Bluemke DA, et al. Diagnosis of arrhythmogenic right ventricular cardiomyopathy/dysplasia: proposed modification of the task force criteria. *Circulation.* 121(13):1533-1541.
- [57] Vasaiwala SC, Finn C, Delpriore J, Leya F, Gagermeier J, Akar JG, et al. Prospective study of cardiac sarcoid mimicking arrhythmogenic right ventricular dysplasia. *J Cardiovasc Electrophysiol.* 2009;20(5):473-476.
- [58] Kies P, Bootsma M, Bax J, Schalij MJ, van der Wall EE. Arrhythmogenic right ventricular dysplasia/cardiomyopathy: screening, diagnosis, and treatment. *Heart Rhythm.* 2006;3(2):225-234.
- [59] Peters S, Trummel M, Koehler B. QRS fragmentation in standard ECG as a diagnostic marker of arrhythmogenic right ventricular dysplasia-cardiomyopathy. *Heart Rhythm.* 2008;5(10):1417-1421.
- [60] Jain R, Dalal D, Daly A, Tichnell C, James C, Evenson A, et al. Electrocardiographic features of arrhythmogenic right ventricular dysplasia. *Circulation.* 2009;120(6):477-487.
- [61] Leclercq JF, Potenza S, Maison-Blanche P, Chastang C, Coumel P. Determinants of spontaneous occurrence of sustained monomorphic ventricular tachycardia in right ventricular dysplasia. *J Am Coll Cardiol.* 1996;28(3):720-724.
- [62] Tabib A, Loire R, Chalabreysse L, Meyronnet D, Miras A, Malicier D, et al. Circumstances of death and gross and microscopic observations in a series of 200 cases of sudden death associated with arrhythmogenic right ventricular cardiomyopathy and/or dysplasia. *Circulation.* 2003;108(24):3000-3005.
- [63] Maron BJ. Sudden death in young athletes. *N Engl J Med.* 2003;349(11):1064-1075.
- [64] Maron BJ, Chaitman BR, Ackerman MJ, Bayes de Luna A, Corrado D, Crosson JE, et al. Recommendations for physical activity and recreational sports participation for

young patients with genetic cardiovascular diseases. *Circulation*. 2004;109(22):2807-2816.

- [65] Hoffmayer KS, Machado ON, Marcus GM, Yang Y, Johnson CJ, Ermakov S, et al. Electrocardiographic comparison of ventricular arrhythmias in patients with arrhythmogenic right ventricular cardiomyopathy and right ventricular outflow tract tachycardia. *J Am Coll Cardiol*. 58(8):831-838.
- [66] Yoerger DM, Marcus F, Sherrill D, Calkins H, Towbin JA, Zareba W, et al. Echocardiographic findings in patients meeting task force criteria for arrhythmogenic right ventricular dysplasia: new insights from the multidisciplinary study of right ventricular dysplasia. *J Am Coll Cardiol*. 2005;45(6):860-865.
- [67] Wichter T, Schafers M, Rhodes CG, Borggrefe M, Lerch H, Lammertsma AA, et al. Abnormalities of cardiac sympathetic innervation in arrhythmogenic right ventricular cardiomyopathy : quantitative assessment of presynaptic norepinephrine reuptake and postsynaptic beta-adrenergic receptor density with positron emission tomography. *Circulation*. 2000;101(13):1552-1558.
- [68] Tandri H, Saranathan M, Rodriguez ER, Martinez C, Bomma C, Nasir K, et al. Noninvasive detection of myocardial fibrosis in arrhythmogenic right ventricular cardiomyopathy using delayed-enhancement magnetic resonance imaging. *J Am Coll Cardiol*. 2005;45(1):98-103.
- [69] Bomma C, Rutberg J, Tandri H, Nasir K, Roguin A, Tichnell C, et al. Misdiagnosis of arrhythmogenic right ventricular dysplasia/cardiomyopathy. *J Cardiovasc Electrophysiol*. 2004;15(3):300-306.
- [70] Fattori R, Tricoci P, Russo V, Lovato L, Bacchi-Reggiani L, Gavelli G, et al. Quantification of fatty tissue mass by magnetic resonance imaging in arrhythmogenic right ventricular dysplasia. *J Cardiovasc Electrophysiol*. 2005;16(3):256-261.
- [71] Tandri H, Castillo E, Ferrari VA, Nasir K, Dalal D, Bomma C, et al. Magnetic resonance imaging of arrhythmogenic right ventricular dysplasia: sensitivity, specificity, and observer variability of fat detection versus functional analysis of the right ventricle. *J Am Coll Cardiol*. 2006;48(11):2277-2284.
- [72] Piccini JP, Dalal D, Roguin A, Bomma C, Cheng A, Prakasa K, et al. Predictors of appropriate implantable defibrillator therapies in patients with arrhythmogenic right ventricular dysplasia. *Heart Rhythm*. 2005;2(11):1188-1194.
- [73] Corrado D, Leoni L, Link MS, Della Bella P, Gaita F, Curnis A, et al. Implantable cardioverter-defibrillator therapy for prevention of sudden death in patients with arrhythmogenic right ventricular cardiomyopathy/dysplasia. *Circulation*. 2003;108(25):3084-3091.
- [74] Corrado D, Calkins H, Link MS, Leoni L, Favale S, Bevilacqua M, et al. Prophylactic implantable defibrillator in patients with arrhythmogenic right ventricular cardiomy-

opathy/dysplasia and no prior ventricular fibrillation or sustained ventricular tachycardia. *Circulation*.122(12):1144-1152.

- [75] Corrado D, Basso C, Leoni L, Tokajuk B, Bauce B, Frigo G, et al. Three-dimensional electroanatomic voltage mapping increases accuracy of diagnosing arrhythmogenic right ventricular cardiomyopathy/dysplasia. *Circulation*. 2005;111(23):3042-3050.
- [76] Boulos M, Lashevsky I, Reisner S, Gepstein L. Electroanatomic mapping of arrhythmogenic right ventricular dysplasia. *J Am Coll Cardiol*. 2001;38(7):2020-2027.
- [77] Tandri H, Asimaki A, Abraham T, Dalal D, Tops L, Jain R, et al. Prolonged RV endocardial activation duration: a novel marker of arrhythmogenic right ventricular dysplasia/cardiomyopathy. *Heart Rhythm*. 2009;6(6):769-775.
- [78] Santangeli P, Hamilton-Craig C, Dello Russo A, Pieroni M, Casella M, Pelargonio G, et al. Imaging of scar in patients with ventricular arrhythmias of right ventricular origin: cardiac magnetic resonance versus electroanatomic mapping. *J Cardiovasc Electrophysiol*.22(12):1359-1366.
- [79] Wichter T, Borggrefe M, Haverkamp W, Chen X, Breithardt G. Efficacy of antiarrhythmic drugs in patients with arrhythmogenic right ventricular disease. Results in patients with inducible and noninducible ventricular tachycardia. *Circulation*. 1992;86(1):29-37.
- [80] Marcus GM, Glidden DV, Polonsky B, Zareba W, Smith LM, Cannom DS, et al. Efficacy of antiarrhythmic drugs in arrhythmogenic right ventricular cardiomyopathy: a report from the North American ARVC Registry. *J Am Coll Cardiol*. 2009;54(7):609-615.
- [81] Arbelo E, Josephson ME. Ablation of ventricular arrhythmias in arrhythmogenic right ventricular dysplasia. *J Cardiovasc Electrophysiol*.21(4):473-486.
- [82] Dalal D, Jain R, Tandri H, Dong J, Eid SM, Prakasa K, et al. Long-term efficacy of catheter ablation of ventricular tachycardia in patients with arrhythmogenic right ventricular dysplasia/cardiomyopathy. *J Am Coll Cardiol*. 2007;50(5):432-440.
- [83] Borger van der Burg AE, de Groot NM, van Erven L, Bootsma M, van der Wall EE, Schalij MJ. Long-term follow-up after radiofrequency catheter ablation of ventricular tachycardia: a successful approach? *J Cardiovasc Electrophysiol*. 2002;13(5):417-423.
- [84] Bhonsale A, James CA, Tichnell C, Murray B, Gagarin D, Philips B, et al. Incidence and predictors of implantable cardioverter-defibrillator therapy in patients with arrhythmogenic right ventricular dysplasia/cardiomyopathy undergoing implantable cardioverter-defibrillator implantation for primary prevention. *J Am Coll Cardiol*. 58(14):1485-1496.
- [85] Lemola K, Brunckhorst C, Helfenstein U, Oechslin E, Jenni R, Duru F. Predictors of adverse outcome in patients with arrhythmogenic right ventricular dysplasia/cardiomyopathy: long term experience of a tertiary care centre. *Heart*. 2005;91(9):1167-1172.

- [86] Oechslin EN, Attenhofer Jost CH, Rojas JR, Kaufmann PA, Jenni R. Long-term follow-up of 34 adults with isolated left ventricular noncompaction: a distinct cardiomyopathy with poor prognosis. *J Am Coll Cardiol*. 2000;36(2):493-500.
- [87] Ichida F, Hamamichi Y, Miyawaki T, Ono Y, Kamiya T, Akagi T, et al. Clinical features of isolated noncompaction of the ventricular myocardium: long-term clinical course, hemodynamic properties, and genetic background. *J Am Coll Cardiol*. 1999;34(1):233-240.
- [88] Pignatelli RH, McMahon CJ, Dreyer WJ, Denfield SW, Price J, Belmont JW, et al. Clinical characterization of left ventricular noncompaction in children: a relatively common form of cardiomyopathy. *Circulation*. 2003;108(21):2672-2678.
- [89] Peters F, Khandheria BK, dos Santos C, Matioda H, Maharaj N, Libhaber E, et al. Isolated left ventricular noncompaction in sub-Saharan Africa: a clinical and echocardiographic perspective. *Circ Cardiovasc Imaging*. 2005;5(2):187-193.
- [90] Dusek J, Ostadal B, Duskova M. Postnatal persistence of spongy myocardium with embryonic blood supply. *Arch Pathol*. 1975;99(6):312-317.
- [91] Weiford BC, Subbarao VD, Mulhern KM. Noncompaction of the ventricular myocardium. *Circulation*. 2004;109(24):2965-2971.
- [92] Jenni R, Wyss CA, Oechslin EN, Kaufmann PA. Isolated ventricular noncompaction is associated with coronary microcirculatory dysfunction. *J Am Coll Cardiol*. 2002;39(3):450-454.
- [93] Chin TK, Perloff JK, Williams RG, Jue K, Mohrmann R. Isolated noncompaction of left ventricular myocardium. A study of eight cases. *Circulation*. 1990;82(2):507-513.
- [94] Bleyl SB, Mumford BR, Brown-Harrison MC, Pagotto LT, Carey JC, Pysher TJ, et al. Xq28-linked noncompaction of the left ventricular myocardium: prenatal diagnosis and pathologic analysis of affected individuals. *Am J Med Genet*. 1997;72(3):257-265.
- [95] Ichida F, Tsubata S, Bowles KR, Haneda N, Uese K, Miyawaki T, et al. Novel gene mutations in patients with left ventricular noncompaction or Barth syndrome. *Circulation*. 2001;103(9):1256-1263.
- [96] Sasse-Klaassen S, Probst S, Gerull B, Oechslin E, Nurnberg P, Heuser A, et al. Novel gene locus for autosomal dominant left ventricular noncompaction maps to chromosome 11p15. *Circulation*. 2004;109(22):2720-2723.
- [97] Vatta M, Mohapatra B, Jimenez S, Sanchez X, Faulkner G, Perles Z, et al. Mutations in Cypher/ZASP in patients with dilated cardiomyopathy and left ventricular noncompaction. *J Am Coll Cardiol*. 2003;42(11):2014-2027.
- [98] Klaassen S, Probst S, Oechslin E, Gerull B, Krings G, Schuler P, et al. Mutations in sarcomere protein genes in left ventricular noncompaction. *Circulation*. 2008;117(22):2893-2901.

- [99] Probst S, Oechslin E, Schuler P, Greutmann M, Boye P, Knirsch W, et al. Sarcomere gene mutations in isolated left ventricular noncompaction cardiomyopathy do not predict clinical phenotype. *Circ Cardiovasc Genet*.4(4):367-374.
- [100] Fazio G, Sutera L, Corrado G, Novo S. The chronic heart failure is not so frequent in non-compaction. *Eur Heart J*. 2007;28(10):1269; author reply 1269-1270.
- [101] Ritter M, Oechslin E, Sutsch G, Attenhofer C, Schneider J, Jenni R. Isolated noncompaction of the myocardium in adults. *Mayo Clin Proc*. 1997;72(1):26-31.
- [102] Caliskan K, Ujvari B, Bauernfeind T, Theuns DA, Van Domburg RT, Akca F, et al. The prevalence of early repolarization in patients with noncompaction cardiomyopathy presenting with malignant ventricular arrhythmias. *J Cardiovasc Electrophysiol*. 23(9):938-944.
- [103] Paterick TE, Umland MM, Jan MF, Ammar KA, Kramer C, Khandheria BK, et al. Left ventricular noncompaction: a 25-year odyssey. *J Am Soc Echocardiogr*.25(4):363-375.
- [104] Jenni R, Oechslin E, Schneider J, Attenhofer Jost C, Kaufmann PA. Echocardiographic and pathoanatomical characteristics of isolated left ventricular non-compaction: a step towards classification as a distinct cardiomyopathy. *Heart*. 2001;86(6):666-671.
- [105] Kohli SK, Pantazis AA, Shah JS, Adeyemi B, Jackson G, McKenna WJ, et al. Diagnosis of left-ventricular non-compaction in patients with left-ventricular systolic dysfunction: time for a reappraisal of diagnostic criteria? *Eur Heart J*. 2008;29(1):89-95.
- [106] Chaowu Y, Li L, Shihua Z. Histopathological features of delayed enhancement cardiovascular magnetic resonance in isolated left ventricular noncompaction. *J Am Coll Cardiol*.58(3):311-312.
- [107] Petersen SE, Selvanayagam JB, Wiesmann F, Robson MD, Francis JM, Anderson RH, et al. Left ventricular non-compaction: insights from cardiovascular magnetic resonance imaging. *J Am Coll Cardiol*. 2005;46(1):101-105.
- [108] Kawel N, Nacif M, Arai AE, Gomes AS, Hundley WG, Johnson WC, et al. Trabeculated (noncompacted) and compact myocardium in adults: the multi-ethnic study of atherosclerosis. *Circ Cardiovasc Imaging*.5(3):357-366.
- [109] Jacquier A, Thuny F, Jop B, Giorgi R, Cohen F, Gaubert JY, et al. Measurement of trabeculated left ventricular mass using cardiac magnetic resonance imaging in the diagnosis of left ventricular non-compaction. *Eur Heart J*.31(9):1098-1104.
- [110] Junga G, Kneifel S, Von Smekal A, Steinert H, Bauersfeld U. Myocardial ischaemia in children with isolated ventricular non-compaction. *Eur Heart J*. 1999;20(12):910-916.
- [111] Toyono M, Kondo C, Nakajima Y, Nakazawa M, Momma K, Kusakabe K. Effects of carvedilol on left ventricular function, mass, and scintigraphic findings in isolated left ventricular non-compaction. *Heart*. 2001;86(1):E4.

- [112] Kobza R, Steffel J, Erne P, Schoenenberger AW, Hurlimann D, Luscher TF, et al. Implantable cardioverter-defibrillator and cardiac resynchronization therapy in patients with left ventricular noncompaction. *Heart Rhythm*.7(11):1545-1549.
- [113] Murphy RT, Thaman R, Blanes JG, Ward D, Sevdalis E, Papra E, et al. Natural history and familial characteristics of isolated left ventricular non-compaction. *Eur Heart J*. 2005;26(2):187-192.

