

We are IntechOpen, the world's leading publisher of Open Access books Built by scientists, for scientists

6,900

Open access books available

185,000

International authors and editors

200M

Downloads

Our authors are among the

154

Countries delivered to

TOP 1%

most cited scientists

12.2%

Contributors from top 500 universities



WEB OF SCIENCE™

Selection of our books indexed in the Book Citation Index
in Web of Science™ Core Collection (BKCI)

Interested in publishing with us?
Contact book.department@intechopen.com

Numbers displayed above are based on latest data collected.
For more information visit www.intechopen.com



Hyperthermia Tissue Ablation in Radiology

Ragab Hani Donkol and Ahmed Al Nammi

Additional information is available at the end of the chapter

<http://dx.doi.org/10.5772/52274>

1. Introduction

Hyperthermia is part of thermal medicine, in which increasing body or tissue temperature used for the treatment of diseases. It can be traced back to the earliest practice of medicine. Cultures from around the world can point to ancient uses of hot therapy for specific medical applications. As mentioned in the foregoing books, cauterization is the first application of hyperthermia in medicine. Cauterization can be done by heat, or by chemicals such as caustics. Al-Zahrawi - an ancient Arabic scientist- generally preferred the former for the use of cauterization in treatment of diseases (1). Depending on the nature of the disease, the patient's temperament and the weather condition, different kinds of metals such as bronze, iron and gold could be used. The important considerations in the procedure include the shape of the cautery, the site of cauterization and the number of exposures. Many of the cauteries were taken from the Greeks, but Al-Zahrawi takes an independent line while describing cauterization for hare-lip, entropion, pulmonary disease, pre-anal fistula, dislocation of femur, back pain, headache, ptosis, perianal fistulae, humeral dislocation, sciatica and face swellings (fig 1).

Modern research in thermal medicine aims to understand molecular, cellular and physiological effects of temperature manipulation and the “stress” response, as well as to develop effective and safe equipment for clinical application and temperature monitoring. As a result, today there are a growing number of clinical applications of thermal therapy that benefit patients with a variety of diseases. Remarkable progress in engineering, radiology and physics over the past decades has led to the implementation of clinical trials that are revealing the true potential of hyperthermia for the treatment of different disease. Hyperthermia ablation (e.g. by radiofrequency electric current, microwaves, laser, or ultrasound), whereby localized heating destroys tissue is now used worldwide for tumors treatment and many other important medical applications. In most circumstances thermal ablation is used under guidance of different radiological modalities such as ultrasound (US), computed tomography (CT) or magnetic resonance imaging (MRI). Thermal ablation is a



Figure 1. Technique of Cauterization by fire for a patient with neck swelling (1)

minimally invasive procedure that significantly reduces risks and speeds recovery. So, it provides an excellent safe alternative to major surgery. The primary advantage of percutaneous radiofrequency thermal ablation is a reduction in the need for post-operative hospitalization and a reduced duration of convalescence. In this chapter, we will review the recent application of hyperthermia medicine in treatment of different disease under the guidance of different radiological modalities. In this chapter, we will provide a clearer picture of the intimate relation between hyperthermia, radiology and medical imaging. We will discuss the multiple facets of tumor growth and the tumor microenvironment that can be impacted by heat during hyperthermia medicine. We will emphasize the approved clinical application of hyperthermia in management of growing number of patients with a variety of diseases. We also discuss other experimental and investigational trial studies that can be used effectively in the future for management of other clinical conditions. Also we will emphasize the adjuvant role of thermal therapy in combination with radiotherapy and chemotherapy in management of cancer. Finally, we will elaborate the exciting new generation of clinical trials of heat-activated drug delivery.

2. Various energy sources of hyperthermia

Various energy sources including laser, ultrasound, microwaves, and radiofrequency electric current are being investigated as minimally invasive, and potentially non-invasive therapies. There are two types of thermal ablation: radiofrequency (RFA) and microwave.

Both are minimally invasive techniques that treat lesions by applying intense heat through a small probe inserted directly into the tumor. Hyperthermia can be either superficial, produced by a microwave generator, or regional, produced by a radiofrequency applicator with multiple antennas, which emanate a deep focalized heating, saving the skin, or interstitial heating. In all these systems the radiations are non-ionizing, in which the energy presents a heterogeneous distribution inside the tissues, depending on their thermal characteristics and on blood perfusion. Radiofrequency ablation (RFA) involves percutaneous or intra-operative insertion of an electrode into a lesion under ultrasonic or CT guidance. Radiofrequency energy is emitted through the electrode and generates heat, leading to coagulative necrosis of the tissue.

3. Rational of tissue necrosis (ablation) in hyperthermia medicine

Modern research in thermal medicine aims to understand molecular, cellular and physiological effects of temperature manipulation and the “stress” response, as well as to develop effective and safe equipment for clinical application and temperature monitoring. Multiple facets of tumor growth and the tumor microenvironment, including vascular perfusion, heat shock protein expression, endothelial/stromal cells, hypoxia, immune cells, pro-inflammatory cytokines, are impacted by heat and these effects may underlie remarkable successes being obtained in a surge of clinical trials throughout the world. Thermal ablation whereby tissue is destroyed by localized heating or freezing, is now used worldwide for treatment of many benign and malignant tumors and several other important medical applications (2-4).

The main actions of hyperthermia in the neoplastic tissues are the following:

- Greater heat sensitivity of neoplastic tissues to hyperthermia, due to its chronic ischemia, hypoxia and acid pH;
- Lethal effect of temperature of 42-43 °C on tumor cells, depending on the application time;
- Temporary growth stabilization of tumor cells after a moderate hyperthermia (39-41 °C);
- Prolonged action of temperature, due to lower thermal dissipation, caused by a chronic ischemia inside the tumor, as a result of its reduced vessel regulation mechanisms;
- Alterations in the neoplastic cell cycle, which lead to the blocking of mitosis, due to a disruption in the S phase;
- Marked action on the core of the tumor, less sensitive to radiation because of ischemia, hypoxia and low pH;
- action in favor of apoptosis mechanisms.

4. Common clinical application of hyperthermia therapy:

Today there are a growing number of clinical applications of thermal therapy that benefit patients with a variety of diseases. Several studies have been published reporting efficacy of RFA in treatment of many different clinical conditions.

Several studies have been published reporting successful use of radiofrequency ablation in the following conditions: as an alternative to surgical resection for debulking of primary and metastatic malignant neoplasms, removal of primary or metastatic malignant neoplasms, treatment of distant metastases of medullary thyroid carcinoma, treatment of metastatic gastrointestinal stromal tumors (GIST) with limited progression, treatment of osteoid osteoma, as a less invasive alternative to surgical resection of the tumor, treatment of soft tissue sarcoma of the trunk or extremities in symptomatic persons with disseminated metastases and many other condition.

There is growing research and experimental and investigational studies interest in the use of hyperthermia for treatment of many other clinical conditions. But these studies need to improve its clinical outcomes to be implemented in the practical life. Examples of these studies include; curative treatment of primary or metastatic malignant neoplasms (e.g., breast cancer, kidney cancer including renal angiomyolipoma, lung cancer, and pancreatic cancer) in persons who are able to tolerate surgical resection, treatment of malignant bile duct obstruction due to insufficient evidence in the peer-reviewed literature. Treatment of Barrett's esophagus, treatment of hepatic tumors, treatment of benign prostatic hypertrophy (transurethral needle ablation or TUNA), cardiac catheter thermal ablation is now standard of care for a variety of cardiac arrhythmia types (irregular heart beat rhythm), endometrial ablation is clinically used to treat endometrial bleeding, intravascular heating can eliminate varicose veins with laser or radiofrequency current, laser and other thermal methods treat excessive subcutaneous fat, which can contribute to obesity and metabolic disorders including diabetes. Hyperthermia can also be used to activate cytotoxic effects of chemotherapy within tumors, thereby sparing normal tissue, when the drugs are encapsulated in thermally sensitive nanoparticles. As a result of these and other clinical applications, combined with a rapidly expanding research base, interest in thermal medicine is rapidly growing, attracting the attention of laboratory and clinical researchers, physicians, engineers, physicists and biotechnologists

4.1. Radiofrequency ablation of osteoid osteoma

Osteoid osteoma, a benign tumor of the bone. It is the third most common primary benign bone tumor, representing approximately 10–12% of benign bone tumors. It generally affects children and young adults. Approximately 80% of patients are between 5 and 24 years of age, with a male: female ratio of 3:1. Clinically, pain is the most common presenting symptom and is described as severe, sharp, boring, and typically worse at night, and improves with nonsteroidal anti-inflammatory drugs [5]. The growth potential of these benign lesions is limited, with a maximum diameter rarely exceeding 15 mm. However, the inflammatory response leads to the characteristic severe pain. The consequences of these lesions include growth deformities when tumors are located in the long bones and scoliosis when the posterior elements of the spine are involved [6]. Patients who cannot tolerate the symptoms or nonsteroidal anti-inflammatory drugs require intervention for pain relief and/or to prevent growth disturbance. Traditionally, surgical resection was the treatment of choice. During open surgery the nidus of the tumor is often difficult to visualize and to

prevent recurrence a wide resection margin may be required. This results in many complications such as hematoma, infection, and fracture. In addition, surgical treatment may require a long period of hospitalization, a period during which the patient cannot bear weight on the affected limb resulting in delayed resumption of physical activity [7]. The optimal method of treatment for osteoid osteoma would involve minimization of bone removal with avoidance of grafting and fixation while ensuring complete destruction of the tumor nidus in a single session. During the past two decades, many attempts have been made to minimize bone removal to decrease the risk of postoperative complications. Percutaneous resection utilizing CT guidance to guide trephines and drills has been described. However, the complication rates are as high as 24% and include fractures, muscular haematomas, paraesthesia, skin burns, transient paresis, and osteomyelitis [8]. Radiofrequency ablation has proved to be an effective method for the treatment of many malignant and benign tumors. RF ablation for the treatment of osteoid osteoma was first described in a four-patient series in 1992 [9]. Since the promising results of Rosenthal et al in the management of osteoid osteoma with RF ablation a large number of studies evaluating RF ablation of osteoid osteoma have been reported in the peer-reviewed medical literature. Most of these studies found very high technical success rates (100%) and good primary success rates with a single session of ablation ranging from 76% to 100% (fig 2 and fig 3). Today, percutaneous CT-guided RF ablation is an effective and safe minimally invasive procedure for the treatment of osteoid osteoma in all ages. It has high technical and clinical success rates (10-12)

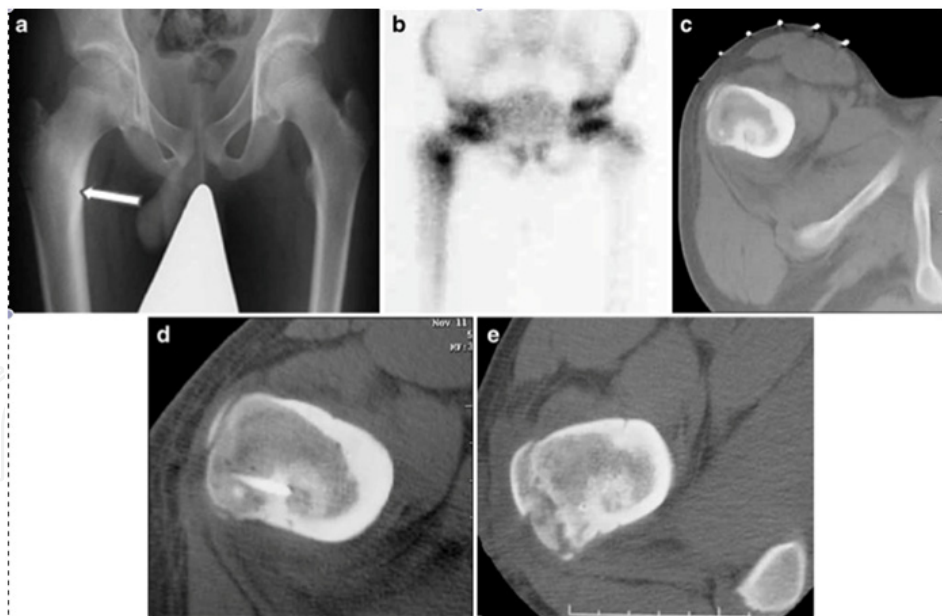

Figure 2. Technique of RFA of osteoid osteoma in a 12-year-boy with chronic right hip pain. a Radiograph of the pelvis shows an ill-defined area of dense sclerosis in the medial aspect of the proximal femoral shaft (arrow). b Bone scan shows active uptake at the site of the dense sclerosis consistent with the diagnosis of osteoid osteoma. c CT scan shows the nidus located deep to the cortex and surrounded by dense new bone. The radiopaque markers on the skin surface are for planning the skin entry point. d Axial 1-mm CT slice shows the correct position of the tip of the RF electrode within the centre of the nidus. e Follow-up CT after 15 months shows sclerosis within the nidus (12)

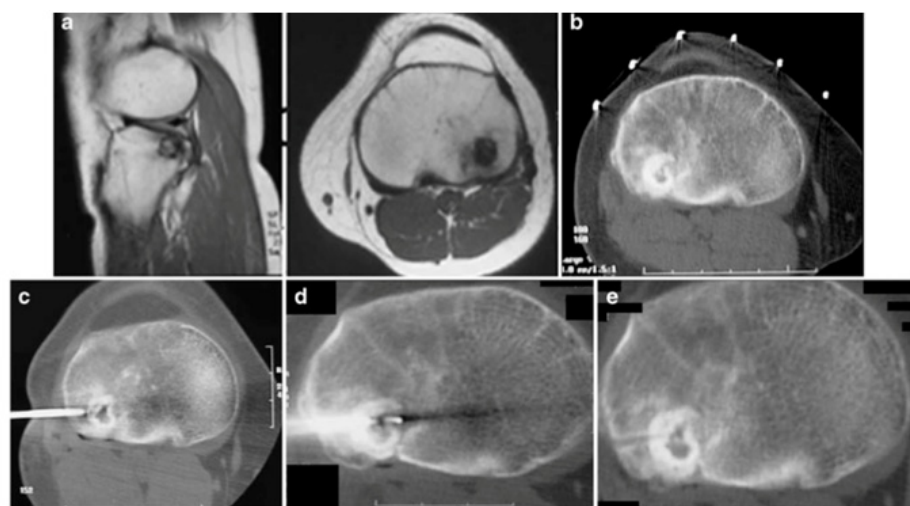


Figure 3. RFA of osteoid osteoma in a 14-year-old girl. a MR images shows a small, well-defined lesion in the proximal tibial epiphysis. b CT during percutaneous RF ablation shows a radiolucent nidus with central calcification surrounded by a dense rim of sclerosis. Note markers for planning the skin entry point. c CT shows the bone biopsy probe tip at the margin of the nidus. d CT shows the tip of the RF electrode within the nidus after slight withdrawal of the penetrating cannula. e Control image obtained immediately after the intervention shows the biopsy tract with no bleeding(12)

4.2. Radiofrequency ablation of pulmonary tumors

Radiofrequency ablation has been advocated as an alternative to resection in persons with lung nodules who cannot be treated surgically because of medical problems, multiple tumors, or poor surgical risk. There are, however, no adequate prospective clinical studies that demonstrate that RFA of lung metastases is as effective as surgical (cold knife) resection in curative resection of malignant neoplasms. An important concern is that RFA does not allow for examination of surgical margins to ensure that cancer is completely resected. Le and Petrik considered RFA as a promising technique for the treatment of early states (state I and stage II) non-small cell lung cancer (13). An assessment by the National Institute for Health and Clinical Excellence (NICE, 2006) concluded: "Current evidence on the safety and efficacy of percutaneous radiofrequency ablation for primary and secondary lung cancers shows that there are no major safety concerns with this procedure. There is evidence that the treatment can reduce tumor bulk; however, this evidence is limited and is based on heterogeneous indications for treatment. The procedure should therefore be used only with special arrangements for consent, audit and clinical governance (14). "The Food and Drug Administration (FDA) has issued a Public Health Notification as clarification for healthcare providers that no RFA devices are specifically approved for use in partial or full ablation of lung tumors (15). Radiofrequency ablation devices are minimally invasive tools used for general removal of soft tissue, such as those that contain cancer cells. It is an image-guided technique that heats and destroys cancer cells. Imaging techniques such as ultrasound and computed tomography (CT) are used to help guide a needle electrode into a cancerous tumor. High-frequency electrical currents are then passed through the electrode, creating heat that destroys the abnormal cells.

4.3. Radiofrequency ablation of pancreatic cancer

Radiofrequency ablation has been used as a treatment of pancreatic cancer for a number of years in Japan. Current evidence of effectiveness of RFA for pancreatic cancer consists of case reports and a phase II (safety) study; the latter concluded that RFA was a relatively safe treatment for pancreatic cancer. However, this evidence is insufficient to draw conclusions about the effectiveness of RFA for this indication. Girelli et al (2010) examined the feasibility and safety of RFA as a treatment option for locally advanced pancreatic cancer. A total of 50 patients with locally advanced pancreatic cancer were studied prospectively. Ultrasound-guided RFA was performed during laparotomy. The main outcome measures were short-term morbidity and mortality. The tumor was located in the pancreatic head or uncinate process in 34 patients and in the body or tail in 16; median diameter was 40 (inter-quartile range [IQR] of 30 to 50) mm. Radiofrequency ablation was the only treatment in 19 patients; it was combined with biliary and gastric bypass in 19 patients, gastric bypass alone in 8, biliary bypass alone in 3 and pancreatico-jejunostomy in 1. The 30-day mortality rate was 2 %. Abdominal complications occurred in 24 % of patients; in half they were directly associated with RFA and treated conservatively. Three patients with surgery-related complications needed re-operation. Reduction of RFA temperature from 105 degrees C to 90 degrees C resulted in a significant reduction in complications (10 versus 2 of 25 patients; $p = 0.028$). Median post-operative hospital stay was 10 (range of 7 to 31) days. The authors concluded that RFA of locally advanced pancreatic cancer is feasible and relatively well tolerated, with a 24 % complication rate. This was a feasibility and safety study; it did not provide any data on the effectiveness of RFA in treating pancreatic cancer (16).

4.4. Radiofrequency ablation of renal tumors

Several authorities have noted that RFA of renal tumors is a promising investigational alternative to partial or total nephrectomy. Studies performed have focused on the technical feasibility of RFA of renal tumors. Prospective clinical studies are needed to determine if RFA of renal cell carcinomas improve survival and are as effective as total or partial nephrectomy (17-18)

An assessment conducted by the National Institute for Clinical Excellence in 2010 reached the following conclusions about RFA of renal tumors: " A meta-analysis of 47 studies (non-randomized comparative studies and case series) including a total of 1375 tumors treated by RFA ($n = 775$) or cryoablation ($n = 600$) reported local tumor progression (defined as radiographic or pathological evidence of residual disease after initial treatment, regardless of time to recurrence) in 13% (100/775) and 5% (31/600) of tumors respectively at a mean 19-month follow-up ($p < 0.001$). The meta-analysis reported progression to metastatic disease in 2% (19/775) of tumors treated by RFA and 1% (6/600) of tumors treated by cryoablation® ($p =$ not significant)" (19). Another assessment of the evidence for RFA of kidney cancer prepared by the Canadian Coordinating Office for Health Technology Assessment (20) reached the following conclusions: "RFA is emerging as a useful alternative to nephrectomy in the management of some types of kidney cancer. It appears to be useful for smaller, non-central

tumors, and for cases where surgery is contraindicated. A disadvantage is the possibility of residual cancer that cannot be detected by diagnostic imaging during follow-up. There are no results from randomized trials, and the period of follow-up for patients who have had the procedure is short. Only with longer follow-up evaluations (five years to 10 years) will relevant comparison with radical and partial nephrectomy be possible."

Furthermore, Hinshaw and Lee stated that RFA, cryoablation, microwave ablation, and laser ablation have all shown promise for the treatment of renal cell carcinomas (RCC), with high local control and low complication rates for RFA and cryoablation. However, the clinical trial data remain early, and survival data are not yet available for a definitive comparison with conventional surgical techniques for removal of RCC (21). Mahnken noted that the increasing number of clinical reports on RFA of the kidney show the promising potential of renal RFA for minimally invasive tumor treatment. Due to its technical benefits, RFA seems to be advantageous when compared to cryoablation or laser ablation. However, there are no long-term follow-up or comparative data proving an equal effectiveness to surgery (22) .

In a systematic review on focal therapy for kidney cancer, Kutikov and colleagues stated that most cryoablations are performed using a laparoscopic approach, whereas RFA of the localized small renal masses (SRM) is more commonly administered percutaneously. Pre-treatment biopsy is performed more often for lesions treated by cryoablation than RFA with a significantly higher rate of indeterminate or unknown pathology for SRMs undergoing RFA versus cryoablation ($p < 0.0001$). Currently available data suggest that cryoablation results in lower re-treatments ($p < 0.0001$), less local tumor progressions ($p < 0.0001$) and may be associated with a decreased risk of metastatic progression compared with RFA. It is unclear if these differences are a function of the technologies or their application. The extent to which focal ablation alters the natural history of SRMs has not yet been established. The authors concluded that currently, data on the ability of interventions for SRMs to affect the natural history of these masses are lacking. They stated that prospective randomized evaluations of available clinical approaches to SRMs are needed (23). A Cochrane systematic evidence review (24) of surgical management of localized renal cell carcinoma found that the main source of evidence for the current practice of laparoscopic excision of renal cancer is drawn from case series, small retrospective studies and very few small-randomized controlled trials. "The results and conclusions of these studies must therefore be interpreted with caution." The authors of the systematic evidence review did not identify any randomized trials meeting the inclusion criteria reporting on the comparison between open radical nephrectomy with laparoscopic approach or new modalities of treatment such as RFA or cryoablation. Three randomized controlled trials compared the different laparoscopic approaches to nephrectomy (transperitoneal versus retroperitoneal) and found no statistical difference in operative or peri-operative outcomes between the two treatment groups. There were several non-randomized and retrospective case series reporting various advantages of laparoscopic renal cancer surgery such as less blood loss, early recovery and shorter hospital stay.

Sooriakumaran and co-workers examined the presentation, management and outcomes of patients with renal angiomyolipoma (AML) over a period of 10 years. These investigators evaluated retrospectively 102 patients (median follow-up of 4 years); 70 had tuberous

sclerosis complex (TSC; median tumor size of 3.5 cm) and the other 32 were sporadic (median tumor size of 1.2 cm). Data were gathered from several sources, including radiology and clinical genetics databases. The 77 patients with stable disease were followed-up with surveillance imaging, and 25 received interventions, some more than one. Indications for intervention included spontaneous life-threatening hemorrhage, large AML (10 to 20 cm), pain and visceral compressive symptoms. Selective arterial embolization (SAE) was performed in 19 patients; 10 received operative management and 4 had a RFA. Selective arterial embolization was effective in controlling hemorrhage from AMLs in the acute setting ($n = 6$) but some patients required further intervention ($n = 4$) and there was a significant complication rate. The reduction in tumor volume was only modest (28 %). No complications occurred after surgery (median follow-up of 5.5 years) or RFA (median follow-up of 9 months). One patient was entered into a trial and treated with sirolimus (rapamycin). The authors concluded that the management of AML is both complex and challenging, especially in those with TSC, where tumors are usually larger and multiple. Although SAE was effective at controlling hemorrhage in the acute setting it was deemed to be of limited value in the longer-term management of these tumors. Thus, novel techniques such as focused ablation and pharmacotherapies including the use of anti-angiogenic molecules and mammalian target of rapamycin inhibitors, which might prove to be safer and equally effective, should be further explored (25).

4.5. Radiofrequency ablation of bone metastases

Radiofrequency ablation has also been used to treat bone metastases. However, there are no adequate clinical studies reported in the literature on the use of RFA of metastatic lesions to bone. In a review of the evidence on RFA of tumors, Wood et al concluded “more rigorous scientific review, long-term follow-up, and randomized prospective trials are needed to help define the role of RFA in oncology” (26). Rhim noted that although RFA represents a paradigm shift in local therapy for many commonly seen tumors, more sophisticated strategies to enhance the therapeutic effectiveness are needed and more randomized, controlled trials to estimate its clinical benefit are warranted (27).

4.6. Radiofrequency ablation of breast cancer

One of the first attempts to use hyperthermia in treatment of breast cancer was in 2001 by Hilger et al (28). They studied the parameters for the minimally invasive elimination of breast tumors by using a selective application of magnetite and exposure of the breast to an alternating magnetic field. Temperature elevations based on magnetite mass (7–112 mg) and magnetic field amplitude (1.2–6.5 kA/m; frequency, 400 kHz). They observed that a mean temperature of $71^{\circ}\text{C} \pm 8$ was recorded in the tumor region at the end of magnetic field exposure of the mice. Typical macroscopic findings included tumor shrinkage after heating. Histologically nuclear degenerations were observed in heated malignant cells. They concluded that magnetic heating of breast tumors is a promising technique for future interventional radiologic treatments. Agnese and Burak stated that ablative therapies, including RFA have been shown promise in the treatment of small cancers of the breast. However, more research is needed to ascertain the

effectiveness of these techniques when they are used as the sole therapy and to determine the long-term local recurrence rates and survival associated with these treatment strategies (29). van der Ploeg et al in 2007 reviewed the literature on the use of RFA for the treatment of small breast carcinoma. The authors concluded that RFA is a promising new tool for minimally invasive ablation of small carcinomas of the breast. They noted that a large randomized control study is needed to ascertain the long-term advantages of RFA compared to the current breast conserving therapies (30).

4.7. Radiofrequency ablation of a parathyroid adenoma

One of the methods of nonsurgical parathyroid ablation is percutaneous thermal ablation, such as laser or radiofrequency ablation. Percutaneous laser and radiofrequency ablation of parathyroid adenomas has been limited to case reports and small-series cases [31–32]. The ultimate utility of thermal ablation has yet to be determined but because it continues to be refined, it does hold promise as a method for treatment of parathyroid disease when surgery is not indicated. RFA can be a therapeutic alternative for patients with contraindications for surgery. Usually after percutaneous ultrasound guided RFTA of the adenoma of the parathyroid gland, the serum parathormone levels and the serum calcium levels dropped back to normal in most of patients (fig 4). Recurrent hyperparathyroidism is rare following transcatheter ablation of mediastinal parathyroid adenomas. When it occurs it is usually early and resistant to further attempts at ablation (33)

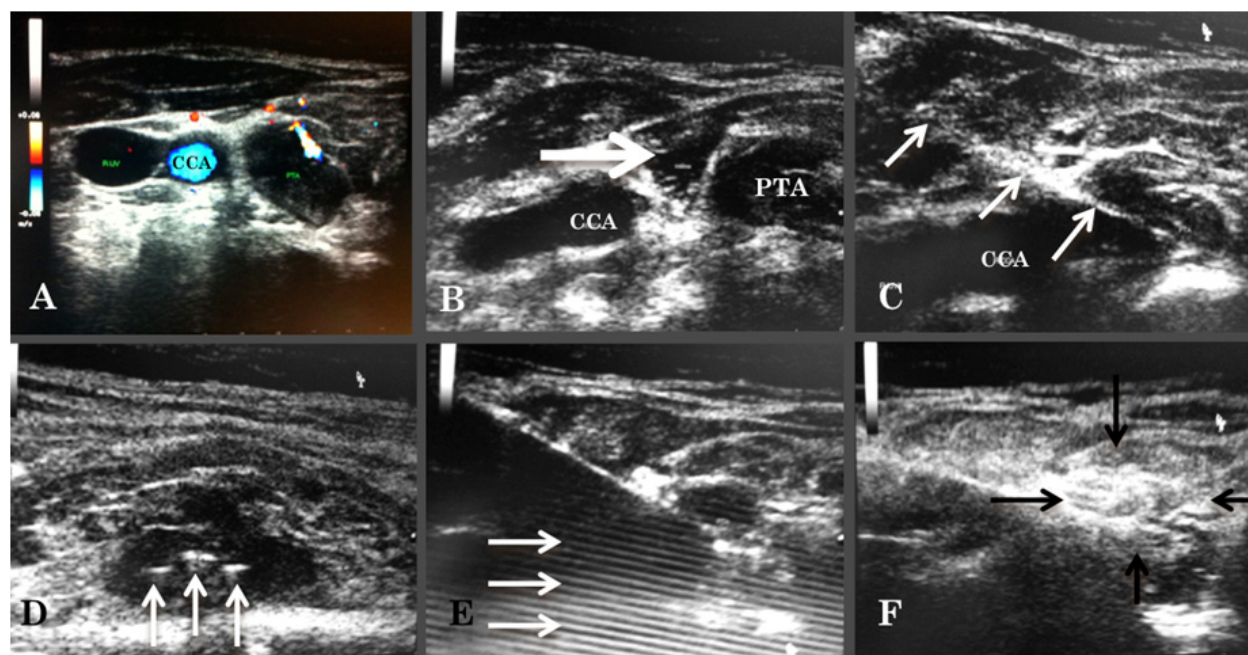


Figure 4. Radiofrequency ablation of parathyroid adenoma .A, Transverse sonogram of neck shows 15x10-mm right inferior parathyroid adenoma (PTA) .B; Sonogram of the neck after inflation of 5 ml saline (white arrow) to separate the PTA from the right common carotid artery (CCA). C ; Sonogram shows 25-gauge needle (arrows) inserted into parathyroid adenoma . D; Sonogram shows fans (arrows) of the radiofrequency probe within the PTA . E ; Sonogram during RFA of PTA shows reverberation artifacts (arrows) posterior to the needle) . F; Sonogram at the total RFA of the PTA, The ablated gland (arrows) appears echogenic.

4.8. RFA in management of Barrett's esophagus

Barrett's esophagus (BE) is defined as the presence of specialized intestinal metaplasia within the esophagus, and it is the pre-malignant precursor of esophageal adenocarcinoma. Esophageal cancer is one of the most deadly gastrointestinal cancers with a mortality rate over 90 %. The principal risk factors for esophageal adenocarcinoma are gastroesophageal reflux disease (GERD) and its sequela, BE. Gastroesophageal reflux disease usually leads to esophagitis. However, in a minority of patients, ongoing GERD leads to replacement of esophageal squamous mucosa with metaplastic, intestinal-type Barrett's mucosa. In the setting of continued peptic injury, Barrett's mucosa can give rise to esophageal adenocarcinoma (34). A new method of endoscopic ablation of BE is balloon-based, bipolar RFA (Stellartech Research Coagulation System; BARRx, Inc, Sunnyvale, Calif), also known as Barrett's endoscopy. This technique requires the use of sizing balloons to determine the inner diameter of the targeted portion of the esophagus. This is followed by placement of a balloon-based electrode with a 3-cm long treatment area that incorporates tightly spaced, bipolar electrodes that alternate in polarity. The electrode is then attached to a radiofrequency generator and a preselected amount of energy is delivered in less than 1 second at 350 W. In a review of evidence on ablative techniques for BE, Johnston stated that it is not clear which of the numerous endoscopic ablative techniques available -- photodynamic therapy, laser therapy, multi-polar electrocoagulation, argon plasma coagulation, endoscopic mucosal resection, RFA or cryotherapy -- will emerge as superior for treatment of BE. In addition, it has yet to be determined whether the risks associated with ablation therapy is less than the risk of BE progressing to cancer. Whether ablation therapy eliminates or significantly reduces the risk of cancer, eliminates the need for surveillance endoscopy, or is cost-effective, also remains to be seen. Comparative trials that are now underway should help to answer these questions (35). Hubbard and Velanovich stated that endoscopic endoluminal RFA using the Barrx device (Barrx Medical, Sunnyvale, CA) is a new technique to treat BE. This procedure has been used in patients who have not had anti-reflux surgery. This report presented an early experience of the effects of endoluminal ablation on the reflux symptoms and completeness of ablation in post-fundoplication patients. A total of 7 patients who have had either a laparoscopic or open Nissen fundoplication and BE underwent endoscopic endoluminal ablation of the Barrett's metaplasia using the Barrx device. Pre-procedure, none of the patients had significant symptoms related to GERD. One to 2 weeks after the ablation, patients were questioned as to the presence of symptoms. Pre-procedure and post-procedure, they completed the GERD-HRQL symptom severity questionnaire (best possible score, 0; worst possible score, 50). Patients had follow-up endoscopy to assess completeness of ablation 3 months after the original treatment. All patients completed the ablation without complications. No patients reported recurrence of their GERD symptoms. The median pre-procedure total GERD-HRQL score was 2, compared to a median post-procedure score of 1. One patient had residual Barrett's metaplasia at 3 months follow-up, requiring re-ablation. The authors concluded that this preliminary report of a small number of patients demonstrated that endoscopic endoluminal ablation of Barrett's metaplasia using the Barrx device is safe and

effective in patients who have already undergone anti-reflux surgery. There appears to be no disruption in the fundoplication or recurrence of GERD-related symptoms. Nevertheless, they stated that studies with longer-term follow-up and with more patients are needed (36).

Ganz et al evaluated the safety and effectiveness of endoscopic circumferential balloon-based ablation by using radiofrequency energy for treating BE that contains high-grade dysplasia (HGD). Patients with histologic evidence of intestinal metaplasia (IM) that contained HGD confirmed by at least 2 expert pathologists were included in this study. A prior endoscopic mucosal resection (EMR) was permitted, provided that residual HGD remained in the BE region for ablation. Histologic complete response (CR) end points: (i) all biopsy specimen fragments obtained at the last biopsy session were negative for HGD (CR-HGD), (ii) all biopsy specimens were negative for any dysplasia (CR-D), and (iii) all biopsy specimens were negative for IM (CR-IM). A total of 142 patients (median age of 66 years, IQR 59 to 75 years) who had BE HGD (median length of 6 cm, IQR 3 to 8 cm) underwent circumferential ablation (median of 1 session, IQR 1 to 2 sessions). No serious adverse events were reported. There was 1 asymptomatic stricture and no buried glands. Ninety-two patients had at least 1 follow-up biopsy session (median follow-up of 12 months, IQR 8 to 15 months). A CR-HGD was achieved in 90.2 % of patients, CR-D in 80.4 %, and CR-IM in 54.3 %. The authors concluded that endoscopic circumferential ablation is a promising modality for the treatment of BE that contains HGD. In this multi-center registry, the intervention safely achieved a CR for HGD in 90.2 % of patients at a median of 12 months of follow-up. Major drawbacks of this study were a non-randomized study design, absence of a control arm, a lack of centralized pathology review, ablation and biopsy technique not standardized, and a relatively short-term follow-up (37).

Shaheen et al examined if endoscopic RFA could eradicate dysplastic BE and decrease the rate of neoplastic progression. In a multi-center, sham-controlled trial, these researchers randomly assigned 127 patients with dysplastic BE in a 2:1 ratio to receive either RFA (ablation group) or a sham procedure (control group). Randomization was stratified according to the grade of dysplasia and the length of BE. Primary outcomes at 12 months included the complete eradication of dysplasia and intestinal metaplasia. In the intention-to-treat analyses, among patients with low-grade dysplasia, complete eradication of dysplasia occurred in 90.5 % of those in the ablation group, as compared with 22.7 % of those in the control group ($p < 0.001$). Among patients with high-grade dysplasia, complete eradication occurred in 81.0 % of those in the ablation group, as compared with 19.0 % of those in the control group ($p < 0.001$). Overall, 77.4 % of patients in the ablation group had complete eradication of intestinal metaplasia, as compared with 2.3 % of those in the control group ($p < 0.001$). Patients in the ablation group had less disease progression (3.6 % versus 16.3 %, $p = 0.03$) and fewer cancers (1.2 % versus 9.3 %, $p = 0.045$). Patients reported having more chest pain after the ablation procedure than after the sham procedure. In the ablation group, 1 patient had upper gastrointestinal hemorrhage, and 5 patients (6.0 %) had esophageal stricture. The authors concluded that in patients with dysplastic BE, RFA was associated with a high rate of complete eradication of both dysplasia and intestinal metaplasia and a reduced risk of disease progression (38). As stated by the authors, this study has several

limitations: (i) these investigators used eradication of intestinal metaplasia and dysplasia, along with neoplastic progression, as surrogate markers for death from cancer, even though long-term data demonstrating an association between eradication of intestinal metaplasia and a decreased risk of cancer are sparse, (ii) the study duration was 1 year. Although other data suggest that reversion to neosquamous epithelium after RFA is durable, it is unclear if the results of the study will persist, (iii) because of stratified randomization according to the degree of dysplasia and the 2:1 ratio for assignment of patients to the ablation group and the control group, the number of patients in some groups was small, (iv) since this study did not compare RFA with other interventions, such as photodynamic therapy and esophagectomy, these researchers can not determine which of these interventions is superior, (v) whether these findings can be generalized to community-practice settings is unknown. Furthermore, the risk of subsquamous intestinal metaplasia following ablative therapy is a concern for all ablative techniques. However, the malignant potential of subsquamous intestinal metaplasia is unknown. In this study, subsquamous intestinal metaplasia was quite common in patients (25.2 %) before enrollment and, similar to previous reports, was low after RF ablation (5.1 %). Although the biopsy regimen in this study was aggressive, it is possible that some patients had undetected subsquamous intestinal metaplasia. Finally, because these investigators sought to define the efficacy of RFA for the spectrum of dysplasia, they enrolled patients with both low-grade dysplasia and high-grade dysplasia. However, the implications of these 2 diagnoses are markedly different. Low-grade dysplasia implies a risk of progression to cancer of less than 1 % per patient-year, whereas the risk associated with high-grade dysplasia may be higher by a factor of 10. In making decisions about the management of pre-cancerous conditions, clinicians, patients, and policy-makers consider possible benefits and risks of competing strategies. Because high-grade dysplasia has a more ominous natural history than low-grade dysplasia (or non-dysplastic intestinal metaplasia), greater risks and costs are tolerable. For less severe disease, the safety profile and associated costs become increasingly important. Detailed consideration of these trade-offs is beyond the scope of this study. Regardless, both of the dysplasia subgroups showed high rates of reversion to squamous epithelium after RFA and reduced rates of disease progression with few serious adverse effects, suggesting that the application of ablative therapy in patients with low-grade dysplasia is worth further investigation and consideration (38).

In the accompanying editorial, Bergman stated that it is still too early to promote RFA for patients with non-dysplastic BE. Dr. Bergman also asked the following questions: (i) is complete response after ablation maintained over time, thus reducing the risk of progression to high-grade dysplasia or cancer?, (ii) will ablation improve patients' quality of life and decrease costs, as compared with the surveillance strategy?, and (iii) can we define a stratification index predicting disease progression or response to therapy? The author noted that "[w]e run the risk of losing the momentum to enroll patients in a trial that is required at this stage: a randomized comparison of endoscopic surveillance and radiofrequency ablation for non-dysplastic Barrett's esophagus. Such a study might truly revolutionize the management of this condition and answer the question as to whether radiofrequency ablation is great just for some or justified for many" (39). Furthermore, the American College

of Gastroenterology's updated guidelines for the diagnosis, surveillance and therapy of BE, Wang and Sampliner states that "further evaluation of the most recent technology; radiofrequency ablation is awaited. Cryotherapy is beginning clinical trials and older technologies are becoming more refined (e.g., photodynamic therapy with the development of new agents). Documentation of the frequency and duration of the surveillance protocol after endoscopic ablation therapy requires careful study" (40).

4.9. RFA of esophageal neoplasm

Yeh and Triadafilopoulos noted that a wide variety of endoscopic mucosal ablative techniques have been developed for early esophageal neoplasia. However, long-term control of neoplastic risk has not been demonstrated. The authors explained that most studies show that specialized intestinal metaplasia may persist underneath neo-squamous mucosa, posing a risk for subsequent neoplastic progression (41). Shaheen noted that the pathogenesis of BE is poorly understood. Given that some patients will have repeated bouts of severe erosive esophagitis and never develop BE, host factors must play an important role. The author stated that the utility of neoadjuvant radiation and chemotherapy in those with adenocarcinoma, although they are widely practiced, is not of clear benefit, and some authorities recommend against it. Ablative therapies, as well as endoscopic mucosal resection, hold promise for those with superficial cancer or high-grade dysplasia. The author noted that most series using these modalities feature relatively short follow-up; longer-term studies are needed to better ascertain the effectiveness of these treatments (38).

Pedrazzani et al evaluated the effectiveness of 90 W argon plasma coagulation (APC) for the ablation of BE that is considered to be the main risk factor for the development of esophageal adenocarcinoma. They found that high power setting APC showed to be safe. The effects persist at a mean follow-up period of 2 years with a comparable cost in term of complications with respect to standard power settings. The authors stated, however, that further studies with greater number of patients are required to confirm these results and to assess if ablation reduces the incidence of malignant progression (42). Hage et al stated that although endoscopic removal of BE by ablative therapies is possible in the majority of patients, histologically complete elimination can not be achieved in all cases. Persistent BE may still harbor molecular aberrations and must therefore be considered still to be at risk of progression to adenocarcinoma (43).

4.10. RFA of thyroid metastasis

Guidelines on thyroid cancer from the National Comprehensive Cancer Network (NCCN, 2010) state that distant metastases from recurrent or persistent medullary thyroid carcinoma that are causing symptoms (e.g., those in bone) could be considered for palliative resection, RFA, or other regional treatment. The guidelines state that these interventions may also be considered for asymptomatic distant metastases (especially for progressive disease) but observation is acceptable, given the lack of data regarding alteration in outcome (44). Monchik and colleagues evaluated the long-term effectiveness of RFA and percutaneous

ethanol (EtOH) injection treatment of patients with local recurrence or focal distant metastases of well-differentiated thyroid cancer (WTC). A total of 20 patients underwent treatment of biopsy-proven recurrent WTC in the neck. Sixteen of these patients had lesions treated by ultrasound-guided RFA (mean size, 17.0 mm; range of 8 to 40 mm), while 6 had ultrasound-guided EtOH injection treatment (mean size, 11.4 mm; range of 6 to 15 mm). Four patients underwent RFA treatment of focal distant metastases from WTC. Three of these patients had CT-guided RFA of bone metastases (mean size, 40.0 mm; range of 30 to 60 mm), and 1 patient underwent RFA for a solitary lung metastasis (size, 27 mm). Patients were then followed with routine ultrasound, whole body scan, and/or serum thyroglobulin levels for recurrence at the treatment site. No recurrent disease was detected at the treatment site in 14 of the 16 patients treated with RFA and in all 6 patients treated with EtOH injection at a mean follow-up of 40.7 and 18.7 months, respectively. Two of the 3 patients treated for bone metastases were disease-free at the treatment site at 44 and 53 months of follow-up, respectively. The patient who underwent RFA for a solitary lung metastasis was disease-free at the treatment site at 10 months of follow-up. No complications were experienced in the group treated by EtOH injection, while 1 minor skin burn and 1 permanent vocal cord paralysis occurred in the RFA treatment group. The authors concluded that RFA and EtOH ablation show promise as alternatives to surgical treatment of recurrent WTC in patients with difficult reoperations. They stated that further long-term follow-up studies are needed to ascertain the precise role these therapies should play in the treatment of recurrent WTC (45).

4.11. RFA of Soft tissue masses

Radiofrequency ablation devices have been cleared by the FDA for the general indication of soft tissue cutting, coagulation, and ablation by thermal coagulation necrosis. This clearance was based only on bench testing or animal testing performance data. Guidelines from the National Comprehensive Cancer Network (NCCN, 2010) include recommendations for RFA of the trunk and extremities in metastatic soft tissue sarcoma. The guidelines include metastasectomy with RFA as an alternative method for control of metastatic lesions in limited metastases. The guidelines also include RFA as options for symptomatic patients with disseminated metastases. "The guidelines are intentionally nonspecific about this group of options, because many different issues are factored into this decision (e.g., patient performance status, patient preferences, specific clinical problems from the metastases, treatment availability.)" (46).

4.12. RFA of gastrointestinal stromal tumors

Pawlik et al at MD Anderson Cancer Center reported a series with 36 non-GIST sarcoma patients and 31 GIST patients who received RFA and/or surgical resection of liver metastases. (47). When surgical resection was possible, that was the first choice (35 patients). RFA was used in combination with surgical resection of the largest lesions in 18 cases. RFA was used alone in 13 cases. Those patients treated with RFA alone, or in combination with

surgical resection, had a significantly higher rate of recurrence (90.9%) than did patients who underwent resection alone (57.1%). However, this difference probably reflects a selection bias, since RFA was never used for patients whose tumors were resectable. Patients who were treated with RFA either alone or as a combined modality with resection also had a shorter disease-free interval (7.4 months) than patients who underwent resection alone (18.6 months). Avritscher et al reported three advanced GIST patients whose focal liver progression was successfully treated with RFA. The patients remained progression-free at 8, 15, and 16 months after ablation (48).

In an ASCO poster presentation, Dileo et al reported treating 9 patients with percutaneous CT-guided RFA for single or limited site(s) of progressing disease (8 liver lesions and 1 soft tissue lesion). There were no complications from the RFA procedure. With median follow-up of 4.2 months (range 1-11 months), all patients had their lesions completely ablated. Five patients developed systemic progression, while 4 patients remain stable on continued treatment with imatinib (median follow-up 5.8 m). The authors concluded "In this small cohort, percutaneous RFA appears to be a safe and effective treatment for localized sites of progression. This procedure helps to manage limited IM-resistant GIST. Continuation of imatinib to control systemic sites of imatinib-sensitive GIST despite emergence of limited clonal resistance can be justified on the basis of this exploratory work." (49)

Evaluating the evidence about RFA for GIST. RFA appears to be a viable palliative option for patients with advanced GIST who develop focal progression of liver or peritoneal disease during imatinib therapy and who are not otherwise candidates for surgical resection. Alternatively, RFA offers a potentially curative option for patients who exhibit a partial response to imatinib and have focal residual disease that is not amenable to surgical resection. The guidelines (NCCN, 2010) also recommend the use of RFA for the treatment of gastrointestinal stromal tumors with limited progression. Progression is defined as a new lesion or increase in tumor size. The NCCN guidelines state that, for limited progressive disease that is potentially easily resectable, surgical resection should be considered. Other treatment options include RFA or embolization.

4.13. RFA of malignant biliary obstruction

In an open-label, pilot study, Steel et al in 2011 examined the safety of endobiliary bipolar RFA in patients with malignant biliary obstruction and reported the 90-day biliary patency of this novel procedure. Main outcome measures were immediate and 30-day complications as well as 90-day stent patency. A total of 22 patients (16 pancreatic, 6 cholangiocarcinoma) were included in this study. Deployment of an RFA catheter was successful in 21 patients. Self-expandable metal stents (SEMSs) placement was achieved in all cases of successful RFA catheter deployment. One patient failed to demonstrate successful biliary decompression after SEMS placement and died within 90 days. All other patients maintained stent patency at 30 days. One patient had asymptomatic biochemical pancreatitis, 2 patients required percutaneous gallbladder drainage, and 1 patient developed rigors. At 90-day follow-up, 1 additional patient had died with a patent stent, and 3 patients had occluded biliary stents.

The authors concluded that endobiliary RFA treatment appears to be safe. They stated that randomized studies with prolonged follow-up are needed (50).

4.14. Role of hyperthermia in treatment of cervical cancer patients

Today, the technique is a standard treatment for patients with advanced cervical cancer, or patients with less advanced cervical cancer that cannot clinically tolerate chemotherapy. It is recommended and used as an alternative to the international gold standard of combined radiation therapy and cisplatin-based chemotherapy (51). The Dutch Deep Hyperthermia Trial, conducted between 1990 and 1996 and published in the *Lancet* in 2000, was a prospective, randomized trial that compared the outcomes of 358 patients with advanced bladder, cervical, and rectal tumors. Half of the patients received only radiation therapy and the other half received both radiation therapy and hyperthermia. Three-year outcomes revealed that hyperthermia improved both pelvic control and overall survival rates, but seemed to be most effective for patients with advanced cervical cancer (52). At 36 months, of an original cohort of 114 patients with advanced cervical cancer, the 58 patients receiving both treatments showed a complete response rate of 83%, compared with 57% for the 56 patients who only received radiation therapy. The survival rate was 51% for the combined treatment group, compared with 27% for the radiation therapy-only group. Furthermore, hyperthermia treatments did not enhance radiation toxicity and were reported to be cost-effective

However, long-term outcomes (**12-year follow-up**) was addressed by a follow-up study published in 2008 that tracked outcomes for both groups 12 years following treatment. The patients who received the combined treatment continued to have significantly better outcomes. The outcomes for the combined therapy group remained consistent. At the end of the study period, 37% of this group was still alive, compared with 20% who received radiation only. Of the combined therapy group, 56% retained pelvic tumor control, compared with 37% for the radiation therapy group. Pelvic recurrence developed in 25% of the combined therapy group and 31% of the radiation therapy group. Approximately one-third of both cohorts developed distant metastasis. Both groups experienced the same number of grades 3-5 radiation-induced toxicities (53).

4.15. Radiofrequency ablation therapy for varicose veins

Venous insufficiency resulting from superficial reflux because of varicose veins is a serious problem that usually progresses inexorably if left untreated. When the refluxing circuit involves failure of the primary valves at the saphenofemoral junction, treatment options for the patient are limited, and early recurrences are the rule rather than the exception. In the historical surgical approach, ligation and division of the saphenous trunk and all proximal tributaries are followed either by stripping of the vein or by avulsion phlebectomy. Proximal ligation requires a substantial incision at the groin crease. Stripping of the vein requires additional incisions at the knee or below and is associated with a high incidence of minor surgical complications. Avulsion phlebectomy requires multiple 2- to 3-mm incisions along the course of the vein and can cause damage to adjacent nerves and lymphatic vessels. Endovenous ablation has replaced stripping

and ligation as the technique for elimination of saphenous vein reflux. One of the endovenous techniques is a radiofrequency-based procedure. Newer methods of delivery of radiofrequency were introduced in 2007. Endovenous procedures are far less invasive than surgery and have lower complication rates. The procedure is well tolerated by patients, and it produces good cosmetic results. Excellent clinical results are seen at 4-5 years, and the long-term efficacy of the procedure is now known with 10 years of experience (54-55).

The US Food and Drug Administration (FDA) cleared the original radiofrequency endovenous procedure in March 1999. Endovenous techniques (endovenous laser therapy, radiofrequency ablation, and endovenous foam sclerotherapy) clearly are less invasive and are associated with fewer complications compared with more invasive surgical procedures, with comparable or greater efficacy. The original radiofrequency endovenous ablation system worked by thermal destruction of venous tissues using electrical energy passing through tissue in the form of high-frequency alternating current. This current was converted into heat, which causes irreversible localized tissue damage. Radiofrequency energy is delivered through a special catheter with deployable electrodes at the tip; the electrodes touch the vein walls and deliver energy directly into the tissues without coagulating blood. The newest system, called ClosureFast, delivers infrared energy to vein walls by directly heating a catheter tip with radiofrequency energy. Published results show a high early success rate with a very low subsequent recurrence rate up to 10 years after treatment. Early and mid range results are comparable to those obtained with other endovenous ablation techniques. The authors' overall experience has been a 90% success rate, with rare patients requiring a repeat procedure in 6-12 months. Overall efficacy and lower morbidity have resulted in endovenous ablation techniques replacing surgical stripping. Patient satisfaction is high and downtime is minimal, with 95% of patients reporting they would recommend the procedure to a friend (56-58).

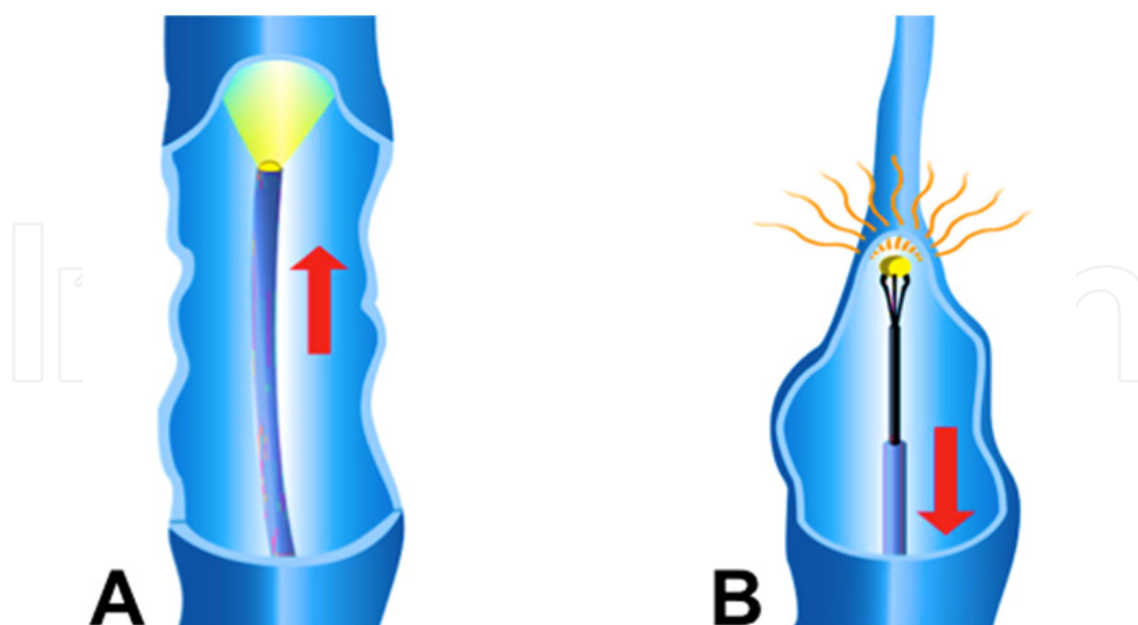


Figure 5. A diagram shows the technique of RFA for varicose veins .A. The catheter is inserted and advanced into the diseased vein through a small incision into the diseased vein under ultrasound guidance. B Then laser or radiofrequency energy is applied to the lining of the vein, heating and shrinking the vein walls, causing them to seal and as the catheter withdrawn the vein is closed

4.16. Catheter ablation for paroxysmal atrial fibrillation

Other diseases where ablation is used include cardiac catheter thermal ablation is now standard of care for a variety of cardiac arrhythmia types (irregular heart beat rhythm). Techniques are directed at cauterizing areas of high irritability that give rise to frequent ectopy and trigger paroxysmal atrial fibrillation (PAF), or cauterisation of the substrate that maintains PAF, (predominantly left atrial tissue), or both. Usually this is done with radiofrequency energy delivered percutaneously by steerable catheters. In the UK, recent Guidance from NICE approved catheter ablation for PAF on the NHS for patients who have failed treatment with two antiarrhythmic drugs. Similar guidelines exist in the USA. Success rates of 70-80% can be achieved, with multiple procedures being needed in many cases. RFCA for PAF carries significant risks. These are; stroke (<1%), cardiac tamponade (2-6%), pulmonary vein stenosis (0.5-1%), a small risk of arteriovenous fistula (<0.5%), and a very small but important risk of oesophago-atrial fistula. In older patients, (>70 years), patients with structural heart disease and patients with persistent or prolonged AF, there is significantly less chance of success with RFCA. Recently an electro-anatomic mapping systems" (a form of mini-"GPS", or "Sat-Nav" system), are becoming increasingly sophisticated at telling an electrophysiologist exactly where a catheter is within the heart, and exactly where anatomical structures are located relative to it. This is important for avoiding complications. A CT Scan or MRI scan of heart chambers is useful for obtaining the detailed anatomy of the heart for RFCA procedures (59-61).

RFA of the AV-junction followed by implantation of a pacemaker provides good control of symptoms, reduced drug and healthcare consumption, and reduced hospital admissions. However, AV-junctional ablation is not reversible, and allows atrial fibrillation to continue, albeit without allowing it to produce rapid, irregular ventricular rates, so that patients may be unaware of being in PAF. RFA of the AV-junction followed by implantation of a pacemaker is increasingly reserved for patients with established/chronic AF in whom ventricular rate-control cannot be achieved with AV-nodal blocking drugs. In these patients AF persists in spite of treatment anyway, and RFA of the AV-junction with permanent pacing can give excellent symptom control (NICE 2006) (62).

5. Combination of hyperthermia with radiotherapy in treatment of cancer

Hyperthermia is a heat cancer treatment FDA approved in combination with low-dose-radiation, applied to tumors, raising tumor temperature to about 42.5°C (108°F) for about 45 to 60 minutes. Heat improves blood circulation and makes tumor cells more susceptible to the low-dose- radiation therapy, killing them more efficiently and quickly. Hyperthermia can be compared with an artificial fever that attacks cancer cells. Starting in the late 1970s, a major focus of many researchers was on achieving focal, cytotoxic temperatures of 42-45 °C within tumors, a strategy which can sensitize tumors to radiation and/or chemotherapy. Remarkable progress in engineering and physics over the past 20 years has led to the implementation of clinical trials that are revealing the true potential of this strategy. Over the past decade, positive clinical data has emerged from trials utilizing HT in the treatment of recurrent chest wall breast cancer, melanoma, esophageal cancer, locally advanced head and neck cancer, locally advanced

cervix cancer and gliomas. 1) Hyperthermia increases perfusion and oxygenation of neoplastic hypoxic cells, which are three times more resistant to ionizing radiation than normal cells. Consequently, the action of radiotherapy becomes 1.5-5 times more efficient. Hyperthermia has a direct cytotoxic action on cancer: due to the pathologic blood vessels, the thermal elevation persists inside the tumor, whereas neighboring normal tissues, adequately perfused, are cooled: at 43 °C, normal cells are not damaged, whereas tumor cells are damaged at the cell nucleus, plasmatic membrane and cytoskeleton, up to apoptosis. Hyperthermia acts mostly at an acid pH and in the S phase of the cell cycle, when cells are radioresistant. This means that radiotherapy and hyperthermia are complementary in their action: radiotherapy forms free radicals, which damage the DNA of tumor cells, whereas hyperthermia inhibits its reparation. 2) Hyperthermic inhibition of repairing radiation damage has been suggested as an essential factor causing the synergistic cell-killing effect of X-rays and hyperthermia. Heating cells before X-irradiation has been shown to inhibit the repair of DNA strand breaks as well as the excision of base damage¹. There are several DNA repair pathways involved in restoration of damage after ionizing irradiation and the kinetics of all of them are affected by heat shock. However, this does not imply that the inhibition of each of these pathways is relevant to the effect of heat on cellular radiosensitivity. Data reported by Kampinga et al showed that thermal inhibition of the non-homologous end-joining pathway plays a role in heat radiosensitization. Furthermore, limited data suggest that the homologous recombination pathway may not be a major heat target. The inhibition of base-excision damage repair could be, by deduction, the crucial step in the mechanism of radiosensitization by heat (63). 3) Hyperthermia enhances the sensitivity of cells to radiation and drugs and this sensitization is not directly related to altered heat-shock proteins (HSP) expression. Elevating HSP prior to heating makes cells thermo- tolerant and altering their expression will affect the extent of thermal action because the HSP will attenuate the heat-induced protein damage, responsible for radiation and drug sensitization. Nuclear protein damage is considered to be responsible for hyperthermic effects on DNA repair, especially base-excision damage repair (64).

In an effort to provide a clearer picture of the interaction between hyperthermia and radiation, asynchronous CHO cell survivals for a matrix of doses of radiation and hyperthermia were determined. The survival matrix was then analyzed by fitting a survival function that was the product of survivals due to hyperthermia alone, to radiation alone and to the interaction of hyperthermia and radiation. This survival function is an expression for the survival surface, a surface in the space defined by the three axes of logarithm of cell survival, hyperthermia dose and radiation dose. The survival surface is a three dimensional extension of the two-dimensional survival curve (65).

The two principal rationales for applying hyperthermia in cancer therapy are that: (a) the S phase, which is relatively radioresistant, is the most sensitive phase to hyperthermia, and can be selectively radiosensitized by combining hyperthermia with x-irradiation; the cycling tumor cells in S phase which would normally survive an x-ray dose could thus be killed by subjecting these cells to hyperthermia; and (b) the relatively radioresistant hypoxic cells in the tumor may be selectively destroyed by combinations of hyperthermia and x-irradiation. Both of these rationales have been mentioned as reasons for using high LET irradiation in cancer therapy; therefore where such irradiation may be of use, hyperthermia may also be advantageous.

It is a **heat cancer treatment FDA approved** in combination with low-dose-radiation, applied to tumors, raising tumor temperature to about 42.5°C (108°F) for about 45 to 60 minutes. Heat improves blood circulation and makes tumor cells more susceptible to the low-dose- radiation therapy, killing them more efficiently and quickly. As a result of these and other clinical applications, combined with a rapidly expanding research base, interest in thermal medicine is rapidly growing, attracting the attention of laboratory and clinical researchers, physicians, engineers, physicists and biotechnologists.

6. Rationale for chemotherapy and hyperthermia association

Hyperthermia can also be used to activate cytotoxic effects of chemotherapy within tumors, thereby sparing normal tissue, when the drugs are encapsulated in thermally sensitive nanoparticles. Hyperthermic drug sensitization can be seen for several anti-cancer drugs, in particular alkylating agents. The combined action between heat and drugs arises from multiple events such as drug accumulation, drug detoxification pathways and repair of drug-induced DNA adducts. Cells with acquired drug resistance can be made responsive to the same drugs again by combining drugs with heat. Hyperthermia, which increases tumor tissue perfusion, facilitates the absorption of chemotherapeutic drugs through cell membrane. The heat accelerates chemical reactions, so that chemotherapy becomes more effective, without being more toxic. Hyperthermia allows the response of tumors resistant to various chemotherapeutic drugs: doxorubicin, cisplatin, bleomycin, mitomycin c, nitrosoureas, cyclophosphamide. Use of liposomes, including adriamycin (Caelyx®) administered i.v., hyperthermia fuses and frees their content inside the heated tumor bed, thus obtaining a target chemotherapy, with reduction of side effects.

On March 18, 2010, the Celsion Corporation (<http://www.celsion.com>, accessed 17 November 2010) announced that an abstract about the phase I/II trial of ThermoDox® in recurrent chest wall cancer has been accepted for presentation at the American Society of Clinical Oncology (ASCO) 2010 Annual Meeting. The abstract presents the background, rationale and design of the DIGNITY study which is ongoing and evaluating ThermoDox® in combination with hyperthermia in women with recurrent breast cancer on their chest wall (66).

In a separate trial with a similar design being conducted at Duke University Medical Center, researchers are reporting convincing evidence of clinical activity. The DIGNITY clinical trial is a phase I/II, open label, dose- escalating trial to evaluate the safety and efficacy of ThermoDox® with hyperthermia for the treatment of recurrent chest wall breast cancer, an aggressive form of cancer with a poor prognosis and limited treatment options. The primary end point in the DIGNITY trial is durable complete local response at the tumor site. Once the safe dose is determined, Celsion intends to enroll up to 100 patients to establish efficacy. The results from the DIGNITY trial are expected to build on the promising data from the phase I dose-escalation study currently being conducted at Duke University Medical Center. ThermoDox® has also demonstrated evidence of efficacy in a phase I study for primary liver cancer. Celsion has been granted FDA orphan drug designation for ThermoDox® and is conducting a pivotal 600 patient global phase III study in primary liver cancer under an FDA special protocol assessment, thus obtaining a target chemotherapy, with reduction of

side effects. It has been demonstrated that hyperthermia also has an anti-angiogenic action and an immunotherapeutic role, due to thermal shock proteins, which are produced by stressed tumor cells. Finally, hyperthermia sustains the action of genic therapy (67).

The immunotherapeutic role of hyperthermia is not yet completely understood. Especially, the effects on natural killer (NK) cell cytotoxicity against tumor cell targets have not been fully demonstrated. At treatment temperatures above 40 °C, both enhancing and inhibitory effects of cytotoxic activity of NK cells against tumor cells have been reported. In particular, an enhancement of human NK cytotoxicity against tumor cell targets has been demonstrated using a temperature of 39.5 °C¹⁰. Data in the literature indicate a strong potential for heat-induced enhancement of NK cell activity in mediating the improved clinical response. A better understanding in this field should be achieved in order to maximize the clinical benefits obtained by using hyperthermia for cancer therapy (68).

7. Heat-activated drug delivery

An exciting new generation of clinical trials is now harnessing drug-containing thermosensitive liposomes, and other nanoparticle drug carriers, that release contained chemotherapy agents upon heating above ~40 °C. Combined with localized heating methods as described above, this allows for targeted chemotherapy delivery to tumors. Thermal ablation or hyperthermia can be combined with heat-activated drug carriers to selectively deposit chemotherapy in the heated area. Initial clinical trial results suggest patient benefits from this combination and thus there is considerable excitement among members of our Society in this approach.

8. Conclusions

Hyperthermia, thanks to the improved systems for achieving an optimal distribution of heat inside the tumor and precise and noninvasive thermometry, is today an important treatment modality in the treatment of cancer, and its results are strongly supported by criteria of evidence-based medicine. Hyperthermia is an important treatment modality in cancer treatment and its results are strongly supported by criteria of evidence-based medicine. Hyperthermia is a therapeutic modality that, employing nonionizing radiations, can be used not only by radiation oncologists but also by clinical oncologists. Its addition to radiotherapy with or without chemotherapy is important when it is necessary to treat advanced or high-risk tumors, or to retreat a relapse in a pre-irradiated area. Hyperthermia appears to be the fourth pillar besides surgery, radiotherapy and chemotherapy.

Author details

Ragab Hani Donkol

Department of Radiology, Faculty of Medicine, Cairo University, Cairo, Egypt

Aseer Central Hospital, Abha, Saudi Arabia

Ahmed Al Nammi

Aseer Central Hospital, Abha, Saudi Arabia

9. References

- [1] Moulvi Azimuddin Ahmad: Catalogue of Arabic and Persian Manuscripts in the Oriental Public Library, Bankipur, Patna, India. Calcutta, 1910, p. 30
- [2] Nikfarjam M, Muralidharan V, Christophi C. Mechanisms of focal heat destruction of liver tumors. *J Surg Res.* 2005; 127:208–23.
- [3] Stauffer PR, Goldberg SN. Introduction: thermal ablation therapy. *Int J Hyperthermia.* 2004;7:671–7.
- [4] Stauffer PR. Evolving technology for thermal therapy of cancer. *Int J Hyperthermia.* 2005; 21:731–44.
- [5] Ahar K (2004) The role and limitations of radiofrequency ablation in treatment of bone and soft tissue tumors. *Curr Oncol Rep* 6:315–320
- [6] Rosenthal DI, Hornicek FJ, Wolfe MW et al (1998) Percutaneous radiofrequency coagulation of osteoid osteoma compared with operative treatment. *J Bone Joint Surg Am* 80:815–821
- [7] Towbin R, Kaye R, Meza M et al (1995) Osteoid osteoma: percutaneous excision using a CT-guided coaxial technique. *AJR* 164:945–949
- [8] Sans N, Galy-Fourcade D, Assoun J et al (1999) Osteoid osteoma: CT-guided percutaneous resection and follow-up in 38 patients. *Radiology* 212:687–692
- [9] Rosenthal DI, Springfield DS, Gebhardt MC et al (1995) Osteoid osteoma: percutaneous radio-frequency ablation. *Radiology* 197:451–454
- [10] Gebauer B, Tunn PU, Gaffke G et al (2006) Osteoid osteoma: experience with laser- and radiofrequency-induced ablation. *Cardiovasc Intervent Radiol* 29:210–215
- [11] Kjar RA, Powell GJ, Schilcht SM et al (2006) Percutaneous radiofrequency ablation for osteoid osteoma: experience with a new treatment. *Med J Aust* 184:563–565 406
- [12] Donkol RH, Al-Nammi A, Moghazi K. Efficacy of percutaneous radiofrequency ablation of osteoid osteoma in children. *Pediatr Radiol.* 2008 Feb;38(2):180-5. Epub 2007 Nov 27
- [13] Le QT, Petrik DW. Nonsurgical therapy for stages I and II non-small cell lung cancer. *Hematol Oncol Clin N AM,* 2005,19:237-261.
- [14] National Institute of Health and Clinical Excellence. Lung cancer: the diagnosis and treatment of lung cancer. Clinical Guideline CG24. 2005 (review expected February 2009).
- [15] U.S. Food and Drug Administration. FDA Public Health Notification: Radiofrequency Ablation of Lung Tumors - Clarification of Regulatory Status. September 24, 2008 Available at: <http://www.fda.gov/cdrh/safety/092408-ablation.html>. Accessed on March 28, 2011.
- [16] Girelli, R.; et al. (2010) Feasibility and safety of radiofrequency ablation for locally advanced pancreatic cancer. *Brit J Surg.* 97(2). 220-225.
- [17] Wood BJ, Ramkaransingh JR, Fojo T, Walther MM, et al. Percutaneous tumor ablation with radiofrequency. *Cancer* 2002; 94(2):443–51. BJ,
- [18] Atkins, M.; Choueiri, T. (2011). Epidemiology, pathology, and pathogenesis of renal cell carcinoma. In: UpToDate, Basow, DS (Ed), UpToDate, Waltham, MA.
- [19] National Institute for Clinical Excellence, Interventional Procedures Programme. Interventional procedures overview of percutaneous radiofrequency ablation of renal tumors, 2010 <http://www.nice.org.uk/page.aspx?o=ip215overview>

- [20] Hailey D. Radiofrequency ablation in the treatment of kidney cancer. Canadian Coordinating Office for Health Technology Assessment (CCOHTA); 2006
- [21] Hinshaw JL, Lee FT Jr. Image-guided ablation of renal cell carcinoma. *Magn Reson Imaging Clin NAm* 2004;12(3):429–47
- [22] Mahnken JAH. Percutaneous radiofrequency ablation of renal cell cancer. *Radiologe*. 2004; 44:358–363.
- [23] Kutikov A, Guzzo TJ, Canter DJ, Casale P. Initial experience with laparoscopic enucleation of renal cell carcinoma with ablation of the tumour base in patients with renal cell carcinoma. *Journal of Urology* 181(2): 486-491, Feb. 200.
- [24] Nabi G, Cleves A, Shelley M. Surgical management of localised renal cell carcinoma. *Cochrane Database Syst Rev*. 2010;(3):CD006579
- [25] Sooriakumaran P, Gibbs P, Coughlin G, Attard V, Elmslie F, Kingswood C, Taylor J, Corbishley C, Patel U, Anderson C. Angiomyolipomata: challenges, solutions, and future prospects based on over 100 cases treated. *BJU int*, 2009 June
- [26] Wood, B. (2002). Feasibility of Thermal Ablation of Lytic Vertebral Metastases with Radiofrequency Current. *The Cancer Journal*, 8(1): 26-29.
- [27] Rhim H, Dodd GD III, Chintapalli KN, Wood BJ, Dupuy DE, Hvizda JL, Sewell PE and Goldberg SN: Radiofrequency thermal ablation of abdominal tumors: lessons learned from complications. *Radiographics* 24: 41-52, 2004.
- [28] Hilger I, Andrä W, Hergt R, Hiergeist R, Schubert H, Kaiser WA. Electromagnetic heating of breast tumors in interventional radiology: in vitro and in vivo studies in human cadavers and mice. *Radiology*. 2001 Feb;218(2):570-5.
- [29] Agnese DM, Burak WE Jr. Ablative approaches to the minimally invasive treatment of breast cancer. *Cancer J* 2005;11:77–82
- [30] van der Ploeg I M, van Esser S, van den Bosch M A, Mali W P, van Diest P J, Borel Rinkes I H, van Hillegersberg R. Radiofrequency ablation for breast cancer: a review of the literature. *European Journal of Surgical Oncology* 2007; 33(6): 673-677
- [31] Carrafiello G, Laganà D, Mangini M, et al. Treatment of secondary hyperparathyroidism with ultrasonographically guided percutaneous radiofrequency thermoablation. *Surg Laparosc Endosc Percutan Tech* 2006; 16:112 -116
- [32] Hänsler J, Harsch IA, Strobel D, Hahn EG, Becker D. Treatment of a solitary adenoma of the parathyroid gland with ultrasound-guided percutaneous Radio-Frequency-Tissue-Ablation (RFTA)]. *Ultraschall Med*. 2002 Jun;23(3):202-6
- [33] Gary J. R. Cook, Ignac Fogelman and John F. Reidy Successful repeat transcatheter ablation of a mediastinal parathyroid adenoma 6 years after alcohol embolization. *Cardiovascular and interventional radiology*. Volume 20, Number 4 (1997), 314-316, DOI: 10.1007/s002709900157
- [34] Feagins LA, Souza RF. Molecular targets for treatment of Barrett's esophagus. *Dis Esophagus*. 2005; 18(2): 75-86
- [35] Johnston, MH, Eastone, JA, Horwhat, JD, Cartledge, J, Mathews, JS, Foggy, JR. Cryoablation of Barrett's esophagus: a pilot study. *Gastrointest Endosc*. 2005 Dec;62(6):842-8. PMID: 16301023
- [36] Hubbard N, Velanovich V. Endoscopic endoluminal radiofrequency ablation of Barrett's esophagus in patients with funduplications. *Surg Endosc* 2007;21:625-8.

- [37] Ganz RA, Uitley DS, Stern RA, et al. Complete ablation of esophageal epithelium with a balloon-based bipolar electrode; a phased evaluation in the porcine and in the human esophagus. *Gastrointest Endosc* 2004;60:1002-10.
- [38] Shaheen NJ, Sharma P, Overholt BF, et al. Radiofrequency ablation in Barrett's esophagus with dysplasia. *N Engl J Med* 2009;360:2277-88
- [39] Bergman JJ, Zhang YM, He S, Weusten B, Xue L, Fleischer DE, Lu N, Dawsey SM, Wang GQ Outcomes from a prospective trial of endoscopic radiofrequency ablation of early squamous cell neoplasia of the esophagus. *Gastrointest Endosc*. 2011 Dec;74(6):1181-90. Epub 2011 Aug 15. PMID: 21839994
- [40] Wang KK, Sampliner RE. Updated guidelines 2008 for the diagnosis, surveillance and therapy of Barrett's esophagus. *Am J Gastroenterol* 2008;103:788-797
- [41] Yeh R, Triadafilopoulos G. Endoscopic therapy for Barrett's esophagus. *Gastrointest Endosc Clin North Am* 2005; 15:377-397.
- [42] Pedrazzani C, Catalano F, Festini M, Zerman G, Tomezzoli A, Ruzzenente A, Guglielmi A, de Manzoni G. Endoscopic ablation of Barrett's esophagus using high power setting argon plasma coagulation: A prospective study. *World J Gastroenterol* 2005; 11(12): 1872-1875
- [43] Hage M, Siersema PD, Vissers KJ, et al. Molecular evaluation of ablative therapy of Barrett's oesophagus. *J Pathol*. 2005; 205(1): 57- 64.
- [44] National Comprehensive Cancer Network. NCCN Clinical Practice Guidelines in Oncology: Thyroid Cancer. Version 1.2011
- [45] Monchik JM, Donatini G, Iannuccilli J, Dupuy D: Radiofrequency ablation and percutaneous ethanol injection treatment for recurrent local and distant well differentiated thyroid cancer. *Ann Surg* 244:296, 2006.
- [46] George D. Demetri; Scott Antonia; Robert S. Benjamin; Marilyn M. Bui; Ephraim S. Casper; Ernest U. Conrad III; Thomas F. DeLaney; Kristen N. Ganjoo; Martin J. Heslin; et al. Soft tissue sarcoma. *JNCCN Journal of the National Comprehensive Cancer Network* 2010;8(6):630-674.
- [47] Pawlik TM, Vauthey JN, Abdalla EK, et al. Results of a single-center experience with resection and ablation for sarcoma metastatic to the liver. *Arch Surg* 2006;141:537-43
- [48] Avritscher R, Gupta S. Gastrointestinal stromal tumor: role of interventional radiology in diagnosis and treatment. *Hematol Oncol Clin North Am*. 2009 Feb;23(1):129-37, ix. PubMed PMID: 19248976.
- [49] Dileo P, Randhawa R, Vansonnenberg E, et al. Safety and efficacy of percutaneous radiofrequency (RFA) in patients with metastatic gastrointestinal stromal tumor (GIST) with clonal evolution of lesions refractory to imatinib mesylate. *J Clin Oncol* 2004;22:9024
- [50] Steel, Alan W.; Postgate, Aymer J.; Khorsandi, Shirin; Nicholls, Joanna; Jiao, Long; Vlavianos, Pangiotis; Habib, Nagy; Westaby, David. Endoscopically applied radiofrequency ablation appears to be safe in the treatment of malignant biliary obstruction. *Gastrointestinal Endoscopy* vol. 73 issue 1 January, 2011. p. 149-153
- [51] Franckena M, Fatehi D, de Bruijne M, Canters RA, van Norden Y, Mens JW, van Rhoon GC, van der Zee J. Long-term improvement in treatment outcome after radiotherapy and hyperthermia in locoregionally advanced cervix cancer: an update of the Dutch Deep Hyperthermia Trial. *Int J Radiat Oncol Biol Phys*. 2008 Mar 15; 70(4):1176-82. Epub 2007.
- [52] van der Zee J, González González D, van Rhoon GC, van Dijk JD, van Putten WL, Hart AA. Comparison of radiotherapy alone with radiotherapy plus hyperthermia in locally

- advanced pelvic tumours: a prospective, randomised, multicentre trial. Dutch Deep Hyperthermia Group. *Lancet*. 2000 Apr 1; 355(9210):1119-25.
- [53] Franckena M, Lutgens LC, Koper PC, Kleynen CE, van der Steen-Banasik EM, Jobsen JJ, Leer JW, Creutzberg CL, Dielwart MF, van Norden Y, et al .Radiotherapy and hyperthermia for treatment of primary locally advanced cervix cancer: results in 378 patients. *Int J Radiat Oncol Biol Phys*. 2009 Jan 1; 73(1):242-50. Epub 2008
- [54] Sadick NS. Advances in the treatment of varicose veins: ambulatory phlebectomy, foam sclerotherapy, endovascular laser, and radiofrequency closure. *Dermatol Clin*. Jul 2005;23(3):443-55
- [55] Nael R, Rathbun S. Treatment of varicose veins. *Curr Treat Options Cardiovasc Med*. Apr 2009;11(2):91-103.
- [56] Merchant RF, Pichot O, Myers KA. Four-year follow-up on endovascular radiofrequency obliteration of great saphenous reflux. *Dermatol Surg*. Feb 2005;31(2):129-34.
- [57] Nicolini P. Treatment of primary varicose veins by endovenous obliteration with the VNUS closure system: results of a prospective multicentre study. *Eur J Vasc Endovasc Surg*. Apr 2005;29(4):433-9.
- [58] Helmy ElKaffas K, ElKashef O, ElBaz W. Great saphenous vein radiofrequency ablation versus standard stripping in the management of primary varicose veins-a randomized clinical trial. *Angiology*. Jan 2011;62(1):49-54.
- [59] Brugada J, Berruezo A, Cuesta A, Osca J, Chueca E, Fosch X, Wayar L, Mont L. Nonsurgical transthoracic epicardial radiofrequency ablation: an alternative in incessant ventricular tachycardia. *J Am Coll Cardiol*. 2003; 41: 2036
- [60] Segal OR, Chow AW, Markides V, Schilling RJ, Peters NS, Davies DW. Long-term results after ablation of infarct-related ventricular tachycardia. *Heart Rhythm*. 2005; 2: 474-482.
- [61] Sosa E, Scanavacca M. Percutaneous pericardial access for mapping and ablation of epicardial ventricular tachycardias. *Circulation*. 2007; 115: e542-e544.
- [62] NICE. Percutaneous radiofrequency ablation for atrial fibrillation. National Institute for Health and Clinical Excellence/www.nice.org/IPG168 2006; Guidance 168.
- [63] Kampinga HH, Dynlacht JR, Dikomey E: Mechanism of radiosensitization (43 °C) as derived from studies with DNA repair defective mutant cell lines. *Int J Hyperthermia*, 20: 131-139, 2004.
- [64] Kampinga HH: Cell biological effects of hyperthermia alone or combined with radiation or drugs: A short introduction to newcomers in the field. *Int J Hyperthermia*, 22: 191-196, 2006.
- [65] Borys N: Phase I/II study evaluating the maximum tolerated dose, pharmacokinetics, safety, and efficacy of approved hyperthermia and lyso-thermosensitive liposomal doxorubicin in patients with breast cancer recurrence at the chest wall. *ASCO abstracts book*, 2010.
- [66] Wahl ML, Bobyock SB, Leeper DB, Owen CS: Effects of 42 degrees C hyperthermia on intracellular pH in ovarian carcinoma cells during acute or chronic exposure to low extracellular pH. *Int J Radiat Oncol Biol Phys*, 39: 205-212, 1997.
- [67] Nakano H, Kurihara K, Okamoto M, Toné S, Shinohara K: Heat-induced apoptosis and p53 in cultured mammalian cells. *Int J Radiat Oncol Biol Phys*, 71: 519-529, 1997.
- [68] Coss RA, Sedar AW, Sistrun SS, Storck CW, Wang PH, Wachsberger PR: Hsp27 protects the cytoskeleton and nucleus from the effects of 42 degrees C at pH 6.7 in CHO cells adapted to growth at pH 6.7. *Int J Hyperthermia*, 18: 216-232, 2002