

We are IntechOpen, the world's leading publisher of Open Access books Built by scientists, for scientists

6,900

Open access books available

186,000

International authors and editors

200M

Downloads

Our authors are among the

154

Countries delivered to

TOP 1%

most cited scientists

12.2%

Contributors from top 500 universities



WEB OF SCIENCE™

Selection of our books indexed in the Book Citation Index
in Web of Science™ Core Collection (BKCI)

Interested in publishing with us?
Contact book.department@intechopen.com

Numbers displayed above are based on latest data collected.
For more information visit www.intechopen.com



Superior Sulcus Tumour with some Emphasis on the Anterior Approach

Haralabos Parissis, Alan Soo and Bassel Al-Alao

Additional information is available at the end of the chapter

<http://dx.doi.org/10.5772/55724>

1. Introduction

Superior sulcus tumours are rarely encountered in clinical practice, representing < 5% of all bronchogenic carcinomas [1, 2]. In 1932, Pancoast [3] published his classic article in which he reported four patients who had a similar presentation including pain in the shoulder and arm, weakness and wasting of the muscles of the hand, and ipsilateral Horner syndrome together with a lesion situated at the apex of the lung. Pancoast [3] rejected the pulmonary origin of the tumour that was recognised by Tobias [4], who described the same clinical syndrome in four other patients.

Pancoast syndrome is due to lesions extending to the superior thoracic inlet. Specific symptomatology mainly due to brachial plexus invasion accounts for the majority of those cases [5-7]. Pancoast tumour is a tumour of the apex of the lung with no intervening lung tissue between tumour and chest wall. Subsequently, there is an involvement of structures of the apical chest wall above the level of the second rib. Almost half of the treated cancers are squamous cell carcinomas (45-50%), while the rest are either adenocarcinomas (36-38%) or undifferentiated large-cell carcinomas (11-13%). The tumour rapidly involves the structures of the thoracic inlet & the root of neck. Due to its localisation in the apex of the lung, invasion of the lower part of the brachial plexus, first ribs, vertebrae, subclavian vessels or stellate ganglion, occurs [8-10]. The classical Pancoast presentation, with shoulder pain radiating to the ulnar side of the arm and the hand, is presented in 55 to 60% of the patients. Pain at the ulnar aspect of the forearm and hand is consistent with T1 involvement; furthermore symptomatology along the intrinsic hand muscles suggests the C8 root or lower trunk tumour deposits. Horner's syndrome is reported in up to 30% of the cases.

Superior sulcus tumours are not necessarily associated with the classic Pancoast syndrome. Though some controversy exists about their exact definition, it is generally accepted that they

may be defined as primary lung cancers involving the apex of the chest wall and usually associated with pain in the shoulder and/or arm [9, 10].

Although these tumours represent a wider range of stage IIB to stage IV disease, (IIB (25-27%), stage IIIA (6-8%), stage IIIB (40-42%) and stage IV (21-23%) it is the T3, T4, N0-N1 subgroup of this spectrum that could be amenable to surgical intervention [11]. This subgroup of patients (less than 5% of Bronchogenic Carcinomas) however, is difficult to be treated surgically due to the location of the tumour and the complex anatomy of the area involved [12]. Historically, Pancoast tumours have been associated with high rates of incomplete resection, local recurrence, and death.

Pancoast tumours were thought to be located posteriorly and early attempts to resect those tumours were approached solely from the back. A percentage of these lesions might also be located at the front, with vascular rather than neuro-vertebral involvement. Various reports suggested spinal involvement in 15%, brachial plexus in 15% and subclavian vessels in 6% of the cases [13]. Therefore surgeons treating these cancers should be able to be familiar and adapt with the various approaches. An understanding of the posterior location of neural structures and somewhat anterior location of vascular structures is important for adequate operative planning.

This article alludes to the anatomy, initial assessment, and surgical approaches with an emphasis on the modified anterior approach for these cancers.

2. How does the treatment of pancoast tumours evolved the last decades

For more than 40 years the treatment of Pancoast tumours has centred on a bi-modality regimen consisting of preoperative external beam radiotherapy followed by surgery. Tri-modality treatment however with the addition of platinum based chemotherapy regimes has become currently the standard treatment, in order to achieve additive anti-tumour effects (chemotherapy as radiation sensitizer). According to Wright et al [14] induction chemoradiotherapy (CT/RT) can be administered with low morbidity, a higher complete resection rate, a high pathologic response rate, a reduced loco-regional recurrence rate and improved survival. Further improvement in radiotherapy with the advent of 3-dimensional conformal radiotherapy, the total radiation dose that could be safely delivered was not anymore constrained by dose-limiting toxicities upon the nearby organs.

Careful patient selection for tri-modality treatment, on the basis of staging and comorbidity, is of vital importance in the treatment of Pancoast tumours. Nevertheless only 30% of M0 patients with Pancoast tumours were eligible for combined treatment according to Pourel et al [15]. Not only operability (patient fitness to surgery) but also ability to resect the tumour is of a major importance bearing in mind the difficulty of access, the crowded anatomy of this region and the tendency of the tumours in this area to involve important adjacent structures. As per the same group [15], following CT/RT, 67% of the patients were amenable to thoracotomy. The resection rate, which had remained unchanged at approximately 50% for almost 40 years with conventional preoperative radiotherapy, was improved to above 70% in SWOG [16] and JCOG [17] studies.

Preoperative radiotherapy was part of the standard treatment, but a recent prospective phase II study (Southwest Oncology Group 9416, INT 0160) [16], suggests that preoperative concur-

rent CT/RT (platinum-based chemotherapy and 45Gy of radiotherapy) improves the rate of complete resection, local recurrence, and intermediate-term survival. Like wise, the Japan Clinical Oncology Group JCOG trial 9806 [17] in a prospective report concluded along the same lines. Furthermore, Kwong et al [18] reported that high dose radiotherapy targeting up to 60 Gy (rather than 45 Gy) could be given in the neoadjuvant setting; it is successfully tolerated and associated with improved resection rate.

3. Applied surgical anatomy

The limited access and poor visualisation of the thoracic inlet is due to: 1) the unique course of the upper ribs downwards and outwards that render the neuro-vascular bundle inaccessible to posterior approaches, 2) the musculature of the area and also 3) the overlapping bulky pectoral-shoulder girdle with the clavicle and the manubrium to further restrict access from the neck. These anatomical idiosyncrasies create a hostile but challenging environment for the thoracic surgeon.

The main goal for cure is to achieve local control of the disease and aim for relapse-free, metastasis-free outcome. Local control is obtained by removing the upper lobe, chest wall and invaded structures (subclavian artery or vertebra), aiming for R0 resection margins. Radically resected cases yield better survival whereas R1 resections are associated with high incidence of local and distal recurrences. Involvement of the vertebral body or brachial plexus, once considered unresectable is nowadays amenable to advanced techniques of spinal reconstruction and should be planned jointly with a spine neurosurgeon. Finally, according to recent reports [16, 17], the rate of R0 resection could be above 85%, with the use of tri-modality protocols.

Contraindications for surgery would be due to metastasis, invasion of the brachial plexus above C7 & invasion of the spinal canal. Resection of the T1 nerve root is usually well tolerated, but removal of the C8 root or lower trunk of the brachial plexus leads to loss of hand and arm function. N2 disease is a relative contraindication and some groups enrol those patients after extended hilar radiation. As per JCOG [17] rib involvement occurs in 77.2% of the patients (usually 3 ribs or more), vertebra involvement in 10.5% of the patients, and major vessels in 5.3%. T1 involvement is the commonest root involved in up to 85% of the cases.

4. Various treatment modalities and tumour down-staging

According to Wright et al [10], marked difference in pathologic response based on the induction therapy is favouring CT/RT. Surgical resection of Pancoast tumours after neoadjuvant high-dose CT/RT was carried out in 40.5% of patients according to Kwong et al [18].

Pathological downstaging although it does not correlate with the radiological appearance [16] is reported to be impressively above 30% in various series. As per Pourel et al [15], pathological

complete response was observed in 39.5% of the patients, necrosis of tumoural tissues between 50% and 95% in 22.5% and less than 50% in 38% of the patients. Along the same lines JCOG reported [17] pathologic downstaging of the tumour in 40% of the patients; No residual viable tumour cells in the resected specimens, was achieved in 16% of the treated patients. Finally SWOG [16] summarised that pathologic no residual microscopic tumour was seen in one third of the resected specimens and minimal microscopic residual (few scattered tumour foci within a mostly necrotic or fibrotic mass), was observed in one third of the resected specimens.

5. What are the various surgical approaches

The approach of Paulson [19] is completely satisfactory in dealing with posteriorly located tumours; however, it is not fully adequate in the presence of invasion of anteriorly located structures (especially subclavian vessels or their branches). Therefore, different anterior approaches have been developed in the last 25 years, including the cervicosterno-thoracotomy [20] or the hemi-clamshell incision [21, 22], the transcervical-transthoracic approach with resection of the clavicle [23, 24], and the trans-manubrial approach [25]. Exact indications for these different approaches remain controversial, and few data are available about long-term outcome of patients treated by anterior approaches [22, 24, 26].

Posterior approach (Paulson)/ posterolateral-paravertebral thoracotomy: This is an extension of the conventional postero-lateral thoracotomy; the incision is extending around the tip of the scapula, then it continues upwards and further midway between the posterior edge of the scapula and the spinous processes, up to the level of C7. By taking the scapula of the chest wall this incision allows good exposure of the posterior chest wall, including the transverse processes, the vertebrae and the roots of the thoracic nerves and the plexus [27]. Nevertheless the exposure of the neuro-vascular structures are limited. This is due to the fact that brachial plexus and vascular structures often lie above the tumour mass and access to such structures, is significantly limited using approaches from below.

According to Vanakesa et al [28], Posterior approach, does not provide adequate access to the many important structures which may be involved by apical chest tumours of bronchogenic origin. This restricted access may be one of the reasons for the high rate of incomplete resections [29] and high surgical morbidity and mortality using this approach [10]. The anterior-cervical entry [24] proved to be the answer to the problem of limited exposure. It appears to be the optimal approach to anterior lung apex or first rib lesions [30].

We would facilitate a case like the one presented in Figure 1 by using an anterior-manubrial-sternal approach for access.

Accurate and thorough staging & re-staging (Radiological response is defined according to the RECIST criteria [31]) following neoadjuvant treatment is necessary prior to surgery (see Figure 2) and typically includes CT-PET and magnetic resonance imaging (Contrast-enhanced MRI of Chest and Brain). MRA is a noninvasive diagnostic method complementary to MR imaging for detecting vascular involvement in bronchogenic carcinoma with Pancoast syndrome [32].

IntechOpen

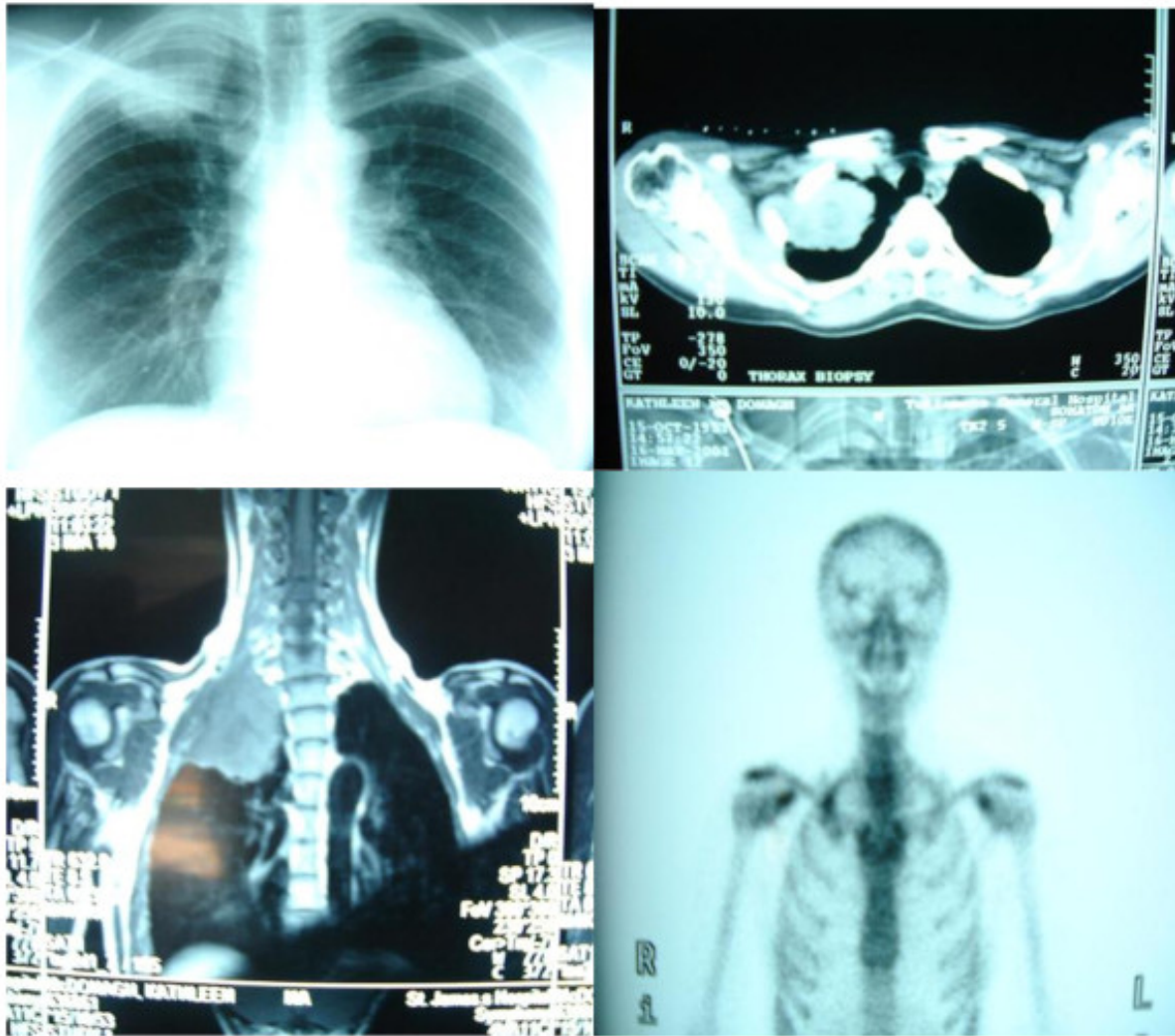


Figure 1. CXR, CT Chest imaging, MRI and bone scan of a Pancoast tumor of a 47 yrs old female, Ex smoker (25 cigs per day up to 13 years ago). Six weeks history of shoulder pain radiating to the median aspect of the right arm. CXR mass at apex of right chest. Percutaneous Biopsy NSCLC. PMH: Hysterectomy for Ca cervix 1996 - no evidence of recurrence. Clinical examination fullness in right supra-clavicular fossa.

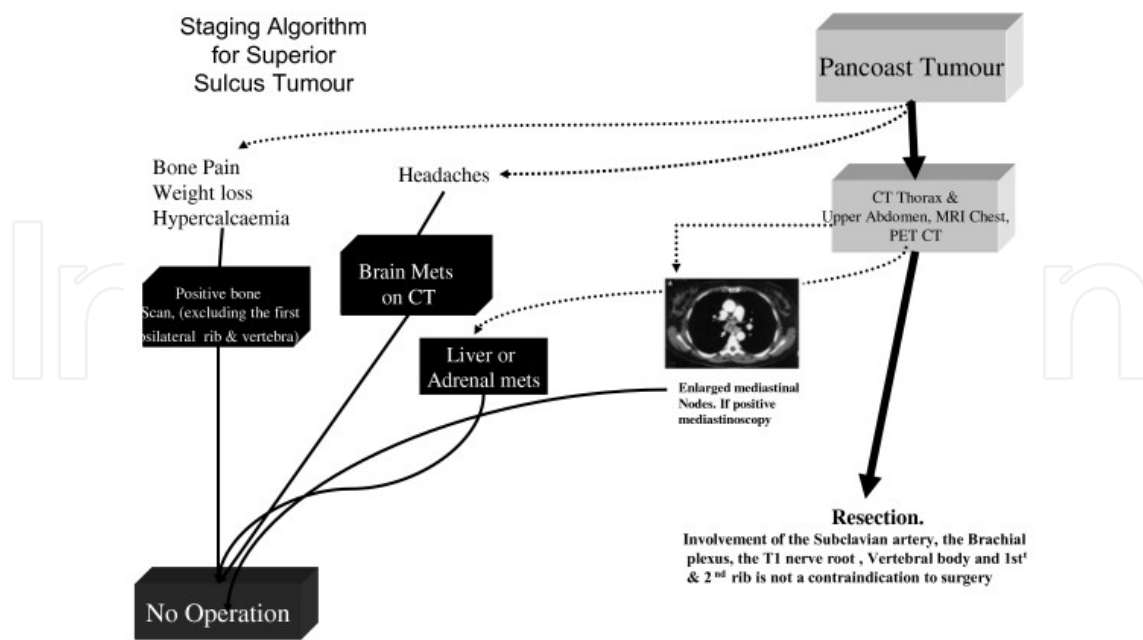


Figure 2. Staging algorithm for patients prior to resection of a Pancoast Tumor. MRI of the thoracic inlet may yield further information's on the status of vertebra involvement.

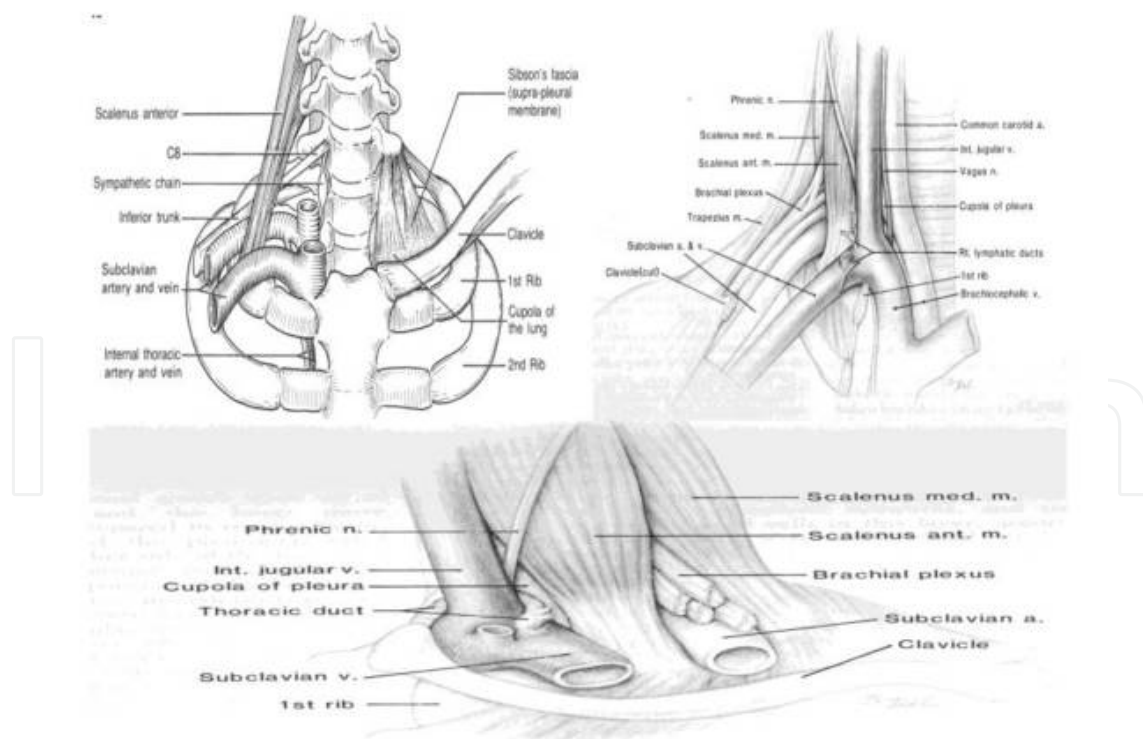


Figure 3. Root of neck anatomy, depicting carefully the relationship of the most important neurovascular structures to the scalene musculature and the first rib.

Root of neck anatomy as in Figure 3 is depicting carefully the relationship of the most important neuro-vascular structures to the scalene musculature and the first rib. The anterior and middle scalene muscles are attached to the first rib and can be used as landmarks: in front of the anterior scalene muscle situated the subclavian and internal jugular veins and the sternocleidomastoid and omo-hyoid muscles.

The subclavian artery, the trunks of the brachial plexus, and the phrenic nerve are emerging above the lateral part of the 1st rib between the anterior and middle scalene muscles. The nerve roots of the brachial plexus, the stellate ganglion, and the vertebral column are situated behind the middle scalene muscle.

6. Exposure and surgical steps (Figure 4)

We favour a modified Darteville approach [24] an L shaped incision at the anterior edge of Sterno-cleido-mastoid (a). Division of the upper sternum extended into 2nd intercostal space (b). This is a modified access something between Grunenwald [25] and Klima et al [33] approach. Grunenwald has described a trans-manubrial approach, which avoids division of the clavicle. Klima and colleagues suggested extending the L-shaped section of the manubrium down to the first intercostal space. We prefer to divide the sternum down to the angle of Luis and then extend the incision horizontally along the 2nd intercostal space, thus allowing the surgeon to lift the clavicle, subclavian muscle, and transected part of the manubrium and superior body of the sternum without dividing the first costal cartilage and ligament. The internal mammary artery is encountered and divided during the horizontal intercostal incision.

Mobilisation & excision of the supra-clavicular fat pad (c), allows exposure of the structures at the thoracic inlet; further division of the subclavious, omohyoid with preservation of the accessory nerve is carried out.

The distal part of the jugular veins is divided to expose the subclavian and innominate veins. If the subclavian vein is affected then it is resected. Following this, the scalenus anterior muscle is divided by taking care to preserve the phrenic nerve (d) & (e). The subclavian artery is mobilised by, dividing most of its branches. Care is taken to preserve the vertebral artery and resection of the vessel is done only if it is involved with the tumour and no substantial extra-cranial occlusive disease can be detected on preoperative Doppler ultrasound.

If the subclavian artery is taken up by tumour, the affected portion is resected and reconstructed, usually with a 6-8 mm PTFE vascular graft. Small dose of heparin is usually administered during vascular clamping.

Following anterior traction of the subclavian artery, the scalenus medius muscle comes into good view. The muscle is divided above its insertion on the first rib, giving access to the brachial plexus. Familiarity with the anatomy of the plexus is important. At this stage, the anterior surface of the vertebral bodies of C7 and T1 are in view. The sympathetic chain and stellate ganglion are lying in front of the anterior surface of the vertebral bodies of C7 and T1.

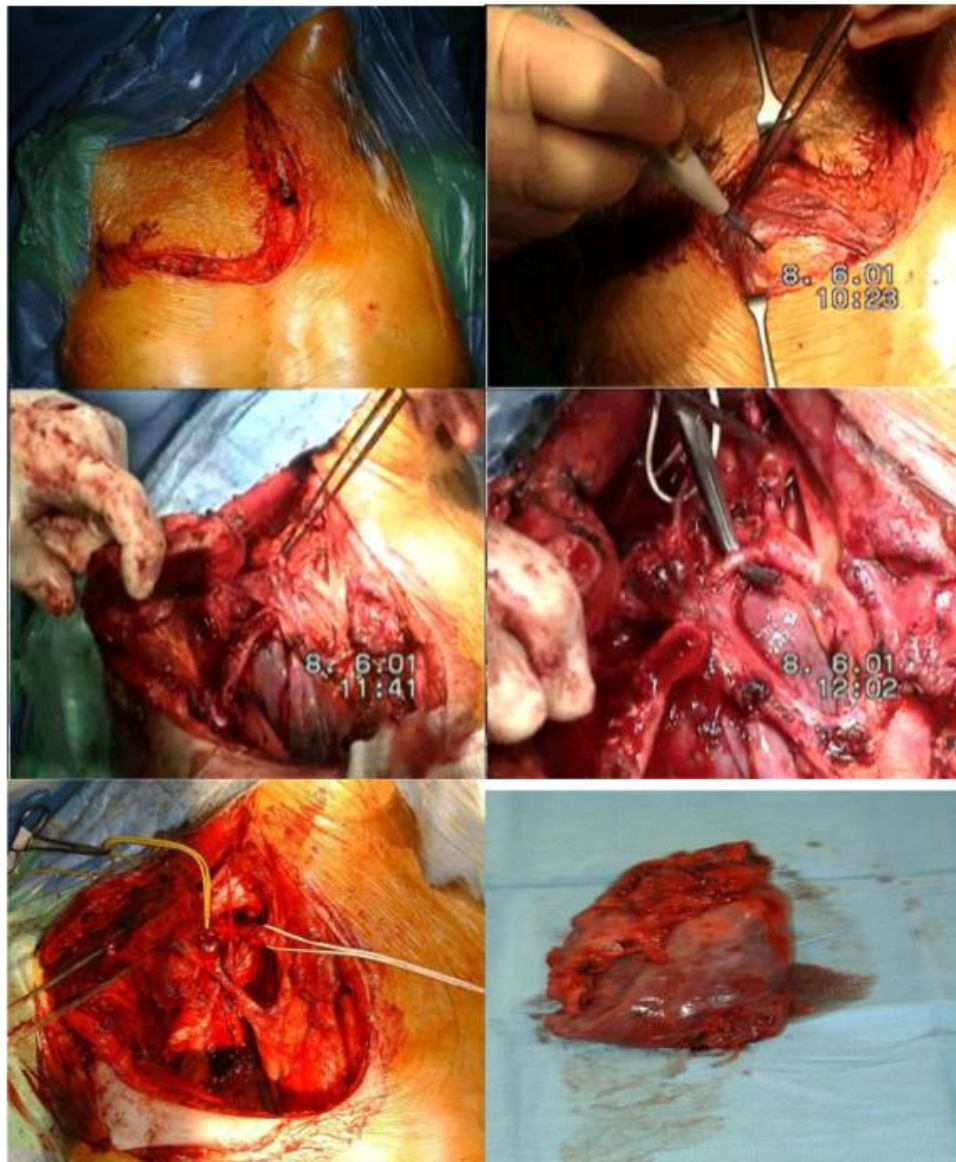


Figure 4. Step by step resection of a Pancoast tumor through an Antero-cervical approach. Incision at the anterior edge of Sternal-cleido-mastoid (a). Division of the upper sternum extended into 2nd intercostal space (b). Mobilisation-Excision of supraclavicular fat pad (c). Exposure of the structures at the thoracic inlet by dividing the subclavius, omohyoid with preservation of the accessory nerve. Division of the Scaleneus anterior with preservation of the phrenic nerve (d) & (e). Right upper Lobectomy (f): can be performed through the neck incision or a posterolateral thoracotomy.

The C8 and T1 nerve roots are visualised and dissected medially up to the lower trunk of the brachial plexus. The C8 nerve component of the plexus is preserved if possible, for better functional outcome of the upper limb.

Care is taken then, to assess tumour invasion and plan with the neurosurgeon the “spinal component” of the operation.

Chest wall resection is carried out by dividing the first 2-3 ribs at the sternal-costal-chondral junction following by disarticulation of the ribs from the transverse processes at the back. The

last part of the resection consists of the upper Lobectomy (f). The access to perform a lobectomy and mediastinal lymph node clearance through the anterior incision is usually limited, therefore like others [34] we perform a traditional postero-lateral thoracotomy through the 5th inter-costal space. Routine coverage of the bronchial stump with an intercostal or serratus muscle flap is advocated by some groups [18] to counteract any potential damage on the stump from the neoadjuvant radiation. Chest wall reconstruction may be necessary in up to 40% of the cases [34].

For Pancoast carcinomas affecting the spine, a posterior midline approach can be added by a neurosurgeon, for multilevel unilateral laminectomy[35], nerve root division inside the spinal canal, and vertebral body division along the midline. The tumour then is removed en bloc with the lung, ribs, and vessels through the posterior incision. Fixation of the spine is mandatory.

7. Anterior approach: Advantages and dis-advantages

7.1. Advantages

According to Machiarini et al [36] one of the major advances in the treatment of Pancoast tumours has been the introduction of anterior approaches for resection. These approaches increase the likelihood of complete resection and permit resection of tumours that were previously considered technically unresectable [37].

Furthermore anterior approach facilitates: 1) Direct visualisation of major structures (eg. Subclavian artery, superior vena cava) thus allowing control and elective sacrifice of the artery if necessary and reconstruct directly to a safe outcome. 2) Excellent exposure of the brachial plexus, sympathetic chain, and stellate ganglion. 3) Carry out hemi-vertebrectomy if the anterior body of the vertebra are involved. 4) Resection of the lower parts of the Brachial plexus, especially of the C8, T1 roots; however T1 root resection results in diffuse weakness of the intrinsic muscles of the hand, whereas resection of the C8 nerve root of the lower trunk of the brachial plexus results in permanent paralysis of the hand muscles. 5) Optimal access, for resection of the chest wall. 6) Oncological clearance of the structures of the Thoracic inlet, because the tumour is the last to be encountered. 7) Lower morbidity than the posterior approach.

Moreover as per Vanakesa et al [28] the cervical-trans-sternal approach has several advantages, chiefly that of avoiding disfigurement and loss of function of the pectoral girdle, whilst providing excellent exposure of the brachial plexus, sympathetic chain, and stellate ganglion. Such an approach results in a short postoperative stay (3–6 days), and yet allows extension as per Grunenwald [25], or by a high, anterior thoracotomy if necessary.

7.2. Disadvantages

Removal of transverse processes and the head of the ribs in order to disarticulate them, could be difficult with the anterior access; furthermore more posterior seated tumours with vertebra involvement may require a complimentary posterior incision.

There are concerns about functional and aesthetic results with the trans-clavicular approach, which includes removal of the medial half of the clavicle.

8. Results from literature review

Unfavourable outcome is due to incomplete resection and life-threatening complications. Current reports are quoting peri-operative mortality not higher than for any other lung resection [16, 17].

The prognosis of this tumour remained poor until 1961 when Shaw et al [38] reported their satisfactory experience with a bi-modality treatment based on preoperative radiotherapy followed by surgery through a posterior thoracotomy approach. Several other reports [2, 10, 19, 29, 38-41] confirmed that 5-year survivals of approximately 10 to 35% could be achieved with this combined approach, which became the standard treatment. Although radiotherapy was performed prior to surgery in most series, in the experience of others [24, 26] it was often carried out postoperatively.

Adverse prognostic factors are including the presence of mediastinal nodal metastases (N2 disease), spine or subclavian-vessel involvement (T4 disease), and limited resection (R1 or R2) [42-44]. Along the same lines Ginsberg et al [2] found Horner's syndrome, N2/N3 disease, T4 disease and incomplete resection, in general, to be adverse prognostic factors. Okubo and associates [29][16] found that incomplete resection particularly tumour invasion to the brachial plexus, influenced the prognosis.

9. Recurrence & survival

With bi-modality regimes the local recurrence rates were reported to be above 70% [10, 13]. Despite the advent in treatment regimes, local recurrence still occurs in about 40% of the patients [43]; it is expected that local recurrence rate is higher in patients with T4 disease because complete resection can be achieved in less than half of the patients with c-T4 disease [17]. More specifically [44] complete resection rate was achieved in only 64% of tumour stage T3 and nodal stage N 0 and 39% of T4N0 tumours. It is apparent however, that loco-regional relapse is predominant in R1-2 resections, whereas distant recurrence is frequent in R0 resections.

One would expect that a shift in the trend of clinical recurrences towards distant metastasis is to be currently expected because of the fact that tri-modality treatment facilitates better R0 resection. As per Pourel et al [15] the most frequent site of relapse was distant metastasis in 66% of the patients, (mainly brain) with the loco-regional recurrence rate of 18%. Likewise Kwong et al [18] reported brain metastasis in 25% and local recurrence rate in 19% of the cases. A small series that had bi-modality treatment however had an incidence of loco-regional recurrence of 17.2% [14].

Survival has been extensively reviewed by Attar et al [45]. Overall survival at 5 years after surgery was 46% for T3N0, 13% for T4N0, and 0% for lesions with N2 disease [44]. Particularly noteworthy [17] was the reproducibility of the favourable survival data, with a 5-year overall survival rate of 44% in the United States trial (SWOG) and 56% in JCOG trial, which were clearly superior to the historical value of 30%.

There is wide variability in overall 5-year survival rates reported in larger series, [19, 24, 26, 39, 41, 44, 46] with figures ranging 10 to 35% probably because of the heterogeneity in studied populations, operative techniques, and preoperative and postoperative treatments. Such heterogeneity is probably responsible for the difference in the percentage of T3 and T4 tumours as well as in the rates of complete resection. Comparison of long-term results of different studies is difficult also for the frequent lack of information about survival according to the pathologic stage.

10. Future thoughts

In the future new neoadjuvant regimes including aggressive protocols of accelerated radiotherapy would potentially increase the pool of surgical candidates from patients diagnosed with a Pancoast tumour (currently 23% of the patients as per Kappers et al [13]. However, several questions still remain unresolved:

- 1) The role of PET-CT in re-staging tumours (eg. The role of “late wash out” images in differentiating between inflammation and residual tumour) following neo-adjuvant treatment; Schmuecking et al [47] have shown that metabolic response after induction CT/RT evaluated within 1 week following its completion, is highly predictive of pathological response.
- 2) What is the significance and implications of ipsilateral supra-clavicular lymph node disease: The argument being that these nodes are in close vicinity of the tumour and therefore could have the characteristics of the biological behaviour of “N1 disease”.
- 3) Recruiting patients with N2 disease: The argument being that inclusion of the hilar and mediastinal nodes in the irradiation field promotes downstaging. Kwong et al [18] did not exclude patients with positive mediastinal nodes from tri-modality treatment and found no difference in survival. In most papers, however, results of patients with persistent N2 disease turned out to be clearly inferior to those of patients with N0/1 only. On the other hand, no clinical trial has yet compared various tri-modality treatment regimes for patients with N2 disease.
- 4) The role of prophylactic cranial irradiation: Due to good loco-regional control with tri-modality treatment, distant metastases now represent the most common site of failure. Furthermore, the incidence of brain metastasis as a first site of recurrence in Pancoast tumour is between 15-30% [34, 48]. The negative impact of brain metastasis on survival has to be weighted against the risks/benefits/ratio of the impact of prophylaxis with radiation to the brain.
- 5) The role of high dose of RT (up to 60Gy): Are there specific subgroups (eg. for patients with clinical T4 disease complete resection is feasible in less than 50% of the cases) that they would benefit.
- 6) The role of Adjuvant postoperative chemotherapy: distant metastases now represent the most common site of failure following treatment for Pancoast tumours therefore

preventing distant metastasis has now become the challenge in the treatment of these patients. Large randomised trials concluded a 5–15% survival benefit at 5 years of adjuvant chemotherapy in patients with radically resected stages I–IIIA NSCLC [49, 50]. However, many patients with Pancoast tumours may not tolerate more extensive treatment. Moreover Martinod et al [26] reported that preoperative radiotherapy significantly improved the 5-year survival for stage IIB–IIIA, while postoperative radiotherapy and chemotherapy did not significantly alter survival. 7) Is the Survival with the use of anterior approach better versus posterior approach for the same stage of Pancoast tumours?

11. Conclusion

Pancoast tumours represent a small percentage of Lung cancer population (1-5%). Due to poor performance status and/or advanced tumour stages, only 30-40 % [10, 13] of those patients are eligible to be enrolled in multi-modality protocols of treatment.

Careful patient selection and adherence to protocols enables Clinical groups to get an impression of the efficacy of an intervention and to compare results between studies.

Superior sulcus tumours remain an extremely severe condition, but cure may be achieved in a large percentage of cases. The surgical approach should be adapted to the different clinical and radiologic presentations in order to achieve a complete surgical resection, which represents the most important positive prognostic factor. Surgery carries a high operative risk, especially if a combined approach is needed, so every effort should be made to identify patients expected to derive a benefit that outweighs risks.

No single surgical approach however, provides the best access to all of the heterogeneous tumours of the thoracic inlet. The thoracic surgeon must be familiar with the potential advantages that the anterior approach offers under given circumstances. This knowledge enables the thoracic surgeon to explore new avenues and exciting challenges. Dartevilles approach and the various modifications are technically demanding, however once the anatomy has been appreciated, direct visualisation of the major structures of the Thoracic inlet aids to facilitate complete oncological clearance. Whether the anterior approach results in less loco-regional recurrences and possibly better 5 year survival, remains to be seen.

12. Summary

12.1. Introduction

Pancoast syndrome is due to lesions extending to the superior thoracic inlet. Pancoast tumour is a tumour of the apex of the lung with no intervening lung tissue between tumour and chest wall. The tumour rapidly involves the structures of the thoracic inlet & the root of neck.

Pain at the ulnar aspect of the forearm and hand is consistent with T1 involvement; furthermore symptomatology along the intrinsic hand muscles suggests the C8 root or lower trunk tumor deposits.

An understanding of the posterior location of neural structures and somewhat anterior location of vascular structures is important for adequate operative planning.

Pancoast tumours were thought to be located posteriorly and early attempts to resect those tumors were approached solely from the back. A percentage of these lesions might also be located at the front, with vascular rather than neuro- vertebral involvement. Therefore surgeons treating these cancers should be able to be familiar and adapt with the various approaches.

12.2. Surgical Approaches

1. Posterior approach (Paulson)/ posterolateral-paravertebral thoracotomy: This is an extension of the conventional postero-lateral thoracotomy; the incision is extending around the tip of the scapula, then it continuous upwards and further midway between the posterior edge of the scapula and the spinous processes, up to the level of C7. By taking the scapula of the chest wall this incision allows good exposure of the posterior chest wall, including the transverse processes, the vertebrae and the roots of the thoracic nerves and the plexus. Never the less the exposure of the neurovascular structures are limited.
2. The anterior-cervical approach proved to be the answer to the problem of limited exposure. It appears to be the optimal approach to anterior lung apex and first rib lesions.

We favour a modified Darteville approach We prefer to divide the sternum down to the angle of Luis and then extend the incision horizontally along the 2nd intercostal space, thus allowing the surgeon to lift the clavicle, subclavian muscle, and transected part of the manubrium and superior boby of the sternum without dividing the first costal cartilage and ligament.

Mobilisation & excision of the supraclavicular fat pad, allows exposure of the structures at the thoracic inlet; further division of the subclavius, omohyoid with preservation of the accessory nerve is carried out.

The distal part of the jugular veins is divided to expose the subclavian and innominate veins. If the subclavian vein is affected then it is resected. Following this, the scalenus anterior muscle is divided by taking care to preserve the phrenic nerve.

The subclavian artery is mobilized by, dividing most of its branches. Care is taken to preserve the vertebral artery and resection of the vessel is done only if it is involved with the tumor and no substantial extracranial occlusive disease can be detected on preoperative Doppler ultrasound.

12.3. The advantages of the anterior- cervical approach

1. Direct visualization of major structures (eg. Subclavian artery), allowing control and elective sacrifice if necessary the artery and reconstruct directly to a safe outcome.

2. Carry out hemi-vertebrectomy if the anterior body of the vertebra are involved.
3. Provide complete oncological clearance of the structures of the Thoracic inlet. The structures which may be sacrificed if involved are the Subclavian artery, the Brachial plexus the T1 nerve root and Vertebral body

12.4. Down-staging

Pathological down-staging although it does not correlate with the radiological appearance is reported to be impressively above 30% in various series.

JCOG reported pathologic down-staging of the tumour in 40% of the patients; No residual viable tumour cells in the resected specimens, was achieved in 16% of the treated patients. Also SWOG summarised that pathologic no residual microscopic tumour was seen in one third of the resected specimens and minimal microscopic residual (few scattered tumour foci within a mostly necrotic or fibrotic mass), was observed in one third of the resected specimens.

12.5. Results

Unfavorable outcome is due to incomplete resection and life-threatening complications. Current reports are quoting perioperative mortality not higher than for any other lung resection. Adverse prognostic factors are including the presence of mediastinal nodal metastases (N2 disease), spine or subclavian-vessel involvement (T4 disease), and limited resection (R1 or R2.

Author (year)	No. of Cases	5 year survival (%)	Mortality (%)
Paulson DL (1985)	79	35	3
Maggi et al (1994)	60	17.4	5
Ginberg et al (1994)	100	26	4
Okubo et al (1995)	18	38.5	5.6
Hagan et al (1999)	34	33	0
Darteville P (1999)	70	34	0

Table 1. Survival with the use of the anterior versus posterior approach

12.6. Recurrence

With bimodality regimes the local recurrence rates were reported to be above 70%. Despite the advent in treatment regimes, local recurrence still occurs in about 40% of the patients; it is expected that local recurrence rate is higher in patients with T4 disease because complete resection can be achieved in less than half of the patients with c-T4 disease. More specifically complete resection rate was achieved in only 64% of tumour stage T3 and nodal stage N 0 and 39% of T4N0 tumours.

It is apparent however, that locoregional relapse is predominant in R1-2 resections, whereas distant recurrence is frequent in R0 resections.

In the future new neoadjuvant regimes including aggressive protocols of accelerated radiotherapy would potentially increase the pool of surgical candidates from patients diagnosed with a Pancoast tumor (currently 23% of the patients as per Kappers et al). However, several questions still remain unresolved such as the role of PET, nodal involvement especially recruiting patients with N2 disease. Lastly the role of trimodality treatment and prophylactic cranial irradiation

12.7. Conclusion

Pancoast tumors represent a small percentage of Lung cancer population (1-5%). Due to poor performance status and/or advanced tumor stages, only 30-40 % of those patients are eligible to be enrolled in multimodality protocols of treatment.

No single surgical approach however, provides the best access to all heterogeneous tumors of the thoracic inlet. What probably provides the most favorable outcome would be a team approach, where the thoracic surgeon coordinates with an experience neuro-spinal surgeon, in a background of limited disease that is responding well to neoadjuvant chemoradiotherapy.

Author details

Haralabos Parissis*, Alan Soo and Bassel Al-Alao

*Address all correspondence to: hparissis@yahoo.co.uk

Cardiothoracic Surgery Department, Royal Victoria Hospital, Belfast, Northern Ireland

References

- [1] Bridgewater B KR, Walton P. Sixth National Adult Cardiac Surgical Database Report. Society for Cardiothoracic Surgery in Great Britain and Ireland 2008. Report No.: ISBN 1-903968-23-2. 2009.
- [2] Ginsberg RJ, Martini N, Zaman M, Armstrong JG, Bains MS, Burt ME, McCormack PM, Rusch VW, Harrison LB. Influence of surgical resection and brachytherapy in the management of superior sulcus tumor. *Ann Thorac Surg* 1994 Jun;57(6):1440-5.
- [3] Pancoast H. Superior pulmonary sulcus tumor: tumor characterized by pain, Horner's syndrome, destruction of the bone and atrophy of hand muscles. *JA-MA* 1932;99:1391-6.

- [4] Tobias J. Síndrome apico-costovertebral-doloroso por tumor apical: su valor diagnóstico en el cáncer primitivo pulmonar. *Rev Med Lat-Am* 1932;17:1522-56.
- [5] Arcasoy SM, Jett JR. Superior pulmonary sulcus tumors and Pancoast's syndrome. *N Engl J Med* 1997 Nov 6;337(19):1370-6.
- [6] Jett JR. Superior sulcus tumors and Pancoast's syndrome. *Lung Cancer* 2003 Dec;42 Suppl 2:S17-21.
- [7] Tsao JW, Garlin AB, Marder SR. Pancoast's syndrome. *N Engl J Med* 1998 Mar 12;338(11):765-6.
- [8] Pitz CC, de la Riviere AB, van Swieten HA, Duurkens VA, Lammers JW, van den Bosch JM. Surgical treatment of Pancoast tumours. *Eur J Cardiothorac Surg* 2004 Jul;26(1):202-8.
- [9] Mansour K. Extended resection of bronchial carcinoma in the superior pulmonary sulcus. In: Shields T, editor. *General thoracic surgery*. Baltimore: Williams and Wilkins; 1994. p. 572-8.
- [10] Wright CD, Moncure AC, Shepard JA, Wilkins EW, Jr., Mathisen DJ, Grillo HC. Superior sulcus lung tumors. Results of combined treatment (irradiation and radical resection). *J Thorac Cardiovasc Surg* 1987 Jul;94(1):69-74.
- [11] Komaki R, Putnam JB, Jr., Walsh G, Lee JS, Cox JD. The management of superior sulcus tumors. *Semin Surg Oncol* 2000 Mar;18(2):152-64.
- [12] Rusch VW. Management of Pancoast tumours. *Lancet Oncol* 2006 Dec;7(12):997-1005.
- [13] Kappers I, Belderbos JS, Burgers JA, van Zandwijk N, Groen HJ, Klomp HM. Non-small cell lung carcinoma of the superior sulcus: favourable outcomes of combined modality treatment in carefully selected patients. *Lung Cancer* 2008 Mar;59(3):385-90.
- [14] Wright CD, Menard MT, Wain JC, Donahue DM, Grillo HC, Lynch TJ, Choi NC, Mathisen DJ. Induction chemoradiation compared with induction radiation for lung cancer involving the superior sulcus. *Ann Thorac Surg* 2002 May;73(5):1541-4.
- [15] Pourel N, Santelmo N, Naafa N, Serre A, Hilgers W, Mineur L, Molinari N, Reboul F. Concurrent cisplatin/etoposide plus 3D-conformal radiotherapy followed by surgery for stage IIB (superior sulcus T3N0)/III non-small cell lung cancer yields a high rate of pathological complete response. *Eur J Cardiothorac Surg* 2008 May;33(5):829-36.
- [16] Rusch VW, Giroux DJ, Kraut MJ, Crowley J, Hazuka M, Johnson D, Goldberg M, Detterbeck F, Shepherd F, Burkes R, Winton T, Deschamps C, Livingston R, Gandara D. Induction chemoradiation and surgical resection for non-small cell lung carcinomas of the superior sulcus: Initial results of Southwest Oncology Group Trial 9416 (Inter-group Trial 0160). *J Thorac Cardiovasc Surg* 2001 Mar;121(3):472-83.
- [17] Kunitoh H, Kato H, Tsuboi M, Shibata T, Asamura H, Ichinose Y, Katakami N, Nagai K, Mitsudomi T, Matsumura A, Nakagawa K, Tada H, Saijo N. Phase II trial of pre-

operative chemoradiotherapy followed by surgical resection in patients with superior sulcus non-small-cell lung cancers: report of Japan Clinical Oncology Group trial 9806. *J Clin Oncol* 2008 Feb 1;26(4):644-9.

- [18] Kwong KF, Edelman MJ, Suntharalingam M, Cooper LB, Gamliel Z, Burrows W, Hausner P, Doyle LA, Krasna MJ. High-dose radiotherapy in trimodality treatment of Pancoast tumors results in high pathologic complete response rates and excellent long-term survival. *J Thorac Cardiovasc Surg* 2005 Jun;129(6):1250-7.
- [19] Paulson DL. Carcinomas in the superior pulmonary sulcus. *J Thorac Cardiovasc Surg* 1975 Dec;70(6):1095-104.
- [20] Masaoka A, Ito Y, Yasumitsu T. Anterior approach for tumor of the superior sulcus. *J Thorac Cardiovasc Surg* 1979 Sep;78(3):413-5.
- [21] Bains MS, Ginsberg RJ, Jones WG, 2nd, McCormack PM, Rusch VW, Burt ME, Martini N. The clamshell incision: an improved approach to bilateral pulmonary and mediastinal tumor. *Ann Thorac Surg* 1994 Jul;58(1):30-2; discussion 3.
- [22] Korst RJ, Burt ME. Cervicothoracic tumors: results of resection by the "hemi-clamshell" approach. *J Thorac Cardiovasc Surg* 1998 Feb;115(2):286-94; discussion 94-5.
- [23] Darteville P, Levasseur P, Rojas-Miranda A, Merlier M, Le Brigand H. [Combined cervical and thoracic approach to the removal of tumours responsible for the Pancoast and Tobias syndrome (author's transl)]. *Nouv Presse Med* 1981 Mar 21;10(13):1051-4.
- [24] Darteville PG, Chapelier AR, Macchiarini P, Lenot B, Cerrina J, Ladurie FL, Parquin FJ, Lafont D. Anterior transcervical-thoracic approach for radical resection of lung tumors invading the thoracic inlet. *J Thorac Cardiovasc Surg* 1993 Jun;105(6):1025-34.
- [25] Grunenwald D, Spaggiari L. Transmanubrial osteomuscular sparing approach for apical chest tumors. *Ann Thorac Surg* 1997 Feb;63(2):563-6.
- [26] Martinod E, D'Audiffret A, Thomas P, Wurtz AJ, Dahan M, Riquet M, Dujon A, Janovic R, Giudicelli R, Fuentes P, Azorin JF. Management of superior sulcus tumors: experience with 139 cases treated by surgical resection. *Ann Thorac Surg* 2002 May;73(5):1534-9; discussion 9-40.
- [27] Kent MS, Bilsky MH, Rusch VW. Resection of superior sulcus tumors (posterior approach). *Thorac Surg Clin* 2004 May;14(2):217-28.
- [28] Vanakesa T, Goldstraw P. Antero-superior approaches in the practice of thoracic surgery. *Eur J Cardiothorac Surg* 1999 Jun;15(6):774-80.
- [29] Okubo K, Wada H, Fukuse T, Yokomise H, Inui K, Ike O, Mizuno H, Aoki M, Hitomi S. Treatment of Pancoast tumors. Combined irradiation and radical resection. *Thorac Cardiovasc Surg* 1995 Oct;43(5):284-6.

- [30] Ducic Y, Crepeau A, Ducic L, Lamothe A, Corsten M. A logical approach to the thoracic inlet: the Darteville approach revisited. *Head Neck*1999 Dec;21(8):767-71.
- [31] Therasse P, Arbuck SG, Eisenhauer EA, Wanders J, Kaplan RS, Rubinstein L, Verweij J, Van Glabbeke M, van Oosterom AT, Christian MC, Gwyther SG. New guidelines to evaluate the response to treatment in solid tumors. European Organization for Research and Treatment of Cancer, National Cancer Institute of the United States, National Cancer Institute of Canada. *J Natl Cancer Inst*2000 Feb 2;92(3):205-16.
- [32] Laissy JP, Soyer P, Sekkal SR, Tebboune D, Servois V, Sibert A, Menu Y. Assessment of vascular involvement with magnetic resonance angiography (MRA) in Pancoast syndrome. *Magn Reson Imaging*1995;13(4):523-30.
- [33] Klima U LA, Haverich A. ransmanubrial approach repropoed: reply. *Ann Thorac Surg*1999;68:1888.
- [34] Marra A, Eberhardt W, Pottgen C, Theegarten D, Korfee S, Gauler T, Stuschke M, Stamatis G. Induction chemotherapy, concurrent chemoradiation and surgery for Pancoast tumour. *Eur Respir J*2007 Jan;29(1):117-26.
- [35] Fadel E, Missenard G, Chapelier A, Mussot S, Leroy-Ladurie F, Cerrina J, Darteville P. En bloc resection of non-small cell lung cancer invading the thoracic inlet and intervertebral foramina. *J Thorac Cardiovasc Surg*2002 Apr;123(4):676-85.
- [36] Macchiarini P. Resection of superior sulcus carcinomas (anterior approach). *Thorac Surg Clin*2004 May;14(2):229-40.
- [37] Tamura M, Hoda MA, Klepetko W. Current treatment paradigms of superior sulcus tumours. *Eur J Cardiothorac Surg*2009 Oct;36(4):747-53.
- [38] Shaw RR, Paulson DL, Kee JL. Treatment of Superior Sulcus Tumor by Irradiation Followed by Resection. *Ann Surg*1961 Jul;154(1):29-40.
- [39] Devine JW, Mendenhall WM, Million RR, Carmichael MJ. Carcinoma of the superior pulmonary sulcus treated with surgery and/or radiation therapy. *Cancer*1986 Mar 1;57(5):941-3.
- [40] Hilaris BS, Martini N, Luomanen RK, Batata M, Beattie EJ, Jr. The value of preoperative radiation therapy in apical cancer of the lung. *Surg Clin North Am*1974 Aug;54(4):831-40.
- [41] Sartori F, Rea F, Calabro F, Mazzucco C, Bortolotti L, Tomio L. Carcinoma of the superior pulmonary sulcus. Results of irradiation and radical resection. *J Thorac Cardiovasc Surg*1992 Sep;104(3):679-83.
- [42] Alifano M, D'Aiuto M, Magdeleinat P, Poupardin E, Chafik A, Strano S, Regnard JF. Surgical treatment of superior sulcus tumors: results and prognostic factors. *Chest*2003 Sep;124(3):996-1003.

- [43] Pfannschmidt J, Kugler C, Muley T, Hoffmann H, Dienemann H. Non-small-cell superior sulcus tumor: results of en bloc resection in fifty-six patients - non-small-cell pancoast. *Thorac Cardiovasc Surg*2003 Dec;51(6):332-7.
- [44] Rusch VW, Parekh KR, Leon L, Venkatraman E, Bains MS, Downey RJ, Boland P, Bilsky M, Ginsberg RJ. Factors determining outcome after surgical resection of T3 and T4 lung cancers of the superior sulcus. *J Thorac Cardiovasc Surg*2000 Jun;119(6):1147-53.
- [45] Attar S, Krasna MJ, Sonett JR, Hankins JR, Slawson RG, Suter CM, McLaughlin JS. Superior sulcus (Pancoast) tumor: experience with 105 patients. *Ann Thorac Surg*1998 Jul;66(1):193-8.
- [46] Maggi G, Casadio C, Pischedda F, Giobbe R, Cianci R, Ruffini E, Molinatti M, Mancuso M. Combined radiosurgical treatment of Pancoast tumor. *Ann Thorac Surg*1994 Jan;57(1):198-202.
- [47] M. Schmuecking CPS, N. Presselt, R. P. Baum, J. Leonhardi, K. Hoeffken, A. Niesen, K. M. Mueller, T. G. Wendt, R. Bonnet, LUCAS-MD Study Group, editor Are timing of chemoradiation and early therapy response as detected by PET prognostic factors of a multimodality treatment approach for NSCLC stage III? (LUCAS-MD). 2007 ASCO Annual Meeting; 2007.
- [48] Komaki R, Derus SB, Perez-Tamayo C, Byhardt RW, Hartz A, Cox JD. Brain metastasis in patients with superior sulcus tumors. *Cancer*1987 May 1;59(9):1649-53.
- [49] Arriagada R, Bergman B, Dunant A, Le Chevalier T, Pignon JP, Vansteenkiste J. Cisplatin-based adjuvant chemotherapy in patients with completely resected non-small-cell lung cancer. *N Engl J Med*2004 Jan 22;350(4):351-60.
- [50] Erman M, Moretti L, Soria JC, Le Chevalier T, Van Houtte P. Adjuvant chemotherapy and radiotherapy in non-small cell lung cancer. *Semin Radiat Oncol*2004 Oct;14(4):315-21.

