

# We are IntechOpen, the world's leading publisher of Open Access books Built by scientists, for scientists

6,900

Open access books available

185,000

International authors and editors

200M

Downloads

Our authors are among the

154

Countries delivered to

TOP 1%

most cited scientists

12.2%

Contributors from top 500 universities



WEB OF SCIENCE™

Selection of our books indexed in the Book Citation Index  
in Web of Science™ Core Collection (BKCI)

Interested in publishing with us?  
Contact [book.department@intechopen.com](mailto:book.department@intechopen.com)

Numbers displayed above are based on latest data collected.  
For more information visit [www.intechopen.com](http://www.intechopen.com)



---

# Echocardiography and Hemodynamic Monitoring Tools for Clinical Assessment of Patients on Mechanical Circulatory Support

---

Sabino Scolletta, Bonizella Biagioli,  
Federico Franchi and Luigi Muzzi

Additional information is available at the end of the chapter

<http://dx.doi.org/10.5772/55918>

---

## 1. Introduction

Mechanical circulatory support (MCS) has become an essential part of the treatment strategy for patients suffering acute, reversible ventricular dysfunction or end-stage heart failure. Cardiac function and systemic blood flow monitoring in patients on ventricular assist device (VAD) is essential in order to avoid low output syndrome, which remains one of the leading causes of death after MCS.

Echocardiography is considered as the procedure of choice for the evaluation of cardiac performance and to gather other critical information both in the pre, intra and postoperative phases. Also, echo-Doppler-based methods can be used to calculate the flow velocity and volume and hence systemic blood flow. Unfortunately, due to intrinsic nature, echocardiography cannot be considered a bedside continuous monitoring system.

Several methods are now available for blood flow assessment and cardiac output (CO) monitoring. An ideal hemodynamic monitoring system should comprise all the key factors listed in Table 1. However, such a system does not currently exist. Indeed, the ultrasonic flowmetry from the graft's outflow is considered as the gold standard method; however, its use is limited to the intraoperative period. The thermodilution continuous CO method is increasingly used. However, it incorporates a thermal coil integrated into the pulmonary artery catheter and it cannot be used in right VAD (RVAD) patients. Pulse contour methods derive systemic blood flow from the analysis of the arterial pressure waveform. They provide a fast response time and may represent suitable tools to assess CO and other hemodynamic variables in patients on MCS.

This chapter will review the most commonly used techniques to assess cardiac function and systemic blood flow in patients assisted with MCS.

### 1.1. Classification of MCS

Current devices for mechanical circulatory assistance provide a wide spectrum of support, ranging from short-term to intermediate and long-term duration [1,2], and the current indications for ventricular assist device implantation are: bridge to cardiac transplantation, bridge to recovery or destination therapy for patient not candidate to heart transplantation.

For these different purposes, different types of devices able to provide pulsatile or continuous blood flow are available for clinical use, and selection of MCS device mainly depends by the degree of the support required, the estimated duration of assistance, the invasiveness of the implantation procedure and the patient's need for postoperative mobility [3].

Over the years, three devices generations have succeeded and the rationale of the innovations and modifications has been mainly focused on decreasing the rate of complications, being the main determinant for patient outcome (chiefly thromboembolisms, bleeding, mechanical failure and infections).

#### 1.1.1. First-generation devices

The first generation devices (Thoratec paracorporeal ventricular assist device and Abiomed BVS 5000) were largely used for bridge to transplant or bridge to recovery. They were able to provide pulsatile flow by means of large paracorporeal consoles but were associated with high mortality and complication rates [4,5]. Nevertheless when used for patients as bridge to transplantation, survival to transplant improved and resulted in optimizing patients' overall hemodynamic status allowing them to be better surgical candidates [6].

#### 1.1.2. Second-generation ventricular assist devices

The second-generation of devices (HeartMate IP/XVE, Novacor and Arrow Lionheart) also provided pulsatile flow but were implanted as intra-corporeal pumps allowing greater patient mobility and resulting in reduced complications and infection rates compared to first-generation devices [3].

#### 1.1.3. Third-generation ventricular assist devices

The concept and the goal of destination therapy guided the development of third-generation VADs (HeartMate II, Berlin Incor, MicroMed DeBakey and Jarvik 2000) [3].

The clinical objectives of destination therapy VADs are to restore an adequate blood flow, preserving end-organ function and providing significant decompression of failing ventricle [7] virtually restoring a normal resting hemodynamics, exercise tolerance and normalizing metabolic as well as neuro-humoral functions [2].

Such devices are currently used and explored in clinical practice. They are fully implantable axial flow pumps, with design modifications (i.e., lack of percutaneous lines and implantation

within the pericardium avoiding the need for a pump pocket) that will decrease patient's complications [8].

## 1.2. Hemodynamic principles of VADs functioning: Basic concepts

VADs consist of electromechanical pumps usually placed in parallel with the native patient's circulation. Their principal components consist in:

1. *Inflow cannula.* Direct the blood from one of the heart chambers to the device. Typically, for a LVAD, the inflow cannula originates in the left atrium (LA) or left ventricle (LV). For a RVAD, the inflow cannula originates in the right atrium (RA) or right ventricle (RV).
2. *Pump.* Provides propulsion to the blood. The generated flow can be either pulsatile (pneumatically or electromechanically driven pumps, e.g., Abiomed BVS 5000, HeartMate I, Novacor, Thoratec), or continuous such as in the most recent axial-flow devices (HeartMate II, Jarvik 2000, MicroMed DeBakey, Berlin Incor Heart) [9-11] or centrifugal pumps (Biomedicus, Levitronix-Centrimag and TandemHeart) [12,13]. Because of the larger size, the requirement of unidirectional valves in the VAD inflow and outflow cannulas, and complicated control mechanism of pulsatile VADs, axial flow pumps have been gaining popularity [11]. In non-pulsatile axial-flow pumps, the propulsion principle is based on a rotating impeller pump, which ejects blood to the systemic circulation at a fixed rate depending on pump speed and inflow-outflow pressure gradient. The advantages of these systems are that they are smaller, do not require unidirectional valves, are more durable, and typically generate higher flows at lower pressures.
3. *Outflow cannula.* The outflow cannula returns the blood to the patient. The LVAD outflow cannula is usually anastomosed to the ascending aorta (or descending aorta with Jarvik 2000) and to the main pulmonary artery (PA) in RVAD.
4. *Controller.* The controller operates the pump by receiving and processing information from it.

Different devices and controllers range from paracorporeal VADs with transcutaneous inflow and outflow cannulas or intracorporeal VADs with transcutaneous drivelines, to completely implantable intra- or extra-ventricular systems. The VAD performance characteristics produce distinctive relationships between pressure and flow in the circulation. These will determine measured hemodynamic parameters as well as echocardiographic signals (such as the continuous (CW) and pulsed wave (PW) Doppler signals) [5,14].

## 2. Echocardiography in patients assisted with VAD

Since low-output syndrome with impaired tissue perfusion and organ dysfunction still remains the main cause of death in such patients [15,16], the determination of both left ventricular function and CO is a decisive and mandatory issue in all the patients implanted with VAD. Echocardiography is the principal tool to investigate the LV function whereas

different methods are available for CO estimation. Nonetheless, because of changes in hemodynamic and blood flow physiology related to every single device, the type of generated blood flow (pump type) and the position of cannulas and pump, respect to native patient's circulation, make the evaluation of CO and ventricular function a challenging issue.

## 2.1. Echocardiographic examination

Echocardiography is an important tool in the management of patients undergoing VAD implantation, since it can easily provide critical information about pre-operative anatomic abnormalities, guide the device implantation procedure, and evaluate post-insertion cardiac and device function. Combined information from both transthoracic (TTE) and transesophageal (TEE) echocardiography are used pre, intra and postoperatively to this purpose [17].

Echocardiographic assessment of patients undergoing VAD insertion involves aspects pertaining both to a general echocardiographic examination and to specific considerations associated with the VAD. The variety of VAD models with different basic and operational principles actually impose specific echocardiographic assessment targeted to the characteristics of the implanted device. This makes essential that the sonographer have a clear understanding of the specific device characteristics to perform a suitable examination. In addition to the standard assessment, essential device-specific considerations in the echocardiographic evaluation include:

- a. *pre-VAD examination.* This includes the analysis of the heart and large vessels to exclude significant abnormalities, such as aortic regurgitation, tricuspid regurgitation, mitral stenosis, pulmonic regurgitation, patent foramen ovale, or other pathologies leading to right-to-left shunt after LVAD insertion. Moreover, intracardiac thrombi, ventricular scars, pulmonary hypertension, pulmonary embolism, and atherosclerotic disease in the ascending aorta can be easily detected by TTE.
- b. *intra- and post-VAD examination.* The examination includes the device function evaluation and reassessment of the heart and large vessels. The examination of the device is focused to confirm the effective device and heart deairing, the cannulas or device alignment and patency, and competency of device valves using two-dimensional, color, continuous and pulsed wave Doppler modalities. Heart reassessment must provide information to exclude aortic regurgitation and intracardiac right-to-left shunt, as well as to assess the RV function, LV unloading, and the effect of device settings respect to global heart function.

## 2.2. Defects creating intracardiac shunts

### 2.2.1. Patent Foramen Ovale(PFO) and other abnormalities of interatrial septum

The presence of PFO must be always ascertained before and after cardiopulmonary bypass (CPB). Because of increased LA pressure with rightward deviation of the interatrial septum in patients with LV failure, investigation of a PFO with color-Doppler echocardiography in the

pre-CPB period can be easily performed (demonstrating a left-to-right shunt). Conversely a bubble study may not reveal a PFO due to the difficulty in producing a reversal of the left-to-right atrial pressure gradient in the presence of left heart failure. Likewise, in the case of biventricular failure, increased RA and LA pressures reduce the interatrial pressure gradient, hindering PFO detection by both agitated saline and color-Doppler. It must be always kept in mind that patients without a detected PFO in the pre-CPB examination can present it once LVAD becomes operating, because the LV unloading and decreased LA pressure associated with maintained/increased right heart pressures, may open an unsealed PFO. Those hemodynamic conditions can favour a paradoxical embolism. Because the presence of right-to left shunt can result in the development of severe hypoxemia (with the degree of shunting also aggravated by chest closure resulting in RA pressure increase), significant right-to-left shunting should always be assessed with TEE as early as possible and also during the weaning from CPB, because a PFO can be potentially detected even before complete separation. Early detection is fundamental because the presence of a PFO requires return to CPB for closure.

## 2.2.2. *Valvular and ascending aortic defects*

### 2.2.2.1. *Aortic valve opening and function*

Because of the increased aortic-LV pressure gradient the aortic valve (native or prosthetic) usually remain closed throughout the whole cardiac cycle during full LVAD assistance. This is typical for pulsatile VADs generating full CO. Conversely, in VADs providing partial or intermittent unloading (e.g., Jarvik 2000, HeartMate II) [18] a transient opening of the aortic valve might be detected. In such devices the intermittent opening of the aortic valve is a target for device setting (e.g., opening of the aortic valve documented echocardiographically once every three cardiac cycles for a HeartMate II and reduction of pump output in the Jarvik 2000 to allow for ventricular ejection through the aortic valve) [5]. In these cases M-mode imaging is used to assess the duration of aortic valve opening [5]. In some particular devices, such as the Impella (that is placed in trans-aortic position) TEE examination is fundamental for its correct positioning.

The identification of aortic regurgitation (AR) (either pre- or postoperative) is essential in patients implanted with a LVAD. Indeed, AR may reduce the forward stroke volume generated by the LVAD as a consequence of a blood back-flow (LVAD ejected blood) into the LV. However, some aspects make the pre-operative echocardiographic evaluation of AR challenging in patients suffering severe heart failure because the combination of increased LV end-diastolic pressure and low aortic diastolic pressure (lowered transvalvular gradient) may underestimate the degree of AR [19]. The actual rate of late AR (not pre-existent to LVAD implantation) is relatively low and some recognized factors may contribute to its development during LVAD support, such as the presence of a closed native valve exposed to systolic pressure (rather than diastolic) [20], and VAD cannula in the ascending aorta determining valve distortion.

Other mechanisms of late AR include endocarditis [21], aortic dissection [22,23], and aortic leaflet prolapse or perforation.



Nevertheless the presence of severe or moderate AR usually mandate the surgical correction [24] consisting alternatively in simple leaflets closure (patients requiring long-term support, bridge to transplantation) which may prevent from systemic embolization also [19,25] or aortic valve replacement/repair (patients candidate to short-term support, bridge to recovery).

Differently from AR, aortic stenosis (AS) does not determine particular problems in patients receiving a LVAD because the systemic blood flow is mainly dependent from the pump output respect to residual ventricular ejection. This is particular true for pulsatile LVADs that are able to provide a full cardiac unloading. However in the case of VADs providing a partial or intermittent ventricular unloading (axial flow devices, with intermittent aortic valve opening) the presence of AS could conversely affect the total systemic blood flow. For this reason patient with pre-existent AS are not considered as the ideal candidates for such kind of devices. As for AR the development of aortic stenosis after LVAD implantation, particularly in long term support with pulsatile devices can result from commissural fusion [26], progressive thrombosis of the aortic valve [27] (due to blood stagnation, low level of anticoagulation, limited/absent aortic valve movement during LVAD function).

#### 2.2.2.2. *Ascending aorta*

Pre and intraoperative examination of the ascending aorta is mandatory in patients receiving a LVAD since it must detect calcifications, atherosclerotic plaques or any other abnormality of the vessel in the site of anastomosis of the outflow cannula. Depending from VAD's outflow cannula placement site the descending aorta should be assessed with the same goal (e.g., Jarvik 2000). Atherosclerotic plaques of  $\geq 5$  mm and/or protruding and/or mobile components are associated with increased risk of cerebral embolic events.

#### 2.2.2.3. *Tricuspid regurgitation*

Tricuspid Regurgitation (TR) is common in patients affected by heart failure [28]. However the presence of an adequate RV function (to maintain an adequate blood flow to the left heart for LVAD filling) is the key of success in patients receiving a LVAD. In this scenario a significant postoperative TR can negatively affect the RV function with possible development of a low output syndrome.

Echocardiographic evaluation of the tricuspid valve (TV) is affected by RV contractility, preload and afterload of RA, preload and afterload of RV.

Ventricular enlargement, due to preload and afterload increase, contributes to the development of tricuspid regurgitation (annulus dilation and chordal tension) [20,29]. The reduction of right ventricle preload (pulmonary artery pressure) in patient on LVAD actually does not determine a reduction of post-operative TR which can, conversely and most frequently, worsen after implantation.

Different factors and mechanisms are responsible for acute worsening of TR, such as increased RV preload due to an increased left-sided output delivered by a functioning, increased PA pressure and RV dysfunction due to the inflammatory response to surgery, CPB and blood

transfusion, and leftward shift of the interventricular septum produced by the LVAD unloading and favoured by hypovolemia and high VAD flows.

The influence of LVAD settings on the degree of TR by shifting the interventricular septum can be frequently observed in axial flow devices where excessively high flow settings exacerbate TR, presumably by mechanisms such as distraction of the septal papillary muscle with systolic restriction of septal leaflet motion and distortion of the tricuspid annulus. Relative RV overload and increased PA pressures can further contribute to worsened TR.

Echocardiography must guide the diagnosis of TR and determine the functional cause and mechanism which, once identified, should be minimized by adjusting the pump setting (flow reduction flow) in order to reduce the degree of regurgitation and consequently improve RV function.

#### *2.2.2.4. Mitral regurgitation / stenosis*

Mitral Regurgitation (MR) in end-stage heart failure and cardiomyopathy is common [28,30] and it mostly consists in a functional pathology due to an incomplete leaflet coaptation secondary to a negative remodeling of both the LV (increased sphericity and dilation, apical displacement of the papillary muscles with typical valve tethering) and mitral annulus (increased intertrigonal and anterior-posterior annular size).

The reduction of LV size after LVAD implantation, differently from TR, almost always contributes to ameliorate mitral leaflets coaptation and, thus, to reduce the degree of pre-existent regurgitation. For this reason, the finding of MR pre-VAD rarely indicates surgical correction.

Conversely, the persistence of significant MR may indicate suboptimal ventricular unloading during LVAD support. During VAD support with pulsatile devices MR can, however, contribute to patient's symptoms and, in some instances, indicate the surgical correction. Actually the asynchronous pulsation of the VAD and the assisted ventricle can determine/worsen mitral regurgitation when LV contraction occurs against both the closed aortic and the inflow VAD valve.

A low output syndrome during LVAD assistance can result from the presence of mitral stenosis (MS) resulting in reduced pump filling. Moreover chronic MS associated with pulmonary hypertension can contribute to postoperative RV dysfunction. Thus, the presence of MS should be always evaluated in the planning of LVAD insertion and critical MS surgically treated at the same time.

#### *2.2.2.5. Pulmonic valve*

Although rare, the presence of pulmonary valve lesions may have important consequences on the RV function and output. Critical pulmonic stenosis (PS) in patients under LVADs can determine an important pressure overload in the RV, compromising the RV output both directly and indirectly by contributing to RV failure. With regard to pulmonic insufficiency (PI) apply the same considerations given for aortic regurgitation in the case of RVAD (reduced



forward flow) while in patients under LVAD the presence of PI (moderate or greater) may contribute to RV overload/dilatation and possible TR determining a dysfunction of the RV.

### 2.3. Ventricular assessment

#### 2.3.1. *Right ventricle*

LVAD assistance can result in two possible and opposite effects on the RV function. The afterload reduction caused by the left-sided pump may positively increase the function of the right ventricle. Opposite, the contemporary augmented left output resulting in increased preload for the right heart sections can be detrimental in the presence of a compromised RV function which can rapidly decompensate [31]. The leftward septal shifts also favour RV dysfunction by reducing RV global contractility [32,33]. Nevertheless, because the LVAD output is strictly dependent on preload, a sufficient RV function must be warranted to avoid a low output syndrome due to LVAD low flow.

As a result, the evaluation of pre-implant RV function and early post-operative detection of severe RV dysfunction (ranging from 9% to 33 in different series) play a key role for the success of LVAD assistance and patient's outcome because in the presence of severe RV failure placement of RVAD may be required and the earlier the detection and the RVAD insertion the better the outcome [34].

Despite a strong association between preoperative impaired RV function (low PA pressure, RV stroke work index) and need for RVAD placement has been demonstrated [35,36] RV failure following LVAD implantation in single patients still remains hard to be predicted because of the multiple factors potentially contributing to its development [35]. A thorough pre-operative evaluation of RV function and identification of any predictors for RV dysfunction is fundamental to select the patient's optimal device and to schedule each one for uni- or bi-ventricular support [35].

Echocardiography is a fundamental diagnostic tool to this purpose. Two-dimensional evaluation of the RV function and dimensions is made by analysing RV inflow–outflow in mid-esophageal (ME) view and the four-chamber views at transgastric level. This allows the assessment of both the longitudinal function (RV base-apex motion and free-wall motion) [37]. Quantitative measurements (global RV fractional area change [14,38], regional fractional area change [33], and the maximum derivative of the RV pressure ( $dP/dt$  max)) can be also used to detail the systolic function of the RV [39,40]. Analysis of tricuspid valve inflow profile is used for the assessment of diastolic dysfunction. Possible predictors of RV dysfunction after LVAD implantation are preoperative RV dilatation and increased preload and afterload, and RV fractional area change  $< 20\%$ .

#### 2.3.2. *Left ventricle*

Patients candidate to VAD insertion show a depressed LV function with a LV ejection fraction (LVEF) usually  $< 25\%$ . The presence of severe LV dysfunction, particularly if associated with aneurismal apical dilatation increases the risk of apical clot formation. Pre-insertion evaluation

of the presence of thrombus in the site of inflow cannula/pump (Jarvik 2000) insertion is a crucial and mandatory issue of the echocardiographic examination.

Depending by the leading cause of heart failure, the ventricle dimensions and volumes can be normal or, more often, augmented.

Once on LVAD assistance, the ventricular unloading usually associates with a normalization of ventricular dimensions and volumes and complete unloading associates with no residual ventricular ejection and persistent closure of the aortic valve.

Echocardiographic “signs” of LVAD malfunction to be considered are spontaneous contrast in the LA or LV. Another important feature to be evaluated is the aspect of the interventricular septum (IVS) because a not adequately unloaded ventricle will show a rightward IVS deviation suggesting a possible insufficient pump output (due to pump failure, cannulas obstruction, or other causes).

Leftward IVS shift usually seen with rotary LVAD will, conversely, suggest an excessive ventricular decompression, which may associate to low pump output as well. Such event can be due to elevated pump speed, in an axial VAD, RV dysfunction or hypovolemia.

It is important to outline that because of ventricular unloading, the correct evaluation of systolic function is critical and not easy to be ascertained while on VAD assistance. Several echocardiographic indexes as well as hemodynamic measurements are used in clinical practice when patients are scheduled for possible weaning from VAD assistance (see text).

More recently the speckle tracking echocardiography has emerged as a new technique for the evaluation of myocardial function. This sophisticated method allows the analysis of longitudinal, radial and circumferential myocardial deformation (strain) providing a in-depth evaluation of both global and regional myocardial contractility. Moreover, speckle tracking echocardiography allows the evaluation of rotational and torsional dynamics of left ventricle function that only with magnetic resonance imaging (MRI) could be otherwise assessed.

## **2.4. Assessment of VAD components**

### **2.4.1. VAD cannulas**

VAD cannulas are made of woven polyester fabric having hyperechoic density in the echocardiographic imaging. Depending on single device characteristics, alternative cannulation methods are used leading to distinct echocardiographic images and considerations.

#### **2.4.1.1. Inflow cannula (Jarvik 2000-pump)**

The inflow cannulas correct positioning can be easily visualized on two-dimensional echocardiography although the precise three-dimensional visualization needs to alternative views (ME four-chamber for deviations towards the interventricular septum, ME two-chamber long-axis view to assess the anterior–posterior direction). In LVAD they can be placed either in LA or LV apex. When positioned in the apex it is important to verify that it is correctly aligned with the left ventricle inflow tract, facing the mitral valve opening without touching any wall

of the ventricle. Colour-Doppler is a useful adjunct, since an accurately positioned cannula will show a unidirectional/laminar flow directed to the device, while the finding of turbulent flow will suggest a not appropriate placement or obstruction of the cannula (thrombosis or partial obstruction of the cannula by the ventricular wall). Device stroke volume and total blood flow can be evaluated by PW Doppler measurements obtained from both the inflow and outflow cannulas. By evaluating the RV and LV outflow tracts, flows PW Doppler can give also an estimation of eventual residual ventricular ejection in VADs providing only partial circulatory support.

#### 2.4.1.2. Outflow cannula

In the most of the cases the outflow cannula of LVADs is anastomosed, as an end-to-side anastomosis, in the right anterolateral portion of the ascending aorta. Other type of devices, (e.g., Jarvik 2000), may have the outflow cannula anastomosed either to the ascending aorta or to the descending thoracic aorta. A long axis view of the ascending aorta will usually show the outflow cannula anastomosis to the ascending aorta. In the case of RVAD the outflow cannula is usually positioned in the main pulmonary artery trunk (directly, or inserted through an incision in the RV apex) although the right PA the can be alternatively used. It can be easily visualized by two-dimensional echocardiography with a mid-esophageal 20–70° view. The flow patterns of the outflow cannulas can be evaluated with color-PW and CW-Doppler.

#### 2.4.1.3. Devices with alternative principles and implantation techniques (Jarvik 2000)

Because new devices with alternative principles and cannulation methods have been introduced in the clinical practice particular echocardiographic evaluations and considerations are required.

Axial flow pumps offers a number of advantages respect to pulsatile pumps. They are relatively easy to be implanted (also without the use of CPB), they are smaller (producing a continuous unidirectional blood flow no valve are needed and do not require a compliance chamber for systolic-diastolic phases) and suitable for a wide size-range of patients and have lower rates of complications.

The Jarvik 2000 is an axial flow-based device implanted in the apex of the LV. Because it has no inflow cannula but the pump itself is positioned inside the left ventricle the TEE examination is important during and after implantation of this type of device.

It is mandatory that the sonographer is able to guide the precise coring position centred at the apex and, once implanted inside the ventricle, verify that the pump is perfect in axial alignment with the mitral valve.

Because no integrated flow sensors are available, echocardiographic evaluation is critical to assess the device performance and the global hemodynamic. Thus, after Jarvik200 implantation the degree of ventricular assistance/unloading (to achieve a full or partial assistance) must be evaluated by first establishing the speed range at which the aortic valve does not open (complete unloading). Then by progressively reducing the pump rotations per minute (usually 1000 rpm steps) it must be assessed the speed at which the aortic valve opens.

Because outflow cannula of Jarvik 2000 is conventionally anastomosed (trans-pericardial) to the descending aorta flow patterns proximal and distal to the anastomotic site are quite different respect to VADs whose outflow cannula is placed in the ascending aorta. Particularly, at high device flows, which determine a complete unloading with permanent closure of the aortic valve, stagnation of blood in the ascending aorta and sinuses of Valsalva might occur with possible thrombosis and obstruction of the coronary ostia with detrimental consequences.

This risk must be reduced or eliminated with the intermittent reduction of the device output to allow ventricular ejection and phasic aortic valve opening which must be echocardiographically assessed, since the degree of the outflow graft pulsatility alone do not predict the presence of systolic aortic valve opening [41].

#### 2.4.1.4. Deairing

Intraoperative echocardiography is very useful for detection of micro- or macro-bubbles and result fundamental to direct de-airing of the heart after VAD implantation.

VADs components can contain significant amounts of air and, in adjunct, pulsatile devices using negative filling pressures may drag air from the thoracic cavity into the circulation especially at the inflow cannula insertion site resulting in the passage of air bubbles to the heart and systemic circulation. The most common locations to which air will migrate, once CPB is interrupted and pulmonary perfusion re-established, are the right coronary artery and the innominate artery possibly contributing to ventricular dysfunction and/or neurologic injury.

Careful deairing should be performed before aortic cross clamp removal and before the pump is set fully operational. Structures to be inspected include heart chambers and both ascending and descending aorta using different TEE views (ME aortic valve long-axis view, ME ascending aorta long-axis view and descending aorta short- and long-axis view).

## 2.5. Recovery and weaning

Identification of the ideal candidates for successful LVAD or RVAD weaning is still an open topic and object of current study. The decision about possibility of successful weaning depends on integration of clinical, hemodynamic and echocardiographic factors [42,43] as documented by several studies reporting recovery and weaning protocols based on cardiopulmonary testing, hemodynamic and echocardiographic variables [44].

The largest reports of weaning and removal from chronic LVAD support suggest as parameters indicative of myocardial recovery a left ventricular ejection fraction  $\geq 40\%$  and a left ventricular end diastolic diameter (LVEDD) inferior to 55-60mm [45]. Other echocardiographic variables indicative of left myocardial recovery may be considered the fractional area change  $> 40\%$ , and the improved ventricular contractility.

Serial echocardiographic examination of the aortic valve opening movements, LVEF and diameters at every reduction step of support is essential to evaluate a possible weaning, because they will reflect the LV response to the progressive increase of preload and, thus, its actual recovery.

Invasive hemodynamic monitoring during dobutamine stress echocardiography has been also proposed as a clinical test to assess the response of the assisted ventricle to unloading and consider a possible weaning from assistance [46]. The improvement of cardiac index, LVEF in absence of increased LVEDD and pulmonary capillary wedge pressure  $\leq 15$  mm are considered favourable for successful device explantation.

The most important parameters to be evaluated and considered for weaning from RVAD assistance are the right ventricular function, the central venous pressure, the degree tricuspid regurgitation and the resulting left ventricular filling.

However, the evaluation and management of pulmonary vascular resistances (PVR) is the most crucial issue when trying to wean patients from RVAD assistance. Because the success of the procedure is actually strictly dependent by PVR optimization[47] when fixed PVR are present patients will need supplementary management before attempting the weaning. Echocardiographic and hemodynamic monitoring demonstrating left and right heart sections maintaining a good function while decreasing the pump assistance without elevation of the central venous pressure, and PVR indicate the possibility to successfully wean the patient from the RVAD support.

Echocardiography evaluation of PVR can be performed by using the following formula :

$$PVR = (V_{\max} TR / VTI_{RVOT}) + 0.16.$$
 (PVR are expressed in Wood units;  $V_{\max} TR$  = maximal tricuspid regurgitation velocity;  $VTI_{RVOT}$  = systolic velocity time integral of the RV outflow tract).

## 2.6. Echocardiography for systemic blood flow assessment

Echocardiography allows measurement of CO using standard two-dimensional imaging or, more commonly, Doppler-based methods.

Doppler-based methods apply the following principle: if an ultrasound beam is directed along the aorta using a probe, part of the ultrasound signal will be reflected back by the moving red blood cells at a different frequency. The resultant Doppler shift in the frequency can be used to calculate the flow velocity and volume and hence CO. In patients on MCS, LVAD- and RVAD-CO can be separately assessed with a simple procedure [48].

Left and right ventricular outflow tract velocity-time integrals (VTIs) can be obtained by pulse wave Doppler signals and used to estimate both the left and right stroke volume (SV) and cardiac output (CO). For reliable measurements care must be taken to ensure an optimal angle between the blood flow and Doppler beam. Once obtained the two (right and left) estimations of cardiac output the following formula is used to have an indirect measure of the VAD output:  $LVAD\ CO = (RVOT\ CO) - (LVOT\ CO)$ .

A direct measurement of the VAD output can be also obtained using both the cross-sectional area and pulse wave Doppler derived VTI in the outflow graft. For such calculation, as previously mentioned, is necessary that the outflow graft blood flow and the Doppler beam are maintained aligned and parallel as much as possible. Is usually advisable to use both the direct and indirect method for CO estimations and verify their correlation because possible



discrepancies can derive from incorrect probe alignment as well as overestimations of the graft's cross-sectional area, or the LVOT and RVOT diameters [41].

### *2.6.1. Echocardiography: Advantages and disadvantages*

Echo-Doppler has the key advantage of providing additional variables in addition to blood flow as previously described. The main disadvantage of Echo-Doppler evaluation is that it is operator dependent and continuous measurement of CO using this technique is not possible. Moreover, Echo-Doppler evaluation may be applied either trans-thoracically or trans-esophageally, but the former does not always yields good images. On the other hand, trans-esophageal technique is more invasive and is uncomfortable in non-intubated patients.

Echo-Doppler CO estimates require a certain expertise, so that blood flow measurements may vary considerably due to the difficulty in assessment of the velocity time integral, calculation error due to the angle of insonation, and problems with correct measurement of the cross-sectional area. Conversely, smaller trans-esophageal Doppler probes than for standard esophageal echocardiography techniques may be inserted nasally. They are operator-independent, less invasive and better tolerated. However these probes focus on blood flow into the descending thoracic aorta, thus a reliable measurement of the total CO could not be provided [49]. (See Table 1 for the main advantages and disadvantages of echocardiography).

## **3. Thermodilution methods to assess cardiac output**

The determination of cardiac output (CO) during MCS is crucial, as low-output syndrome is the main cause of death in such patients [15]. Several methods are available for blood flow estimation and CO monitoring. However, the hemodynamic changes subsequent to VAD implantation somehow limit the application of current methods for CO determination [50]. Two principal methods capable of assessing systemic blood flow are available in clinical practice: thermodilution (ThD) and transpulmonary ThD system.

### **3.1. Pulmonary thermodilution method**

The techniques based on pulmonary ThD method employ a pulmonary artery catheter (PAC) to monitor CO. The intermittent ThD technique employs a bolus of ice-cold fluid, which is injected into the right atrium via a PAC. The change in temperature detected in the blood of the pulmonary artery is used to calculate CO. This technique is still widely considered as the standard method in clinical practice and it is taken as the reference approach when comparing new CO monitoring technologies [51]. More recently, PAC has been adapted to incorporate a thermal filament (Vigilance™, Edwards Life Sciences, Irvine, CA, USA) or thermal coil (OptiQ™, ICU Medical, San

Clemente, CA, USA) that warms blood in the superior vena cava and measures changes in blood temperature at the PAC tip using a thermistor [52]. These modified techniques provide continuous monitoring of systemic blood flow (continuous ThD-CO) and the displayed values represent an average of CO values over the previous 8-10 minutes.

### **3.2. Transpulmonary thermodilution method**

The techniques based on transpulmonary thermodilution method allow CO to be assessed less invasively, using a central venous (to allow injection of the indicator) and an arterial catheter, rather than needing to introduce a catheter into the pulmonary artery. Among these systems, PiCCO (Pulsion Medical Systems, Munich, Germany), and LiDCO (LiDCO Ltd, London, UK) are the most widely used devices, which apply the same basic principles of dilution to monitor blood flow as with PAC thermodilution [53].

PiCCO uses injections of cold intravenous fluid as the indicator, measuring change in temperature downstream to estimate systemic blood flow [54]. LiDCO uses small amounts of lithium chloride as the indicator and measures levels using a lithium-selective electrode [55].

### **3.3. Pulmonary and transpulmonary thermodilution method: Advantages and disadvantages**

The PAC has a key advantage over other systems in that it provides measurements of other hemodynamic parameters in addition to systemic blood flow, including pulmonary artery pressures, right-sided and left-sided filling pressures, and mixed venous oxygen saturation (SvO<sub>2</sub>). Moreover, the PiCCO system provides variables in addition to blood flow, such as global end-diastolic volume and measurements of extravascular lung water. All the aforementioned parameters are of importance in patients on MCS in order to improve treatment of pulmonary hypertension, avoid fluid overloading, hypo-oxygenation, and high oxygen consumption [18].

Another main advantage of continuous ThD-CO is that it eliminates variability in CO estimates in the presence of arrhythmias. However, it has the disadvantage of not displaying real-time values, thus limiting its usefulness for assessing abrupt hemodynamic changes in patients with hemodynamic instability [48].

Methods based on “cold” pulmonary ThD (bolus ThD), as well as systems for continuous “hot” ThD (continuous ThD-CO) are theoretically suitable in patients assisted with a left VAD (LVAD) but are unreliable techniques for patients on RVAD due to “cold or hot” indicator loss bypassed by the pump from the right heart sections [56]. Similar limitations exist for systems based on transpulmonary ThD, which cannot be applied to any patient on MCS [RVAD, LVAD or biventricular assist devices (BiVAD)] unless modified set-up are used for application during isolated RVAD, as indicator loss would happen in both the right and left heart sections [50]. However, the ThD techniques measure the right heart CO, which is conditioned by the systemic venous return and by “total” left CO. Thus, they could actually provide the true

systemic blood flow in patients on LVAD [56]. (See Table 1 for the main advantages and disadvantages of thermodilution methods).

| Assessment of:                              | Echocardiography | Thermodilution (PAC) | Pulse Contour Methods |
|---|------------------|----------------------|-----------------------|
| - Left ventricular function                 | +                | -                    | +                     |
| - Right ventricular function                | +                | +                    | -                     |
| - Anatomical features                       | +                | -                    | -                     |
| - Cardiac output                            | +                | +                    | +                     |
| - Systemic arterial pressure                | -                | -                    | +                     |
| - Pulmonary arterial pressure               | +                | +                    | -                     |
| - Systemic vascular resistances             | -                | +                    | +                     |
| - Pulmonary vascular resistances            | +                | +                    | -                     |
| - Preload                                   | +                | +                    | +/-                   |
| - Blood flow generated by VAD               | +                | -                    | +/-                   |
| - Cardiac valve function                    | +                | -                    | -                     |
| - VAD components                            | +                | -                    | -                     |
| - Mixed venous oxygen saturation            | -                | +                    | -                     |
| - Extravascular lung water                  | -                | -                    | +/-                   |
| General requirements of an "ideal" tool     |                  |                      |                       |
| - Accuracy                                  | +                | +                    | +/-                   |
| - Reproducibility                           | +                | +                    | +                     |
| - Fast response time                        | -                | -                    | +                     |
| - Operator independency                     | -                | -                    | +                     |
| - Easy to use                               | -                | +                    | +                     |
| - Continuous use                            | -                | +/-                  | +                     |
| - Cost effectiveness                        | -                | +                    | +/-                   |
| - Minimally invasive                        | +                | -                    | +/-                   |
| - Clear data display and interpretation     | +                | +                    | +                     |
| - Neonates to adults                        | +                | -                    | +/-                   |
| - Information that is able to guide therapy | +                | +                    | +                     |

+ satisfactory; - not satisfactory; +/- only some tools. PAC, pulmonary artery catheter. VAD, ventricular assist device.

**Table 1.** Main desirable characteristics of a monitoring tool to be used in patients on mechanical circulatory assistance (see text for details).

#### 4. Pulse contour methods to estimate systemic blood flow

The analysis of the arterial trace is the key point of the so called "pulse contour methods" (PCMs). These techniques are based on the main assumption that the pressure rise during

systole is related to the systolic filling of the aorta and proximal large arteries [57]. Thus, stroke volume, and hence CO, can be derived by means of the analysis of the shape of the arterial trace and the area under the pressure curve [58]. These are low-invasive techniques and allow beat-by-beat CO determinations. Indeed, these systems provide a fast response time and may represent suitable tools in patients on MCS, in whom sudden hemodynamic changes may lead to hypotension and low output syndrome.

There are presently four major PCMs that are able to calculate CO and other cardiovascular parameters from the analysis of the arterial pressure waveform: 1) PiCCO Monitor (Pulsion Medical Systems, Munich, Germany), 2) LiDCO System (LiDCO Ltd, London, UK), 3) Vigileo Monitor (Edwards Lifesciences LLC, Irvine, CA), and 4) MostCare Monitor (Vygon Health, Padua, Italy) [54].

The PiCCO needs transpulmonary thermodilution for its calibration (i.e., iced bolus in a central venous line) and a catheter into the femoral artery for the analysis of the arterial trace [59]. The LiDCO system measures systemic blood flow after an external calibration with an intravenous (centrally or peripherally) bolus of lithium [60]. The Vigileo system does not need external calibration with a bolus but it requires internal calibration (i.e., patient demographic and physical characteristics) for arterial impedance estimation [61]. The MostCare monitor has the innovative feature of not necessitating external or internal calibration, being based on PRAM (Pressure Recording Analytical Method) algorithm. Indeed, PRAM analyses the shape of the arterial trace taking into account all the points of the pressure wave. Simultaneously, it relates these points to the systolic and diastolic area under the pressure wave to estimate the interaction of left ventricle contraction with aortic impedance and compliance changes [62].

#### **4.1. Pulse contour methods: Some practical considerations**

Methods based on external calibration (i.e., bolus injected into a central or peripheral line) are unreliable techniques for patients on RVAD due to indicator loss bypassed by the VAD from the right heart sections [48]. Actually, these PCMs cannot be applied to any patient on MCS (RVAD, LVAD or biventricular assist devices (BiVAD)) as their external calibration is affected by indicator loss in both the right and left heart sections [63].

In order to avoid these limitations, PiCCO has been used in a patient on RVAD (Levitronix-CentriMag, Levitronix GmbH, Zurich, Switzerland) with a modified set-up for calibrating the system. Basically, the investigators positioned a left atrial catheter to inject the iced solution, instead of using a central venous catheter for the iced bolus [64]. However, this modified set-up cannot be used in clinical practise because it is very invasive and highly risky.

A modified set-up of lithium bolus dilution was used for the calibration of LiDCO in patients supported by a centrifugal pump (LevitronixCentriMag, Levitronix GmbH, Zurich, Switzerland) in the RVAD configuration (between the right atrium and pulmonary artery). Indeed, just before lithium bolus administration to the central venous catheter, the investigators increased the RVAD's revolutions per minute (RPM) as much as possible to ensure that all the blood flowed through the RVAD and to avoid RVAD suction events. The increase in RPM

before calibration caused streamlined blood flow from the right atrium to the RVAD, excluding blood leakage through the native right ventricle [65].

MostCare has been recently used in 12 patients implanted with a pulsatile left ventricular assist device (LVAD) (HeartMate-I XVE, HM-I, Thoratec Corporation, Pleasanton, CA, USA) [48] and in one patient undergoing left (Jarvik 2000 axial flow pump, Jarvik Heart, Inc., New York, NY) and right (Levitronix CentriMag, Levitronix GmbH, Zurich, Switzerland) ventricular assist device implant [66]. Good performance with MostCare in such patients was found. Moreover, there was no need for changing the set-up of the device, as it is the only PCM that does not need external/internal calibration [66].

#### **4.2. Pulse contour methods: Advantages, limitations and drawbacks in pulsatile and non-pulsatile VAD**

Incomplete LV unloading during mechanical circulatory support can occur as the result of inadvertent and transient changes in afterload and preload (e.g. heart–lung interactions in patients who are mechanically ventilated). As a consequence, the native heart can unpredictably open the aortic valve and eject a variable amount of blood into the ascending aorta [48]. Moreover, when a pulsatile LVAD is set to operate in fixed-rate mode, independently of patient's heart rate, such a discrepancy can itself determine the occurrence of residual effective LV contractions and stroke outputs that can contribute to “total” CO (blood flow generated by the LVAD plus stroke volumes produced by the native heart). Thus, depending on the patient's heart rate and the device's stroke rate, arterial blood pressure waves related to ventricular ejection may coincide with LVAD arterial pulse waves (being unapparent) or may be variably interposed between the LVAD arterial pulse waves (Figure 1) [63].

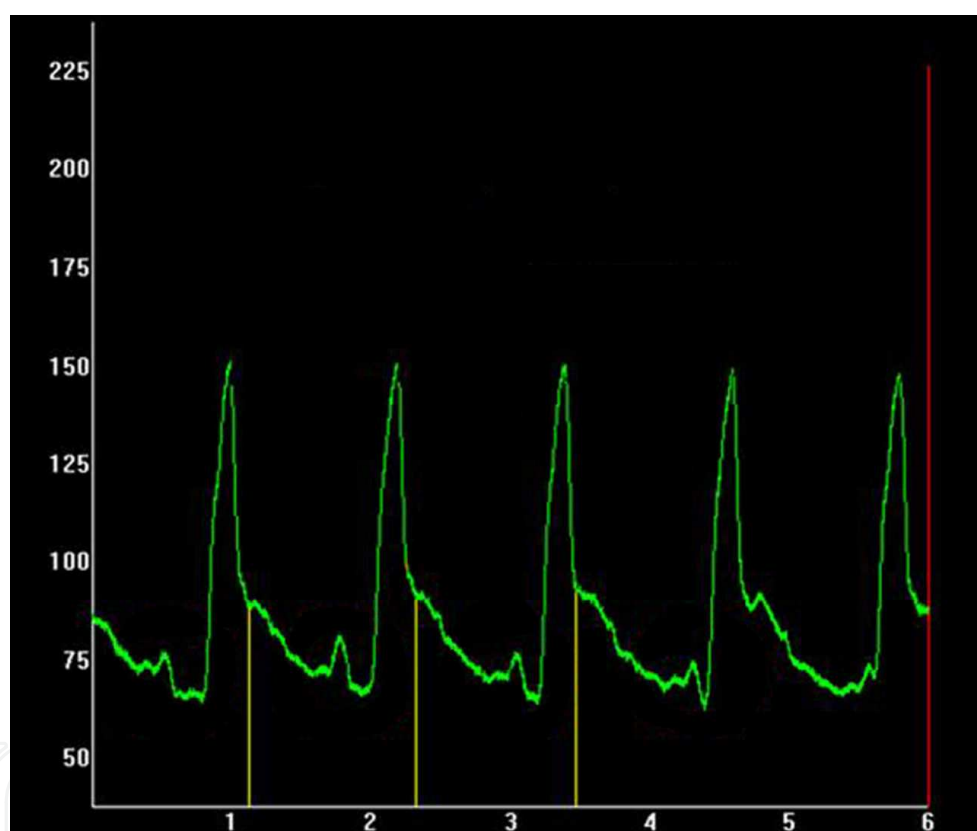
A main advantage of PCMs is that they compute systemic blood flow from the analysis of a peripheral artery. Therefore, their blood flow estimation could represent the true systemic perfusion (i.e., the sum of the contributions from the native left ventricle ejecting through the aortic valve, and the pump ejecting directly into the aorta) [63].

A major limitation of PCMs resides in the fact that an arterial pulsatile pressure wave (i.e., pulse pressure) must be present for CO estimation. Thus, some issues about their reliability exist for non-pulsatile VADs, where incomplete LV unloading must occur to generate a pulse pressure sufficient to allow PCMs to compute CO. Conversely, with pulsatile VADs an arterial pulsatility can be anyhow detected, independently of ventricular loading or unloading conditions. In such conditions, uncalibrated PCMs should be able to analyse the arterial pressure wave morphology in any condition of LV preload [16].

With respect to pulsatile pump flow, rotary continuous-flow VADs produce less pulsatile and non-physiologic flows, and their hemodynamic characteristics are different from pulsatile VADs. First, at a given speed rotation, the flow through a rotary device is variable, generally unquantifiable and it is sensitive to the pressure gradient across it (aortic minus left ventricular pressure). Secondly, if the pump speed is too fast, the



arterial pressure waveform decreases and the dicrotic notch is absent (indicating a closed aortic valve). Finally, with a rotary VAD, the fluctuations in left ventricular pressure are transmitted to the systemic arteries through the device even when the pump speed is sufficiently high to maintain the closure of the aortic valve. This may have important clinical consequences (e.g. aortic valve cusp fusion and thrombosis in the ascending aorta) [67]. PCMs could be useful under these circumstances, as PCMs analyse pulsatile flows and cannot work without a minimum pulse pressure. Indeed, a “no-value” alarm on the screen could serve as a “wake-up call” for an in-depth hemodynamic evaluation. This is particularly true for MostCare, which displays the dicrotic notch (and hence the aortic valve closure) at each cardiac cycle [68].



**Figure 1.** The figure 1 shows the arterial wave recording of a patient under pulsatile left ventricular assist device (LVAD) by the pulse contour method MostCare-PRAM (Pressure Recording Analytical Method). Values on y-axis are arterial pressures (mmHg). On x-axis are the cardiac cycles over time. The yellow vertical lines represent the identification of the dicrotic notch at each cardiac cycle. The arterial pressure waves are generated by LVAD stroke outputs. Of note, some smaller pressure waves are interposed between them. These smaller arterial traces represent residual left ventricular ejections of blood from the native heart. MostCare calculates the actual systemic total blood flow from the analysis of the sum of both the waves (i.e., stroke volumes produced by the artificial plus the native ventricle) (see text for details).

A major advantage of PCMs is that they can provide information on fluid responsiveness and cardiac function. In particular, MostCare is able to measure  $dP/dt$  (an index of myocardial contractility) and cardiac cycle efficiency (CCE, an index of ventricular-arterial coupling). Both

these indices may have importance in the assessment of cardiovascular performance during the weaning from a VAD.

However, several factors could affect the accuracy of blood flow measurements and hemodynamic evaluation based on the analysis of the arterial waveform, such as arterial pathology in the proximal segments, vasoplegic patients on vasoconstrictor therapy. Indeed, all these conditions may affect the transmission of the pressure wave. Moreover, damped arterial waveforms and inadequate pulse detection (e.g., catheter dislodgement) may influence the precision of the pressure wave analysis [54,57,69,70]. (See Table 1 for the main advantages and disadvantages of pulse contour methods).

## 5. Conclusions

The development of mechanical circulatory support technology is now moving from displacement pumps (pulsatile flow) to axial and centrifugal pumps (continuous flow). Hemodynamic evaluation and measurement of blood flow is of crucial importance in patients on mechanical circulatory support.

Echocardiography has emerged as an important tool to assess hemodynamic performance in patients assisted with a ventricular assist device. However, it is operator dependent and cannot be used as a continuous bedside monitoring device. On the other hand, other hemodynamic monitoring techniques provide information on cardiac function and systemic blood flow on a beat-by-beat basis. Unfortunately, many of them they have the limitation of not being applicable in some circumstances.

An ideal hemodynamic monitoring system should comprise all the key factors listed in Table 1. However, such a system does not currently exist so we must try and choose devices that have a maximum of these attributes, bearing in mind that there is no “one size fits all” type of system and one should, therefore, select the system most appropriate for each patient and for each type of problem [54]. This is particularly true for patients supported with mechanical circulatory support, in whom abrupt hemodynamic changes may lead to severe arterial hypotension and clinical instability, which, in turn, are responsible for low output syndrome and poor outcome.

## Author details

Sabino Scolletta\*, Bonizella Biagioli, Federico Franchi and Luigi Muzzi

\*Address all correspondence to: [sabino.scolletta@unisi.it](mailto:sabino.scolletta@unisi.it)

Department of Medical Biotechnologies, Unit of Cardiac Surgery, Anesthesia and Intensive Care, S. Maria alle Scotte University Hospital, Siena, Italy

## References

- [1] Hetzer R, Muller JH, Weng YG, Loebe M, Wallukat G. Midterm follow-up of patients who underwent removal of a left ventricular assist device after cardiac recovery from end-stage dilated cardiomyopathy. *J ThoracCardiovascSurg* 2000;120:843–53.
- [2] Leprince P, Combes A, Bonnet N, Ouattara A, Luyt CE, Theodore P, Leger P, Pavie A. Circulatory support for fulminant myocarditis: consideration for implantation, weaning and explantation. *Eur J CardiothoracSurg* 2003;24:399–403.
- [3] Goldstein D, Oz M, Rose E. Implantable left ventricular assist devices. *N Engl J Med* 1998; 339:1522-1533.
- [4] Kirklin JK, Holman WL. Mechanical circulatory support therapy as a bridge to transplant or recovery (new advances). *CurrOpinCardiol* 2006;21:120–6.
- [5] Mitter N, Sheinberg R. Update on ventricular assist devices. *CurrOpinAnaesthesiol* 2010;23(1):57-66.
- [6] Maybaum S, Williams M, Barbone A, Levin H, Oz M, Mancini D. Assessment of synchrony relationships between the native left ventricle and the HeartMate left ventricular assist device. *J Heart Lung Transplant* 2002;21:509–15.
- [7] Joffe IL, Jacobs LE, Lampert C, Owen AA, Ioli AW, Kotler MN. Role of echocardiography in perioperative management of patients undergoing open heart surgery. *Am Heart J* 1996;131:162–76.
- [8] Park SJ, Tector A, Piccioni W, Raines E, Gelijns A, Moskowitz A, Rose E, Holman W, Furukawa S, Frazier OH, Dembitsky W. Left ventricular assist devices as destination therapy: a new look at survival. *J ThoracCardiovascSurg* 2005;129:9–17.
- [9] Mihaylov D, Verkerke GJ, Rakhorst G. Mechanical circulatory support systems - a review. *Technol Health Care* 2000;8:251–66.
- [10] Gemmato CJ, Forrester MD, Myers TJ, Frazier OH, Cooley DA. Thirty-five years of mechanical circulatory support at the Texas Heart Institute: an updated overview. *Tex Heart Inst J* 2005;32:168–77.
- [11] Song X, Throckmorton AL, Untaroiu A, Patel S, Allaire PE, Wood HG, Olsen DB. Axial flow blood pumps. *ASAIO J* 2003;49:355–64.
- [12] Noon GP, Lafuente JA, Irwin S. Acute and temporary ventricular support with Bio-Medicus centrifugal pump. *Ann ThoracSurg* 1999;68:650–4.
- [13] Vranckx P, Foley DP, de Feijter PJ, Vos J, Smits P, Serruys PW. Clinical introduction of the Tandemheart, a percutaneous left ventricular assist device, for circulatory support during high-risk percutaneous coronary intervention. *Int J CardiovascIntervent* 2003;5:35–9.

- [14] Scalia GM, McCarthy PM, Savage RM, Smedira NG, Thomas JD. Clinical utility of echocardiography in the management of implantable ventricular assist devices. *J Am SocEchocardiogr* 2000;13:754–63.
- [15] Myers TJ, Robertson K, Pool T, Shah N, Gregoric I, Frazier OH. Continuous flow pumps and total artificial hearts: management issues. *Ann ThoracSurg* 2003;75: S79-85.
- [16] Myers TJ, Bolmers M, Gregoric ID, Kar B, Frazier OH. Assessment of arterial blood pressure during support with an axial flow left ventricular assist device. *J Heart Lung Transplant* 2009 May;28(5):423-7.
- [17] Vitarelli A, Gheorghiade M. Transthoracic and transesophageal echocardiography in the hemodynamic assessment of patients with congestive heart failure. *Am J Cardiol* 2000; 86:36–40.
- [18] Nussmeier NA, Probert CB, Hirsch D, Cooper JR Jr, Gregoric ID, Myers TJ, Frazier OH. Anesthetic management for implantation of the Jarvik 2000 left ventricular assist system. *AnesthAnalg* 2003;97:964–71.
- [19] Rao V, Slater JP, Edwards NM, Naka Y, Oz MC. Surgical management of valvular disease in patients requiring left ventricular assist device support. *Ann ThoracSurg* 2001;71:1448–53.
- [20] Holman WL, Bourge RC, Fan P, Kirklin JK, Pacifico AD, Nanda NC. Influence of left ventricular assist on valvular regurgitation. *Circulation* 1993;88:309–18.
- [21] Gruber EM, Seitelberger R, Mares P, Hiesmayr MJ. Ventricular thrombus and subarachnoid bleeding during support with ventricular assist devices. *Ann ThoracSurg* 1999;67:1778–80.
- [22] Lacroix V, d’Udekem Y, Jacquet L, Noirhomme P. Resection of the ascending aorta and aortic valve patch closure for type A aortic dissection after Novacor LVAD insertion. *Eur J CardiothoracSurg* 2003;24:309–11.
- [23] Momeni M, Van Caenegem O, Van DyckMJ. Aortic regurgitation after left ventricular assist device placement. *J CardiothoracVascAnesth* 2005;19:409–10.
- [24] Bryant AS, Holman WL, Nanda NC, Vengala S, Blood MS, Pamboukian SV, Kirklin JK. Native aortic valve insufficiency in patients with left ventricular assist devices. *Ann ThoracSurg* 2006;81:E6–8.
- [25] Pelletier MP, Chang CP, Vagelos R, Robbins RC. Alternative approach for use of a left ventricular assist device with a thrombosed prosthetic valve. *J Heart Lung Transplant* 2002;21:402–4.
- [26] Connelly JH, Abrams J, Klima T, Vaughn WK, Frazier OH. Acquired commissural fusion of aortic valves in patients with left ventricular assist devices. *J Heart Lung Transplant* 2003;22:1291–5.

- [27] Rose AG, Connelly JH, Park SJ, Frazier OH, Miller LW, Ormaza S. Total left ventricular outflow tract obstruction due to left ventricular assist device-induced sub-aortic thrombosis in 2 patients with aortic valve bioprosthesis. *J Heart Lung Transplant* 2003;22:594–9.
- [28] Koelling TM, Aaronson KD, Cody RJ, Bach DS, Armstrong WF. Prognostic significance of mitral regurgitation and tricuspid regurgitation in patients with left ventricular systolic dysfunction. *Am Heart J* 2002;144:524–9.
- [29] Gibson TC, Foale RA, Guyer DE, Weyman AE. Clinical significance of incomplete tricuspid valve closure seen on two-dimensional echocardiography. *J Am CollCardiol* 1984;4:1052–7.
- [30] Bursi F, Enriquez-Sarano M, Nkomo VT, Jacobsen SJ, Weston SA, Meverden RA, Roger VL. Heart failure and death after myocardial infarction in the community: the emerging role of mitral regurgitation. *Circulation* 2005;111:295–301.
- [31] Schmid C, Radovancevic B. When should we consider right ventricular support? *J ThoracCardiovascSurg* 2002;50:204–7.
- [32] Santamore WP, Gray LA Jr. Left ventricular contributions to right ventricular systolic function during LVAD support. *Ann ThoracSurg* 1996;61:350–6.
- [33] Kawai A, Kormos RL, Mandarino WA, Morita S, Deneault LG, Gasior TA, Armitage JM, Griffith BP. Differential regional function of the right ventricle during the use of a left ventricular assist device. *ASAIO J* 1992;38:M676–8.
- [34] Miller LW. Patient selection for the use of ventricular assist devices as a bridge to transplantation. *Ann ThoracSurg* 2003;75:S66–71.
- [35] Ochiai Y, McCarthy PM, Smedira NG, Banbury MK, Navia JL, Feng J, Hsu AP, Yeager ML, Buda T, Hoercher KJ, Howard MW, Takagaki M, Doi K, Fukamachi K. Predictors of severe right ventricular failure after implantable left ventricular assist device insertion: analysis of 245 patients. *Circulation* 2002;106:I198–202.
- [36] Fukamachi K, McCarthy PM, Smedira NG, Vargo RL, Starling RC, Young JB. Preoperative risk factors for right ventricular failure after implantable left ventricular assist device insertion. *Ann ThoracSurg* 1999;68:2181–4.
- [37] Mendes LA, Picard MH, Sleeper LA, Thompson CR, Jacobs AK, White HD, Hochman JS, Davidoff R. Cardiogenic shock: predictors of outcome based on right and left ventricular size and function at presentation. *Coron Artery Dis* 2005;16:209–15.
- [38] Maslow AD, Regan MM, Panzica P, Heindel S, Mashikian J, Comunale ME. Pre-cardiopulmonary bypass right ventricular function is associated with poor outcome after coronary artery bypass grafting in patients with severe left ventricular systolic dysfunction. *AnesthAnalg* 2002;95:1507–18.



- [39] Vaur L, Abergel E, Laaban JP, Raffoul H, Jeanrenaud X, Diebold B. Quantitative analysis of systolic function of the right ventricle by Doppler echocardiography. *Arch Mal Coeur Vaiss* 1991;84:89–93.
- [40] Yamada S, Nakatani S, Imanishi T, Nakasone I, Sunagawa K, Miyatake K. Estimation of right ventricular contractility by continuous-wave Doppler echocardiography. *J Cardiol* 1996; 28:287–93.
- [41] Stainback RF, Croitoru M, Hernandez A, Myers TJ, Wadia Y, Frazier OH. Echocardiographic evaluation of the Jarvik 2000 axial-flow LVAD. *Tex Heart Inst J* 2005;32(3):263-70.
- [42] Sun BC, Catanese KA, Spanier TB, Flannery MR, Gardocki MT, Marcus LS, Levin HR, Rose EA, Oz MC. 100 long-term implantable left ventricular assist devices: the Columbia Presbyterian interim experience. *Ann ThoracSurg* 1999;68:688–94.
- [43] Dandel M, Weng Y, Siniawski H, Potapov E, Lehmkuhl HB, Hetzer R. Long-term results in patients with idiopathic dilated cardiomyopathy after weaning from left ventricular assist devices. *Circulation* 2005;112:I37–45.
- [44] Slaughter MS, Silver MA, Farrar DJ, Tatooles AJ, Pappas PS. A new method of monitoring recovery and weaning the Thoratec left ventricular assist device. *Ann ThoracSurg* 2001;71:215–18.
- [45] Hetzer R, Muller JH, Weng Y, Meyer R, Dandel M. Bridging-to-recovery. *Ann ThoracSurg* 2001;71:S109–13; discussion S114–15.
- [46] Khan T, Delgado RM, Radovancevic B, Torre-Amione G, Abrams J, Miller K, Myers T, Okerberg K, Stetson SJ, Gregoric I, Hernandez A, Frazier OH. Dobutamine stress echocardiography predicts myocardial improvement in patients supported by left ventricular assist devices (LVADs): hemodynamic and histologic evidence of improvement before LVAD explantation. *J Heart Lung Transplant* 2003;22:137–46.
- [47] Chen JM, Levin HR, Rose EA, Addonizio LJ, Landry DW, Sistino JJ, Michler RE, Oz MC. Experience with right ventricular assist devices for perioperative right-sided circulatory failure. *Ann ThoracSurg* 1996;61:305–10; discussion 311–13.
- [48] Vincent JL, Rhodes A, Perel A, Martin GS, Della Rocca G, Vallet B, Pinsky MR, Hofer CK, Teboul JL, de Boode WP, Scolletta S, Vieillard-Baron A, De Backer D, Walley KR, Maggiorini M, Singer M. Clinical review: Update on hemodynamic monitoring-a consensus of 16. *Crit Care* 2011; 18;15(4):229.
- [49] Tsutsui M, Matsuoka N, Ikeda T, Sanjo Y, Kazama T. Comparison of a new cardiac output ultrasound dilution method with thermodilution technique in adult patients under general anesthesia. *J CardiothoracVascAnesth* 2009; 23:835–840.
- [50] Scolletta S, Miraldi F, Romano SM, Muzzi L. Continuous cardiac output monitoring with an uncalibrated pulse contour method in patients supported with mechanical pulsatile assist device. *Interact CardioVascThoracSurg* 2011;13:52–57.

- [51] Shah MR, Hasselblad V, Stevenson LW, Binanay C, O'Connor CM, Sopko G, Califf RM. Impact of the pulmonary artery catheter in critically ill patients: meta-analysis of randomized clinical trials. *JAMA* 2005;294:1664–1670.
- [52] Schmid ER, Schmidlin D, Tornic M, Seifert B. Continuous thermodilution cardiac output: clinical validation against a reference technique of known accuracy. *Intensive Care Med* 1999;25(2):166–72.
- [53] Goedje O, Hoeke K, Lichtwarck-Aschoff M, Faltchauser A, Lamm P, Reichart B. Continuous cardiac output by femoral arterial thermodilution calibrated pulse contour analysis: comparison with pulmonary arterial thermodilution. *Crit Care Med* 1999;27:2407–2412.
- [54] Gondos T, Marjanek Z, Kisvarga Z, Halász G. Precision of transpulmonary thermodilution: how many measurements are necessary? *Eur J Anaesthesiol* 2009;26(6):508–12.
- [55] Linton NWF, Linton RAF. Estimation of changes in cardiac output from the arterial blood pressure waveform in the upper limb. *Br J Anaesth* 2001;86:486–96.
- [56] Mets B, Frumento RJ, Bennett-Guerrero E, Naka Y. Validation of continuous thermodilution cardiac output in patients implanted with a left ventricular assist device. *J CardiothoracVascAnesth* 2002;16:727–730.
- [57] Thiele RH, Durieux ME. Arterial waveform analysis for the anesthesiologist: past, present, and future concepts. *AnesthAnalg* 2011;113:766–776.
- [58] Wesseling KH, Jansen JRC, Settels JJ, Schreuder JJ. Computation of aortic flow pressure in humans using a nonlinear, threeelement model. *J ApplPhysiol* 1993;74: 2566–73.
- [59] Giraud R, Siegenthaler N, Bendjelid K. Transpulmonary thermodilution assessments: precise measurements require a precise procedure. *Crit Care* 2011;15(5):195.
- [60] Cecconi M, Dawson D, Grounds RM, Rhodes A. Lithium dilution cardiac output measurement in the critically ill patient: determination of precision of the technique. *Intensive Care Med* 2009;35(3):498–504.
- [61] Monnet X, Anguel N, Jozwiak M, Richard C, Teboul JL. Third-generation FloTrac/Vigileo does not reliably track changes in cardiac output induced by norepinephrine in critically ill patients. *Br J Anaesth* 2012;108(4):615–22.
- [62] Scolletta S, Franchi F, Taccone FS, Donadello K, Biagioli B, Vincent JL. An uncalibrated pulse contour method to measure cardiac output during aortic counterpulsation. *AnesthAnalg* 2011;113(6):1389–95.
- [63] Scolletta S, Muzzi L, Romano SM, Gregoric ID, Frazier HO. The “left” ventricle during pulsatile mechanical assistance: reliability of cardiac output monitoring with an uncalibrated pulse contour method. *Eur Heart J* 2010;31(2):148.

- [64] Wiesenack C, Prasser C, Liebold A, Schmid FX. Assessment of left ventricular cardiac output by arterial thermodilution technique via a left atrial catheter in a patient on a right ventricular assist device. *Perfusion* 2004;19:73–75.
- [65] Riha H, Kotulak T, Syrovatka P, Netuka I. Hemodynamic monitoring with LiDCO-plus system in the patients supported by isolated right ventricular assist device. *Interact CardiovascThoracSurg* 2011;13(1):57.
- [66] Scolletta S, Gregoric ID, Muzzi L, Radovancevic B, Frazier OH. Pulse wave analysis to assess systemic blood flow during mechanical biventricular support. *Perfusion* 2007;22(1):63–6.
- [67] Frazier OH, Myers TJ, Westaby S, Gregoric ID. Clinical experience with an implantable, intracardiac, continuous flow circulatory support device: physiologic implications and their relationship to patient selection. *Ann ThoracSurg* 2004;77:133–42.
- [68] Romano SM, Pistolesi M. Assessment of cardiac output from systemic arterial pressure in humans. *Crit Care Med* 2002;30:1834–1841.
- [69] Montenij LJ, de Waal EE, Buhre WF. Arterial waveform analysis in anesthesia and critical care. *Curr Opin Anaesthesiol* 2011;24(6):651–6.
- [70] Camporota L, Beale R. Pitfalls in haemodynamic monitoring based on the arterial pressure waveform. *Crit Care* 2010;14:124.

