

# We are IntechOpen, the world's leading publisher of Open Access books Built by scientists, for scientists

6,900

Open access books available

185,000

International authors and editors

200M

Downloads

Our authors are among the

154

Countries delivered to

TOP 1%

most cited scientists

12.2%

Contributors from top 500 universities



WEB OF SCIENCE™

Selection of our books indexed in the Book Citation Index  
in Web of Science™ Core Collection (BKCI)

Interested in publishing with us?  
Contact [book.department@intechopen.com](mailto:book.department@intechopen.com)

Numbers displayed above are based on latest data collected.  
For more information visit [www.intechopen.com](http://www.intechopen.com)



---

# Diagnosis and Management of Orbital Cellulitis

---

Imtiaz A. Chaudhry, Waleed Al-Rashed,  
Osama Al-Sheikh and Yonca O. Arat

Additional information is available at the end of the chapter

<http://dx.doi.org/10.5772/52719>

---

## 1. Introduction

Orbital cellulites is an uncommon infectious process in which patient may present with pain, reduced visual acuity, compromised ocular motility and significant proptosis. [1]- [3] In the modern era of relatively early access to the health care facilities, complete loss of vision from orbital cellulitis is rare. In the vast majority of cases, a history of upper respiratory tract infection prior to the onset is very common especially in children. [4], [5] Chandler et al, [6] for simplicity has classified the disease into 5 categories and emphasized the possibility of fatal outcome due to the extension of the abscess to cavernous sinus in the form of thrombosis and intracranial spread. In addition to the loss of vision, orbital cellulitis can be associated with a number of other serious complications that may include intracranial complications in the form of cavernous sinus thrombosis, meningitis, frontal abscess and even death. Historically, since the wide spread use of effective antibiotics, the serious complications of orbital cellulitis have become much less frequent. In the past, loss of vision was a relatively more common outcome of orbital cellulitis. [2] In the recent years, only few case reports of loss of vision following orbital cellulitis has been reported in the literature. For example, Connel et al, [3] reported case of a 69-year-old man who presented with no light perception vision, proptosis and significant ophthalmoplegia. In their case, despite emergent drainage of the abscess and systemic antibiotics, no improvement in vision was noted despite the return of the full ocular motility and disappearance of proptosis. Connel et al, [3] postulated Streptococcal-related ischemic necrosis of the optic nerve as a possible mechanism of loss of vision in their patient. In one of the recent survey of 52 patients treated for orbital cellulitis, over 35% had decreased vision and on their last follow-up, only 4% had decreased visual acuity. [1] Our own experience in treating 218 patients with orbital complications of cellulitis revealed that visual acuity improved in 16.1% and worsened in 6.2%, including 4.3% that sustained complete loss of vision. [8] We attributed the perma-

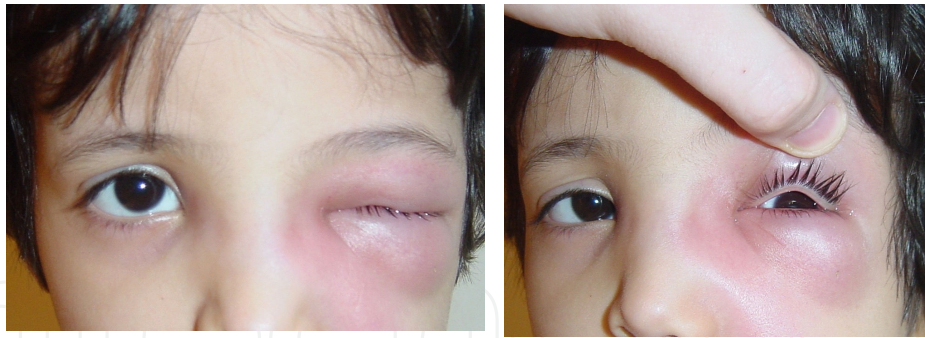
nent loss of vision to the delay in diagnosis and intervention. Further, there were 9 cases of intracranial orbital abscess extension that required either extended treatment with systemic antibiotics alone or in combination with neurosurgical intervention. [3]

## 2. Patient presentation

Patients with orbital cellulitis may present with signs of eyelid swelling, conjunctival chemosis, diplopia and proptosis which may not be prominent in cases of preseptal cellulitis. [1], [8], [9] These patients may present with corneal infections resulting from exposure keratopathy due to their inability to close their eyes. Many of these patients come with local symptoms in the form of eyelid edema, redness, chemosis, decreased ocular motility and proptosis (Figure 1). Patients having superficial signs of swelling (preseptal cellulitis) should be differentiated from deeper infection resulting in orbital cellulitis, in which case, signs and symptoms resulting from inflammation may be helpful. [9] In particular, external ophthalmoplegia, proptosis and decreased visual acuity are associated with orbital cellulitis rather than preseptal cellulitis. [8], [9] Temperature greater than 37.5°C and leukocytosis resulting in fever may be more prominent feature of the pediatric orbital cellulitis. [4], [5] In children, external ophthalmoplegia and proptosis may be the most common features, while decreased visual acuity and chemosis may be less frequent signs in both the pediatric as well as in the adult patients. In cases of the optic nerve involvement, disc edema or neuritis with rapidly progressing atrophy resulting in blindness may occur. Mechanical pressure on the optic nerve and possibly compression of the central retinal and other feeding arteries results in optic nerve atrophy. [10] Also orbital inflammation itself may spread directly into the substance of the optic nerve causing small necrotic areas or abscesses. [2] Compression of the feeding vessels as well as inflammation may result in the infarction of the optic nerve, infarction of the sclera, choroids as well as the retina. Inflammation may result in septic uveitis, iridocyclitis or choroiditis with a cloudiness of the vitreous, including septic pan ophthalmitis. A less common complication of orbital cellulitis is glaucoma that can cause decreased vision, reduced visual field or even enlarged blind spot on presentation. On occasion, one may not find any fundus abnormalities. Among our patients presenting to a tertiary eye care center in the developing country, presenting signs of 218 patients with orbital cellulitis included, eyelid swelling in 71.5%, proptosis in 68.3%, motility restriction in 59.2%, pain in 52.3%, and decreased visual acuity in 14.2% of cases. [8]

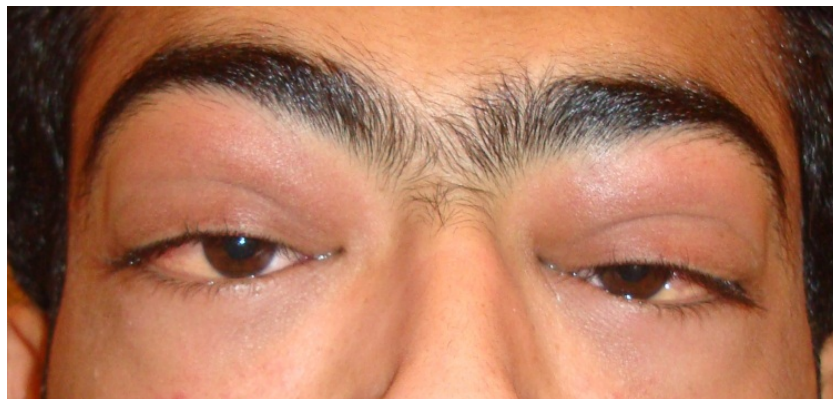## 3. Differential diagnosis

Some of the differential diagnosis for patients presenting with orbital cellulitis may include, allergic reaction to topical or systemic medication, edema from hypo-proteinemia due to variety of systemic causes, orbital wall infarction and subperiosteal hematoma due to unrecognized trauma or due to blood coagulation disorders. Differential diagnosis may also include orbital pseudotumor (Figure 2), retinoblastoma, metastatic carcinoma and unilateral or



**Figure 1.** A child with left sided eyelid erythema, swelling and proptosis following a bout of upper respiratory infection.

bilateral exophthalmos secondary to thyroid related orbitopathy. [11] In all cases, careful history, thorough physical examination along with carefully selected imaging studies may help in differentiating orbital cellulitis from other causes of proptosis.



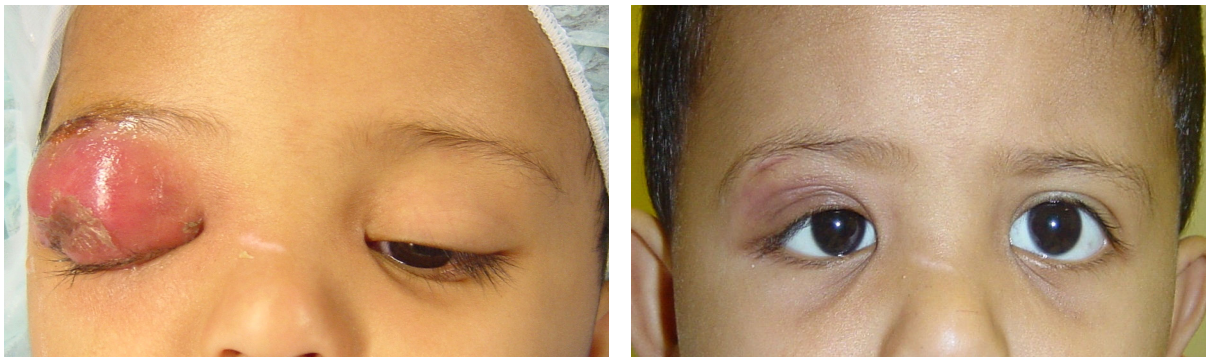**Figure 2.** A 25-year-old male with bilateral eyelid swelling, proptosis and painful diplopia was found to have evidence of bilateral orbital pseudotumor and treated with systemic corticosteroids after imaging studies failed to show evidence of any infectious cause of his symptoms.

#### 4. Most common predisposing factors for orbital cellulitis

In the most reported series, the most common predisposing factor for orbital cellulitis is sinus disease, especially in children. [1], [4], [8] Usually, the infection originates from sinusitis. It can originate from face or eyelids after a recent or past trauma, dental abscess or from a distant source by hematogenous spread. [1], [8], [11-13] For simplification purposes, Chandler et al, [6] grouped complication of sinus inflammation into 5 classes. In the group 1, eyelids may be swollen along with presence of orbital content edema (preseptal cellulitis). Swelling may reflect impedance of drainage through ethmoidal vessels. Group II reflects evidence of orbital cellulitis in which inflammatory cells diffusely infiltrate orbital tissues. In Group II, the eyelids



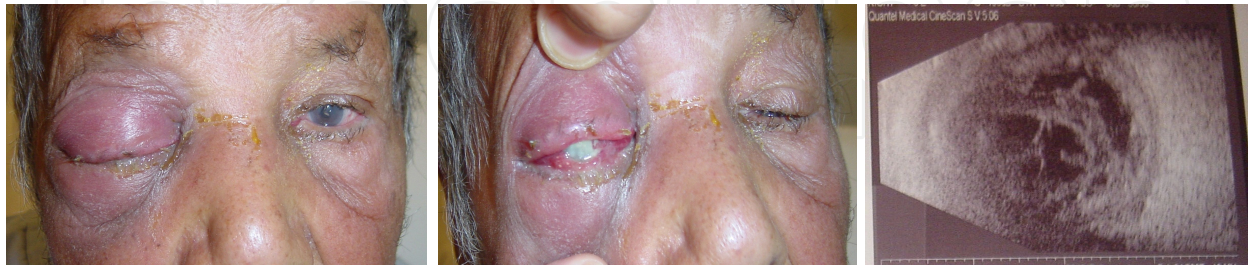may be swollen along with conjunctival chemosis as well as some degree of proptosis. Visual loss may be present in Group II patients. Purulent material may be collecting as subperiosteal abscess between the periorbita and the bony walls of the orbit in Group III. These patients may have significant conjunctival chemosis, eyelid edema, along with tenderness in the involved areas with variable degree of proptosis, and decreased ocular motility. The abscess may be anywhere in the vicinity of the orbit. Patients in group IV (orbital abscess), may present with their abscess being inside or outside the muscle cone following untreated orbital cellulitis. These patients may have significantly more pain, proptosis, decreased ocular motility and variable degree of severe visual loss. Patients in group V may present with bilateral eyelid edema along with involvement of third, fifth and sixth cranial nerves which is thought to be due to the extension of the infectious process into the cavernous sinus with formation of thrombosis. These patients may have nausea, vomiting along with signs of nervous system involvement which could also be due to septicemia. Signs of proptosis, eyelid edema, optic neuritis, frozen globe, decreased supra-orbital nerve conduction may be hallmarks of orbital apex syndrome which is thought to be due to the sinusitis in the area of the superior orbital fissure and optic foramen. [14]



**Figure 3.** External photographs of a young male child who suffered trauma over his right brow area after which he developed orbital cellulitis and formation of an abscess that required drainage.

Our own experience in treating orbital cellulitis from a developing country confirmed previous observations from the Western countries in which sinusitis has been implicated as the cause of orbital cellulitis in most of the cases. [8] Specifically in children, vast majority of cases with orbital cellulitis had pre-existing sinusitis, and significant number of them had multiple sinuses involved. Our experience revealed that unlike patients from the Western countries, most patients with sinusitis and orbital cellulitis in the developing countries had sought treatment later in the course of their disease. Unlike Western countries, in our patients, prior history of periocular trauma or ocular/ periocular surgery were also very common cause of orbital cellulitis. (Figure 3). [1], [10] Although less common, dacryocystitis, dental infection and endophthalmitis, were also found to be the cause of orbital cellulitis in our patients (Figure 4). [8] Patients with prior history of sinusitis may also develop osteomyelitis and intracranial infection. In these cases, osteomyelitis, commonly involve the frontal bone which is due to a direct extension of frontal infection or septic thrombophlebitis via the valveless sinus of

Breschet. [15] Less common cause of osteomyelitis results from the ethmoidal sinusitis because from this location, infection can rapidly spread through the thin lamina papyracea into the orbit or maxilla, where arterial anastomoses are sufficient to prevent necrosis due to septic thrombosis of a single artery. Although meningitis may be the most common intracranial complication of sinus disease, epidural, subdural and brain parenchymal abscess can also develop. [15]



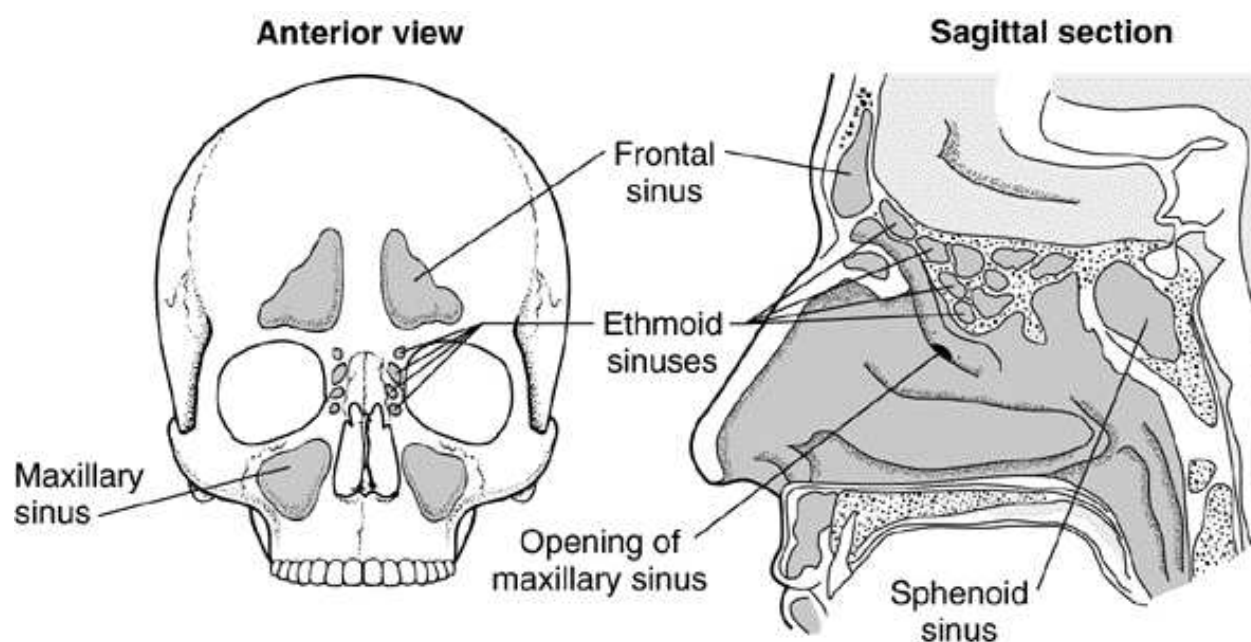
**Figure 4.** External photograph and U/S of right eye of an 83-years-old male who suffered right eye trauma and then developed panophthalmitis resulting in total loss of his vision.

## 5. Sources of infection

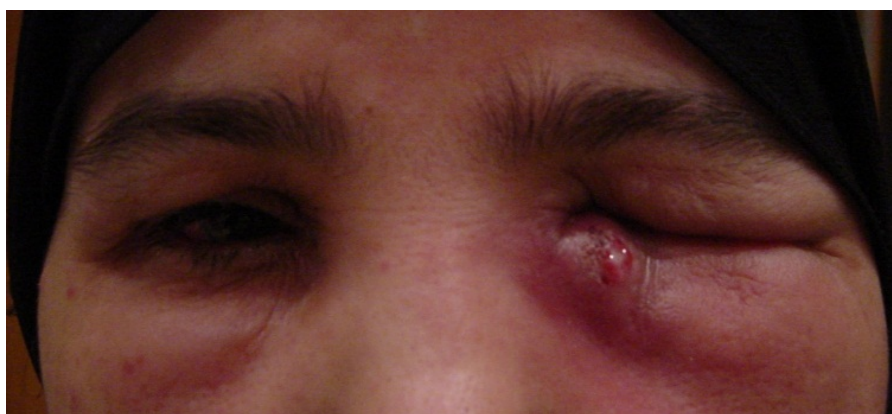Usually, orbital cellulitis occurs in the childhood years which has been attributed to the relatively incomplete development of immunity in this age group. [1], [4], [5], [16], [17] In these patients, sinus disease has been found to be the most common predisposing factor. Over 90% of these patients have radiologically confirmed sinusitis, the most common being ethmoidal and maxillary. [1], [8] In the reported series, ethmoidal sinusitis has been demonstrated to be the source of infection in significantly large number of cases. [18], [19]

Ethmoidal sinusitis is usually present with maxillary sinusitis on the same side of the infection. [19], [20] Frontal sinus disease has been frequently identified especially in series in which a large number of adolescents and adults have been studied (Figure 5). [10], [18], [20] Up to 38% of children may have more than one sinus involved and in the adult patients, up to 50% may have underlying sinusitis, while up to 11% may have multiple sinuses involved. [1], [8] Other etiological factors resulting in orbital cellulitis may include dacryocystitis with orbital extension (Figure 6), retained foreign body, panophthalmitis, infected tumor, Herpes Zoster, (Figure 7), and mucormycosis. [8], [21]

As orbital cellulitis has a close relationship with sinus (Figure 5), and upper respiratory disease, a seasonal distribution paralleling that of upper respiratory infections (URI) has been documented with a bi-model seasonal distribution of cases with peak occurring in late winter and early spring season. [1], [8] Bacterial sinusitis can result in orbital cellulitis leading to a subperiosteal abscess from the accumulation of purulent material between the periorbita and the orbital bones. [6], [8], [20] Since the use of modern imaging studies in the form of computed tomography (CT-scan), the concept of subperiosteal abscess has been accepted as a separate



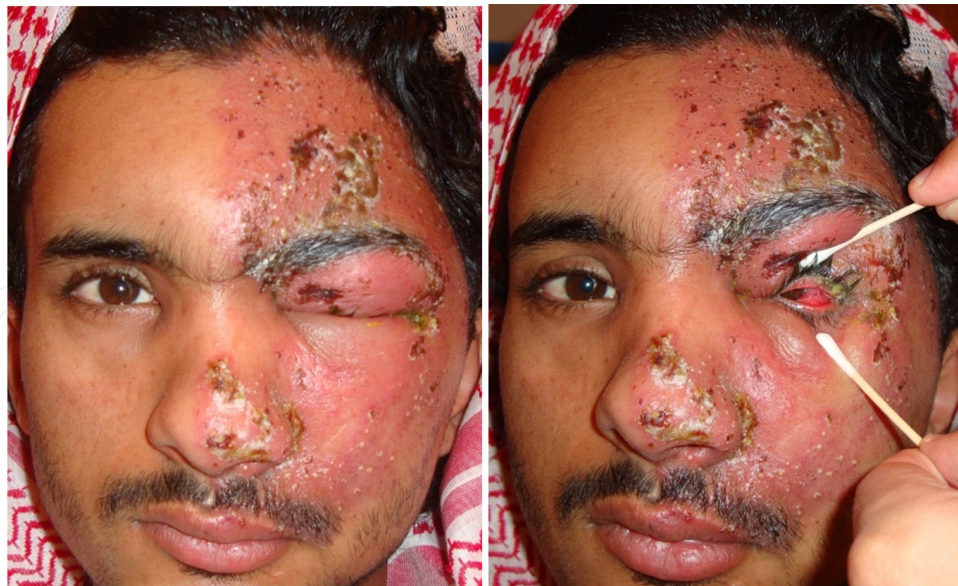**Figure 5.** Anterior and sagittal view of the frontal, ethmoidal, sphenoid and maxillary sinuses and their close relationship with orbital anatomy.



**Figure 6.** External photograph of a 42-years-old female who presented with left-sided orbital cellulitis and abscess formation due to the acute over chronic dacryocystitis.

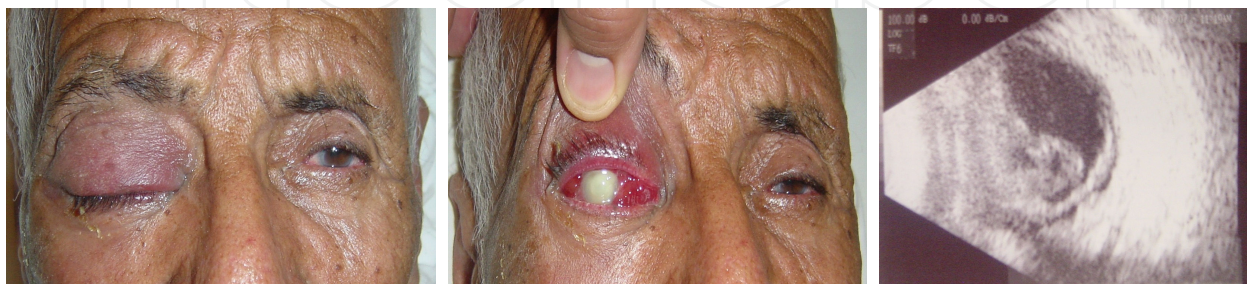entity. [20], [22] Because of the reports of rapidly progressive visual and intracranial complications from subperiosteal abscess, some clinicians argue for the prompt surgical drainage of the abscess and paranasal sinuses when a subperiosteal abscess is first diagnosed by a CT-scan. [15], [20], [22-26] Among our survey of 218 patients who required treatment of their orbital cellulitis, imaging studies revealed that sinus disease was the most cause in 39.4%, trauma in 19.7%, endophthalmitis in 13.3%, (Figure 8), orbital implants in 8.2%, dacryocystitis in 4.6%, retained orbital foreign body in 3.2%, dental infection in 2.7%, and scleral buckle in 2.3%.<sup>8</sup> A history of sinusitis and recent trauma was the cause of orbital cellulitis in 4.1%, and intraocular or orbital tumors were the cause in another 4% of patients.





**Figure 7.** External photograph of a 19-years-old male who presented with 3 day history of left-sided facial erythema, swelling, conjunctival chemosis, proptosis and eruptive skin lesions. A diagnosis of Herpes Zoster Ophthalmicus was made and patient was treated for acute Zoster infection and its complications.

In diabetic and immune-compromised patients one has to rule out fungal infection as the cause of orbital cellulitis, the most common being Mucormycosis and Aspergillosis. While infection with Mucormycosis has no climatic or age restriction, Aspergillosis usually occurs in hot and humid climates in patients older than 20 years of age. Although predisposing factors for Aspergillosis are unclear multiple risk factors for Mucormycosis have been proposed, among them diabetic ketoacidosis is the most common. The course of onset for Mucormycosis infection is rapid (usually 1-7 days) as compared with slow infection due to Aspergillosis which can take a month to a year. Otolaryngologic findings in patients with Mucormycosis may include nasal and palatal necrosis along with paranasal sinusitis. In Aspergillosis, one may find evidence of chronic fibrosis and non-necrotizing granulomatous reaction of the involved structures. In cases of Mucormycosis infections there is evidence of ischemic necrosis along with thrombosed arteries

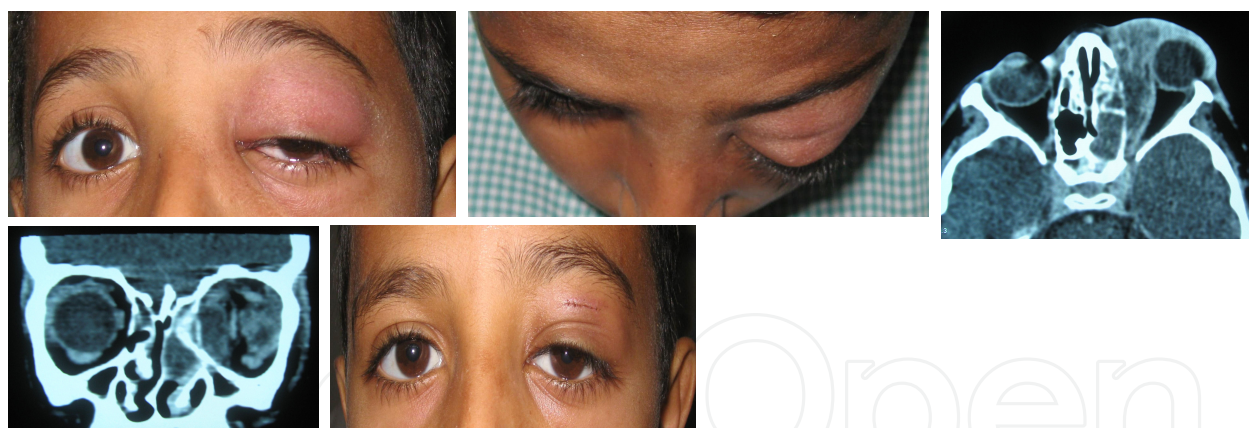

**Figure 8.** External photographs and U/S of the right eye of a 73-years-old male who developed panophthalmitis after cataract surgery.



## 6. Epidemiology of orbital cellulitis

Orbital complications of sinusitis have been reported to range anywhere between 0.5 to 3.9%. [1], [17], [27] However, the incidence of abscess formation vary considerably from 0-25% in the reported series. [15] No cases of abscess formation was reported in the published series from the Children's Memorial Hospital in Chicago including 87 patients with orbital cellulitis and from Children's Hospital in Pittsburgh including 104 orbital celulitis cases. [28], [29] On the other hand, a larger study of 6,770 patients from the Hospital for Sick Children in Toronto revealed that 2.3% developed orbital complications; of which 10.7% had abscess formation. [19] Another study reported 20.8% incidence of abscess formation among the 158 patients admitted for orbital cellulitis. There was a 20.8% incidence of abscess formation. [30] Among other series which has reported orbital complications of sinus disease, the incidence of abscess formation had varied from 6.25 to 20 % to as high as 78.6%. [18], [31], [32] One may attribute differences among these studies due to the inclusion criteria, age group and the severity of the complications studied by these authors. The incidence of major complications following sinusitis may be low, however such complications may be associated with considerable morbidity and mortality. [8], [15] According to the published report, in the pre-antibiotic era, orbital cellulitis resulted in death from meningitis in 17% of cases and blindness in 20%. [6] However, in the antibiotic era, incidence of menengitis was reported as 1.9% in patients with orbital cellulitis, despite prompt treatment with systemic antibiotics. [33]



**Figure 9.** External photographs as well as CT-scan (axial and coronal views) of a 7-year-old boy who presented with upper respiratory infection followed by painful diplopia, left eye proptosis and decreased vision. His symptoms did not improve with a course of systemic antibiotics. This patient required drainage of his orbital abscess which resulted in immediate resolution of his symptoms.

In-spite of systemic antibiotics and surgical intervention, orbital abscesses may have devastating outcome. [15] According to the series in which final visual results have been reported, a significant percentage of patients have been left with non-seeing eyes ranging anywhere from 7.1% to as high as 23.6%. [10] Visual loss in these cases have been attributed to optic atrophy, central retinal artery occlusion, or exposure keratopathy with corneal ulcer formation. [8], [10], [19] Some of the other hypothesized mechanisms of vision loss are septic optic neuritis, embolic

or thrombotic lesions in the vascular supply of the optic nerve, choroid or retina. It has been postulated that delayed medical and surgical intervention may produce unacceptable visual outcome. [19], [20], [22]- [25] Among our 218 patients with diagnosis of orbital cellulitis, there were 116 cases of radiologically confirmed subperiosteal abscess, (Figure 9), 87% of them required drainage, and the remaining 13% were observed closely until their resolution while those patients were being treated with systemic antibiotics. [8] Thirty-nine eyes (17.8%) had endophthalmitis causing orbital cellulitis which required evisceration (9.6%) or enucleation (8.2%). Seven orbits required exenteration and 6 infected orbital implants had to be removed. Six patients had dacryocystitis that required a dacryocystorhinostomy to treat orbital cellulitis in addition to the administration of systemic antibiotics. [8]

## 7. Investigative studies

On orbital ultrasonography (U/S), abscess may show low internal reflectivity and therefore, U/S can be useful as a screening office procedure for patients suspected of having orbital abscess. [8], [27] Computed tomography scan may be necessary to assess the evidence of sinusitis and orbital processes. On CT-scan, orbital abscess may appear as localized, generally homogenous elevation of the periorbital adjacent to an opacified sinus, (Figure 9). On imaging studies, there may be evidence of inflammatory or infective changes in the sinus areas as well as orbital structures. In children, more patients may have subperiosteal abscess as compared to the adult group at the time of their initial presentation. [4] In the series reported by Ferguson and McNab, [1] among children, 29% had inflammatory changes only, while 62% had evidence of a subperiosteal abscess, only 9% had orbital abscesses, compared with 72%, 5% and 22%, respectively, in their adult group. Computed tomography scan may influence the initial therapeutic plan by demonstrating the size and location of the abscess and the specific sinuses involved, features that may be necessary in the approach of surgical drainage. [8], [20], [27] Experience however have shown that the CT-scan characteristics of the subperiosteal collection may not always be predictive of the clinical course. For example, in reports from the patients who recovered with systemic antibiotics alone, findings were similar to the findings in patients who underwent surgical drainage. [22] The imaging studies have shown that the size of an orbital abscess may increase over the first few days of intravenous antibiotics regardless of the bacteriological response to the treatment in these patients. [22] In some patients, the identification of an orbital abscess may be a diagnostic challenge. The reliability of some of the imaging modalities such as CT-scan in demonstrating some orbital abscesses has been questioned. For example from a series of 25 cases of orbital infection, all 15 orbital abscesses were satisfactorily demonstrated only when the CT-scan examination included coronal sections. [34] According to this study, one-third of abscesses would have been missed if coronal sections had not been performed. Magnetic resonance imaging studies have been found to be necessary in some cases where CT-scan have not satisfactorily addressed clinician's concerns.

The development of an orbital abscess does not correlate specifically with visual acuity, proptosis, chemosis, or any other signs. [15], [27] Therefore diagnostic procedures are essential in evaluating the patient with orbital cellulitis and possible abscess or retained orbi-

tal foreign bodies. Although sinus X-ray may demonstrate an air-fluid level when present in an abscess cavity, gas-free abscesses may not be readily visible. [15] Ultrasound may detect an abscess of the anterior orbit or the medial wall with 90% accuracy, [25] although an acute abscess may be poorly delineated. Currently, the investigative procedure of choice to diagnose an orbital infection is the CT-scan, although MRI can be utilized when there is a contra-indications for CT-scan. [8], [27], [35] By CT-scan, orbital walls, extraocular muscles, optic nerve, intraconal area and adipose tissue can be seen clearly. An orbital abscess can be seen as a homogenous, a ring-like, or a heterogenous mass. In these studies, the site of origin, orbital or subperiosteal, and extent of abscess are readily visible. [8], [22] When administered, contrast-media can enhance the surrounding wall of an abscess. Computed tomography scan will not differentiate between preseptal cellulitis and eyelid edema but will differentiate between preseptal and orbital cellulitis. [15] Beside foreign bodies, sinus disease and intracranial complications may also be visible on the CT-scan. [8] Our experience has shown that CT-scan may be the most comprehensive source of information about orbital infections and the most sensitive means of monitoring resolving orbital or intracranial lesions. [8], [27] Computed tomography scan is indicated in all patients with periorbital inflammation in whom proptosis, ophthalmoplegia, or a decrease in visual acuity develop, in whom a foreign body or an abscess is suspected, severe eyelid edema prevents an adequate examination, or surgery is contemplated. [8], [15], [20], [22], [35] In our study of the 218 patients with orbital cellulitis, diagnosis was made clinically and confirmed by CT-scans or U/S in 90.4% and 36.2% orbits, respectively. [8] Orbital abscesses were identified in 53.2% of orbits. In all cases of orbital cellulitis, there was evidence of inflammatory or infective changes of the orbital structures. Abscess location was found to be medial in 35%, superior in 33%, intraconal in 13%, superomedial in 6%, inferomedial in 6% and lateral in 2% of orbits. [8]

## 8. Bacteriology of orbital infection

In the reported series, the bacteriology of orbital abscesses has received little attention. In series in which the contents of the abscess cavity have been cultured, a wide range of organisms have been reported. [8], [36] Most commonly reported bacterial species from the abscesses of the orbit and periorbital area include *Staphylococcus aureus*, *Staphylococcus epidermidis*, *Streptococci*, *Diphtheroids*, *Haemophilus influenzae*, *Escherichia Coli*, multiple species of aerobes and anaerobes. There was no growth in up to 25% of abscesses. [15], [17] Microbiological results from Ferguson and McNab, [1] series varied, with differences in the rate of testing between the pediatric age group and the older age group. In their series, some forms of cultures were performed in 93% of their patients. Fifty percent of their patients had blood cultures none of which yielded positive results. According to their study, cultures taken from abscesses were more likely to yield positive results. The authors noted that there was no correlation between cultures taken from conjunctival swab and the etiological organisms recovered from the abscesses of those patients with positive cultures. In their study, *Staphylococcus aureus* was the most common micro-organism recovered. In their pediatric age group



various species of *Streptococcus* predominated. Among their pediatric patients, 4 patients had anaerobic *Streptococcus* isolates, two had mixed anaerobes and one had *Clostridium bifermentans*. In Ferguson and McNab's, [1] series, orbital cellulitis due to anaerobes was much less common in adults, with only one case of mixed anaerobes identified. In their series, only 5 adults and 4 pediatric patients had multiple organisms isolated from the abscesses. No pathogenic organisms were isolated from their 6 adult and 15 pediatric patients in whom the cultures were performed. [1] Although in the past, *H influenza* was a major pathogenic bacteria responsible for orbital cellulitis in the pediatric age group, [8], [15] in the series reported by Ferguson and McNab,<sup>1</sup> no cases of *H. influenza* were identified in the pediatric age group and only one case was found in an adult patient. This observation has been attributed to the general immunization of children with *H. influenza* type B vaccine since the early 1990s. [1], [27] Schramm et al,<sup>5</sup> reported 32 cases of orbital abscesses, the predominant microorganisms being *Staphylococci*, *Streptococci* and *Bacteroids* species.

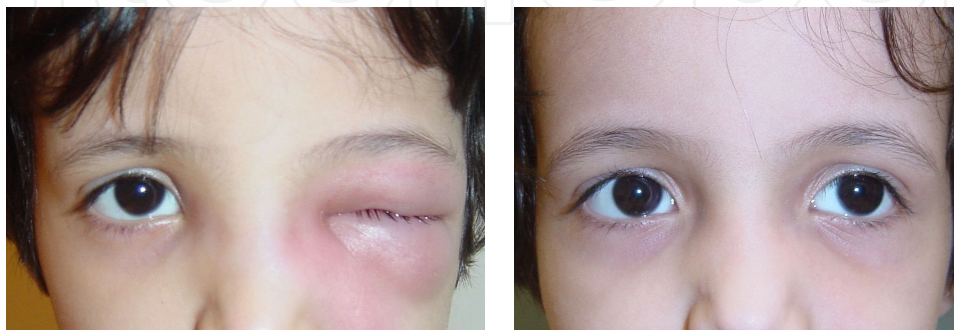The role of anaerobes, not usually considered pathogens in the sinus disease is unclear, although considerable number of cultures in adult patients have yielded anaerobes. [8], [20], [23] In general, patients during their first decade of life may have infection caused by a single aerobic pathogen which may be responsive to the medical therapy alone. On the other hand, patients older than 15 years of age may have complex infections caused by multiple aerobic and anaerobic organisms that may be slow to clear despite medical and surgical intervention. [23] The virulence of pathogens and responsiveness to anti-microbial agents appear to be age-related. [20], [37] With enlarging of the size of the sinus cavities, the ostia gets narrow creating optimal condition for anaerobic bacterial growth. As the person ages, there is a trend towards appearance of more complex infections. In mixed infections, aerobes utilize oxygen which encourage growth of more anaerobic microorganisms. On the other hand anaerobes produce B-Lactamase which makes antibiotics less effective. Harris, [20] reviewed microbiology results of 37 patients with orbital abscesses in which one-third were younger than 9 years, 58% were culture negative and the rest had single aerobic pathogen. From his series, 16 patients between ages 9-14 years showed transition towards more complex infections. Among these, 9 patients which were older than 15 years had positive cultures despite being on systemic antibiotics for 3 days. In Harris's, [20] study, older group had more often polymicrobial infections and anaerobes were found in all cases. According to our study the most common microorganisms isolated from the drained abscesses were the most common microorganisms isolated from the drained abscesses were *Staphylococci* and *Streptococci* species; less common organisms included *Propionibacterium acnes*, *Haemophilus influenzae*, *Bacillus*, and fungi. [8]

## 9. Medical management

Medical management depends on the patient's appearance, ability to take oral medications, compliance and clinical progression of the disease. Patients presenting with signs and symptoms of eyelid edema, diplopia, reduced visual acuity, abnormal light reflexes, ophthalmoplegia and proptosis need admission (Figure 10). Further, if a patient appears toxic and eye exam is difficult to be completely performed, along with signs of CNS involvement as evident

by lethargy, vomiting, seizures, headache or cranial nerve deficit, admission is needed for further evaluation and proper treatment. Intravenous antibiotics are usually started once the diagnosis of orbital cellulitis is suspected, broad-spectrum antibiotics that cover most gram positive and gram negative bacteria are considered initially. The recommendations for antibiotics are usually based on the microorganisms most frequently suspected from abscesses; *Staphylococcus aureus*, *Staphylococcus epidermidis*, *Streptococci*, and *Hemophilus* species. [15] Empiric antibiotics should cover methicillin-resistant *Staph.aureus* if suspected. [38], [39] One should suspect mixed infections including aerobic and anaerobic species in the abscesses. [20] Warm compresses over the involved area may help to improve the softening of the tissues to bring in more blood circulation in the area where blood supply is already abundant. If no improvement occurs in 24-48 hours of systemic antibiotics, one may consider Infectious Disease, Ear, Nose and Throat and/or Neurosurgery consultations. [27]

Historically, cultures from the conjunctiva, nose and throat are usually not representative of the pathogens cultured from the abscesses and blood cultures may frequently be negative and are not usually helpful. [15] Most patients in the reported series, had received a combination of a third-generation cephalosporin and flucloxacillin. [1], [8] According to those reports, most patients had received oral antibiotics on discharge for varying periods of time. [40] For example, all patients in the Ferguson and McNab's [1], series had received intravenous antibiotic treatment during their admission and most of these patients had received multidrug therapy with up to 5 different antibiotics at some point. In these cases treatment regimens were empirically based and instituted prior to the identification of responsible organisms. [1] In our experience, most of our patients also had multiple antibiotic regimens administered during their stay in the hospital and most of them were discharged on at least one antibiotic therapy. [8] In our study of 218 patients having orbital cellulitis and abscess, all patients received systemic antibiotic treatment, and in all patients, treatment regimens were empirically based and were instituted before the identification of any responsible organisms. [8] In our study, the most common antibiotic regimen included cephalosporins in 90%, and aminoglycosides in 66% with a combination of other antibiotics. These antibiotics included flucloxacillin in 15%, vancomycin in 13%, ampicillin in 6%, metronidazole in 4%, and penicillin in 3% of patients. In our study, most patients received oral antibiotics on their discharge for varying periods, ranging from 3 days to 3 weeks. [8]



**Figure 10.** Patient from Figure 1 after medical treatment of her left-sided orbital cellulitis.

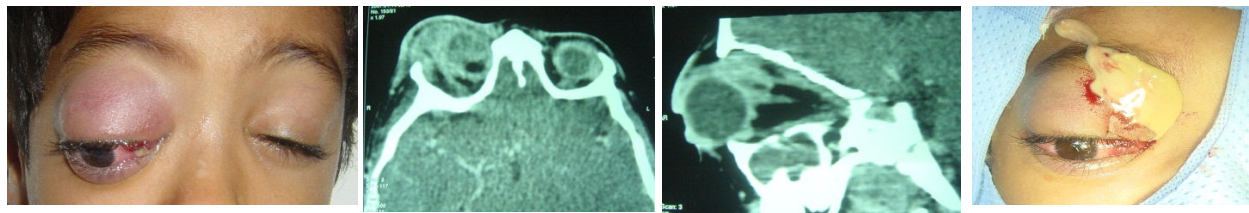
From the reported series, patient age has been identified as a factor in the bacteriology and the response of these patients to treatment for their orbital abscesses. [16], [17], [20] In general, children aged <9 years have been found to have simpler, more responsive infections, primarily caused by single aerobic pathogen. Older children and adults have been found to harbor more complex infections caused by multiple aerobic and anaerobic organisms, resistant to both medical and surgical treatment. [20] In addition to starting systemic antibiotics, emergent drainage of the orbital abscesses may be necessary in patients with compromised vision regardless of patient age. Urgent drainage (within 24 hour of presentation) has been recommended for large abscesses, for extensive superior or inferior orbital abscesses, for patients with central nervous system complications and for infections following dental work in which anaerobes might be expected. [20] These patients require surgical option if improvement does not occur as expected. In these patients, careful monitoring of the clinical course is mandatory and comparison of serial CT-scan may be necessary as an adjunct to clinical judgment. In Harris's series 27 of 29 patients which were younger than 9 years old recovered with antibiotic treatment alone with a good clinical outcome. [20] He described "sliding scale" of risk associated with increasing age and argued that patients in the older age group who present with orbital process should undergo prompt sinus surgery even before orbital or intracranial abscesses develop. Once sinus infection in older children or adults has extended into the orbit as an abscess, urgent drainage may include the orbit along with the infected sinuses. [20] Computed tomography scan may not be accurate in assessing clinical course in some of these patients. In a review of 37 cases of orbital abscesses, Harris, found that subperiosteal material could not be predicted from the size or relative radiodensity of the collections from the CT-scans. [22] Initial scans were not as predictive of the clinical course. In fact the serial scans showed enlargement of abscesses during the first few days of systemic antibiotic therapy regardless of the final outcome of the response to treatment. He concluded that expansion of orbital abscess on the serial CT-scans during the initial treatment may not be equated to failure of the infection to respond to the medical management in the form of antibiotics alone. [22]

## 10. Surgical intervention

From their vast experience with the management of orbital abscesses, Garcia and Harris [23], concluded that surgical therapy for orbital abscesses may be contemplated based on several factors, including the sinuses involved, the presumed pathogens, the anticipated bacterial response to administered antibiotic, visual status, the size and location of the orbital abscess and potential intracranial complications. They recommended emergency drainage of the orbital abscesses and sinuses of patients of any age whose optic nerve or retinal function is compromised. Urgent drainage for large abscesses, in cases of extensive superior or inferior abscesses that might not quickly resolve despite clearance of sinusitis by medical treatment has been recommended, (Figure 11). In cases of intracranial complications at the time of presentation and in frontal sinusitis, in which the risk of intracranial extension is increased, and when complex infections that include anaerobes are suspected, urgent drainage of an abscess is recommended. [23] Again, expectant approach has been recommended for patients



younger than 9 years of age in whom simple infections may be suspected. Surgical option may still be exercised if clinical improvement does not occur in a timely manner and if relative afferent pupillary defect develops at any time. Further, surgical option should be considered in cases of fever not abating within 36 hours of systemic antibiotic treatment suggesting that the infection may not be responding to the choice of antibiotics being administered. Surgery should also be considered when there has been deterioration of vision despite 48 hours of appropriate antibiotic therapy and no improvement despite 72 hours of such treatment. Usually, CT-scan improvement should be expected to lag behind the clinical picture. In fact, the CT findings may worsen during the first few days of hospitalization despite successful treatment with antibiotics alone. [23]



**Figure 11.** External photograph of an 8-year-old boy who required drainage of his right orbital abscess after failing 3 days of by systemic antibiotic treatment. CT-scan (axial and sagittal cuts) showed an evidence of maxillary sinusitis and an abscess formation in the superior orbit.

In majority of the cases, surgical intervention is indicated for significant underlying sinus disease, orbital or subperiosteal abscess, or both in the children, (Figure 11). [1], [5], [8], [17] For older patients, sinus surgery remains the most common surgical intervention. Recent literature suggests that the volume of subperiosteal abscess seems to be the most important criterion in determining medical versus surgical management; the volumes of abscesses needing surgery appears to be larger than the volumes of abscesses not needing surgery. In general, volumes of <1,250 mm may not need surgical intervention. [41], [42] There may be an argument regarding early drainage of an orbital abscess to prevent complications whereas early surgical intervention has the possibility of seeding the infection. [20] For practical purposes, Harris, has outlined a useful approach in the management of an orbital abscess. [20] He emphasizes on the emergent drainage for patients of any age whose visual function may be compromised. Also for the patients in whom a large orbital abscess causes discomfort, presence of superior or inferior orbital abscess, evidence of intracranial extension, involvement of frontal sinuses, and a known dental source of the infection in patients older than 9 years, urgent drainage usually within 24 hours has been recommended. [20] Wait and see approach may be indicated for patients younger than 9 years of age having medial subperiosteal abscess of modest size, for patients having no visual compromise and in those having no intracranial or frontal sinus involvement. In these patients, careful evaluation and close monitoring of their optic nerve function and the level of consciousness and mental state are necessary. When indicated, one may consider making an incision approximately 2-inch down to the periosteum at the inner quadrant of the orbit to drain these orbital abscesses. [27] Patients with suspected fungal orbital cellulitis (especially Mucormycosis), need to be treated with intravenous

Amphotericin B and predisposing factors such as diabetes, acidosis and other medical conditions need to be addressed. Wide excision along with debridement of the necrotic tissue is desired. If necessary, a drain may be inserted and tissues may not need to be sutured and may be left for granulation. One may consider removal of drain when no further drainage occurs. In some cases, endoscopic approach may be utilized and has been found to be effective for the treatment subperiosteal abscess as a result of sinus infection. Some of the advantages of endoscopic surgical drainage may be the avoidance of external ethmoidectomy and associated external facial scar and an early drainage of the affected sinuses and subperiosteal abscess at the same time. [27], [43] In our study [8], among the 116 radiologically confirmed orbital abscesses, 87% required drainage, and the remaining 13% required close observation until their resolution while on systemic antibiotics. Thirty-nine eyes (17.8%) had endophthalmitis causing orbital cellulitis and required evisceration or enucleation. Seven orbits required exenteration and 6 infected orbital implants had to be removed. Other 6 patients had dacryocystitis that required a dacryocystorhinostomy to treat orbital cellulitis in addition to the administration of systemic antibiotics. Combined endoscopic sinus surgery with transnasal orbital abscess drainage was carried out in some of our patients with sinusitis and orbital abscess, especially in the medial orbit. [8]

## 11. Complications of orbital cellulitis

Although less common, major complications related to orbital cellulitis and abscess can occur. Even after the successful treatment of such infections, permanent visual loss or loss of function of the vital structures may remain. Ferguson [1] reported no visual function loss among their patients after resolution of their infections. Only one of their patients from the pediatric age group had proptosis on follow-up; one had ophthalmoplegia and one had recollection of the abscess. One of their adult patients developed presumed meningitis and another adult patient required enucleation. In rare circumstances, the microorganism may cause necrotizing eyelid disease often referred as necrotizing fasciitis. [3], [44]- [46] This may progress to systemic manifestations including the potentially fatal toxic streptococcus syndrome, characterized by multi-organ failure. [44], [46] These complications can occur in the absence of antecedent health problems or history of trauma. [3], [45], [46] The virulence of this organism is related to the production of M proteins and exotoxins A and B. [47] These proteins act as super-antigens in vitro and mediate tissue necrosis by causing massive release of cytokines such as tumor necrosis factor and interleukins.

## 12. Visual loss in orbital cellulitis

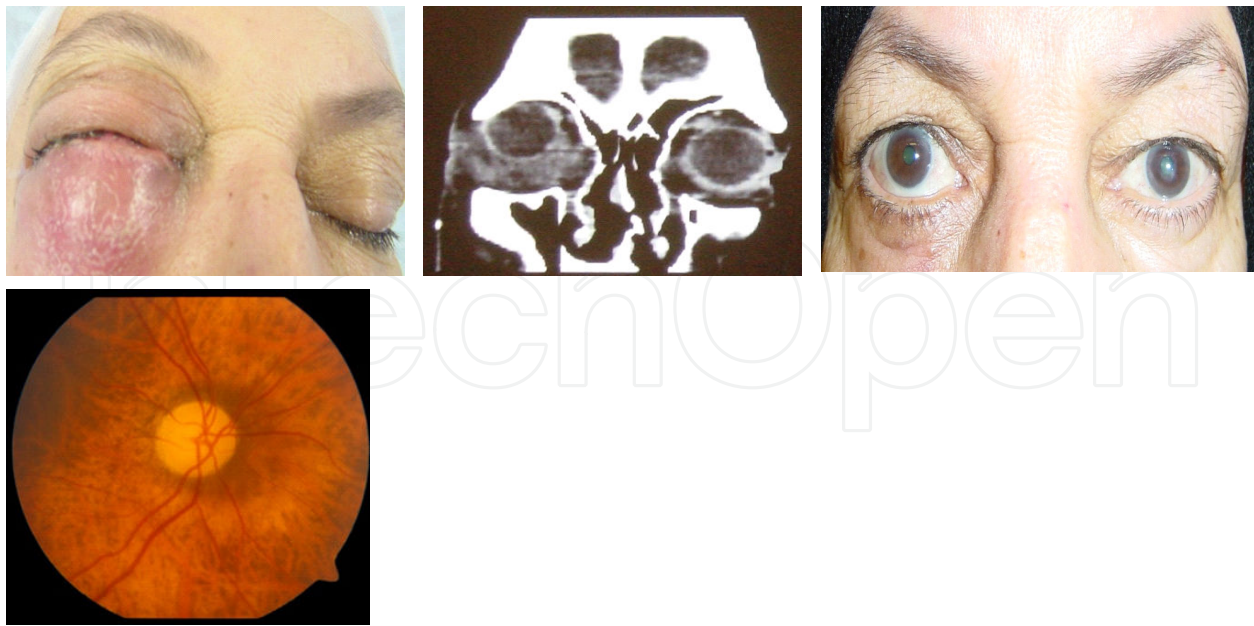Permanent loss of vision has been noted as a complication of orbital infection and up to one fifth of patients with orbital inflammation had blindness in the pre-antibiotic era. [2] Now, although permanent loss of vision resulting from orbital inflammation is unusual it can still occur, (Figure 12). [8], [25], [26] Patt [26] reported 38 patients with orbital cellulitis and resultant

permanent vision loss one of which progressed to no light perception vision. Loss of vision with orbital inflammation may result from optic neuritis as a reaction to adjacent or nearby infection, ischemia due to thrombophlebitis along valveless orbital veins, or compressive/presure ischemia possibly resulting in central artery/occlusion, (Figure 12). [22], [26] Permanent irreversible visual loss may occur in cases with orbital and subperiosteal abscess despite early intervention. In a survey of 46 cases with confirmed diagnosis of orbital and subperiosteal abscess in which visual results were reported, permanent loss of vision occurred in 15% of the cases. [48] Blindness was attributed to the central retinal artery occlusion in 4, optic atrophy in 2 of these patients. Permanent visual loss in orbital cellulitis probably has a vascular cause, whereas partial vision loss that respond to antibiotic therapy and drainage procedures may be due to inflammatory infiltrates or presence of compressive optic neuropathy. [21] It is believed that the confinement of the optic nerve in the orbital apex area and within its bony canal along with its proximity to the posterior ethmoid and sphenoid sinuses may further highlight the importance of these factors in the exacerbation of posterior orbital cellulitis. Physicians need to be aware that patients with sinusitis and associated orbital cellulitis may be at risk for developing severe vision deficit requiring timely intervention. In a review of 148 patients with orbital abscess from 13 series reported by Hornbliss [15], 3 patients had evidence of no light perception vision.

Clinical examination by itself may not exactly delineate the nature of orbital inflammatory processes, clinicians may have to rely on imaging studies to select potential surgical candidates. Despite availability of modern CT-Scan and MRI studies, the physician still needs to rely on the clinical progression of the inflammation based on vision, pupillary function, and assessment of ocular motility. Patt and Manning [26], reported 4 patients with vision loss due to orbital cellulitis and in each of these cases had CT-scan readings of “no definite abscess” contributing to the delay in diagnosis of orbital abscess, with a resultant delay in surgical drainage.

Ethmoidal sinuses are separated from the orbital cavity by the lamina papyracea and anterior and posterior ethmoidal foramina serve as additional connections that may allow infection to gain access from ethmoidal air cells to the orbital cavity, (Figure 5). Periorbital in this area is loosely attached to bone and may be elevated by a purulent collection, resulting in subperiosteal abscess. Acute visual loss due to sinusitis may either be secondary to complications of orbital cellulitis or may be seen as a part of orbital apex syndrome. orbital cellulitis or as a part of the orbital apex syndrome. [27] Two cases of acute visual loss have been reported by El-Sayed and Muhaimeid [49], as a complication of orbital cellulitis due to sinusitis. One of these patients had dramatic improvement in vision from hand motion to normal vision after systemic antibiotic treatment of pansinusitis and associated orbital cellulitis. The second patient, (a 10-year old girl), achieved normal visual acuity from no light perception after only surgical intervention by exploration of sphenoid and ethmoid sinuses along-with intravenous antibiotic administration. Three cases of sphenothmoiditis with minimal signs of orbital inflammation causing permanent loss of vision have been reported by Slavin and Glaser. [48] These authors suggested the use of term “posterior orbital cellulitis” for such cases and defined it as a clinical syndrome in which early severe visual loss overshadows or precedes accompanying inflammatory orbital signs. Acute blindness may also result from orbital infarction syndrome.





**Figure 12.** External photographs, CT-scan (coronal view) and right eye fundus photograph of a 70-year-old female who presented late in the course of her right-sided orbital cellulitis/abscess which required surgical drainage. She had complete loss of vision in the right eye which was attributed to central retinal artery occlusion due to orbital infectious process. Fundus photo reveals evidence of a pale optic nerve.

Orbital infarction syndrome is a disorder that may take place secondary to different mechanisms which may include acute perfusion failure like common carotid artery occlusion, systemic vasculitis such as giant-cell arteritis, or as a result of orbital cellulitis with vasculitis such as Mucormycosis. In some of these cases, vision loss can be permanent due to retinal or optic nerve damage. [50] According to our experience in a developing country, most patients with sinusitis and orbital abscess presented late in the course of their disease. [8] Most patients with refractory or complicated subperiosteal abscesses have been older children or adults. In one of the largest studies reported, among the 159 patients with orbital complications of sinusitis, 4 had permanent blindness. [26] All 4 had surgically confirmed subperiosteal abscess, and all were older than 15 years of age. In another study, among the 13 patients with intracranial abscess extension from sinusitis or orbital abscesses, 2 patients were 9 to 14 years of age and 11 were older than 15 years of age. [7] In our study of orbital cellulitis, visual acuity improved in 16.1% and worsened in 6.2%, including 4.3% that sustained complete loss of vision. We attributed the permanent loss of vision to the delay in diagnosis and intervention. [8]

### 13. Intracranial extension of orbital abscess

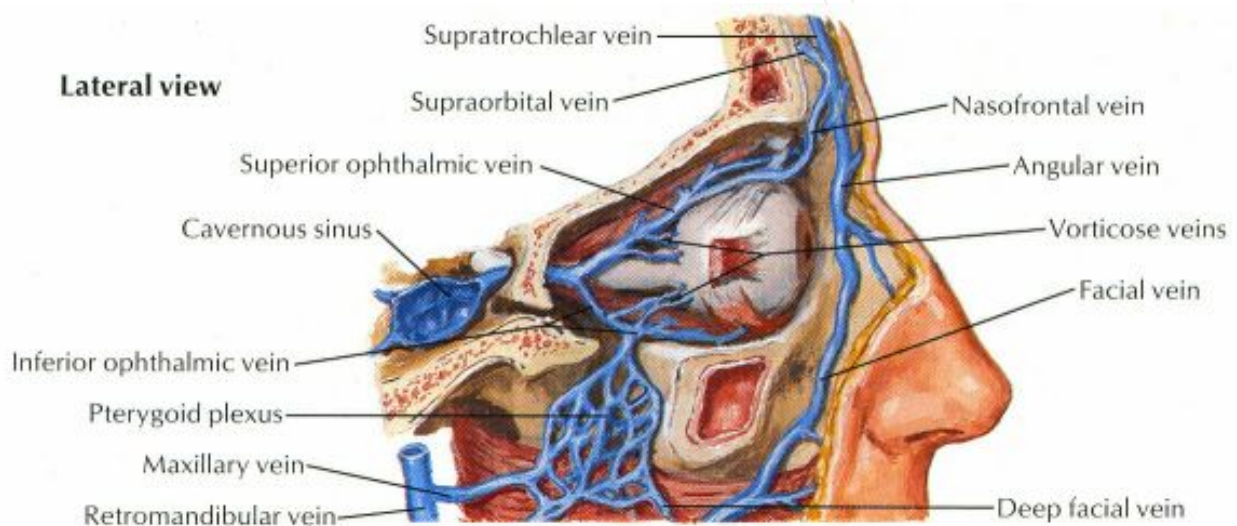
In the pre-antibiotic era, Birch-Hirschfeld reported that 19% of 275 cases of orbital cellulitis reported in the studies from 1907-1930 died mostly due to the intracranial complications of orbital cellulitis. [2] More recently, Hartstein et al, [51], reported case-studies of 3 patients who were found to have pansinusitis which progressed to subperiosteal abscess of the orbit and

subsequent intracranial extension. All 3 patients had been treated with systemic antibiotics and surgical drainage of the orbital abscesses as well as sinuses. Two of the 3 patients required surgical drainage of their intracranial abscesses.

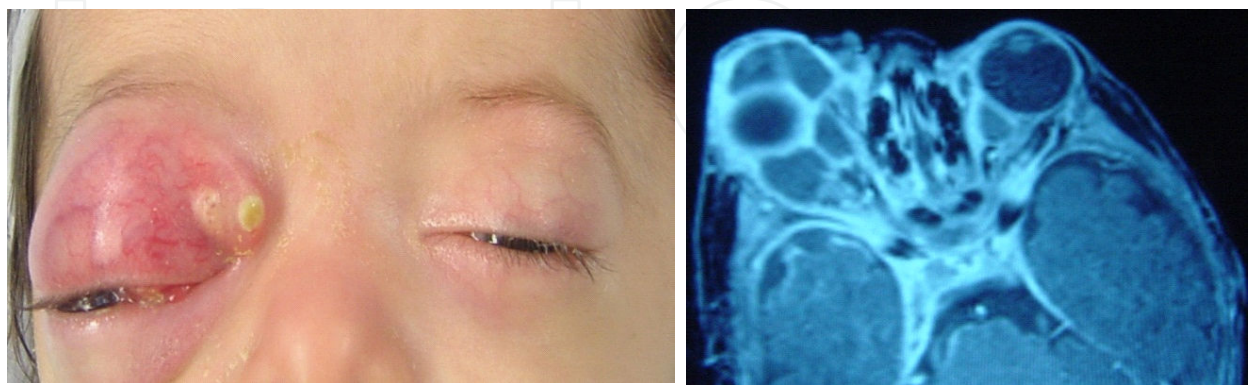
In our series of 218 patients with orbital cellulitis, there were 9 cases of intracranial extension of orbital abscesses that required either extended treatment with systemic antibiotics alone or in combination with neurosurgical intervention. [8] Nineteen cases of intracranial abscesses due to mid-face infection had been reported by Maniglia et al, [7] anaerobic organisms were the most common cause of their abscesses. Most of these intracranial complications were due to the nasal, sinus and orbital disease while cavernous sinus thrombosis occurred in only one of these patients. Intracranial abscesses were mostly located in frontal lobe, epidural or subdural. Handler et al [52], recommend surgical drainage for those with deterioration of ocular motility and vision. Ethmoidal sinusitis was overwhelming predisposing cause in their study of orbital cellulitis and intracranial spread occurred in 6 of their 65 patients with orbital cellulitis. Sinus infections appear to be more common cause of intracranial abscess, the most common being frontal sinus, followed by ethmoid and maxillary sinuses. While the superior ophthalmic vein drains into the cavernous sinus, the inferior ophthalmic vein may drain either into the cavernous sinus through the superior orbital fissure or into the pterigoid plexus through the inferior orbital fissure (Figure 13). [15]

In the past, intracranial abscess formation had a poor prognosis with a significant mortality rate. The valveless veins interconnect the orbit with sinuses, eyelids and the cavernous sinus, (Figure 13). Since intracranial abscess may be a life-threatening complication of orbital processes, it may require aggressive intervention by multidisciplinary team. Undesirable complications of intracranial abscess may result from cavernous sinus thrombosis as well as intracranial rupture of the abscess. Patient with intracranial abscess may be asymptomatic or present with nausea, vomiting, seizures and change of their mental status. [27] Among other signs, neurological signs of intracranial abscess may include fever or altered mental status. The classic neurological presentation of intracranial abscess seen in adults may be typical, while in children these symptoms may be minimal or even absent, (Figure 14). [27] Cavernous sinus thrombosis may represent the most severe form of orbital cellulitis. The condition may be suspected clinically by the presence of bilateral orbital process along with ophthalmoplegia and loss of vision. [53], [54] Repeat imaging studies may be necessary when there is evidence of neurologic deficit, to rule out presence of epidural or subdural empyema, brain abscess, or cavernous sinus thrombosis. [55]- [57] In such cases, successful management of orbital and/or intracranial abscesses may require timely recognition of the infectious process, administration of systemic antibiotics, serial head and orbital imaging studies, early surgical management of orbit disease and often the intracranial process, (Figure 14). Computed tomography scan of the orbit and sinuses with fine cuts is the recommended imaging study of choice. [8], [51], [57] Magnetic resonance imaging studies with fat suppression has been found to be useful for visualizing the intracranial abscesses in suspected cases. The cause of most of the intracranial infectious complications of sinusitis are polymicrobial organisms, with anaerobes being the most common pathogens. [38], [51]- [54] Although no specific species or combination of bacterial microorganisms is

found to be predominant; *Streptococcus*, *Staphylococcus*, *Bacteriodes*, and *Fusobacterium* species are frequently encountered. Hartstein et al. reported 3 cases of intracranial abscess all of which had evidence of polymicrobial infection with no predominance of any one particular organism. [51] Initial treatment of such patients requires broad-spectrum antibiotics including beta-lactamase resistant antibiotics that have good anaerobic coverage, as well as good central nervous system penetration. [20], [23], [27], [51] Routine follow-up imaging studies may be indicated based on the clinical examination. Proper management of these patients may require a multidisciplinary team that includes an orbital surgeon, otolaryngologists, neurosurgeon, and an infectious disease specialist.



**Figure 13.** Lateral view of the schematic drawing showing extensive venous drainage of the facial structures along with orbital veins and their direct connections with cavernous sinus.



**Figure 14.** External photograph and MRI (axial view) of the orbits and brain of an infant with bilateral orbital cellulitis/abscesses and its extension to the brain requiring broad-spectrum systemic antibiotics along with drainage of right orbital abscess.



## Author details

Intiaz A. Chaudhry<sup>1</sup>, Waleed Al-Rashed<sup>2</sup>, Osama Al-Sheikh<sup>3</sup> and Yonca O. Arat<sup>4</sup>

<sup>1</sup> Houston Oculoplastics Associates, Memorial Herman Medical Plaza, Texas Medical Center, Houston, Texas, USA

<sup>2</sup> Al Imam Mohammad Ibn Saud Islamic University, Faculty of Medicine, Riyadh, Saudi Arabia, Saudi Arabia

<sup>3</sup> Oculoplastic and Orbit Division, King Khaled Eye Specialist Hospital, Riyadh, Saudi Arabia

<sup>4</sup> Department of Ophthalmology, University of Wisconsin-Madison, Wisconsin, USA

## References

- [1] Ferguson MP, McNab AA. Current treatment and outcome in orbital cellulitis. *Aust N.Z. J Ophthalmol.* 1999; 27: 375-9.
- [2] Duke-Elder S, MacFaul PA. The ocular adnexa: part 2. Lacrimal orbital and para orbital diseases. In: Duke-Elder S, ed. *System of Ophthalmology*. Vol. 13. London: Henry Kimpton; 1974:859–89.
- [3] Connel B, Kamal Z, McNab AA. Fulminant orbital cellulitis with complete loss of vision. *Clin Exp Ophthalmol* 2001; 29: 260-1.
- [4] Meara DJ. Sinonasal disease and orbital cellulitis in children. *Oral Maxillofac Surg Clin North Am.* 2012;24:487-96.
- [5] Bedwell J, Bauman NM. Management of pediatric orbital cellulitis and abscess. *Curr Opin Otolaryngol Head Neck Surg.* 2011;19:467-73.
- [6] Chandler JR, Langenbrunner DJ, Stevens ER. The pathogenesis of orbital complications in acute sinusitis. *Laryngoscope.* 1970;80:1414 –28.
- [7] Maniglia AJ, Goodwin WJ, Arnold JE, Gonz E. Intracranial abscess secondary to nasal, sinus and orbital infections in adults and children. *Arch Otolaryngol Head Neck Surg* 1989; 115: 1424-9.
- [8] Chaudhry IA, Shamsi FA, Elzaridi E, Al-Rashed W. Al-Amri AM, Al-Anezi F, Arat YO, Holck DEE. Outcome of treated orbital cellulitis from a tertiary eye care center in the Middle East. *Ophthalmology* 2007;114:345-54.

- [9] Chaudhry IA, Shamsi FA, Elzaridi E, Al-Rashed W, Al-Amri A, Arat YO. Inpatient preseptal cellulitis: experience from a tertiary eye care centre Br. J. Ophthalmol. 2008;92;1337-41.
- [10] Jarrett WH, Gutman FA. Ocular complications of infection in the paranasal sinuses. Arch Ophthalmol, 1969; 81: 683-8.
- [11] Fezza J, Chaudhry IA, Kwon YH, Grannum E, Sinard J, Wolfley DE. Orbital melanoma presenting as orbital cellulitis: A clinicopathologic report. Ophthal Plast Reconstr Surg 1998;14:286-9.
- [12] Chaudhry IA, Shamsi FA, Morales J. Orbital cellulitis following implantation of aqueous drainage devices for glaucoma. Eur J Ophthalmol, 2007;17:136-140.
- [13] Chaudhry IA. Herpes Zoster Presenting with Orbital Cellulitis, Proptosis, and Ophthalmoplegia Middle East J Ophthalmol. 2006;13:167-9.
- [14] Krouschabel EF. Orbital apex syndrome due to sinus infection. The Laryngoscope, 1974; 84: 353-71.
- [15] Hornblass A, Herschorn BJ, Stern K, Grimes C. Orbital abscess. Surv Ophthalmol. 1984; 29: 169-78.
- [16] Hauser, A and Fogarasi, S. Periorbital and Orbital Cellulitis. Pediatrics in Review. 2010;31:242-9.
- [17] Seltz LB, Smith J, Durairaj VD, Enzenauer R, Todd J. Microbiology and antibiotic management of orbital cellulitis. Pediatrics. 2011;127:566-72.
- [18] Morgan PR, Morrison WV. Complications of frontal and ethmoid sinusitis. The Laryngoscope, 1980; 90: 661-6.
- [19] Fearon B, Edmonds B, Bird R. Orbital-facial complication of sinusitis in children. The Laryngoscope, 1979; 86: 947-53.
- [20] Harris GJ. Subperiosteal abscess of the orbit: age as a factor in the bacteriology and response to treatment. Ophthalmology, 1994; 101: 585-95.
- [21] Coşkun M, İlhan Ö, Keskin U, Ayıntap E, Tuzcu E, Semiz H, Öksüz H. Central retinal artery occlusion secondary to orbital cellulitis and abscess following dacryocystitis. Eur J Ophthalmol. 2011;21:649-52.
- [22] Harris GJ. Subperiosteal abscess of the orbit: computed tomography and the clinical course. Ophth Plast Reconstr Surg. 1996; 12: 1-8.
- [23] Garcia GJ, Harris GJ. Criteria from nonsurgical management of subperiosteal abscess of the orbit: analysis of outcomes 1988-1998. Ophthalmology 2000; 107: 1454-8.
- [24] Harris GJ. Subperiosteal abscess of the orbit: older children and adults require aggressive treatment: Editorial. Ophth Plast Reconstr Surg. 2001; 17: 395-7.

- [25] Schramm VL, Myres EN, Kennerdell JS. Orbital complications of acute sinusitis: Evaluation, management and outcome. *ORL Digest*. 1979; 86: 221-30.
- [26] Patt BS, Manning SC. Blindness resulting from orbital complications of sinusitis. *Otolaryngol. Head Neck Surg* 1991; 104: 789-95.
- [27] Chaudhry IA, Al-Rashed W, Arat YO. The hot orbit: Orbital cellulitis. *Middle East Afr J Ophthalmol* 2012;19:34-42.
- [28] Gellady AM, Shulman ST, Ayoub EM. Periorbital and orbital cellulitis in Children. *Pediatrics*, 1978; 61: 272-7.
- [29] Watters EC, Waller PH. Acute orbital cellulitis. *Arch Ophthalmol* 1976; 94: 785.
- [30] Weiss A, Friendly D, Eglin K. Bacterial periorbital and orbital cellulitis in childhood. *Ophthalmology*, 1983; 90: 195-204.
- [31] Welsh LW, Welsh JJ. Orbital complications of sinus disease. *The Laryngoscope*, 1974; 84: 848-56.
- [32] Giletto JB, Scherr SA, Mikaelian DO. Orbital complications of acute sinusitis in children. *Trans Pa Acad Ophthalmol Otolaryngol*, 1980; 34: 60.
- [33] Smith AT, Spencer JT. Orbital complications resulting from lesions of sinuses, *Ann Otolaryngol, Rhinology, and Laryngology*, 1948; 57: 5.
- [34] Langham – Brown JJ, Rhys-Williams S. Computed tomography of acute orbital infection: the importance of coronal sections. *Clin Radiol*. 1989; 40: 471-4.
- [35] Hilal SK. Computed tomography of the orbit. *Ophthalmology*, 1979; 86: 864-9.
- [36] Bagheri A, Tavakoli M, Aletaha M, Salour H, Ghaderpanah M. Orbital and preseptal cellulitis: a 10-year survey of hospitalized patients in a tertiary eye hospital in Iran. *Int Ophthalmol*. 2012;32:361-7.
- [37] Donahue SP, Schwartz G. Preseptal and orbital cellulitis in childhood: A changing microbiologic spectrum. *Ophthalmology*, 1998; 105: 585-95.
- [38] Mathias MT, Horsley MB, Mawn LA, Laquis SJ, Cahill KV, Foster J, Amato MM, Durairaj VD. Atypical presentations of orbital cellulitis caused by methicillin-resistant *Staphylococcus aureus*. *Ophthalmology*. 2012;119:1238-43.
- [39] Kobayashi D, Givner LB, Yeatts RP, Anthony EY, Shetty AK. Infantile orbital cellulitis secondary to community-associated methicillin-resistant *Staphylococcus aureus*. *J AAPOS*. 2011;15:208-10.
- [40] Emmett Hurley P, Harris GJ. Subperiosteal abscess of the orbit: duration of intravenous antibiotic therapy in nonsurgical cases. *Ophthal Plast Reconstr Surg*. 2012;28:22-6.



- [41] Todman MS, Enzer YR. Medical management versus surgical intervention of pediatric orbital cellulitis: the importance of subperiosteal abscess volume as a new criterion. *Ophthal Plast Reconstr Surg*. 2011;27:255-9.
- [42] Gavriel H, Yeheskeli E, Aviram E, Yehoshua L, Eviatar E. Dimension of subperiosteal orbital abscess as an indication for surgical management in children. *Otolaryngol Head Neck Surg*. 2011;145:823-7.
- [43] Bhargava D, Saukhla D, Ganesan A, Chand P. Endoscopic sinus surgery for orbital subperiosteal abscess secondary to sinusitis. *Rhinology* 2001; 39: 151-5.
- [44] Ingraham HJ, Ryan ME, Burns JT. Streptococcal preseptal cellulitis complicated by the toxic streptococcus syndrome. *Ophthalmology* 1994; 102: 1223-6.
- [45] Shayegani A, MacFarlane D, Kazim M. Streptococcal gangrene of the eyelids and orbit. *Am J Ophthalmol* 1995; 120: 784-92.
- [46] Marshall DH, Jordan DR, Gilberg SM. Periocular necrotizing fasciitis: a review of five cases. *Ophthalmology* 1996; 104: 1857-62.
- [47] Meyer MA. Streptococcal toxic shock syndrome complicating preseptal cellulitis. *Am J Ophthalmol* 1996; 123: 841-3.
- [48] Slavin ML, Glaser J. Acute severe irreversible visual loss with sphenothmoiditis - 'posterior' orbital cellulitis. *Arch Ophthalmol*. 1987; 105: 345-8.
- [49] El-Sayed Y, Al-Muhaimeid H. Acute visual loss in association with sinusitis. *J Laryng Otol*. 1993; 107:840-2.
- [50] Borruat FX, Bogousslavsky J, Uffer S, Klainguti G, Schatz NJ. Orbital infarction syndrome. *Ophthalmology*, 1993; 100:562-8.
- [51] Hartstein ME, Steinvurzel MD, Choen CP. Intracranial abscess as a complication of subperiosteal abscess of the orbit. *Ophth plast Reconstr Surg*. 2001; 17: 398-403.
- [52] Handler LC, Davey IC, Hill JC, Lauryssen C. The acute orbit: differentiation of orbital cellulitis from subperiosteal abscess by computerized tomography. *Neuroradiology*, 1991; 33: 15-18.
- [53] Giannoni CM, Stewart MG, Alford EL. Intracranial complications of sinusitis. *Laryngoscope* 1997; 107: 863-7.
- [54] Brook I. Bacteriology of intracranial abscess in children. *J Neurosurg* 1981; 54: 484-8.
- [55] Weber AL, Mikuli D. Inflammatory disorders of the periorbital sinuses and their complications. *Radiol Clin North Am* 1987; 25: 615-30.
- [56] Towbin R, Han B, Kaufmann R, Burke M. Postseptal cellulitis: CT in diagnosis and management. *Radiology* 1986; 158: 735-7.

- [57] Harr DL, Quencer RM, Abrams GW. Computed tomography and ultrasound in the evaluation of orbital infection and pseudotumor. *Radiology* 1982; 152: 395.
- [58] Brook I, Frazier EH. Microbiology of subperiosteal orbital abscess and associated maxillary sinusitis. *Laryngoscope* 1996; 106: 1010-3.

IntechOpen

IntechOpen