

We are IntechOpen, the world's leading publisher of Open Access books Built by scientists, for scientists

6,900

Open access books available

186,000

International authors and editors

200M

Downloads

Our authors are among the

154

Countries delivered to

TOP 1%

most cited scientists

12.2%

Contributors from top 500 universities



WEB OF SCIENCE™

Selection of our books indexed in the Book Citation Index
in Web of Science™ Core Collection (BKCI)

Interested in publishing with us?
Contact book.department@intechopen.com

Numbers displayed above are based on latest data collected.
For more information visit www.intechopen.com



Endoscopy of Larynx and Trachea with Rigid Laryngo-Tracheoscopes Under Superimposed High-Frequency Jet Ventilation (SHFJV)

Alexander Aloy and Matthaeus Grasl

Additional information is available at the end of the chapter

<http://dx.doi.org/10.5772/52996>

1. Introduction

1.1. History (an overview)

1.1.1. Indirect laryngoscopy

Knowing that almost all laryngeal and tracheal diseases are visible at the surface of the mucous membranes it is of particular interest to visualize these structures.

Endoscopic examinations of the larynx and the trachea are essential in the otorhinolaryngological field and had their beginning over 200 years ago. Before the 1800's only autopsy specimen could clarify laryngotracheal diseases.

In 1807 the physician Phillip Bozzini (Germany) reported about a speculum called “the light conductor, or a simple apparatus for the illumination of the internal cavities and spaces in the living animal body” [1].

In 1816 Ludwig Mende (Germany), a gynaecologist & obstetrician and forensic doctor examined first the inner part of the larynx at a living human being. He looked at a larynx of a suicidal person, who had cut through the soft tissue of the supraglottic area [2].

In 1827 L. Senn (Switzerland) successfully examined the larynx of a child with a small mirror, cited in [3].

In 1829 Benjamin Guy Babington (Great Britain) developed a larynx-mirror “glottoscope” and could illuminate the upper parts of the larynx. The instrument combined an epiglottic retractor with a laryngeal mirror. He presented it in the Hunterian Society of London [4].

In 1854 the Spanish singer, voice teacher and scientist Manuel García, living in London, succeeded in performing the auto-laryngoscopy. He first visualized his own larynx, using a dental mirror and a second hand-held mirror to reflect sunlight. Garcia tranfered the method to patients (Figure 1) and could analyse directly the phonation. He presented his invention to the Royal Society in 1855 [5]. The importance of this technique was unrealised first. But in 1862 he was granted an honour of medical degree followed by many international distinctions.

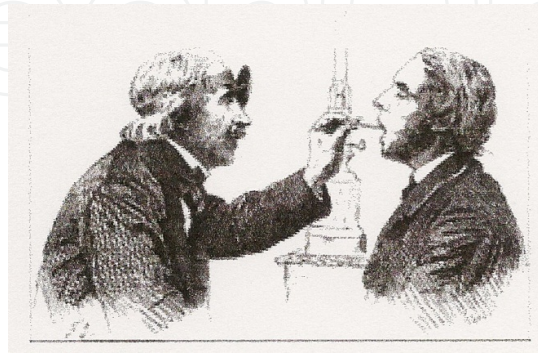


Figure 1. Manuele Garcia`s laryngoscopy.

In 1857 Ludwig Türk, a neurologist and professor of laryngology in Vienna (Austria), unsuccessfully tried Garcia`s mirror under the use of the ophthalmoscope [6] which was invented by Hermann v. Helmholtz (Germany), a physiologist and physicist in 1851[7].

Johann Nepomuk Czermak, professor of physiology at the University of Pest (Hungary) assumed Türk`s mirror, completed this procedure using light-concentration by a concave head mirror (Figure 2), and presented it 1858 the Viennese medical community [8].




Figure 2. Johann Nepomuk Czermak performing the indirect laryngoscopy using natural lighting.

This method propagated rapidly and is still in use, but with electric light source.

In 1878 Max Joseph Oertel (Germany) describes his invention: the laryngo-stroboscopy via a perforated disc. But the feasibility of this apparatus was not implemented until 1895 when the electricity has been installed [9].

Important milestones for the investigation and treatment of laryngeal diseases were the beginnings of the anaesthesia 1846 using ether by William Morton (USA) [10] and the introduction of antiseptics by Joseph Lister (Scotland) who performed first 1867 surgery under antiseptic conditions [11]. A fundamental progress was the introduction of the cocaine as an anaesthetic and analgetic agent in 1884 by the laryngologist Edmund Jelinek (Austria) [12].

1.1.2. Direct laryngoscopy

The direct inspection of the larynx is essential in cases of endotracheal intubation and can be performed by spatulate instruments like the straight Miller-spatulate (Robert A. Miller 1941, USA), especially for children [13] or the slightly arcuated Macintosh-spatulate (Robert R. Macintosh, 1943, Great Britain) [14].

But this is not the topic of this historical overview.

The real interest consists in tube-shaped instruments with lighting for direct inspection of the larynx, which is only practicable under anaesthesia or deep sedation.

The first laryngologist who directly visualized the larynx using a tongue depressor and a mirror for illumination was Albert von Tobold (Germany) in 1864. He removed with this method laryngeal papilloma [15].

In 1895 the laryngologist Alfred Kirstein (Germany) first described direct inspection of the vocal cords. He had modified an oesophagoscope for this purpose and called this device an autoscope (electroscope) [16].

In 1897 Gustav Killian a laryngologist (Germany) removed at first with success via a rigid bronchoscope a bronchial foreign body. It was a piece of bone in the right main bronchus [17]. This practical invention was affiliated in professional circles with enthusiasm because the dramatical death rate of 50 percent in case of tracheobronchial foreign bodies could be minimized continuously. This technique persisted for almost 70 years as the standard diagnosis and therapeutic procedure for bronchopulmonary diseases.

In 1910 Gustav Killian constructed a special laryngoscope, not a tube but a spatula, with a mouth gag (hypopharynx was clearly visible) that could be fixed to a supporting construction by a hook, the „suspension-laryngoscopy“ (Figure 3). The inspection of the larynx was easier by the hanging position of the head and laryngotracheal surgery could be done with both hands [18].

Wilhelm Brünings 1910 [19] and Arthur Hartmann 1911 [20] (both Germany) improved Kirstein's electroscope with proximal electric lighting at the handgrip.

Paul H. Holinger 1947 (USA) created a laryngoscope using an U-shaped handgrip and had a better view to the anterior commissure [21].

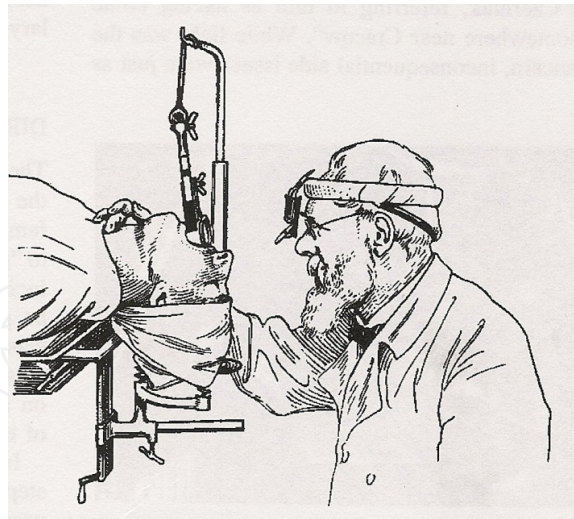


Figure 3. Gustav Killian performing a suspension laryngoscopy. The patient's head is suspended by attaching the laryngoscope to the "gallows".

1961 Oskar Kleinsasser (Germany) published [22] his development of a new instrument for magnified endolaryngeal observation and photography. He used a chest holder. A combination of a wide-angle telescope and a telephoto lens guaranteed excellent depth of field for still and motion photography.

In 1970 Geza J. Jako (USA) referred about his development of a laryngoscope, a modified Holinger-Yankauer tube with an ellipsoidal proximal and a round distal aperture. It is made of stainless steel with the inside surface matt to decrease glare. On each side of the instrument there is a built-in tube for the insertion of fiberoptic light pipes. The laryngoscope with a special holder is suspended on an instrument table over the patient's chest and was developed for laser surgery in the larynx [23].

1970 M. Stuart Strong (USA) coupled the carbon dioxide laser to the surgical microscope. The laser provides precise cutting and also haemostasis of small vessels and is manipulated with a joystick and a foot-pedal [24].

In 1979 Hilko Weerda et al. (Germany) designed an expandable laryngoscope which derived from the Kleinsasser-tube and the Killian-Lynch-suspension laryngoscope consisting of an upper and lower blade. Their distance and angle of twist are variable [25].

The rigid laryngotracheal endoscopy made a qualitative leap with the introduction of the Hopkins-fibreglass-optics with their unachievable splendour and precision with endoscopic resolutions which allow a hundredfold magnification when used additionally. Prof. Harald H Hopkins (Great Britain) developed it in the 1960s with Karl Storz Ltd. Company with limited liability (Germany) [26].

1.1.3. Jet ventilation

First attempts to sustain the pulmonary gas exchange without periodical alterations of gas volumes were done by Franz Volhard in an animal experiment with dogs in 1908 [27]. He

performed an “artificial respiration” by leading in oxygen with a very low flow via a trans-laryngeal tracheal tube which did not fill out the diameter of the trachea.

This method indeed enabled sufficient oxygenation but hypercapnia occurred rapidly.

In 1909 Samuel J. Meltzer et al. (USA) enhanced Volhard's method by applying the oxygen with high velocity and named it “diffusion respiration”. With this high insufflation flow partial elimination of carbon dioxide was practicable.

Clinical application was implemented at first in 1954 by Lothar Barth (Germany) and was used for bronchoscopies and for bridging short apnoea phases over a period of lung resections [29]. Because of insufficient elimination of carbon dioxide it could be applied only 15 -20 minutes. Therefore a broad distribution did not take place.

In 1967 R. Douglas Sanders developed a method enabling a continuous ventilation during bronchoscopy [30]. Two cannulas are placed into the endoscope and 15 to 20 breathing gas portions are applied periodically during the inspiration phase. Because of the injector effects the primarily very small-sized tidal volumes receive an enhancement. The Venturi effect additionally entrains air through the open proximal end of the endoscope and both result in a sufficient pressure and flow at the end of the endoscope for inflating the lungs. Subsequently gas exchange occurs comparable to conventional breaths (Figure 4). This method simplified general anaesthesia for bronchoscopy and is still in use in surgery of the thorax, published by E. Gebert et al. [31] and Shaotsu Thomas Lee [32].

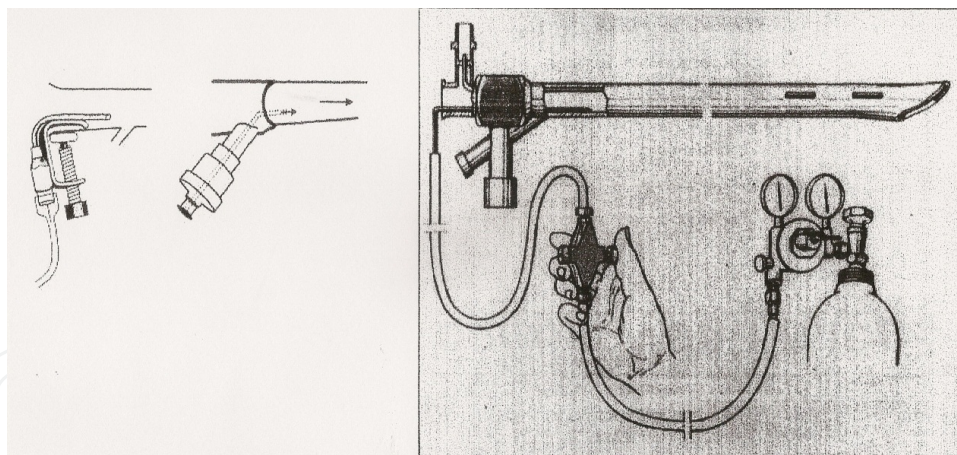


Figure 4. The injector apparatus of R. Douglas Sanders.

In 1971 Jane L. Bradley et al. (Great Britain) described improvements of Sanders' pulmonary ventilation for bronchoscopy. She fixed the proximal injector needle at the bronchoscope and the distal needle became an integral part of the bronchoscope, oxygen feeding was assured and interruption of the oxygen flow was regulated electronically [33].

In 1972 Paul Peter Lunkenheimer et al. succeeded a further advancement by oscillating the gas mixture, which was insufflated into the airways. A membrane vibration generator placed at the proximal end of the bronchoscope enabled it. Such oscillations of the breathing gas with

frequencies from 1200 to 6000 per minute led in a satisfactory manner to a gas exchange with widely minimisation of intrathoracic pressure fluctuations [34]. An additional integrated carbon dioxide absorber increased elimination of carbon dioxide [35].

In 1980 Demond J. Bohn et al. published at first a successfully ventilation with this technique in an animal experiment [36]. With a piston pump sinuoidal vibrations with a frequency from 900 to 1500 per minute were tranfered to the breathing gas, elimination of the carbon dioxide is carried out by a cross-flow of fresh mixture. At this way of high frequency oxygenation a superposition of spontaneous breathing is not feasible.

In 1977 and 1980 Ulf H. Sjöstrand (Sweden) published about his invention of high-frequency positive pressure ventilation. He modified a conventional lung ventilator by the application of special valve configuration and could reduce the compressible gas volume. Tidal volumes from 200 to 300 ml with a frequency of 60 to 80 per minute were applicable [37, 38].

Miroslav M. Klain et al. (USA) developed 1976 the high-frequency ventilation. A high pressure jet is conditioned into small-sized single gas quantities by an assessable valve and then applicated via a catheter with a low inner diameter. The breathing gas quantities leave the catheter as a clocked high frequency jet. This jet activates a suction mechanism (entrainment) and the tidal volume is augmented. In a frequency range of 100 to 200 per minute a sufficient gas exchange can be perpetuated in a completely open system towards the atmosphere [39-41].

This high frequency jet ventilation is the initial point of all following developments.

In particular Alexander Aloy and colleagues are engaged practically and scientifically since 1990 over more than twenty years in this field of ventilation [42].

His and contemporarely applicatioins and publications are presented in the next following parts of this chapter.

2. Microlaryngoscopy and endolaryngeal microsurgery

Direct laryngoscopy via the transoral route allows the immediate entry to the inner laryngeal and tracheal structures and has now an extreme importance for the special field of laryngological diagnoses and surgical treatments in the otorhinolaryngologic discipline.

A laryngoscope holder is adhered to the chest selfholding by a mount as a suspension similar to a gallow.

The binocular vision and bi-manual manipualtion via the forward spaced microscopy facilitates detailed diagnoses and treatment at the vocal cords and circumjacent areas [43-45].

2.1. Indications

Microlaryngocopy is particulary helpful in the need of diagnosis and treatment of the vocal chords or surrounding areas, which are first seen by indirect laryngoscopy. The microlaryngoscopy for staging and excision biopsy of tumours is part of a panendoscopy of the upper

aerodigestive tract. Absolute indications are the strong suspicion of precancerous or cancerous epithelial diseases as well as constricting processes. But also benign lesions like polyps, cysts and oedemas have to be operated soon, because it is often found that the opposite vocal chord reacts with a dent, oedema or epithelial thickening. These secondary alterations prolongate healing. Inflammatory epithelial reactions are to be treated with inhalations before in few hard going cases operation is done. Rigid laryngoscopy is a domain for the elimination of foreign bodies in larynx and trachea as well as the surgical treatment of laryngeal or glottic webs. Laryngotracheal injuries and the placement respectively the removal of laryngotracheal endoprosthesis, medialization of vocal chords after palsy of an inferior laryngeal nerve by relining and surgical widening of the glottis are further areas of application of laryngotracheoscopy.

2.2. Contraindications

Special endangering of patients life by anaesthesia when medical conditions such as apoplectic stroke, heart infarction, aneurysm, severe cardiadic arrhythmias, aggravated pulmonary, liver and renal diseases are contraindication for general anaesthesia and consecutively for micro-laryngoscopy. Unfrequent contraindications are severe malformations of the jaws, cervical spine diseases like Morbus Bechterew and local spasticity [43].

2.3. Description of the instruments

The design of the instrumental equipment represents the association of the representational problems and their solution. The present instrumentation indicates the requirement on average in the German-speaking language room and is to be adapted individually for particular purposes:

2.3.1. Laryngoscope

The mostly used laryngoscope tube at our institution, the Department of Otorhinolaryngology of the Medical University, is that of Kleinsasser with a length of 80 to 200 mm and a distal diameter of 8 -16 mm (Figure 5). The medium-sized closed coverage type for adults is used predominantly in the endolarynx. An overlong small-bore universal applicable laryngoscope is used in children and adults with difficult adjustable areas of the endolarynx - especially the anterior commissure, the interary and subglottic region. The proximal end of the tube is differently shaped in dependency to the size for adults and children. The side of the tubes turned to the teeth is flat for spreading the pressure to the teeth as uniform as possible. At both sides of the proximal end mounting parts are placed to fix the cold light rod either at the left or right side [43].

The spatulated laryngoscope of Weerda et al. [46] has an upper and lower blade which is inserted in a closed position and once inside the larynx the distance and angle of twist of the blades is variable. This instrument has adapters for suction and jet stream ventilation and is suitable in particular for the root of the tongue, the vallecula, supraglottis and hypopharynx.



Figure 5. The Kleinsasser laryngoscope already adapted for jet ventilation (see also part 3 of this chapter).

When laser is used the tubes and spatulas are adapted according to the needs. The inner surface coating should be non-reflecting, opal or black. On the lateral outside cannulas for suction of smoke are mounted.

2.3.2. Laryngoscope holder

The laryngoscope holder is either placed on patient's chest with a broad rubber ring or it is put on a robust instrument table [43, 47] respectively a holding bow [48] just over his chest to avoid pressure on the anaesthetized chest and to minimize movement of the instrument.

2.3.3. Example for a configuration of a microscope combining modern visualization technologies with a user friendly platform

1. Light source:

- 2 x 300 W xenon,
- automatic iris control for adjusting the illumination to the field of view,
- individual light threshold setting,
- focus light link: working distance controlled light intensity,
- display of remaining lamp life time.

2. Microscope:

- free to move at a tripod or as a ceiling mounted,
- motorized focus,
- working distance 200-500 mm,
- motorized zoom 1:6 zoom ratio,
- 10 x magnetic widefield eyepieces with integrated eyecups,

- autofocus with 2 visible laser dots - automatic mode with magnetic brakes,
- binocular observer ocular,
- multifunctional programmable handgrips,
- magnetic clutches for all system axes,
- central user interface,
- XY robotic movement in 3 axes (variable speed),
- system setup: autobalance,
- navigation interface,
- interface for micromanipulator,
- intraoperative fluorescence,
- laseradapter.

3. Video, photography, Television for documentation and teaching:

- HD video touchscreen on extended arm,
- integrated video still image capturing on HDD and USB-media,
- integrated HD video camera,
- integrated SD or HD video recording and editing,
- adaptation of consumer (SLR) photo/video camera,
- video-in for external SD video sources,
- patients data transfer from/to PACS.

2.3.4 Instruments

Instruments are small at the tip, thin, long (25 cm) and flexible.

All instruments should be manipulated freehanded, which is easily trainable and backing of the arms becomes dispensable. The set of microsurgical instruments should be kept in a basic amount. It includes double-spoon forceps, scissors: straight, laterally and upwards arcuated, acutenaculum, sickle and peeling knives, suction tubes and coagulation probes.

Instruments for laser microlaryngological surgery are of nonreflecting surface. Protectors are necessary for the subglottic area when tubeless ventilation is applicated. Additional when the vocal chords are treated the false cords and also the contralateral intact side is to be moved sideways.

2.4. Beginning and protection activities

The often “poor risk” patients need preoperatively a careful investigation and treatment to make them capable for anaesthesia. Dental record is essential before insertion of the laryngo-

scope. When indicated patients have to go for remediation preoperatively. Dental impression trays equally spread the pressure of the laryngoscope at the teeth of the upper jaw and can bridge a dental gap.

Patients lie in dorsal position on the operating table and the correct posture of the head is the dorsal flexion in flat bedding. Using adequate laryngoscope types it enables even in patients with a thick and short neck to adjust the larynx. If there are anamnestic indications concerning pathologies at the cervicale spin an orthopaedic specialist has to decide if the head position during laryngoscopy will be tolerated well.

In case of laser application all persons in the operating room have to wear special glasses. When CO₂ laser is in use eyeglass lenses are sufficient. Patients face and eyes are to be protected by a humid green woven fabric. The doors to the operating room where laser is used must be signalized.

2.5. Anaesthesia and ventilation during micro laryngotracheoscopy (basic considerations)

Please see the next part of this chapter.

2.6. Insertion of the laryngoscope

First of all a teeth protector for the lower and upper jaw is placed in position. The insertion of the laryngoscope should be performed not until the patient is full relaxed and in sufficient depth of narcosis. The laryngoscope should be as large as possible enabling best lighting and overview of the larynx. In cases of preexisting laryngotracheal intubation the ventilation tube is moved by two fingers to the left side and the laryngoscope is inserted from the right side under the illumination of a cold light which is piped inside of the tube to the distal end. The tongue should not be pinched between the teeth and the laryngoscope at the same time. The epiglottis is loaded up by the laryngoscope. If the laryngeal skeleton is to be pressed from outside to inward in cases of the need to expose the anterior commissure the laryngoscope should be inserted only into the area of the false cords. In cases of a small, weak or U-shaped epiglottis it can happen that the epiglottis is enrolled and the suprahoidal part is folded and compressed when the laryngoscope is inserted. Consecutively inspection of the anterior commissure is hindered and a postoperative oedema can occur. Solving of this problem is to clamp the epiglottis when inserting the laryngoscope. The laryngoscope is positioned few millimeters above the anterior commissure. The dorsal lying ventilation tube can be used as a guidance till the exposition of the false and vocal chords.

Next is to underpin the laryngoscope at the mobile laryngoscopy-table and to move it slowly upwards. When a distending laryngoscope is inserted at maximum aperture laterally between the spatulas parts of the tongue can be pinched and it protrudes into the lumen of the laryngoscope. This can be prevented by covering the closed distending-laryngoscope with a finger of a medical glove which is forming a lateral wall when the laryngoscope is opened [49].

2.7. Inspection of the larynx and the circumjacent areas

At the begin of the introduction of the laryngoscope the structures are inspected by looking with the naked eyes using the lighting inside the laryngoscope: base of the tongue, valleculae, epiglottis: lingual and laryngeal surface area and free margin, aryepiglottic fold, pharyngoepiglottic fold, the processus vocalis and tubercula cuneiformia respectively corniculata, the arytaenoid cartilage, the sinus piriformis bilateral, the posterior hypopharyngeal wall and postcricoid area. After fixation of the laryngoscope under the use of the microscope the false and vocal chord, the sinus Morgagni, the anterior and posterior commissure as well as the subglottic space and the upper parts of the trachea are to be seen under a magnification of up to 40.

2.8. Microlaryngoscopic diagnoses and surgical therapies

(most frequent clinical symptom is hoarseness)

2.8.1. Tumours

Diagnosis and therapy of precancerous lesions and carcinomas of the larynx, especially the vocal chords are still a central domain of laryngoscopy. Any unclear or suspicious epithelial alteration is to be extirpated and examined by histology. As followup exam after radiotherapy microlaryngoscopy is qualified in particular.

2.8.1.1. Precancerous lesions

Chronic hyperplastic laryngitis is an epithelial thickening of laryngeal mucous membrane affecting both vocal chords with a spread over their complete length. In this dermatoid epithelium often *leukoplakia* lies as milky area, slightly opacity of the surface or as verrucous, thick, white coating. A second group of cornification of the epithelium is the circumscript *keratosis* which is located nearly only at one vocal chord. The surface can be plain, tubercular, verrucous or papillary with all transitions. Histological differentiation of the keratosis is for all benign types is grade I, when few atypic cells are seen grade II and when a carcinoma in situ is diagnosed grade III. A carcinoma in situ becomes in a high rate an apparent carcinoma and is to be treated as such a malignant tumour. The human papilloma virus induced *solitary hyperkeratotic "adult" papilloma* has a high rate of recurrence after surgery and is to be distinguished from the "*juvenile*" *papilloma* which also occurs in adults but never turns to a malignization. Precancerous lesions are always movable over the muscle of the vocal chord without problems.

2.8.1.2. Squamous scell carcinomas

Carcinomas in situ and apparent carcinomas primarily originate bilateral from an enlarged area and are named wallpaper carcinomas respectively superficial spreading carcinomas. Additionally, not infrequently, multiple focuses of seperated carcinomas confluence later. Difficult relocatability, solid or swollen areas and superficial exulceration are important signs of deeper invasion. A relatively rare shape of growth is excessive polypus/exophytic like. Because of tumour infiltration the blood supply suffers and necroses occur. To identify the

superficial spread of the tumours it is additionally necessary to investigate the infraglottic area as well as the ventriculus Morgagni and the false chord via a 30 ° and 70° rigid fiberoptics.

A huge advantage of endolaryngeal microsurgery is the possibility to get biopsies from all locations without contusion. In cases of palliative tumour size reduction (“debulking”) laryngeal tumour masses can easily be reduced to avoid a tracheotomy. Small-sized tumours can be removed in one piece as an “excision biopsy”.

Clear guidelines applied for endoscopic resections of carcinomas include the selective and reluctant production of the indication by a laryngologist experienced in microlaryngologic diagnosis and surgery. Resection is only permitted when the complete tumour circumference over his borders is easily visible with the microscope. Otherwise an external approach is to be chosen allowing simultaneously reconstruction of the glottis. The careful histological investigation is a condition precedent in cases of microlaryngeal resection. When resection was not in healthy tissue an immediate revision surgery is necessary [43].

Laser surgery in the larynx demands special safety precautions, instruments, anaesthesiological procedures, experiences of the microsurgeon and knowledge of histopathological appraisal. Because bleeding is the most common complication of laser surgery of tumours of the upper aerodigestive tract every clinic performing this surgery should have a clear concept of managing it. When these conditions are respected even enlarged function receiving and organ saving operations in the larynx and hypopharynx with good oncological results are quite practicable [49].

2.8.2. Benign lesions

Polyps are only seen at the vocal chords predominantly at one side inserting at the anterior two third at the slope of the vocal chord. They have a diameter on average of 5 mm, bigger ones are floating in the glottic area. Petiolated pendulous polyps sustain longer, broad based polyps are juvenile and have a thin transparent epithelium (Figure 6). Polyps never degenerate into a carcinoma. If a polyp persists a longer period at the contralateral side contact reaction in shape of excavation, epithelial thickening or oedematous swelling occurs. This is not to be treated when the polyp is resected.

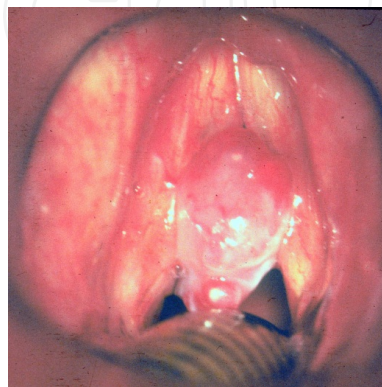


Figure 6. Large vocal chord polyp in the anterior part of the glottis.

Vocal chords nodules are seen exclusively in women with powerful voice formation. They present as a symmetric swelling of the epithelium of the vocal chords in typical localisation at the border between the first and second third. In up to 50 % the diagnosis of nodules by indirect laryngoscopy is wrong – microlaryngoscopy shows cysts or polyps. Morphodifferentiation compared to polyps is difficult but in any case they are no fibroepithelioma. Microlaryngeal resection and postoperative phoniatric training is indicated.

In hyperactive children vocal nodes impress as soft spindling swelling in the middle of both vocal chords. Operative resection is not necessary because by no longer than the puberty they involute spontaneously. Phoniatic therapy is useful. Laryngeal papillomas are to be excluded.

The *varix chordis* is found in patients with vocal oversteering at the surface or margin in the middle or posterior part of one vocal chord. Under microscopy one or various capillaries lead to a bloodblaster. Laser coagulation followed by vocal training is a promising therapy.

Laryngeal cysts are frequent and located typically at three areas:

1. *vocal chord cysts* are with about 50 % the most frequent and in most cases as one chamber at the subglottic slope of the anterior third of a vocal chord with a diameter of about 5 mm. Their inner lining is squamous epithelium. The content matter is a muddy aqueous-milky detritus. Under microscopy the subepithelial content glimmers yellowish. They are removed gentle under protection of the muscle layer.
2. *vestibular fold cysts* are found nearly exclusively in elderly patients. The first mode, originating from the minor salivary glands, presents with one chamber and is pedunculated at the roof of the ventriculus laryngis (Morgagni) with a prolapse into the glottis. They are neither a real prolapse nor an inner laryngocele and can be mutated oncocytoïd, which is a benign age-related metaplastic dyschylic transformation. They can be removed easily by cutting through the peduncle. The second mode is characterized by multiple chambers, often bilateral, inside the vestibular fold and metaplastic transformed epithelium. The excision is hindered by the deep location and the botryoid extension, which promotes relapses.
3. *epiglottic cysts* are located always at the same position, deep in the vallecula epiglottica slightly paramedian at the lingual surface of the epiglottis. In ten percent they occur multiple, only the bigger one cause dysphagia and have to be operated. This can be complicated by prominent venes. The inner layer of the wall of the cysts is squamous epithelium enclosing a milky pale yellow fluid. The complete sac of the cyst is to be removed.

The *Reinke-oedema* or *polypoid chorditis* is a frequent disease mostly in heavy smokers. The extension ranges from marginal spindle shaped swelling to bulky floating bulges with stridor. In most cases both vocal chords are involved, but asymmetrically. With longer persistence of the Reinke-oedema the epithelium keratinizes. Patients develop a compensatory phonation by the vestibular folds which are to be reversed by postoperative voice therapy. Surgery begins with plain and clean cutted margins at the tip of the processus vocalis of the arytaenoid cartilage where the oedema is pronounced. The anterior commissure is not involved and an

epithelial debridement there should be prevented to avoid synechias. The subepithelial mucous is to be sucked carefully.

Chronical hyperplastic laryngitis is predominantly seen in 90 percent in heavy smoking men. Additional working place associated noxious agents as heat, dust and noise-induced overuse of the voice are said to be at least co-factors. Microlaryngoscopic findings are typical. The thickening of the epithelium begins always at the anterior third of the vocal chords and spreads to the whole vocal chords and inner larynx. In advanced cases of expanse leucoplakia and a pathological secretion of a yellow viscous mucous adheres. Sometimes the disease progresses per acute exacerbation. Signs of this procedure are slit shaped ulcers at the free margin of the vocal chords and crimson bulges of oedema at the border from squamous to cylindrical epithelium. Carcinoma can follow. Resection of nearly all hyperplastic area via microlaryngoscope is the symptomatic therapy of choice. It lasts about 4 to 8 weeks till re-epithelisation of a vocal chord is finished. In this period a stringent ban on smoking is to order.

Contact granuloma and *contact pachydermia* are two pathogenetic identical but independent diseases caused by vocal abuse and strike of the processus vocales against each other with following formation of granulation tissue. This can be connected with dysphagia, odynophagia, scratching, sensation of foreign body and haemoptysis. Sometimes granulomas are rejected spontaneously. In other cases the granuloma persists over months and years which are forming bilateral cranial and caudal from the processus vocalis lip-like bulges (in America the Jackson's "contact ulcer", which is not really an ulcer - there is no loss of substance) and dash against each other during phonation. All transitions to the typical dish-shaped epithelialized contact pachyderms are seen. Despite careful microsurgical resection and postoperative voice training local recurrences frequently arise.

Intubation granulomata are caused by too large sized larynotracheal tubes which excoriate the processus vocales almost one-sided (Figure 7). Depending on their growth they get a pendulated form and can be rejected and expectorated spontaneously. Recurrences after resection are seen not infrequently, additionally application of cortison should minimize them.

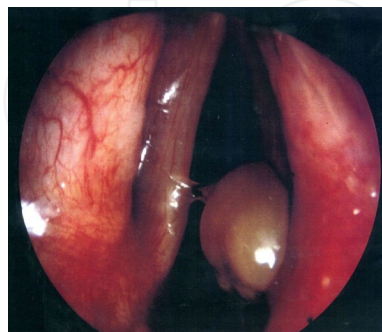


Figure 7. Intubation granuloma in the posterior third of the right vocal chord.

"Juvenile" *papillomata* are to be removed repeatedly because of their tendency of frequent recurrences: optionally by cold instruments, laser, ultrasound, cryocautery or electrocoagulation. Additional mitomycin is applied. It is of importance to work organ preserving. The

essential advantage nowadays is that the surgical procedure is performed endolaryngeal and therefore the affected children do not need a tracheostomy.

Haemangioma of the larynx are congenital and become symptomatic several months postpartum with the general growth. They are treated by laser resection and additional long-term application of cortisone and recently by propranolol alone.

The incidence of laryngeal *mycosis* is increasing caused by more patients with immunosuppressive therapy and AIDS. In Europe *Candida albicans* and aspergillosis as endomycosis are of clinical relevance. The affection of the larynx is predominantly secondary, the mucous membrane is discrete swollen and reddened, typical off-white coatings are seen only exceptionally and it looks like a chronic laryngitis. The basic concept of the diagnosis is still the microbiological demonstration of the pathogenic agent. Systemic antimycotic drugs are given.

Laryngeal *synechia* can be differentiated by location into anterior vocal chord ones, posterior interarytaenoid ones and false chord ones. Anterior synechia can be congenital and are very rare and then acquired more frequent as complication after microlaryngeal surgery. Resection of the narrowing and movement blocking scar tissue is difficult and recurrences many times arise. Cortisone and mitomycin is applied additionally. Subglottic annular stenosis "*pinhole aperture synechia*" are sequels of artificial ventilation and are resectable without the need of inserting a dilator. "*Cricoid stenosis*" caused by diminution of the cricoid cartilage are funnel-shaped and not to be treated endolaryngeal but resected by an external approach.

Unilateral pareses of the *inferior laryngeal nerve* are treated by a phoniatric training, improvement of voice in definitive unilateral pareses demands an injection of the vocal chord for example with Teflon®. In cases of *acute bilateral paresis* of the *inferior laryngeal nerve* a tracheotomy is only to be avoided when a laryngologist performs immediately a posterior chordectomy including a resection of the processus vocalis or partial arytaenoidectomy or a (temporary) laterofixation of the vocal chord or applies Botulinum toxin [50].

2.9. Disadvantages

General anaesthesia is essential for microscopic laryngoscopy because of the required length of time and the inconveniences to the patient if not applied. Risks of general anaesthesia can be diminished by a close preoperative examination of all vital functions. It is in the responsibility of the laryngologist to estimate the practicability of tracheal intubation after the induction of anaesthesia. Patients with compromised airways in a severe degree have to be tracheotomized in local anaesthesia before microscopic laryngoscopy is performed. A set of instruments for a cricothyrotomy is to be provided. In some cases the anterior larynx cannot be adjusted without the risk of damage of the upper teeth. Exposure can be achieved by using smaller laryngoscopes and additionally by impressing the larynx.

2.10. Complications

It is not an unusual finding that cardiac arrhythmias occur during direct laryngoscopy but they clear all spontaneously. Continuous anaesthetic monitoring discovers them and medication can stop them if necessary.

Obstruction of the airway by compression or kinking of the flexible intratracheal ventilation tube is a serious problem and the prevention requires constant attention from both, the anaesthesiologist and the endoscopist.

Post-extubation laryngospasm is a severe complication and are to be kept to a minimum if anaesthetic experts anticipate and prevent them.

Although the incidence of dental fracture is very low the chipping of enamel by friction is seen more especially when the laryngoscope is in contact with unprotected teeth.

If the operative manipulation leads to a dramatic narrowing of the airway by oedema an elective tracheotomy is to be performed. Minor oedemas in the larynx are treated by intravenous applied cortisone. Cortisone is additionally given to prevent postoperatively the formation of endo-laryngotracheal cicatrices and following synechiae and webs.

Tearing, contusion and haematoma of the lips, tongue or pharyngeal wall can be avoided by gentle introduction of the laryngoscope.

In few cases an overexpansion causes a palsy of the hypopharyngeal or glossopharyngeal or lingual nerve. Although very seldom taste disturbances are referred.

Bleedings after biopsies are staunches by swabbing with adrenalin respectively by well-directed monopolar cauterization. Bleeding is the main complication after laser surgery.

2.11. Postoperative procedures

Until recovery of one's voice is secured a rest is indicated with avoidance of susurrations, coughing and harrumph. Coughing depressing and secretolytic agents are helpful in this phase. A normal theme of speech is considered as possible after healing of the alteration and laryngological investigation. Phoniatric exercises are a useful help for voice rehabilitation especially in cases of functional causation and after removal of a Reinke-oedema or a chronic laryngitis or resection of a vocal chord or an arytaenoidectomy. Antibiotics are prescribed only when enlarged surgical operations like partial endoscopic tumorresection or arytaenoidectomies were performed. Humid inhalations are to be recommended in any case.

3. Low-frequency and high-frequency jet ventilation: Technical basics and special considerations for clinical application

The supraglottic jet ventilation is a technique whereby the ventilation gas is emitted by a jet injector above the glottic level via an endoscope. The superimposed high-frequency jet ventilation, used by us [51], represents a supraglottic jet ventilation and needs an endoscope, a jet laryngoscope, with two integrated jet nozzles for ventilation. Ng [52] localizes the jet nozzles for the supraglottic jet ventilation at the distal end of the endoscope nearby the tip of the endoscope and thus immediately in front of the glottis. On the contrary we put the jet nozzles more proximal far away from the tip of the endoscope. Initially this ventilation technique was applied preferential in laryngeal interventions without reduction in cross

section of the glottic level. Further clinical experience pointed out that this technique is also implementable in cases of severe stenosis in front of the tip of the endoscope.

3.1. Construction of the jet laryngoscope

The jet laryngoscope used by us and first described by Aloy et al. 1990 [53] is originally a larynx endoscopy tube [54] which was modified by incorporation of fix jet nozzles (Figure 8).




Figure 8. Jet laryngoscope according to KLEINSASSER for SHFJV[®] according to ALOY (Carl Reiner Jet Laryngoscope, Carl Reiner Ltd. Company with limited liability, Vienna, Austria) with a connexion for the low-frequency (LF) and high-frequency (HF) jet gas at the left proximal side. Opposite at the right side there is the connexion of the monitoring. At the basis of the grip of the laryngoscope lies the aperture for the feeding of the moistened and warmed-up ventilation gas.

The findings of flow dynamic measurements at the lung simulator served for the basic conception of the construction of this jet laryngoscope. Experiences with nozzles suspended in standard laryngoscopes achieved success. To attain a sufficient tidal volume, under the utilization of the Venturi Effect, the size of the jet nozzle as well as its localisation and adjustment play a major role. This was demonstrated in corresponding investigations. The gas jet, entering the laryngoscope, must not be directed to the opposite wall but should be targeted to the caudal direction at the virtual central point of the distal end of the tube finding the continuation median in the trachea. The optimal angle of incidence is 18 degrees. As aperture of the nozzles which influences the effectivity of the jet beam 1.8 mm was chosen. At the right side of the laryngoscope there is a conduction fixed ending at the tip of the laryngoscope used for the measurement of the ventilation pressure and oxygen concentration (Figure 9).

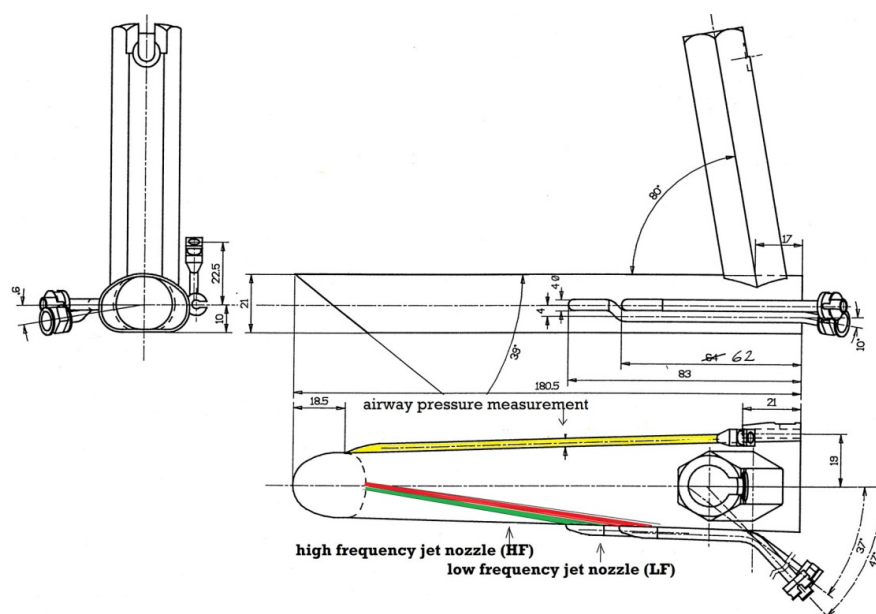


Figure 9. Schematic drawing of the gas flow in the jet laryngoscope (two jet nozzles) and of the pressure measurement and oxygen concentration (FIO_2) at the tip of the endoscope (yellow nozzle).

3.2. Ventilation technique

The simultaneous application of a jet stream with low- (normo- upto lowfrequent) frequency (12-20 impulses per minute; 0.2 - 0.3 Hz) and a further jet stream with high-frequency is performed via a jet nozzle. The low-frequent jet produces a high, superior pressure plateau representing the inspiration phase with a sufficient tidal volume (Figure 10). This is followed by breathing space of expiration.

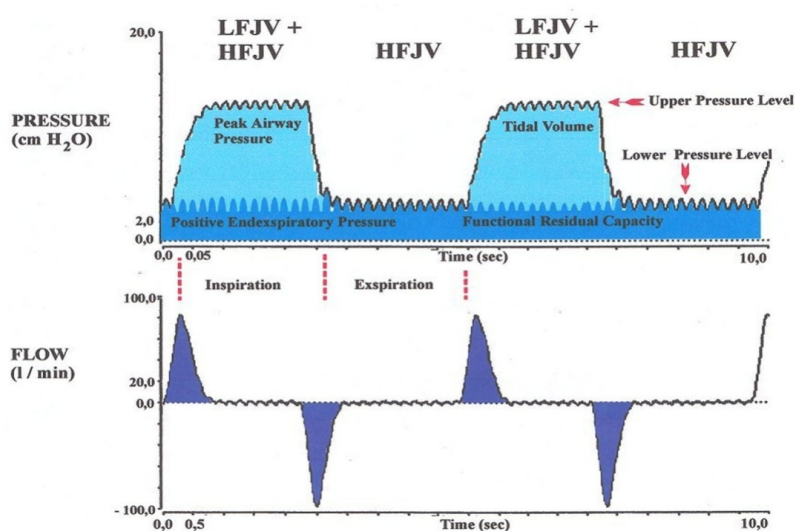


Figure 10. Relationship of pressure and flow during simultaneous low-frequency and high-frequency jet ventilation.

On the other hand via a second nozzle during the low-frequent inspiration and the subsequent expiration a continuous high-frequent gas application is conducted and is additionally superimposed to the low-frequent jet ventilation causing a minimal enhancement of the inspiratory pressure plateau. In the expiration phase of the low-frequent jet ventilation there exists only the high-frequent jet. The high-frequent jet portion (frequency from 20 to 1500 impulses per minute; 0.3 to 25 Hz) produces a lower pressure plateau corresponding to an end-expiratory pressure plateau, corresponding to an end-expiratory pressure (PEEP).

3.3. Pressure profile in the lung

Ventilation via a complete open system with two different pressure plateaus is generated.

The periods of inspiration and expiration of the normo-frequent as well as the high-frequent jet gases are to be adjusted variable. It is a *time- and pressure controlled ventilation* at two pressure plateaus with decelerating flow.

3.4. Adjustment of the respirator

Variable parameter of the low-frequency jet ventilation:

Working pressure of the gas leaving the jet nozzle: 0.03-0.04 bar/kg body weight.

Frequency: 12-20 impulses/min (adults), 20-30 impulses/min (children).

Inspiration/Expiration ratio: primary 1:2 or 1:1.

Variable parameter of the high-frequency jet ventilation:

Working pressure of the gas leaving the jet nozzle: 0.02 bar/kg body weight.

Frequency variable: 100-1500 impulses/min.

Inspiration/Expiration ratio: primary 1:2 or 1:1.

3.5. Respirator

The development of the jet ventilation with two jet streams made it mandatory to design a specific respirator (Figure 11). An electronic respirator enabling the low- and high-frequent gas application was developed. Simultaneously the pinside of the endoscope measured ventilation pressures are digital and graphically represented, just as the adjusted and measured FIO₂. Furthermore a laser mode is practicable reducing automatically the FIO₂. The ventilation parameters are recorded and an integrated pressure limitation reacts to a too high pressure and also to a pressure drop. Therefore a barotrauma can be avoided with greatest certainty. After the input of patients body weight the ventilation is started with a default setting of the device. The connection with the jet laryngoscope is made by two not confusable jet hose couplings. Moreover the respirator includes different usable ventilation modes for the application of bronchoscopy and infraglottic one-lumen catheter techniques.



Figure 11. Jet respirator for the combined high-frequent and low-frequent jet ventilation (Twin Stream TM multimode respirator, Carl Reiner Ltd. Company with limited liability, Vienna, Austria). The continuous airway pressure is displayed in the left upper corner. The top right part shows the adjustable pressure limitation. In the middle left the digital airway pressure and in the center of the display the inspiratory oxygen concentration is displayed. On the lower left side the low-frequency jet unit can be seen and on the right there is the high-frequency jet unit.

3.6. Physical effects during ventilation

3.6.1. Gas velocity

The applied ventilation gas (oxygen/air mixture) is a fluid with 1 to 1.5 bar of pressure of at the nozzle. At the tip of the laryngoscope a decompression of a 100 fold occurs so that there are registered pressures of 20 mbar. The flow velocity can achieve at the discharge of the nozzle up to 300 m/sec, but at the tip of tube it is also distinctly shortened and represents less than 100 m/sec [55].

3.6.2. Characteristics of the gas flow – Computational fluid dynamics

The computational fluid dynamics performed by us shows that during application of superimposed high-frequency jet ventilation via the jet laryngoscope an *asymmetric bi-directional gas flow* occurs in the jet laryngoscope (Figure 12).

3.6.3. Free-jet

The gas stream emitted from the particular jet nozzle is a free jet inducing an entrainment of surrounding air at the rim caused by an occurring discontinuity [56]. This entrainment is also the reason why the oxygen concentration adjusted from the respirator is diminished at the tip of the endoscope. The beams respectively the stream becomes progressively broader and his velocity decelerates (Figure 13).

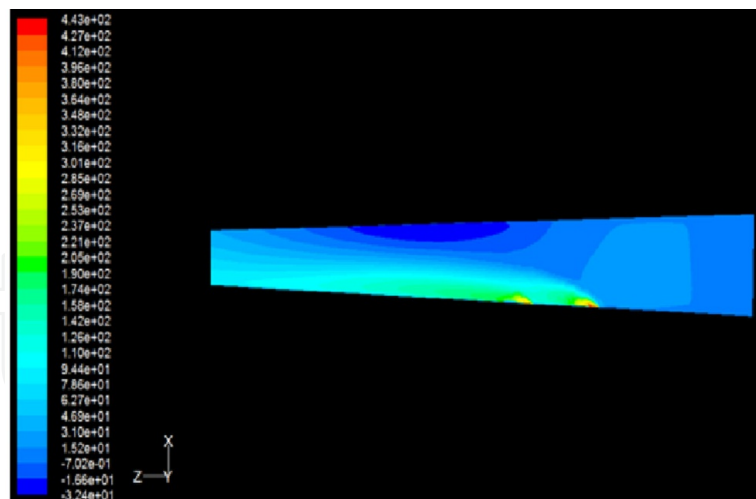


Figure 12. Characteristics of the gas flow in the jet endoscope: flow of the gas leaving the nozzles with high velocity (yellow) towards left side to the virtual tip of the endoscope. Additionally a fluid flow exists towards left side with decreasing velocity (light blue) directed to the tip of the endoscope. At the opposite side of the endoscope there is a flow (dark blue) toward right side outwards.

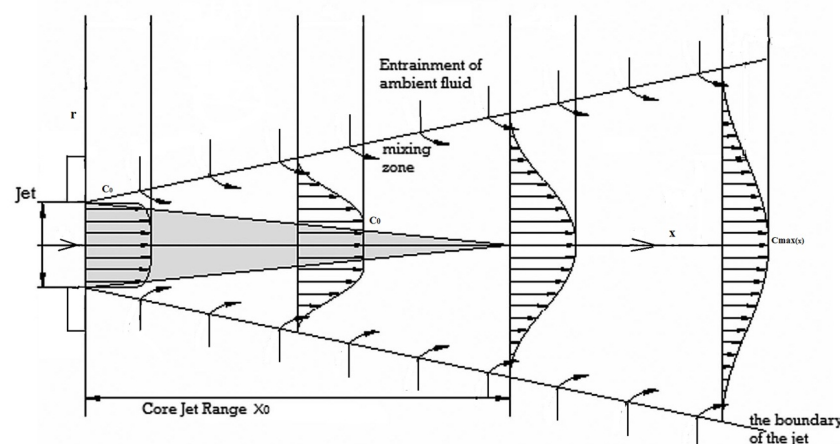


Figure 13. Schema of the characteristics of the free jet as it ejects from the nozzle. A typical deformation of the profile of the beams respectively the stream and an entrainment of the (rim) boundary zone is demonstrated.

3.6.4. Characteristics of pressure in the jet laryngoscope

The described position of the nozzles causes a typical behaviour of the pressure, as shown in Figure 14. In front of the nozzles a negative pressure occurs, which comes to its maximum immediately after the aperture of the jet nozzles.

Due to the nozzles ending in the first section of the jet laryngoscope the Venturi-effect takes place far away from the surgical area, suction and spraying of blood is prevented.

Only after the nozzles the pressure in the laryngoscope increases.

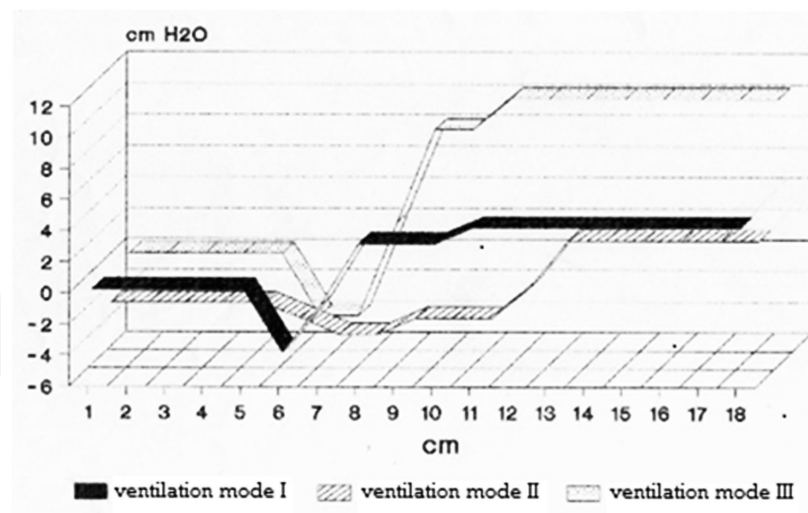


Figure 14. Characteristics of the pressure in the jet laryngoscope under the application of three different ventilation modes. On the outside (left) of the endoscope a moderate negative pressure originates when gas is emitted at jet nozzles. In the area of the nozzles the pressure becomes strongly negative. Then a positive pressure originates in the direction of the tip of the endoscope (right).

3.6.5. The Joule Thomson effect

Real gases cool when expanding without performing work (against an external pressure) [57, 58]. The increase of the volume enlarges the median distance of the gas molecules. Work is to be applied against the intermolecular attracting forces. The potential energy of the system grows at the cost of the kinetic energy of the gas molecules and therefore the temperature drops. Due to this effect during prolonged mechanical ventilation, heating and humidification of the respiratory gas is needed to avoid damage to the mucous membrane in the trachea.

3.7. Influence on physical effects

3.7.1. Moistening and warming of the respiratory gas

Further development of the jet laryngoscopes allows now the continuous moistening and warming of the respiratory gas. The gas is supplied via a so-called bias-flow to a moistening device and is moistened and warmed inside (Figure 15).

3.7.2. Entrainment of the gas

Due to the installation of an aperture in the grip of the endoscope oxygen enters the laryngoscope replacing the entrainment of surrounding air. Therefore the oxygen concentration remains the same as it leaves the jet nozzles. Thereby at first the entrainment of the air in the laryngoscope is reduced and as second the ventilation gas is moistened and as third it is warmed-up. Although physical effects cannot be eliminated completely, they can be diminished in their intensity nevertheless.



Figure 15. Device for moistening and warming-up of the respiration gas. The central unit (white) incorporates the electronical control unit. The humidifying chamber (blue) for single or multiple use is fixed at the central unit. The tubing system (yellow) is splitted in a short tube which transports the ventilation gas coming from the respirator to the humidifying chamber, and in a long tube which transports the now moistened and warmed-up gas from the humidifier chamber to the jet laryngoscope. The distal part of the long tube is metallic and is connected to the jet laryngoscope.

Recent developments and clinical experiences with superimposed high-frequency jet ventilation demonstrate that a broad spectrum of clinical application is practicable [59].

This method is suitable for laryngotracheal diseases in adults and also excellent in infants and children [60, 61]. Additional, special indications for jet ventilation are supraglottic, glottic, subglottic and tracheal stenoses. Further applications are the ventilation during bronchoscopy, the percutaneous dilatation tracheostomy (PDT) [62] and the placement of airway stents and the treatment of acute respiratory distress syndrome (ARDS).

4. Tubeless laryngotracheal surgery via jet ventilation

Endolaryngeal and -tracheal surgery always burdens from the situation in the operation area which is to share with the anaesthesiologists. An endotracheal tube narrows the view for endoscopic examination and surgery in the larynx and in particular in the trachea. Stenotic areas cause respiratory insufficiency and often can not be passed by a tube however small they may be. A safe ventilation technique, the superimposed high-frequency jet ventilation (SHFJV), which allows the laryngotracheal surgeon optimal conditions for diagnosis and surgical procedures was invented by Aloy 1990 [63]. This tubeless method, described in detail before, became rapidly the anaesthetic method of choice for laryngotracheal operations at our Department of Otolaryngology in Vienna [64, 65] (Figure 16). The following report stresses out in general our experiences when laryngotracheal surgery is performed under SHFJV.

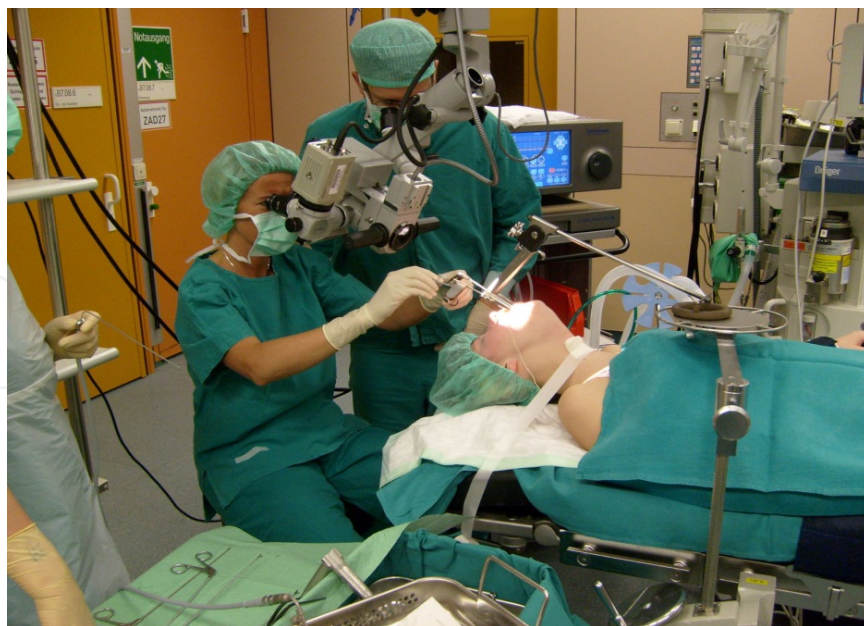

Figure 16. Microlaryngoscopy under superimposed high-frequency jet ventilation (SHFJV)

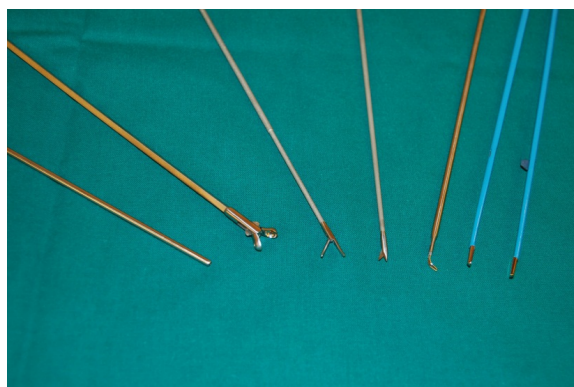


Figure 17. Long micro instruments for the operative procedure in the larynx and in the trachea.

At our department of otorhinolaryngology in Vienna, Austria 2123 micro laryngeal/tracheal surgical interventions were made under SHFJV from 1990 up to December 2011 using micro instruments demonstrated in Figure 17. Diagnoses and number of patients is demonstrated in the following Table 1.

If it becomes necessary that the vocal chords are in a complete standstill in fine phonosurgical interventions it is easy and hazard-free to interrupt the jet ventilation for a few seconds.

We never saw complications associated with jet ventilation which include inadequate oxygenation and ventilation, severe dehydration of the mucosa, gastric distension, regurgitation, and even gastric rupture. Pneumomediastinum or pneumothorax have been reported, and occurs mostly when applying jet ventilation with an obstructed airway [66].

Diagnoses	Total (n=2123)	Percent (100%)
Laryngeal carcinoma	403	19.0
Vocal chord leucoplakia	272	12.8
Laryngeal papillomatosis	122	5.7
Chronic laryngitis	116	5.5
Vocal chord polyp	259	12.2
Reinke`s oedema	221	10.4
Laryngeal/tracheal stenosis	172	8.1
Bilateral vocal chord paralysis	45	2.1
Unilateral vocal chord paralysis	72	3.4
Vocal chord nodule	57	2.7
Vocal chord granuloma	71	3.3
Vocal chord cyst	93	4.4
Vocal chords synechia	53	2.5
Supraglottic cyst	83	3.9
Phonosurgery	32	1.5
Others	52	2.5

Table 1. Diagnoses of patients undergoing micro laryngeal/tracheal surgery with superimposed high-frequency jet ventilation (SHFJV).

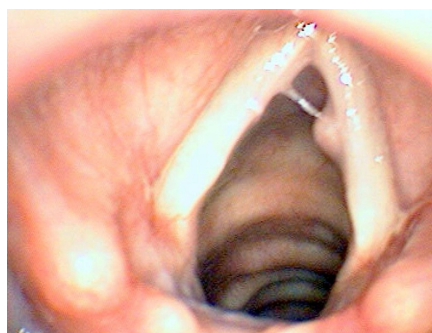


Figure 18. Cyst at the free margin of the right vocal chord anterior half with free access to the operation area.

The continuous pressure control of the SHFJV- device could ward a barotrauma in our application in any case.

4.1. Contraindications of SHFJV in laryngotracheal surgery

The jet ventilation has proven to be most suited for patients with normal, unobstructed airways and normal lung and chest wall compliance (Figure 18). Reduced chest wall compliance such as in obesity (body mass index >35) may lead to unmeant gastric insufflation and distension causing worsening of the respiratory compliance. A significant overbite especially in combination with retrognathia makes laryngotracheal placement of the ventilation laryngoscope impracticable and the incidence of accidental gastric hyperinflation is high.

Expected massive bleeding is an absolute contraindication. However slight bleeding does not reach the trachea and deeper airways because of the high-frequent gas flow with PEEP-effect pressures the blood to the laryngeal respectively tracheal wall and with the expiration it is transported externally.

5. CO₂ laser micro laryngotracheal surgery during supraglottic jet ventilation

Three characteristics are the basics of the high energy density of laser:

- 1. monochromaticity: in a high degree with very limited range of wavelengths,
- 2. coherence: in the laser beam the electromagnetic fields of all photons oscillate synchronously in identical phase, and
- 3. collimated beam: laser light remains in a narrow spectrum.

With laser light, tissue penetration is mostly a function of wavelight. Long-wavelight laser light such as that from CO₂ laser (operation at 10,600 nm) is completey absorbed by water in the first few layers of cells. The thermal effect is therefore largely limited to the point of entry into the target tissue. This results in explosive vaporisation of the surface tissue of the target with surprisingly little damage to underlying cells. When coupled to an operating microscope the laser vaporizes the lesions with precision, causing minimal bleeding and oedema: an obvious advantage, especially in small pediatric airways.

Technique of CO ₂ laser microsurgery	Advantages of CO ₂ laser microsurgery
Wavelength: ~10.000 nm; infrared - invisible	Contactless operating
Pilotlaser: red (aiming beam), coaxial	Precise dosing and control
Micromanipulator for application	Reduced bleeding
Focus diameter: 0.3-0.7 mm	Reduced risk of infection
at a distance of 40 cm	Less postoperative pain
Microscopic magnification: 4 to 40-fold	

Table 2. Technique of CO₂ laser microsurgery and advantages of laser surgery.

The pulsed dye laser (PDL) has a shorter wavelength and spares the epithelium, but specifically hits the microvascular supply of the lesion. This has an advantage in the anterior laryngeal commissure because not denuting the epithelium is beneficial, it should limit the occurrence of webs. In certain situations, a laser based resection technique is surgical method of choice for:

- 1. sessile lesions,
- 2. lesions in scared areas and

3. lesions near or in the laryngeal ventricle.

Anaesthesia for laryngotracheal interventions can be performed with or without endotracheal tubes [67]. As the most severe complication laser induced combustion is considered. Within 635 laser applications under SHFJV at the Department of Otorhinolaryngology of the Medical University of Vienna we had to see in one case an endlaryngeal fire caused by ignition of an erroneous dry swab which was inserted in the subglottic space for laser prevention of the trachea wall. The fire could be extinguished rapidly. After orotracheal intubation a tracheostomy was performed for the entrance of ventilation. The patient could be discharged from the intensive care unit within 10 days and from hospital after closure of the tracheostomy after 21 days without further essentially respiration problem deriving from this accident, especially there was no stenotic laryngotracheal process [68]. It is clearly to state, that this ignition was not in a causal connection with the SHFJV. The major complication, airway fire, is avoided by SHFJV itself: there is no flammable material in the airway. Other ventilation devices like plastic tubes do not withstand laser strikes and will ignite the longer the laser exposure lasts. Metallic foil-wrapped plastic tubes may injure pharyngeal and laryngotracheal tissues by sharp edges, loose their elasticity and tend to kink. The protective effect is lost if the foil is detached and airway obstruction may occur when parts of the foil is aspirated. The reflexion from the surface bears the risk of damage of surrounding tissues. For a considerable time laser safe endotracheal-tubes are put up for sale. The disadvantage of these tubes is the size of its diameter. Because of the required material safety these tubes have a large outer diameter and a small inner diameter. In case of a larger stenosis it is not possible to use these endotracheal tubes. But just in cases of stenoses jet ventilation has a major advantage. No tube - no fire when the applied oxygen concentration is low (< 40%). The jet ventilation is done with a mixture of oxygen/air. Nitrous oxide should not be used.

The high gas flow dilutes and eliminates the smoke and therefore additional suction for smoke is redundant. Laser laryngotracheal surgery was performed with a CO₂ laser (Hercules 5040; Haereus, Germany or Sharplan 1050; Vörösmarty, Israel).

Special indications for CO₂ laser application in combination with SHFJV in laryngeal diseases are the early glottic cancer [69, 70], the papillomatosis and the stenoses. Indispensable precaution is the internal approval for general anaesthesia, the adjustability of the inner laryngealtracheal structures with special attention to the anterior commissure and the expectation of low bleeding. The laser surgical procedures under SHFJV lasted from 15 up to 120 minutes, on the average of 42 minutes.

5.1. Circumscribed carcinoma

The preoperative information of the patients include the postoperative bleeding which depends on the extent of the resection. A revision under endotracheal intubation and general anaesthesia and sometimes a tracheotomy will be necessary. The patient has to know that until the definitive histological findings are evident in case of incomplete resection a re-operation will be necessary. Healing of the wound is delayed with functional consequences like hoarseness and transient aphonia. Synechiae and stenoses rarely occur. After histological confir-

mation of the initial diagnosis the surgery by CO₂ laser with the soft super pulsed mode a nearly char-free cutting via vaporisation is performed.

Dissecting the soft tissue of the tumour is has proven to perform with the micro manipulator fine serrated hither and thither movements. With this method laser's physical properties for cutting and coagulation are utilized most effective [71]. Like the study group of our department could show excellent oncological results can be expected in T1a-glottic cancer in comparison to radiotherapy and conventional surgery [72].

Postoperative stridor is mostly due to a swelling of the local mucous membrane and is easy to be treated by cortisone.

5.2. Laryngo/tracheal stenosis

Congenital and aquired stenoses in all regions of the larynx are a preferred indication for CO₂ laser surgery (Figures 19, 20, 21). Tubeless ventilation allows the surgeon to operate in an already narrow area.

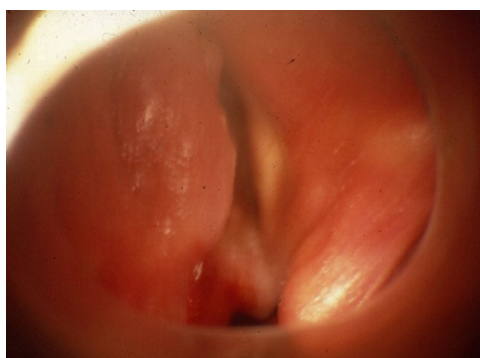

Figure 19. View through the ventilation laryngoscope in position. Tumour caused massive stenosis. In the area of the posterior commissure a residual lumen exists, enabling patient's spontaneous but stridulous breathing.

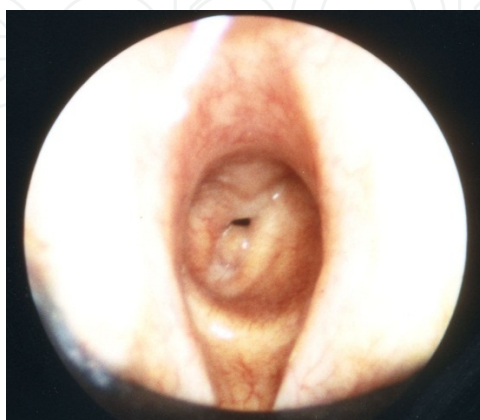


Figure 20. High grade subglottic stenosis with a substantially reduced lumen.

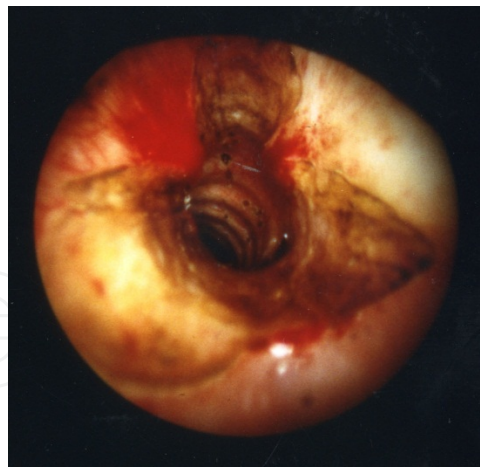


Figure 21. Star-shaped opening of a glottic/subglottic stenosis with CO₂ laser under SHFJV.

5.3. Laryngeal papillomatosis (see also part 6)

Accordingly to their biological behavior with multiple recurrences in juvenile papillomatosis repeated interventions are necessary (Figure 22). The CO₂ laser in combination with SHFJV [73] offers the opportunity of a safe procedure with preserving the functional important vocal chords.

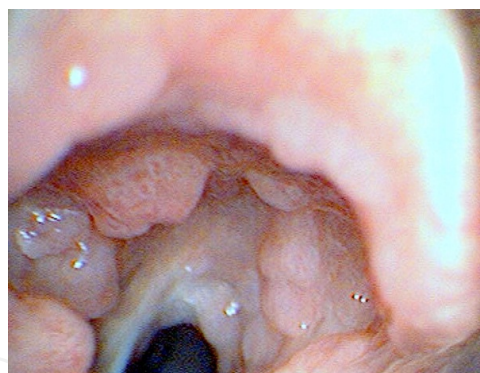

Figure 22. Glottic and supraglottic recurrence of a juvenile papillomas.

(We thank Prof. W. Bigenzahn from the Department for Phoniatriy and Logopaedia of the Medical University of Vienna for providing this figure).

6. Tubeless laryngotracheal surgery in infants and children via jet ventilation

Laryngotracheal surgery in infants and children is handicaped by the narrow anatomical area of operations and often additionally by the pathological substrate itself. A special cooperation

between the surgeon and the anaesthetist is indispensable. Ventilation via an endotracheal tube with a cuff is most safe to operate. But even this endotracheal tube blocks on the one hand the unobstructed view of the operating field and on the other hand the necessary space for surgical activity and additionally mutates the anatomical structures. In cases of pronounced stenoses in the laryngotracheal area an endotracheal intubation cannot be applied. An alternative procedure is the tracheotomy, especially for infants and children and the postoperative care an enormous burden.

A rigid bronchoscope used for ventilation restricts the visibility of the working space and it may occur that it cannot pass a stenosis. Laryngotracheal surgery in the apnea technique is still in use but is associated with the heightened risk of hypoxemia and hypercapnia.

An improvement of ventilation of the patient during laryngotracheal surgery was established by single-frequency jet ventilation techniques applied either per percutaneous insertion of a needle into the trachea or endotracheal tubes or catheters, or application of a jet nozzle into the endocopy tube [74, 75]. All these techniques have the disadvantage of the risk of hypoxaemia and hypercapnia especially in patients underlying pulmonary and cardiac aggravated risks and operations with a long continuance. Needles placed transtracheal bear the elevated risk of barotrauma because the gas supply takes place below the stenosis [76].

6.1. Ventilation

As an alternative ventilation technique the jet ventilation presents themselves with 3 modalities:

1. *transtracheal jet ventilation* (Figure 23): for endoscopic laryngeal surgery, also with laser, excellent visibility for the surgeon, even in glottic or supraglottic stenoses with minor complications up to 20 % [77-79]. Very important is the bedding of the child with maximum extension of the head. This allows fixing the mobile trachea between middle finger and thumb. The cricoid membrane is narrow and at best to be felt by a fingernail. The puncture with ventilation catheter is to be directed in a caudal direction.

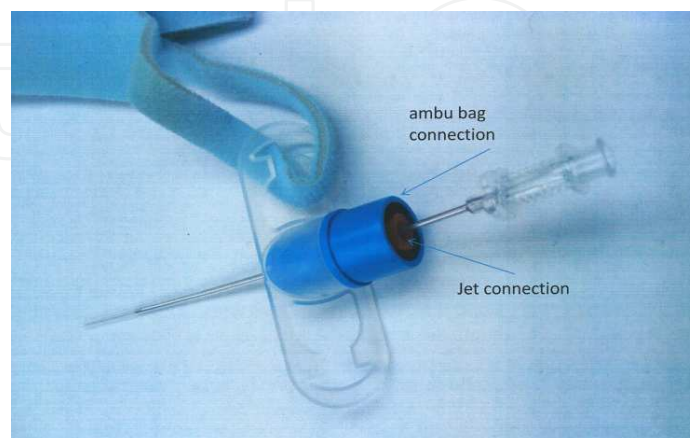

Figure 23. Percutaneous transtracheal jet ventilation catheter (VBM®-Medizintechnik, Germany) for children with steel puncture needle.

2. *infraglottic, transoral jet ventilation*: transoral or nasotracheal positioning of a catheter through the glottis deep enough into the trachea. Available if the glottis is not narrowed.

Not available for children because the diameter of the catheter is often more than 5 mm.

3. *supraglottic jet ventilation*: as an alternative method the authors, Grasl et al. 1997 [80], have presented their experiences in the first use of tubeless superimposed high- and low-frequency jet ventilation (SHFJV) with a jet laryngoscope in laryngotracheal surgery in infants and children 28 infants and children. This intervention was spread successively [81]. Because of the absence of an additional jet catheter optimal working conditions with best visibility in primarily narrow areas are created. Nowadays jet laryngoscopes with also two integrated jet nozzles for children are available in different sizes. The transfer of the jet gas takes place at the proximal section of the laryngoscope and not nearby the glottis. The endoscopes are equipped with an integrated ventilation pressure measurement positioned at the tip. At the grip of the endoscope (Figure 24) there is an aperture for the connection of the moistening and warming of the ventilation gas. On the left side there of upper section of the laryngoscope there are two jet nozzles, on the right side are located a nozzle for the ventilation pressure measurement and a nozzle for the true FIO₂ recording. Additional monitorings are the pulsoxymetry, the electrocardiogram and the noninvasive measurement of the blood pressure. We consider because of our complication free experiences the invasive arterial monitoring as needless.

The supraglottic jet ventilation offers the surgeon the opportunity to use the CO₂ laser [82].



Figure 24. The proximal section of the ventilation laryngoscope for children with all connexions.

6.2. Anaesthesia

Ventilation is carried out by an air/oxygen mixture. If the CO₂ laser is used the inspiratory oxygen concentration is reduced to 40 %. In corresponding dose rate propofol is applied as hypnoticum, fentanyl or remifentanyl as analgesia and rocuronium as short effective relaxant.

Anaesthesia starts with manual ventilation by a conventional respirator. When relaxation takes effect the jet laryngoscope is placed and jet ventilation starts. After the end of the surgical

intervention the jet laryngoscope is removed and mask ventilation follows till the patient is awake.

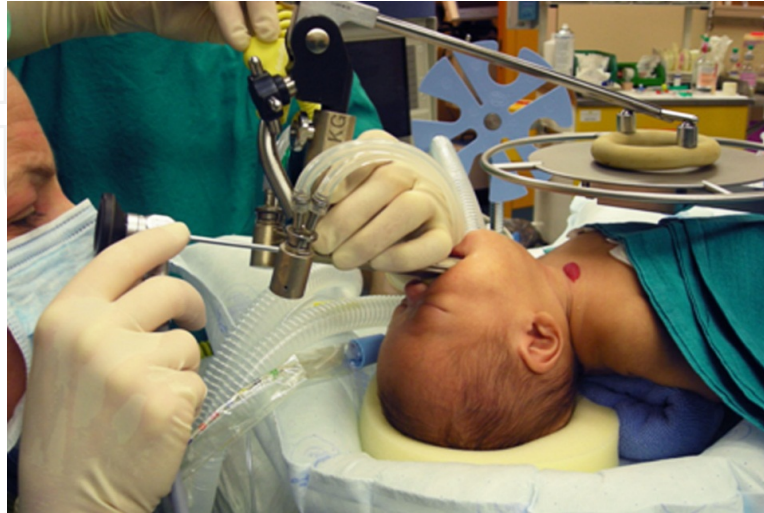

Figure 25. Procedure of an endoscopic surgical intervention under a continuous superimposed high-frequency jet ventilation.

The physiology of the infantile lung offers several specifics. The compliance and also the resistance of the lung make age-related fluctuations. The compliance is significantly lower and the resistance higher than in adults. Due to the resulting time constant a higher ventilation frequency exists. With increasing age an approximation to the values up to that of adults occurs. Subsequently the following considerations for the adjustment of the respirator are: higher frequency of ventilation, ventilation pressure low but not too low, the start calibration of the respirator with body weight specification, orientation at the displayed and measured values of ventilation pressure. As in adults the supraglottic jet ventilation is performed at two different pressure plateaus. With the superior pressure plateau CO_2 is eliminated, the inferior pressure plateau produces the positive end-expiratory pressure (PEEP).

Contraindications for the jet ventilation are: impracticality to bring the jet laryngoscope in the right position, bleeding in larynx and trachea and the absence of patient's sobriety.

The superimposed jet ventilation offers the anaesthetist and the surgeon optimal working conditions (Figure 25). Anaesthesia has as advantage the continuous mechanical ventilation with integrated limitation of pressure. The surgeon has optimal conditions of visibility with no displacement of anatomical structures by a catheter or endotracheal tube. A further advantage is the safe application of laser surgery.

The youngest patient was two week old. Therefore no age-related limitation exist for the superimposed high-frequency jet ventilation.

Up to now at the Department of Otorhinolaryngology of the Medical University of Vienna 230 infants and children with an age below 14 years were ventilated sufficiently by a therefore

extra designed rigid endoscopy tube derived from the Kleinsasser tube [79] during laryngo-tracheal surgery. Diagnoses were: papillomatosis, subglottic stenoses, laryngeal inspection, web, foreign body, vocal chord cyst, vocal chords granuloma and miscellaneous. Movement of foreign bodies becomes much more easy and elegant during the tubeless ventilation: a Fogarty-Catheters® guided behind the foreign body helps to bring him more proximal where he can be gripped and extracted with a forceps [83]. With this SHFJV technique laryngeal stenoses and cardiopulmonal insufficiencies do not present special risks. Laryngotracheal surgery under SHFJV can be applied in any child except special general contraindications.

As in adults before effective jet ventilation can start, the laryngoscope tube, adjusted to size of the childlike larynx, is inserted and evaluated for suitability for jet ventilation. Immediately afterward the suspension system is installed and the jet injector needles are attached to the laryngoscope. The steadily ventilation can begin. Up to this point of time the manipulation happens in an anaesthetized but apnoeic patient.

The procedure of the jet ventilation took from 5 up to 130 minutes, on average about 35 minutes. The ventilation assured in any case a sufficient oxygenation and CO₂ elimination.

Only in a few cases during introduction or recovery of the anaesthesia an endotracheal tube had to replace the ventilation tube temporarily caused by adverse anatomical characteristics. A severe laryngospasm never resulted from SHFJV. To eliminate the danger of pneumothorax in the application of SHFJV it is to state that it is an open system with an air supply always above the existing stenoses. Additionally an integrated monitoring of pressure in the laryngoscope is positioned. The surgical procedure could be performed in any case.

Contraindication for SHFJV in infants und children are in principle the same as in grownups.

The technique of SHFJV has helped us to handle the naturally difficult surgery of the larynx and trachea in infants and children and simplified it considerably.

A very special laryngeal disease in children is the recurrent respiratory papillomatosis (RRP) [84-86].

Only a minority of Human papilloma virus (HPV) carrying mothers will become symptomatic. The route of transmission to the infant is not yet completely understood.

There is no cure for RRP at present and no therapy modality that might eradicate the virus from the respiratory mucosa. Local recurrences are therefore frequently seen.

Vaccination against HPV 6 and 11 across the board should decrease the incidence of children in future.

RRP requires a protracted and repeatedly therapy over years.

The surgical therapy with a removal of the papillomas as much as possible und preservation of normal structures is the procedure of (Figure 26). Scaring from overaggressive resections effects dysphonia and airway comprise. Incomplete resections are accepted under these aspects especially in the anterior commissure. It is not practicable to eradicate all virus particles even when clinically all evident papillomas had been removed.

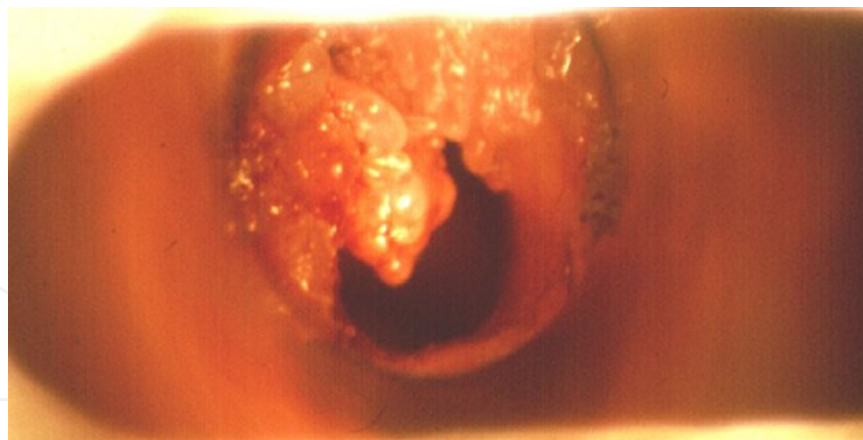

Figure 26. Laryngeal papillomatosis. View through the jet laryngoscope.

We have experiences about 122 surgical interventions under SHFJV in children with RRP.

Near all of them received papilloma ablation by CO₂ laser.

In addition the adjuvant medical therapy plays an increasing role: a-Interferon, and various antiviral agents, of which the most commonly used is the intralesional sidovir.

We cannot confirm, based on our experiences, the theoretical risk in clinical practice that the applicated jet is forcing papilloma fragments deeper into the airways. Our preliminary results provide no indication that the risk of spread of papillomas by jet ventilation into the trachea has increased. A spread of papillomas by an endotracheal tube cannot be entirely excluded.

7. Supraglottic jet ventilation in laryngotracheal stenoses

High degree stenoses in the larynx and trachea represent an acute alarming situation for the affected patients. In a slow increasing stenotic process the narrowing of the laryngeal or tracheal lumen up to 80 % is clinically well tolerated by the patients [87-89]. A further increase of the stenoses, for example caused by a local swelling, is associated with life-threatening dyspnoea and hypoxia. In these cases a tracheotomy is necessary to maintain gas exchange. If an endotracheal intubation is impossible due to the massive narrowing of the laryngotracheal area and ventilation via mask provides sufficient oxygenation tracheotomy is performed under local anaesthesia. An extreme dyspnoea requires oxygenation via a percutaneous transtracheal puncture or surgical cricothyrotomy.

7.1. Applications of the jet ventilation in obstructive supraglottic respectively glottic or infraglottic narrowing of the airways

According to the local spread of pathologies the following anatomical localisations of obstructions exist: *i) supraglottic, ii) glottic, iii) subglottic and iv) tracheal.*

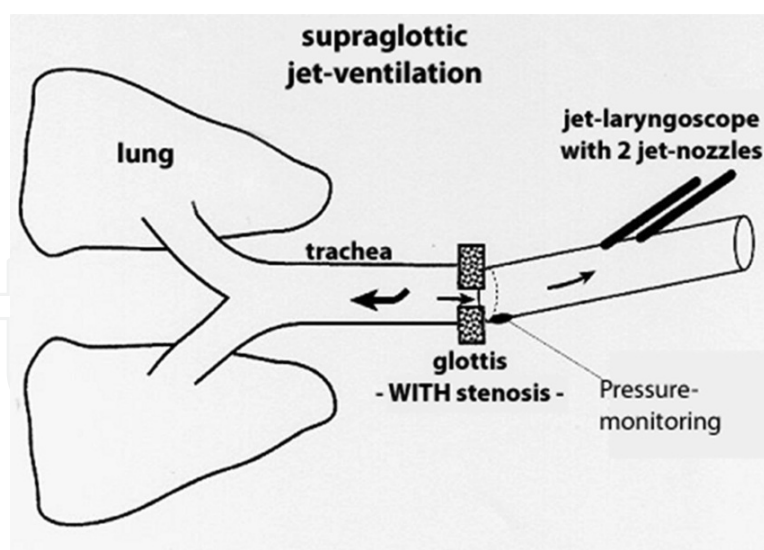


Figure 27. Schematic drawing of the supraglottic jet ventilation with a stenosis in front of the tip of the laryngoscope.

If the glottis is not obstructed any form of jet ventilation can be applied. The narrower the glottic space becomes because of a pathological process the more attention is to be applied to the chosen jet ventilation.

In principle three options are available for jet ventilation with stenosis: *i)* the *transcricoidal puncture* – not usable in cases of long-stretched stenoses where the trachea is not to be localized, *ii)* the *transoral infraglottic jet catheter* – not to be inserted through high-grade stenoses and *iii)* the *jet laryngoscope* – a supraglottic jet ventilation with jet gas emission above the glottic area (Figure 27). The first and second techniques are in terms of the location of the jet nozzles infraglottic jet ventilations.

Initially the application of the supraglottic jet ventilation was applied cautious in obstructive pathologies but at an early stage the advantages in severe airway obstructions emphasized [90, 91]. It became apparent that the increasing ventilation pressure, measured at the tip of the laryngoscope, behind an obstruction can not be higher than in front of it.

Therefore this technique is best suited for all kinds of to be expected difficult airway. However absolute requirement is to place the jet laryngoscope ahead the expected obstruction.

If a stenosis is produced at the lung simulator in the level of the fictitious glottis immediately ahead of the laryngoscope the following characteristics with regard to the tidal volumes are observed (Figure 28).

Increasing of the working pressure of the device for both types of ventilation, the low- and high-frequent jet, produces a sufficient respiratory tidal volume (**blue columns**).

With decrease of the compliance (0.05 l/mbar, **red columns**) the tidal volume without stenosis is already low and decreases dramatically with increase of a stenosis, at the identical original setting of the jet ventilator.

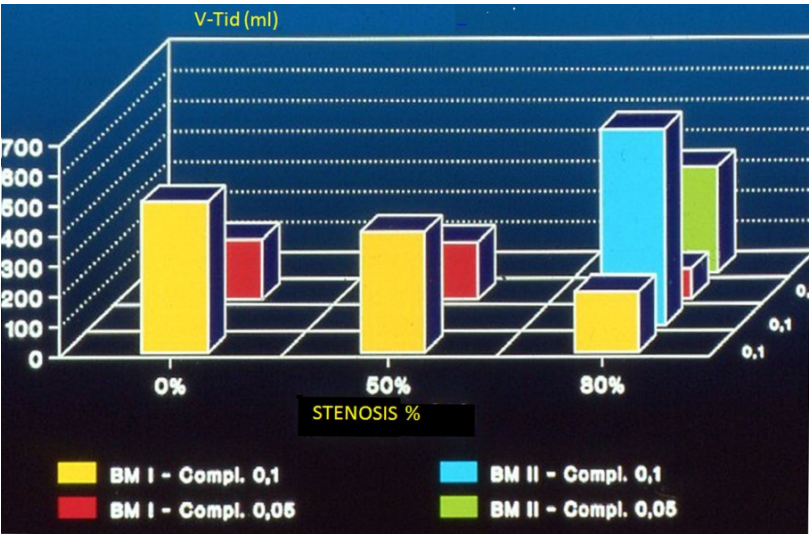


Figure 28. Diagram of the respiratory tidal volume (ml) to be achieved by a supraglottic jet ventilation via a jet laryngoscope in a default setting on the lung simulator: with a narrowing of the cross section for ventilation, at first without stenosis (0 %, left), then with a 50 % stenosis (centre) and at last with a 80 % stenosis (right) all **yellow columns**. The lung compliance was adjusted at 0.1 liter per millibar (l/mbar).

The increase of the working pressures of the ventilators succeeds in achievement of sufficient tidal volumes even in 80 % stenosis (**green column**).

7.2. Computational fluid dynamic

In a jet laryngoscope a flow simulation with ANSYS fluent® was carried out. First, the creation of a three-dimensional image of the jet laryngoscope with the preprocessor Gambit was performed. This was followed by the definition of boundary conditions and input parameters in the solver and the iterative calculation in fluent.

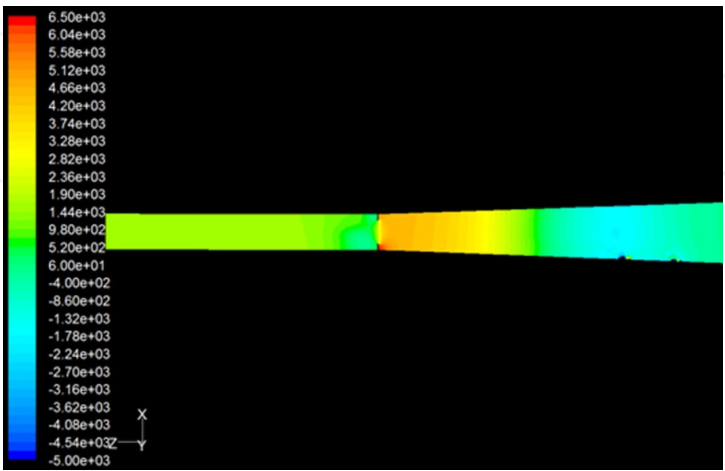


Figure 29. Distribution of pressure in the jet laryngoscope in case of a stenosis. Note the impact pressure in front of the stenosis (Figures 29, 30). The pressure behind the stenosis is lower than the pressure before the stenosis.




Figure 30. Characteristics of pressure in front and behind the stenosis in the jet laryngoscope. Note the pressure before the stenosis (left) and behind the stenosis (right).

These experimental results show that the pressure behind a stenosis is not higher than the pressure in front of the stenosis.

This simulation of the gas flow at a stenosis at the tip of the endoscope shows in the case of a reduction of the cross-section immediately in front of the tip of the endoscope the occurrence of an impact pressure. This pressure increases continuously at the shock front up to the stagnation point, but the velocity decreases. However the pressure behind the stenosis is lower than ahead the stenosis.

The supraglottic jet ventilation via the jet laryngoscope guarantees even in high grade stenoses (grade II-III according to RT Cotton [92]) a sufficient ventilation. The development of a barotrauma can be excluded like experimental results demonstrated. Only in stenosis grade IV when in no way a lumen exists the SHFJV via a jet laryngoscope cannot be applied.

An essential advantage of this technique is that the surgeon has in these difficult situations an absolutely free approach to the larynx and trachea. Because of the absence of inflammable material laser is safe to apply. The high gas flow avoids the smoke induced obstruction of vision.

Parameter	Setting
Inspiration time	Long-time
Expiration time	Short-time
Driving pressure	High
Ventilation frequency	High

Table 3. Setting of the respirator in stenosis and supraglottic jet ventilation.

Experimental results demonstrate if supraglottic jet ventilation is applied the ventilation pressure behind a stenosis cannot be higher than in front of a stenosis. The pressure measure-

ment at the tip of the endoscope allows the detection of elevated airway pressures. At the ventilator a pressure limitation can be adjusted and the ventilation stops when the pressure limit is reached. Clinical results with the absence of any complications caused by ventilation confirm this. The supraglottic jet ventilation can be applied in severe high-grade stenoses [93] (Figures 31, 32, 33). All these results are only valid for the type of supraglottic jet ventilation where the jet nozzles are positioned in the proximal section of the jet laryngoscope and not at the tip of the endoscope. Only in the case of grade IV stenosis after Cotton, in which no lumen in the area of the larynx is more available, the SHFJV on the jet laryngoscope cannot be applied.

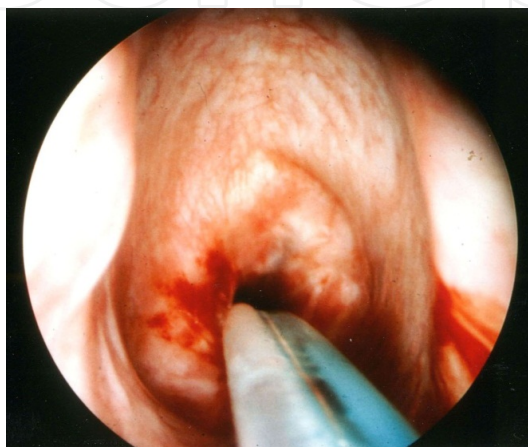


Figure 31. A severe subglottic stenosis: a jet-catheter (Hunsaker Mon®-Jet-Ventilation Tube, Medtronic Xomed® Inc. Jacksonville USA) is placed through this stenosis. Although the visibility conditions are good, the working conditions are difficult for the surgeon caused by the catheter.

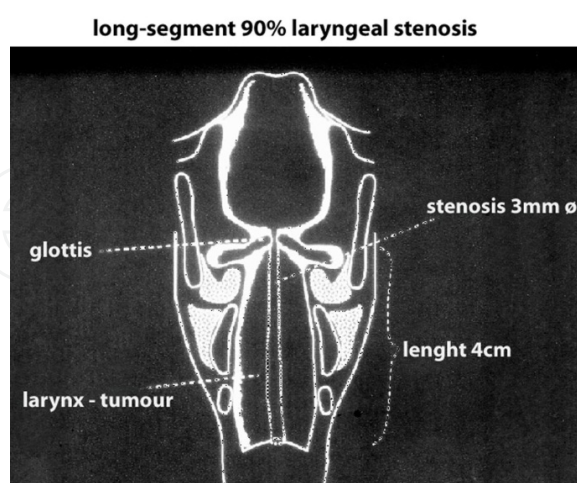


Figure 32. Schematic drawing of a long-segment 90% laryngeal stenosis. The diameter of the stenosis was 3 mm. In this clinical case, it was realizable to achieve a sufficiently ventilation. A transoral jet ventilation with a catheter would not have been possible. The diameter of a jet catheter is more than 3 mm. In the case of transtracheal jet ventilation, it would not have been possible to find the trachea in a simple way.

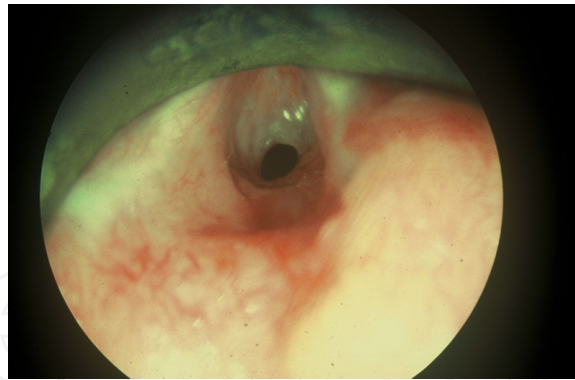


Figure 33. Extended subglottic stenosis. The use of a jet catheter through the glottis would make the outflow of the jet gas impossible.

8. Superimposed high-frequency jet ventilation (SHFJV) for tracheobronchial stent insertion

Central airway obstruction is caused by lung cancer, esophageal carcinoma, thyroid carcinoma, malignant lymphoma, and rather rare carcinoma of the larynx, trachea and hypopharynx. If the airway constriction is not yet in the focus external-beam radiation therapy, endoluminal brachytherapy and photodynamic therapy can be applied.

If curative treatment fails and progressive extended tumour growth infiltrates and advances intraluminal or external compression the effective lumen of the airway becomes dramatically narrow.

Palliative surgical tumour reduction methods are intraluminal laser ablation, electrocautery or mechanical removal. This is followed by implantation of tracheal or bronchial stents for to improve ventilation.

Indications for insertion of tracheobronchial stents are severe stridor and dyspnea in patients with tracheobronchomalacia and extraluminal compression, intraluminal tumour growth and tracheoesophageal fistulas. Airway stents have proved as best practical environmental option to renew and to perpetuate airways in such patients with a serious central airway obstruction.

[94-97]. Endotracheal intervention can be performed under local anaesthesia by fiberoptical bronchoscopy or under general anaesthesia using rigid bronchoscopy or suspension laryngoscopy [98]. From the consideration of anaesthesia a conventional ventilation or jet ventilation can be performed [99, 100].

Suspension laryngoscopy and jet ventilation offers an ideal setting with directly visual control for the precise placement of tracheal and bifurcational airway stents [101].

Low-frequency jet ventilation provides adequate ventilation as well as a non obstructed field during fibre optic bronchoscopy and stent insertion [102].

Airway stent placement requires a combination of surgical techniques and skills with safety and perpetuated ventilation during manipulation. The procedure is to be planned carefully, a constant communication between the surgeon and anaesthesiologist is an indispensable condition.

Stents are made from either metallic expandable prostheses or flexible silicone, with each type having their special indications according to the requirements and are placed either temporary or permanent.

Temporary	Permanent
Decay of a post-stenotic pneumonia	Benig: long-segment stenosis
Improvement of the overall condition	complicated injuries
Stabilization of a tracheobronchomalcia	functional inoperative patients
Pretherapeutic until radio/chemotherapy is effective.	Malign: anatomical and functional inoperative patients
	(lenghts of stenosis, tumour spread,
	overall condition).

Table 4. Indication for temporary and permanent tracheobronchial stents.

8.1. Technique of stent implantation

Usually the stent implantation is carried out under general anaesthesia in most cases via a bronchoscope under conventional ventilation or via a tracheoscope with the opportunity for jet ventilation or with growing extent via a jet laryngoscope [101]. Even in severe tracheal stenosis the jet ventilation is recommended [102, 103]. First at all inspection and then measurement of the stenosis is performed. If necessary a surgical debulking for the enlargement of the tracheal lumen is made.

8.2. Anaesthetic management

During execution of these steps and the placement of the stent a continuous ventilation of the patient is applied, preferential with jet ventilation [104] without phases of apnoea.

Often we really succeed to create a straight axis between the trachea and the jet laryngoscope and under certain circumstances the view extends to the carina.

The advantage of jet ventilation especially via the jet laryngoscope is the continuous automatically ventilation and the operation area with no limitation of visibility. Ventilation is arranged by an air/oxygen mixture applicated via the bronchoscope or the jet laryngoscope.

Through the jet laryngoscope or the rigid bronchoscope a simultaneous low- and high-frequency jet ventilation is applicated.

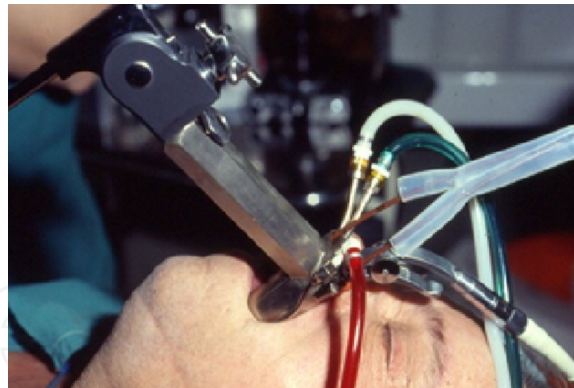


Figure 34. Application of a Y-stent under guidance of two catheters (right and left main bronchus) under superimposed high-frequency jet ventilation.

Anaesthesia is performed as totally intravenous, as hypnoticum propofol continuous, as short-acting relaxant serves rocuronium as a bolus and as short-acting analgesic remifentanyl. This kind of anaesthesia has well proven in adults and children [105].

If the stent is to be positioned as a distal Y stent or a tube, it is essential to check that both limbs are patent. The ventilation laryngoscope allows a lot of space for manipulation. Folding and or creasing of a limb of a T or Y tube can disable ventilation with the need of emergent removal of the stent. Additionally, when jet ventilation is used, a totally stent blockage can cause high airway pressures with the risk of a tension pneumothorax. After the placement of a stent, the laryngoscope is removed and the patient may awaken with mask ventilation.

At this moment all equipment and personnel should stay at call in the operating room until the patient is completely awake and ready for transport.

If a stent reaches into the upper trachea, standard intubation in following anaesthesia should be avoided, because this second endotracheal tube may adhere to the stent and remove it during extubation.

8.3. Types of stents

Selfexpanding stents

Wallstent: small-meshed grating, self expanding, for extraluminal caused stenosis.

Gianturco-Z-stent: broad-meshed grating, for example for tracheobronchial malacia.

Silicone stents

For application various sizes and types can be adapted to the particular located situation (Figures 34, 35, 36). Their application is descibed in numerous publications [106, 107]. That includes also the Montgomery -T-tubes [108], the Dumona-Artemis-Stent and also the Orłowski-stent [109] and also the Polyflex® stent is to be allocated to the silicone stents. In the silicone grating polyester fibres are integrated. The application of all these stents can be done under continuous jet ventilation.

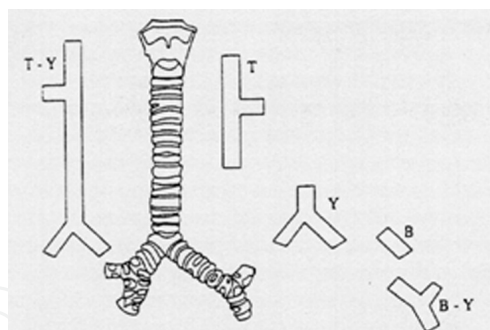


Figure 35. Various forms of silicone stents to be inserted according the respective local anatomical situation. From W. Klepetko et al. Endoluminal Stenting of the Tracheobronchial System. *Acta Chirurgica Austriaca* 1991;23(3)124-129 [11] with friendly permission of Springer Verlag, Vienna-New York.

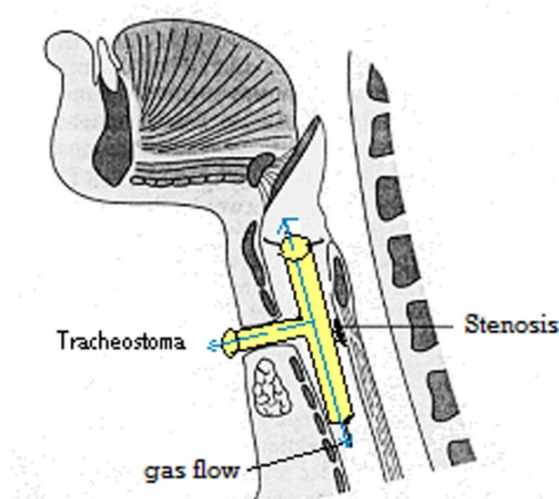


Figure 36. A typical T-tube according Montgomery in correct position.

The T-tube according Montgomery serves to bridge tracheal stenoses in the presence of a tracheotomy.

Polyflex®-Stent

The application of a Polyflex® stent is made with a special application system (Fa. Rüsch®). The stent is produced from silicone with a polyester meshwork and is X-ray shadow giving. The Polyflex® stent includes a stent loader with an insertion tube (Figures 37, 38). Suitable stent dimensions are: diameter: 8-22 mm; length: 2-8 cm.

The most frequently and dangerous complications of anaesthesia (SHFJV) and surgery for patients with airway pathology and stent insertion are listed in Table 5. Bleeding can occur from the underlying pathology or manipulation of the laryngoscope or when tissue is ablated (e.g. by laser). If bleeding originates from friable tissue a significant compromise of ventilation results. Then rapid suction is as necessary as the control of bleeding which requires a variety of interventions, including epinephrine solution, tamponade with a bronchoscope or balloon-

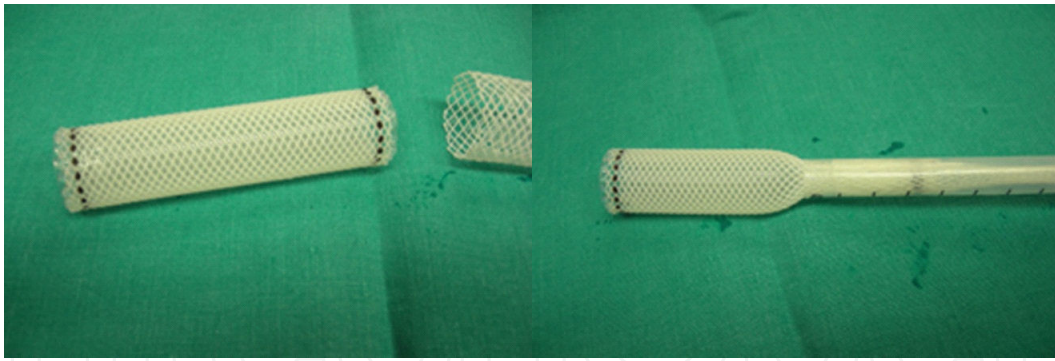


Figure 37. Polyflex®-stent in regular size (left) and after potential expansion with the stent-loader (right). The stent loader can be placed through each jet laryngoscope.

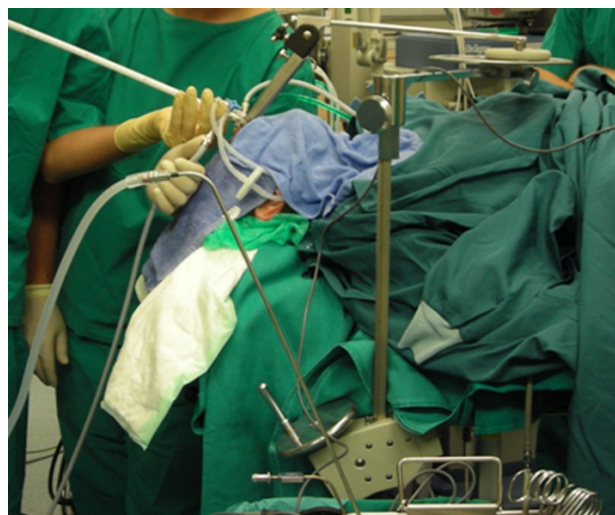

Figure 38. Application of a Polyflex® stent with a stent loader under superimposed jet ventilation. The patient is ventilated continuously by the jet laryngoscope. The stent loader can be adapted and placed into the trachea passing the jet laryngoscope.

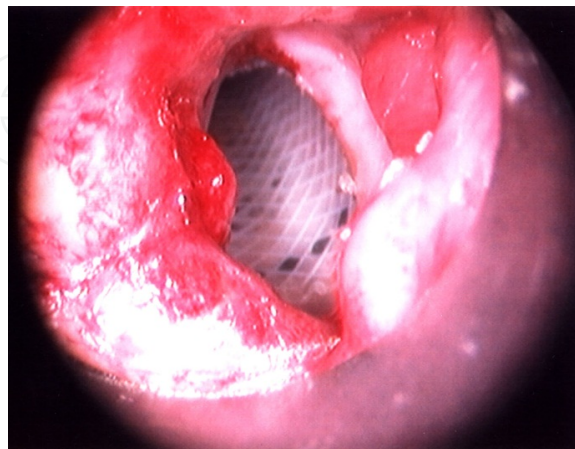


Figure 39. Tracheal stent (Polyflex®-stent) in the trachea.

tipped catheter. Pieces of necrotic or fragmentary tissue as well as clots from bleeding can block the distal airway. SHFJF is not to be interrupted when they are removed. Airway perforation can be caused by the manipulation at the walls of the trachea or bronchii when the stent is inserted, a subcutaneous emphysema results. An injury of the inner larynx, especially the vocal chords, happens prevalently when difficulties of insertion of the laryngoscope tube occur and is rarely severe.

A barotrauma occurs suddenly when a mass causes a ball-valve effect or in a distal airway the route of air exit is blocked by a mass and the air pushed behind causes a tension pneumothorax. Typical signs are absence of chest excursion, sudden tachycardia and hypotension. A rapid decompression to prevent a cardiovascular collapse is essential.

The occurrence of inadequate oxygenation and ventilation are always to be observed and this is best to be done by strictly attention to a loud pulsoxymeter which allows quickly an adequate reaction and correction.

Complications of tracheobronchial stent insertion	
Acute complications	Long-term complications
Bleeding	Displacement of the stent
Occlusion	Granulation tissue
Perforation	Mucosa impaction of the stent
Vocal chord injury	Oesophagotracheal fistula
Subcutaneous emphysema	
Pneumothorax	
Hypoxaemia	
Hypercapnia	

Table 5. Complications of tracheobronchial stent insertion.

The application of the described stents like silicone stents, wall stents and Polyflex® stents via the jet laryngoscope enables the surgeon due to the excellent field conditions a fast and safe intervention (Figure 39). The anaesthesiologist takes care of an unproblematic ventilation. A ventilation caused barotrauma under supraglottic jet ventilation did not occur in any case at our department. Inside the jet laryngoscope a continuous ventilation pressure measurement with pressure limitation under connection to the respirator is conducted.

9. High-frequency ventilation techniques in adult respiratory distress syndrom (ARDS)

The high frequency ventilation is characterized as a type of artificial respiration where low tidal volume is applicated with a hyper-physiological frequency. Different types of high-frequency jet ventilations were developed and used in the last 30 years [110]. From the numerous potential

applicable types of high-frequency ventilations like High-Frequency-Pulsation (HFP), Forced Diffusion Ventilation (FDV) [111, 112] and High Frequency Jet Ventilator (HFJV) only the High Frequency Positive Pressure Ventilation (HFPP), the High Frequency Jet Ventilation (HFJ), the High Frequency Oscillation (HFO) and combined high-frequency ventilation techniques became widely accepted and are used in clinical field (Table 7).

9.1. Theoretical advantages of the high-frequency ventilation

From the aspect of a lung protective ventilation with the option to reduce the end-inspiratory lung volume the risk of ventilation-induced damage of lungs [113] when conventional ventilation is performed should be reduced by the high- frequency ventilation.

However higher end-expiratory lung volumes can be applied [114]. Simultaneously these tidal volumes are transferred with only marginally pressure variations at a higher frequency and thus the average airway pressure is to be kept at a higher level as it is in conventional ventilation. The high average airway pressure seems to optimize the end-expiratory lung volume and is protective against the periodic collapse and therefore also avoiding an atalectatic trauma. The perfect mode of application of high-frequency ventilation should permit lung recruitment manoeuvre and thereby shifting the lung under optimizing of the compliance and oxygenation to the expiratory arm of the pressure/volume relationship. The opened lung is ventilated then with small-sized tidal volumes and slight fluctuation of pressure. This results also in a diminished alveolar distension and a reduced collapse of alveolar tissue. In an experimental laboratory animal study the high-frequency oscillation shows in comparison to a lung protective conventional ventilation an attenuation of activation of alveolar macrophages and neutrophils in lung injury [115].

Clinical indications for high frequency ventilation
Bronchopulmonary fistula
All types of pulmonary reduction of ventilation with no improvement under conventional ventilation therapy
Atalectasis
Pneumonia
Acute lung insufficiency (ALI)
Adult respiratory distress syndrome (ARDS)
Inhalation injury

Table 6. Clinical indications for high-frequency ventilation in adult distress syndrom (ARDS).

9.2. High-frequency oscillatory ventilation (HFO)

Lunkenheimer and co-workers observed already 1994 [116] that normocapnea can be achieved when small gas volumes rates are applicated into the airway of animals with a ventilation frequency of more than 40 Hertz. Using a piston pump sinus-like variations of pressure are

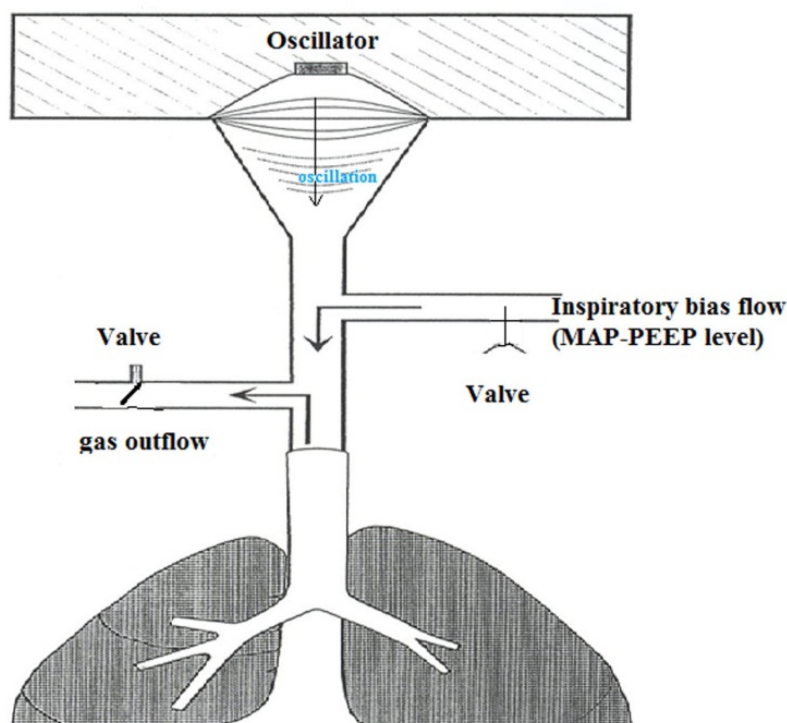


Figure 40. A piston pump puts an oscillation membrane in vibration.

produced and directed into the lungs (Figure 40). An auxiliary flow of gas (bias-flow) crosses the oscillating gas flow to provide fresh gases. This was followed by the application and further developments of the high frequency oscillation with numerous clinical applications. Although the high frequency oscillation has established in paediatrics it could not be implemented in adults with ARDS because of limited elimination of CO_2 . With the improvement of the technical devices this problem of CO_2 elimination could be resolved.

High-frequency oscillation differs from high-frequency jet ventilation by the fact that in addition to the inspiration the expiration is also active, the tidal volume is less.

The frequencies could be higher, however, they are today similar to the jet ventilation usually under 10 Hz. Recently the interest in the high-frequency oscillation has risen again especially for the acute respiratory distress syndrome. The high-frequency pressure oscillations allow the use of a high mean airway pressure to achieve a recruitment of atelectatic lung tissue. At the same time the high mean airway pressure prevents a collapse of lung tissue and high peak airway pressure during inspiration can be avoided.

Different mechanisms of gas transport have been described, like: direct alveolar ventilation in the lung units situated near the airway opening, bulk convective mixing in the conducting convective transport of gases as a result of the asymmetry between inspiratory and expiratory velocity profiles, longitudinal dispersion caused by the interaction between axial velocities and radial transports due to turbulent eddies, molecular diffusion near the alveolo-capillary membrane [117].

9.3. Parameters to be adjusted on the apparatus for high frequency oscillatory ventilation (Figure 41)

Oscillations frequency

3-15 f = Hz

Inspiratory time (I:E) of the pulsation (a single breath cyclus) in %:

33-50%

Mean airway pressure (MAP - Paw = PEEP – post end-expiratory pressure):

3-55 cm H₂O

Oscillation pressure –amplitude –delta P:

up to 10 cm H₂O

Bias flow:

0-60L/min

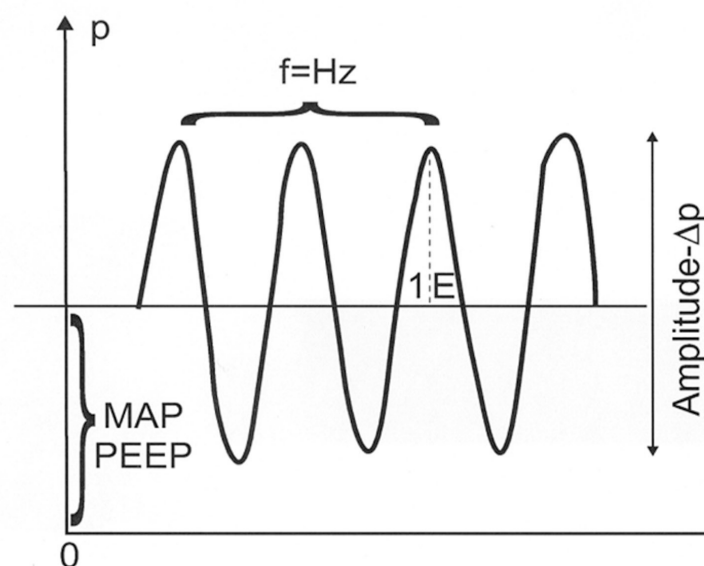


Figure 41. Parameters to be adjusted on the apparatus for high-frequency oscillatory ventilation.

9.4. Combined high-frequency ventilation (CHFJV)

At the first time in 1983 El-Baz et al. introduced the Combined High Frequency Ventilation Technique [118]. Two types of high-frequency ventilation (HFPPV and HFO) were combined.

At a basic frequency of 60 breaths per minute high-frequent gas pulses up to 3000 were superimposed. Further developments combined different types of high frequency ventilation.

The application of an additive, mostly conventional breath with an enlarged tidal volume enables the enhancement of CO₂ elimination. A disadvantage is the usually need of combination of two devices.

Author	Frequency (LF/HF)	Mode (Combination)
El Baz et al. [118]	60/3000	HFPPV HFO
Yeston et al. [119]	2/250	IMV HFO
Keszler et al. [120]	5-7/200	IMV HFJV
Boynton et al. [121]	5-10/1200	IMV HFO
Barzilay et al. [122]	1-5/130-170	IMV HFPPV
Borg et al. [123]	15-20/900-1200	PCV HFO
Jousela et al. [124]	15/360	CMV HFV

Table 7. Authors and their use of combinations of predominately conventional types of ventilation with different high-frequency ventilation techniques. HFPPV... High-Frequency Positive Pressure Ventilation; HFO... High-Frequency Oscillation; IMV... (Intermittend mandatory Ventilation); HFJV... High- Frequency Jet Ventilation; PCV... (Pressure Controlled Ventilation); CMV... (Controlled Mechanical Ventilation); HFV... (High-Frequency Ventilation).

9.5. High-frequency percussive ventilation

Can be considered as a special type of the combined high-frequency ventilation. The high-frequency jet pulse produced by the respirator are superimposed by a apparently conventional pressure controlled higher pressure plateau. A pulsatile jet ventilation with two different high pressure plateaus is generated by only one respirator (Figure 42).

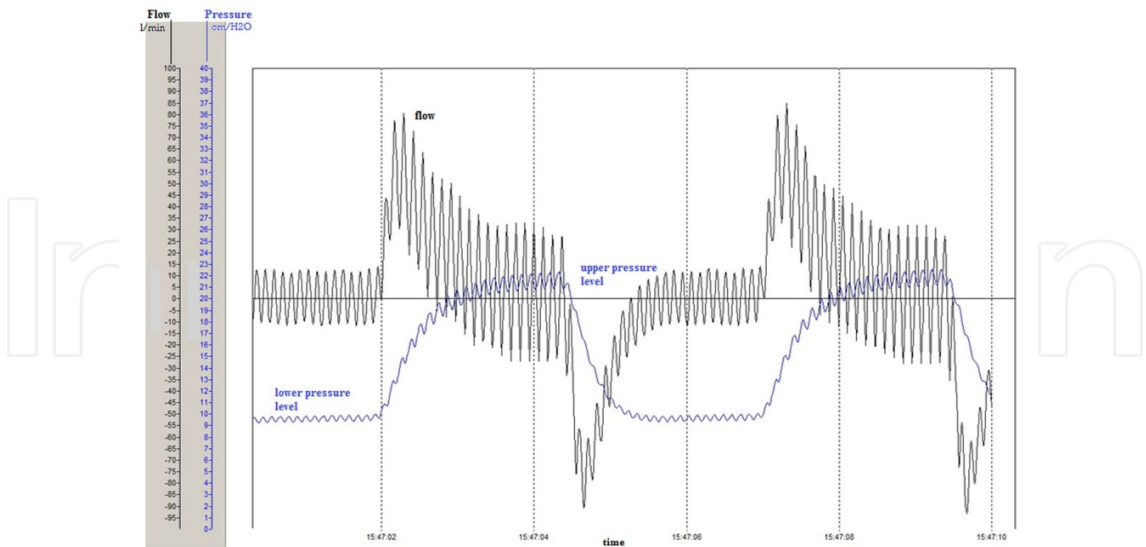


Figure 42. Characteristics of pressure and flow during ventilation with the VDR-4 ventilator. Peak airway pressure: 21 cm/H₂O; PEEP: 9 cm/H₂O; low-frequency: 12 cycles/min; high-frequency 500 cycles/min; inspiration:expiration ratio = 1:2.

Phasitron® (Percussionaire® Corporation, Sandpoint, Idaho, USA)

The gas delivered by the respirator is first transmitted to the so-called Phasitron® (Figure 43) where its augmentation of volume, humidification and warming takes place.

The mobile Venturi-body in the Phasitron® is moved forward in the inspiratory phase. This causes a closure of the expiratory aperture and now warmed-up and moisturized air is sucked in by the jet effect.

This prepared column of air lying in front of the Phasitron® is now applied to the lung according to the jet frequency.

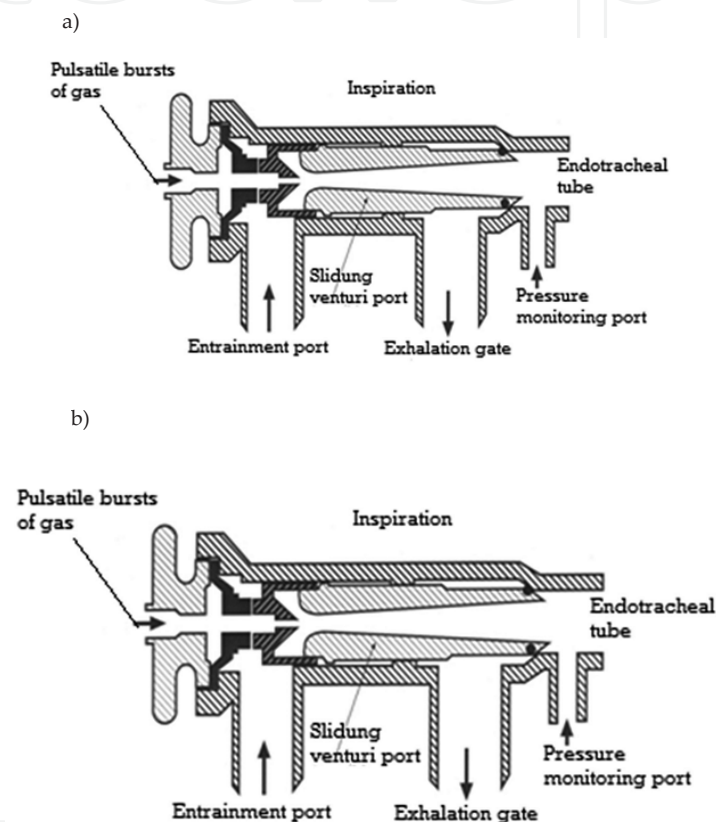


Figure 43. Phasitron®: movement of the Venturi-body during a) inspiration and b) expiration. During the inspiration moistened and warmed air is drawn in by the entrainment port. During the expiration the entrainment port is closed.

9.6. Clinical experiences with high-frequency ventilation

9.6.1. High-frequency oscillatory ventilation

The high-frequency oscillatory ventilation is recently moved in the centre of interest especially for application at the acute lung failure [125]. However bronchopulmonary fistulas are indications for this method [126] and from the theoretical point of view for all purposes of lung protection. Without controversy high-frequency oscillatory ventilation is applied in paediatric intensive care since a longer period and has become a routine method.

The best references for their indicated application at ARDS results from two prospective studies [127, 128] and a retrospective clinical trial with application of high-frequency oscillation in combination with a recruitment manoeuvre [129], all showing significantly increase of oxygenation in comparison to conventional ventilation.

9.6.2. *Combined high-frequency jet ventilation (CHFJV)*

The use of the conventional part of ventilation with low ventilation frequencies with conventional PEEP but higher volume tides guarantees a sufficient CO₂ elimination.

A high-frequent ventilation mode superimposes the conventional mode. Predominantly the oxygenation is enhanced by the high-frequent pulsatile fraction of ventilation.

9.6.3. *High-frequency percussive ventilation*

In literature concerning the implementation of the high-frequency percussive ventilation in patients with acute lung failure was reduced over a long period to paediatric and adult. More descriptions exist about successful application in patients with ARDS, after inhalation trauma and traumata [130]. In paediatric patient population with an inhalation trauma a lower rate of infection and mortality could be observed. Surprisingly a greater extent of departments apply the high-frequency percussive ventilation in clinical use even though they do not publicize their results.

9.6.4. *High-frequency jet ventilation*

The high-frequency jet ventilation has become widely accepted in operative interventions in the larynx and trachea. Optimal working conditions with best view for the surgeons are achieved under the application of thin jet catheter and the absence of an endotracheal tube.

Application of high-frequency ventilation in intensive care units in premature patients with respiratory distress syndrome and interstitial pulmonary emphysema is a safe procedure and diminishes peak pressures. In relation to the outcome and mortality from the high-frequency jet ventilation did not derive a benefit in comparison to conventional ventilation.

The exclusive application of high-frequency jet ventilation in adults did not prevail. Usually is is applied as combined high-frequency jet ventilation in cases when the conventional ventilation fails. The literature refers only about case reports or not randomized trials with few cases. However it demonstrates that these ventilation techniques are in use, although expensive, safe in application with a high potential to increase the oxygenation.

9.6.5. *Superimposed high-frequency jet-ventilation (SHFJV)*

SHFJV is a special type of combined high-frequency ventilation. A respirator produces a low-frequent jet ventilation with a higher pressure level. Simultaneously a superposition with a high-frequent jet ventilation takes place which ensures for itself alone a lower plateau of pressure analogous a positive end-expiratory pressure (PEEP). Only one respirator generates these two plateaus of pressure. This ventilation technique is primarily used in the operative

area of otorinolaryngology, but this Ventilation can be applied also due to ventilation technique of the respirator in the intensive care unit. So we could show in a clinical study [131] that this ventilation technique can lead to a quicker recruitment of the lungs in patients with a respiratory insufficiency. However, further studies are necessary to make more precise and definitive statements.

9.6.6. Potential effects of high-frequent ventilation techniques

First clinical results show that under high-frequency ventilation potentially a fast recruitment of dependent areas of the lung occurs without a simultaneous massive overexpansion of non-dependent areas of the lungs. It is conceivable that the under high-frequency ventilation observed enhanced gas exchange is not so much to be explained by mechanism of increasing diffusion but by pulsatile mechanism leading to a fast recruitment of lung tissue.

Acknowledgements

The authors thank Mr. Heinrich Reiner from the Carl Reiner Corp. in Vienna, Austria, for his understandingful and dynamic help in implementation and propagation of our jet ventilation program at the Medical University of Vienna. Mr. Reiner supported not only the clinical and practical issues but also the scientific ones.

Author details

Alexander Aloy^{1*} and Matthaëus Grasl²

*Address all correspondence to: alexander@aloy.co.at, matthaëus.grasl@meduniwien.ac.at

1 Department of Anaesthesia and General Intensive Care Medicine, Vienna, Austria

2 Department of Otorhinolaryngology, Head & Neck Surgery, Vienna, Austria

This chapter deals with the history of laryngoscopy and the fruitful scientific and clinical collaboration of anaesthesiologists and laryngologists in development and application of jet ventilation for surgical laryngotracheal interventions via a rigid laryngoscope.

References

- [1] Bozzini, Ph. Der Lichtleiter oder die Beschreibung einer einfachen Vorrichtung innerer Höhlen und Zwischenräume des lebenden animalischen Körpers. Weimar: Verlag des Industrie Compoir; (1807).

- [2] Mende, L. Von der Bewegung der Stimmritze beym Athemholen; eine neue Entdeckung; mit beygefügtten Bemerkungen über den Nutzen und die Verrichtung des Kehlsdeckels. Greifswald; (1916).
- [3] Mackenzie, M. The Use of the Laryngoscope in Diseases of the Throat. Philadelphia: Lindsay and Blaciston; (1865).
- [4] Babington, B. Report of the Huntarian Society. The London Medical Gazette. (1829); 3:565.
- [5] Garcia, M. Observations on the Human Voice. Proceedings of the Royal Society of London, (1855);7:397-410.
- [6] Türk, L. Kehlkopfspiegel und die Methode seines Gebrauchs. Z Ges Ärzte zu Wien. (1858);26:401-409.
- [7] Helmholtz von H. Beschreibung eines Augenspiegels zur Untersuchung der Netzhaut im lebenden Auge; Berlin.. Translation in Arch Ophthalmol. (1951);46:565-583.
- [8] Czermak JN. Über den Kehlkopfspiegel. Wiener Med Wschr. (1858);8:196-198.
- [9] Oertel MJ. Das Laryngo-stroboskop und die laryngostroboskopische Untersuchung. Arch Laryngorhinologie. (1985);3:1-16.
- [10] Morton W. Remarks on the Proper Mode of Administering Sulfuric Ether by Inhalation. Dutton and Wentworth; (1847).
- [11] Lister J. On the Antiseptic Principle of Surgery. The British Medical Journal (1867); 351:245-260.
- [12] Jelinek E. Das Cocain als Anästhetikum für den Pharynx und den Larynx. Wiener Med Wschr. (1934);34:1334-1337 and 1364-1367.
- [13] Miller RA. A new laryngoscope. Anaesthesiology. (1941);7:205-206.
- [14] Macintosh RR. New Inventions. A new laryngoscope. Lancet. (1943);241:205.
- [15] Tobold A. Lehrbuch der Laryngoskopie. Berlin; August Hirschwald Verlag, (1869).
- [16] Kirstein, A. Autoskopie des Larynx und der Trachea (Laryngoscopia directa, Euthyskopie, Besichtigung ohne Spiegel). Archiv für Laryngologie und Rhinologie. (1895); 3:156-164.
- [17] Kollofrath O. Entfernung eines Knochenstücks aus dem rechten Bronchus auf natürlichem Wege und unter Anwendung der directen Laryngoskopie. Münch Med Wschr. (1897);38: 1038-1039.
- [18] Killian G. Die Schwebelaryngoskopie. Archiv für Laryngologie und Rhinologie. (1912);26:277-317.

- [19] Brünings W. Direct Laryngoscopy: Criteria determinating the applicability of auto-scopy. Direct laryngoscopy, bronchoscopy and esophagoscopy. London: Bailliere, Tindall, Cox; (1912);93-95.
- [20] Hartmann A. Zur Behandlung der Larynxtuberkulose. In: Hoffmann R (Hrsg) Verh d Vereins dt Laryngologen 1908-1912. Würzburg: Kabitsch; (1913).
- [21] Holinger P. A new anterior commissure laryngoscope. Ann Otol Rhinol Laryngol. (1947);56:437-440.
- [22] Kleinsasser O. Larynx-Microscope for Early Diagnosis and Differential-Diagnosis for Carcinoma of the Larynx, Pharynx and Oral Cavity. Z Laryng Rhinol. (1961); 40:276-279.
- [23] Jako GJ. Laryngoscope for microscopic observation, surgery and photography. The development of an instrument. Arch Otolaryngol (1970);91:196-199.
- [24] Strong MS. Microscopic laryngoscopy. A review and appraisal. Laryngoscope. (1970);80:1540-1552.
- [25] Weerda H, Pedersen P, Meuret G, Wehmer H, Braune H. A new laryngoscope for endolaryngeal microsurgery. A contribution to inject respiration. Arch Otolaryngol. (1979);225:103-106.
- [26] Hopkins, HH. The Application of Frequency Response Techniques in Optics. Proceedings of the Physical Society. (1962);79(5): 889-896.
- [27] Volhard F. Über die künstliche Beatmung durch Ventilation der Trachea und eine einfache Vorrichtung zur rhythmischen künstlichen Atmung. Münch Med Wschr. (1908);55:209-211.
- [28] Meltzer SJ, Auer J. Continuous respiration without respiration movements. J Exp Med. (1909);11:622-625.
- [29] Barth L. Thearpeutic use of diffusion breathing in bronchoscopy. Anaesthetist. (1954);3(5) 227-229.
- [30] Sanders RD. Two ventilatory attachments for bronchoscopes. Del Med J. (1967); 39:170-176.
- [31] Gebert E, Deilman M, Pedersen P. Inject-ventilation in bronchoscopy. Anaesthetist. (1979);28(8) 378-389.
- [32] Lee S. A ventilating laryngoscope for inhalation anaesthesia and augmented ventilation during laryngoscopic procedures. Br. J Anaesth. (1972);44(8) 874-878.
- [33] Bradley JL, Moyes RN, Parke FW. Modifications of Sanders` technique of ventilation during bronchoscopy. Thorax. (1971);26(1) 112-114.

- [34] Lunkenheimer PP, Raffenbeul W, Keller H, Frank I, Dickhut HH, Fuhrmann C. Application of transtracheal pressure oscillations as modification of "diffusion respiration". *Br Anaesth.* (1972);44(6) 627-633 .
- [35] Lunkenheimer PP, Frank I, Ising H, Keller H, Dickhut HH, Fuhrmann C. Intrapulmonary gas exchange during simulated apnea due to transtracheal periodic intrathoracic pressure changes. *Anaesthesist* (1973);22(5):232-238.
- [36] Bohn DJ, Mijasaka K, Marchak BE, Thomson WK, Froese AB, Bryan AC. Ventilation by high-frequency oscillation. *J Appl Physiol* (1980);48(4) 710-716.
- [37] Sjöstrand U. Review of the physiological rationale for and development of high-frequency positive pressure ventilation. *Acta Anaesth Scand [Suppl.]* (1977);64:7-27.
- [38] Sjöstrand U. High-frequency positive pressure ventilation (HFPPV): a review. *Crit Care Med* (1980);8(6) 345-364.
- [39] Smith RB, Lindholm CE, Klain M. Jet ventilation for fiberoptic bronchoscopy under general anaesthesia. *Acta Anaesthesiol Scand.* (1976);20(2) 111-116.
- [40] Babinski M, Smith RB, Klain M. High-frequency jet ventilation for laryngoscopy. *Anesthesiology.* (1980);52(2) 178-180.
- [41] Klain M, Kezler H. High-frequency jet ventilation. *Surg Clin North Am.* (1985);65(4) 917-930.
- [42] Aloy A, Schachner M, Spiss CK, Cancura W. Tube-free translaryngeal superposed jet ventilation. *Anaesthesist.* (1990);39(19) 493-498.
- [43] Kleinsasser O. *Microlaryngoscopy and endolaryngeal microsurgery.* Philadelphia: WB Saunders & Co; (1968).
- [44] Jako GJ. Laryngoscope for microscopic observation, surgery and photography. *Arch Otol.* (1970);91(2) 196-199.
- [45] Strong MS. Microscopic laryngoscopy. A review and appraisal. *Laryngoscope.* (1970);80(10) 1540-1552.
- [46] Weerda H, Pedersen P, Meuret G, Wehmer H, Braune H. A new laryngoscope for endolaryngeal microsurgery. A contribution to inject respiration. *Arch Otolaryngol.* (1979);225:103-106.
- [47] Ono J, Saito S. Endoscopic microsurgery of the larynx. *Ann Otol Rhinol Laryngol.* (1971);80(4) 479-86.
- [48] Thomas GK. Suspension apparatus for laryngeal microsurgery. *Arch Otolaryngol.* (1971);94(3) 258-259.
- [49] Steiner W, Ambrosch P. *Endoscopic Laser surgery of the upper aerodigestiv tract. With special emphasis on cancer surgery.* Stuttgart/New York: Thieme; (1997).

- [50] Cohen SR, Thompson JW. Use of botulinum toxin to lateralize true vocal cords: a biochemical method to relieve bilateral abductor vocal cord paralysis. *Ann Otol Rhinol Laryngol.* (1987);96(4) 534-541.
- [51] Aloy A, Schachner M, Cancura W. Tubeless translaryngeal superimposed jet-ventilation. *Eur Arch Otorhinolaryngol.* (1991);248(8) 475-478.
- [52] Ng A, Russell WC, Harvey N, Thompson JP. Comparing methods of administering high frequency jet ventilation in a model of laryngotracheal stenosis. *Anesth Analg.* (2002);95(3): 764-769.
- [53] Aloy A, Schachner M, Spiss CK, Cancura W. Tube-free translaryngeal superimposed jet ventilation. *Anaesthesist.* (1990);39(10) 493-498.
- [54] Kleinsasser Operations Laryngoskop; Zepf. Medical Instruments; Germany Tuttlingen
- [55] Aloy A, Schragl E, Neth H, Donner A, Kluwick A. Flow pattern of respiratory gases in superimposed high-frequency jet ventilation (SHFJV) with the jet laryngoscope. *Anaesthesist* (1995);44(6) 558-565.
- [56] Piquet J. *Turbulent Flows: Models and Physics.* Berlin-Heidelberg-New York: Springer Verlag; (2001).
- [57] Halder G. *Introduction to chemical engineering thermodynamics.* New Dehli: Book Vistas, PHI:learning; (2009).
- [58] Winterbone D.E. *Advanced Thermodynamics for Engineers;* Oxford: Butterworth Heinemann; An imprint of Elsevier Science (2002).
- [59] Leiter R, Aliverti A, Priori R, Staun P, Lo Mauro A, Larsson A, Frykholm P. Comparison of superimposed high-frequency jet ventilation with conventional jet ventilation for laryngeal surgery. *Br J Anaesth.* (2012);108(4):690-698.
- [60] Lanzenberger-Schragl E, Donner A, Grasl M, Zimpfer M, Aloy A. Superimposed High-Frequency Jet Ventilation for Laryngeal and Tracheal Surgery. *Arch Otolaryngol Head Neck Surg.* (2000);126:40-44.
- [61] Rezaie-Majd A, Bigenzahn W, Denk DM, Burian M, Kornfehl J, Grasl MCh, Ihra G, Aloy A. Superimposed high-frequency jet ventilation (SHFJV) for endoscopic laryngotracheal surgery in more than 1500 patients. *Br J Anaesth.* (2006);96(5):650-9. Epub 2006 Mar 30.
- [62] Nowak A, Langebach R, Klemm E, Heller W. Percutaneous dilational tracheostomy (PDT) and prevention of blood aspiration with superimposed high-frequency jet ventilation (SHFJV) using the tracheostomy-endoscope (TED): results of numerical and experimental simulations. *Biomed Tech, Berlin.* (2012);57(2):107-111.
- [63] Aloy A, Schachner M, Spiss CK, Cancura W. Tube-free translaryngeal superposed jet ventilation. *Anaesthesist.* (1990);39(10) 493-498.

- [64] Lanzenberger-Schragl E, Donner A, Grasl MC, Zimpfer M, Aloy A. Superimposed high-frequency jet ventilation for laryngeal and tracheal surgery. *Arch Otolaryngol Head Neck Surg.* (2000);126(1) 40-44.
- [65] Rezaie-Majd A, Bigenzahn W, Denk DM, Burian M, Kornfehl J, Grasl MCh, Ihra G, Aloy A. Superimposed high-frequency jet ventilation (SHFJV) for endoscopic laryngo-tracheal surgery in more than 1500 patients. *Br J Anaesth.* (2006);96(5) 650-569.
- [66] Jaquet Y, Monnier P, Van Melle G, Ravussin P, Spahn DR, Chollet-Rivier M. Complications of different ventilation strategies in endoscopic laryngeal surgery. A 10-year review. *Anaesthesiology.* (2006);104(1) 52-59.
- [67] Rampii IJ. Anaesthesia for laser surgery. In Miller RD, ed. *Miller's Anesthesia.* 7 th ed. Philadelphia: Churchill Livingstone; (2010); p2405-2418.
- [68] Wöllmer W, Schade G, Kessler G. Endotracheal tube fires still happen – a short overview. *Med Laser Appl.* (2010);25(2) 118-25.
- [69] Burian K, Höfler H. On microsurgical treatment of vocal cord carcinomas with CO₂-laser. *Laryngol Rhinol Otol.* (1979);58(7) 551-556.
- [70] Strong MS. Laser excision of carcinoma of the larynx. *Laryngoscope.* (1975); 85:1286-1289.
- [71] Steiner W, Ambrosch P. Laser microsurgery for laryngeal carcinoma. In: Steiner W, Ambrosch P. (ed.) *Endoscopic Laser Surgery of the Upper Aerodigestive Tract.* New York: Thieme; (2000); p47-82.
- [72] Thurnher D, Erovic BM, Frommlet F, Brannath W, Ehrenberger K, Jansen B, Selzer E, Grasl MC. Challenging a dogma--surgery yields superior long-term results for T1a squamous cell carcinoma of the glottic larynx compared to radiotherapy. *Eur J Surg Oncol.* (2008);34(6) 692-698.
- [73] Grasl M.C, Donner A, Schragl E, Aloy A. Tubeless laryngotracheal surgery in infants and children via jet ventilation laryngoscope. *Laryngoscope.* 1997;107(2) 277-281.
- [74] Aloy A, Schachner M, Cancura W. Tubeless translaryngeal superimposed jet ventilation. *Eur Arch Otorhinolaryngol.* (1991);248(8):475-478.
- [75] Ossoff RH, Tucker JA, Werkhaven JA. Neonatal and pediatric microsubglottiscope set. *Otol Rhinol Laryngol.* (1991);100(4) 325-326.
- [76] Bourgain JL, Desruennes E, Fischler M, Ravussin P. Transtracheal high frequency jet ventilation for endoscopic airway surgery: a multicentre study. *Br J Anaesth.* (2001); 87(6) 870-875.
- [77] Ravussin P, Bayer-Berger M, Monnier P, Savary M, Freeman J. Percutaneous transtracheal ventilation for laser endoscopic procedures in infants and small children with laryngeal obstruction: report of two cases. *Can J Anaesth.* (1987);34(1) 83-86.

- [78] Depierraz B, Ravussin P, Brossad E, Monnier P. Percutaneous transtracheal jet ventilation for paediatric endoscopic laser treatment of laryngeal and subglottic lesions. *Can J Anaesth.* (1994);41(12) 1200-1207.
- [79] Ross-Anderson D.J, Ferguson C, Patel A. Transtracheal jet ventilation in 50 patients with severe airway compromise and stridor. *Br J Anaesth.* (2011);106(1) 140-144.
- [80] Grasl M.C, Donner A, Schragl E, Aloy A (1997) Tubeless laryngotracheal surgery in infants and children via jet ventilation laryngoscope. *Laryngoscope.* (1997);107(2) 277-281.
- [81] Mausser G, Friedrich G, Schwarz G. Airway management and anesthesia in neonates, infants and children during endolaryngotracheal surgery. *Paediatr Anaesth.* (2007); 17(10) 942-947.
- [82] Ihra G, Hieber C, Adel S, Kashanipour A, Aloy A. Tubeless combined high-frequency jet ventilation for laryngotracheal laser surgery in paediatric anaesthesia. *Acta Anaesthesiol Scand.* (2000);44(4) 475-479.
- [83] Tan SS, Dhara SS, Sim CK. Removal of a laryngeal foreign body using high frequency jet ventilation. *Anaesthesia.* (1991);46(9) 741-3.
- [84] Derkay CS, Faust RA. Recurrent respiratory papillomatosis. In: Flint PW, Haughey BH, Lund VJ, et al. eds. *Cummings Otolaryngology: Head & Neck Surgery.* 5 th ed. Philadelphia: Mosby; (2010); p2884-2885.
- [85] Derkay CS. Recurrent respiratory papillomatosis. *Laryngoscope.* (2001);111(1) 57-69.
- [86] Weisberger EC, Miner JD. Apneic anaesthesia for improved endoscopic removal of laryngeal papillomata. *Laryngoscope.* (1988);98(7) 693-697.
- [87] Drenger B, Zidenbaum M, Reifen E, Leitersdorf E. Severe upper airway obstruction and difficult intubation in cicatricial pemphigoid. *Anaesthesia* (1986);41(10) 1029-1031.
- [88] Hallenborg C, Rowe LD, Gamsu G, Boushev HA, Golden JA. Severe upper airway obstruction caused by bullous pemphigoid: diagnostic usefulness of the flow-volume curve. *Otolaryngol Head Neck Surg.* (1982);90(1):20-24.
- [89] Monniere Ph, editor. *Pediatric Airway surgery. Management of laryngotracheal stenosis in infants and children.* New York: Springer; (2011).
- [90] Schragl E, Donner A, Kashanipour A, Gradwohl I, Ullrich R, Aloy A. Anesthesia in acute respiratory tract obstructions caused by high grade degree laryngeal and tracheobronchial stenosis. *Anaesthesiol Intensivmed Notfallmed Schmerzther.* (1994); 29(5) 269-277.
- [91] Schragl E, Donner A, Grasl MC, Kashanipour A, Aloy A. Beatmung während einer Tracheotomie bei langstreckiger 90% iger laryngealer Stenose mittels superponierter

- Hochfrequenz Jet-Ventilation über das Jet-Laryngoskop. *Laryngorhinootologie*. (1995);74(4) 223-226.
- [92] Cotton RT. Management of subglottic stenosis. *Otolaryngol Clin North Am* (2000); 33(1) 111-130.
- [93] Aloy A, Kimla T, Schragl E, Donner A, Grasl M. (1994) Tubeless superimposed high frequency jet ventilation in high grade laryngeal stenosis. *Laryngorhinootologie* (1994);73(8) 405-411.
- [94] Olak J, Rosenberg S. Simple technique for sizing and positioning tracheal stents. *Ann Thorac Surg*. (2000);70(4) 1389-1390.
- [95] Wassermann K, Eckel HE, Michel O, Mueller RP. Emergency stenting of malignant obstruction of the upper airways: long-term follow-up with two types of silicone prosteses. *Ann Otol Rhinol Laryngol* (1998);107(2) 149-154.
- [96] Saito Y, Imamura H. Airway stenting. *Surg Today* (2005);35(4) 265-270.
- [97] Wood DE. Airway stenting. *Chest Surg Clin N Am* (2001);11(4) 841-860.
- [98] Shin JH. Interventional management of tracheobronchial strctures. *World Journal of Radiology*. (2010);2(8) 323-328.
- [99] Bourgain JL, Desruennes E, Fischler M, Ravussin. Transtracheal high frequency jet ventilation for endoscopic airway surgery: a multcenter study. *Br J Anaesth* (2001); 87(6) 870-875.
- [100] Aloy A, Donner A, Strasser K, Klepetko W, Schragl E, Taslimi R, Rotheneder E, Kashanipour A. Jet ventilation superimposed on a special jet laryngoscope for endoluminal stent insertion in the tracheobronchial system. *Anaesthesist*. (1994);43(4) 262-269.
- [101] Eckel HE, Berendes Sh, Damm M, Klusmann JP, Wassermann K. Suspension laryngoscopy for endotracheal stenting. *Laryngoscope* (2003);113(1) 11-15.
- [102] Baraka AS, Siddik SS, Taha SK, Jalbout MI, Massouh FM. Low frequency jet ventilation for stent insertion in a patient with tracheal stenosis. *Can J Anaesth* (2001);48(7) 701-704.
- [103] Brodsky JB. Anesthesia for pulmonary stent insertion. *Curr Opin Anaesthesiol*. (2003);16(1) 65-67.
- [104] Klepetko W, Müller MR, Grimm M, Aloy A, Kashanipour A, Wisser W, Eckersberger F, Wolner E. doluminale Schienung (Stenting) bei Stenosen des Tracheobronchialsystems. *Acta Chirurgica Austriaca*. (1991);23(3)124-129 .
- [105] Choudhury M, Saxena N. Total intravenous anaesthesia for tracheobronchial stenting in children. *Anaesth Intensive Care* (2002);30(3) 376-379.

- [106] Wassermann K, Eckel HE, Michel O, Mueller RP. Emergency stenting of malignant obstruction of the upper airways: long-term follow-up with two types of silicone prostheses. *J Thorac Cardiovasc Surg* (1996);112(4) 859-66.
- [107] Ernst A, Majid A, Feller-Kopman D, Guerrero J, Boisele P, Loring SH, O'Donnel C, Decamp M, Herth FJ, Gangadharan S, Ashiku S. Airway stabilisation with silicone stents for treating adult tracheorachomalacies. *Chest* (2007);132(2) 609-916.
- [108] Montgomery WW. T-tube tracheal stent. *Arch Otolaryngol* (1965);82(5) 320-321.
- [109] Grillo HC. *Surgery of the trachea and bronchi*. London: B.C. Decker Inc.; (2004).
- [110] Froese AB, Bryan AC, High frequency ventilation. *Am Rev Respir Dis* (1987);135(6) 1363-1374.
- [111] Baum M, Benzer H, Geyer A, Haider W, Mutz N, Forced diffusion ventilation (FDV). Bases and clinical application. *Anaesthesist*. (1980);29(11) 586-591.
- [112] Baum M, Benzer H, Mutz N, Pauser G, Tonczar L. Inversed ratio ventilation (FDV). Role of the respiratory time ratio in artificial respiration in ARDS. *Anaesthesist* (1980); 29(11) 592-596.
- [113] Slutsky AS, Drazen JM, Ventilation with small tidal volumes. *N Engl J Med* (2002); 347(9) 630-631.
- [114] Krishnan JA, Brower RG. High-frequency ventilation for acute lung injury and ARDS. *Chest* (2000);118(3) 795-807.
- [115] Shimaoku M, Fujino Y, Taenaka N, Hiroi T, Kiyono H, Yoshiya II. High frequency oscillatory ventilation attenuates the activation of alveolar macrophages and neutrophils in lung injury. *Crit Care* (1998);2(1) 35-39.
- [116] Lunkenheimer PP, Redmann K, Krebs S, Gleich C, Brasselet M, Scheld HH. Ventilation by high frequency oscillations in adults. An experimental study of conditions and methods. *Can Anesthesiol* (1994);42(3): 303-314.
- [117] Chang HK. Mechanisms of gas transport during ventilation by high-frequency oscillation. *J. App. Physiol.* (1984) 56(3):553-563.
- [118] El-Baz N, Penfield Faber L, Doolas A. Combined high-frequency ventilation for management of terminal respiratory failure: a new technique. *Anesth Analg.* (1983);62(1) 39-49.
- [119] Yeston NS, Grasberger RC, McCormick JR. Severe combined respiratory and myocardial failure treated with high-frequency jet ventilation. *Crit Care Med.* (1985);13(3): 208-209.
- [120] Keszler M, Donn SM, Spitzer AR. High-frequency jet ventilation in respiratory distress syndrome. *J Pediatr.* (1991);119(2):340-341.

- [121] Boynton BR, Mannino FL, Davis RF, Kopotic RJ, Friederichsen G. Combined high-frequency oscillatory ventilation and intermittent mandatory ventilation in critically ill neonates. *J Pediatr.* (1984);105(2):297-302.
- [122] Barzilay E, Kessler D, Raz R. Superimposed high frequency ventilation with conventional mechanical ventilation. *Chest.* (1989);95(3):681-682.
- [123] Borg UR, Stoklosa JC, Siegel JH, Wiles CE 3rd, Belzberg H, Blevins S, Cotter K, Laghi F, Rivkind A. Prospective evaluation of combined high-frequency ventilation in post-traumatic patients with adult respiratory distress syndrome refractory to optimized conventional ventilatory management. *Crit Care Med.* (1989);17(11):1129-1142.
- [124] Jousela I, Mäkeläinen A, Linko K. The effect of combined high frequency ventilation with and without continuous positive airway pressure in experimental lung injury. *Acta Anaesthesiol Scand.* (1992);36(6):508-512.
- [125] McLuckie A, Editorial II: High-frequency oscillation in acute respiratory distress syndrome (ARDS). *Brit J Anaesth* (2004);93(3) 322-324.
- [126] Ha DV, Johnson D. High frequency oscillatory ventilation in the management of a high output bronchopleural fistula: a case report. *Can J of Anesth* (2004);51(1) 78-83.
- [127] Mehta S, Lapinsky SE, Hallett DC, Merker D, Groll RJ, Cooper AB, MacDonald RJ, Stewart TE. Prospective trial of high-frequency oscillation in adults with acute respiratory distress syndrome. *Crit Care Med* (2001);29(7) 1360-1369.
- [128] Derdak S, Metha S, Steward T, Smith T, Rogers M, Buchmann T, Carlin B, Lowson S, Granton J and the multicenter oscillatory ventilation for acute respiratory distress syndrome TRIAL (MOAT) study investigators. High frequency oscillatory ventilation for acute respiratory distress syndrome in adults. *Am J Respir Crit Care Med* (2002);166(6) 801-808.
- [129] Ferguson ND, Chiche JD, Kacmarek RM, Hallett DC, Metha S, Findlay GP, Granton JT, Slutsky AS, Stewart TE, Combining high-frequency oscillatory ventilation and recruitment maneuvers in adults with early acute respiratory distress syndrome: the treatment with oscillation and an Open Lung Strategy (TOOLS) trial pilot study. *Crit Care Med* (2005);33(3): 479-486.
- [130] Cortiella J, Mlcak R, Herndon D. High frequency percussive ventilation in pediatric patients with inhalation injury. *J Burn Care Rehabil* (1999);20(3) 232-235.
- [131] Kraincuk P, Körmöcz G, Prokop M, Ihra G, Aloy A. Alveolar recruitment of atelectasis under combined high-frequency jet ventilation: a computed tomography study. *Intensive Care Med* (2003);29:1265-1272.