

We are IntechOpen, the world's leading publisher of Open Access books Built by scientists, for scientists

6,900

Open access books available

185,000

International authors and editors

200M

Downloads

Our authors are among the

154

Countries delivered to

TOP 1%

most cited scientists

12.2%

Contributors from top 500 universities



WEB OF SCIENCE™

Selection of our books indexed in the Book Citation Index
in Web of Science™ Core Collection (BKCI)

Interested in publishing with us?
Contact book.department@intechopen.com

Numbers displayed above are based on latest data collected.
For more information visit www.intechopen.com



Radiosurgery and Hypofractionated Stereotactic Irradiation with Photons or Protons for Tumours of the Skull Base

Dante Amelio, Marco Cianchetti, Barbara Rombi,
Sabina Vennarini, Francesco Dionisi,
Maurizio Amichetti and Giuseppe Minniti

Additional information is available at the end of the chapter

<http://dx.doi.org/10.5772/55692>

1. Introduction

The fundamental goal of improving radiation therapy (RT) is to maximize dose to the tumour while limiting dose to normal tissues. Higher radiation dose to the tumour can result in better disease control, and possibly also in improving survival. Decreasing dose to normal tissues is desirable in order to avoid acute and late side effects.

Recent technological advances in photon-RT have allowed an improvement in targeting accuracy, dose escalation, delivery of multiple large fractions (hypofractionated stereotactic radiation therapy - HSRT) or single fraction stereotactic ablative radiation therapy (radiosurgery - SRS). Radiosurgery delivers a single large dose with very steep dose fall-off outside the lesion to very small volumes in order to be tumouricidal through DNA damage or ablative causing necrosis via a vascular endothelial damage [1]. Furthermore, it has been shown that molecular responses to radiation differ based on dose per fraction. More recently, HSRT in two to five sessions has been employed to deliver extremely hypofractionated regimens. Preliminary data suggest that HSRT may represent an effective treatment associated with lower risk of radiation-related adverse effects in patients with periorbital or large benign tumours as compared with single fraction SRS, although potential benefits remain to be demonstrated.

Different techniques are used to deliver both HSRT and SRS, enabling patient immobilization, set-up uncertainty reduction, targeting accuracy, delivery of high doses, and heterogeneous dose distribution with a steep dose gradient. Despite these enhancements in delivery with

better conformality indices, photons still have a relatively high exit dose (beyond the tumour target), which can produce significant normal-tissue exposure.

Protons are positively-charged elementary particles, with similar biological effectiveness to conventional photon radiation. They have a defined range exhibited by the Bragg peak resulting in an energy deposition with no exit dose beyond the target volume. Thanks to these fundamental physics characteristics, proton radiation therapy offers superior dose distribution and reduced low-dose integral irradiated volume [2] enabling more radiation dose to be delivered to the tumour while significantly lowering the dose to the surrounding normal tissues.

The skull base (SB) is a very complex anatomical region that includes portions of the anterior cranial fossa, clivus, petrous bone, middle cranial fossa, cavernous sinus and infratemporal fossa encompassing several critical neurovascular structures. Tumours of the SB are challenging lesions because of their anatomical location and close proximity to several critical neurovascular structures. Surgical treatment is considered the first managing step and it has the aim to remove (completely or partially) the tumour. The deep location of SB tumour requires extensive experience in surgical procedures; in fact, surgical damage could severely affect vision, hearing, speech, swallowing, and could even be life-threatening.

New RT techniques allow targeting SB tumours when surgery is not feasible, macroscopic residual is left after surgical intervention or even as an alternative, definitive treatment. Most patients with lesions of the SB have a benign tumour and a long-life expectancy. They need to be treated with techniques allowing target irradiation with a conformal isodose configuration and a steep fall-off into other surrounding structures in order to provide long-term tumour control with a low morbidity profile.

Several machines have been developed or implemented to deliver stereotactic treatments and are currently in use: Gamma Knife, linear accelerators, Cyberknife, and dedicated proton equipments are the most used and have been compared in several plan-comparison studies. At the same time, in the treatment of SB tumours, many studies have shown the effectiveness of SRS and HSRT with photons and, though less frequently, with protons. Considering the continuous advancement of technology in delivering SRS and HSRT with photons and the increased use of protons, we deemed it useful to review this topic by evaluating differences with photons and possible advantages of the use of protons. An analysis of the fundamental principles and differences underlying photon- and proton-based SRS/HSRT as well as clinical outcomes in SB tumours is provided and discussed.

2. Radiobiological background

Experimental and clinical data suggest that the radiobiological principles may differ when irradiation is delivered with different fractionation regimens (fractionated versus large single doses) [3] or when a different type of radiation, such as protons, is employed [4].

This section provides a brief overview on the radiobiological principles underlying radiation therapy and their applications to single or (hypo)fractionated radiotherapy. For a comprehensive analysis of the topic, the reader is referred to specific textbooks and articles [4-6].

The first principle points out that hypoxic cells are highly resistant to the radiation-related killing [7] when radiations with low linear energy transfer are employed.

Secondly, the dose-response relationship differs according to the type of tissues. Those containing mainly non-cycling cells (classified as “late reacting tissues” [8]), are more sensitive to large doses per fraction than tissues containing mainly cycling cells (classified as “early reacting tissues” [8]).

Finally, experimental data show that cells have different radiation sensitivities in different parts of the cell cycle [9].

Taking into account such knowledge, the employment of a fractionated regimen allows hypoxic cells to reestablish their oxygenation state [6] so that they will be more sensitive to a second, and subsequent, dose fraction. Dose fractionation also spares late reacting (healthy) tissues more than early reacting (malignant tumor) tissues [5]. Finally, it allows part of the cells to leave the resistant phase while entering in a more sensitive phase. As an overall result, a more effective cell killing takes place.

Conversely, SRS exploits a different pattern of dose distribution, rather than radiobiological differences between normal and tumour tissue, to achieve effective tumour destruction. Theoretically, the use of large single dose does not allow reoxygenation [4] and may be more damaging if the target is in close proximity of or embedded within late responding organs at risk [10]. Provided that SRS dose falloff is steep enough to spare surrounding structures, the delivery of high single dose should translate into a greater rate of local tumour control, while still offering a low rate of complications. Moreover, the delivery of a single large dose does not allow redistribution of cells into a more radiosensitive phase of the cell cycle. However, the argument for the use of SRS is the relevant radiobiological effect of single-session radiation cell kill or cell division capability arrest, regardless of the mitotic phase [10].

Protons and photons differ in terms of physical properties and interaction with matter, which ultimately translate into different dose distribution as well as biological effectiveness [2]. To date, such a difference has been quantified in a 1.1 relative biological effectiveness (RBE) of protons over photons [11]. Despite the fact that this generic RBE may not be true, its variations do not show sufficient degree to be clinically relevant [11]. As a consequence, all of the above stated radiobiological principles as well as the corresponding clinical applications keep their validity regardless the employed type of radiation so that there is no difference between photon- and proton-based stereotactic irradiation.

However, experimental data [11] have shown that proton RBE values increase over the last few millimeters of the range, ultimately leading to an increased linear energy transfer. The corresponding effect may be equivalent to the expansion of 2 mm or more of the distal penumbra [11], which may be clinically relevant for the surrounding healthy structures. From the radiobiological standpoint, this issue probably represents the most relevant difference

between photon- and proton-based stereotactic radiotherapy. Therefore, it is wise to take into account the biological effects of this high-RBE component during the planning.

3. Dosimetrical features

The stereotactic delivering modalities and techniques have been compared in several plan comparison studies [12-15]. The corresponding efficacy has been investigated also on the basis of the normal tissue complication probability (NTCP) and tumour control probability (TCP) models in the attempt to set the results also on a biological basis [14,16].

In general, the differences among photon-based techniques (GK, multi- non-coplanar arcs or shaped beams linac treatment) are negligible [12-15]. Conversely, the modality (photons or protons) can be what is more important. Target features such as size, shape and location within the brain can influence the choice for the best stereotactic modality. In fact, all modalities are equally good if the target is small and regular [14,15].

Based on the normal brain dose, the dosimetrical advantage of charged particles relative to photons is evident in all types of targets [12,14,15]. Such a difference is more relevant under the 60% dose level regardless of the target features [14]. Moreover, the larger the target volume the greater the difference [12,14,15], which peaks for regular shaped targets larger than 24-26 cc, even though it can be relevant even for smaller and irregular targets (about 6 cc) [14,15].

All of the above-stated considerations also apply with respect to the lesion's shape and location: charged particles perform better than photon techniques.

All of the above-mentioned quantitative differences have been confirmed when the analysis was approached on a biological basis, being the NTCP different according to the treatment modality, size, shape and location of the target [14,16]. Again, protons demonstrated the lowest NTCP for medium-large regular and irregular shaped lesions [14,16]. In this scenario, charged particles scored NTCP values 4-6% smaller than photon techniques.

In this context, it is noteworthy that radiation-induced tumours have been reported after photon SRS [17,18]. It is well-known that protons feature a low integral dose to healthy structures providing the potential to reduce this risk. However, the tissue volume that can benefit from this feature may be very small in SRS and the corresponding clinical gain may be difficult to detect.

In conclusion, in the attempt to customize the treatment according to the clinical scenario it is possible to state that small to medium regularly-shaped lesions can be effectively managed by all photon-based techniques although at the expense of some target dose inhomogeneity. The charged particle capability to simultaneously provide high-target conformity and dose homogeneity maximizes for regularly and irregularly-shaped, medium to large lesions.

Finally, it is noteworthy that despite such comparisons included several planning and treatment strategies, further improvements, such as intensity-modulated photon and proton RT, have been introduced. These certainly deserve further investigation.

4. Clinical results of photon and proton SRS/HSRT for skull base tumours

4.1. Search strategy and selection criteria

Data for this review were obtained searching MEDLINE databases for publications dated between January 1980 and December 2011.

The search terms were: “skull base” and “stereotactic radiosurgery”. Further research was conducted by adding the definitions of different SB tumours (“meningioma”, “schwannoma / acoustic neuroma”, “pituitary adenoma”, “chordoma”, “chondrosarcoma”, “craniopharyngioma”, “olfactory neuroblastoma / esthesioneuroblastoma”, “glomus jugulare / chemodectoma”, “proton”) to the previously-searched keywords.

This search was limited to articles written in English. Editorials, case reports, letters of opinion, and congress abstracts were excluded, even if they added valuable information. In case of repeated publications by the same institution, only the most updated was used for the analysis. Papers were reviewed and prioritized according to content relevancy. Reference lists from these sources were searched for additional publications. A systematic review was beyond the aim of the paper; the following results are reported in the form of a narrative summary.

4.2. Clinical outcomes

Photon-based SRS and HSRT have been increasingly employed as primary or post-operative treatments with more than 10.000 patients reported in published studies over the last two decades. Less data are available on the treatment with proton-based SRS and HSRT even though several types of tumour in benign and malignant settings, and also non-tumoural lesions as arteriovenous malformations, have been treated since its early use showing that it as a viable option for larger volumes.

To date, no randomized or non-randomized study has compared photon SRS/HSRT with proton SRS/HSRT, and almost all the studies available in literature are retrospective. Clinical outcomes are presented in the following, according to histopathological classification.

A brief summary is provided in Table 1.

Tumor type	Delivery technique	Doses	Five-year tumor control
Benign meningioma	SRS	12 – 18 Gy	> 92%
	HSRT	14 – 25 Gy / two-five fractions	93.5%
Pituitary adenoma	SRS	15 – 22 Gy (non functioning) 18 – 26 Gy (secreting)	94%
	HSRT	17 – 25 Gy / three-five fractions	98% (three-years)

Tumor type	Delivery technique	Doses	Five-year tumor control
Acoustic neuroma	SRS	12 – 13 Gy	92%-100%
	HSRT	30 – 36 Gy /six fractions 20 – 25 Gy /five fractions	94%-100%
Craniopharyngioma	SRS	3 – 25 Gy	36%-91.6%
	HSRT	NA	NA
Chordoma and chondrosarcoma	SRS	15 – 20 Gy	Chordoma: 32-72% Chondrosarcoma: 63-100%
	HSRT	20 – 43.6 Gy / two-five fractions	Chordoma: 100% (two-years)

Table 1. Main clinical outcomes regarding the most frequent tumours of the skull base treated with stereotactic radiosurgery (SRS) and hypofractionated stereotactic radiotherapy (HSRT).

• Meningioma

Meningiomas represent approximately 25% of all intracranial tumours, the majority of which are benign (grade I according to the World Health Organization classification).

These lesions can be observed or treated with surgery or RT. Surgical resection is the preferred treatment for accessible tumours that can be safely removed. RT is used when surgery is not possible for the location of the lesion or when the patient is not a suitable surgical candidate. Other indications are the risk of progression after partial excision or the salvage after a relapse. Atypical or malignant meningioma are usually irradiated adjuvantly after complete surgical excision [19]. Recently-published multicenter series [20] and review [21] on benign lesions show a 5-year control rate $\geq 92\%$. Radiosurgical doses between 12 and 18 Gy have been used in the control of skull base meningiomas. A similar 5-year actuarial tumour control rate in the range of 90-95% has been observed with doses of 15-16 Gy or 12-14 Gy. Large meningiomas are associated with worse long-term local control [22,23].

Radiation-induced toxicity has been shown in up to 40% after SRS, being represented by either transient or permanent neurological complications; however, the reported rate of significant complications at doses of 12-15 Gy, as currently used in most centres, is relatively low. Reference [22] reported permanent neurological deficits of 6.3% for cavernous sinus meningiomas treated with GK SRS. Reference [24] showed late transient or permanent complications in 4.5% of patients, and similar complication rates have been reported in the majority of published series [21]. Other complications, such as epilepsy, internal carotid occlusion, and hypopituitarism have been rarely reported (less than 1-2%).

Only few studies report on the use of HSRT for skull base meningiomas [25-27]. In a series of 157 patients treated with Cyberknife [27], 5-year control was 93.5%. Interestingly, local control in tumours bigger than 8 ml and/or situated close to critical structures and treated with two to five daily fractions was similar to that obtained in smaller meningiomas treated with single fraction SRS.

Protons have been used in this context usually with conventional fractionation and in association with photons for benign [28-32] or atypical lesions [33,34], but also with HSRT or single session SRS [35-37]. In reference [35], 23 patients were treated, 18 with three fractions HSRT, and five with HSRT in 16 or more fractions: the mean reference dose was 20.3 Cobalt Gray equivalent (CGyE). In the HSRT group, clinical control was 89% (16/18) and radiological local control was 88%. Two patients (11%) developed transient new cranial nerve neuropathy after radiosurgery, which gradually recovered. Two more patients (11%) developed late side effects. The results of 51 cases of benign meningioma treated, between 1996 and 2007, with proton SRS as primary treatment (n = 32) or for residual tumour following surgery (n = 8), or recurrent tumour following surgery (n = 10) were recently published [37]. The median dose delivered was 13 CGyE (range, 10 -15.5 CGyE) prescribed to the 90% isodose line. After a median follow-up of 32 months (range, 6-133 months), MRI revealed 33 meningiomas with stable, 13 with decreased, and five with increased size. The 3-year actuarial tumour control rate was 94%. Symptoms were improved in 47% (16/34) of patients. Potentially permanent adverse effects after SRS were recorded in 3/51 (5.9%) patients. The main limitation of these studies is that longer follow-up is needed to assess the durability of tumour control.

- Pituitary adenoma

There are two general categories of pituitary tumours: non-secreting and secreting lesions. Functioning tumours cause an excess secretion of one or more pituitary hormones. Although pituitary adenomas are histologically benign, successful management of these tumours can be challenging. Treatment options include microresection, medical therapy, fractionated RT, and SRS. The role of RT in pituitary adenomas is well-established [38], particularly when medical and surgical options have been exhausted. Therapeutic goals when performing RT for pituitary tumours are: stopping the tumour growth by preventing problems from mass effect, and normalization of excessive hormone secretion.

All main published results on the long-term effectiveness of SRS in patients with non-functioning and secreting pituitary adenomas have been recently reviewed [39,40]. In 15 studies reporting 684 patients with non-functioning adenomas treated with SRS at doses of 15-22 Gy, the reported 5-year actuarial tumour control rate was 94%. A similar local control was observed in patients with secreting pituitary adenomas, although higher doses in the range of 18-26 Gy are usually employed with the aim to achieve normalization of hormone hypersecretion. SRS data for 1215 patients with acromegaly have been reported in 29 studies [39]. At a median follow-up of 50 months, the 5-year and 10-year biochemical remission rates were 44% (range, 15-60%) and 74% (range, 46-86%), respectively. Time to response ranged from 12 to 66 months. Results of SRS were reported for 280 patients with Cushing's disease in 12 studies [40]. At a corrected median follow-up of 45 months, 48% of patients had biochemical remission of disease, with a reported time to hormonal response ranging from 3 months to 3 years. SRS is rarely used in the treatment of prolactinomas since medical treatment with dopamine agonists can achieve tumour shrinkage and normalize prolactin (PRL) levels in more than 80% of patients. When employed in patients who fail surgery and medical therapy, at a median follow-up of 29 months normalization of elevated PRL levels has been observed in 33% of 353 patients included in 18 studies, with a reported time to hormonal response ranging

from 5 to 40 months [40]. The reported overall rate of serious complications after SRS is low. The main complication is hypopituitarism, which is reported in up to 47% of patients, with higher rates in those series with a longer median follow-up.

HSRT has been employed in patients with tumours involving the optic apparatus and patients who are not considered suitable for SRS. Initial experiences with Cyberknife in treating patients with pituitary adenomas are promising [25,41,42]. Reference [25] reported high rates of tumour control and preservation of visual function in a small group of patients with pituitary adenomas within two mm of the optic apparatus treated to doses of 18-24 Gy delivered in two to five sessions. Although hypofractionated treatment schedules may offer a reduced risk of radiation-related adverse effects as compared to single fraction SRS, its efficacy needs to be evaluated in large prospective studies.

Data on proton treatment in pituitary adenomas are available both with the option of conventional fractionation [43] or with SRS [44-47]. In a small series of 22 patients treated with proton SRS for persistent acromegaly at a median follow-up of 6.3 years, the biochemical remission of disease was observed in 13 patients (59%) [44]. Time to response was 42 (range, 6-62) months. In a retrospective series of 33 patients with Cushing's disease at a median follow-up of 62 months, normalization of plasma and urinary free cortisol was achieved in 17 (52%) patients, with a time to remission of 18 (range, 5-49) months [45]. In both series, the only reported toxicity was represented by new pituitary deficits, which occurred in up to 52% of patients, whereas no visual complications, seizures, or secondary tumours were noted. The small number of cases treated and limited follow-up precludes drawing firm conclusions, even though it supports the hypothesis that proton SRS may offer better dosimetric coverage of the pituitary gland than photon-based treatments.

- Acoustic neuroma/vestibular schwannoma

Acoustic neuroma is a benign primary intracranial tumor of the vestibulocochlear nerve that can be treated with surgery or with several stereotactic irradiation techniques. Studies in the literature are poorly comparable because of the lack of uniform-reporting evaluation criteria [48].

SRS as an effective treatment for acoustic neuroma has evolved over the last decades, leading to an improvement of local control and reduction of long-term toxicity. At doses of 12-13 Gy, as used in most recent studies, SRS results in an actuarial 5-year tumour control between 92 and 100% with a low incidence of radiation-induced complications [49]. The reported local control is similar to that reported with higher doses in the range of 15-18 Gy as used in early experiences of SRS, however with a lower incidence of radiation-induced complications. A recent review of more than 2000 patients included in 23 studies has shown an overall facial nerve preservation rate of 96% after GK, with a significant better facial nerve preservation rate in patients receiving ≤ 13 Gy of radiation at the marginal dose and with a tumor volume ≤ 1.5 cm³ [50]. Using similar doses, an overall hearing preservation, as defined by the maintenance of Gardner-Robertson Grade I or II after SRS, has been reported in 51% (range, 32-71%) of 4234 patients included in 45 publications [51]. Equivalent tumor control and hearing preservation rates have been reported for larger acoustic neuromas compressing the brainstem, with a reported balance improvement or stabilization in more than 85% of patients who had imbal-

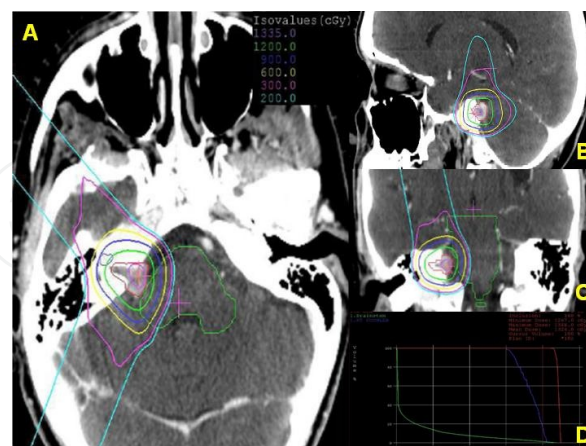
ance at presentation [52]. Neurological toxicity, including facial and trigeminal neuropathies, and balance disturbances may occur in 0-3% of patients. Hydrocephalus has been observed in 1-2% of patients, whereas radiation-induced tumors or malignant transformation of acoustic neuroma have been reported rarely [49].

There are only few reports regarding the use of HSRT in patients with vestibular schwannomas [53,54]. The reference [53] employed a regimen of 30 or 36 Gy in six fractions. At a median follow-up of 4.5 years, absolute tumor control, as well as hearing, facial and trigeminal preservation were 100%.

In reference [54], 20 or 25 Gy were delivered in five fractions. Five-year tumor control, trigeminal, facial, and hearing preservation were 94%, 98%, 97%, and 61%, respectively. It is noteworthy that in the latter reference HSRT provided equivalent tumor control, facial and hearing preservation with respect to SRS. Conversely, trigeminal preservation was significantly improved in patients treated with HSRT.

Also in this site, proton beam has been used with conventional fractionation [55] or with SRS with a satisfactory level of hearing, facial nerve, trigeminal nerve preservation, and with tumor-control rates of 84-100% [56-58]. Reference [56] reported on 88 patients with vestibular schwannomas treated at the Massachusetts General Hospital between 1992 and 2000 with proton SRS. At a median follow-up period of 38.7 months (range, 12-102), the actuarial 2- and 5-year tumor control was 95.3% and 93.6%, respectively. Hearing was preserved in 33% of 21 (24% of the total) patients with functional hearing before treatment. Actuarial 5-year normal facial and trigeminal nerve function preservation rates were 91% and 89%, respectively. Three patients (3.4%) underwent shunting for hydrocephalus.

Figure 1 shows a representative case of vestibular schwannoma treated with proton SRS.



Courtesy of Francis H. Burr Proton Therapy Center – Massachusetts General Hospital, Boston (USA).

Figure 1. Dose distribution in axial (A), sagittal (B), and coronal (C) views of a right vestibular schwannoma treated by proton radiosurgery. Tumor volume (in red) was 1 cubic centimeter. A dose of 12 Cobalt Gray Equivalent was prescribed to 90% isodose. Three equally weighted passive scattering beams were employed. The dose-volume histogram graph (D) shows the doses to organs at risk (right cochlea in blue and brainstem in green) and tumor volume (in red).

Reference [58] reported on 51 patients treated with proton HSRT with a dose of 26 CGyE in three fractions. At a median follow-up of 72 months, the 5-year local control was 98%. Hearing, facial nerve, and trigeminal nerve preservation rates were 42%, 90.5% and 93% at 5 years, respectively.

- Craniopharyngioma

Craniopharyngioma is a rare and mostly benign epithelial paediatric brain tumour of the sellar and suprasellar region. The treatment is based on a surgical approach with transcranial approaches or endoscopic endonasal surgery followed by RT, mainly in form of fractionated regimens with a local control of 80-90% at 5-10 years [59]. The proximity of craniopharyngiomas to the optic pathways provides a major limitation to the use of SRS, although in selected series of relatively small residual tumours, a local control of 34-88% has been reported [60-62]. Tumor control was achieved with a median dose of 22-24 Gy (marginal dose 11-12 Gy), whereas the use of lower radiation results in an unsatisfactory tumor control [63]. The reported late toxicity after SRS ranges from 0 to 38%, mainly represented by visual and endocrinological deficits [59].

To date, there are no data dealing with the delivery of HSRT in patients with craniopharyngioma.

Protons have been recently used for the treatment of this tumour but only with conventional fractionated regimens [64-66], and to date no experience with proton SRS has been reported.

- Chordoma and chondrosarcoma

Chordomas and chondrosarcomas of the SB are rare bone tumours with locally aggressive behaviour. Safe, maximal resection is the mainstay of treatment, usually followed by adjuvant RT. Protons are used with conventional fractionation schemes utilizing doses of 70 Gy in chondrosarcoma and, 74-78 in chordoma with valuable results [67,68]. The improvements in surgical techniques allow more radical tumour resection, while frequently providing small residual lesions suitable also for SRS or HSRT. Few clinical data was published on this issue, showing, however, promising preliminary results. Both for chordomas and chondrosarcomas, SRS has been employed to treat small tumour volumes: with few exceptions, corresponding median or mean values were less than 20 cm³. Median delivered dose was 15-20 Gy in most series, depending on the proximity with organs at risk. Such dose levels translated into actuarial local control rates of 32-72% at 5 years for chordomas [67] and 63-100% for chondrosarcomas [68]. It is noteworthy that most series have mean or median follow-up of less than 5 years.

Concerning the delivery of HSRT, literature shows very limited data [69-71]. None of them reports outcomes regarding chondrosarcomas. Total dose was 20-43.6 Gy delivered in 2 to 5 fractions. When reported, tumour volumes were again limited in size (less than 20 cm³). Only one series reports specific outcomes for patients treated with HSRT: at a median follow-up of just 24 months, absolute local control was 100% [70].

Both for SRS and HSRT severe radiation-related side effects were rare [67].

Even though such data need to be confirmed at a longer follow-up, it seems that SRS and HSRT could represent viable treatment options for small sized chordomas and chondrosarcomas residual after surgery or relapsing.

No data are available at this moment concerning the use of proton SRS or HSRT.

- Chemodectoma/glomus jugulare tumours

Radiation has been found to be helpful in controlling glomus jugulare tumour growth by inducing fibrosis around the supplying vessels. A recent comprehensive review identified 109 studies for a total of 869 patients described outcomes for patients with glomus jugulare tumours [72]. Patients undergoing SRS had the lowest rates of recurrence and the most favourable rates of tumour control. In particular, those treated with subtotal resection plus SRS had a control rate of 71% at 96 months of follow-up. At a median follow-up of 71 months, patients undergoing SRS alone had a tumour control rate of 95%. A recent meta-analysis [73] found 19 eligible studies. SRS marginal dose ranged between 12 and 20.4 Gy. Ninety-seven percent of patients achieved tumour control, and 95% of patients achieved clinical control suggesting the useful utilization of SRS for the primary management of glomus jugulare tumours in particular for patients with preserved glossopharyngeal and vagus nerve function, after surgical recurrence, in the elderly, and in patients with serious pre-existing medical conditions [74].

So far, data dealing with the use of HSRT in patients with chemodectoma or tumors of glomus jugulare are very limited. In reference [75], part of the patient sample received a slight hypofractionated regimen: 2.67 Gy per fraction (median dose 45 Gy). Overall, the 10-year tumour control rate was 92%. In reference [76] 49 patients received a median dose of 45 Gy in 15 or 16 fractions. At both 5 and 10 years, 92% of cases were recurrence-free. More recently, 18 patients were treated with a median dose of 20 Gy in 3 fractions [77]. At a median follow-up of 22 months, local control was 100%.

No data are available for the use of protons in this field.

- Olfactory neuroblastoma/Esthesioneuroblastoma

Olfactory neuroblastoma or esthesioneuroblastoma is a rare tumour of the frontal SB. It is characterized by high rates of tumour recurrence and mortality. A recent meta-analysis [78] demonstrated that the most effective management of these lesions is usually based on surgery followed by post-operative irradiation. For early stage tumours, where the risk of cervical nodes involvement is very low, the combination of SRS (15-34 Gy marginal dose) with endoscopic sinus surgery seems a promising treatment option [79,80].

To date, there are no data dealing with the delivery of HSRT in patients with olfactory neuroblastoma or esthesioneuroblastoma.

In the only report concerning the use of protons in this field, 14 patients received irradiation as definitive treatment [81]. Total dose was 65 CGyE, with 2.5 CGyE per fraction. Actuarial 5-year local progression-free survival rate was 84%.

5. Conclusions

Stereotactic irradiation is highly effective in the management of SB benign tumours and long-term data clearly indicate a tumour control in more than 90% of cases after 5 and 10 years, with an acceptable incidence of complications. In most series, radiosurgical dose has been delivered using GK, although outcome is similar for patients with SB tumours treated with Linac SRS.

Even though protons are increasingly used in the clinical community, only few studies have been performed to assess the efficacy and toxicity of proton SRS and HSRT in skull base tumors. The number of Institutions that are currently using protons is small, particularly those performing proton-based stereotactic techniques. Proton beam, while utilizing a different type of radiation, also represents a similar highly focused and targeted radiation tool. The physical properties of protons offer superior conformality in dose distribution with respect to photons. This advantage becomes more apparent as the lesion volume increases. However, current results do not clearly indicate that proton SRS/HSRT is superior to photon SRS/HSRT. Clinical results are probably confounded by a bias toward reserving proton beams for the treatment of larger and more complex lesions; but conclusions about the presumed superiority of protons in comparison to other photons-based techniques are difficult to draw.

With respect to the small number of treated patients and short follow-up, toxicity was similar with the use of the different techniques; however, the evaluation of complications is often completely subjective and unsatisfactory. Proton SRS may represent a treatment alternative to photon SRS especially for larger and/or irregularly shaped tumors close to sensitive structures. The difference between techniques may be small and large numbers of patients followed for long periods would be required to demonstrate any clinically significant advantage. The more widespread use of protons could allow comparative multi-institutional trials to select the appropriate modality for each tumour type.

Acknowledgements

We thank Valentina Piffer (ATreP, Trento – Italy) for her language editing of the manuscript.

Author details

Dante Amelio¹, Marco Cianchetti¹, Barbara Rombi¹, Sabina Vennarini¹, Francesco Dionisi¹, Maurizio Amichetti¹ and Giuseppe Minniti²

1 ATreP – Provincial Agency for Proton Therapy, Trento, Italy

2 Department of Radiation Oncology, University La Sapienza, S. Andrea Hospital, Rome, Italy

The authors have no conflicts of interest. All authors have contributed to the review.

References

- [1] Balagamwala EH. Principles of Radiobiology of Stereotactic Radiosurgery and Clinical Applications in the Central Nervous System. *Technol Cancer Res Treat* 2012;11(1) 3-13.
- [2] Suit H. Proton beams to replace photon beams in radical dose treatments. *Acta Oncol* 2003; 42(8) 800-808.
- [3] Kirkpatrick JP. The linear-quadratic model is inappropriate to model high dose per fraction effects in radiosurgery. *Semin Radiat Oncol* 2008;18(4) 240-243.
- [4] Breuer H, Smit BJ. Proton therapy and radiosurgery. Heidelberg: Springer-Verlag; 2010.
- [5] Chin LS, Regine WF. Principles and practice of stereotactic radiosurgery. New York: Springer; 2008.
- [6] Hall EJ. The radiobiology of radiosurgery: rationale for different treatment regimens for AVMs and malignancies. *Int J Radiat Oncol Biol Phys* 1993;25(2) 381-385.
- [7] Overgaard J. Modification of hypoxia-induced radioresistance in tumors by the use of oxygen and sensitizers. *Semin Radiat Oncol* 1996;6(1) 10-21.
- [8] Whithers HR, Thames HD, Peters LJ. Progress in radio-oncology, vol 2. New York: Raven Press; 1982.
- [9] Whithers HR. Cell cycle redistribution as factor in multifractionation irradiation. *Radiology* 1975;114(1) 199-202.
- [10] Larson DA. Radiobiology of radiosurgery. *Int J Radiat Oncol Biol Phys* 1993;25(3) 557-561.
- [11] Paganetti H. Relative biological effectiveness (RBE) values for proton beam therapy. *Int J Radiat Oncol Biol Phys* 2002;53(2) 407-421.
- [12] Phillips MH. Comparison of different radiation types and irradiation geometries in stereotactic radiosurgery. *Int J Radiat Oncol Biol Phys* 1990;18(1) 211-220.
- [13] Luxton G. Stereotactic radiosurgery: principles and comparison of treatment methods. *Neurosurgery* 1993;32(2) 241-259.
- [14] Serago CF. Comparison of proton and x-ray conformal dose distributions for radiosurgery applications. *Med Phys* 1995;22(12) 2111-2116.
- [15] Verhey LJ. Comparison of radiosurgery treatment modalities based on physical dose distributions. *Int J Radiat Oncol Biol Phys* 1998;40(2) 497-505.

- [16] Smith V. Comparison of radiosurgery treatment modalities based on complication and control probabilities. *Int J Radiat Oncol Biol Phys* 1998;40(2):507-513.
- [17] Yu JS. Glioblastoma induction after radiosurgery for meningioma. *Lancet* 2000;356(9241) 1576-1577.
- [18] Loeffler JS. Second tumors after radiosurgery: tip of the iceberg or a bump in the road? *Neurosurgery* 2003;52(6) 1436-40; discussion 1440-1442.
- [19] Hanft S. A review of malignant meningiomas: diagnosis, characteristics, and treatment. *J Neurooncol* 2010;99(3) 433-443.
- [20] Santacrose A. Long term tumor control of benign intracranial meningiomas after radiosurgery in a series of 4565 patients. *Neurosurgery* 2012;70(1) 32-39.
- [21] Minniti G. Radiotherapy and radiosurgery for benign skull base meningiomas. *Radiat Oncol* 2009;4 42.
- [22] Kondziolka D. Radiosurgery as definitive management of intracranial meningiomas. *Neurosurgery* 2008;62(1) 53-58.
- [23] DiBiase SJ. Factors predicting local tumor control after gamma knife stereotactic radiosurgery for benign intracranial meningiomas. *Int J Radiat Oncol Biol Phys* 2004;60(5) 1515-1519.
- [24] Nicolato A. The role of Gamma Knife radiosurgery in the management of cavernous sinus meningiomas. *Int J Radiat Oncol Biol Phys* 2002;53(4) 992-1000.
- [25] Adler JR Jr. Visual field preservation after multisession cyberknife radiosurgery for periophtic lesions. *Neurosurgery* 2008;62(Suppl 2) 733-743.
- [26] Tuniz F. Multisession cyberknife stereotactic radiosurgery of large, benign cranial base tumors: preliminary study. *Neurosurgery* 2009;65(5) 898-907.
- [27] Colombo F. Cyberknife radiosurgery for benign meningiomas: short term results in 199 patients. *Neurosurgery* 2009;64(Suppl 2) A7-13.
- [28] Noël G. Highly conformal therapy using proton component in the management of meningiomas. Preliminary experience of the Centre de Protonthérapie d'Orsay. *Strahlenther Onkol* 2002;178(9) 480-485.
- [29] Wenkel E. Benign meningioma: Partially resected, biopsied, and recurrent intracranial tumors treated with combined proton and photon radiotherapy. *Int J Radiat Oncol Biol Phys* 2000;48(5) 1363-1370.
- [30] Weber DC. Spot Scanning-based Proton Therapy for Intracranial Meningioma: Long-term Results from the Paul Scherrer Institute. *Int J Radiat Oncol Biol Phys* 2012;83(3) 865-871.

- [31] Noël G. Functional outcome of patients with benign meningioma treated by 3D conformal irradiation with a combination of photons and protons. *Int J Radiat Oncol Biol Phys* 2005;62(5) 1412-1422.
- [32] Arvold ND. Visual outcome and tumor control after conformal radiotherapy for patients with optic nerve sheath meningioma. *Int J Radiat Oncol Biol Phys* 2009;75(4) 1166-1172.
- [33] Boskos C. Combined proton and photon conformal radiotherapy for intracranial atypical and malignant meningioma. *Int J Radiat Oncol Biol Phys* 2009;75(2) 399-406.
- [34] Hug EB. Management of atypical and malignant meningiomas: role of high-dose, 3D-conformal radiation therapy. *J Neurooncol* 2000;48(2) 151-160.
- [35] Vernimmen FJ. Stereotactic proton beam therapy of skull base meningiomas. *Int J Radiat Oncol Biol Phys* 2001;49(1) 99-105.
- [36] Gudjonsson O. Stereotactic irradiation of skull base meningiomas with high energy protons. *Acta Neurochir* 1999;141(9) 933-940.
- [37] Halasz LM. Proton stereotactic radiosurgery for the treatment of benign meningiomas. *Int J Radiat Oncol Biol Phys* 2011;81(5) 1428-1435.
- [38] Loeffler JS. Radiation therapy in the management of pituitary adenomas. *J Clin Endocrinol Metab* 2011;96(7) 1992-2003.
- [39] Minniti G. Radiation techniques for acromegaly. *Radiat Oncol* 2011;6 167.
- [40] Minniti G. Modern techniques for pituitary radiotherapy. *Rev Endocr Metab Disord* 2009;10(2) 135-144.
- [41] Iwata H. Hypofractionated stereotactic radiotherapy with CyberKnife for nonfunctioning pituitary adenoma: high local control with low toxicity. *Neuro Oncol* 2011;13(8) 916-922.
- [42] Killory BD. Hypofractionated CyberKnife radiosurgery for perichiasmatic pituitary adenomas: early results. *Neurosurgery* 2009;64(Suppl 2) A19-25.
- [43] Ronson BB. Fractionated proton beam irradiation of pituitary adenomas. *Int J Radiat Oncol Biol Phys* 2006;64(2) 425-434.
- [44] Petit JH. Proton stereotactic radiosurgery in management of persistent acromegaly. *Endocr Pract* 2007;13(7) 726-734.
- [45] Petit JH. Proton stereotactic radiotherapy for persistent adrenocorticotropin-producing adenomas. *J Clin Endocrinol Metab* 2008;93(2) 393-399.
- [46] Yock TI. Stereotactic Proton Beam Radiosurgery for ACTH Producing Adenomas in the MRI/CT Era. *Int J Radiat Oncol Biol Phys* 2001;51(Supplement 1)162.

- [47] Aghi MK. Management of Recurrent and Refractory Cushing's Disease with Reoperation and/or Proton Beam Radiosurgery. *Clin Neurosurg* 2008;55 141-144.
- [48] Bassim MK. Radiation therapy for the treatment of vestibular schwannoma: a critical evaluation of the state of the literature. *Otol Neurotol* 2010;31(4) 567-573.
- [49] Murphy ES. Radiotherapy for vestibular schwannomas: a critical review. *Int J Radiat Oncol Biol Phys* 2011;79(4) 985-997.
- [50] Yang I. A comprehensive analysis of hearing preservation after radiosurgery for vestibular schwannoma. *J Neurosurg* 2010;112(4) 851-859.
- [51] Sughrue ME. Preservation of facial nerve function after resection of vestibular schwannoma. *Br J Neurosurg* 2010;24(6) 666-671.
- [52] Nakaya K. Gamma knife radiosurgery for benign tumors with symptoms from brain-stem compression. *Int J Radiat Oncol Biol Phys* 2010;77(4) 988-995.
- [53] Kalapurakal JA. Improved trigeminal and facial nerve tolerance following fractionated stereotactic radiotherapy for large acoustic neuromas. *Br J Radiol* 1999;72(864) 1202-1207.
- [54] Meijer OW. Single-fraction vs. fractionated LINAC-based stereotactic radiosurgery for vestibular schwannoma: a single institution study. *Int J Radiat Oncol Biol Phys* 2003;56(5) 1390-1396.
- [55] Bush DA. Fractionated proton beam radiotherapy for acoustic neuroma. *Neurosurgery* 2002;50(2) 270-273.
- [56] Weber DC. Proton beam radiosurgery for vestibular schwannoma: tumor control and cranial nerve toxicity. *Neurosurgery* 2003;53(3) 577-586.
- [57] Harsh GR. Proton beam stereotactic radiosurgery of vestibular schwannomas. *Int J Radiat Oncol Biol Phys* 2002;54(1) 35-44.
- [58] Vernimmen FJ. Long-term results of stereotactic proton beam radiotherapy for acoustic neuromas. *Radiother Oncol* 2009;90(2) 208-212.
- [59] Minniti G. The role of fractionated radiotherapy and radiosurgery in the management of patients with craniopharyngioma. *Neurosurg Rev* 2009;32(2) 125-132.
- [60] Kobayashi T. Long-term results of gamma knife surgery for the treatment of craniopharyngioma in 98 consecutive cases. *J Neurosurg* 2005;103(Suppl 6) 482-488.
- [61] Mokry M. Craniopharyngiomas: a six year experience with Gamma Knife radiosurgery. *Stereotact Funct Neurosurg* 1999;72(Suppl 1) 140-149.
- [62] Niranjan A. Radiosurgery for craniopharyngioma. *Int J Radiat Oncol Biol Phys* 2010;78(1) 64-71.

- [63] Ulfarsson E. Gamma knife radiosurgery for craniopharyngiomas: long-term results in the first Swedish patients. *J Neurosurg* 2002; 97(Suppl 5) 613–622.
- [64] Beltran C. On the Benefits and Risks of Proton Therapy in Pediatric Craniopharyngioma. *Int J Radiat Oncol Biol Phys* 2012;82(2) e281-287.
- [65] Luu QT. Fractionated proton radiation treatment for pediatric craniopharyngioma: preliminary report. *Cancer J* 2006;12(2) 155-159.
- [66] Fitzek MM. Combined proton and photon irradiation for craniopharyngioma: long-term results of the early cohort of patients treated at Harvard Cyclotron Laboratory and Massachusetts General Hospital. *Int J Radiat Oncol Biol Phys* 2006;64(5) 1348-1354.
- [67] Amichetti M. Proton therapy in chordoma of the base of the skull: a systematic review. *Neurosurg Rev* 2009;32(4) 403-416.
- [68] Amichetti M. A systematic review of proton therapy in the treatment of chondrosarcoma of the skull base. *Neurosurg Rev* 2010;33(2) 155-165.
- [69] Chang SD. Stereotactic radiosurgery and hypofractionated stereotactic radiotherapy for residual or recurrent cranial base and cervical chordomas. *Neurosurg Focus* 2001;10(3) E5.
- [70] Gwak HS. Hypofractionated stereotactic radiation therapy for skull base and upper cervical chordoma and chondrosarcoma: preliminary results. *Stereotact Funct Neurosurg* 2005;83(5-6) 233-243.
- [71] Henderson FC. Treatment of chordomas with CyberKnife: Georgetown University experience and treatment recommendations. *Neurosurgery* 2009;64(Suppl 2) A44-53.
- [72] Ivan ME. A meta-analysis of tumor control rates and treatment-related morbidity for patients with glomus jugulare tumors. *J Neurosurg* 2011;114(5) 1299-1305.
- [73] Guss ZD. Radiosurgery of glomus jugulare tumors: a meta-analysis. *Int J Radiat Oncol Biol Phys* 2011;81(4) e497-502.
- [74] Hafez RF. The safety and efficacy of gamma knife surgery in management of glomus jugulare tumor. *World J Surg Oncol* 2010;8 76.
- [75] Krych AJ. Long-term results of irradiation for paraganglioma. *Int J Radiat Oncol Biol Phys* 2006;65(4) 1063-1066.
- [76] Pemberton LS. Radical radiotherapy alone for glomus jugulare and tympanicum tumours. *Oncol Rep* 2005;14(6) 1631-1633.
- [77] Wegner RE. Linac-based stereotactic body radiation therapy for treatment of glomus jugulare tumors. *Radiother Oncol* 2010;97(3) 395-398.
- [78] Dulguerov P. Esthesioneuroblastoma: a meta-analysis and review. *Lancet Oncol* 2001;2(11) 683–690.

- [79] Walch C. The minimally invasive approach to olfactory neuroblastoma: combined endoscopic and stereotactic treatment. *Laryngoscope* 2000;110(4) 635-640.
- [80] Unger F. Combined endoscopic surgery and radiosurgery as treatment modality for olfactory neuroblastoma (esthesioneuroblastoma). *Acta Neurochir (Wien)* 2005;147(6) 595-601.
- [81] Nishimura H. Proton-beam therapy for olfactory neuroblastoma. *Int J Radiat Oncol Biol Phys* 2007;68(3) 758-762.