

We are IntechOpen, the world's leading publisher of Open Access books Built by scientists, for scientists

6,900

Open access books available

186,000

International authors and editors

200M

Downloads

Our authors are among the

154

Countries delivered to

TOP 1%

most cited scientists

12.2%

Contributors from top 500 universities



WEB OF SCIENCE™

Selection of our books indexed in the Book Citation Index
in Web of Science™ Core Collection (BKCI)

Interested in publishing with us?
Contact book.department@intechopen.com

Numbers displayed above are based on latest data collected.
For more information visit www.intechopen.com



Combined Cataract-Glaucoma Surgery

Vassilis Kozobolis,
Aristeidis Konstantinidis and
Georgios Labiris

Additional information is available at the end of the chapter

<http://dx.doi.org/10.5772/54808>

1. Introduction

Glaucoma is an optic neuropathy which causes a characteristic loss of optic nerve fibers. The loss of the nerve fibers leads to an increase of the optic disc cupping with subsequent visual field defects [1]. It is estimated that around 60 million people suffer from open angle and closed angle glaucoma with the majority of the patients being female and 47% living in Asia. Another 6 million people suffer from various forms of secondary glaucoma. The patients blind from glaucoma are around 8 million [2,3]. The glaucoma is the second cause of blindness worldwide following cataract.

The aim of the treatment of the glaucoma is the lowering of the intraocular pressure (IOP) as research shown that the higher the IOP the higher the risk of developing glaucoma [4]. In the developed countries the first treatment option is the use of IOP lowering drops while in the developing world trabeculectomy is the first option. Trabeculectomy was regarded as an excellent option for the initial management of glaucoma before the introduction of the newer antiglaucoma drops [6]. Later research showed that patients on topical medication had better quality of life compared to those who underwent trabeculectomy although trabeculectomy was more efficient in lowering the IOP [7]. The introduction of newer and more potent drops as well as further research that showed the failure of trabeculectomy over time, limited the initial enthusiasm of the surgical approach as the initial management of glaucoma [8,9]. This led to a decrease in the number of trabeculectomies performed every year in the developed countries from mid 1990's [10-14].

2. Glaucoma surgery overview

Surgical techniques of the glaucoma surgery include:

- the penetrating techniques (trabeculectomy and its variations)
- the non-penetrating techniques (deep sclerectomy, viscocanalostomy, canaloplasty)
- the glaucoma drainage devices
 - with valve (Ahmed, Krupin)
 - without valve (Molteno, Baerveldt)
 - mini shunt (Ex-PRESS)
- newer devices (Glaukos iStent, Eyepass, Trabectome, CyPass, Solx gold shunt, Aquashunt, endophotocoagulation)
- The trabecular aspiration in pseudoexfoliation glaucoma

The concept of minimally invasive glaucoma surgery (MIGS) has gained a lot of interest in the recent years. The aim of these procedures is to minimize the side effects of the classic trabeculectomy by avoiding the formation of a large filtering bleb. The primary indication for MIGS is early to moderate open-angle glaucoma as they tend not to lower the IOP as much as trabeculectomy. The classification of MIGS can vary according to the surgical technique used, the formation of a filtering bleb and the aqueous dynamics

2.1. Classification of MIGS

Surgical technique

- **Ab interno** (Glaukos iStent, Trabectome, Cypass, Eyepass, Aquashunt, Solx Gold microshunt)
- **Ab externo** (canaloplasty)

Bleb formation

- **Bleb related** (Deep sclerectomy)
- **Blebless** (canaloplasty, Glaukos iStent, Trabectome, CyPass, Eyepass, Aquashunt, Solx Gold microshunt)

Aqueous dynamics

- Increasing outflow through the trabeculum (canaloplasty)
- Increasing outflow through collector channels (trabectome, Glaukos iStent, Eyepass)
- Increasing outflow through suprachoroidal space (CyPass, Solx Gold microshunt, Aquashunt)

All the above techniques can be combined with simultaneous cataract extraction.

3. Combined cataract–glaucoma surgery

Indications

The main indications for combined surgery are:

- the presence of cataract and medically uncontrolled glaucoma
- advanced glaucoma and cataract which is likely to progress soon after an antiglaucoma surgical procedure
- the early treatment of glaucoma in cataract patients

Pros

- Decreased risk of one surgical and anaesthetic procedure compared to two different procedures
- Less cost to healthcare services
- Less operating time
- Faster visual rehabilitation
- Decreased incidence of postoperative pressure spikes compared to cataract surgery alone

Cons

- Lengthy procedure that requires experience
- A complicated cataract surgery may compromise the success of the antiglaucoma procedure

The procedure that the surgeon will undertake first largely depends on the level of the IOP and the severity of the glaucomatous damage. It is known that phacoemulsification has a small hypotensive effect [15,16, 17]. Phacoemulsification can be considered first when there is mild glaucomatous damage which progresses very slowly (as assessed by fundoscopy and standard automated perimetry), the IOP is in the mid twenties and the patient's main concern is poor vision due to cataract. Furthermore cataract extraction can take place first if there is a bulky cataractous crystalline lens that is the most likely cause of an elevated IOP.

Trabeculectomy should be considered first if the glaucomatous damage is extensive and/or the IOP is very high and when the cataract operation is likely to intervene with the success of the glaucoma filtering procedure (e.g.: zonular instability due to pseudoexfoliation). The surgeon should be aware of the fact that phacoemulsification following trabeculectomy has an adverse effect on the survival of the antiglaucoma procedure [18]

The combined procedure should be considered when there is significant cataract in the presence of significant glaucomatous damage in a patient whose cataract operation is likely to be uneventful or when the patient would not like to have two separate procedures done or the surgeon feels that it is risky for a particular patient to be taken to theatre twice.

3.1. Anaesthetic considerations

The combined surgery can be done under general anaesthesia, retro/peribulbar or sub-Tenon's block or with topical anaesthesia. All topical blocks are carried out with the patient lying on the operating bed. We use a mixture of 1:1 lidocaine 2% and bupivacaine 0.5%.

We perform retrobulbar anaesthesia with a 23G needle. The inferior orbital rim is palpated through the skin at the junction of its middle and lateral thirds and the needle is inserted through the skin just above the rim with the patient looking straight ahead. It is then advanced parallel to the orbital floor and when the 4/5 of the length of the needle have been advanced it is slightly retracted and then redirected upwards and slightly nasally to enter the muscle cone. The plunge is retracted to check for blood reflux (blood reflux indicates that the needle may have entered a vessel and the mixture may be injected in the blood circulation). Five to 7 ml of the mixture are injected. Immediate drooping of the upper eyelid is an indication that the anaesthetic is being injected in the muscle cone. Retro/peribulbar block offers excellent anaesthesia and akinesia. The main complications are: globe perforation, retrobulbar haemorrhage, central retinal artery occlusion (due to severe and untreated retrobulbar haemorrhage), and inadvertent brain stem anaesthesia due to puncture of the meningeal sheaths of the optic nerve and injection of the anaesthetic agents in the cerebrospinal fluid circulation. As the risk of globe rupture increases with the axial length of the eye it should be avoided in big eyes as well as in patients who receive anticoagulants.

The subtenon's block is done as follows: after topical anaesthesia with tetracaine drops, a speculum is inserted and the conjunctiva and Tenon's capsule are grasped with serrated forceps 5-7 mm from the limbus in the inferonasal or inferotemporal quadrant. A fold of conjunctiva is raised with the forceps and a small incision is made with Westcott scissors. A subtenon's canula is inserted through the incision and in closed contact with the globe it is advanced around and behind the eye. Three to 5 ml of the anaesthetic mixture are injected. If the canula is in the subtenon's space then there should not be any conjunctival chemosis. Presence of significant chemosis indicates that the canula lies in the subconjunctival rather than the subtenon's space. The surgeon should make a deeper incision through both conjunctiva and Tenon's capsule and guide the canula behind the globe in close contact with the globe. Subtenon's block also offers adequate anaesthesia but less good akinesia. The most common complications are: subconjunctival haemorrhage and conjunctival chemosis. The risk of globe perforation is minimized as the subtenon's canula is blunt.

Topical anaesthesia is provided with tetracaine drops and Visthesia ampoules containing 2% lidocaine. It is the least invasive procedure but it does not offer akinesia. As the iris is not anaesthetized the patient may be more uncomfortable during the operation compared to the above techniques especially during the iridectomy.

General anaesthesia is seldom done and it is more suitable for claustrophobic patients or those who cannot lie flat and still for lengthy periods of time. In the case of general anaesthesia, retro/peribulbar and subtenon's block the eye needs to be rotated downwards with the use of a traction suture (described later) in order to expose the superior bulbar conjunctiva.

4. Combined phacoemulsification–trabeculectomy

4.1. One–site versus two–site combined surgery

There is evidence that the two-site surgery offers slightly lower IOP (1-3 mmHg) than the one-site surgery [19-21]. The authors favor the two-site technique as it causes less damage to the area of filtration and subsequently less fibrosis with better chances for the survival of the trabeculectomy over time.

In the one-site technique the main incision of the phacoemulsification is done under the sclera flap and the corneoscleral block excision is done at the site of the main incision. In the two-site approach the main incision of the phacoemulsification is done 90° away from the trabeculectomy site and towards the temporal side of the eye.

In the surgeons' experience there was no significant difference in the IOP control between the two approaches.

4.2. Limbus versus fornix conjunctival incision

The limbus and fornix based conjunctival flaps are equally effective in lowering IOP [22-24]. However there is evidence that limbus based flaps are more prone to late hypotony and bleb infection [22,25]. Early bleb leaks were more common in the fornix based flaps [23,24].

4.3. Aqueous humor dynamics in trabeculectomy

The aim of the trabeculectomy is to bypass the conventional outflow pathway through the trabeculum and Schlemm's canal. The aqueous humor flows through an internal ostium at the level of the trabeculum under the scleral flap in the subconjunctiva/sub-Tenon's space with the formation of a filtering bleb. The scleral flap reduces the unrestricted flow of aqueous and can be secured to the sclera with fixed, releasable or adjustable sutures. A peripheral iridectomy at the site of the operation prevents the peripheral iris from obstructing the internal ostium. In some cases such as pseudophakic or myopic eyes where the peripheral iris rests well away from the ostium the peripheral iridectomy can be avoided. In this way the chances of hyphaema and significant postoperative inflammation are reduced.

4.4. Risk factors in trabeculectomy

The long term success of the trabeculectomy depends on several risk factors:

- *Black race.* The AGIS study showed weak evidence that Afro-Caribbean origin is a risk factor for failed trabeculectomy [26]. The results by Scott et al [27] agree with AGIS outcomes. However two studies by Sturmer et al [28] and Broadway et al [29] did not show statistically significant differences. The latter publication although it reports higher success rate in white patients it concludes that this difference was not statistically different. The authors speculate that trabeculectomy generally is considered to be less successful in black patients and the reason for that being their younger age during surgery and the fact that Tenon's capsule is capable of producing more intense inflammatory and subsequently fibrotic response.

- *Young age.* There is conflicting evidence in the literature as to whether young age is a risk factor for failed trabeculectomy. While the AGIS study [26] and Broadway et al [29] report that trabeculectomy has less favourable outcome overtime in young patients, other studies do not confirm these findings [28,30]
- *Combined procedure.* Research shows that combined phacotrabeculectomy produces lower hypotensive effect than trabeculectomy alone (discussed later)
- *Long term treatment with multiple antiglaucoma drops.* There is strong evidence that long term treatment with antiglaucoma drops increases the number of inflammatory cells [31] and decreases the success of trabeculectomy [32]
- *Previous operations.* Subconjunctival scarring from previous operations can limit the success of the trabeculectomy. The AGIS study [26] did not identify repeat trabeculectomies (second or third trabeculectomy) as a risk factor for failure. A possible explanation may be that repeat trabeculectomies were done with the use of antifibrotic agents. Indeed Broadway et al [33] reported that trabeculectomies following conjunctival incisional operations were more likely to fail compared to primary trabeculectomies. More recent studies confirmed that repeat trabeculectomies augmented by intraoperative use of mitomycin C is an effective procedure for IOP control [34,35]
- *Secondary glaucomas (traumatic, uveitic, aphakic, rubeotic).* Mietz et al [36] found that the neovascular, traumatic and uveitic glaucoma had the worst prognosis regarding trabeculectomy survival.
- *Diabetes.* The AGIS study as well as a study by Hugkulstone et al [37] found that diabetes is a risk factor for failed trabeculectomy

4.5. Antifibrotic agents

4.5.1. Antimetabolites

Despite the initial success of the trabeculectomy clinical experience has shown that the operation tends to fail over time. This is due to the postoperative inflammation and the resulting formation of scar tissue at the site of the operation especially in the subconjunctival space. In order to improve the success of the operation surgeons resort to the use of antimetabolites namely mitomycin C (MMC) and 5-fluorouracil (5-FU) [38]. They both inhibit fibroblast proliferation: 5-FU antagonizes pyrimidine activity and inhibits DNA synthesis and thus suppresses fibroblast activity and inhibits epithelial cell proliferation while mitomycin C which is an alkylating agent interferes with all phases of cell cycle and prevents fibroblast and endothelial cell replication. MMC is more potent and has a more lasting in vivo effect than 5-FU. They can be used both intraoperatively and postoperatively. When used during surgery MMC was found to be slightly more effective than 5-FU with comparable rate of side effects [39]. The intraoperative dose of 5-FU is 0.1 ml of a 50mg/ml solution for 5 minutes. MMC has been used in varying concentration (0.2-0.4mg/ml) and application time (2-5 minutes) depending on the severity of glaucoma and presence of risk factors. The authors prefer the use

of lasik shields soaked in the antimetabolite solution under the conjunctiva and after the formation of the scleral flap.

Evidence has shown that the use of antimetabolites during surgery is associated with better IOP control [40,41]. On the other hand the use of antimetabolites has increased the incidence of side effects such as the postoperative hypotony, toxicity of the corneal epithelium, early and delayed bleb leaks, blebitis and endophthalmitis [42-44]. The antimetabolites can also be used postoperatively with bleb needling in cases of failing blebs.

4.5.2. Corticosteroids and non-steroidal anti-inflammatory drugs (NSAIDs)

It is well established that the postoperative use of topical steroids is associated with better IOP control and less glaucoma medicines [45]. Corticosteroids can be used in a preemptive fashion before surgery in patients who were treated with antiglaucoma drops as these patients have lower success rate [46,47]. Research has shown that the instillation of corticosteroids and NSAIDs before surgery leads to better outcomes in terms of likelihood of bleb needling and postoperative use of antiglaucoma drops [48]. The injection of triamcinolone in the bleb or behind the globe seems beneficial in terms of IOP control [49-51]

4.5.3. Anti-VEGF

Recently bevacizumab has been used intraoperatively instead of MMC in order to improve the success rate of the trabeculectomy but it has not proved to be superior to MMC [52,53].

4.6. Pre-operative preparation

The authors do not routinely prescribe topical corticosteroids before the antiglaucoma procedures unless the conjunctiva is markedly inflamed. In this case fluorometholone drops are given four times per day for one month before the operation. If the IOP is unacceptably high and there is high risk of expulsive haemorrhage tablets acetazolamide 250 mg 4 times per day are given for one or two days preoperatively. Additionally 200-400 ml of intravenous mannitol 20% are administered over 45-60 minutes on the morning before the operation. In theatre the eye is first anaesthetized with topical medication and then the local block is given according to the surgeon's preference. The skin around the eye is cleaned with iodine povidone solution 10%. A sterile drape is placed over the eye and a diluted 5% iodine solution is instilled on the eye and conjunctival fornices to achieve asepsis of the ocular surface.

4.7. Surgical technique

The following steps are the technique of choice of the authors for the combined phacoemulsification-trabeculectomy procedure:

- 7/0 Vicryl corneal traction suture 4 mm from the limbus (optional)
- Blunt conjunctival and Tenon's dissection over a wide area. We try to limit limbal peritomy to three o'clock hours in order to achieve watertight closure with as few sutures as possible. Dissection is carried out posteriorly towards the insertion of the superior rectus muscle

- Scleral flap formation (4×4mm) at 50% of the sclera thickness. Initially we perform a sclera incision 4mm long 4mm behind the limbus. Scleral dissection is performed with a beveled crescent knife until the limbal vessels are reached. Then we perform the side cuts to create the sclera flap.
- Application of MMC (0.2 mg/ml for 2-3 minutes) with the use of a few pieces of of a lasik shield arranged over a wide area under the conjunctiva. The edges of the conjunctiva are grasped with serrated forceps and are wiped with Weck-cell sponges in order to remove MMC. The presence of MMC at the cut edge of the conjunctiva may prevent wound closure and lead to postoperative leak.
- The area of application of MMC is then irrigated with 20 ml of balanced salt solution
- Bipolar cautery is kept to a minimum
- 2.75 mm clear cornea phacoemulsification from a temporal approach with injectable intraocular lens insertion
- Balanced salt solution (BSS) injection in the stroma or a 10/0 nylon suture at the site of the main incision of the phacoemulsification in order to encourage filtration through the scleral flap rather than the main incision. As BSS induced stromal oedema lasts for a very short period of time we prefer to close the main incision with a suture
- Pre-placement of two 10/0 Nylon releasable sutures at the two corners of the flap (fig 1). We prefer to pre-place the sutures in order to reduce the period of hypotony during the creation of the internal ostium and peripheral iridectomy
- Entry in the anterior chamber at the site of the scleral flap
- Excision of a corneoscleral block (internal ostium) with a Kelly punch.
- Peripheral iridectomy (if needed). This step can be omitted in cases of highly myopic and pseudophakic in which case the iris lies quite posteriorly from the internal ostium
- Tying of the scleral flap releasable sutures (more sutures can be used according to the surgeon's discretion). This step is very critical as the surgeon checks the amount of aqueous flowing from the edges of the sclera flap. Ideally there should be some "oozing" only, after BSS is slowly injected from side ports of the phacoemulsification
- Conjunctival and Tenon's layer closure in one plane with 10/0 nylon sutures. Usually two sutures (one at each side of the limbal peritomy) are used and tied in a purse-string fashion. One or two horizontal mattress sutures are used between the first sutures. The conjunctival wound is then checked for leakage.
- Triamcinolone or celectone chronodose injection subconjunctivally 0.1 ml behind the scleral flap at the end of the operation. 0.1 ml of gentamycin (solution of 80 mg in 2ml) is injected subconjunctivally in the lower fornix.

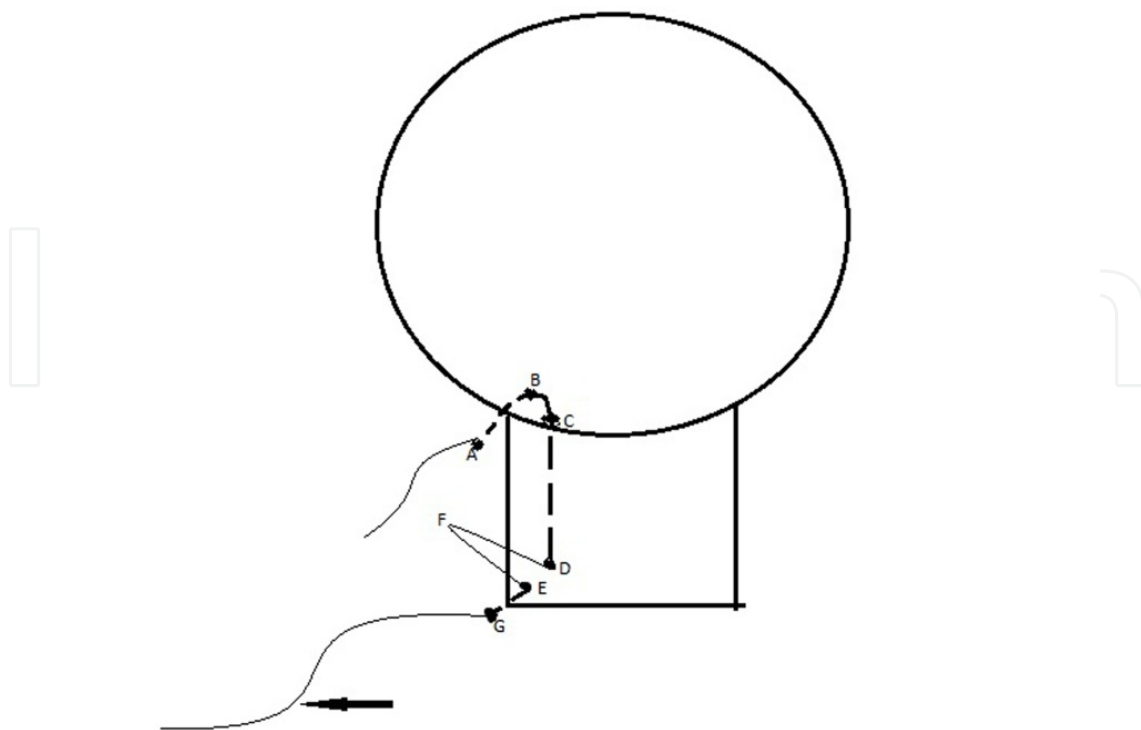


Figure 1. Technique for inserting a releasable suture. A: first entry of suture just behind the limbus, B: first exit of suture into clear cornea just in front of the limbus, C: second entry of suture into clear cornea just in front of the limbus. The suture runs through the thickness of the sclera flap and exits at point D, E: third entry point of suture through the full thickness of the sclera flap and exits at point G in the sclera. The free end of the suture (arrow) is tied with 4 throws to the loop F. The suture is not locked. It can be removed by pulling the small loop between points B and C. It is important that the suture runs at an angle of 45° between points E and G in order to pull the flap both laterally and posteriorly.

4.8. Postoperative management

Cyclopentolate drops 1% are given 3 times per day for 2-3 weeks in order to reduce the intraocular inflammation and reduce the incidence of aqueous misdirection. Drops dexamethasone 0.1% and tobramycin 0.3% 8 times per day are given in the immediate postoperative period. The frequency is reduced according to the postoperative course of the operation. If there is anterior chamber or conjunctival inflammation the drops should be given more frequently and for longer periods of time. While the antibiotic drops can be discontinued after 4 weeks, steroids may need to be continued for 6 months at a low frequency (e.g.: 1 drop/day or on alternate days). If there are signs of subconjunctival scarring (dilated vessels that do not run smoothly on the conjunctiva but seem distorted along their course), subconjunctival dexamethasone 0.1 ml (8mg in 2ml solution) and 5FU 0.1 ml (10 ml solution containing 500 mg) injections can be administered not more frequently than weekly injections. The injections are done just behind the bleb. The insertion of the needle should be at least 5mm away from the bleb in order to avoid bleb leakage after the needle is withdrawn.

Needling may be needed if there is scarring. We perform the needling at the slit lamp as follows: the eye is anaesthetized with tetracaine 1% and Visthesia ampoules. Asepsis of

the ocular surface is achieved with 5% iodine povidone solution. A 30G needle mounted on a insulin syringe containing BSS is inserted under the conjunctiva at least 5mm away from the bleb. BSS is slowly injected to lift the conjunctiva and the needle is directed towards the site of the bleb. Subconjunctival fibrosis is broken with sweeping movements of the needle. If the anterior chamber is to be entered a Hoskins lens is used to deturgess the conjunctiva. The tip of the needle is used to cut the fibrous tissue around the edges of the sclera flap and lift the flap. The needle then enters the anterior chamber through the internal ostium. A mixture of 0.1 ml dexamethasone and 0.1 ml 5 FU is injected through the same entering point behind the bleb.

Argon laser suturolysis can be performed when the sclera flap sutures are tight and obstruct aqueous outflow. The settings are 50 μ spot size, 150-250 mW power, 0.1 seconds exposure time through a Hoskins lens.

4.9. Outcomes

There is evidence that combined cataract-glaucoma surgery produces slightly lower hypotensive effect than trabeculectomy alone. [54]

4.10. Complications

The complications of the combined cataract-glaucoma surgery include those of phacoemulsification and those of trabeculectomy. In this chapter we analyze the most common complications of trabeculectomy. It should be noted that a complicated cataract surgery can compromise the success of the trabeculectomy mainly due to the presence of intense inflammation, vitreous or blood in the anterior chamber.

Intraoperative:

- Conjunctival buttonhole. Management: suturing with 10/0 nylon
- Hyphaema

Mechanism: bleeding from the peripheral iridectomy

Management: none if it is minimal, aspiration of blood if it stains the cornea or the IOP is high (≥ 30 mmHg for 5 days or ≥ 50 mmHg for two days)

Postoperative

The postoperative complications can broadly be divided in early (which occur 6 weeks after surgery) and late (which occur after 6 weeks from surgery)

Early postoperative:

- High IOP with deep anterior chamber
- Retained viscoelastic. Management: observation, antiglaucoma drops. If IOP is very high it can be aspirated in theatre
- Steroid response. Management: antiglaucoma drops, non-steroidal anti-inflammatory drugs

- Resistance at the level of sclerostomy

Causes:

- Blood. Management: topical steroids, ocular massage, intracameral tissue plasminogen activator [55], aspiration in theatre.
- Iris: retraction of iris tissue with argon laser, removal of iris in theatre.
- Vitreous: YAG-laser to release vitreous, removal of vitreous in theatre.
- Resistance at the level of scleral flap

Causes:

- Tight sutures. Management: ocular massage, argon laser suturolysis, removal of releasable sutures
- Blood. Management: topical steroids, ocular massage, intracameral tissue plasminogen activator, aspiration in theatre.
- Resistance at the level of conjunctiva/Tenon's layer

Causes

Diffuse scar tissue formation or formation of encapsulated bleb (Tenon's cyst). Management. Topical steroids, bleb needling with 5-FU or MMC injection, scar tissue removal in theatre.

There are several signs that will help the clinician to identify the site of obstruction. Gonioscopy will reveal the causes of the obstruction at the level of the internal ostium. Resistance at the level of the sclera flap will produce a very low bleb with no intraepithelial cysts (which are a sign of ample aqueous flow). Resistance at the subconjunctival level with diffuse scar formation will produce a low or slightly elevated bleb with microcysts formation at some areas of the bleb. The conjunctival vessels may be dilated (due to inflammation and subsequent scar tissue deposition) and they can appear "kinked" at some points along their course. Tenon's cyst is a high dome shaped, localized and avascular bleb without microcysts. There may be some engorged vessels on its surface. They typically appear 2-6 weeks after surgery.

- High IOP with shallow anterior chamber

Causes

- Pupillary block. Management: YAG laser/surgical iridectomy. The setting that we use for YAG laser iridectomy are: single or double pulsed shots, defocused posteriorly with starting energy at 5 mJoules
- Suprachoroidal haemorrhage. Management: cycloplegia, topical and systemic steroids, evacuation of blood through sclerostomies in the case of kissing choroidals.
- Aqueous misdirection. Management: mydriatics, aqueous suppressants, YAG laser disruption of the anterior vitreous face, vitrectomy (it disrupts the anterior hyaloids)
- Low IOP with deep/shallow anterior chamber

Risk factors: male gender, young age myopia, MMC [56-58]

Causes

- Overfiltration. Management: pressure patch, large diameter contact lens, cryotherapy, suturing of the scleral flap

- Bleb leak. Management: pressure patch, large diameter contact lens, cyanoacrylate glue, autologous blood, suturing of the conjunctiva
- Aqueous shutdown. Management: topical steroids
- Cyclodialysis cleft. Management: mydriatics, laser photocoagulation/cryotherapy/suturing of the cleft with 7/0 or 8/0 nylon sutures as the 10/0 nylon may not be strong enough to hold the cleft closed if the IOP increases dramatically in the early postoperative period.

In the presence of a very shallow anterior chamber management should include reformation of the anterior chamber with viscoelastic and if there are large choroidal effusions which touch each other (kissing choroidals) then they must be drained via sclerostomies. If the choroidal effusions are not touching each other they can be conservatively managed with cycloplegics, topical steroids. Periocular and oral steroids can also be given

Late postoperative

- Late bleb failure

Causes: scarring. Management: bleb needling, injection of 5-FU/MMC, trabeculectomy revision/redo, glaucoma drainage implants

- Late bleb leak

Cause: thin walled bleb. Risk factors: antimetabolites. Management: aqueous suppressants, large diameter bandage contact lens, autologous serum, cyanoacrylic glue, autologous blood injection in the bleb, conjunctival excision with conjunctival advancement or flap

- Blebitis and bleb related endophthalmitis

Causes: infection of the bleb by various micro-organisms.

Risk factors: thin walled blebs, bleb leaks, exposed sutures, antimetabolites, blepharitis, conjunctivitis, nasolacrimal duct obstruction, diabetes.

Management: sample cultures, broad-spectrum antibiotics (for blebitis), vitreous tap, intravitreal antibiotics ± vitrectomy (for bleb related endophthalmitis)

- Persistent hypotony due to MMC effect (toxic effect on the ciliary body) [59,60]

5. Combined phacoemulsification–non penetrating glaucoma surgery (NPGS)[deep sclerectomy (DS)–Viscocanalostomy (VC)]

5.1. Aqueous humor dynamics in NPGS

The search for a filtering surgery that would minimize the complications of the penetrating surgery has led to the development of the non penetrating procedures in which the anterior chamber is not entered. The aqueous from the anterior chamber percolates through the trabeculo-Descemet's membrane (TDM) either in the episcleral space and then in the subconjunctival/sub-Tenon's space (fig 2), or in the Schlemm's canal (SC) and suprachoroidal space. As the aqueous diffuses to routes other than the subconjunctival/sub-Tenon's space these procedures do not always show elevated filtering blebs. This is especially true for viscocana-

lostomy in which the aqueous is directed in the enlarged SC and the tight suturing of the scleral flap is considered as a crucial part of the surgical procedure.

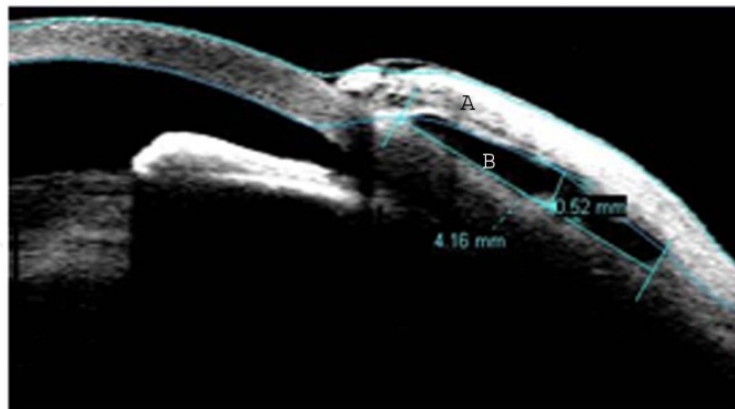


Figure 2. Aqueous in the subconjunctival space flowing DS. A: bleb wall, B: bleb cavity (courtesy of Prof Kozobolis).

5.2. Indications

The main indication for combined phaco-NPGS is the primary open and secondary open angle glaucomas in the presence of visually debilitating cataract.

5.3. Contraindications

Non penetrating glaucoma surgery is useful in open angle glaucomas but should be avoided in closed angle glaucomas as the peripheral iris in these cases blocks the TDM and obstructs the percolation of aqueous. NPGS has also been used in congenital and juvenile glaucomas [61-63].

5.4. Antimetabolites

The adjunctive use of MMC in NPGS showed better hypotensive effect at the cost of higher rate of complications (thin avascular blebs, transconjunctival oozing) [64,65].

5.5. Pre-operative preparation

The same principles apply for the pre-operative preparation as for trabeculectomy

5.6. Surgical technique

The following steps are the technique of choice of the authors for the combined phacoemulsification-DS procedure:

- 7/0 Vicryl corneal traction suture 4 mm from the limbus (optional)
- Conjunctival and Tenon's dissection. As for trabeculectomy we try to keep the limbal peritomy as small as possible

- Application of MMC (0.2 mg/ml for 2-3 minutes) with the use of a few pieces of a lasik shield under the conjunctiva. The edges of the conjunctiva are lifted and wiped off the MMC solution
- The area of MMC application is then irrigated with 20 ml of balanced salt solution
- Bipolar cautery is kept to a minimum
- Formation of a superficial scleral flap at 1/3 of sclera thickness. After the sclera incisions the sclera is dissected anteriorly with a diamond knife until it projects for 1.5 mm into clear cornea
- 2.75 mm clear cornea phacoemulsification from a temporal approach with injectable intraocular lens insertion
- 10/0 nylon suture at the site of the main incision of the phacoemulsification
- The superficial flap is then everted over the cornea and a second deeper triangular scleral flap is dissected under high magnification leaving a very thin layer of scleral tissue over the uvea.
- This second flap is dissected anteriorly in order to deroof Schlemm's canal followed by the removal of the inner wall of SC and the juxtacanalicular trabeculum with the purpose of increasing the aqueous outflow (fig 3)
- Excision of the deep scleral flap
- The superficial scleral flap is repositioned and secured with two 10/0 nylon sutures in a tent – like formation
- Viscoelastic (sodium hyaluronate 1%) is then injected under the scleral flap in order to create a space for the pooling of the aqueous humor
- Conjunctival and Tenon's layer closure in one plane with 10/0 nylon sutures in the same fashion as for trabeculectomy.
- Viscoelastic is then injected under the conjunctiva
- Triamcinolone or celectone chronodose injection subconjunctivally 0.1 ml behind the scleral flap at the end of the operation. 0.1 ml of garamycin (80 mg in 2 ml solution) are injected subconjunctivally in the lower fornix

For viscocanalostomy (VC) the steps are:

- Conjunctival dissection as for DS
- Application of MMC (0.2 mg/ml for 2-3 minutes) with the use of a few pieces of of a lasik shield arranged over a wide area under the conjunctiva.
- Superficial scleral flap creation as for DS
- Clear cornea phacoemulsification from a temporal approach with injectable intraocular lens insertion

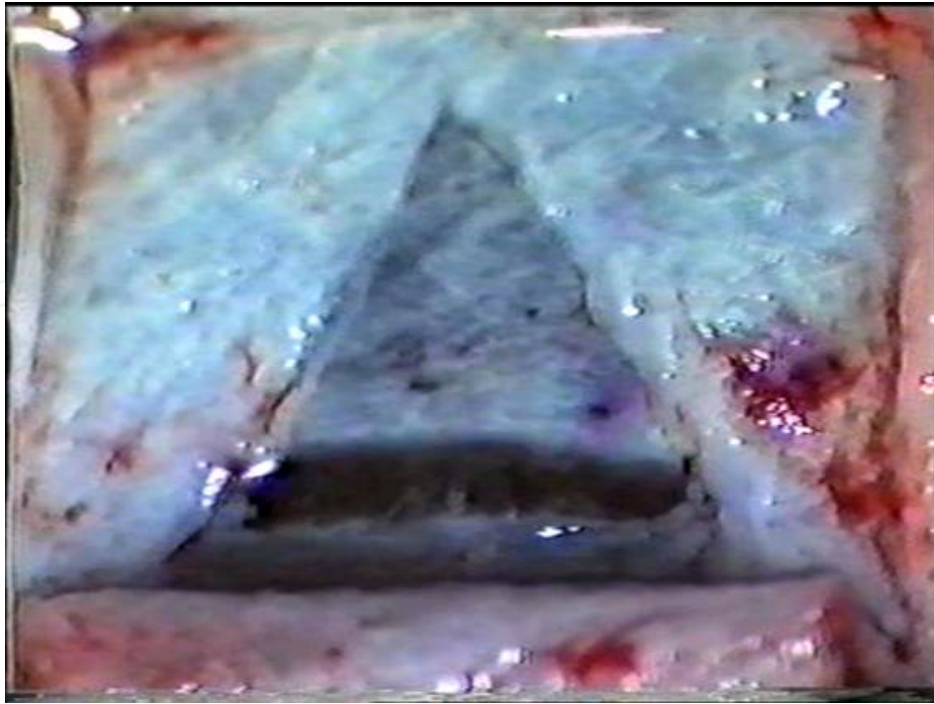


Figure 3. Deep sclerectomy site after excision of the deep scleral flap and peeling of the inner wall of the SC (courtesy of Prof Kozobolis)

- 10/0 nylon suture at the site of the main incision of the phacoemulsification
- Deep scleral flap formation as for DS
- Cannulation of the SC with the injection of high molecular weight viscoelastic device
- Unroofing of SC and dissection of deep peripheral corneal stroma from underlying Descemet's membrane
- Peeling of the inner wall of SC and juxtacanalicular trabeculum
- Excision of the deep scleral flap
- Tight suturing of the superficial flap to sclera with two 10/0 Nylon sutures
- Conjunctival closure with 10/0 nylon sutures.

Viscocanalostomy with or without the use of an implant has the same success rate [66]. One-site and two-site phaco-VC showed the same level of success [67].

5.7. Postoperative management

Topical steroids and antibiotics are given as in trabeculectomy. Again as for trabeculectomy antibiotics can be stopped after 4 weeks but steroids can be continued for 6 months or even longer at a low frequency. Cycloplegia is not necessary. As DS (and VC to a lesser extent) relies on a bleb formation for IOP control needling may be required if there is subconjunctival scarring or Tenon's cyst formation which are managed as described above. Tight sclera flap

sutures are treated with argon laser suturolysis. Specifically for NPGS YAG laser puncture can be performed in case of iris prolapsed through the TDM with high IOP. The settings used are single pulsed shots, 3-5 mJoules through a gonioscopy lens. Pilocarpine 2% and argon laser iridoplasty can be used to pull away the iris from the site of incarceration. The settings for iridoplasty are 300-400 μ spot size, 0.2 seconds exposure time, 300-400mWatt power through an iridectomy lens. If the IOP in the early or late postoperative period is thought to be due to poor aqueous filtration through the TDM, then YAG laser goniopuncture of the TDM can be tried. The settings are single pulsed shots, 4-6mJoules energy through a gonioscopy lens.

5.8. Outcomes

As opposed to phacotrabeculectomy, combined phaco-DS has better outcomes in terms of IOP control than DS alone [68]. Phacotrabeculectomy and phaco-DS showed no statistical difference in the IOP control although the phacotrabeculectomy groups tend to have lower IOP. Phaco-DS was the safer procedure in terms of complication rates [69,70].

Similarly viscocanalostomy offers slightly better hypotensive effect than phacoviscocanalostomy [71]. Compared to phacotrabeculectomy, phaco-VC offers similar IOP control in patients with primary open angle glaucoma. [72,73]

5.9. Complications

The complications of the combined cataract-glaucoma surgery include those of phacoemulsification and those of NPGS. The latter can be divided into intraoperative and postoperative.

● Intraoperative

- Perforations of the TDM. Management: if small no further management is required. If they are large with iris prolapse a peripheral iridectomy should be carried out.
- Hyphaema

● Postoperative

- Early hypertony.
 - Causes:
 - retained viscoelastic. Management: observation, antiglaucoma drops, aspiration
 - haemorrhage in the scleral bed. Management: none required
 - Steroid response. Management: antiglaucoma drops, non-steroidal anti-inflammatory drugs
 - Rupture of the TDM with iris prolapse. Mechanism: rubbing of the eye, Valsalva's maneuver. Management: miotics, steroids, YAG laser of the prolapsed iris, argon laser iridoplasty, surgical removal of iris tissue
 - Pupillary block, aqueous misdirection, suprachoroidal haemorrhage. Management: as in trabeculectomy
- Early hypotony
 - Causes:
 - Conjunctival wound leak. Management: suturing

- Ciliary body shutdown due to inflammation. Management: steroids
- MMC effect (toxic effect on the ciliary body)
- Hemorrhagic Descemet's membrane detachment [74] (fig 4,5)
- Ocular decompression retinopathy [75] (fig 6). It is caused by a sudden drop of the IOP during surgery. It is not exclusively seen in NPGS but also in penetrating glaucoma surgery, YAG laser iridotomy, and medical treatment for acute primary closure glaucoma (76,77)
- Late hypertony
 - Causes:
 - rupture of the TDM with iris prolapsed
 - Poor filtration through TDM. Management: YAG laser microperforations to TDM
 - Conjunctival scarring. Management: intensive topical steroids, subconjunctival injection of 5-FU/MMC
 - Bleb encapsulation. Management: bleb needling with 5-FU/MMC injections
- Late hypotony
 - Causes
 - Conjunctival wound leak
 - Ciliary body shutdown due to inflammation
 - MMC effect
- Blebitis and bleb related endophthalmitis

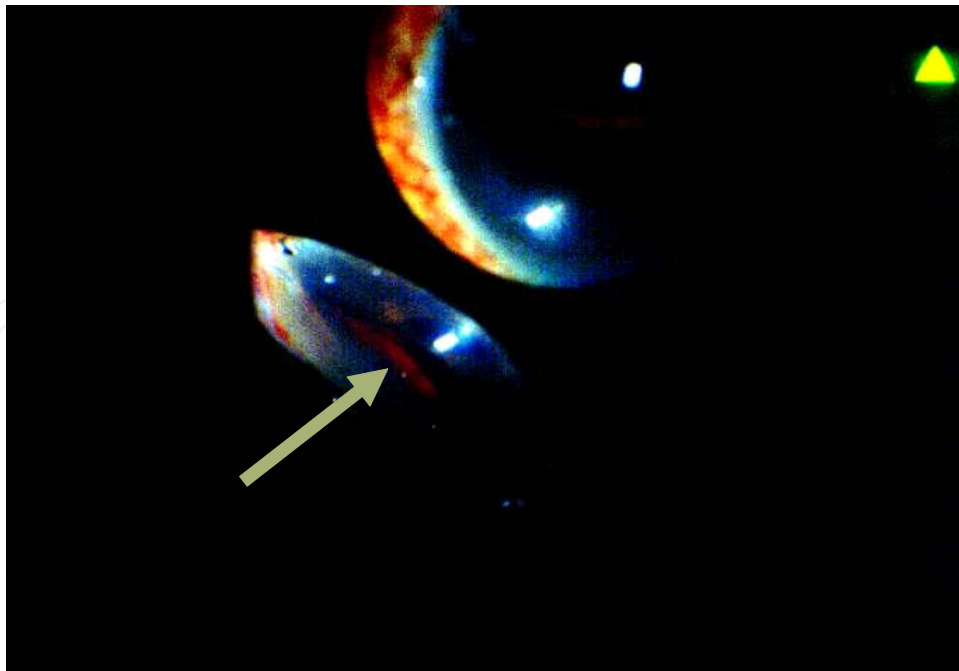


Figure 4. Hemorrhagic Descemet's membrane detachment (arrow) as seen through a Goldmann 4-mirror lens (courtesy of Prof Kozobolis)

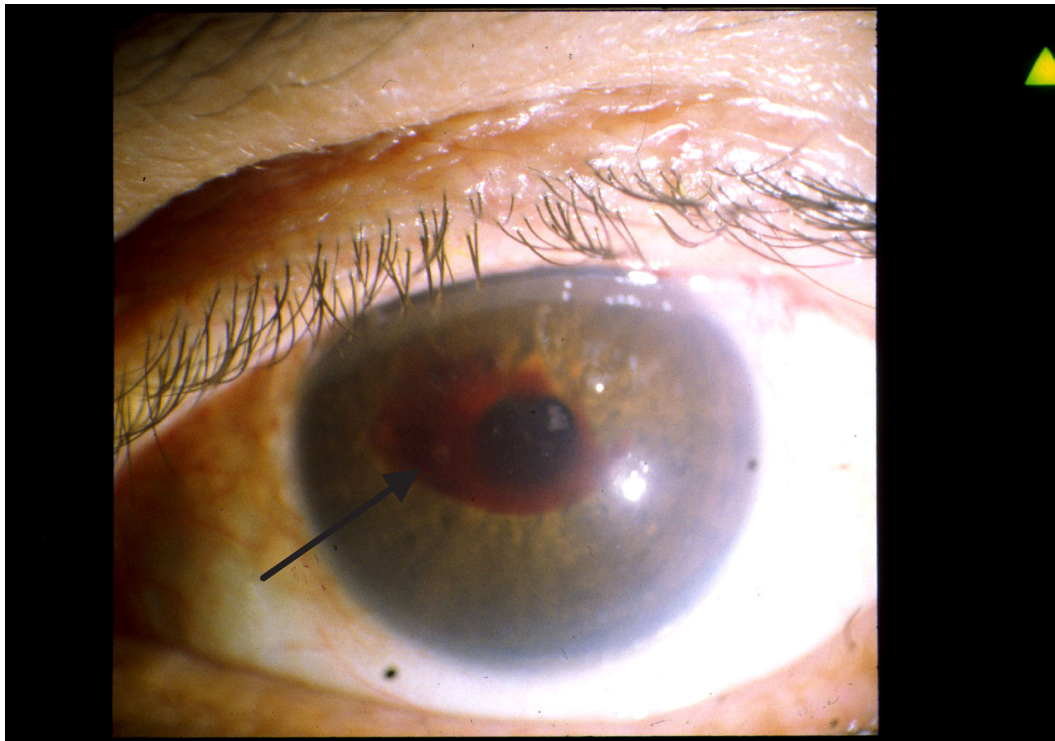


Figure 5. Hemorrhagic Descemet's membrane detachment 3 weeks postoperatively (arrow). The patient had a visual acuity of hand movements from 20/32 preoperatively. Six months after surgery the Descemet's membrane was completely re-attached with a small residual scar. IOP control was excellent throughout the postoperative period (courtesy of Prof Kozobolis).

6. Combined phacoemulsification–glaucoma drainage devices (GDDs)

The first choice in the surgical management of glaucoma is a filtering operation. In some cases though, this type of surgical approach is thought to have low success rate. In these cases a GDD is the optimum choice.

6.1. Indications

The indications for this combined procedure are the presence of visually significant cataract in the presence of the following conditions:

- Failed trabeculectomy
- Neovascular glaucoma
- Primary and secondary congenital glaucoma
- Corneal grafts
- Traumatic glaucoma
- Extensive conjunctival scarring (e.g. buckle surgery)

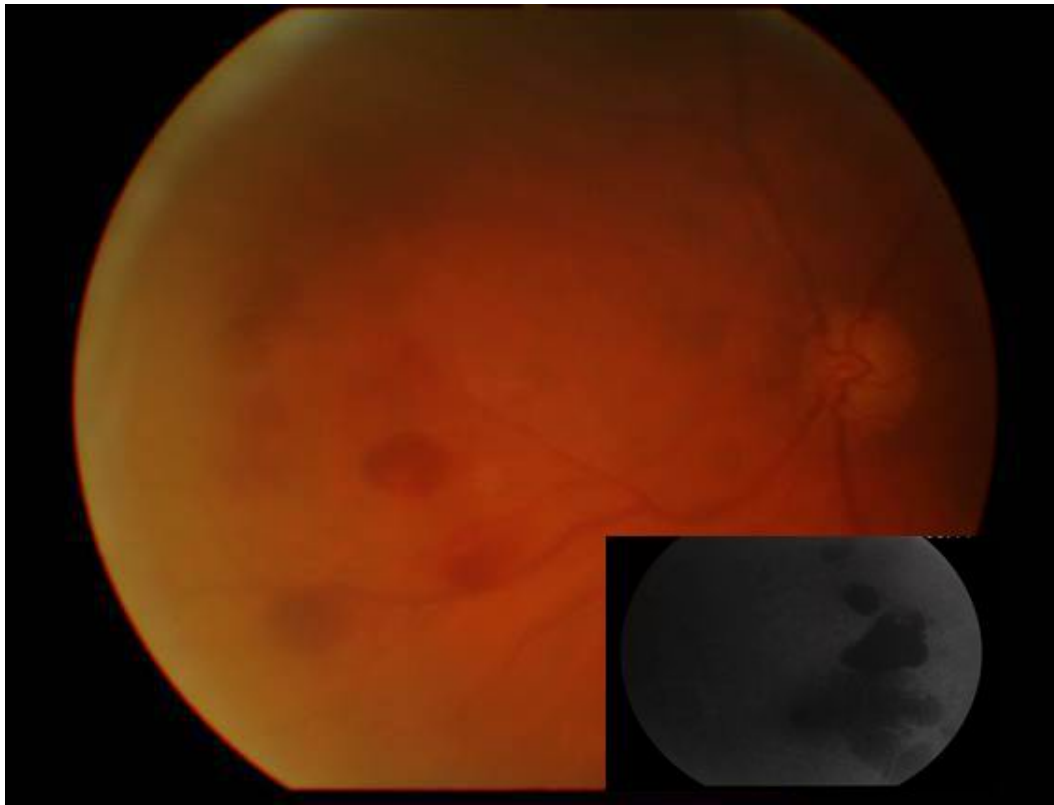


Figure 6. Decompression retinopathy. Insert: red free picture. This patient had a decrease of his visual acuity from 0.2 loMAR preoperatively to hand movements on the first postoperative day and the IOP dropped from 32 mmHg before surgery to 5 mmHg on the day after surgery. There was no leakage and the patient denied violent coughing or sneezing. The patient was prescribed the standard postoperative topical medication. An intravenous fluorescein angiogram did not show any evidence of central retinal vein occlusion. The visual acuity improved to preoperative level 3 months after surgery and the retinal haemorrhages gradually disappeared. IOP ranged from 7-14 mmHg without any topical antiglaucoma drops (courtesy of Prof Kozobolis)

- Primary surgery in open angle glaucoma (Ahmed GDD)

6.2. Choice of GDD

When deciding which GDD to use the surgeon should have in mind that:

- Valved GDDs allow unidirectional flow with low opening pressure and do not require ligating suture
- Non valved GDDs require ligation of the lumen with 7/0 or 8/0 Vicryl suture and/or occlusion of the lumen with 3/0 supramid suture (nylon braided)
- Size of plate: the larger the plate the larger the fibrous capsule around the plate and filtration area. However numerous studies have shown that in the long term the larger plates do not produce significantly lower intraocular pressures [78-79]
- Plate material: silicone plates seem to do better than the polypropylene ones with lower complication rate (Tenon's cyst formation) [80-84].

6.3. Antimetabolites and anti-VEGF

There is conflicting evidence as to whether MMC and bevacizumab improve the success rate of Ahmed GDD. Mahdy et al [85] reported that both the application of MMC and injection of bevacizumab around the footplate of the GDD at the end of the operation improve the hypotensive effect. Alvarado et al [86] found that the use of high concentrations and application time of MMC also offer better hypotensive effect. On the other several other authors have reported that the intraoperative use of MMC did not improve the results of the GDD implantation [87-90].

6.4. Surgical technique

The surgical technique described below applies mainly to the Ahmed GDD as this is the GDD that we use.

- 7/0 Vicryl corneal traction suture 4 mm from the limbus at the quadrant of the GDD insertion (optional)
- Conjunctival and Tenon's dissection (fornix based, supero-temporal quadrant preferably). Limbal peritomy extends for 3-4 o'clock hours. Relieving cuts are made perpendicular to the limbus in order to achieve better exposure of the sclera.
- When using large plate GDDs lateral/medial rectus muscles and superior rectus need to be isolated with bridle 4/0 silk sutures
- Fixate plate on the sclera with 8/0 nylon sutures. The plate is fixated 8mm from the limbus and the suture needles are passed through the holes at the anterior edge of the plate
- Prime valved GDDs. The GDDs are primed by irrigating BSS with a 30G blunt canula from the tip of the tube. BSS should exit at the proximal end of the tube
- Trim tube. The surgeon trims the tube with scissors allowing about 3 mm of the tube length to enter in the anterior chamber in front of the iris
- Preplace tube fixation suture (9/0 silk) on sclera
- Preplace patch graft sutures (8/0 nylon) on sclera. Two sutures are used one at each side of the graft. Preplacing the sutures reduces the period of hypotony during the GDD insertion. The patch graft may be sclera, pericardium, cornea, fascia lata or dura.
- Do clear cornea phacoemulsification (away from the area of GDD insertion, suture main incision)
- Create track for the tube with 22 or 23G needle. The needle is bent at 90° at two places with the bevel of the tip of the needle facing upwards. The needle is inserted 1 mm behind the limbus at a plane parallel to the iris. The needle is mounted on a viscoelastic syringe. Viscoelastic can be injected as the needle is withdrawn in order to keep the tract open and facilitate the tube insertion
- Insert tube in anterior chamber. The tube is grasped with serrated forceps near the tip and pushed along the needle track. It may need to be grasped several times until it is inserted

- Tie the tube fixation suture. The suture must not occlude the lumen of the tube
- Tie patch graft sutures
- Suture Tenon's capsule and conjunctiva. The conjunctiva is first sutured at the limbus at its two corners. The relaxing incisions are sutured with running sutures. Finally the anterior edge of the conjunctiva is sutured to the limbus with two horizontal mattress sutures. We use 10/0 nylon for this step of the procedure
- Supramid suture must protrude under the conjunctiva so that it can be removed later in the postoperative period

6.5. Complications

The complications of the combined cataract-glaucoma surgery include those of phacoemulsification and those of the GDDs.

GDD complications

- Hypotony (more likely with non valved GDDs)
 - Causes:
 - incomplete obstruction of the non valved GDDs. Management: resuturing
 - Leakage around the tube. Management: repositioning of the tube
 - inflammation
 - Hypertensive phase (most common with Ahmed GDDs).
Mechanism: formation of fibrous capsule around the plate. Management: antiglaucoma drops, ocular massage, needling with 5-FU, removal of GDD
 - Tube occlusion
Causes: blood, fibrin, vitreous, iris. Management: removal of the agent that causes the obstruction with YAG laser or surgically.
 - Tube/graft erosion through conjunctiva. Management: covering of the tube with donor sclera.
 - Tube touching corneal endothelium. Management: repositioning of the tube
 - Retraction of the GDD. Management: repositioning of the GDD
 - Endothelial decompensation
 - Diplopia (large plate GDDs). Management: prisms, strabismus surgery, removal of GDD.
 - Endophthalmitis

6.6. Postoperative management

Topical antibiotic and steroids are given as for trabeculectomy. Antibiotics can be stopped one month postoperatively but steroids will need to be continued for longer. Cycloplegia is given for 2-3 weeks. Ahmed GDDs are renowned for their hypertensive phase which happens after

3-6 weeks as fibrous tissue is forming around the plate. The IOP must be lowered with topical antiglaucoma medication or even acetazolamide tablets. Needling of the fibrous capsule with 30G needle may be tried with injection of dexamethasone and 5FU as for trabeculectomy.

6.7. Outcomes

The combined surgery does not seem to adversely affect the hypotensive effect of the GDD [91].

7. Combined phacoemulsification-Ex-PRESS GDD

The Ex-PRESS GDD works differently compared to the GDDs described above. It is a miniature stainless steel non valved GDD with 0.4mm external diameter and 50 or 200 μm internal diameter depending on the model. It has a length of 2.4 – 3.0 mm, it is safe in magnetic fields up to 3 Tesla [92,93] and does seem to interfere with the quality of the MRI images of the orbit [94].

7.1. Indications

- Open angle glaucomas
- In case of narrow angles there may not be enough room to fit the mini implant
- Is not the best option in congenital glaucomas as it is a new procedure and the concomitant use of antimetabolites may cause problems in the long run in young patients.

7.2. Aqueous humor dynamics in Ex-PRESS GDD

The Ex-PRESS GDD is an alternative to trabeculectomy as it only replaces the internal ostium and negates the need for a peripheral iridectomy. The aqueous flows through the GDD in the subconjunctival/sub-Tenon's space and forms a filtering bleb.

7.3. Antimetabolites

The insertion of the Ex-PRESS GDD can be augmented with the intraoperative application of MMC in order to reduce conjunctival scarring and improve bleb survival

7.4. Corticosteroids

As with trabeculectomy the authors augment the operation with the injection of 0.1 ml of triamcinolone under the conjunctiva behind the scleral flap at the end of the operation. Standard postoperative care includes the use of topical steroids and antibiotics.

7.5. Surgical technique

- The initial steps for the combined phaco- Ex-PRESS GDD procedure are the same as for trabeculectomy up to the creation of the track for the insertion of the mini shunt

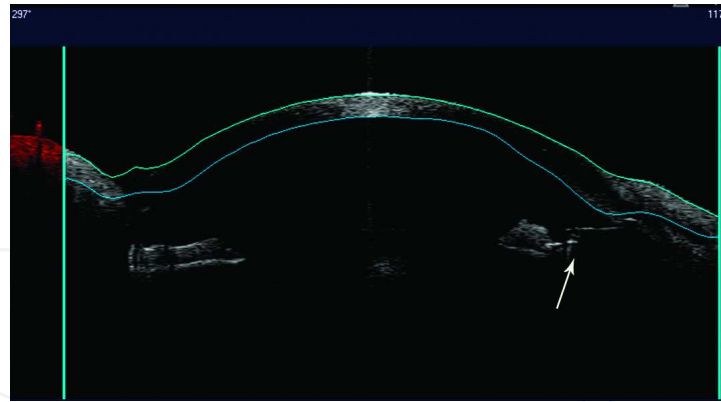


Figure 7. Ex-PRESS GDD indenting the iris (arrow) without any adverse effects and excellent IOP control(courtesy of Prof Kozobolis)

- Ex-PRESS inserted at the blue transition zone between clear cornea and sclera (corresponds to juxtacanalicular meshwork) with the use of a 25G needle. The direction of the needle must be parallel to the iris plane. The needle is advanced until it is clearly seen in the anterior chamber
- Tying of the scleral flap releasable sutures (more sutures can be used according to the surgeon's discretion).
- Conjunctival closure with 10/0 nylon sutures as in trabeculectomy.
- Triamcinolone injection subconjunctivally 0.1 ml behind the scleral flap at the end of the operation.

7.6. Postoperative management

As the insertion of the Ex-PRESS GDD is a small trabeculectomy the postoperative management is the same as for trabeculectomy.

7.7. Complications

As the Ex-PRESS mini GDD is a modification of trabeculectomy and the aqueous dynamics are similar the complications from its insertion are similar to that of trabeculectomy. Complications specific to the technique include obstruction of the GDD by blood, fibrin and vitreous. The device may also touch the iris and can be repositioned via another track (fig 7). The track can be done under the same sclera flap next to the initial one. Mal-positioned devices do not need to be re-inserted if they are symptom free and offer adequate hypotensive effect (fig 8). The Ex-PRESS mini shunt may be blocked by fibrin, blood or vitreous. YAG laser is an excellent tool which can be used to remove the blockage [95].

7.8. Outcomes

The Ex-Press GDD is at least as effective as TM in terms of long term IOP control and number of postoperative antiglaucoma drops. It also has lower complication rate compared to

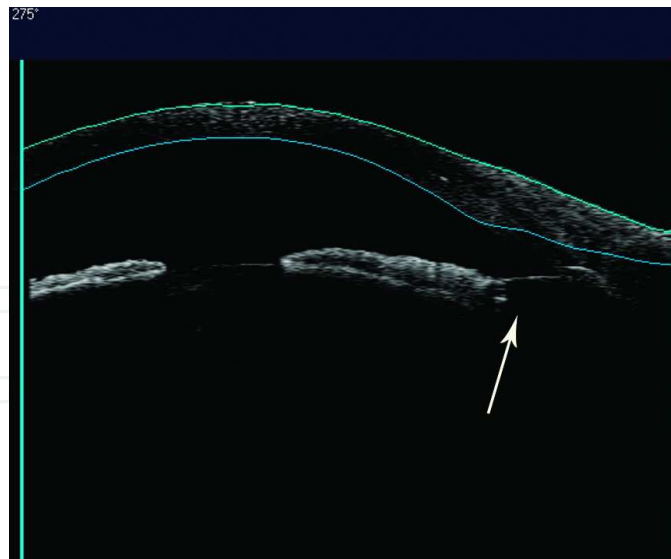


Figure 8. Ex-PRESS GDD (arrow) inserted through a patent peripheral iridectomy in posterior chamber with excellent IOP control (courtesy of Prof Kozobolis)

trabeculectomy [96-101]. The combined phaco-Ex-PRESS operation has the hypotensive effect as the simple insertion of the device [102].

8. New techniques

The aim of the procedures is to enhance the normal outflow of aqueous via the conventional and uveoscleral pathways without the formation of a filtering bleb. The Trabektome, the Eyepass and the Glaukos iStent require access to SC through the trabeculum and can be combined with phacoemulsification which by the removal of a bulky cataractous crystalline lens facilitates access to the anterior chamber angle.

8.1. Indications

The indications of the new techniques is mild to moderate open angle glaucoma

8.2. Surgical technique

The micro-implants described below are inserted after the completion of standard phacoemulsification

9. Canaloplasty

9.1. Surgical technique

- Conjunctival dissection

- Formation of a 5×5 mm superficial scleral flap at 50% of sclera thickness
- Formation of a 4×4 mm deep scleral flap extending into clear cornea to create a Descemet's window as for DS
- Clear cornea phacoemulsification from a temporal approach with injectable intraocular lens insertion
- Excision of the deep scleral flap
- Insertion of a microcatheter in one of the two cut ends of Schlemm's canal (iTrack 250A)
- The microcatheter is pushed around SC with injection of sodium hyaluronate in order to dilate the canal and create microruptures in the wall.
- The microcatheter has a light at its tip so that the surgeon can follow it as it is driven around SC
- When the tip of the microcatheter emerges at the other cut end of SC a 10/0 Nylon suture is tied on the tip and the microcatheter is pulled back
- When the tip of the microcatheter emerges from the cut end of SC the two ends are tied together to provide moderate tension on the canal.
- The superficial flap is tied securely to the sclera with 10/0 Nylon
- Conjunctiva is sutured with 10/0 Nylon

9.2. Outcomes

Combined phaco-canalostomy provides slightly better hypotensive effect and less antiglaucoma drops than canalostomy alone [103,104]. Compared to trabeculectomy it offers lower but not statistically significant hypotensive effect and requires more antiglaucoma medication than trabeculectomy [105].

9.3. Complications

The most common complications are hyphaema, peripheral anterior synechiae, Descemet membrane detachment

10. Solx gold microshunt (GMS)

The GMS is a flat-plate non valved drainage device which is inserted in the suprachoroidal space and increases uveoscleral outflow. It is made of 24 karat gold and its dimensions are 3.2 mm wide, 5.2 mm long and 44µm thick. The aqueous enters the device from the proximal side which contains 60 holes 100 µm each. The device contains 10 open and 9 closed channels (width of lumen 24µm and height 50µm) and at the distal end the fluid exits in the suprachoroidal space via a grid of 117 holes on either side. The proximal end of the GMS contains 12 additional channels and the distal end 10 channels 50 µm each

10.1. Surgical technique [106]

- Conjunctival dissection at the limbus
- Full thickness scleral incision 2.5 mm behind the limbus down to the ciliary body. Anterior chamber is entered at 90% of the scleral thickness with a crescent knife
- Posterior dissection to expose the suprachoroidal space with a blunt cannula for 4-5 mm
- The anterior part of the GMS is placed in the anterior chamber and the posterior in the suprachoroidal space
- The implant is pushed posteriorly with an insulin needle so that 1-1.5 mm of the proximal end is in the anterior chamber
- Sclera is closed with 7/0 Vicryl sutures
- Conjunctiva is sutured with 10/0 Nylon sutures

10.2. Outcomes

Figus et al [107] reported 67% qualified success at 2 years. Melamed et al [106] reported 79% success rate with or without medication after a mean follow up period of 11.7 months

10.3. Complications

Hyphaema, choroidal effusions, bullous keratopathy due to contact of the implant with the endothelium, exudative retinal detachment due to overfiltration

11. Glaukos iStent

The iStent is an L shaped titanium device 1mm long with an internal lumen diameter of 120 μm . It is inserted in the SC following phacoemulsification. The most common complication is stent malposition and obstruction by blood, vitreous, fibrin.

11.1. Outcomes

Samuelson et al [108] reported that combined phaco-iStent provided better hypotensive effect at one year than simple phacoemulsification which is statistically significant. Craven et al [109] also support this finding with phaco-iStent which offers better IOP control at 2 years than phacoemulsification.

12. Trabektome

Trabektome is a foot switch operated handpiece which ablates the trabeculum and inner wall of SC and can follow phacoemulsification with a temporal approach. If the anterior chamber

angle is wide enough the ablation can take place before cataract extraction through the main incision. The Trabektome's handpiece has an aspiration port and an electrocautery-ablation system. The handpiece is driven along the nasal angle and treats an area of 60°-120° of trabeculum

12.1. Outcomes

Ting et al [110] reported that Trabektome controls IOP better in eyes with pseudoexfoliation glaucoma than primary open angle glaucoma and has more profound effect when combined with phacoemulsification.

13. Aquashunt

The Aquashunt device is placed in the suprachoroidal space and aims to facilitate aqueous outflow via the uveoscleral pathway. Instead a multiple small channels it has one large channel. A phase I multicenter trial is being conducted.

14. Eyepass

The Eyepass intracanalicular stent is a Y-shaped 1 mm long silicone tube that can be inserted in the SC following phacoemulsification. The two arms of the tube are inserted in the SC and the dual-bonded end protrudes in the anterior chamber.

14.1. Surgical technique [111]

- Conjunctival dissection at the limbus
- Formation of a superficial scleral flap (as in NPGS)
- Clear cornea phacoemulsification away from the area of the scleral flap
- Creation of the deep scleral flap with unroofing of the SC
- Dilatation of the SC with viscoelastic device (sodium hyaluronate 1%)
- Insertion of the two arms of Eyepass in the SC
- Insertion of the common stem of the device in the anterior chamber through a paracentesis 1 mm in front of the trabeculum
- Watertight suturing of the scleral flap with 10/0 Nylon sutures
- Conjunctiva closed with 10/0 Nylon sutures

14.2. Complications

The most serious complication is the perforation of the trabeculum during insertion of the arms of the device and conversion to trabeculectomy.

14.3. Outcomes

Dietlein et al [111] reported good hypotensive effect with fewer antiglaucoma drops of the Eyepass combined with phacoemulsification in patients with pseudoexfoliation and primary open angle glaucoma.

15. CyPass

The Cypass is a polyamide implant 6mm long with a 300 μ m diameter that is inserted ab interno in the suprachoroidal space with a specially designed inserter. It is inserted through the main incision of cataract surgery following clear cornea phacoemulsification [112]. Lanchulev et al reported IOP reduction from 22.9 mmHg to 16.2 mmHg after 6 months in eyes that underwent phacoemulsification and Cypass insertion [113]. Craven et al reported that the most common adverse effects are: hyphaema, persistent inflammation, branch retinal vein occlusion and exacerbation of diabetic macular oedema [114].

16. Ciliary body endophotocoagulation (ECP)

Photocoagulation of the ciliary body processes is done by a 810 nm semiconductor diode laser. The endoscope carries the viewing system, the laser system and the light source. The procedure can be applied via a pars plana approach or from corneal incision. The treatment is applied over 360°. When it is delivered through a corneal incision it can follow phacoemulsification as the removal of the crystalline lens offers easier access to the ciliary processes. The probe is pushed forward between the intraocular lens implant and the iris

16.1. Outcomes

Phaco-ECP provides good control of the IOP in early/moderate glaucoma over time with no ECP related complications [115]. This study also suggests that phaco-ECP offers an additional hypotensive effect to phacoemulsification alone. Lima et al compared ECP with Ahmed GDD in the treatment of refractory glaucoma and found no differences in the success rate. Ahmed GDD had a higher complication rate than ECP [116].

17. Summary

Phaco-trabeculectomy remains the standard procedure for the management of coexisting cataract and glaucoma. Newer techniques have been developed in order to avoid entering the

eye and provide a more controlled reduction of the IOP. The use of antifibrotic agents have improved the survival of these procedures but also increased the incidence of complications. On the other hand the development of the newer antiglaucoma drops gave more options to the ophthalmologists for the medical management of glaucoma but have adversely affected the outcome of the antiglaucoma surgery.

The glaucoma drainage implants retain their place as a useful tool in many forms of severe glaucoma where the penetrating and non-penetrating procedures are likely to fail. The Ex-PRESS mini implant is a penetrating procedure but has a better safety profile and equal hypotensive effect to trabeculectomy.

Current research aims to the development of miniature devices that will facilitate the drainage of aqueous via the physiological pathways without leading to aqueous accumulation under the external coatings of the eye.

Author details

Vassilis Kozobolis, Aristeidis Konstantinidis* and Georgios Labiris

*Address all correspondence to: aristeidiskon@hotmail.com

Eye department, University Hospital of Alexandroupolis, Alexandroupolis, Greece

References

- [1] Foster, P. J, Buhrmann, R, Quigley, H. A, & Johnson, G. J. The definition and classification of glaucoma in prevalence surveys. *Br J Ophthalmol.* (2002). Feb;; 86(2), 238-42.
- [2] Quigley, H. A, & Broman, A. T. The number of people with glaucoma worldwide in 2010 and 2020. *Br J Ophthalmol.* (2006). Mar;; 90(3), 262-7.
- [3] Quigley, H. A. Number of people with glaucoma worldwide. *Br J Ophthalmol.* (1996). May;; 80(5), 389-93.
- [4] Davanger, M, Ringvold, A, & Blika, S. The probability of having glaucoma at different IOP levels. *Acta Ophthalmol (Copenh).* (1991). Oct;; 69(5), 565-8.
- [5] Boateng, W. Economics of surgery worldwide. Developing countries. *Glaucoma Saunders.* Philadelphia. , 1, 13.
- [6] Migdal, C, Gregory, W, & Hitchings, R. Long-term functional outcome after early surgery compared with laser and medicine in open-angle glaucoma. *Ophthalmology.* (1994). Oct;; 101(10), 1651-6.

- [7] Lichter, P. R, Musch, D. C, Gillespie, B. W, Guire, K. E, Janz, N. K, & Wren, P. A. Mills RP; CIGTS Study Group. Interim clinical outcomes in the Collaborative Initial Glaucoma Treatment Study comparing initial treatment randomized to medications or surgery. *Ophthalmology*. (2001). Nov;; 108(11), 1943-53.
- [8] Chen, T. C, Wilensky, J. T, & Viana, M. A. Long-term follow-up of initially successful trabeculectomy. *Ophthalmology*. (1997). Jul;; 104(7), 1120-5.
- [9] Nouri-mahdavi, K, Brigatti, L, Weitzman, M, & Caprioli, J. Outcomes of trabeculectomy for primary open-angle glaucoma. *Ophthalmology*. (1995). Dec;; 102(12), 1760-9.
- [10] Keenan, T. D, Wotton, C. J, & Goldacre, M. J. Recent trends in the rate of trabeculectomy in England. *Eye (Lond)*. (2011). Sep;25(9).
- [11] Whittaker, K. W, Gillow, J. T, & Cunliffe, I. A. Is the role of trabeculectomy in glaucoma management changing? *Eye (Lond)*. (2001). Aug;15(Pt 4):449-52.
- [12] Strutton, D. R, & Walt, J. G. Trends in glaucoma surgery before and after the introduction of new topical glaucoma pharmacotherapies. *J Glaucoma*. (2004). Jun;; 13(3), 221-6.
- [13] Rachmiel, R, Trope, G. E, Chipman, M. L, Gouws, P, & Buys, Y. M. Laser trabeculoplasty trends with the introduction of new medical treatments and selective laser trabeculoplasty. *J Glaucoma*. (2006). Aug;; 15(4), 306-9.
- [14] Knox, F. A, Barry, M, McGowan, B, & Brien, O. C. The rising cost of glaucoma drugs in Ireland 1996-2003. *Br J Ophthalmol*. (2006). Feb;; 90(2), 162-5.
- [15] Shingleton, B. J, Pasternack, J. J, Hung, J. W, Donoghue, O, & Three, M. W. and five year changes in intraocular pressures after clear corneal phacoemulsification in open angle glaucoma patients, glaucoma suspects, and normal patients. *J Glaucoma*. (2006). Dec;; 15(6), 494-8.
- [16] Cimetta, D. J, & Cimetta, A. C. Intraocular pressure changes after clear corneal phacoemulsification in nonglaucomatous pseudoexfoliation syndrome. *Eur J Ophthalmol*. (2008). Jan-Feb;; 18(1), 77-81.
- [17] Brig JKS PariharLt Col Jaya Kaushik, Surg Lt Cdr AS Parihar and Ashwini KS Parihar. Combined approach to co-existing glaucoma and cataract. In Pinakin Gunvant (ed). *Glaucoma-Current clinical and research aspects*. Rijeka: InTech; (2011). , 275.
- [18] Husain, R, Liang, S, Foster, P. J, Gazzard, G, Bunce, C, Chew, P. T, Oen, F. T, Khaw, P. T, Seah, S. K, & Aung, T. Cataract surgery after trabeculectomy: the effect on trabeculectomy function. *Arch Ophthalmol*. (2012). Feb;; 130(2), 165-70.
- [19] Liu, H. N, Li, X, Nie, Q. Z, & Chen, X. L. Efficacy and tolerability of one-site versus two-site phacotrabeculectomy: a meta-analysis. *Int J Ophthalmol*. (2010). , 3(3), 264-8.

- [20] Nassiri, N, Nassiri, N, Mohammadi, B, & Rahmani, . . Comparison of 2 surgical techniques in phacotrabeculectomy: 1 site versus 2 sites. *Eur J Ophthalmol*. 2010 Mar-Apr;20(2):316-26.
- [21] Gdih, G. A, Yuen, D, Yan, P, Sheng, L, Jin, Y. P, & Buys, Y. M. Meta-analysis of 1-versus 2-Site Phacotrabeculectomy. *Ophthalmology*. (2011). Jan,, 118(1), 71-6.
- [22] Wells, A. P, Cordeiro, M. F, Bunce, C, & Khaw, P. T. Cystic bleb formation and related complications in limbus- versus fornix-based conjunctival flaps in pediatric and young adult trabeculectomy with mitomycin C. *Ophthalmology*. (2003). Nov,, 110(11), 2192-7.
- [23] Tezel, G, Kolker, A. E, Kass, M. A, & Wax, M. B. Comparative results of combined procedures for glaucoma and cataract: II. Limbus-based versus fornix-based conjunctival flaps. *Ophthalmic Surg Lasers*. (1997). Jul,, 28(7), 551-7.
- [24] Kozobolis, V. P, Siganos, C. S, Christodoulakis, E. V, Lazarov, N. P, Koutentaki, M. G, & Pallikaris, I. G. Two-site phacotrabeculectomy with intraoperative mitomycin-C: fornix- versus limbus-based conjunctival opening in fellow eyes. *J Cataract Refract Surg*. (2002). Oct,, 28(10), 1758-62.
- [25] Solus, J. F, Jampel, H. D, Tracey, P. A, Gilbert, D. L, Loyd, T. L, Jefferys, J. L, & Quigley, H. A. Comparison of limbus-based and fornix-based trabeculectomy: success, bleb-related complications, and bleb morphology. *Ophthalmology*. (2012). Apr,, 119(4), 703-11.
- [26] The Advanced Glaucoma Intervention Study (AGIS): 11Risk factors for failure of trabeculectomy and argon laser trabeculoplasty. AGIS Investigators. *Am J Ophthalmol*. (2002). Oct,, 134(4), 481-98.
- [27] Scott, I. U, Greenfield, D. S, Schiffman, J, Nicolela, M. T, Rueda, J. C, Tsai, J. C, & Palmberg, P. F. Outcomes of primary trabeculectomy with the use of adjunctive mitomycin. *Arch Ophthalmol*. (1998). Mar,, 116(3), 286-91.
- [28] Stürmer, J, Broadway, D. C, & Hitchings, R. A. Young patient trabeculectomy. Assessment of risk factors for failure. *Ophthalmology*. (1993). Jun,, 100(6), 928-39.
- [29] Broadway, D, & Grierson, I. Hitchings R Racial differences in the results of glaucoma filtration surgery: are racial differences in the conjunctival cell profile important? *Br J Ophthalmol*. (1994). Jun,, 78(6), 466-75.
- [30] Jacobi, P. C, Dietlein, T. S, & Krieglstein, G. K. Primary trabeculectomy in young adults: long-term clinical results and factors influencing the outcome. *Ophthalmic Surg Lasers*. (1999). Sep-Oct,, 30(8), 637-46.
- [31] Flach, A. J. Does medical treatment influence the success of trabeculectomy? *Trans Am Ophthalmol Soc*. (2004). discussion 223-4, 102, 219-23.

- [32] Lavin, M. J, Wormald, R. P, Migdal, C. S, & Hitchings, R. A. The influence of prior therapy on the success of trabeculectomy. *Arch Ophthalmol.* (1990). Nov; , 108(11), 1543-8.
- [33] Broadway, D. C, Grierson, I, & Hitchings, R. A. Local effects of previous conjunctival incisional surgery and the subsequent outcome of filtration surgery. *Am J Ophthalmol.* (1998). Jun; , 125(6), 805-18.
- [34] Olali, C, Rotchford, A. P, & King, A. J. Outcome of repeat trabeculectomies. *Clin Experiment Ophthalmol.* (2011). Sep-Oct; , 39(7), 658-64.
- [35] Cankaya, A. B, & Elgin, U. Comparison of the outcome of repeat trabeculectomy with adjunctive mitomycin C and initial trabeculectomy. *Korean J Ophthalmol.* (2011). Dec; , 25(6), 401-8.
- [36] Mietz, H, Raschka, B, & Krieglstein, G. K. Risk factors for failures of trabeculectomies performed without antimetabolites. *Br J Ophthalmol.* (1999). Jul; , 83(7), 814-21.
- [37] Hugkulstone, C. E, Smith, L. F, & Vernon, S. A. Trabeculectomy in diabetic patients with glaucoma. *Eye* (1993). , 7, 502-506.
- [38] Joshi, A. B, Parrish, R. K, & Feuer, W. F. (2002). survey of the American glaucoma society: Practice preferences for glaucoma surgery and antifibrotic use. *J Glaucoma* 2005; , 14, 172-174.
- [39] Lin, Z. J, Li, Y, Cheng, J. W, & Lu, X. H. Intraoperative mitomycin C versus intraoperative 5-fluorouracil for trabeculectomy: a systematic review and meta-analysis. *J Ocul Pharmacol Ther.* (2012). Apr; , 28(2), 166-73.
- [40] Wilkins, M, Indar, A, & Wormald, R. Intra-operative mitomycin C for glaucoma surgery. *Cochrane Database Syst Rev.* (2005). Oct 19; (4):CD002897.
- [41] Five year follow-up of the fluorouracil filtering surgery studyThe fluorouracil filtering surgery study group. *Am J Ophthalmol* (1996). , 121, 349-366.
- [42] The Fluorouracil Filtering Surgery Group: fluorouracil filtering surgery study one year follow upAm J Ophthalmol (2001). , 12, 143-148.
- [43] Beckers, H. J, Kinders, K. C, & Webers, C. A. Five-year results of trabeculectomy with mitomycin C. *Graefes Arch Clin Exp Ophthalmol.* (2003). Feb; , 241(2), 106-10.
- [44] Zacharia, P. T, Deppermann, S. R, & Schuman, J. S. Ocular hypotony after trabeculectomy with mitomycin C. *Am J Ophthalmol.* (1993). Sep 15; , 116(3), 314-26.
- [45] Higginbotham, E. J, Stevens, R. K, Musch, D. C, Karp, K. O, Lichter, P. R, Bergstrom, T. J, & Skuta, G. L. Bleb-related endophthalmitis after trabeculectomy with mitomycin C. *Ophthalmology.* (1996). Apr; , 103(4), 650-6.

- [46] Araujo, S. V, Spaeth, G. L, Roth, S. M, & Starita, R. J. A ten-year follow-up on a prospective, randomized trial of postoperative corticosteroids after trabeculectomy. *Ophthalmology*. (1995). Dec;, 102(12), 1753-9.
- [47] Lavin, M. J, Wormald, R. P, Migdal, C. S, & Hitchings, R. A. The influence of prior therapy on the success of trabeculectomy. *Arch Ophthalmol*. (1990). Nov;, 108(11), 1543-8.
- [48] Broadway, D. C, Grierson, I, Brien, O, & Hitchings, C. RA. Adverse effects of topical antiglaucoma medication. II. The outcome of filtration surgery. *Arch Ophthalmol*. (1994). Nov;, 112(11), 1446-54.
- [49] Breusegem, C, Spielberg, L, Van Ginderdeuren, R, Vandewalle, E, & Renier, C. Van de Veire S, Fieuws S, Zeyen T, Stalmans I. Preoperative non steroidal anti-inflammatory drug or steroid and outcomes after trabeculectomy: a randomized controlled trial. *Ophthalmology*. (2010). Jul;, 117(7), 1324-30.
- [50] Tham, C. C, Li, F. C, Leung, D. Y, Kwong, Y. Y, Yick, D. W, Chi, C. C, & Lam, D. S. Intraleak triamcinolone acetonide injection after bleb-forming filtration surgery (trabeculectomy, phacotrabeculectomy, and trabeculectomy revision by needling): a pilot study. *Eye (Lond)*. (2006). Dec;, 20(12), 1484-6.
- [51] Kahook, M. Y, Camejo, L, & Noecker, R. J. Trabeculectomy with intraoperative retrobulbar triamcinolone acetonide. *Clin Ophthalmol*. (2009). , 3, 29-31.
- [52] Yuki, K, Shiba, D, Kimura, I, Ohtake, Y, & Tsubota, K. Trabeculectomy with or without intraoperative sub-tenon injection of triamcinolone acetonide in treating secondary glaucoma. *Am J Ophthalmol*. (2009). Jun;, 147(6), 1055-60.
- [53] Nilforushan, N, Yadgari, M, Kish, S. K, & Nassiri, N. Subconjunctival bevacizumab versus mitomycin C adjunctive to trabeculectomy. *Am J Ophthalmol*. (2012). Feb;, 153(2), 352-357.
- [54] Sedghipour, M. R, Mostafaei, A, & Taghavi, Y. Low-dose subconjunctival bevacizumab to augment trabeculectomy for glaucoma. *Clin Ophthalmol*. (2011). , 5, 797-800.
- [55] Friedman, D. S, Jampel, H. D, Lubomski, L. H, Kempen, J. H, Quigley, H, Congdon, N, Levkovitch-verbin, H, Robinson, K. A, & Bass, E. B. Surgical strategies for coexisting glaucoma and cataract: an evidence-based update. *Ophthalmology*. (2002). Oct;, 109(10), 1902-13.
- [56] Tripathi, R. C, Tripathi, B. J, Park, J. K, Quaranta, L, Steinsapir, K, Lehman, E, & Ernest, J. T. Intracameral tissue plasminogen activator for resolution of fibrin clots after glaucoma filtering procedures. *Am J Ophthalmol*. (1991). Feb 15;, 111(2), 247-8.
- [57] Seah, S. K. Prata JA Jr, Minckler DS, Baerveldt G, Lee PP, Heuer DK. Hypotony following trabeculectomy. *J Glaucoma*. (1995). Apr;, 4(2), 73-9.

- [58] Bindlish, R, Condon, G. P, Schlosser, J. D, Antonio, D, Lauer, J, Lehrer, K. B, & Efficacy, R. and safety of mitomycin-C in primary trabeculectomy: five-year follow-up. *Ophthalmology*. (2002). Jul;discussion 1341-2., 109(7), 1336-41.
- [59] Costa, V. P, & Arcieri, E. S. Hypotony maculopathy [review]. *Acta Ophthalmol Scand* (2007). , 85, 586-597.
- [60] Mietz, H. The toxicology of mitomycin C on the ciliary body. *Curr Opin Ophthalmol*. (1996). Apr;; 7(2), 72-9.
- [61] Nuyts, R. M, Greve, E. L, Geijssen, H. C, & Langerhorst, C. T. Treatment of hypotony maculopathy after trabeculectomy with mitomycin C. *Am J Ophthalmol*. (1994). Sep 15;; 118(3), 322-31.
- [62] Lüke, C, Dietlein, T. S, Jacobi, P. C, Konen, W, & Krieglstein, G. K. *Ophthalmology*. Risk profile of deep sclerectomy for treatment of refractory congenital glaucomas. (2002). Jun; , 109(6), 1066-71.
- [63] Nouredin, B. N, Haibi, C. P, Cheikha, A, & Bashshur, Z. F. Viscocanalostomy versus trabeculectomy ab externo in primary congenital glaucoma: 1-year follow-up of a prospective controlled pilot study. *Br J Ophthalmol*. (2006). Oct;; 90(10), 1281-5.
- [64] Kay, J. S, Mitchell, R, & Miller, J. Dilation and Probing of Schlemm's Canal and Viscocanalostomy in Pediatric Glaucoma. *J Pediatr Ophthalmol Strabismus*. (2011). Jan-Feb;doi:, 48(1), 30-7.
- [65] Yarangümeli, A, Köz, O. G, Alp, M. N, Elhan, A. H, & Kural, G. Viscocanalostomy with mitomycin-C: a preliminary study. *Eur J Ophthalmol*. (2005). Mar-Apr;; 15(2), 202-8.
- [66] Anand, N, & Atherley, C. Deep sclerectomy augmented with mitomycin C. *Eye (Lond)*. (2005). Apr;; 19(4), 442-50.
- [67] Lüke, C, Dietlein, T. S, Jacobi, P. C, Konen, W, & Krieglstein, G. K. A prospective randomised trial of viscocanalostomy with and without implantation of a reticulated hyaluronic acid implant (SKGEL) in open angle glaucoma. *Br J Ophthalmol*. (2003). May;; 87(5), 599-603.
- [68] Gimbel, H. V, Penno, E. E, & Ferensowicz, M. Combined cataract surgery, intraocular lens implantation, and viscocanalostomy. *J Cataract Refract Surg*. (1999). Oct;; 25(10), 1370-5.
- [69] Eliseo, D, Pastena, D, Longanesi, B, Grisanti, L, & Negrini, F. V. Comparison of deep sclerectomy with implant and combined glaucoma surgery. *Ophthalmologica*. (2003). May-Jun;; 217(3), 208-11.
- [70] Cillino, S. Di Pace F, Casuccio A, Calvaruso L, Morreale D, Vadalà M, Lodato G. Deep sclerectomy versus punch trabeculectomy with or without phacoemulsification: a randomized clinical trial. *J Glaucoma*. (2004). Dec;; 13(6), 500-6.

- [71] Funnell, C. L, Clowes, M, & Anand, N. Combined cataract and glaucoma surgery with mitomycin C: phacoemulsification-trabeculectomy compared to phacoemulsification-deep sclerectomy. *Br J Ophthalmol.* (2005). Jun;, 89(6), 694-8.
- [72] Wishart, M. S, Shergill, T, & Porooshani, H. Viscocanalostomy and phacoviscocanalostomy: long-term results. *J Cataract Refract Surg.* (2002). May;, 28(5), 745-51.
- [73] Tanito, M, Park, M, Nishikawa, M, Ohira, A, & Chihara, E. Comparison of surgical outcomes of combined viscocanalostomy and cataract surgery with combined trabeculectomy and cataract surgery. *Am J Ophthalmol.* (2002). Oct;, 134(4), 513-20.
- [74] Kobayashi, H, & Kobayashi, K. Randomized comparison of the intraocular pressure-lowering effect of phacoviscocanalostomy and phacotrabeculectomy. *Ophthalmology.* (2007). May;, 114(5), 909-14.
- [75] Kozobolis, V. P, Christodoulakis, E. V, Siganos, C. S, & Pallikaris, I. G. Hemorrhagic Descemet's membrane detachment as a complication of deep sclerectomy: a case report. *J Glaucoma.* (2001). Dec;, 10(6), 497-500.
- [76] Kozobolis, V. P, Kalogianni, E, Katsanos, A, Dardabounis, D, Koukoula, S, & Labiris, G. Ocular decompression retinopathy after deep sclerectomy with mitomycin C in an eye with exfoliation glaucoma. *Eur J Ophthalmol.* (2011). May-Jun;, 21(3), 324-7.
- [77] Alwitry, A, Khan, K, Rotchford, A, Zaman, A. G, & Vernon, S. A. Severe decompression retinopathy after medical treatment of acute primary angle closure. *Br J Ophthalmol.* (2007). Jan;91(1):121
- [78] Landers, J, & Craig, J. Decompression retinopathy and corneal oedema following Nd:YAG laser peripheral iridotomy. *Clin. Experiment Ophthalmol.* (2006). Mar;, 34(2), 182-4.
- [79] Molteno, A. C, Bevin, T. H, Herbison, P, & Houliston, M. J. Otago glaucoma surgery outcome study: long-term follow-up of cases of primary glaucoma with additional risk factors drained by Molteno implants. *Ophthalmology.* (2001). Dec;, 108(12), 2193-200.
- [80] Britt, M. T. LaBree LD, Lloyd MA, Minckler DS, Heuer DK, Baerveldt G, Varma R. Randomized clinical trial of the 350-mm² versus the 500-mm² Baerveldt implant: longer term results: is bigger better? *Ophthalmology.* (1999). Dec;, 106(12), 2312-8.
- [81] Ishida, K, Netland, P. A, Costa, V. P, Shiroma, L, Khan, B, & Ahmed, I. I. Comparison of polypropylene and silicone Ahmed Glaucoma Valves. *Ophthalmology.* (2006). Aug;, 113(8), 1320-6.
- [82] Brasil, M. V, Rockwood, E. J, & Smith, S. D. Comparison of silicone and polypropylene Ahmed Glaucoma Valve implants. *J Glaucoma.* (2007). Jan;, 16(1), 36-41.
- [83] Bai, Y. J, Li, Y. Q, Chai, F, Yang, X. J, Zhang, Y. C, Wei, Y. T, Huang, J. J, Ge, J, & Zhuo, Y. H. Comparison of FP-7 and S-2 Ahmed glaucoma valve implantation in re-

- fractory glaucoma patients for short-term follow-up. *Chin Med J (Engl)*. (2011). Apr;; 124(8), 1128-33.
- [84] Khan, A. O, & Al-mobarak, F. Comparison of polypropylene and silicone Ahmed valve survival 2 years following implantation in the first 2 years of life. *Br J Ophthalmol*. (2009). Jun;; 93(6), 791-4.
- [85] Hinkle, D. M, Zurakowski, D, & Ayyala, R. S. A comparison of the polypropylene plate Ahmed glaucoma valve to the silicone plate Ahmed glaucoma flexible valve. *Eur J Ophthalmol*. (2007). Sep-Oct;; 17(5), 696-701.
- [86] Mahdy, R. A. Adjunctive use of bevacizumab versus mitomycin C with Ahmed valve implantation in treatment of pediatric glaucoma. *J Glaucoma*. (2011). Sep;; 20(7), 458-63.
- [87] Alvarado, J. A, Hollander, D. A, Juster, R. P, & Lee, L. C. Ahmed valve implantation with adjunctive mitomycin C and 5-fluorouracil: long-term outcomes. *Am J Ophthalmol*. (2008). Aug;; 146(2), 276-284.
- [88] Costa, V. P, Azuara-blanco, A, Netland, P. A, Lesk, M. R, & Arcieri, E. S. Efficacy and safety of adjunctive mitomycin C during Ahmed Glaucoma Valve implantation: a prospective randomized clinical trial. *Ophthalmology*. (2004). Jun;; 111(6), 1071-6.
- [89] Kurnaz, E, Kubaloglu, A, Yilmaz, Y, Koytak, A, & Ozertürk, Y. The effect of adjunctive Mitomycin C in Ahmed glaucoma valve implantation. *Eur J Ophthalmol*. (2005). Jan-Feb;; 15(1), 27-31.
- [90] Perkins, T. W, Gangnon, R, Ladd, W, Kaufman, P. L, & Libby, C. M. Molteno implant with mitomycin C: intermediate-term results. *J Glaucoma*. (1998). Apr;; 7(2), 86-92.
- [91] Cantor, L, Burgoyne, J, Sanders, S, Bhavnani, V, Hoop, J, & Brizendine, E. The effect of mitomycin C on Molteno implant surgery: a 1-year randomized, masked, prospective study. *J Glaucoma*. (1998). Aug;; 7(4), 240-6.
- [92] Costa, V. P. Surgical management. Combined cataract extraction and glaucoma drainage implant surgery. *Glaucoma Saunders*. (2009). , 2, 367.
- [93] Seibold, L. K, Rorrer, R. A, & Kahook, M. Y. MRI of the Ex-PRESS stainless steel glaucoma drainage device. *Br J Ophthalmol*. (2011). Feb;; 95(2), 251-4.
- [94] Geffen, N, Trope, G. E, Alasbali, T, Salonen, D, Crowley, A. P, & Buys, Y. M. Is the Ex-PRESS glaucoma shunt magnetic resonance imaging safe? *J Glaucoma*. (2010). Feb;; 19(2), 116-8.
- [95] De Feo, F, Roccatagliata, L, Bonzano, L, Castelletti, L, Mancardi, G, & Traverso, C. E. Magnetic resonance imaging in patients implanted with Ex-PRESS stainless steel glaucoma drainage micro device. *Am J Ophthalmol*. (2009). May;; 147(5), 907-11.

- [96] Bagnis, A, Papadia, M, Scotto, R, & Traverso, C. E. Obstruction of the Ex-PRESS miniature glaucoma device: Nd: YAG laser as a therapeutic option. *J Glaucoma*. (2011). Apr-May;20(4):271
- [97] Dahan, E. Ben Simon GJ, Lafuma. A Comparison of trabeculectomy and Ex-PRESS Implantation in fellow eyes of the same patient: a prospective, randomised study. *Eye (Lond)*. (2012). Feb 17.
- [98] Marzette, L, & Herndon, L. W. Comparison of the Ex-PRESS™ mini glaucoma shunt with standard trabeculectomy in the surgical treatment of glaucoma. *Ophthalmic Surg Lasers Imaging*. (2011). Nov-Dec; 42(6), 453-9.
- [99] De Jong, L, Lafuma, A, Aguadé, A. S, & Berdeaux, G. Five-year extension of a clinical trial comparing the EX-PRESS glaucoma filtration device and trabeculectomy in primary open-angle glaucoma. *Clin Ophthalmol*. (2011). , 5, 527-33.
- [100] Good, T. J, & Kahook, M. Y. Assessment of bleb morphologic features and postoperative outcomes after Ex-PRESS drainage device implantation versus trabeculectomy. *Am J Ophthalmol*. (2011). Mar; 151(3), 507-13.
- [101] De Jong, L. A. The Ex-PRESS glaucoma shunt versus trabeculectomy in open-angle glaucoma: a prospective randomized Study. *Adv Ther*. (2009). Mar; 26(3), 336-45.
- [102] Maris PJ JrIshida K, Netland PA. Comparison of trabeculectomy with Ex-PRESS miniature glaucoma device implanted under scleral flap.*J Glaucoma*. (2007). Jan; 16(1), 14-9.
- [103] Kanner, E. M, & Netland, P. A. Sarkisian SR Jr, Du H. Ex-PRESS miniature glaucoma device implanted under a scleral flap alone or combined with phacoemulsification cataract surgery..*J Glaucoma* (2009). Aug; 18(6), 488-91.
- [104] Lewis, R. A, Von Wolff, K, Tetz, M, Koerber, N, Kearney, J. R, Shingleton, B. J, & Samuelson, T. W. Canaloplasty: Three-year results of circumferential viscodilation and tensioning of Schlemm canal using a microcatheter to treat open-angle glaucoma. *J Cataract Refract Surg*. (2011). Apr; 37(4), 682-90.
- [105] Bull, H, Von Wolff, K, Körber, N, & Tetz, M. Three-year canaloplasty outcomes for the treatment of open-angle glaucoma: European study results. *Graefes Arch Clin Exp Ophthalmol*. (2011). Oct; 249(10), 1537-45.
- [106] Ayyala, R. S, Chaudhry, A. L, Okogbaa, C. B, & Zurakowski, D. Comparison of surgical outcomes between canaloplasty and trabeculectomy at 12 months' follow-up. *Ophthalmology*. (2011). Dec; 118(12), 2427-33.
- [107] Melamed, S. Ben Simon GJ, Goldenfeld M, Simon G. Efficacy and safety of gold micro shunt implantation to the supraciliary space in patients with glaucoma: a pilot study. *Arch Ophthalmol*. (2009). Mar; 127(3), 264-9.

- [108] Figus, M, Lazzeri, S, Fogagnolo, P, Iester, M, Martinelli, P, & Nardi, . . Supraciliary shunt in refractory glaucoma. *Br J Ophthalmol.* 2011 Nov;95(11):1537-41
- [109] Samuelson, T. W, Katz, L. J, Wells, J. M, Duh, Y. J, & Giamporcaro, J. E. US iStent Study Group. Randomized evaluation of the trabecular micro-bypass stent with phacoemulsification in patients with glaucoma and cataract. *Ophthalmology.* (2011). Mar;; 118(3), 459-67.
- [110] Craven, E. R, Katz, L. J, & Wells, J. M. Giamporcaro JE; iStent Study Group. Cataract surgery with trabecular micro-bypass stent implantation in patients with mild-to-moderate open-angle glaucoma and cataract: Two-year follow-up. *J Cataract Refract Surg.* (2012). Aug;; 38(8), 1339-45.
- [111] Ting, J. L, & Damji, K. F. Stiles MC; Trabectome Study Group. Ab interno trabeculectomy: outcomes in exfoliation versus primary open-angle glaucoma. *J Cataract Refract Surg.* (2012). Feb;; 38(2), 315-23.
- [112] Dietlein, T. S, Jordan, J. F, Schild, A, Konen, W, Jünemann, A, Lüke, C, & Krieglstein, G. K. Combined cataract-glaucoma surgery using the intracanalicular Eyepass glaucoma implant: first clinical results of a prospective pilot study. *J Cataract Refract Surg.* (2008). Feb;; 34(2), 247-52.
- [113] Parul Ichhpujani and Marlene RMoster. Novel Glaucoma Surgical Devices. In: Shimon Rumelt (ed). *Glaucoma- Basic and clinical concepts.* Rijeka: InTech; (2011). , 438.
- [114] Lanchulev, S, Ahmed, I, Hoeh, H, et al. Minimally invasive suprachoroidal device (Cypass) in open glaucoma. *AAO* (2010). poster.
- [115] Craven, E. R. Khatana A Hoeh H et al. Minimally invasive ab interno suprachoroidal micro-stent for the IOP reduction in combination with phaco cataract surgery. *AAO* (2011). poster
- [116] Lindfield, D, Ritchie, R. W, & Griffiths, M. F. Phaco-ECP': combined endoscopic cyclophotocoagulation and cataract surgery to augment medical control of glaucoma. *BMJ Open.* (2012). May 30;2(3). pii: e000578. doi:bmjopen-Print 2012., 2011-000578.
- [117] Lima, F. E, Magacho, L, & Carvalho, D. M. Susanna R Jr, Avila MP. A prospective, comparative study between endoscopic cyclophotocoagulation and the Ahmed drainage implant in refractory glaucoma. *J Glaucoma.* (2004). Jun;; 13(3), 233-7.