

We are IntechOpen, the world's leading publisher of Open Access books Built by scientists, for scientists

6,900

Open access books available

185,000

International authors and editors

200M

Downloads

Our authors are among the

154

Countries delivered to

TOP 1%

most cited scientists

12.2%

Contributors from top 500 universities



WEB OF SCIENCE™

Selection of our books indexed in the Book Citation Index
in Web of Science™ Core Collection (BKCI)

Interested in publishing with us?
Contact book.department@intechopen.com

Numbers displayed above are based on latest data collected.
For more information visit www.intechopen.com



Minimally Invasive Glaucoma Surgery – Strategies for Success

Daljit Singh

Additional information is available at the end of the chapter

<http://dx.doi.org/10.5772/54421>

1. Introduction

The aim of glaucoma surgery is to drain the internal reservoir of aqueous in such a manner that the inside head pressure remains within normal limits. The conventional and alternative pathways have been well known for decades - the anterior route that goes through the canal of Schlemm and the posterior route which is called “uveo-scleral outflow”. While the former route has been studied and discussed thoroughly for over a century, the latter mechanism has been discovered only recently and is talked about more as a functional rather than an anatomical entity. When the natural drainage mechanisms get stressed for any reason, the intra ocular pressure rises proportionately. The dearth of knowledge about the involvement of an extensive lymphatic channel system in aqueous drainage, has unwittingly encouraged the surgeons to perform dissections on the sclera with a rather large footprint. Bipolar cautery is used with impunity for the same reason. We shall now discuss the lymphatic channel system.

2. Lymphatics

Without a shadow of doubt, it has been proved that the conjunctival lymphatics do exist [1,12,17,22,23,24]. Every glaucoma surgeon should verify it with his own eyes. Under high magnification of a slit lamp microscope, the lymphatics are visible at the limbus, especially if there is some pigment. Pigment highlights the lymphatics. They stand out in cases of subconjunctival haemorrhage as a result of trauma, accidental or surgical. The blood is drained through the lymphatics. The network of lymphatics can be charted by injecting tyrpan blue at the limbus. Injection of the dye in the sclera demonstrates scleral channels as well as their

continuity with the sub-conjunctival lymphatics. Yeni et al [28] have demonstrated the presence of lymphatics in the ciliary body. It becomes obvious that uveoscleral outflow is actually a channel based aqueous pathway. No lymphatics can be demonstrated in the areas of subconjunctival scarring. All glaucoma surgeons need to be aware of the lymphatics.

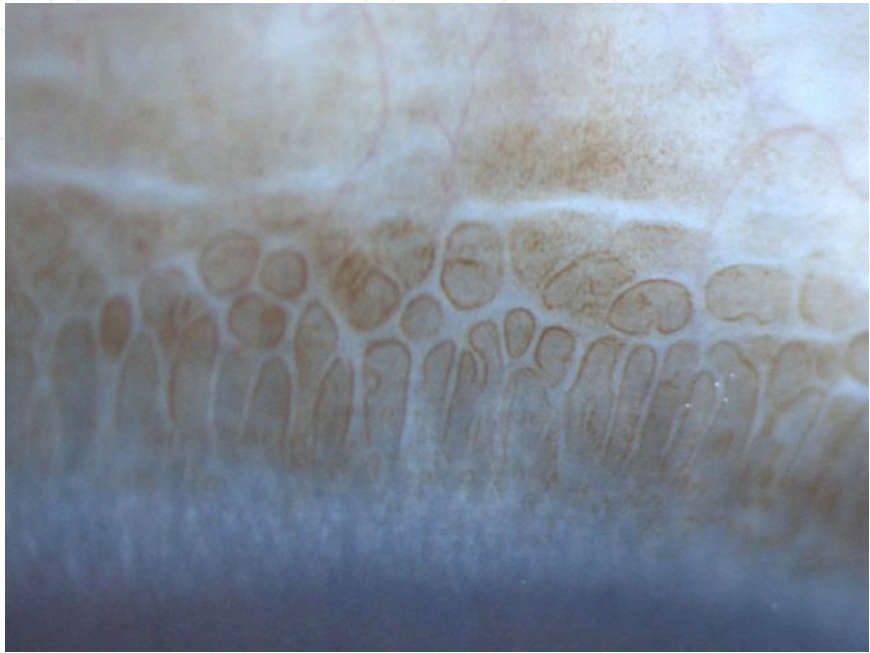


Figure 1. Limbal lymphatics.They enter the cornea singly, but anastomose proximally and join the conjunctival lymphatic network.The presence of pigment at the limbus makes the lymphatics prominent.

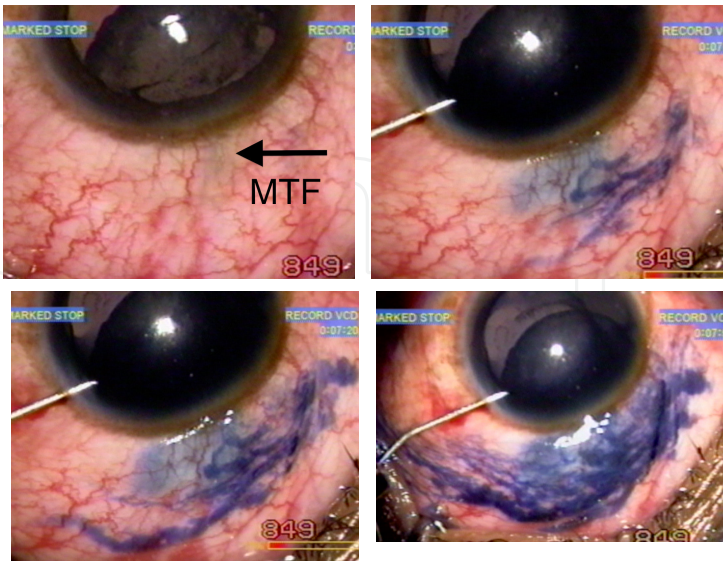


Figure 2. Microtrack filtration was done one day earlier to control glaucoma after blunt injury.Before removing dislocated lens, trypan blue was injected to chart lymphatics of conjunctva.

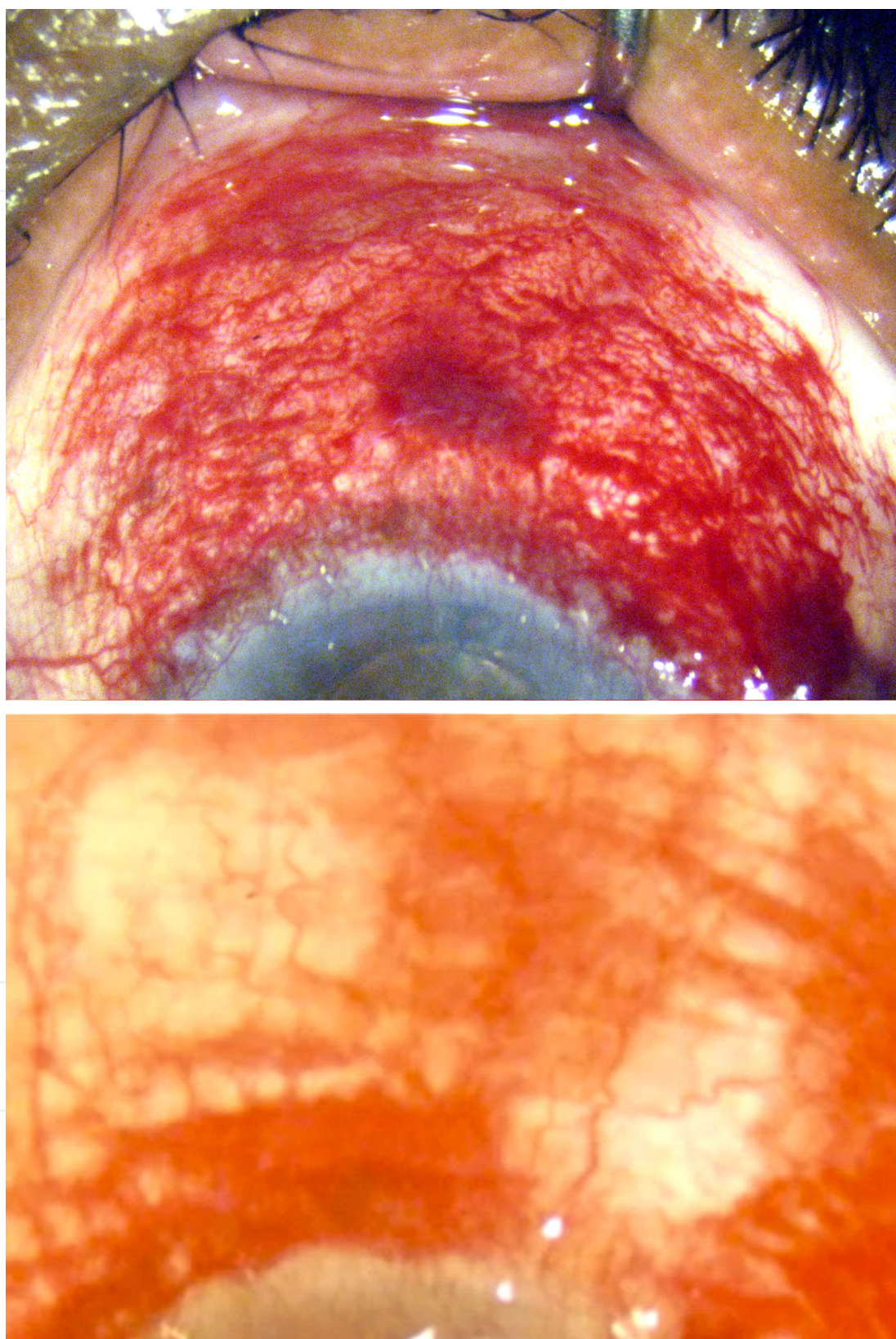


Figure 3. Entry of blood in the lymphatics after an unintended surgical trauma to the conjunctiva. Two hours later, most of the blood had migrated in to the conjunctival lymphatics.

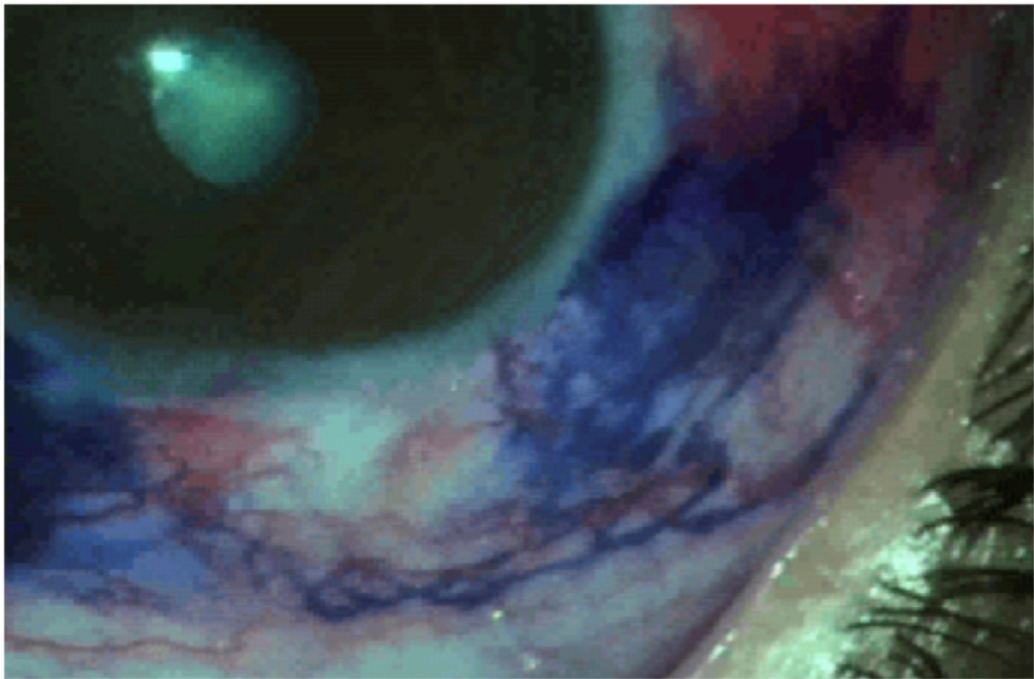


Figure 4. A failed case of trabeculectomy. Dye injection fails to show lymphatics in the totally scarred central area. The seen lymphatics are thin and have a disturbed pattern.

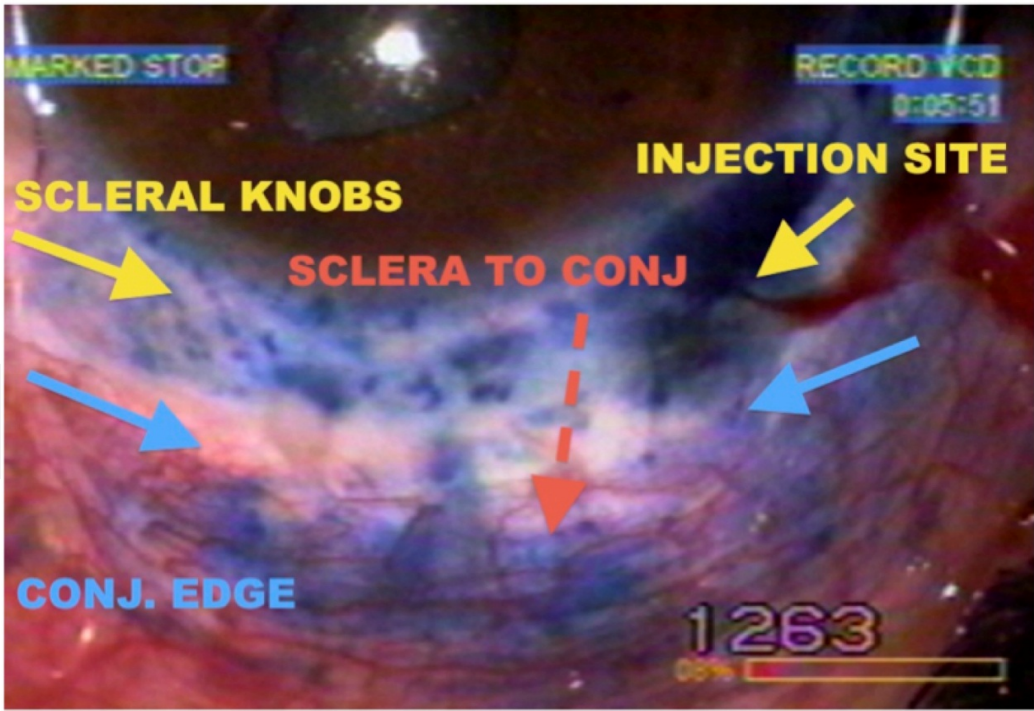


Figure 5. It demonstrates the intrascleral movement of injected trypan blue along the limbus where it ends in knobs. The proximal movement of the dye through the sclera enters the subconjunctival lymphatics, proving that conjunctival and scleral channels are one system.

Anatomy is the basis of physiology. The lymphatics drain the extracellular fluid, one that comes out of the arterial ends of the capillaries, the leakage from the aqueous veins and the uveoscleral outflow. The drainage occurs all around the limbus. When a filtration surgery is performed, there is a huge local outflow, which can be handled only by the flood drain like function of the lymphatics. Their sizes and capabilities match the changing needs after filtration surgery.

The techniques of glaucoma surgery are limited by the tools that are employed to achieve them. For the last one century, the tools are basically the same - forceps, scissors, knife and cautery. Only they are now finer and sharper. Excellent magnification and coaxial light are recent helps for the surgeon. Tissues are cut and dissected in layers, which are sutured back, after making a large opening in to the anterior chamber. Tissue reaction and scarring is a serious concern to manage/prevent which anti-mitotics are used during and often post-surgery.

The arrival of a radically new surgical tool, Fugo blade, providing plasma energy on the tip of a filament has remained largely un-noticed or un-understood outside the United States and even less actually used.

2.1. What is Fugo blade ?

Fugo blade [3,4,8,9,13,14,15,16,17,26,27] produces “laser like plasma” on the operating blunt metal tip. It works on 4 rechargeable battery cells. Numerous glaucoma operations can be done after one charge. Cut power and intensity can be adjusted from the console. How does it function ? It focusses electromagnetic energy to the operating tip. The energy is pre-tuned to the tissues and is transferred by resonance. The moment the activated tip touches the tissues, the energy gets transferred to the tissue molecules, which go to higher energy levels, become unstable and explode, just as happens with excimer laser when it acts on the cornea. A plume with aromatic smell is produced. The molecules/tissues split in the path of incision/ablation. The incisions are bloodless, since the small blood vessels are also removed from the path of incision. It is possible to ablate surfaces and create channels/tracks in simple and efficient manner.

The width of the cutting plasma coating on the operating tip can be varied from “power” adjustment- 25, 50 or 75 microns. The intensity can be varied from 1 to 10 from the second knob.

Fugo blade application in glaucoma surgery raises a dilemma. You cannot make the traditional surgery any better with it. So why use it? That it opens newer ways to do glaucoma surgery is not yet attractive, because the new techniques have not yet been approved and advocated by the stalwarts in the field. That in stead of dissecting in layers, you can tap the aqueous chambers through direct track formation seems frightening, since it breaks the five decades old taboo by not making a “guarding scleral flap”. The scleral flap in trabeculectomy might help prevent over-filtration, but the prevention of infection always rests upon healthy conjunctiva.



Figure 6. Fugo blade console, hand piece and the disposable operating tip. One connection goes to the hand-piece and the other to the foot-switch. The left knob is for cut power and the right for intensity. Manufacturer: Medisurg Ltd. c/o Richard J. Fugo. 100 West Farnance St. The Fugo Building. Norristown, Pa 19401. USA




Figure 7. High magnification photograph of activated Fugo blade tip showing yellow plasma coating (cutting) around the metal filament and the orange photonic cloud (non cutting).

In short, lack of awareness about the lymphatic network that drains the aqueous normally and that works like flood drains after filtration surgery, and the failure to appreciate new possibilities of glaucoma surgery that are opened up with Fugo plasma blade, keeps the modern glaucoma surgery where it is - essentially a standstill.

2.2. Minimally invasive glaucoma surgery

Trabeculectomy or its modification remains the operation of choice for most surgeons. Non perforating filtration under a scleral flap and glaucoma valve are other choices. Every operation makes a fairly large foot print on the sclera and inevitably destroys the lymphatics in the surgical field. This happens because the surgery involves making flaps of the tissues. A “guarded flap” is a necessity for making a rather large trabeculectomy opening at the limbus.

2.3. Transciliary Filtration (TCF)

Fugo blade allows the making of a filtration track (TCF) in to the posterior chamber. There is no other tool that has this capability. The filtration track goes through the sclera and the ciliary body to reach the posterior chamber [2,5,6,7,10,17,19,21,23]. TCF may be done after making a fornix or limbus based conjunctival flap, which involves some/considerable trauma. Transconjunctival (TC) TCF minimizes surgical trauma. TCF prevents anterior chamber problems like a shallow or flat anterior chamber and hyphaema. No iridectomy is done in this operation.

In all the operations described below, subconjunctival anaesthesia is given.

The steps of TCTCF are as follows:

1. The posterior edge of the surgical limbus is visible through the conjunctiva. It lies over the the anterior corneo-scleral trabeculae. A point is chosen 1.5 mm posterior to it. This point is pressed with the blunt tip of a forceps to leave a mark on the sclera.
2. A 300 micron or 500 micron Fugo blade tip is chosen to be used at high power and intensity. The conjunctiva is pushed towards the limbus with a blunt sapphire knife till it reaches the marked point on the sclera.
3. The activated Fugo blade is passed through the conjunctiva, the sclera and the ciliary body to reach the posterior chamber. The track may be made in one step or a series of small steps progressively taking the track to the posterior chamber. The end point shows as aqueous drainage. Nothing further needs to be done.
4. 0.1 ml to 0.2 ml of Mitomycin C (MMC) 0.01 % or 0.02 % is deposited under the conjunctiva. The conjunctival opening is sutured.

An anteriorly misdirected track can open in to the anterior chamber and posterior misdirection can lead to the vitreous show/prolapse.

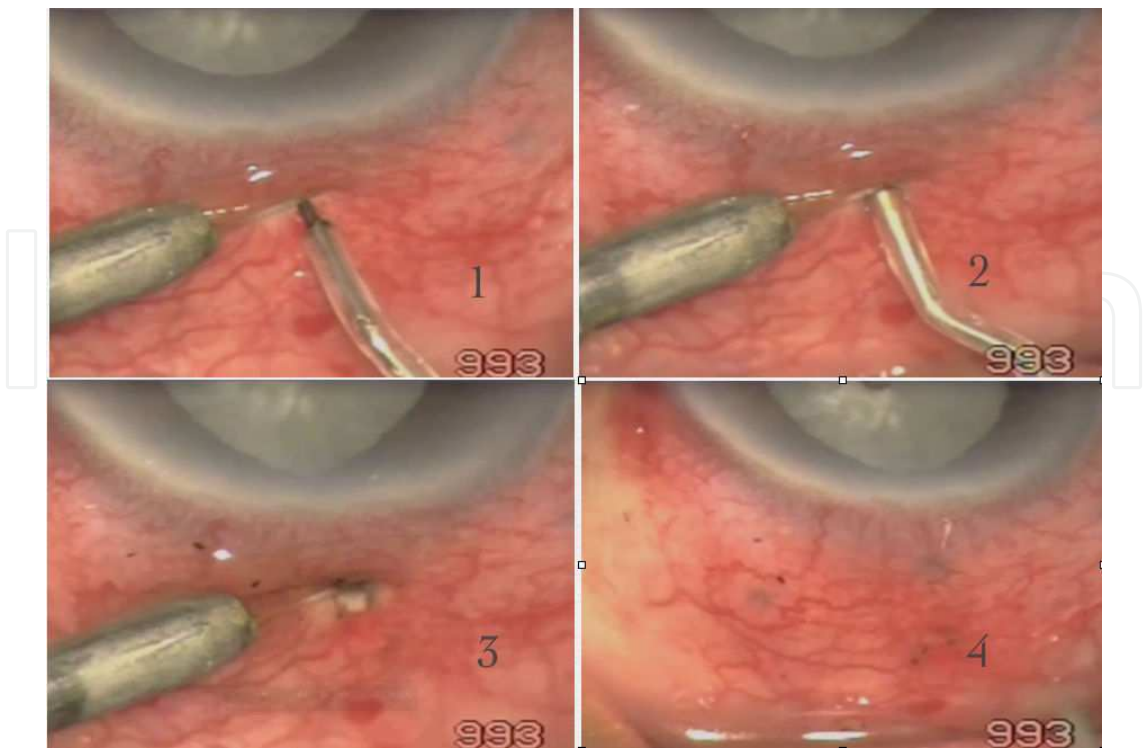


Figure 8. in a case of phakomorphic glaucoma.The conjunctiva is pushed towards the limbus up to a pre-determined point.Fugo blade tip passes through the conjunctiva, the sclera and the ciliary body to drain the posterior chamber.

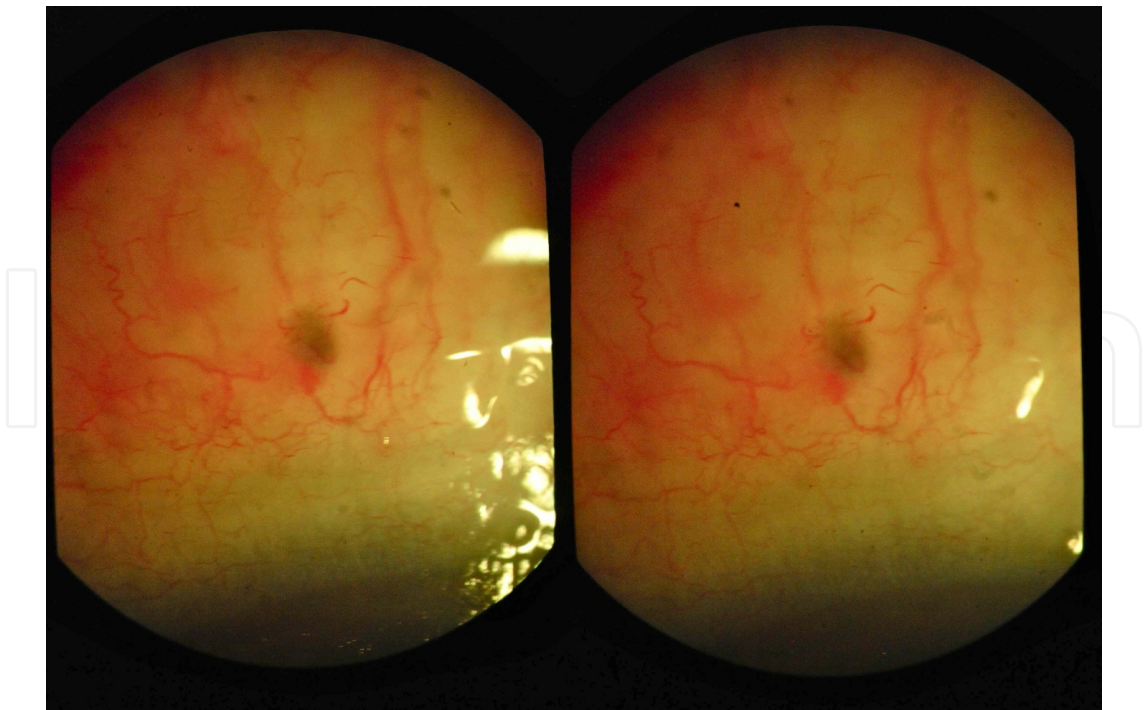


Figure 9. TCTCF with a 500 micron Fugo blade tip in a case of neovascular glaucoma, one day after surgery.

TCTCF is the least traumatic way to drain the posterior chamber. It is most useful in cases of acute congestive glaucoma, phakomorphic glaucoma and neovascular glaucoma. The last group of cases show vascularization of the iris and the angle, but there are no such changes over the ciliary body. TCTCF can be done in any case with a normal posterior chamber.

TCTCF does pass through the tenon capsule, the thickness of the sclera and the highly vascular ciliary body, which is a trauma, howsoever slight it may be.

The following film depicts TCTCF in a difficult case of neovascular glaucoma. There was extensive scarring around the limbus. TCTCF was done by approaching the posterior chamber, from beyond the scarred area.

<http://www.youtube.com/watch?v=uO57F9gdTU4>

TCTCF is handy to treat cases of phakomorphic glaucoma that has lasted for many days or weeks (a common happening in the third world). There is a vicious cycle of the swollen cataract raising IOP and the raised IOP pushing more fluid in to the swollen lens. The moment the posterior chamber drainage starts, there is an improvement in the depth of the anterior chamber. Over days one can see a diminution in the thickness of the intumescent cataract.

The following film shows TCTCF in a case of phakomorphic glaucoma:

<http://www.youtube.com/watch?v=wSWrIr7Jesc>

Now we turn our attention to anterior chamber filtration and look at the opportunities that it offers for minimally traumatic filtration surgery.

2.4. Microtrack Filtration

Microtrack Filtration (MTF) makes a track between the anterior chamber and the anterior most area of subconjunctival space [17,20,25]. If a filtering track between 100 micron to 250 micron could be sustained without internal block and outer scarring, and the aqueous kept seeping out and getting drained by the network of lymphatics, the problem of glaucoma is as good as solved. Easier said than done. Even a microtrack creates a few hurdles that need to be crossed.

Let us first describe the technique of Microtrack Filtration. The steps of surgery are as follows:

1. Anaesthesia: Facial block and subconjunctival injection of lignocaine in adults. General anesthesia in children.
2. Eyeball fixation: An episcleral suture is passed close to the nasal limbus and the eye turned down.
3. Making an opening in the conjunctiva close to the 10 O' clock limbus with a Fugo blade 100 micron tip.
4. Through this hole, 0.1 to 0.2 ml of mitomycin C (MMC) 0.01 % or 0.02 %, is injected under the conjunctiva with a 30 gauge cannula, to raise a bleb at the upper limbus.

5. A pocket incision is made in the anterior chamber with a 0.75 mm diamond knife close to the limbus. Depending upon the surgical plan of peripheral iridectomy, it may be made in line with 3 O' clock, 9 O' clock or 12 O' clock.
6. Pilocarpine or carbachol is injected in the anterior chamber to contract the pupil.
7. Two or three iridotomies are made in the iris periphery, with the help of a 100 micron Fugo blade tip. The iris is touched with the tip and then activated with the highest energy- an opening gets made instantly. Pigment from the posterior pigment epithelium raises a small cloud. The anterior chamber is irrigated with a 30 gauge cannula. It is also passed through the iridotomies to make sure they are patent.
8. A 1.5 mm 100 micron Fugo blade tip is passed through 12 O' clock conjunctiva about 7-8 mm from the limbus, with the lowest energy. It is then pushed under the ballooned/raised conjunctiva in un-activated form, to reach the limbus. When the tip reaches the limbus/ desired point, its location is clearly visualized.
9. The tip is raised by about 30 degrees, while its point remains engaged at the limbus, close to, but slightly away from the attachment of conjunctiva. We wish to avoid conjunctival puncture at the time of microtrack formation.
10. The track making is the next step. The machine has been set at the desired power and intensity levels. The point of the tip is lightly pushing the limbal tissues, when it is activated. In a fraction of a second, it passes through the limbus in to the anterior chamber. As the tip is withdrawn, the aqueous follows, raising an enlarging bleb. A track about 250 micron wide, gets formed anterior to the corneo-scleral trabeculae.
11. Air is injected to deepen the anterior chamber.
12. Sodium hyaluronate (NaHa) in the anterior chamber is optional. It also helps to keep the anterior chamber deep.

Application of MTF:

Any patient with a healthy/virgin perilimbal conjunctiva and an intact anterior chamber is suitable for this operation. It can be used at any age. The surgical trauma is minimal, compared to all other available manual or laser procedures.

Here are some films on MTF:

<http://www.youtube.com/watch?v=C5pHb2JfmaA>

MTF in a case of buphthalmos is shown here:

<http://www.youtube.com/watch?v=XKQ9-JnBx9I>

MTF in a case of keratouveitis is shown here:

<http://www.youtube.com/watch?v=C5pHb2JfmaA>

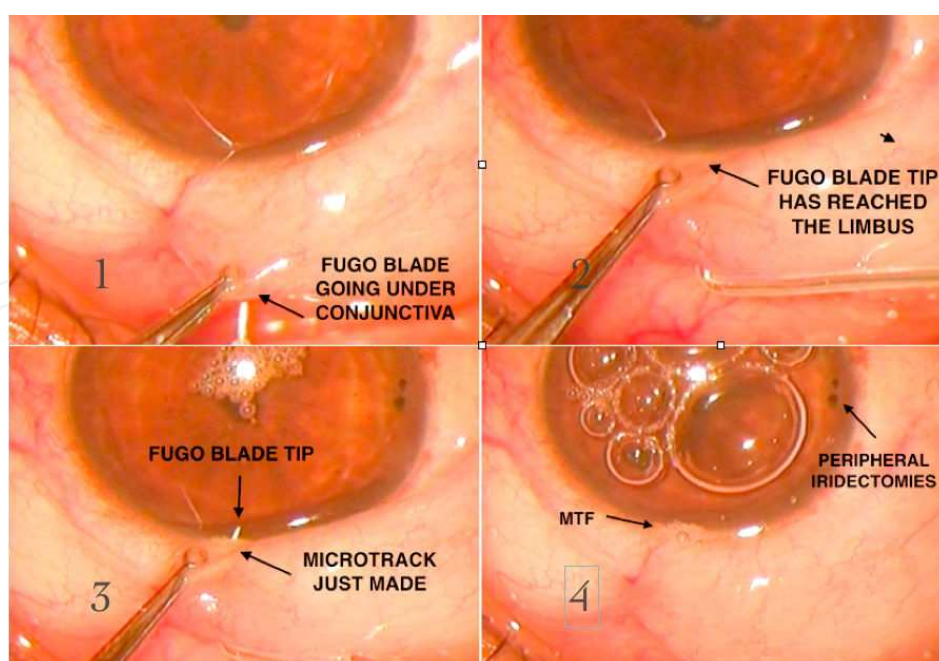


Figure 10. Fugo blade tip is passed through the ballooned conjunctiva about 7 mm from the limbus. It is then pushed to the limbus in un-activated form. Activation of the tip instantly makes MTF track.

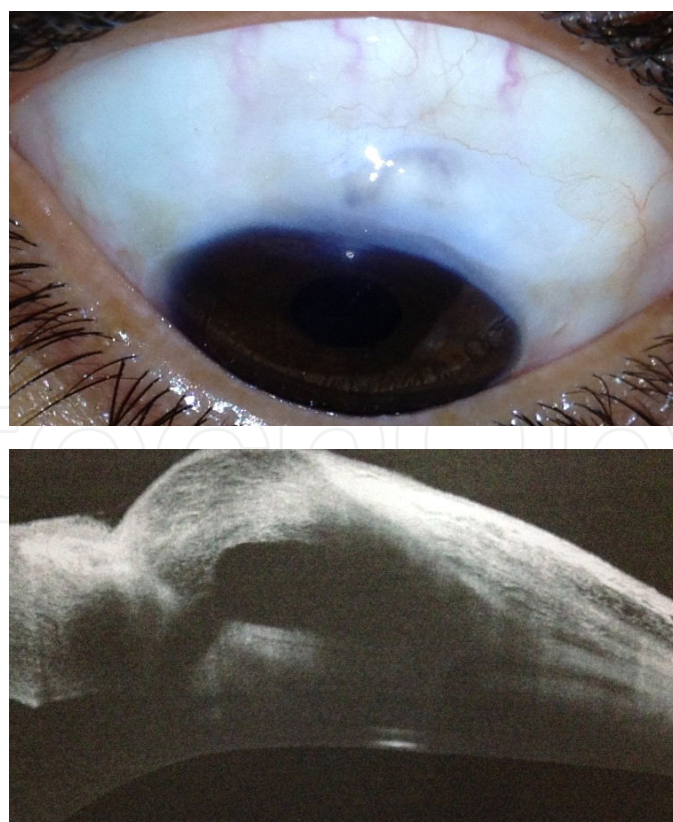


Figure 11. Microtrack filtration, one year after surgery. OCT shows MTF track.

Postoperative course and management:

In the beginning the normal subconjunctival tissues offer little resistance to the outward flow of the aqueous. This little resistance is what keeps the anterior chamber formed, even though it is on the shallower side. We need to keep the iris away from the internal opening of the track. Therefore from day one the pupil is kept contracted by pilocarpine 2% three times a day. I firmly believe that lymphatics play a definite role in offering resistance to aqueous outflow. Initially they act as flood drains, but the outflow is so excessive that a big conjunctival bleb is formed. Later the initial rush of aqueous is over. Then sets in a balance between the out going aqueous and the tissue resistance, at least a part of which is resistance from the lymphatics. The anterior chamber begins to deepen. If it deepens too fast, and the bleb begins to dry up, it is a sign of a partial or complete closure of internal opening by the iris which needs early correction. If the block is complete, the pressure goes high and the patient experiences pain and reduction of vision. The tiny internal blockage with iris shuts down the system. The fluid filled subconjunctival tissues start shrinking and become capable of greater resistance. The internal block is opened with a shot of Yag laser. Once the filtration restarts, the chances of its second time failure are much reduced. If the internal block is not opened for many days and weeks, the external opening also gets closed by healing process. Healing starts when fluid movement stops. One to two days of internal closure does not cause irreversible damage to the filtration track. In cases where cross-linked NaHa (Healaflo) has been used over the external opening track, the fluid movement has been restored after a week or even longer. During these crucial days the patient takes oral diamox and local pilocarpine drops. The moment the tiny piece of iris is detached with a shot of YAG laser, the filtration starts and conjunctival bleb forms.

It is thus clear that the first 3-4 weeks after surgery need very careful watch both by the surgeon and the patient. The vigilance is relaxed but not given up altogether after that. A regular follow up on a monthly or two monthly basis is a must for every glaucoma operated case.

In one recent report (Roy et al 2012) on Deep Sclerectomy in which Healaflo (cross linked sodium hyaluronate) had been used as adjunct, a sizable percentage (38.2 %) of patients required needling to treat bleb failure and encysted blebs. Nearly half (47.3 %) the patients required Nd:YAG laser goniopuncture.

After MTF procedure, there is no scope/necessity for a needling procedure. A bleb leakage never occurs, since a conjunctival flap is not made. The only intervention required/possible is a shot of Nd:YAG laser to disengage the iris if it sticks to the internal opening. If filtration is tardy and the pressure does not come below 20 mm, a combination of timolol and pilocarpine is started. The other medicine is the costlier latanoprost. If that too is ineffective or the patient feels the burden of cost, a re-operation is done. A re-operation is easy, since most of the conjunctiva along with lymphatics is intact. Failure is not an option, since a way can always be found to create a new filtration track.

Film: drainage of suprachoroidal fluid.

<http://www.youtube.com/watch?v=M35h7JShnqc>

Variations in Microtrack Filtration:

MMC may be deposited under the conjunctiva either at the beginning of surgery or at the end of it. We have ample photographic and OCT evidence that the lymphatics are not damaged by the concentrations used.

A side port incision serves many purposes - to make PI, to inject carbachol or NaHa. The last one is useful if more than one MTF tracks are planned. NaHa does not let the anterior chamber collapse, which allows a second or even a third MTF.

In some situations, especially repeat failures by any kind of technique, accompanied by subconjunctival scarring, it may be necessary to make a wider track up to 500 micron (300 micron tip at highest energy setting). In a case of perilimbal scar formation, the track formation is started proximal to the scar and a longish track is made through the sclera and limbus in to the anterior chamber.

Pre-tenon MTF:

The tenon capsule gets attached to the limbus, proximal to the attachment of the conjunctiva. Thus there is a potential subconjunctival space distal to the tenon attachment. This pre-tenon subconjunctival space can be approached to produce a somewhat tangential filtration track at the limbus. A film of this procedure can be see here:

<http://www.youtube.com/watch?v=TXAw6tXPDfE&feature=endscreen>

2.5. Choroidal detachment

Hypotony is the probable cause of choroidal detachment. There are greater chances of hypotony In aphakes, vitrectomized eyes, trauma, buphthalmos and high myopia cases. It may start soon after surgery or during the first 2 postoperative days. In some cases there is severe pain at the start. Fundus examination and b-scan reveal choroidal detachment - from slight to kissing choroidals. The situation is watched for a week, after which the suprachoroidal fluid is drained.

The steps of operation are as follows:

The conjunctiva is pushed towards the limbus from a distance of about 8 mm to a distance of 4-5 mm, with a blunt sapphire knife. A 100 micron Fugo blade tip is used to incise the conjunctiva, tenon capsule and the sclera, till supra-choroidal fluid starts draining. When sufficient fluid has drained, air is injected in the anterior chamber. No attempt is made to suture the scleral incision. The tenon capsule and the conjunctiva retract to normal. A couple of sutures are applied to the conjunctival incision.

Film: drainage of suprachoroidal fluid.

<http://www.youtube.com/watch?v=M35h7JShnqc>

Strategies to improve results with Microtrack Filtration

The strategies are based on the knowledge that the out coming aqueous is drained by the conjunctival lymphatics. Also on the observation that in the beginning the aqueous outflow

is excessive and can sometimes cause excessive shallowing of the anterior chamber, leading to internal closure by the iris.

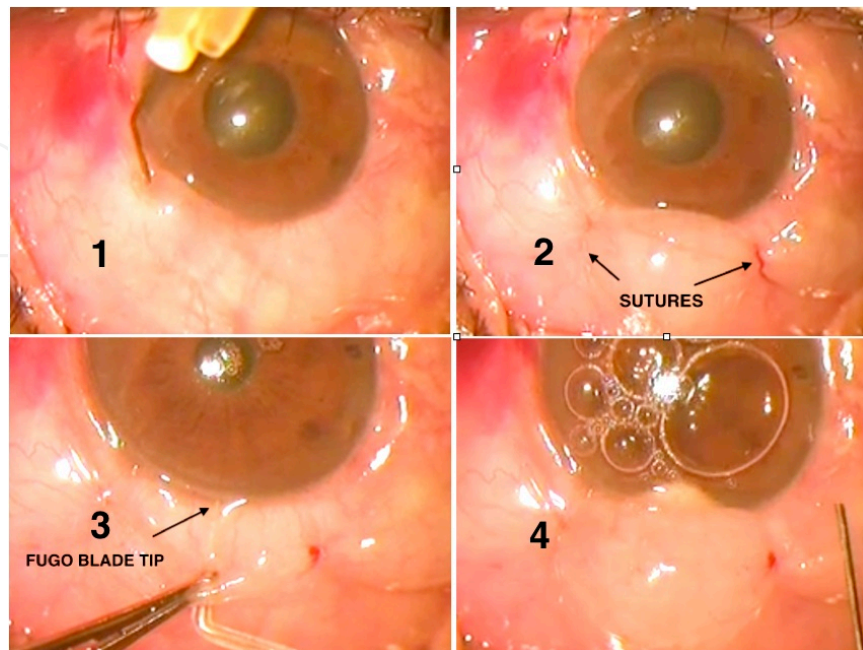


Figure 12. The ballooned conjunctiva is tied vertically on either side of 12 O' clock. Fugo blade is passed under the conjunctiva, taken to the limbus and MTF track made. A bleb gets formed. Air is injected in to the anterior chamber.

2.6. Tying the lymphatics

On either side of the proposed site of MTF, the conjunctiva is tied like a sheaf with a 10 zero suture. This ties the subconjunctival lymphatics too.

The steps of operation are as follows:

1. Making a hole in the conjunctiva close to the limbus of 10' O clock.
2. Injecting MMC 0.01%, 0.02 % through a 30 gauge cannula, to raise the conjunctiva widely, between 11 and 1 O' clock.
3. A suture is tied at 1 O' clock, starting near the limbus and getting out of the conjunctiva, three or four mm proximally. The bite catches the subconjunctival lymphatics along with the conjunctiva. The suture may be 10 zero prolene or 30 micron steel. It may be tied loosely with the intention of removing it after a few days. Or it may be tied fast, the intention being to leave the suture permanently. The second suture is tied at 11 O' clock. The conjunctiva gets raised between the two sutures.
4. A 0.75 mm corneal pocket incision is made close to the limbus, through which two iridotomies are made with a 2 mm long 100 micron Fugo blade tip. Highest energy is given to the tip to do iridotomy.

5. Anterior chamber is irrigated with a 30 gauge cannula. It is also used to verify the patency of iridotomies.
6. Microtrack filtration is done as usual. The raised conjunctiva only makes the job easier.
7. Air or NaHa or both are injected in the anterior chamber, through the pocket incision. NaHa can also be placed under the conjunctiva, between the two sutures.

The shape and the size of the filtration bleb is determined by the sutures. I call it a 'designer bleb'. The purpose is to restrict the outflow of aqueous, which reduces the tendency to shallowing of the anterior chamber, in the early postoperative period.

The resistance from the subconjunctival space between the sutures, can be further increased by putting cross linked NaHa (Healaflo) or collagen matrix (Ologen).

The purpose of every exercise is to control the depth of the anterior chamber.

Microtrack filtration, with two conjunctival sutures to restrain lymphatics is shown here:

<http://www.youtube.com/watch?v=YYwalTIXQ0s>

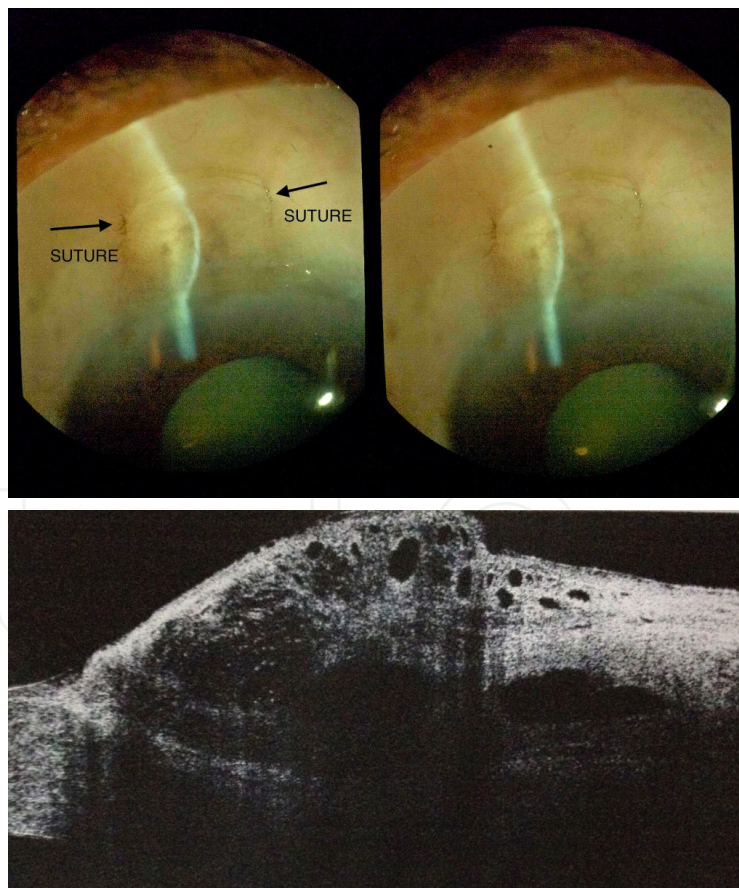


Figure 13. Bleb resulting from two conjunctival sutures, 5 months after surgery. The IOP is 12 mm from the initial 40 mm. The bleb has a good conjunctival cover. The proximal end of the bleb shows pleating. OCT shows the effect of two conjunctival sutures. There is a small kink. Lymphatics are also visible.

3. Intracameral suture

Intracameral sutures have been in use for a long time, mostly in relation to intraocular lens implants and trauma surgery. The tracks they make and the space they occupy are devoid of complications.

In connection with Microtrack filtration surgery, we thought of using intracameral sutures to prevent the iris from moving forward and closing the internal opening. The idea is to have a 10 zero polypropylene suture or a 30 micron stainless steel wire stretched in front of the iris periphery in the area of the MTF track.

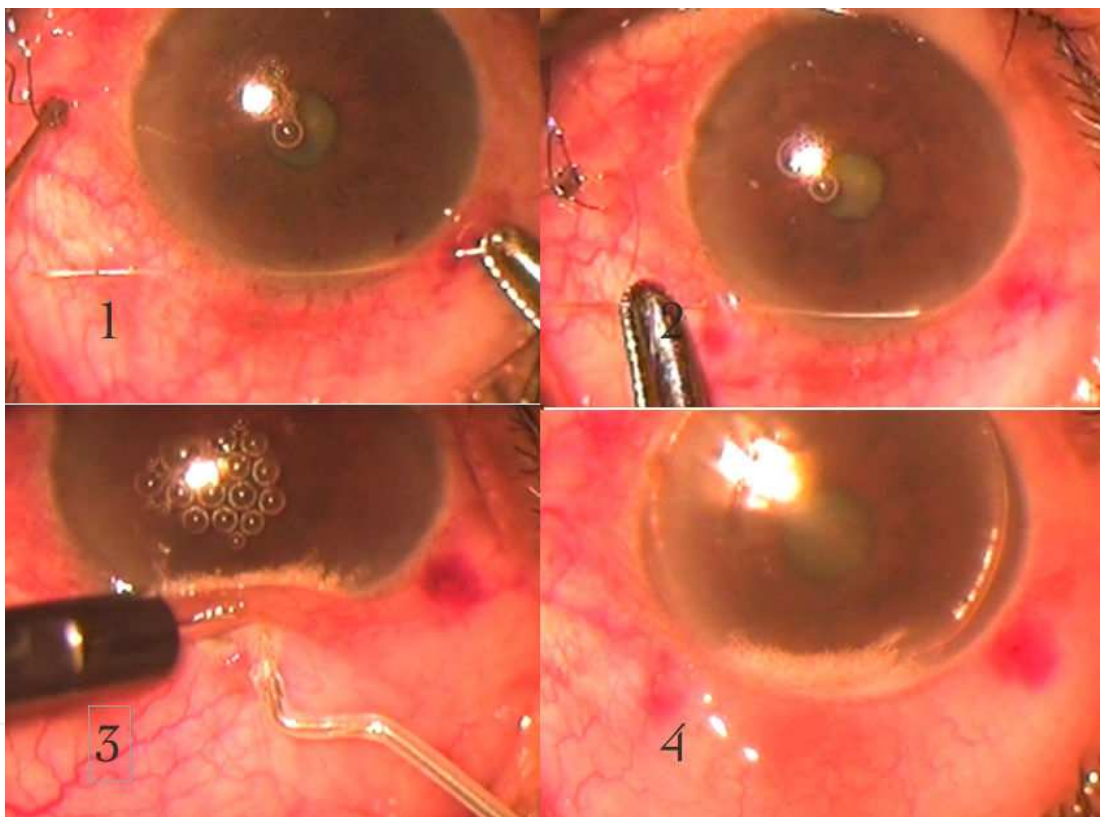


Figure 14. Transcameral suture is passed once towards the left and then it is returned to the right. The entry point is about 1 mm from the limbus in the sclera. Air is injected after MTF.

Steps of operation:

1. A small pocket incision in the cornea with a 0.75 mm diamond knife, at 3 O' clock or 12 O' clock.
2. The pupil is contracted with intracameral carbachol.
3. One two or three iridotomies are done in the periphery of the iris. The iridotomies are verified with a 30 gauge irrigation cannula.

4. A 1 cm + long straight needle carrying 10 zero prolene is passed through the upper part of the anterior chamber. The entry and the exit points are in the sclera, about 1 mm from the limbus. For leaving the suture permanently, the needle is returned parallel and close to the first route. The suture is tied and cut short and the knot buried.
5. A conjunctival hole is made at 10 O' clock close to the limbus. 0.1 to 0.2 ml of MMC 0.01% or 0.02 % is injected through a 30 gauge cannula, so as to raise a balloon. The fluid is spread out by the length of the cannula. Wait for 2 minutes.
6. MTF is done with a 100 micron Fugo blade tip is set at highest energy, which ablates a 250 micron track.
7. An air bubble is placed in the anterior chamber. NaHa can also be added to the anterior chamber to provide better stability.

MMC can be placed under the conjunctiva, either before or after doing MTF.

If a temporary intracameral suture is to be placed it is done as follows: The prolene carrying needle is passed through the anterior chamber, but is not pulled out on the other side, till MTF track has been made. The suture is tied over the limbus. The suture is stretched close and under the internal opening of the MTF track. This suture can be easily lifted and cut after 2-3 weeks, when the anterior chamber has become stabilized. Both variations of intracameral suture are seen in the following film:

http://www.youtube.com/watch?v=iNk_AsC-SEw

The procedure is somewhat cumbersome.

4. Viscoelastic resistance

The goal is to create resistance around the filtration track by injecting a viscoelastic material in the anterior chamber or subconjunctivally. NaHa is one such material. Its effectivity is difficult to perceive beyond 4-5 hours.

The other material is Healaflow- cross linked sodium hyaluronate, a material of high viscosity with an ability to stay in place for a long time and getting resorbed slowly. It has been used in all kinds of glaucoma operations as an adjunct since 2008. It has been used in the scleral space, under the scleral flap and under the conjunctiva. Healaflow is reticulated i.e. its architecture is like a network. This makes it a good space former and it has a long life span in situ.

The unique properties of Healaflow, make it particularly suitable as an adjunct in MTF. Under the conjunctiva, it is used as a "liquid cushion" against excessive flow during the first days and weeks after surgery. It is also our understanding that Healaflow presence under the conjunctiva shall retard the entry of aqueous in to the conjunctival lymphatics, create a sort of back pressure, that may prevent a flat anterior chamber. This reduces/prevents internal iris block.

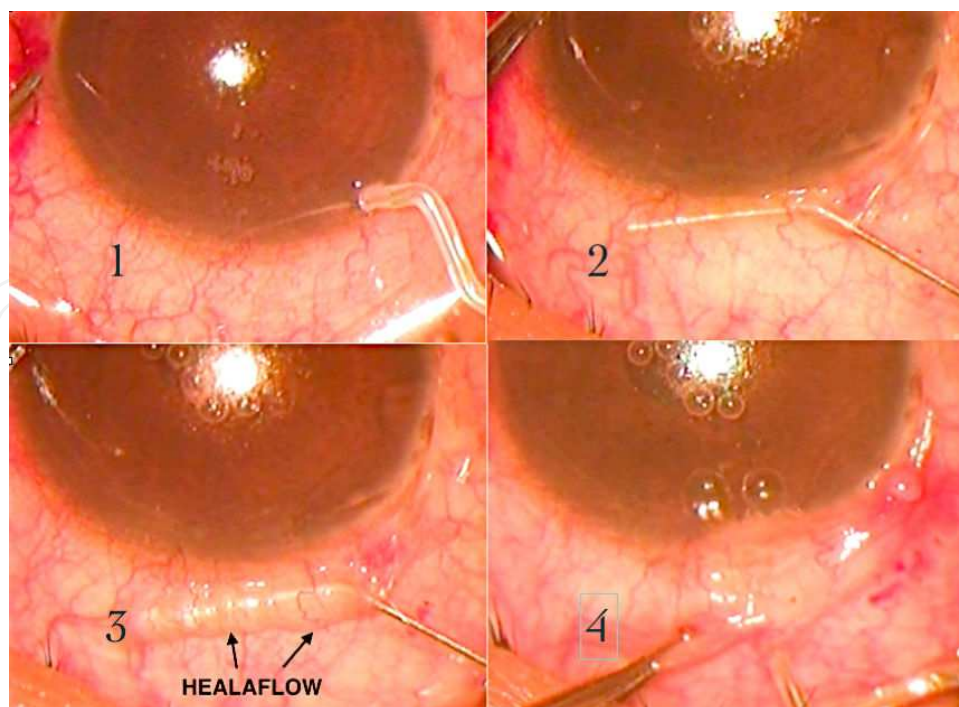


Figure 15. Peripheral iridotomy is made at 12 O' clock. Space is created along the limbus, in which Healaflow is deposited. MTF is done with 100 micron Fugo blade tip two times. The aqueous does not rush out since there is NaHa in the anterior chamber.

The steps of operation are as follows:

1. Making a conjunctival hole at 11 O'clock close to the limbus.
2. Raising a large bleb of MMC 0.01% or 0.02 % at the upper limbus.
3. Opening the anterior chamber with a pocket incision of 0.75 mm.
4. Contract the pupil with intracameral carbachol.
5. Making one or more peripheral iridotomies at 12 O'clock of the limbus.
6. Injecting NaHa in the anterior chamber close to the upper limbus.
7. Pushing away the subconjunctival fluid close to the limbus, with a cannula.
8. Through the existing conjunctival hole, Healaflow is injected along the upper limbus. it appears as a raised transparent strip along the limbus. The excess starts coming out through the conjunctival hole, which hole is closed with a single suture.
9. MTF is performed with a 100 micron Fugo blade glaucoma tip. With low energy it is passed through the conjunctiva about 7-8 mm from the limbus. It is then pushed towards the limbus unactivated, till the root of the conjunctiva is reached. The transparent raised Healaflow prominence improves the visibility of Fugo blade tip. Once the position of the tip clearly visualized, it is lifted at an angle of about 30 degrees, kept lightly pressed at the limbus as inactivated. The moment it is activated from the foot switch, it ablates a track

through the limbus in to the anterior chamber. There is only a slight flow of aqueous due to the presence of NaHa in the anterior chamber. The 100 micron Fugo blade tip if activated at high power, makes a precise 250 micron track. At medium power, the track shall be 200 microns.

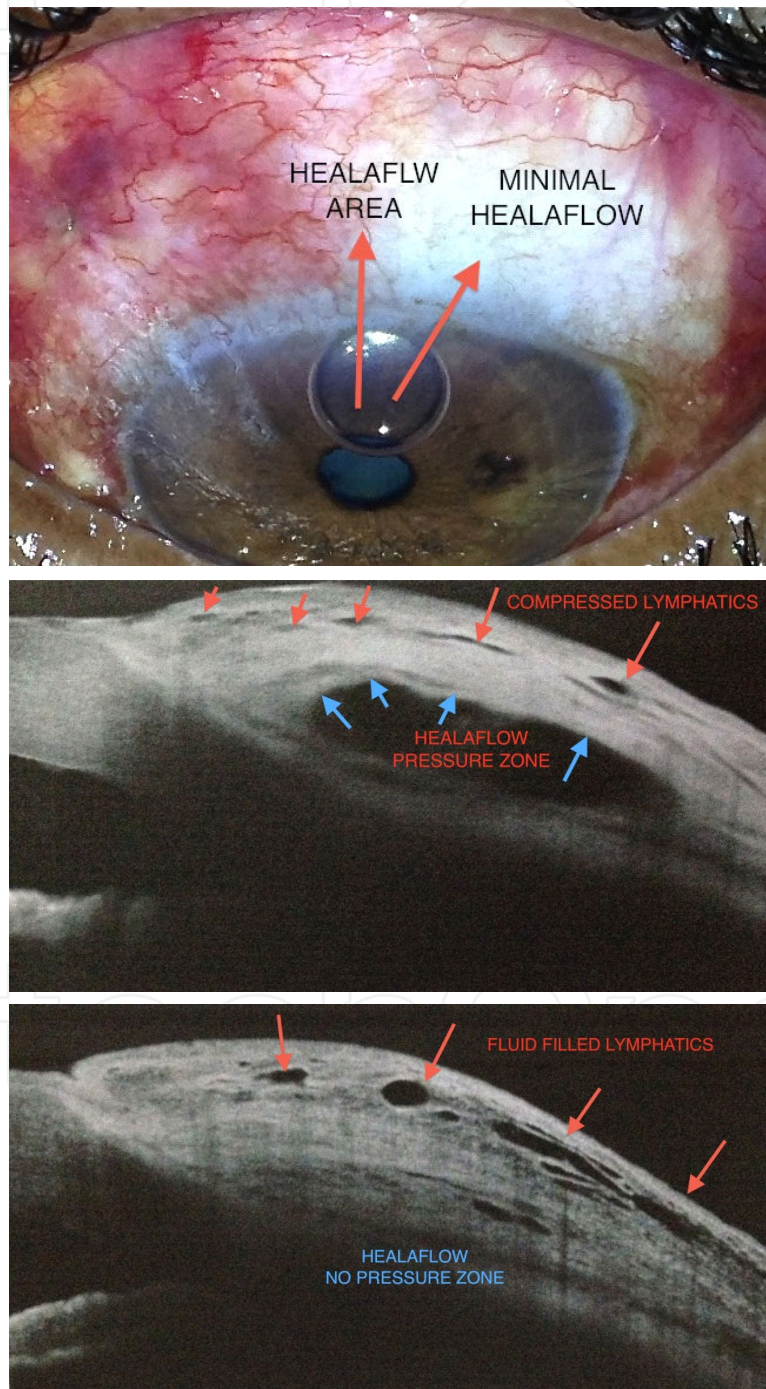


Figure 16. MTF with Healaflow 2 days after surgery. Healaflow compresses the overlying conjunctival lymphatics. The compression is maximum in the central area and minimum in the periphery

10. The conjunctival hole for MTF being only 150 micron, there is no need to apply a suture to it.

The use of NaHa inside the anterior chamber and Healaflow on the outside, provides excellent control on the flow of aqueous during surgery and for many hours and a few days after surgery. Even though NaHa shall disappear after some hours, Healaflow continues to exert the useful effect of a liquid cushion from the outside.

OCT done in the early postoperative days shows a dome of conjunctiva raised by Healaflow. The dome soon flattens out, after which it is difficult to discern clearly the location of Healaflow. For any dark slit like appearance, we can presume it to be that.

Conjunctival lymphatics act as flood drains for the aqueous and blood under the conjunctiva. Huge quantities of blood can be removed from the field quite efficiently. We have found that subconjunctival silicone oil is not taken away by the lymphatics. We do not know if Healaflow finally gets drained by lymphatics or it gets broken by the natural enzymes.

For delivering a precise amount of Healaflow along the limbus, it is filled in a cannula of desired size. The cannula is then transferred to NaHa syringe and used. The end point is difficult to make out since NaHa and Healaflow are both transparent. The other way is to attach Healaflow carrying cannula to a trypan blue syringe. The moment blue dye is seen, it means that whole of "cannula contained" Healaflow has been delivered. If more Healaflow is desired, the amount can be delivered direct from Healaflow syringe.

Microtrack Filtration plus Healaflow films are here:

Healaflow only:

<http://www.youtube.com/watch?v=2wKcwOYdKfc>

Healaflow and trypan blue:

<http://www.youtube.com/watch?v=CBnJl2riAso>

Failed MTF Ologen case, Re-MTF along with Healaflow <http://www.youtube.com/watch?v=WTWSK1O1c8g>

5. Spongy resistance

Collagen matrix (available as Ologen) is a sponge like structure having wide bore channels ranging from 20 to 200 microns. It is available as discs of various sizes and shape, the sizes being 6 to 10 mm and the height being 1 to 2 mm. They have been made with a view to cater for the needs of filtration surgery techniques in which scleral flaps are made. The matrix is said to guide the fibroblasts through the pores in a random fashion and thus prevent scar formation. It may also act as a reservoir buffer to prevent shallow or flat anterior chamber. When wetted it swells up like a sponge. Ologen is said to disappear in 3 months time.

Ologen appears an interesting material to increase subconjunctival resistance to the free flow of aqueous, after MTF. I have used it two ways:

1. Placing a small piece of Ologen in the immediate vicinity or directly over the MTF external pore.
2. Placing multiple Ologen pieces some distance from MTF track, with a view to create resistance to the passage of aqueous, in to the lymphatics.. The swollen Ologen pieces compress the lymphatics in the area.

The steps of operation are as follows:

Anesthesia as usual

1. Make a 0.75 mm pocket incision close to the limbus. Use carbachol intraocular to contract the pupil.
2. Fugo blade iridotomy/iridotomies, as described earlier, followed by irrigation of the anterior chamber to clear the released pigment.
3. Make a hole in the conjunctiva close to the limbus at 10 O'clock. Through this hole a long 30 gauge cannula is introduced under the conjunctiva and is used to loosen the subconjunctiva close to the limbus.
4. A small elongated piece of Ologen is brought close to the conjunctival opening. It swells up immediately by the local moisture. The material is spongy and pliable. It can be pushed under the conjunctiva by the tip of a thin cannula. The Ologen piece is taken to 12 O'clock site close to the limbus. It shrinks when the conjunctiva is pressed, and swells up again when the pressure is released. The Ologen piece may be stained with trypan blue before insertion, for better visualization during the entire process.
5. A 100 micron Fugo blade glaucoma tip is entered with momentary low energy under the conjunctiva about 7-8 mm from the limbus, in line with the Ologen piece. The tip is then pushed unactivated under the conjunctiva and under the Ologen piece, till it reaches real close to the conjunctival attachment to the limbus. The tip is rested there and is then raised to an angle of 30 degree or over, depending upon of the resistance of the conjunctiva, under which it is working.
6. With hand steadily holding the Fugo blade and the tip putting very slight pressure at the limbus, it is momentarily activated from foot switch. It instantly passes through the limbus in to the anterior chamber, as indicated by the formation of cavitation bubbles in the anterior chamber. During passage through the limbus, cavitation bubbles also spread on both sides of the entry point, which makes the corneal tissue temporarily opaque.
7. Air is injected in the anterior chamber.
8. A balloon of 0.1 to 0.2 ml of Mitomycin 0.01 or 0.02 % is made under the conjunctiva.

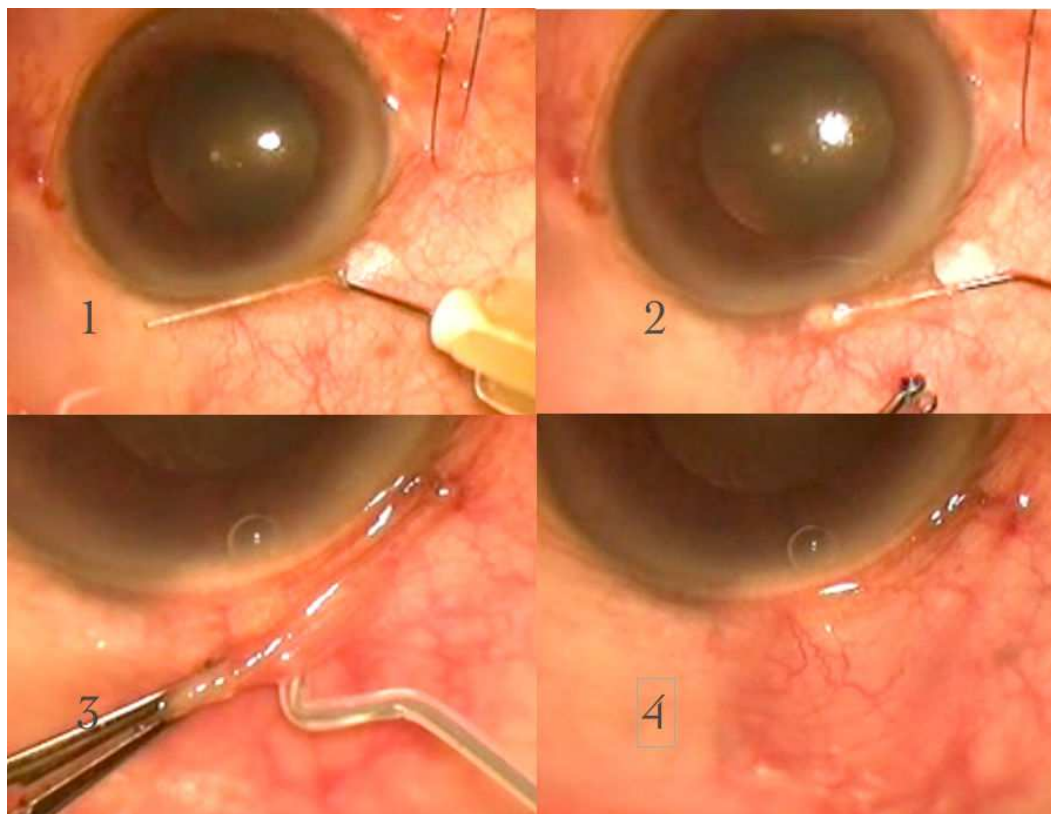


Figure 17. A thin cannula loosens the subconjunctival space close to the limbus. A piece of Ologen is pushed through the conjunctival opening to the 12 O clock limbus. MTF is performed close to one end of Ologen. Air bubble in the anterior chamber is an indication that MTF track really got made.

Postoperatively, we watch the state of the anterior chamber and the bleb and remain awake to the possibility of internal blockage of the track with the iris, the only problem point of MTF surgery.

We have observed that if there is no free movement of aqueous, the collagen matrix becomes hard and dry and refuses to get absorbed. It also becomes adherent to the overlying conjunctiva and it becomes difficult to separate the two.

Healaflo and Ologen are two materials, which can increase the subconjunctival lymphatic resistance to the out coming aqueous. This resistance is important in the first few postoperative weeks. It reduces the chances of shallowing/absence of the anterior chamber. Both materials provide resistance, one as a liquid cushion and the other as a soft sponge. The placement of Healaflo is easier than Ologen. Both materials are supposed to disappear with passage of time. It is not easy to find out when the material disappeared or whether it really disappeared. However our main concern is to see if they did the work that was expected from them i.e. reducing the incidence and severity of internal blockage of the track with iris. After doing 75-80 surgeries in both groups, it is our perception that there has been a palpable reduction in the use of YAG laser for removing internal MTF iris blocks.

There is only one variation possible with Healaflo, namely the amount of the material deposited. With Ologen many variations are possible, namely number, size and position of the

pieces. Furthermore, if an Ologen piece is placed at the limbus, MTF track can be made on one side, under it or through it.

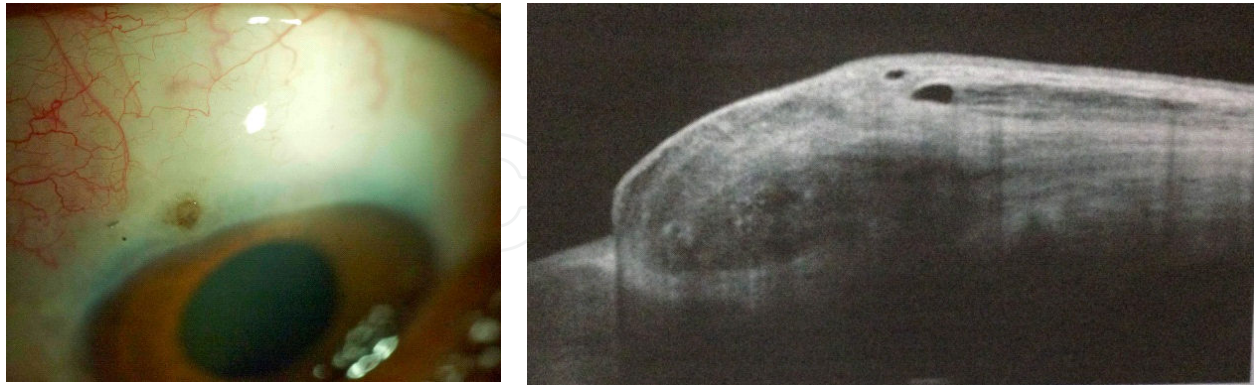

Figure 18. MTF and Ologen, 6 months postoperative. Ologen has caught the pigment coming from inside, that would otherwise have been drained away with aqueous. OCT shows good cover for bleb. It is difficult to decide if Ologen has been absorbed or not.

Here is a film on MTF with Ologen piece over the filtration track:

<http://www.youtube.com/watch?v=NkwuIRjA3aQ>

To treat hypotony after MTF surgery, we have also used/placed a piece of Ologen directly on the over-filtering MTF track, with success.

6. Reducing the width of the filtration track

The standard 100 micron glaucoma tip has a teflon sleeve of 50 microns thickness. For it to pass through the limbus, the plasma on the tip has to be wider than combined width of the fibre and sleeve. At medium power, the plasma cloud is 50 microns, therefore the track width is 200 microns. At high power setting the plasma cloud is 75 microns on all sides of the filament, therefore the track size is 250 microns. If we use naked filaments of 75, 100 or 120 microns at low energy, we can have smaller widths of MTF tracks. Thinner tracks cause slow decompression during surgery. Since the speed of aqueous out flow gets reduced, the track is less likely to attract the iris. If a block occurs, the iris tissue is small and is easy to dislodge. Some successful cases show no bleb at all.

The steps of mini-MTF operation are as follows:

1. Pocket incision 0.75 mm parallel to the upper limbus. Inject carbachol to contract the pupil.
2. Make a conjunctival opening near 10 O'clock limbus and inject 0.01 or 0.02 % MMC to balloon the conjunctiva along the limbus and beyond.

3. Peripheral iridotomies are done with Fugo blade. The important thing is to wash out completely all the pigment/debris produced during iridotomy, because even a small particle can block the filtration track from inside.
4. Fill the upper part of anterior chamber with NaHa.
5. Push away any subconjunctival fluid close to the limbus, by sweeping with a cannula.
6. For MTF, use a 75 micron naked filament Fugo blade tip. Push the conjunctiva towards the cornea, with a blunt sapphire knife. When the limbal area is clearly seen, the activated tip is passed through the conjunctiva and the limbus in to the anterior chamber. The aqueous does not come out, but the track making is complete, since cavitation bubbles are seen to arise in the anterior chamber. One can make two or more tracks if so desired. A second track can not be made if aqueous has started flowing out, because the naked tip does not work in the water. NaHa in the anterior chamber helps make more than one track.
7. Healaflow may be deposited under the conjunctiva if so desired, at this stage.
8. A small air bubble is placed in the anterior chamber. It pushes out some NaHa and aqueous, proving that the system is working.

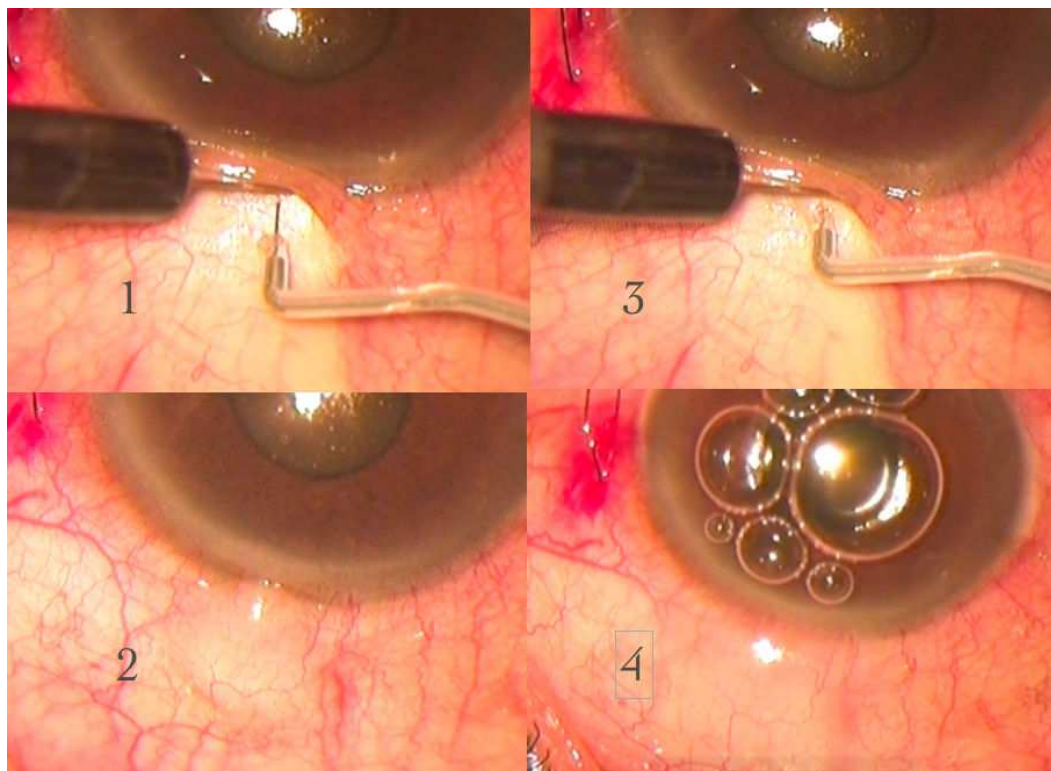


Figure 19. A naked 75 micron Fugo blade tip kept close to the conjunctiva retracting sapphire blunt blade, passes through the conjunctiva and limbus as soon as it is activated. The bleb forms slowly. Air is injected in the anterior chamber at the end.

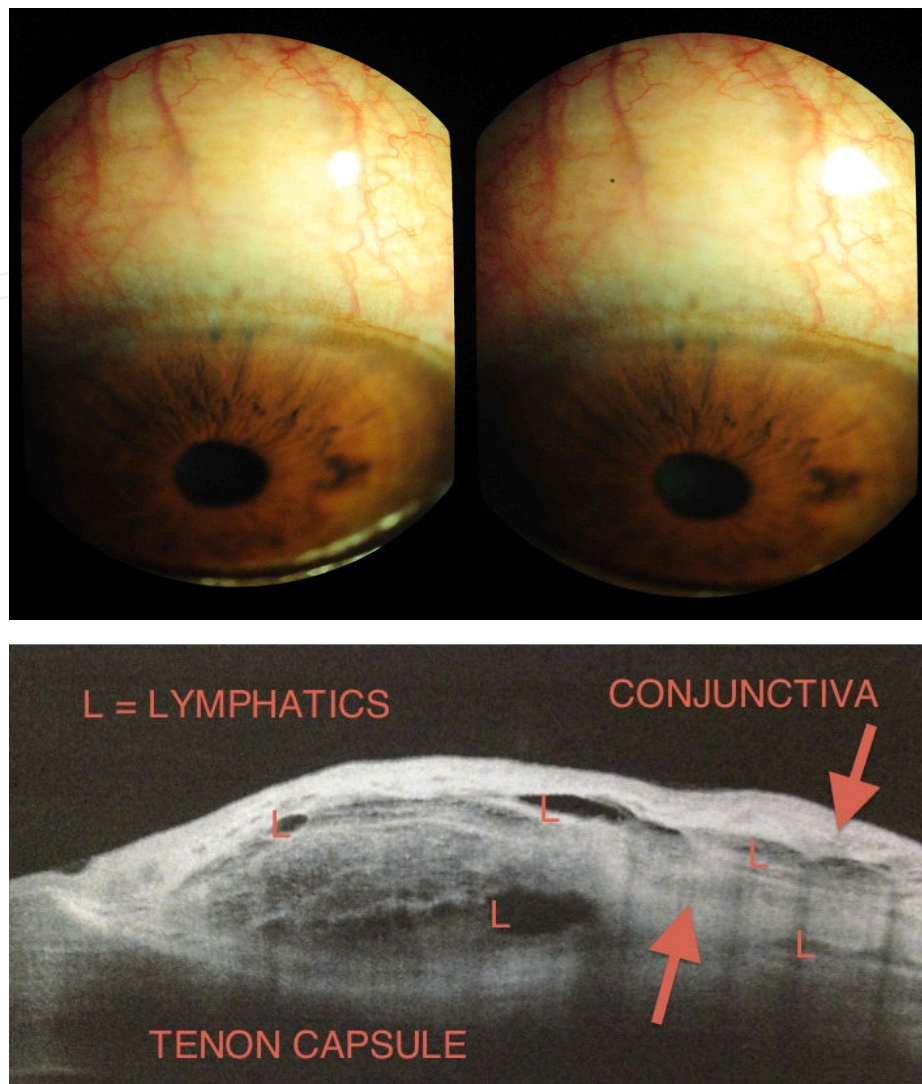


Figure 20. The bleb after Mini-MTF. The anterior chamber has remained well formed. The bleb appearance is reassuring. L are for lymphatics.

Here is a film on small track MTF

http://www.youtube.com/watch?v=WEn_AS_h9Do

7. Mitomycin

MMC reduces scar formation. This helps to improve results. Unlike other surgical techniques in which MMC is applied under the conjunctiva with sponges, we raise a bleb with 0.1 to 0.2 ml of a desired concentration of MMC. This assures a wider spread that results in a borderless bleb. Our OCT observations of the blebs show that MTF cases maintain a healthy cover of the conjunctiva. There is no danger of bleb leakage, because no conjunctival flap is made. MMC concentration has been used varying from 0.005 % to 0.04 %. The higher risk

cases receive higher concentration of MMC. The deposited MMC is left as such, its dilution starts as soon as the track is made and aqueous starts draining. The mainstream glaucoma surgery does not give a thought to lymphatics. We believe that they are the crux of successful filtration surgery. It is a great satisfaction that they are not damaged by MMC with the concentration used. An MTF opening is small compared to tracks made with other techniques. Therefore it is all the more important that it should not get scarred on the outside.

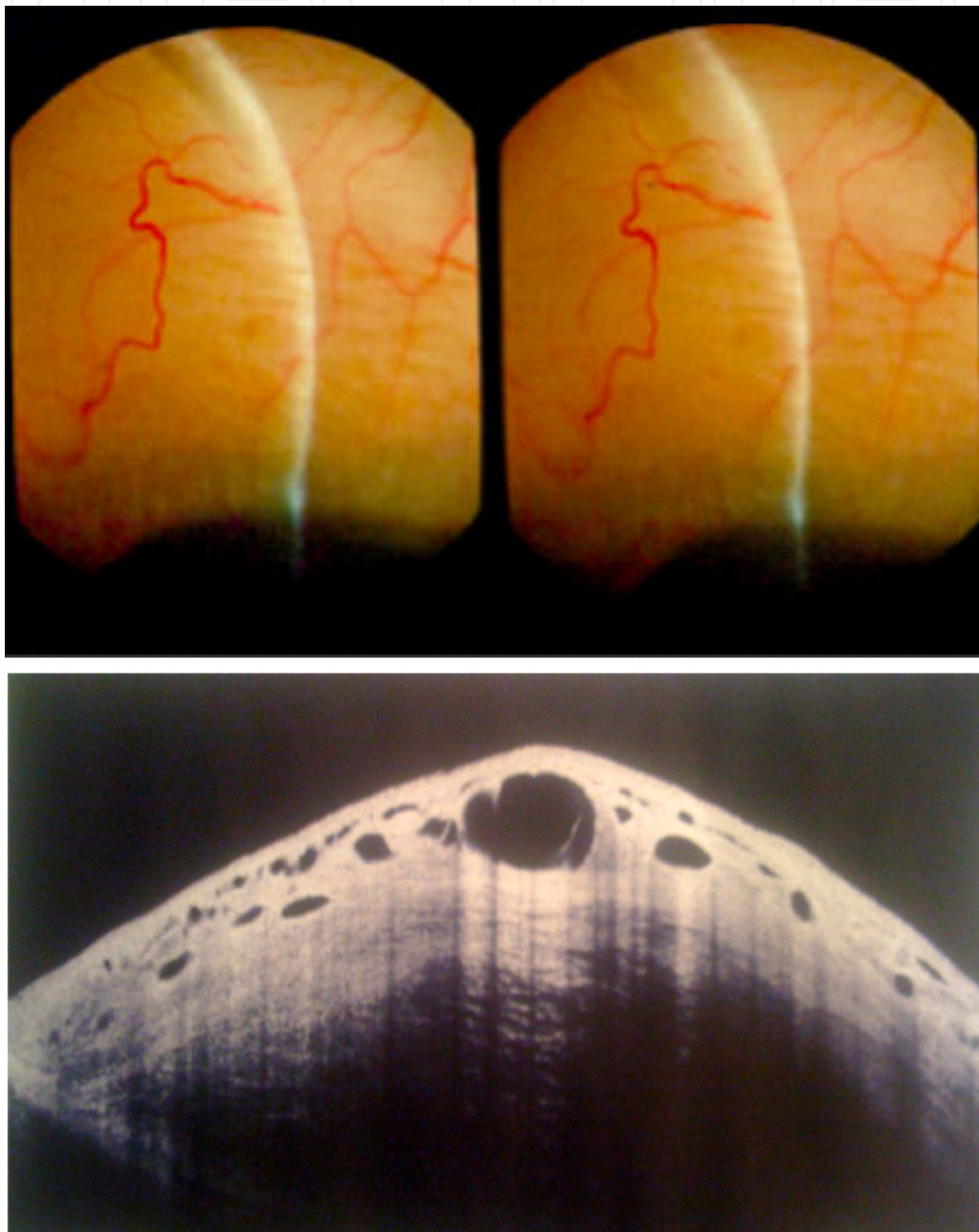


Figure 21. A 35 years old case of MTF, shows the presence of filled lymphatics under the conjunctiva, one month after surgery, both on slit lamp optical section and with OCT. The OCT image is particularly striking. IOP is 9 mm, down from 35 mm.

8. A bandage contact lens

A bandage lens provides a soft lid over the external opening of MTF. It helps to maintain the depth of the anterior chamber. At the time of surgery there is already formed a bleb that prevents it from occupying its intended place. However, after 3-4 hours, when the taped eye is opened, the bandage lens shall be found sitting over the track. The bandage lens may be removed after a week or two. If no bleb is seen under the bandage lens, it is a sign that somehow the iris has blocked the track from inside.

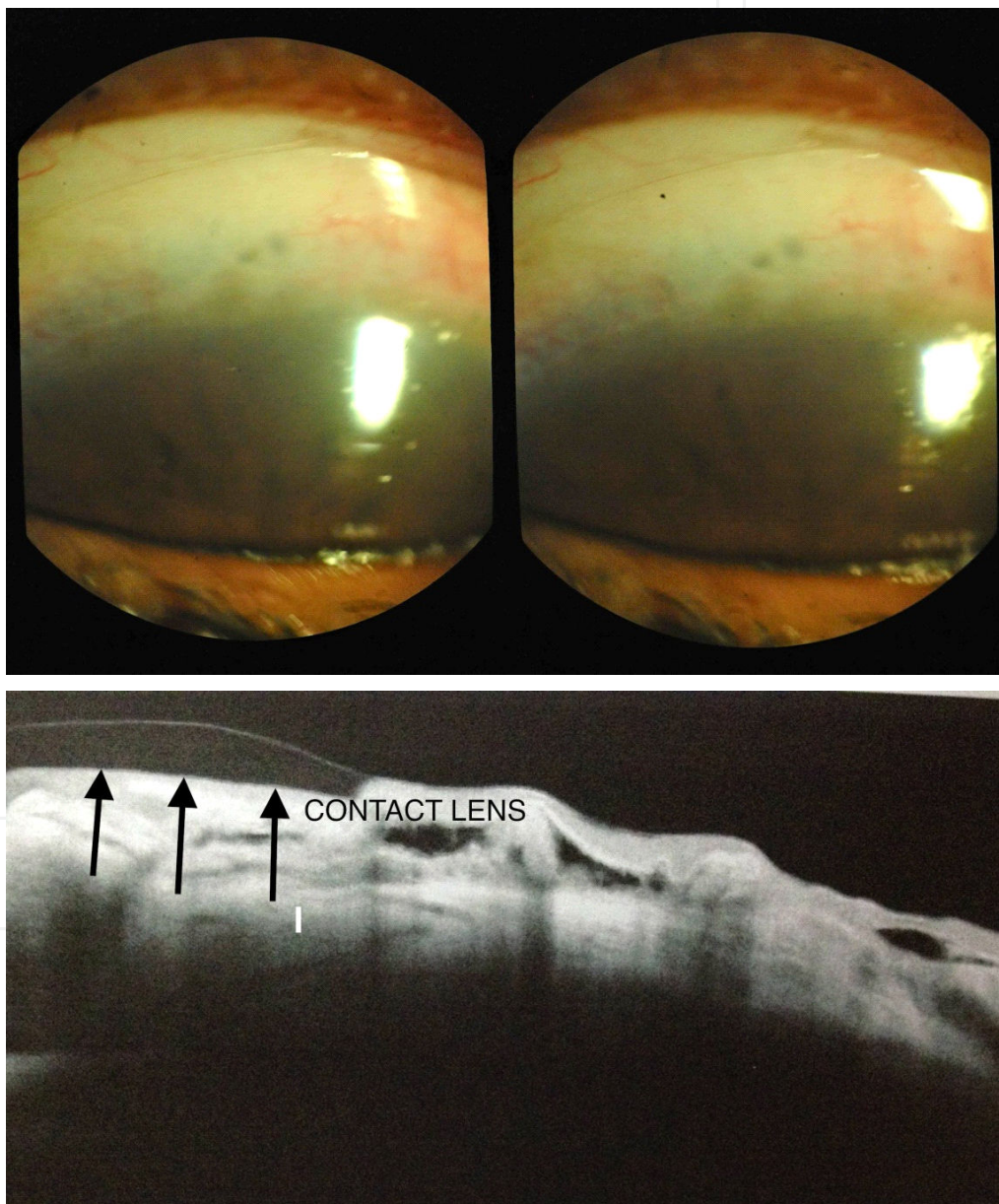


Figure 22. A bandage lens over two MTF tracks. The anterior chamber has good depth. OCT shows a bandage contact lens riding over track area

9. Comments

From the foregoing description many points are clear. MTF is the least traumatic of all filtration operations. Currently we are making 150 to 250 micron filtration tracks. We are trying to cope with the frequent problem of internal block by iris, which has to be cleared with YAG laser. YAG laser management of iris block is a minor intervention. But think of the worldwide lack of YAG lasers in clinics and far off places. All the various strategies described above are attempts to keep the iris away. At the same time filtration should continue. I do all my filtration surgery with a 6X head-worn loupe/microscope. Thus it is possible to perform MTF in any remote area, where the light source shall be a hand held bright LED flash light. No dissection filtration surgery protects conjunctival lymphatics. There is an ever increasing load of tens of millions of glaucoma patients, who can not afford life long medication.

Now let us consider, minimally traumatic filtration surgery in some specific situations.

10. Failed trabeculectomy

The following is a description of a forty years old male who had a failed trabeculectomy surgery. IOP was 41 mm. under multiple medications. The

scleral flap was clearly visible and there was no trace of a bleb. The surgery was done as under:

The conjunctiva was raised with MMC 0.01%. A 100 micron microtrack was made close to the failed area followed by air injection in the anterior chamber. A 300 micron Fugo blade was then used to make a conjunctival opening 7-8 mm proximal to the upper edge of the closed scleral flap. The tip was pushed to the edge of the scleral flap. The tip was activated and insinuated under the edge of closed scleral flap at many places. The subsclear space communication with the anterior chamber was assured. 4 months postoperative, the IOP was 12 mm and the bleb was good.

The movie of this patient is here:

<http://youtu.be/T72kVgNeKzY>

There are more movies on this topic:

<http://www.youtube.com/watch?v=HxZravthPGI>

<http://www.youtube.com/watch?v=jn7ojuYbmaE>

Management of Tenon cyst formation after TCFTCF:

<http://www.youtube.com/watch?v=Bo3crwrpUDg>

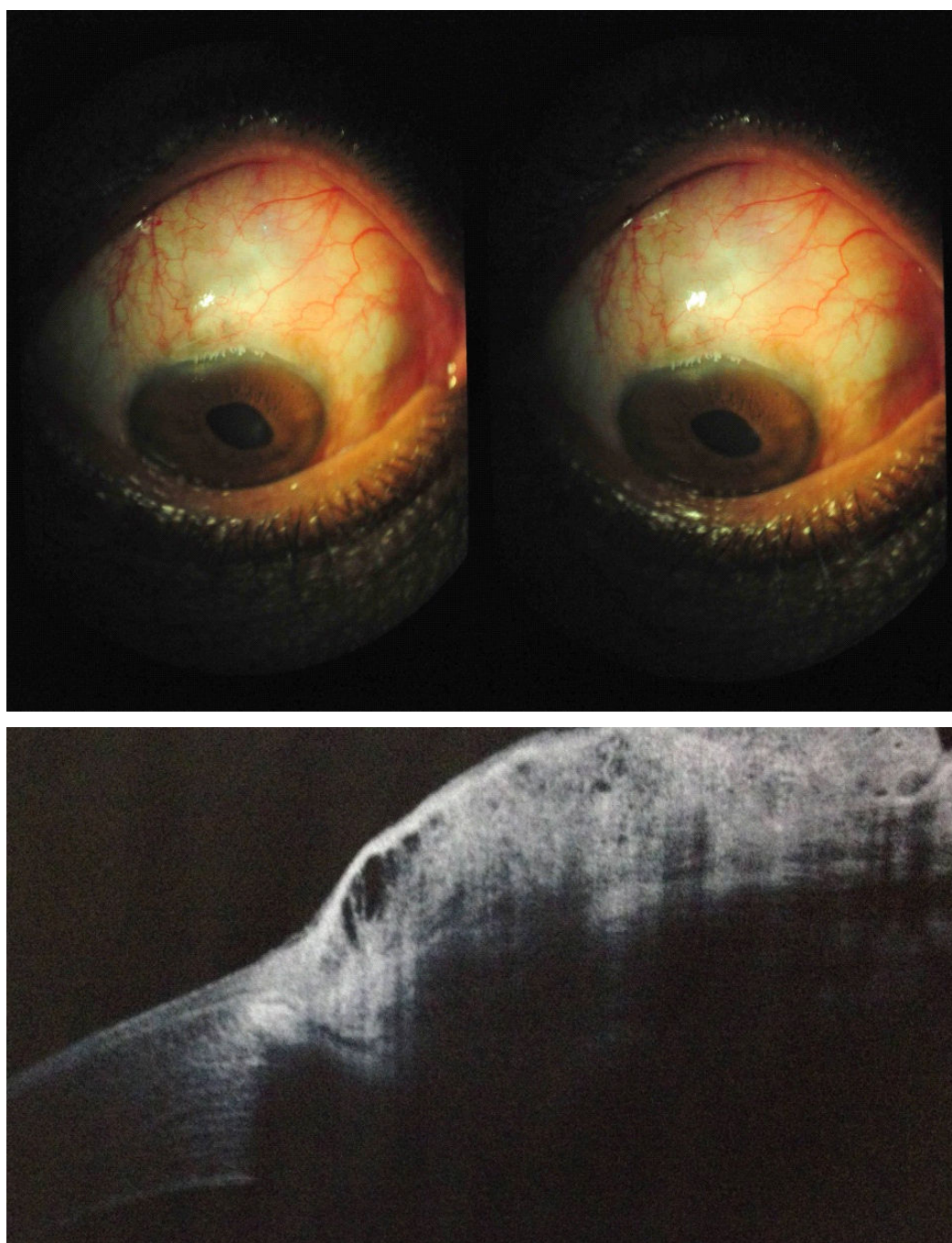


Figure 23. Failed trabeculectomy case, 4 months after MTF and opening the scleral flap with Fugo blade. OCT shows that the bleb is well made and safe.

10.1. Neovascular glaucoma

TCTCF is the least traumatic way of filtration surgery in neovascular glaucoma. The track avoids the new vessel formation in the iris and angle. Decompression may start bleeding in the angle, but it does not affect the filtration through TCF track.

A film on TCTCF in an already failed glaucoma surgery is seen here:

<http://www.youtube.com/watch?v=uO57F9gdTU4>

10.2. Buphthalmos

Buphthalmos is one of the most difficult conditions to treat. Failures are common. Therefore it is important that any glaucoma surgery should not leave behind a large foot print on the sclera and the overlying tissues. With the standard approaches, we run short of surgical space and options very soon. Then comes the turn of destructive procedures. Our technique of choice is MTF with or without additional measures to improve chances of success. TCTCF is less commonly employed. The surgery might succeed on the very first attempt or after many attempts. There always remains a chance of successfully doing another atraumatic filtration operation.

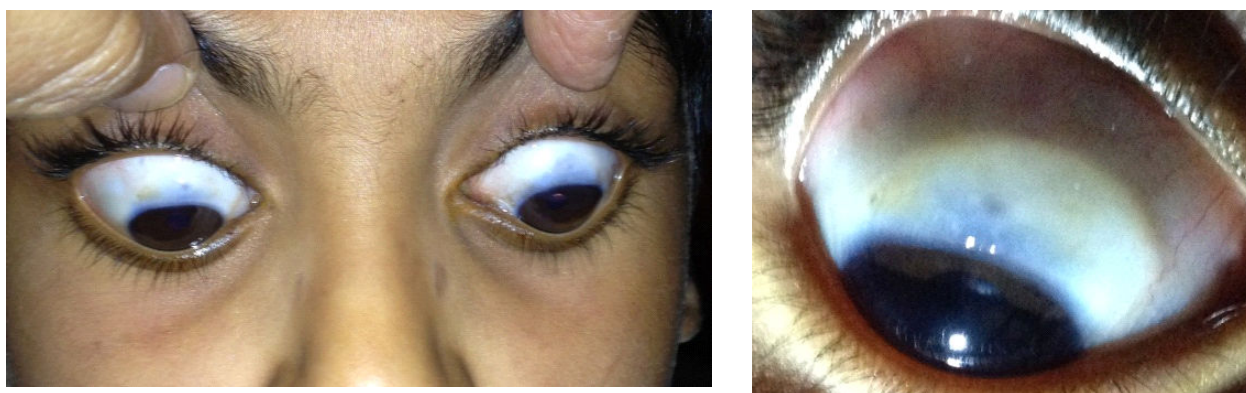

Figure 24. A ten year old buphthalmos child who had MTF 5 years before. The surgery was successful on the very first attempt. In both eyes IOP is 12 mm without medication. MMC 0.01 was used to balloon the conjunctiva at the beginning of surgery. There was a wait period of 4 minutes, before MTF was done.

A few films on MTF in buphthalmos are here:

MTF for buphthalmos, Healaflow put under the conjunctiva at the end:

<http://www.youtube.com/watch?v=glddXJmSOeg>

TCTCF in a case of pediatric glaucoma (patient 10 years old). Mitomycin injected under the conjunctiva at the end:

<http://www.youtube.com/watch?v=Xfe6ac659Xc>

Another MTF for buphthalmos:

http://www.youtube.com/watch?v=eziJ_8HIeMM

Micro-spherophakia and buphthalmos:

<http://www.youtube.com/watch?v=yM-raYTKdgc&feature=relmfu>

10.3. Pseudophakic pupil block glaucoma

Through one or more 0.7 mm pocket incisions in the cornea, Fugo blade 100 micron glaucoma tip is introduced and many iridotomies are done to completely overcome the pupillary block. This may be followed by MTF or TCTCF.

A few films on the topic are seen here:

<http://www.youtube.com/watch?v=etyBCd4pWoU>

<http://www.youtube.com/watch?v=CtgNZGwFOJU>

http://www.youtube.com/watch?v=8R_n729PWno

11. Concluding remarks

An estimated 80 million (and increasing by millions every year) cases of glaucoma patients worldwide are a challenge to the ingenuity of the surgeons and the producers of glaucoma medications and devices.

We have understood the presence and importance of lymphatics under the conjunctiva and in the adjoining tissues. We have tried to preserve the lymphatics by minimally invasive techniques of TCTCF and especially MTF. Besides new surgical innovations, we have also made use of newer viscoelastic and spongy materials in the hope of preserving the filtration tracks as well as saving the conjunctival lymphatics. Much work/research remains to be done before we and other workers in the field can declare a victory over the worldwide blinding epidemic of glaucoma. Needless to say, Fugo blade is helpful in making TCF and MTF tracks. As yet there is no other tool that can do the same.

Author details

Daljit Singh

Guru Nanak Dev University, Amritsar, India

References

- [1] Bethke WC. A New Clue to Lymphatic Drainage? Review of Ophthalmology. 2002; 9, 3
- [2] Dow T, Devenecia G. Transciliary Filtration (Singh Filtration) with the Fugo Plasma Blade. Ann Ophthalmol. 2008; 40,1; 8-14
- [3] Eisenstein P. World's Smallest Knives. Popular Mechanics. 2003; 180, 10; 56-8.

- [4] Fine IH, Hoffman RS, Packer M. Highlights of the 2002 ASCRS Symposium, Part I. Eyeworld. 2002;7,7:38
- [5] Fugo R. Regarding Transciliary Filtration. Tropical Ophthalmology. 2002; 2, 1; 7-8.
- [6] Fugo R. Transciliary Filtration Procedure Offers New Approach to Glaucoma. Ocular Surg News. 2005; 16,6; 18-19.
- [7] Fugo RJ. Trans-ciliary Filtration. Video Journal of Current Glaucoma Practices. Sept-Dec. 2007. Vol. 1, No. 2.
- [8] Fugo RJ. Plasma blade has several applications in ophthalmic surgery. Ocular Surg News. Dec 25, 2009
- [9] Guttman C. Anterior segment tool proves ideal for many applications. Ophthalmology Times. 2005;30,2;14,16.
- [10] Guttman C. Transciliary filtration provides improved safety and simplicity. Ophthalmology Times. 2005;30,3; 28.
- [11] Izak AM, Werner L, Pandey SK, Apple DJ, Izak MGJ. Analysis of the capsule edge after Fugo plasma blade capsulotomy, continuous curvilinear capsulorhexis, and can-opener capsulotomy. J Cataract Refract Surg. 2004;30, 12;2606-2611.
- [12] Kent C. Revealed: the Eye's Lymphatic System. Ophthalmic Manage. 2002; 6, 5: 114.
- [13] McGrath, D. Fugo Blade effective tool for multiple surgical applications. Eurotimes. 2008; 13, 6:43.
- [14] Peponis V, Rosenberg P, Reddy SV, Herz JB, Kaufman HE. The Use of the Fugo Blade in Corneal Surgery: A preliminary Animal Study. Cornea. 2006; 2: 206-8.
- [15] Pollack, I.P. (2000). Ocular Surgery News. Europe/Asia Pacific Edition, July 1, 2000.
- [16] Ronge L. How to Use the Fugo Blade. EyeNet. 2003; 7, 9; 23-4.
- [17] Roy, H., Singh, D., Fugo, R. Ocular Applications of Fugo Blade. (2010) Lippincott Williams and Wilkins, p. 77-126.
- [18] (Roy, S, Thi HD, Feusier M and Mermoud A (2012). Crosslinked sodium hyaluronate implant in deep sclerectomy for the surgical treatment of glaucoma. European Journal of ophthalmology, Vol 22, No. 2. pp 70-76 (2012).
- [19] Scimeca G. Phaco with Transciliary Filtration an Alternative to Triple Procedure. Ocular Surg News. 2005; 23,11; 58.
- [20] Singh D. Singh Micro-Filtration for Glaucoma; A New Technique. Tropical Ophthalmology. 2001; 1, 6: 7-11.
- [21] Singh D, Singh K. Transciliary Filtration Using the Fugo Blade. Ann Ophthalmol. 2002; 34,3; 183-87

- [22] Singh D. Letters: Conjunctival Lymphatic System. J Cataract Refract Surg. 2003; 29, 4; 632-3.
- [23] Singh D. Transciliary Filtration & Lymphatics of Conjunctiva- A Tale of Discovery. Tropical Ophthalmology. 2002; 2, 1; 9-13
- [24] Singh D, Singh RSJ, Singh K, Singh SK, Singh IR, Singh R, Fugo RJ. The Conjunctival Lymphatic System. Ann Ophthalmol. 2003;35, 2;99-
- [25] Singh D. Microtrack Filtration. Annals of Ophthalmology 2002;34,3;183-187
- [26] Trivedi RH, Wilson Jr. ME, Bartholomew LR. Extensibility and scanning electron microscopy evaluation of 5 pediatric anterior capsulotomy techniques in a porcine model. J Cataract Refract Surg. 2006; 32, 7:1206-13.
- [27] Winn CW. Broad applications seen for electrosurgical instrument. Ocular Surg News. 2001; 19, 11: 45-46
- [28] Yeni H et al. Identification of lymphatics in the ciliary body of the human eye: A novel "uveolymphatic" outflow pathway. Experimental Eye Research 89 (2009) 810–819

