

We are IntechOpen, the world's leading publisher of Open Access books Built by scientists, for scientists

6,900

Open access books available

185,000

International authors and editors

200M

Downloads

Our authors are among the

154

Countries delivered to

TOP 1%

most cited scientists

12.2%

Contributors from top 500 universities



WEB OF SCIENCE™

Selection of our books indexed in the Book Citation Index
in Web of Science™ Core Collection (BKCI)

Interested in publishing with us?
Contact book.department@intechopen.com

Numbers displayed above are based on latest data collected.
For more information visit www.intechopen.com



Aortic Aneurysm in Children and Adolescents

Cemşit Karakurt

Additional information is available at the end of the chapter

<http://dx.doi.org/10.5772/53383>

1. Introduction

Aortic aneurysm involves the aorta which is one of the large arteries through which blood passes from the heart to the rest of the body. Aortic aneurysm is a relatively common finding in the elderly patients because of aging, hypertension, or atherosclerosis, but it is rarely seen in childhood. In the adult population, the incidence of aortic aneurysm has been estimated to be 5.9 cases per 100000 person-years. However, there are no real data about the incidence of aortic aneurysm in childhood [1]. Aortic aneurysm is mostly seen in the ascending aorta, but it may also be seen in the descending aorta and /or aortic branches [2, 3]. Although it is rare, aortic aneurysm can be important cause of mortality in children and adolescents. Aortic aneurysm may be related to hereditary diseases (Marfan syndrome, Loeys –Dietz syndrome, Ehler-Danlos syndrome, Arterial Tortuosity Syndrome, Cutis laxa syndrome, Alagille syndrome, and Noonan Syndrome), or non genetic diseases (bicuspid aortic valve, coarctation of aorta, tetralogy of Fallot, and aortitis syndromes). In this review, causes, clinical findings, diagnostic methods, and treatment modalities of aortic aneurysm in children and adolescents have been discussed.

2. Genetic causes of aortic aneurysm

2.1. Marfan syndrome

Marfan syndrome, characterized by otosomal dominant inheritance, I was first described in 1986. The syndrome is due to more than 500 mutations in the fibrillin 1 gene on chromosome 15q21. Expression of the disease is variable and 30% of cases represent new mutation. Although cardiovascular manifestations are variable, the incidence (35-80%) of aortic root dilatation, mitral regurgitation in Marfan patients depends on the patient's age. In Marfan

syndrome, fibrillin-1 gene mutation leads to elastic fiber fragmentation and cystic medial necrosis. Fibrillin-1 is a matrix glycoprotein and a constituent of fibrils. Apart from structural abnormalities, a defective subventricular fibrillin leads to decreased distensibility, and increased aortic stiffness was showed in patients with Marfan syndrome. Excessive transforming growth factor β (TGF β) activity, defect in gene encoding TGF β receptor and complex interaction between the fibrillin, microfibrils, TGF β and its receptor have been proposed hypothesis of defective arterial wall matrix. Aortic dilatation may be related to arterial muscle cell apoptosis due to angiotensin-II receptor signalling pathways. Aortic stiffness has been showed to be an independent predictor for progressive aortic dilatation and dissection [4]. Beta blocker and ACE inhibitor therapy have been showed to decrease aortic stiffness and delay aortic surgery [5].

Clinical findings of Marfan syndrome are variable. Although most of the patients are diagnosed after 10 years, physical findings may be present at birth. The height of the patient increases. An arm span exceeds the height. Marfan patients have hypermobile joints, chest deformities, long and thin fingers, kyphoscoliosis, high palates, inguinal hernias, and dental abnormalities. Figure 1 shows long and thin fingers; figure 2 shows increased arm length and height in a Marfan syndrome patient. Ocular abnormalities such as lens subluxation, and/or myopia may be present in nearly 75% of the patients. Cardiovascular manifestation including aortic aneurysm, mitral valvar prolapse less severe in children than adults. Ghent nosology has been developed for diagnosis of Marfan syndrome in 1996. The 1996 Ghent criteria were adopted worldwide, but diagnostic criteria were revised in 2010, highlighting aortic root aneurysm and lens subluxation more [6, 7].

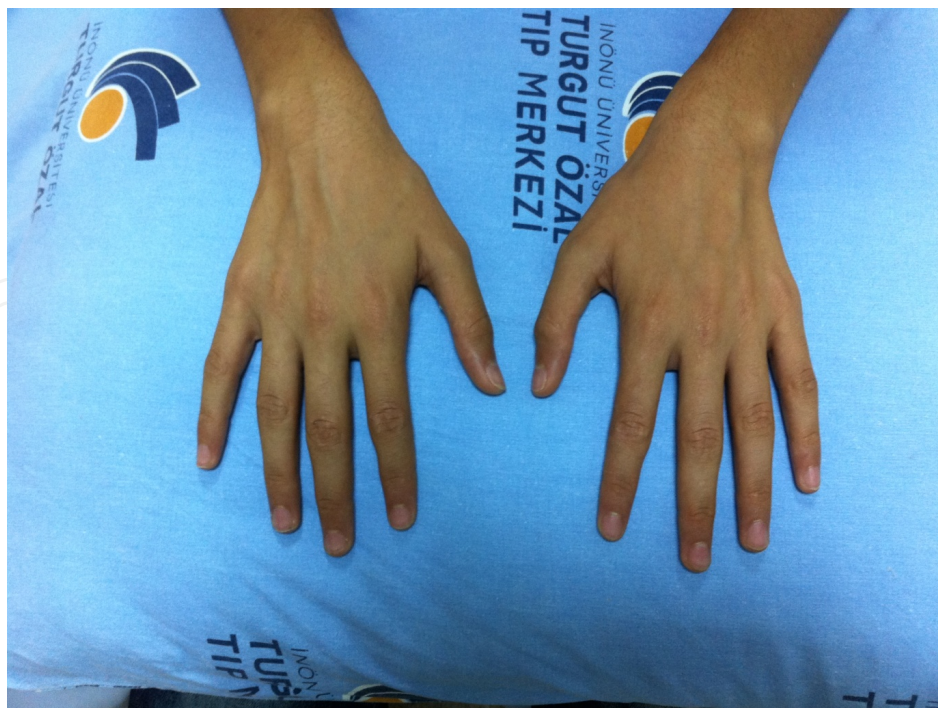

Figure 1. shows long and thin fingers in a 13-years-old patient with Marfan syndrome

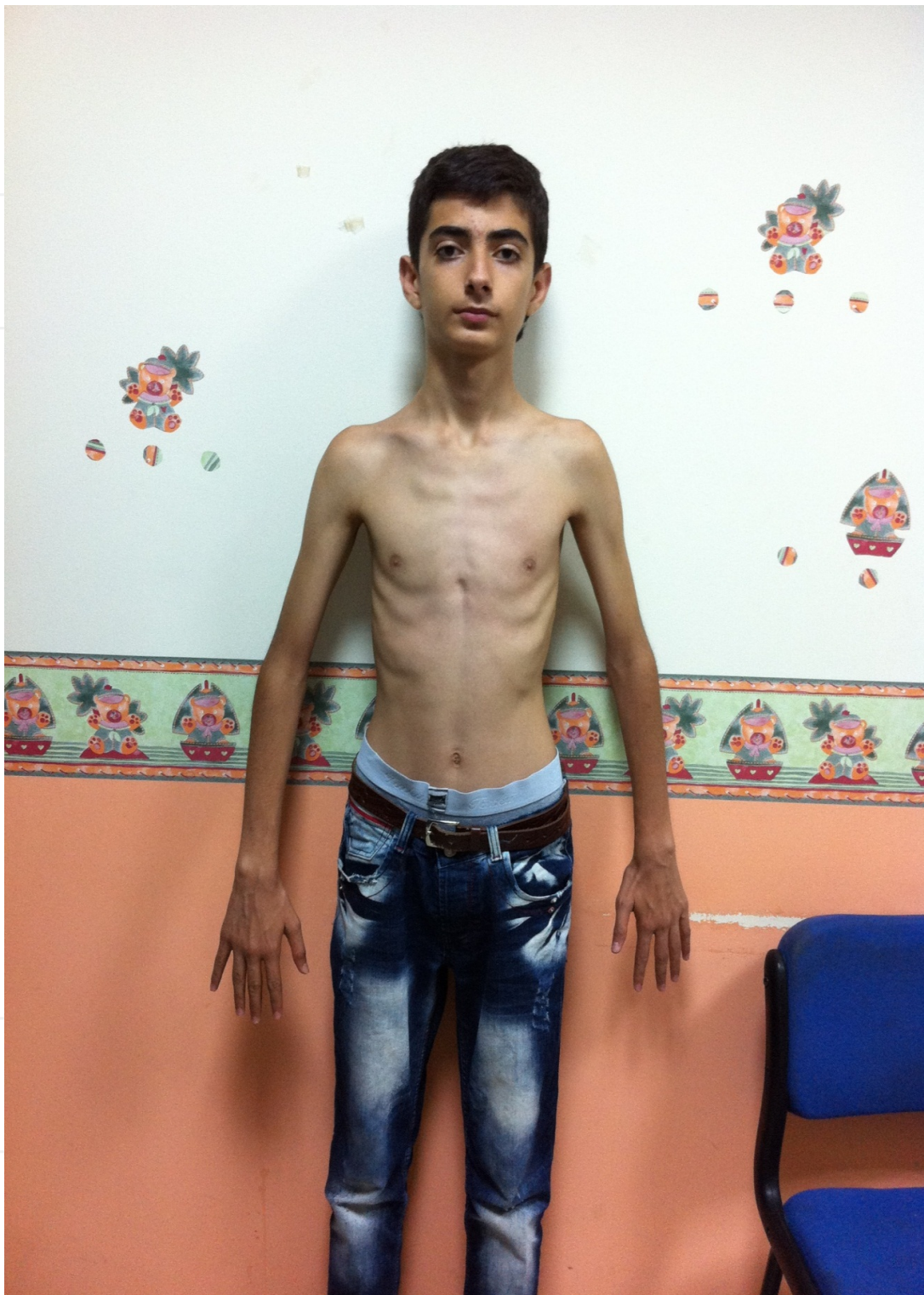

Figure 2. shows increased height and arm length in a 13-year-old patient with Marfan syndrome

According to Ghent's criteria, positive family history of Marfan syndrome (known fibrillin 1 mutation in the parent(s) or siblings), cardiac findings including aortic root dilatation, aortic dissection, and lumbosacral dural ectasia are the major criteria. Mitral valvar prolapse, cal-

cific mitral annulus (age < 40 years), other aortic dilatations or dissections (age < 50 years), spontaneous pneumothorax, apical blebs, skin abnormalities including recurrent or incisional hernias, and stria atrophicae are considered minor criteria. Recently, diagnostic criteria were revised nosology established for adult Marfan population [8, 9, 10].

Cardiovascular manifestations, especially aortic aneurysm and dissection, are the most common causes of mortality. Aortic aneurysms are usually located in the ascending aorta but it may also be located in the abdominal aorta or aortic branches [11, 12, 13]. Figure 3 and 4 show an aneurysm in the right renal artery and multiple aneurysm in the hepatic artery in a 16-year-old Marfan patient. Figure 5 shows intraoperative appearance of an aneurysm in the ascending aorta in an 18-year-old patient with Marfan syndrome.

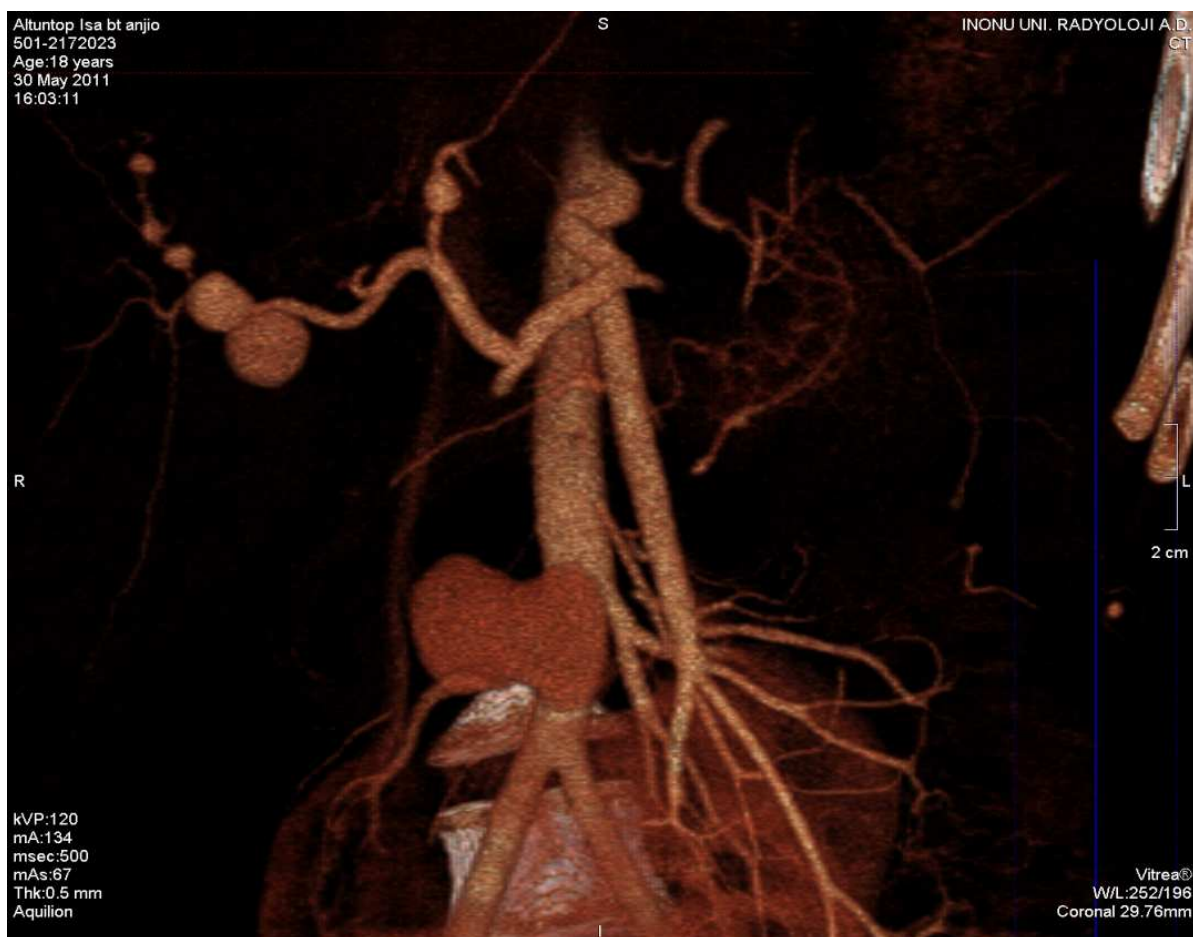


Figure 3. shows a large aneurysm in the right renal artery of a 16-year-old patient with Marfan syndrome

Elective root replacement should be seriously considered in any Marfan patient with significant root dilatation. Reoperation is required for half of Marfan syndrome patients [14]. Risk of sudden death or aortic dissection remains low in patients with Marfan syndrome and aortic diameter between 45-49 mm. Aortic diameter of 50 mm appears to be reasonable threshold for prophylactic surgery [15, 16].

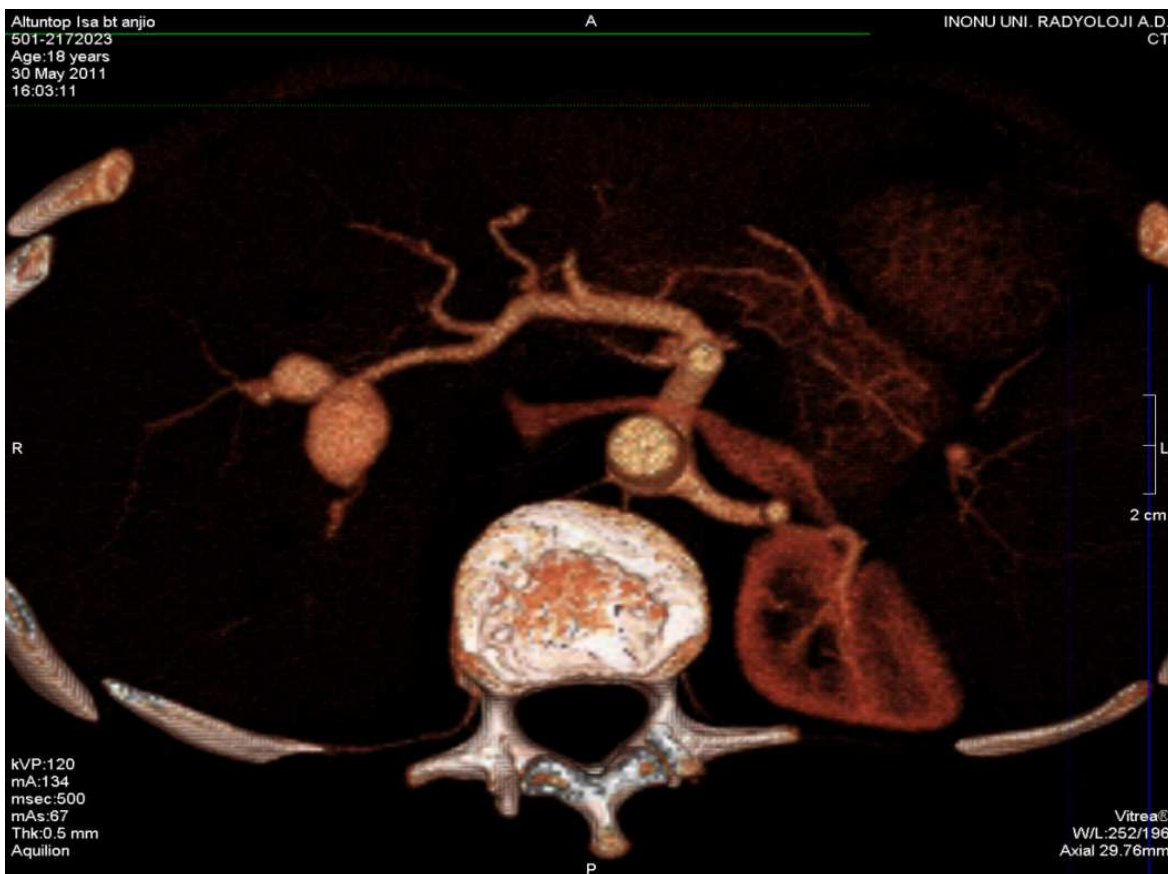

Figure 4. shows multiple aneurysms in the hepatic artery of a 16- year- old patient with Marfan syndrome

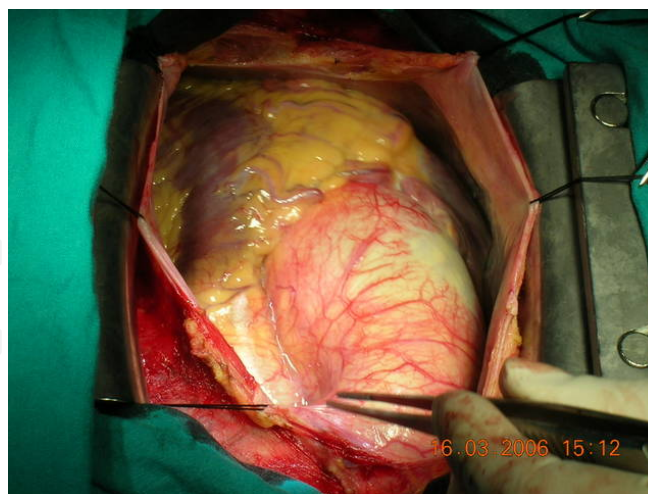

Figure 5. shows intraoperative appearance of the ascending aorta aneurysm in an 18- year-old patient with Marfan Syndrome (By courtesy of Prof Dr Nevzat Erdil)

The findings extend the mutation spectrum of Marfan syndrome, and that mutations at the F-helix in the kinase domain of TGFBR2 may be associated with the development of severe

cardiovascular and skeletal lesions and minor ocular disorders [17, 18]. For patients with Marfan syndrome, failed aortic surveillance and consequent emergency dissection repair have important long-term implications with regard to the status of distal aorta; they need multiple procedures for better quality of life. These findings emphasize the importance of aortic surveillance and timely elective aortic root aneurysm repair for patients with Marfan syndrome [19, 20]. Prophylactic propranolol treatment delays progression of aortic root dilatation. Because the pathogenetic role of angiotensin II receptor signaling pathway and TGF β in Marfan syndrome is clearly understood, angiotensin converting enzyme inhibitors should be started in patients with Marfan syndrome. Timing of surgery including aortic root surgery and/or valve replacement must be determined according to the risk and benefit of the surgery. Because annual mortality rate is 5% in patients with an aortic root greater than 50 cm, elective surgery must be performed before aortic root reaches 55 mm. For patients with a family history of aortic dissection and likelihood of pregnancy, elective surgery should be performed while the aortic root is in a smaller size. Upon diagnosis of Marfan syndrome, echocardiographic evaluation should be done, and beta blocker treatment and angiotensin converting enzyme inhibitors should be started after aortic root measurement. Patients with this syndrome should be followed up with echocardiograph periodically, and if it is necessary, with magnetic resonance imaging. Patients with Marfan syndrome who remain undiagnosed until adulthood are more likely to require surgical intervention. Early diagnosis of Marfan syndrome can improve the long-term outcome [21].

Infantile form of Marfan syndrome is a rare condition in which the ocular and skeletal abnormalities are similar to those in the adult form. Myxomatous changes of mitral and tricuspid valves and chordae with elongation of chordae tendineae are seen commonly in infantile form. Pulmonary emphysematous changes are also seen. Cardiovascular morbidity is commonly related to mitral and tricuspid valve disease rather than aortic aneurysm and dissection. Family history is rare and death commonly occurs in 2 years after diagnosis [22, 23].

2.2. Loeys-Dietz syndrome

Loeys-Dietz syndrome, which was first described in 2005, resembles Marfan syndrome, which is also inherited autosomal dominant, aortic aneurysm, and vascular pathology in Loeys-Dietz syndrome is more probable than in Marfan patients. It is caused by heterozygous mutations in the genes encoding type I and II transforming growth factor- β (TGFB1, TGFB2) and is characterized by hypertelorism, bifid uvula, cleft palate, arterial tortuosity, aneurysms of the ascending aorta, and dissection. Despite phenotypical resemblance, Loeys-Dietz syndrome can be differentiated from Marfan syndrome by palatal involvement and hypertelorism. Aneurysms may occur in young ages and lead to aortic dissection in Loeys-Dietz Syndrome. Elective surgery is recommended at an aortic root diameter of 40 mm. In Loeys-Dietz syndrome, defective microfibrils due to excessive activity of Transforming Growth Factor β activity lead to defective formation of matrix in the arterial wall and thus, aortic aneurysms [24, 25, 26].

Valve sparing operation of the aortic root is ideal in treating young patients with aortic root aneurysm with normal or minimally diseased aortic cusps to avoid the disadvantages of prosthetic valve replacements [27, 28].

Loeys-Dietz syndrome is an aggressive aortic aneurysm syndrome that can be addressed by prophylactic aortic root replacement with low operative risk. Valve-sparing procedures have encouraging early and midterm results, similar to Marfan syndrome, and are an attractive option for young patients [29, 30, 31].

2.3. Ehler-Danlos syndrome

The other genetic cause of aortic aneurysm is Ehler-Danlos syndrome. Ehler-Danlos syndrome is a genetically heterogeneous disorder of collagen and extracellular matrix and it is characterized by abnormal collagens. Although more than 10 subtypes have been described, 90% of patients with Ehler –Danlos Syndrome encompass six subtypes. Hyper extensibility of joints and skin, distinctive facial appearance, easy bruising, poor healing of wounds, smooth and rubbery palm and soles, blue sclera, epicanthal folds, lens subluxation, poor muscle tone are clinical findings of Ehler-Danlos. Premature death can occur in the most severe forms due to poor muscle tones. Cardiovascular findings are seen in subtype IV. In Ehler Danlos type IV collagen type III α -1 gene mutation leads to abnormal type III collagen in the vascular wall, skin and other organs. These patients carry aortic dissection risk and it does commonly occur after the 3rd decade. Aortic aneurysm can be seen in Ehler-Danlos type IV patients, but dissection is a rare condition in these patients [32, 33, 34, 35].

2.4. Arterial tortuosity syndrome

Arterial tortuosity syndrome is an autosomal recessive disorder characterized by tortuosity of the aorta and its major branches due to SLC2A10 genes that encodes for the glucose transporter GLUT10. Coucke et al reported location of the arterial tortuosity syndrome locus to 20q13 to a 1.2 Mb region containing 7 genes. Aortic aneurysms can also be seen in Arterial tortuosity syndrome patients [36, 37, 38].

2.5. Turner syndrome

Turner syndrome is an aneuploidy syndrome [45, XO) characterized by short stature, webbed neck, and infertility. Bicuspid aortic valve, coarctation of the aorta, aortic dilatation, pseudo-coarctation, aortic aneurysm, and dissection are common in Turner patients. Histological evidence of cystic medial necrosis has been reported in Turner syndrome. The prevalence of aortic dilation and aneurysm is lower in the young girls and women with Turner syndrome than in older Turner syndrome population [39, 40].

2.6. Noonan syndrome

Noonan syndrome is characterized by hypertelorism, a downward eyeslant, and low-set posterior rotated ears, short stature, short neck with webbing, cardiac anomalies, epicanthic folds, deafness, motor delay, and bleeding diathesis. Noonan syndrome is similar to Turner

syndrome but a genetically heterogeneous disease (PTPN11, RAS-MAPK mutations) characterized by dysplastic pulmonary valve, pulmonary stenosis [41,42]. Aortic aneurysm and dissection are rarely seen in Noonan syndrome [43].

2.7. Alagille syndrome

Alagille syndrome is an autosomal dominant syndrome that has been defined as paucity of intrahepatic bile ducts, cholestasis, cardiac disease, skeletal abnormalities, ocular abnormalities and characteristic facial appearance, ocular and renal abnormalities caused by heterozygous mutation in the Jagged -1 gene on chromosome 20p12. Another form of Alagille syndrome is caused by mutation in the NOTCH2 gene. Basillary artery aneurysm, middle cerebral artery aneurysm, aortic coarctation and aortic aneurysms have been reported in Alagille patients [44, 45, 46].

2.8. Cutis laxa

Cutis laxa is rare genetically heterogeneous disorder characterized by loose, sagging disease from early age. Autosomal dominant and recessive forms of cutis laxa have been described. In patients with cutis laxa, skin is loose and appears to be larger for the body [47]. Cutis laxa phenotypically resembles Ehler –Danlos syndrome due to hypermobile joints, fragility of skin, and easy bruising. However, the skin slowly recoils after it is stretched. Inguinal hernias and rectal prolapses may be seen [48]. Pulmonary stenosis, pulmonary emphysema, cor pulmonale, mitral regurgitation, dysplastic valvar disease and aortic aneurysm have also been reported in cutis laxa syndrome.

Fibulin-4 is a member of the fibulin family, a group of extracellular matrix proteins predominantly expressed in medial layers of large veins and arteries. Fibulin-4 deficiency has been showed in autosomal recessive cutis laxa patients [49].

2.9. Aneurysms-osteoarthritis syndrome

Aneurysms-osteoarthritis syndrome (AOS) is a new autosomal dominant syndromic form of thoracic aortic aneurysms and dissections caused by mutations SMAD3 gene, characterized by the presence of arterial aneurysms and tortuosity, mild skeletal, craniofacial and cutaneous anomalies, and early onset osteoarthritis [50]. Smooth muscle alpha-actin (ACTA2) mutations have been determined to be associated with aortic aneurysm and dissection in some families [51].

3. Non-genetic causes of aortic aneurysm

Non genetic causes of aortic aneurysm are bicuspid aorta, coarctation of aorta, aortitis syndromes, systemic hypertension, and vasculitis.

3.1. Bicuspid aortic valve

Congenitally bicuspid aortic valve is the most common congenital anomaly, with a prevalence of 0.5 to 2 in 100 individuals. A bicuspid aortic valve with a fused commissure and an eccentric orifice accounts for the most common form of aortic stenosis. Bicuspid aortic valve patients have also variable degrees of aortic insufficiency and aortic aneurysm in addition to aortic stenosis (figure 6). Cystic medial necrosis has been reported in the aortic wall. Thereby, aortic aneurysm may lead to aortic dissection [52, 53]. Hope et al determined that four-dimensional flow MR imaging showed helical systolic flow in the ascending aorta of patients with bicuspid aortic, including those without aneurysm or aortic stenosis. They stated that identification and characterization of eccentric flow jets in these patients may help identify those at risk for development of ascending aortic aneurysm [54].

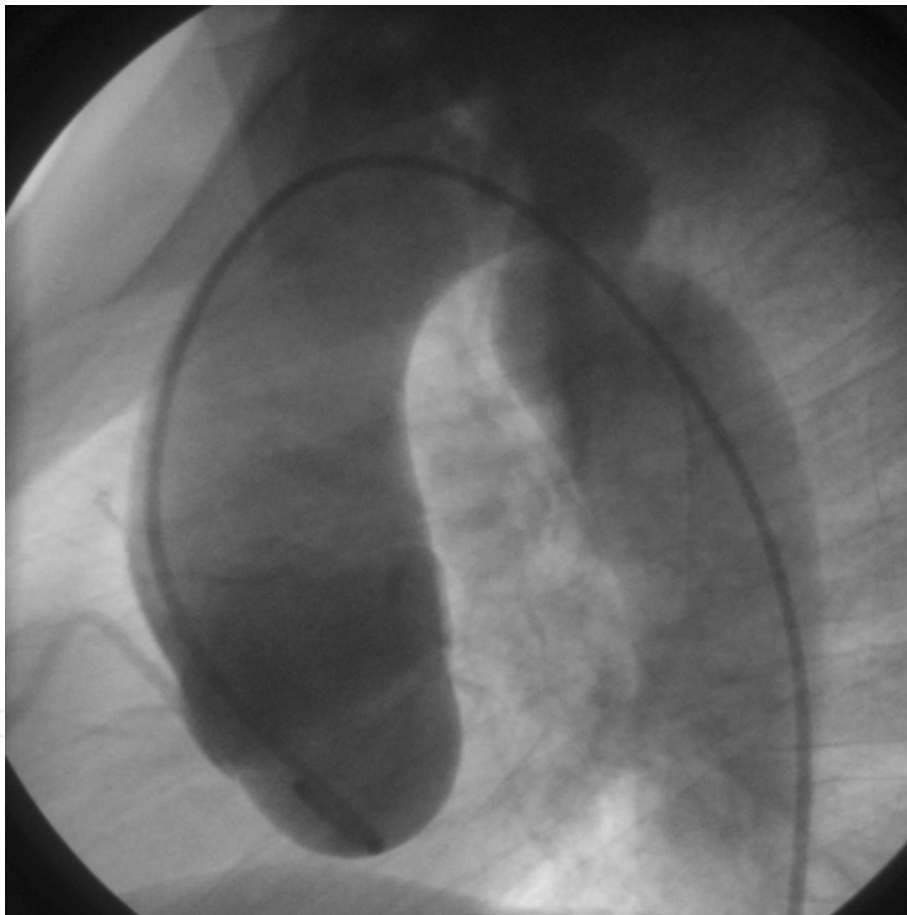


Figure 6. shows aneurysm of the ascending aorta secondary to bicuspid aortic valve and pseudocoarctation in a 13-year-old patient.

3.2. Coarctation of aorta

Coarctation of aorta occurs in 8% to 10% of all congenital heart defects. As many as 85% of patients with aortic coarctation patients have a bicuspid aortic valve. Aortic aneurysm can

be seen in untreated coarctation of aorta patients, after balloon dilatation and after surgical treatment or infective endocarditis. Aneurysm formation at the site of the dilatation with balloon angioplasty markedly in different series, but in generally rare. In the earlier era of balloon angioplasty, the incidence of aneurysm was high due to over dilatation with balloon catheter but recent series showed that aneurysm incidence decreased after balloon angioplasty. The pathology in the aneurysms that were operated was tears through the intima and media of the aorta. Aneurysm of the aorta is rare but can be seen after surgical repair especially with patch aortoplasty. When discrete aneurysm was determined after surgical repair or balloon angioplasty, it should be followed closely with CT, MRI, or angiographic imaging. A discrete aneurysm can be treated by using a covered stent [55]. Aortic aneurysms are less reported but may be rarely seen after bare stent implantation [56]. Aortic aneurysm formation complicating aortic coarctation carries a risk of rupture with high mortality. Covered stents are a safe and effective treatment with low risk of complications for the treatment of coarctation associated with aortic wall aneurysm [57, 58, 59].

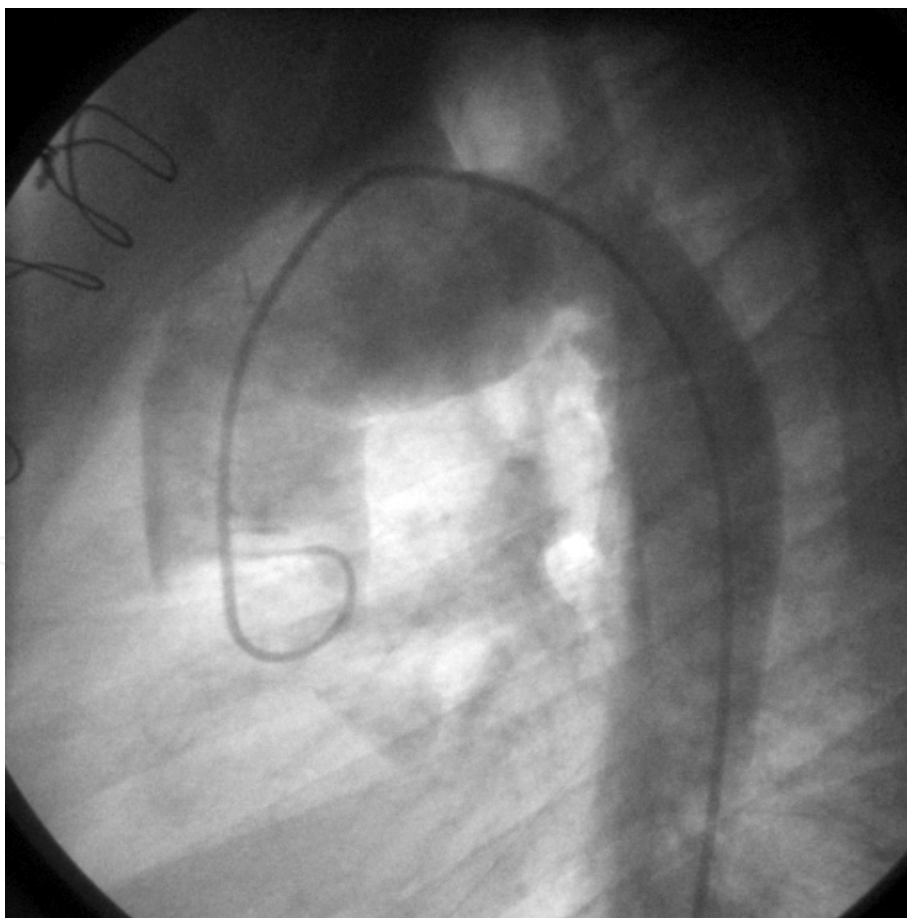


Figure 7. shows aortic aneurysm in a 14-year-old patient with operated tetralogy of Fallot.

3.3. Tetralogy of Fallot

Tetralogy of Fallot occurs in 10 % of all congenital heart defects. Although tetralogy of Fallot include ventricular septal defect, overriding of aorta, and right ventricular outflow tract obstruction, it can present with a pulmonary atresia, absent pulmonary valve. Tetralogy of Fallot patients also have variable degrees of aortic dilatation; it sometimes leads to aortic aneurysm and dissection due to volume overload, abnormalities of tunica media, elastic fibers and collagen in the aortic wall [60]. Histological abnormalities of aortic wall characterized by medial necrosis, fibrosis, and elastic fragmentation of the aortic root and ascending aorta lead to subsequent aortic root dilatation and aneurysm in patients with tetralogy of Fallot [61]. Aortic aneurysm has also been described after aortic arch repair [62].

3.4. Aortitis syndromes

Aortic aneurysm can be seen in aortitis syndromes related to syphilis, inflammatory bowel disease, and vasculitic syndromes. The primary systemic vasculitis is a group of autoimmune conditions characterized by occlusion, stenosis or aneurysmal dilations secondary to inflammation [63, 64, 65]. Aortic aneurysm may also be related to infective endocarditis (figure 8) or septicemia [66, 67, 68, 69, 70, 71].

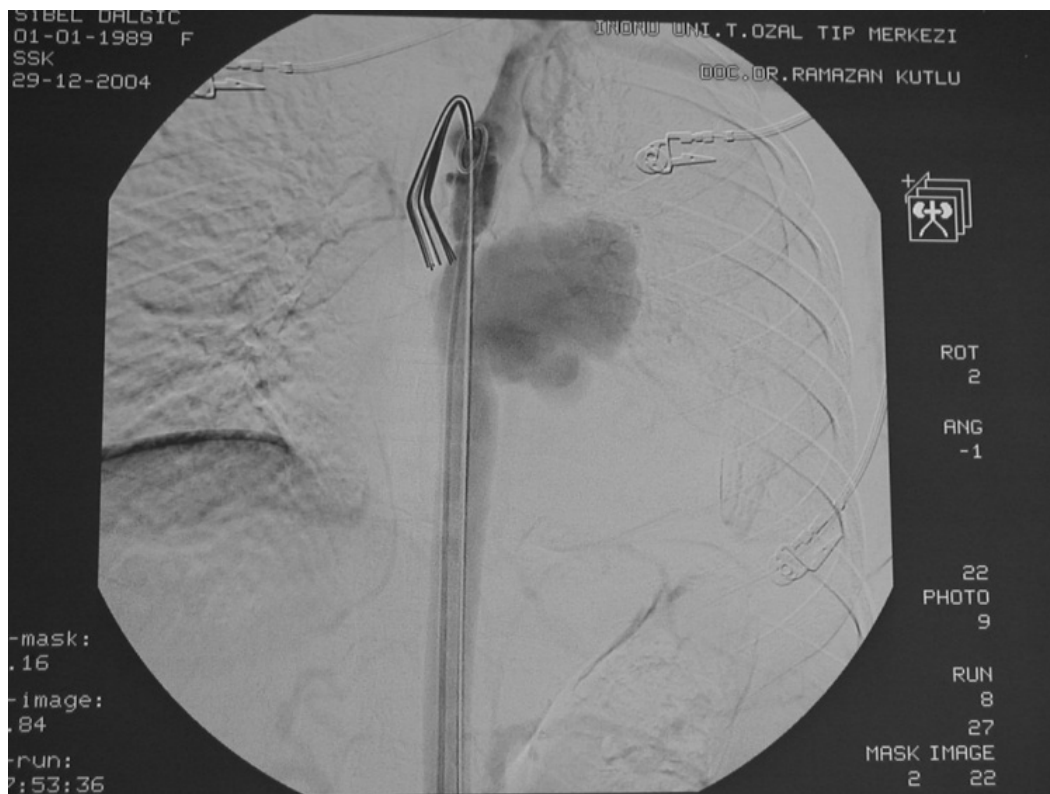

Figure 8. shows mycotic aneurysm at the postcoarctation area in a 16-year-old patient with coarctation of the aorta and infective endocarditis.

Aortic aneurysm has also been rarely described with Wiskott-Aldrich syndrome but real cause is not known [72].

3.5. Homosystinuria

Homosystinuria is an autosomal recessive metabolic disorder due to deficiency of cystathionin synthase which phenotypically resembles Marfan syndrome. Major cardiovascular complication of homosystinuria is premature atherosclerotic changes in the vascular system. Vitamin B6 and folic acid treatment helps reduce homocystein levels [73, 74].

4. Clinical presentation and diagnosis

Clinical presentation of aortic aneurysm depends on underlying disease, size, and location of aneurysm as well as presence of aortic dissection. Patients with aortic aneurysm related to genetic cause have specific phenotypical appearance such as having hypermobile joints, chest deformities, long and thin fingers, kyphoscoliosis, high palate, inguinal hernias, and/or arachnodactylia (Figure 1, 2). If patients have Marfan like appearance, family history should be sought. Decreased femoral pulsus, systolic ejection murmur in the aortic area can be detected during cardiac examination in patients with aortic aneurysm related to coarctation of the aorta or bicuspid aortic valve. Diastolic murmur can be heard secondary to aortic insufficiency or apical pansystolic murmur can be heard secondary to mitral valve insufficiency related to mitral valve prolapse. It is important to evaluate aortic dissection if presence of sharp chest and abdominal pain in patients who have aortic aneurysm.

Transthoracic and transesophageal echocardiographic evaluation is the first step evaluation for the aortic aneurysm. On transthoracic echocardiography, proximal ascending, thoracic aorta and proximal abdominal aorta can be visualized by using parasternal long axis, suprasternal views, and subcostal views. Echocardiographic evaluation can show mitral valve prolapse, aortic aneurysm, left ventricular and/or left atrial enlargement secondary to the mitral valve or aortic insufficiency, bicuspid aortic valve or coarctation of the aorta. 2D and colour-coded echocardiographic pictures from the parasternal long axis and apical four chamber view show mild aortic enlargement at the sinotubular junction, mitral valve prolapsus and mitral insufficiency in a 13-year-old patient with Marfan syndrome (figures 9, 10, 11, 12). Aortic aneurysm patients are also evaluated by transesophageal echocardiography.

The other imaging modalities are cardiac catheterization, magnetic resonance imaging and computed tomography (figure 3, 4, 6, 7, 8). With the increasing availability of whole body imaging, the role of magnetic resonance imaging and multidetector computed tomography are increasing diagnostic modalities in patients with aortic aneurysm/dissection [75, 76, 77, 78].

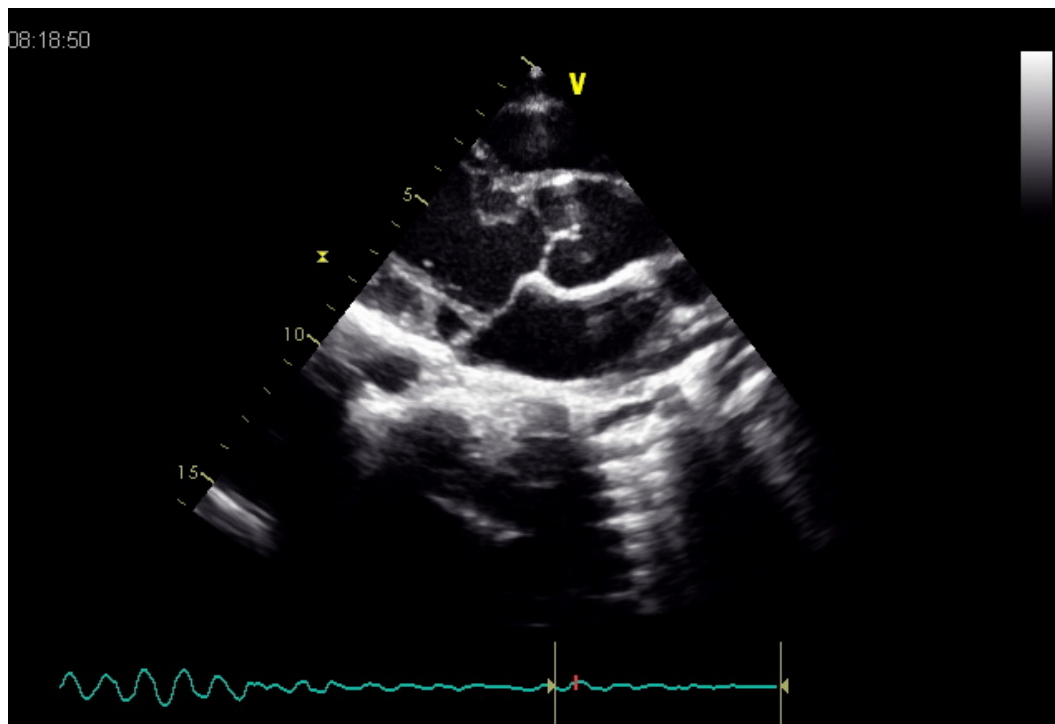


Figure 9. Long axis echo picture shows mild sinotubular junction in a 13-year-old patient with Marfan syndrome

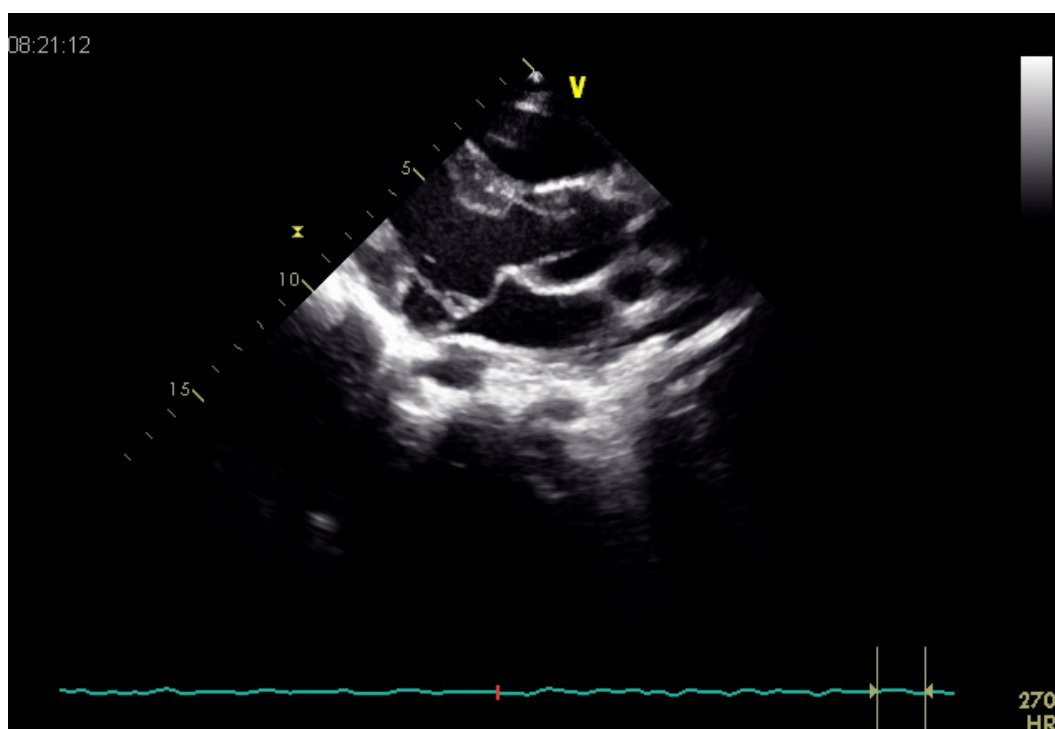


Figure 10. Long axis echo picture shows mitral valve prolapse in a 13-year-old patient with Marfan syndrome

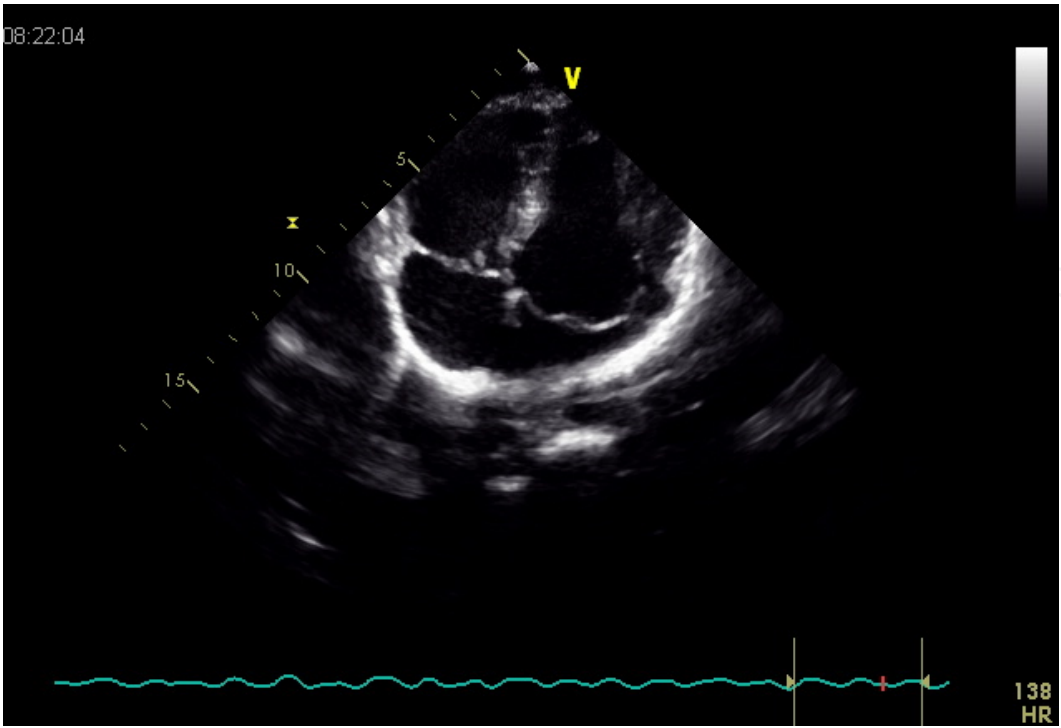


Figure 11. Apical four chamber echo picture shows mitral valve prolapse in a 13-year-old patient with Marfan syndrome

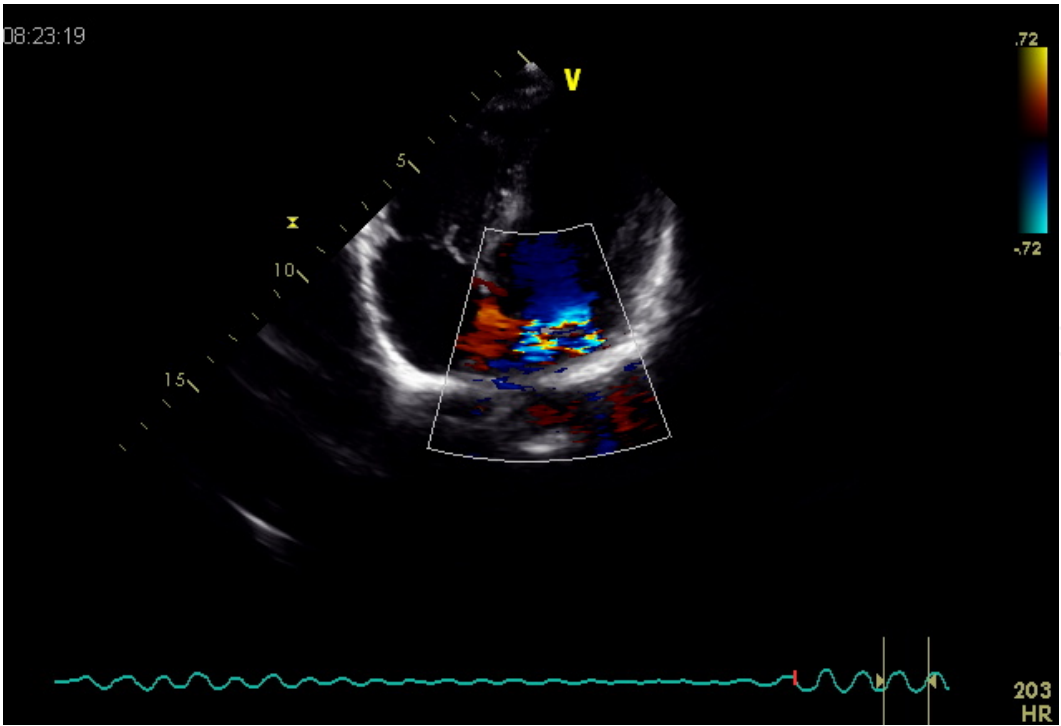


Figure 12. Apical four chamber echo picture shows mitral insufficiency secondary to mitral valve prolapse in a 13-year-old patient with Marfan syndrome

5. Treatment

Treatment of the cell cultures with dexamethasone induced remarkable up-regulation in the expression of tropoelastin, fibulin 1 and fibulin 4 encoding mRNAs, leading to normalization of elastic fiber production in fibroblasts with TGF β -R1 mutations [78].

Among children who have aortic aneurysm, timing of surgical treatment should be weighed against life expectancy, underlying disease, the size and location of aneurysm and presence of dissection. It has been showed that beta blocker and ACE inhibitor therapy delay aortic surgery in patients with aortic aneurysm related Marfan syndrome.

The indications of surgical treatment are aortic size over 5 cm, aneurysm growth rate exceeding 1 cm per year, progressive aortic insufficiency, and familial history of early aortic dissection for most of aortic aneurysm patients. However, since the risk of dissection is higher in Loeyz-Dietz syndrome, surgery is indicated even at lower diameters of the aorta.

In conclusion, aortic aneurysm is a rare but a lifethreatening condition in childhood. It is generally related to genetic hereditary syndromes. The patients who have predisposition to aortic aneurysm should be followed-up closely.

Author details

Cemşit Karakurt

Inonu University Faculty of Medicine, Department of Pediatric Cardiology, Malatya, Turkey

References

- [1] Bickerstaff. LK, Pairolero PC, Hollier LH, et al. Thoracic aortic aneurysms: a population- based study. *Surgery*. 1982; 92: 1103-8.
- [2] Ye C, Yin H, Lin Y, Zhou L, Ye R, Li X, Han A, Wang S. Abdominal aorta aneurysms in children: a single -center experience of six patients. *Ann Thorac Surg*.2012; 93(1): 201-5.
- [3] Mukkannavar SB, Choudhary SK, Talwar S, Makhija N, Gulati GS, Kabra SK. Aneurysmal circumflex aortic arch. *J Card Surg*. 2011; 26(5):515-8.
- [4] Baumgartner D, Baumgartner C, Matyas G, Steinmann B, Löffler-Ragg J, Schermer E, Schweigmann U, Baldissera I, Frischhut B. Diagnostic power of aortic elastic properties in young patients with Marfan syndrome. *J Thorac Cardiovasc Surg*. 2005;129(4): 730-9.
- [5] Ramirez F, Dietz HC. Marfan syndrome: From molecular pathogenesis to clinical treatment. *Curr Opin Genet Dev*. 2007; 17(3):252-8.

- [6] De Paepe A, Devereux RB, Dietz HC, Hennekam RC, Pyeritz RE. *Am J Med Genet.* 1996; 62(4):417-26.
- [7] Faivre L, Collod-Beroud G, Ades L, Arbustini E et al: The new Ghent criteria for Marfan syndrome: what do they change? *Clin Genet.* 2012; 81(5):433-42.
- [8] Radonic T, de Witte P, Groenink M et al. Critical appraisal of revised Ghent criteria for diagnosis of Marfan syndrome. *Clin Genet.* 2011 doi 10.1111/j.1399-0004.2011.01646.4).
- [9] Loeys BL, Dietz HC, Braverman AC, Callewaert BL, De Backer J, Devereux RB, Hilhorst-Hofstee Y, Jondeau G, Faivre L, Milewicz DM, Pyeritz RE, Sponseller PD, Wordsworth P, de Paepe AM: The revised Ghent nosology for the Marfan syndrome. *J Med Genet.* 2010; 47(7):476-85.
- [10] Lachhab A, Doghmi N, Ouenzar M, Bennani R, Amri R, Cherti M. Cardiovascular manifestations of Marfan syndrome. *Presse Med.* 2012; 41(3Pt1):328-30). Myers PO, Aggoun Y, Tissot C.
- [11] Myers PO, Aggoun Y, Tissot C. Giant aortic root aneurysm in Marfan syndrome: a rare complication in early childhood. *J Thorac Cardiovasc Surg.* 2011; 141(1):293-4.
- [12] Ozdemir O, Olgunturk R, Kula S, Tunaoglu FS. Echocardiographic findings in children with Marfan syndrome. *Cardiovasc J Afr.* 2011; 22(5):245-8.
- [13] Espinola-Zavaleta N, Iqbal FM, Nanda NC, Enrique-Rodriguez E, Amezcua-Guerra LM, Bojalil-Parra R, Reyes PA, Soto ME. Echocardiographic study of a Mestizo-Mexican population with Marfan syndrome. *Echocardiography.* 2010; 27(8):923-30.
- [14] Geisbuesch S, Schray D, Bischoff MS, Lin HM, Di Luozzo G, Griep RB. Frequency of reoperations in patients with Marfan syndrome. *Ann Thorac Surg.* 2012; 93(5):1496-501.
- [15] Jondeau G, Detaind D, Tubach F et al. Aortic event rate in Marfan population: a cohort study. *Circulation.* 2012; 125(2):226-32.
- [16] Miyahara Y, Kasahara S, Takagaki M, Sano S. Successful aortic reimplantation in a three-year-old child with Marfan syndrome. *Interact Cardiovasc Thorac Surg.* 2010; 11(2):218-20.
- [17] Dietz HC. TGF-beta in the pathogenesis and prevention of disease: A matter of aneurysmic proportions. *J Clin Invest.* 2010; 120(2):403-7.
- [18] Zhang L, Gao LG, Zhang M, Zhou XL. Genotype-phenotype analysis of F-helix mutations at the kinase domain of TGFBR2, including a type 2 Marfan syndrome familial study. *Mol Vis* 2012; 18:55-63.
- [19] Song HK, Kindem M, Bavaria JE, Dietz HC et al. Long term implications of emergency versus elective proximal aortic surgery in patients with Marfan syndrome in the genetically triggered thoracic aortic aneurysms and cardiovascular conditions consortium registry. *J Thorac Cardiovasc Surg.* 2012; 143(2):282-6.

- [20] David TE, Maganti M, Armstrong S. Aortic root aneurysm: Principles of repair and long term follow-up. *J Thorac Cardiovasc Surg.*2010; 140(6):S14-9.
- [21] Willis L, Roosvelet GE, Yetman AT. Comparison of clinical characteristics and frequency of adverse outcomes in patients with Marfan syndrome diagnosed in adulthood versus childhood. *Pediatr Cardiol.* 2009; 30(3):289-92.
- [22] Pernot C, Worms AM, Marçon F, Menard O, Nassi C, Floquet J. Malignant quadri-valvular dysplasia of Marfan syndrome in a neonate. *Arch Mal Coenur Vaiss.*1989; 82(5):797-801.
- [23] Abdel-Massih T, Goldenberg A, Vouhe P, Iserin F, Acar P, Villain E, Agnoletti G, Sidi D. Marfan syndrome in the newborn and infant less than 4 months: a series of 9 patients. *Arch Mal Coeur Vaiss.*2002; 95(5):462-72.
- [24] Yang JH, Ki CS, Han H, Song BG, Jang SY, Chung Ty, Sung K, Lee HJ, Kim DK. Clinical features and genetic analysis of Korean patients with Loeys-Dietz syndrome. *J Hum Genet.* 2012; 57(1):52-6.
- [25] Vida VL, Padalino MA, Motta R, Micciolo M, Cerutti A, Milanese O, Stellin G. Traumatic aortic dissection in a boy with Loeys-Dietz syndrome. *Ann Thorac Surg.* 2011; 92(4):1520-2.
- [26] Ha JS, Kim YH. A sporadic case of Loeys-Dietz syndrome type I with two novel mutations of theTGBR2 gene. *Korean J Pediatr.*2011; 54(6):272-5.
- [27] Ozker E, Vuran C, Saritas B, Türköz R. Valve-sparing replacement of the ascending aorta and aortic arch in a child with Loeys-Dietz syndrome. *Eur J Cardiothorac Surg.* 2012; 41(5):1184-5.
- [28] Valverde I, Simpson J, Beerbaum P. Magnetic resonance imaging findings in Loeys-Dietz syndrome. *Cardiol Young.*2010; 20(2):210-3.
- [29] Patel ND, Arnaotakis GJ, George TJ, Allen JG, Alejo DE, Dietz HC, Cameron DE, Vri-cellia LA. Valve sparing aortic root replacement in Loeys-Dietz syndrome. *Ann Thorac Surg.* 2011; 92(2):556-60.
- [30] Rodrigues VJ, Elsayed S, Loeys BL, Dietz HC, Yousem DM. Neuroradiologic manifestations of Loeys-Dietz syndrome type 1. *AJNR.*2009; 30(8):1614-9.
- [31] Everitt MD, Pinto N, Hawkins JA, Mitchell MB, Kouretas PC, Yetman AT. Cardiovascular surgery in children with Marfan syndrome or Loeys-Dietz syndrome. *J Thorac Cardiovasc Surg.*2009; 137(6):1327-32.
- [32] Beighton P, De Paepe A, Steinmann B, Tsipouras P, Wenstrup RJ. Ehlers-Danlos syndromes: revised nosology, Villefranche, 1997. *Am J Med Genet.*1998; 77:31-37.
- [33] Byers PH, Barsh GS, Holbrook KA. Molecular mechanism of connective tissue abnormalities in the Ehlers-Danlos syndrome. *Collagen Res.*1981; 5:475-489.

- [34] Germain DP, Herrera-Guzman Y. Vascular Ehlers-Danlos syndrome. *Ann Genet.* 2004; 47:1-9.
- [35] Kontusaari S, Tromp G, Kuivaniemi H, Romanic AM, Prockop DJ. A mutation in the gene for type III procollagen (COL3A1) in a family with aortic aneurysms. *J Clin Invest.* 1990; 86:1465-1473.
- [36] Coucke PJ, Willaert A, Wessels M et al. Mutations in the facilitative glucose transporter GLUT10 alters angiogenesis and cause arterial tortuosity syndrome. *Nature Genet.* 2006; 38:452-457.
- [37] Beuren AJ, Hort W, Kalbfleisch H, Muller H, Stoermer J. Dysplasia of the systemic and pulmonary arterial system with tortuosity and lengthening of the arteries: new entity, diagnosed during life, and leading to coronary death in early childhood. *Circulation.* 1969; 39:109-115.
- [38] Cine N, Basaran M, Guzelmeric F, Sunar H. Repair of ascending aortic aneurysm in a patient with arterial tortuosity syndrome. *Interact Cardiovasc Thorac Surg.* 2011; 12(6):1051-3.
- [39] Cleemann L, Mortensen KH, Holm K, Smedegaard H, Skouby SO, Wieslander SB, Leffers AM, Leth-Espensen P, Pedersen EM, Gravholt CH. Aortic dimensions in girls and young women with Turner syndrome: a magnetic resonance imaging study. *Pediatr Cardiol.* 2010; 31(4):497-504.
- [40] Prandstraller D, Mazzani L, Giardini A, Lovato L, Tamburrino F, Scarano E, Cicognani A, Fattori R, Picchio FM: Correlations of phenotype and genotype in relation to morphologic remodelling of the aortic root in patients with Turner's syndrome. *Cardiol Young;* 19(3)264-71.
- [41] Allonson JE. Noonan syndrome. *J Med Genet.* 1987; 24:9-13. Mendez HM, Opitz JM. Noonan syndrome: a review. *Am J Med Genet.* 1985; 21:493-506.
- [42] Mendez BR, Opitz JM. Noonan syndrome: a review. *Am J Med Genet.* 1985; 21:493-506.
- [43] Power PD, Lewin MB, Hannibal MC, Glass IA. Aortic root dilatation is a rare complication of Noonan syndrome. *Pediatr Cardiol.* 2006; 27(4):478-80.
- [44] Alagille D, Estrada A, Hadchouel M, Gautier M, Odihvre M, Dommergues JP. Syndromic paucity of interlobular bile ducts (Alagille syndrome or arteriohepatic dysplasia): review of 80 cases. *J Pediatr.* 1987; 110:195-200.
- [45] Boyer -Di Ponio J, Wright-Crosnier C, Groyer-Picard MT, Driancourt C, Beau I, Hadchouel M, Meunier-Rotival M. Biological function of mutant forms of JAGGED1 proteins in Alagille syndrome: inhibitory effect on Notch signalling. *Hum Molec Genet.* 2007; 16:2683-2692.
- [46] Kamath BM, Spinner NB, Emeric KM, Chudley AE, Booth C, Piccoli DA, Krantz ID. Vascular anomalies in Alagille syndrome. *Am J Med Genet.* 2002; 112:176-180.

- [47] Hutchagowder V, Sausgruber N, Kim KH, Angle B, Marmorstein LY, Urban Z. Fibulin-4: a novel gene for an autosomal recessive cutis laxa syndrome. *Am J Hum Genet.* 2006; 78:1075-10880.
- [48] Dasouki M, Markova D, Garola R, Sasaki T, Charbonneau NL, Sakai LY, Chu ML. Compound heterozygous mutations in fibulin-4 causing neonatal lethal pulmonary artery occlusion, aortic aneurysm, arachnodactyly and mild cutis laxa. *Am J Med Genet.* 2007; 143A:2635-2641.
- [49] Renard M, Holm T, Veith R, Callewaert BL, Ades LC, Pickart A, Dasouki M, Hoyer J, Rauch A, Trapane P, Earing MG, Coucke PJ, Sakai LY, Dietz HC, De Paepe AM, Loeys BL. Altered TGFbeta signalling and cardiovascular manifestations in patients with autosomal recessive cutis laxa type I caused fibulin-4 deficiency. *Eur J Hum Genet.* 2010; 18(8):895-901.
- [50] Van der Laar IM, Vand der Linde D, Oei EH et al. Phenotypic spectrum of the SMAD 3 related aneurysms-osteoarthritis syndrome. *J Med Genet.* 2012; 49(1):47-57.
- [51] Disabella E, Grasso M, Gambarin FI, Narula N, Dore R, Favalli V, Serio A, Antoniazzi E, Mosconi M, Pasotti M, Odero A, Arbustini E. Risk of dissection in thoracic aneurysm associated with mutations of smooth muscle alpha-actin 2 (ACTA2). *Heart.* 2011; 97(4):321-6.
- [52] Amazcua-Guerra L, Santiago C, Espinola-Zavaleta N, Pineda C. Bicuspid aortic valve: a synergistic factor for aortic dilation and dissection in Marfan syndrome. *Rev Invest Clin.* 2010; 62(1):39-43.
- [53] Binnetoglu K, Yildiz CE, Babaoğlu K, Altun G, Cetin G. Management of an ascending aortic aneurysm associated with a bicuspid aortic valve and a coarctation in an adolescent. *J Card Surg.* 2011; 26(6):635-7.
- [54] Hope MD, Hope TA, Meadows AK, Ordovas KG, Urbania TH, Alley MT, Higgins CB. Bicuspid aortic valve: a four dimensional MR evaluation of ascending aortic systolic flow patterns. *Radiology.* 2010; 255(1):53-61.
- [55] Yuan SM, Raanani E. Late complications of coarctation of the aorta. *Cardiol J.* 2008; 15(6):517-24.
- [56] Thanopoulos BD, Giannakoulas G, Giannaopoulos A, Galdo F, Tsaoussis GS. Initial and six-year results of stent implantation for aortic coarctation in children. *Am J Cardiol.* 2012; 109(10):1499-503.
- [57] Butera G, Heles M, MacDonald ST, Carminati M. Aortic coarctation complicated by wall aneurysm: the role of covered stents. *Catheter Cardiovasc Interv.* 2011; 78(6): 926-32.
- [58] Chakrabarti S, Kenny D, Morgan G, Curtis SL, Hamilton MC, Wilde P, Tometzki AJ, Turner MS, Martin RP. Balloon expandable stent implantation for native and recurrent coarctation of the aorta-prospective computed tomography assessment of stent integrity, aneurysm formation and stenosis relief. *Heart.* 2010; 96(15):1212-6.

- [59] Careage-Reyna G, Ramirez-Vargas AF, Hernandez-Magro RM, Arguero-Sanchez R. Thoracic aortic aneurysm associated with aortic coarctation without previous surgery: report of two cases. *Cir Cir*.2009;77(1):61-3.
- [60] Ramayya AS, Coelho R, Sivakumar K, Radhakrishnan S. Repair of tetralogy of Fallot with ascending and proximal aortic arch aneurysm: case report. *J Card Surg*.2011; 26(3):328-30.
- [61] Niwa K. Aortic root dilatation in tetralogy of Fallot long-term after repair-histology of the aorta in tetralogy of Fallot: evidence of intrinsic aortopathy. *Int J Cardiol*.2005; 103(2):117-9.
- [62] Ghosh A, Liu A, Mora B, Egarwala B. Giant aortic aneurysm after interrupted aortic arch repair. *Pediatr Cardiol*. 2010; 31(7):1104-6.
- [63] Mukhtyar C, Brogan P, Lugmani R. Cardiovascular involvement in primary systemic vasculitis. *Best Pract Res Clin Rheumatol*.2009; 23(3):419-28.
- [64] Bolin E, Moddie DS, Fraser CD Jr, Guirola R, Warren R, Eldin KW: Takayashu arteritis presenting as severe ascending aortic arch dilation and aortic regurgitation in a 10-year-old female. *Congenit Heart Dis*.2011; 6(6):630-3.
- [65] Karakurt C, Koçak G, Selimoğlu A, Özen M. Aortic aneurysm: a rare complication of ulcerative colitis. *Anadolu Kardiyol Derg*.2007; 7(4):461-2.
- [66] Lin Q, Min Y, Song XX, Ren Y, Ding YY, Xu QQ, Li XZ. Childhood staphylococcus aureus septicemia complicated by aortic aneurysm: a case report. *Zhongguo Dang Dai Er Ke Za Zhi*. 2011; 13(12):1005-6.
- [67] Andersen ND, Bhattacharya SD, Williams JB, McCann RL, Hughes GC. Mycotic aneurysm of thoracoabdominal aorta in a child with end-stage renal disease. *J Vasc Surg*.2011; 54(4):1161-3.
- [68] Zhu WH, Shen LG, Neubauer H. Clinical characteristics, interdisciplinary treatment and follow-up of 14 children with Takayasu arteritis. *World J Pediatr*.2010; 6(4):342-7.
- [69] Schwartzs SB, Fisher D, Reinus C, Shahroor S. Infectious aortitis: a rare cause of chest pain in a child. *Pediatr Emerg Care*. 2011; 27(7):654-6.
- [70] Erkut B, Becit N, Kantarci M, Ceviz N. Mycotic pseudo aneurysm of the ascending aorta following purulent pericardial effusion diagnosed by multi-slice computed tomography. *Cardiovasc J Afr*.2011; 22(3):143-4.
- [71] Haas B, Wilt HG, Carlson KM, Lofland GK. Streptococcus pneumoniae causing mycotic aneurysm in a pediatric patient with coarctation of the aorta. *Congenit Heart Dis*. 2012; 7(1):71-5.
- [72] Pellier I, Dupuis Girod S, Loisel D, Benabidahallah S, Proust A, Malhlaoui N, Picard C, Najioullah, de Saint Basile G, Blanche S, Rialland X, Casanova JL, Fischer A. Occurrence of aortic aneurysms in 5 cases of Wiskott-Aldrich syndrome. *Pediatrics*.2011; 127(2):e498-504.

- [73] Yap S, Boers GH, Wilcken B, Wilcken B, Wilcken DE, Brenton DP, Lee PJ, Walter JH, Howard PM, Naughten ER. Vascular outcome in patients with homocystinuria due to cystathionine beta-synthase deficiency treated chronically: a multicenter observational study. *Arterioscler Thromb Vasc Biol*; 21(12):2080-5.
- [74] Almgren B, Eriksson I, Hemmingsson A, Hillerdal G, Larsson E, Aberg H. *Acta Chir Scand*.1978;190(1):8-10.
- [75] Shon GH, Jang SY, Moon JR, Yang JH, Sung K, Ki CS, Oh JK, Choe YH, Kim DK. The usefulness of multidetector computed tomographic angiography for the diagnosis of Marfan syndrome by Ghent criteria. *Int J Cardiovasc Imaging*. 2011; 27(5):679-88.
- Suarez B, Caldera A, Castillo M. Imaging and clinical features in a child with Loeys-Dietz syndrome. A case report. *Interv Neuroradiol*. 2011; 17(1):9-11.
- [76] Garg SK, Mohan S, Kumar S. Diagnostic value of 3D contrast-enhanced magnetic resonance angiography in Takayasu's arteritis: a comparative with digital subtraction angiography. *Eur Radiol*.2011; 21(8):1658-66.
- [77] Tsai SF, Triverdi M, Boettner B, Daniels CJ. Usefulness of screening cardiovascular magnetic resonance imaging to detect abnormalities after repair of coarctation of the aorta. *Am J Cardiol*.2011; 107(2):297-301.
- [78] Barnett CP, Chitayat D, Bradley TJ, Wang Y, Hinek A. Dexamethasone normalizes aberrant elastic fiber production and collagen 1 secretion by Loeys-Dietz syndrome fibroblasts: a possible treatment? *Eur J Hum Genet*.2011; 19(6):624-33.

