

We are IntechOpen, the world's leading publisher of Open Access books Built by scientists, for scientists

6,900

Open access books available

186,000

International authors and editors

200M

Downloads

Our authors are among the

154

Countries delivered to

TOP 1%

most cited scientists

12.2%

Contributors from top 500 universities



WEB OF SCIENCE™

Selection of our books indexed in the Book Citation Index
in Web of Science™ Core Collection (BKCI)

Interested in publishing with us?
Contact book.department@intechopen.com

Numbers displayed above are based on latest data collected.
For more information visit www.intechopen.com



Invasive Fungal Infections in ALL Patients

Roman Crazzolaro, Adrian Kneer,
Bernhard Meister and Gabriele Kropshofer

Additional information is available at the end of the chapter

<http://dx.doi.org/10.5772/54990>

1. Introduction

The success rate of acute lymphoblastic leukemia (ALL) therapy has gradually increased over the past decades. With more than 80% long-term survivors, treatment of ALL in children is undoubtedly one of the great success stories of innovative study-controlled modern medicine [1]. Attempts to boost cure rates for those who do not respond to therapy or relapse with more intense chemotherapy including allogeneic hematopoietic stem cell transplantation have further improved the outcome of patients, particularly for prognostic unfavorable subgroups [2]. However, intensification of treatment can substantially increase morbidity, the risk for life-threatening sequelae and mortality [1].

Several studies address this important issue and report on the emergence of fungi. A retrospective review of ~ 5.600 patients who underwent hematopoietic stem cell transplantation at the Fred Hutchinson Cancer Research Center (Seattle) from 1985 to 1999 reports a constant increase of 3.5% in the one-year cumulative incidence of probable and proven invasive fungal infections [3]. Investigation of autopsies, skin, and lung biopsies, and bronchoalveolar lavage fluid analyses reveal that non-fumigatus *Aspergillus* species, such as *Fusarium* and *Zygomycetes* have increased, especially in patients, who have received multiple transplants. These observations are particularly worrisome given the increasing importance of amphotericin-B resistant organisms, resulting in a very poor one-year survival rate of ~ 20% [4]. For those who do survive, length of hospital stay and total hospital charges are increased, compared with immunocompromised patients without fungal infection [5].

Despite much effort has been taken to improve therapeutic treatments and strategies, there still remains much uncertainty and controversy regarding the best method to diagnose, prevent and treat fungal infections [6]. Practicing physicians approach this uncertainty by treating suspected infections empirically. However, researchers that conduct clinical trials tend

to accept only cases in which the diagnosis is certain in order to improve clarity and uniformity of clinical trials. Therefore, members of the European Organization for Research and Treatment of Cancer / Invasive Fungal Infection Study Group (EORTC) and the National Institute of Allergy and Infectious Disease (NIAID) Mycoses Study Group (MSG) formed a consensus study group to define standard definitions of invasive fungal infections for clinical research [7]. Practice guidelines are intended to limit practice variations towards movements such as evidence-based medicine and are primarily suggested by the European Conference of Infections in Leukemia (ECIL; <http://www.ebmt.org/Contents/Resources/Library/ECIL/Pages/ECIL.aspx>). For the clinical purpose there is still a need to develop more effective prevention and treatment strategies. Such strategies may rely on newer antifungal agents that are active against amphotericin B resistant moulds and are well tolerated. Because of limited number of affected patients, multicenter collaborative trials are required.

This case-based review examines the current literature to explore basic concepts on epidemiology, diagnosis and treatment of invasive fungal infections in ALL patients. A case report will be used to illustrate these specific issues.

2. Methods

A systematic review of the literature for an explicit identification of major problems related to the heterogeneity of patients with acute lymphoblastic leukemia who have invasive fungal infections was undertaken. *Pneumocystis* infections were not considered. In brief, the abstracts of 711 articles published from 1985 through 2012 were screened. Of these, 41 articles were finally selected because these report clinical research on patients with ALL who also had deep-tissue fungal infections. The minimum diagnostic criteria used to include patients in the study were extracted from definitions devised by the investigators. Likewise, the criteria used to express different degrees of diagnostic probability were summarized, as were the terms most often used to express these levels of uncertainty.

3. Case study: A sixteen-year old patient with Ph+ ALL

A sixteen-year old adolescent was referred to the outpatient oncologic clinic with suspicion of a proliferative disease of the hematopoietic system. Two weeks prior the admission, the patient suffered from sub febrile temperatures and fatigue. At the time of the visit to the general physician scarlet was ruled out and the patient discharged. At admission, the patient's general condition was slightly deteriorated; his physical examination revealed petechial rash over the extremities, pallor and hepatosplenomegaly. Laboratory findings showed ALL with a positive BCR/ABL result and an absolute count of 398.000 blasts per μL . He was subjected to treatment with the ALL BFM 2000 program for high-risk patients. He responded well to chemotherapy and achieved complete morphological remission on day ten of treatment. Following day fifteen, the tyrosine-kinase inhibitor Imatinib Mesylate was added to the standard treatment.

On the thirtieth day of induction chemotherapy the patient developed fever of 39.2°C. Physical examination was unremarkable. The laboratory tests showed leucopenia ($0.5 \times 10^9/L$) with an absolute neutrophilic count of $19/\mu L$, but no elevation of inflammatory proteins (CRP <0.06 mg/dL).

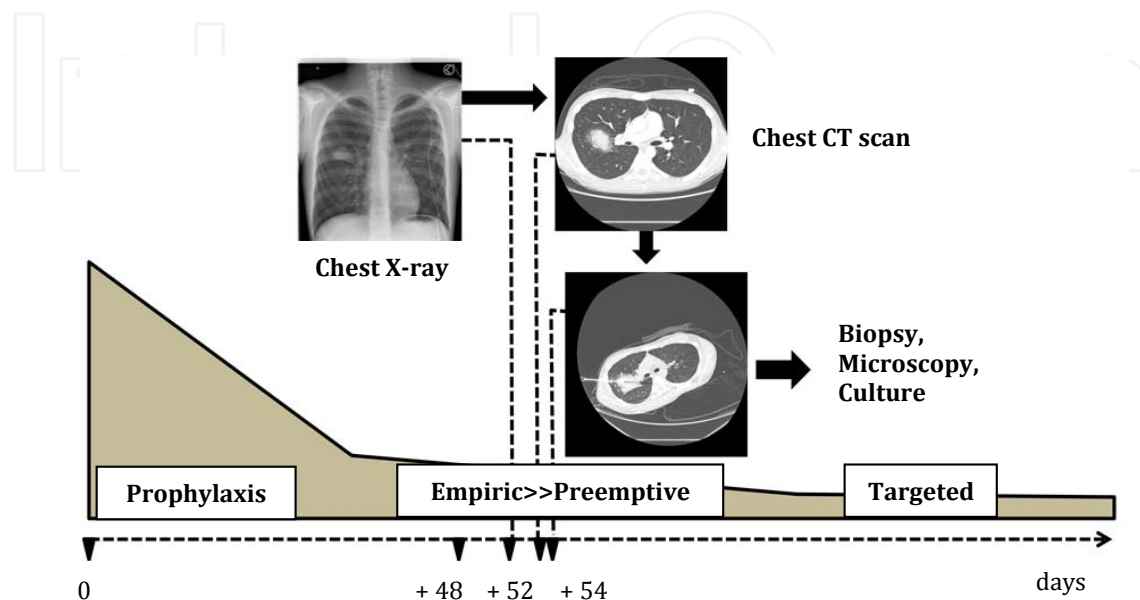


Figure 1. Time course of diagnosis and treatment of fungal infection in a Philadelphia chromosome-positive acute lymphoblastic leukemia (Ph+ALL) patient. Fungal infection was suspected by a chest X-ray on day thirty four of induction chemotherapy for Ph+ ALL. Prophylactic treatment with Fluconazole was switched to pre-emptive therapy with liposomal Amphotericin. Five days later histology of the fungal mass obtained by computed tomography (CT)-guided percutaneous biopsy confirmed the diagnosis of invasive mould infection. Culture revealed *Aspergillus flavus*, susceptible to Voriconazole.

Empirical antibiotic regimen was initiated with a carbapenem (Meropenem) and an aminoglycoside (Gentamycin). Because of relapsing fever four days after the initiation of antibiotics, vancomycin was added. Both blood and urine cultures were aseptic.

A chest X-ray showed a distinctive and peculiar mass in the middle of the right lung. Because the radiological image was ambiguous the diagnostics were extended by a chest CT scan, which showed a large mass in the right upper lobe, surrounded by a wide zone of ground-glass attenuation demonstrating the halo sign. On the ground of the radiologic examinations, fungal infection was suspicioned and pre-emptive antifungal therapy was initiated. Fluconazole, included in the treatment as a prophylactic measure, was replaced by liposomal Amphotericin administered at a dose of three mg/kg once daily. On the next day CT-guided biopsy was planned to obtain a definitive diagnosis. Biopsy was performed with only a single puncture using a 20 G cutting needle. No pneumothorax or hemorrhage was noted after the procedure. Histological examination yielded dichotomously branching septated hyphae consistent with *Aspergillus* species, confirming the diagnosis of invasive fungal infection. Culture demonstrated a growth of *Aspergillus flavus*. Antifungal susceptibility testing with

the agar-based MIC test showed good activity for Voriconazole, Posaconazole and Caspofungin, but high MIC⁹⁰ for liposomal Amphotericin.

Accordingly antifungal therapy was switched to Voriconazole (6 mg/kg) for eight weeks intravenously and then orally until the twelfth week. CT imaging studies that followed confirmed a gradual recession of the lesion. The patient underwent right sided thoracotomy with wedge resection of the fungal mass. Histopathology revealed Aspergilloma with surrounding chronic granulomatous inflammation, fibrosis and sheets of macrophages. Post-operative course was uneventful and no recurrence of fungal infection over twenty four months follow up was observed. He underwent allogeneic hematopoietic stem cell transplantation and has been in complete molecular remission since.

4. Epidemiology

Worldwide surveys evaluating the epidemiology of invasive fungal infections have been conducted in large center studies in North America [8]. In European countries data is most commonly derived from single-center reports or regional reports from single countries [8]. Though local epidemiology is a cornerstone of clinical decision making, efforts are now undertaken worldwide to start multi-national surveys on fungal infections in order to improve uniformity of clinical trials.

Until 2 decades ago, infections by *Candida* were the most common fungal pathogen in patients treated for ALL. However, with the introduction of Fluconazole as primary antifungal prophylaxis and the application of more aggressive treatment protocols, including allogeneic hematopoietic stem cell transplantation, a notable shift towards the advent of invasive aspergillosis has been noted [9]. Whereas almost all of the fungal infections were attributable to candidiasis (11/11) in autopsy studies of the late seventies, mould infections were responsible for 62% of IFIs (16/26) two decades later [9]. Concordantly, a large multi-centre report from the SEIFEM-2004 study (Sorveglianza Epidemiologica Infezioni Fungine nelle Emopatie Maligne) confirms this trend, indicating, that over half of all fungal infections (346/538) were caused by moulds, in most cases *Aspergillus* species (310/346) [10]. Most importantly, such infections have become a prime cause of death in patients with hematologic malignancies. The IFI-attributable mortality rate was 39% (209/538). The highest IFI-attributable mortality rates were associated with zygomycosis (64%) followed by fusariosis (53%), aspergillosis (42%), and candidemia (33%) [10].

Along with the increased incidence of mould infections caused by *Aspergillus* species, other emerging mould opportunistics, such as *Zygomycetes* and *Fusarium* species, have progressively been noted; interestingly, frequency varies by geographical location [8]. Another trend in changing the face of epidemiology is that infections caused by non-albicans *Candida* species (e.g. *Candida glabrata*, *C. krusei*, *C. tropicalis*, *C. parapsilosis*) have steadily increased, particularly in patients with ALL [11].

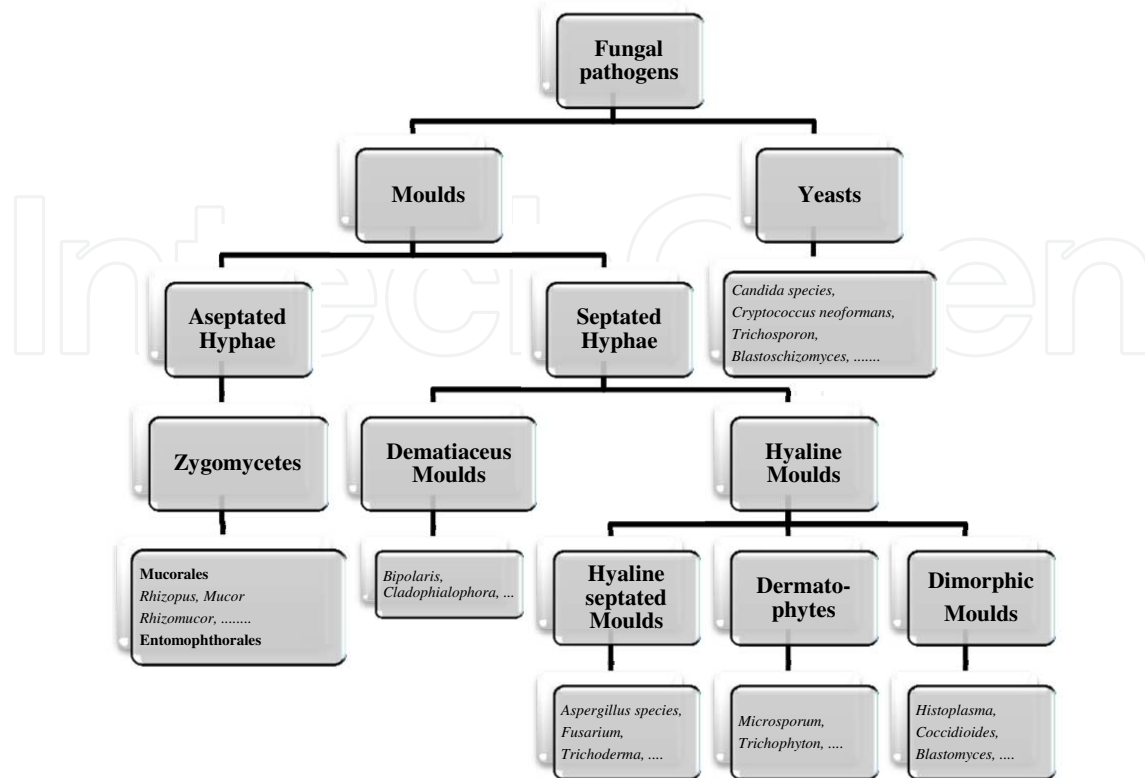


Figure 2. Pathogenic fungi that cause disease in acute lymphoblastic leukemia (ALL) Patients. A schematic classification depending on phylogenetic properties of fungal pathogens encountered in ALL patients is presented.

Yeast like pathogens enter the body via the gut or skin and mostly follow the pattern of fungemia and disseminated infection known from *Candida* species. Rarely the central nervous system, cardiovascular system or other tissues represent sites of dissemination [12].

Besides invasive infections of the skin and subcutaneous tissues, moulds involve, as airborne pathogens, the sino-pulmonary tract; the emerging opportunistic moulds have a higher propensity for dissemination, in particular into the central nervous system. Because of the lack of specific clinical, radiographic and histological features and the absence of diagnostic surrogate markers in blood, the diagnosis depends on the identification of the organism by means of culture based methods [12].

5. Diagnostics

In general, diagnostic testing should begin with non-invasive methods and only approach invasive steps if needed. Diagnostic options include conventional or high-resolution CT (this has less radiation exposure and was performed in this case report), positron emission tomography (PET), magnetic resonance imaging (MRI), GM assay, 1,3-β-D-Glucan test, Polymerase chain reaction (PCR), bronchoalveolar lavage, blood culture and tissue biopsy. At this time,

MRI and PET are more research-oriented than commonly used clinical approaches. The utility of standard blood cultures is limited because of a high percentage of false-negative results, particularly in patients with disseminated aspergillosis. Of the listed options, the GM and 1,3- β -D-Glucan serum assay, PCR and the CT scan will be described in detail.

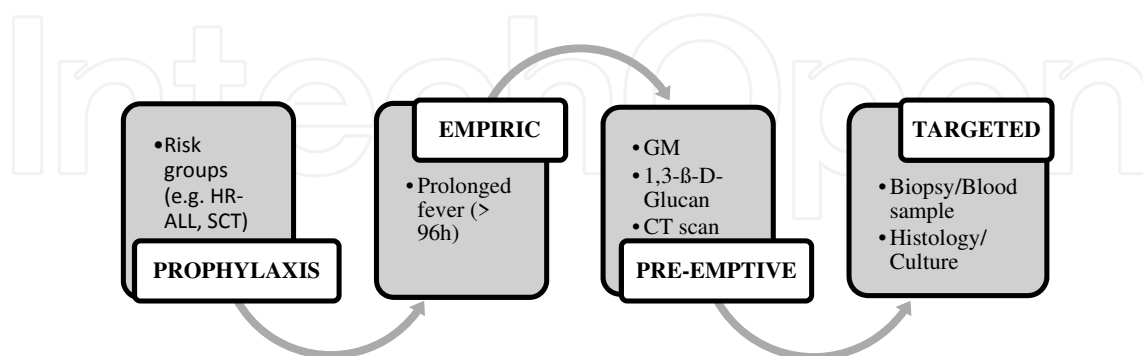


Figure 3. Simplified view of antifungal strategy in acute lymphoblastic leukemia (ALL) patients. Clinical practice (not EORTC criteria) in the management of IFIs depends on the population at risk (e.g. genetics, clinical), availability/value of diagnostic tests and availability/effectiveness of antifungal drugs. HR-ALL: high risk – acute lymphoblastic leukemia; SCT: stem cell transplantation; GM: Galactomannan; CT: computed tomography.

5.1. Galactomannan (GM)

GM testing with the Platelia Aspergillus Enzyme Immunoassay (EIA; Biorad Laboratories, Redmond, WA) has been approved by the U.S. Food and Drug Administration (FDA) for Aspergillus diagnostics and is included as a mycological criterion in the revised definitions of invasive fungal disease from the EORTC/MSG consensus group [6]. The test is based on detection of a component of the Aspergillus cell wall, Galactomannan (GM), which is released in the surrounding environment by growing Aspergillus species. Concentration of serum GM correlates with fungal burden in animals with experimental pulmonary aspergillosis – and, according to the 2011 ECIL clinical practice guidelines may be considered as surrogate marker for detection of invasive aspergillosis (<http://www.ebmt.org/Contents/Resources/Library/ECIL/Pages/ECIL.aspx>). Recent data suggest that sequential measuring of GM serum levels may be used for therapeutic monitoring in children and adults with pulmonary aspergillosis. The guidelines from the Infectious Disease Society of America (IDSA) state, that duration of antifungal therapy must not only rely on disappearance of GM levels, but also on resolution of clinical and radiological findings [13].

The GM EIA has been most studied in hematologic malignancy and bone marrow transplantation populations. Both the specificity and sensitivity of the GM EIA for invasive aspergillosis are high for infected, neutropenic adult patients from these populations. Comparison of 5 studies which use EORTC/MSG criteria and give adequate information for individual patients with results of a formal meta-analysis, indicate sensitivity, specificity of 76% to 73%, 86% to 90% in children and adults respectively [14]. Controversy of GM testing exists about the interpretation of the assay cutoff level (0.5, 1.0), which was originally set at 1.5 and was applied

in Europe but which was lowered to 0.5 after review by the FDA. Studies have shown that using an index cutoff for positivity of 0.5 versus greater indices substantially increases sensitivity, with only minimal loss in specificity [15]. Factors, which increase false positivity and influence the specificity of the assay, include a low level of cut-off (<0.5), colonization with *Bifidobacterium bifidum* in the intestinal flora, which mimics the epitope recognized by the EB-A2 in the enzyme-linked immunosorbent assay kit [16] and invasive infections with other fungi, such as *Penicillium* spp., histoplasmosis, and blastomycosis [13]. Moreover, cross-reactivity of the assay has been shown with the use of piperacillin/ tazobactam or amoxicillin/ clavulanate antibiotic therapy and in infants with the nutrition of milk-based formulas [17].

The IDSA guidelines currently recommend using the GM EIA in conjunction with CT scans for early, noninvasive diagnosis of invasive aspergillosis in high-risk patients [13]. The test should be performed serially, at least twice per week through the periods of highest risk, whether the periods involve neutropenia or active GVHD [13].

When GM in serum is used for screening for invasive mold infection in children with hematological malignancies/undergoing HSCT, data should be interpreted with caution, since the assay has a number of limitations in the sensitivity and specificity profile. Prospective monitoring of GM in serum every three to four days in children at high risk for IFD is reasonable for early diagnosis of invasive aspergillosis. Although the optimal cut-off value of GM in the serum of children is not well defined, published data support the use of a threshold of an optical density index 0.5 (<http://www.ebmt.org/Contents/Resources/Library/ECIL/Pages/ECIL.aspx>).

5.2. 1,3-β-D Glucan

1,3-β-D Glucan (BG) is a fungal cell wall component circulating in the blood of patients with invasive aspergillosis, candidemia, but also *Fusarium*, *Trichosporum*, *Saccharomyces*, and *Pneumocystis jirovecii*. Moreover, BG is also detected in patients with infections due to bacteria such as *Streptococcus pneumoniae*, *Pseudomonas aeruginosa* and in healthy individuals. However, BG is absent in patients with cryptococcosis and zygomycosis [18]. Antibiotics such as cefepime, piperacillin/tazobactam or meropenem may cause positive BG levels. Investigations using different BG assays in 2979 patients (594 with proven or probable IFI) have reported a pooled sensitivity of 76.8% and specificity of 85.3% [19]. Differences in study design (population studies versus case-control, variation in the number of proven or probable IFIs, proportions of patients with candidemia and aspergillosis, case-mix of neutropenic and non-neutropenic patients, and previous antifungal prophylaxis) highlight the need for further investigations. In children, data is very limited: elevated levels of BG were reported in a case-control study of only four children with IFI (3 patients with candidemia, one patient probable aspergillosis) [20].

The Fungitell assay (Associates of Cape Cod) for detection of 1,3-β-D Glucan is approved by the FDA for the diagnosis of invasive mycoses, including aspergillosis [13] and is included as mycological criterion in the revised definitions of invasive fungal disease from the EORTC/MSG consensus group [6]. Unfortunately, there is no recommendation from ECIL or IDSA for clinical practice. However, BG testing in adults is considered as having good

diagnostic accuracy for early diagnosis of IFD; in children, data are too limited to make any recommendations (<http://www.ebmt.org/Contents/Resources/Library/ECIL/Pages/ECIL.aspx>).

5.3. PCR

Detection of antifungal DNA has been advocated as a promising, rapid and more sensitive diagnostic tool, but false-positive results can occur, and a standardized commercial method is not yet available. Several PCR assays to detect fungal DNA have been described, but most have shown that the global performance was too low to be of clinical interest. Different situations have been reported: PCR either has high sensitivity and NPV, while specificity and PPV is low, or, conversely, high specificity and PPV with low sensitivity and NPV [21-24]. These discrepancies can be due to the different technical approaches used. Indeed, a major difference is the type of PCR method used in these studies, i.e., nested PCR, PCR–enzyme-linked immunosorbent assay, or RT-PCR [22;24]. Also, the superiority of large serum volumes (> 1 ml) in comparison with conventional serum samples (100 µl to 200 µl) has clearly been shown [23]. In view of changing epidemiology a panfungal PCR might be advantageous to permit the detection of a wide range of fungal pathogens. Its sensitivity of 96%, negative predictive values of 98%, whereas the specificity and positive predictive value were 77% and 62%, respectively is far superior to single PCR measurements [25].

In summary, despite ISDA and ECIL do not give any recommendations, combining non-culture based diagnostics is an important research direction that may improve the overall predictive value of these systems [26].

5.4. Chest CT scan

Systematic chest CT scan allows early diagnosis of invasive pulmonary aspergillosis, is more sensitive and specific than traditional chest radiographs and is a clinical criterion in the revised definitions of invasive fungal disease from the EORTC/MSG consensus group. Characteristic findings consist of nodules surrounded by the 'halo sign', an area of haziness or ground-glass opacity, or pleura-based, wedge-shaped areas of consolidation [27]. These findings correspond to areas of hemorrhagic infarcts. In severely neutropenic patients, the halo sign is highly suggestive of angioinvasive aspergillosis. However, a similar appearance has been described in a number of other conditions, including infections with herpes virus or cytomegalovirus, Kaposi sarcoma, Wegener granulomatosis, and bronchiolitis obliterans organizing pneumonia [12]. The air crescent sign, a crescent-shaped area of radiolucency in a region of nodular opacity, is usually seen during convalescence in angioinvasive aspergillosis (i.e., 2–3 weeks after initiation of treatment and concomitant with resolution of the neutropenia) [28]. Of note, some studies suggest that cavitation and the air-crescent sign are more likely to be observed in adults, and may frequently be absent from CT scans obtained from young children with pulmonary invasive aspergillosis [29]. When obtaining serial CT scans, it is also important to realize that irrespective of antifungal therapy, the pattern is characterized by an initial rise in number and size of lesions, followed by a plateau in lesion size, and gradual reduction [12]. Moreover, is time until complete radiologic remission and outcome independent of initial or maximum

lesion size and number in patients with invasive pulmonary aspergillosis [30]. The appearance of cavities on serial CT scans (frequently accompanied by the appearance of the air-crescent sign as neutropenia resolves) may be indicative of patient recovery. Similarly, if antifungal therapy is initiated and subsequent scans show an increase in the number or size of lesions, this is more likely a reflection of the typical progression of disease rather than failed therapy. According to the ECIL recommendations, in high-risk patients with persistent febrile neutropenia that persists beyond 96 hours or with focal clinical findings, imaging studies (e.g., CT-scan of the lung or adequate imaging of the symptomatic region) should be performed. Further diagnostic work-up (e.g., BAL, biopsy) should be considered and mold-active antifungal treatment should be initiated.

6. Treatment

Antifungal strategies include prophylaxis, empiric antifungal therapy, pre-emptive antifungal therapy and treatment of established invasive fungal infection (Figure 3). For individual patient populations, each strategy needs to consider the patients risk, the local epidemiology, the availability of diagnostic tools and the availability and effectiveness of antifungal agents. Last, but not least a cost – benefit analysis (i.e. toxicity, financial aspects) is mandatory. For the purpose of this textbook spectrum, potency, mode of action, and clinical indication of antifungal agents will be discussed.

6.1. Amphotericin B

Amphotericin deoxycholate (DAMB) and its lipid formulations, including amphotericin B colloidal dispersion (ABCD), amphotericin B lipid complex (ABLC), and liposomal amphotericin B (LAMB,) have a wide range of activity against most fungal pathogens. Only *Aspergillus terreus* and *Fusarium* species are less susceptible (Table 1.) [31].

In comparison to DAMB, nephrotoxicity is rarely seen with the use of the lipid formulations; infusion-related reactions, such as fever, chills and rigor are substantially less frequent with LAMB. Mild increases in bilirubin and alkaline phosphatase are associated with all three lipid formulations, elevation of transaminases with LAMB only. Currently, DAMB is licensed for neonatal invasive candidiasis and induction therapy for cryptococcal meningitis; LAMB is approved as first line empirical treatment of suspected invasive aspergillosis and candidiasis; ABCD is licensed for second-line treatment of patients with invasive aspergillosis, and ABLC for second-line treatment of patients with invasive *Candida* or *Aspergillus* infections [34].

The recommended therapeutic dosages are 0.7 to 1.0 mg/kg/day for DAMB, 3–4 mg/kg/day for ABCD, 5 mg/kg/day for ABLC, and 3 (to 5) mg/kg/day for LAMB, respectively. The available evidence does not suggest pharmacokinetic differences of LAMB between adults and children including preterm and newborn infants [33].

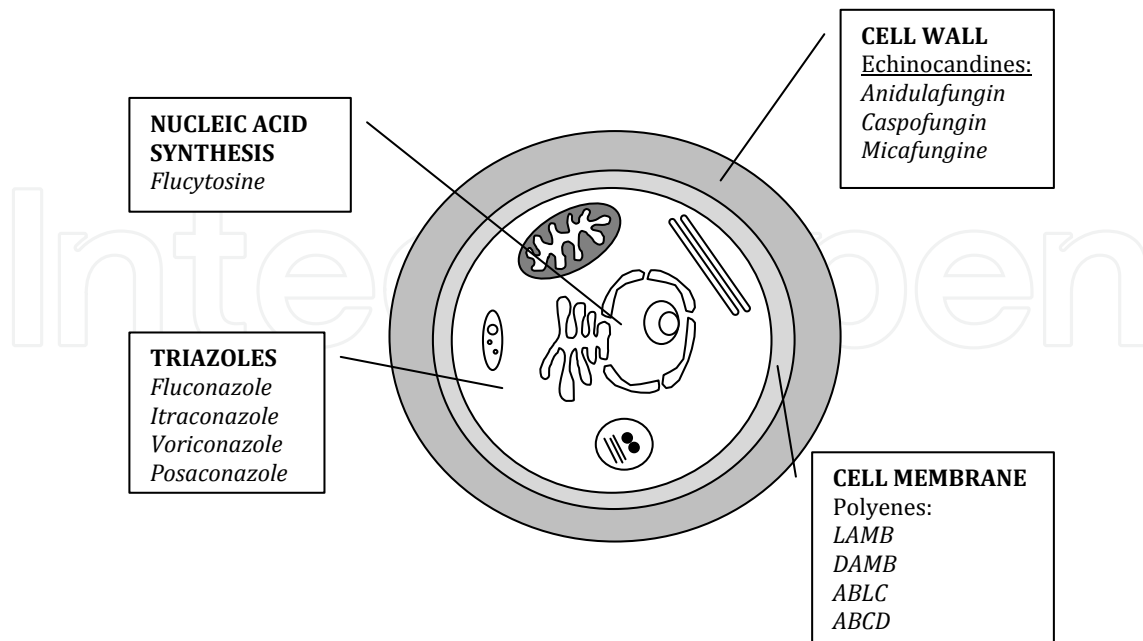


Figure 4. Schematic overview of current antifungal agents in regard to its target. Flucytosine inhibits RNA and DNA synthesis, Triazoles inhibit ergosterol biosynthesis, polyenes bind to sterols in the plasma membrane and echinocandines inhibit beta [1,3]-D-Glucan-synthesis. LAMB: liposomal Amphotericin B; DAMB: Amphotericin B deoxycholate; ABCD: Amphotericin B colloidal dispersion; ABLC: amphotericin B lipid complex.

6.2. Fluconazole

Fluconazole has a very narrow fungal susceptibility against *Candida* species (*Candida glabrata* and *krusei* have a high MIC index) and lacks activity against *Aspergillus* species and zygomycetes (Table 1.). Fluconazole is not metabolized and mainly renally excreted, and drug levels correlate with strictly with renal function [33]. It is licensed for prophylactic use in patients at risk for IFIs and for targeted treatment of candidiasis. For pediatric patients (they show a more rapid excretion and shorter half-life), the recommended dosage is higher than for adults, 8 to 12 mg/kg/day versus 5 mg/kg/day, respectively [34].

6.3. Itraconazole

The compound is active against most *Candida* and *Aspergillus* species, but the susceptibility against *Candida glabrata* and *C. krusei* is limited (Table 1). There is no activity against zygomycetes. The pharmacokinetics is characterized by inter-individual variability of gastrointestinal absorption and hepatic metabolism [35]. Accordingly, measurement of drug levels is necessary and results of meta-analysis suggest that the trough plasma level should be higher than 0.5 µg / mL [36]. Concerns have arisen on the interaction with drugs such as vincristine and cyclosporine, which are major components of both induction ALL therapy and prevention of GvHD in ALL transplanted patients. Moreover, 10% of patients experience gastrointestinal adverse effects, such as nausea and diarrhea, which limits its acceptance [34]. According to the

	Amphotericin B	Fluconazole	Voriconazole	Posaconazole	Itraconazole	Caspofungin	Micafungin
<i>Candida albicans</i>	+	(+)	+	+	+	+	+
<i>C. parapsilosis</i>	+	+	+	+	+	+/-	+/-
<i>C. lusitanae</i>	-/+	+	+	+	+	+	+
<i>C. tropicalis</i>	+	-/+	+	+	+	+	+
<i>C. glabrata</i>	+	-	-/+	+	-/+	+	+
<i>C. krusei</i>	+	-	-/+	+	-/+	+	+
<i>Asp. fumigatus</i>	+	-	+	+	+	+	+
<i>Asp. flavus</i>	(+)	-	+	+	+	+	+
<i>Asp. terreus</i>	-	-	+	+	+	+	+
<i>Asp. niger</i>	+	-	(+)	+	(+)	+	+
Zygomycetes	+	-	-	(+)	-	-	-
<i>Fusarium</i> spp.	(+)	-	-	-	-	-	-

+ = high activity rate; (+) = little reduced activity rate; -/+ = higher resistant rates in some areas; - = mostly resistant [11;32;33]. C.: *Candida*; Asp.: *Aspergillus*; spp.: species.

Table 1. Susceptibility of important fungal pathogens against some common antifungal agents.

ECIL and IDSA guidelines, Itraconazole should be used as second-line therapy in the prevention of IFIs.

6.4. Voriconazole

Voriconazole has similar activity as Itraconazole and is active against most *Candida* and *Aspergillus* species, but not zygomycetes, *Candida glabrata* and *C. krusei* (Table 1.). The effectiveness of this compound has been demonstrated in large clinical trials in both adults and children, and has led to its approval for empirical and pre-emptive antifungal therapy [31]. Because of its wide use, breakthrough infections with zygomycetes have been reported [37]. Additionally, breakthrough infections with susceptible strains have been noted in patients with low plasma levels, necessitating the monitoring of through plasma levels [38]. In children, Voriconazole is more rapidly metabolized, suggesting a higher dosage of 7-8 mg/kg/b.i.d. than in adults (4-5 mg/kg/b.i.d.) [33]. Relevant side effects of Voriconazole include elevations of liver enzymes, visual disturbances and photosensitivity skin reactions, particularly if combined with nucleoside analogs, which are commonly used in the treatment of ALL. In addition,

the interaction of Voriconazole with a number of drugs (e.g. Vincristine, Cyclosporine A, and Omeprazole) has to be considered [33].

6.5. Posaconazole

This compound has a potent and broad-spectrum activity against most clinically important fungal infections, including zygomycetes, distinguishing it from the other azoles [33]. According to the ECIL/ IDSA guidelines it is recommended as second-line treatment of aspergillosis, fusariosis, chromoblastomycosis and coccidioidomycosis. In addition, Posaconazole is approved for prophylaxis in high-risk patients older than 13 years of age with ALL and in hematopoietic stem cell transplant patients with graft-versus-host disease [31;39]. The dosage for prophylaxis is 200 mg three times daily, for salvage treatment the dose is increased to 400 mg two times daily. Similar to Voriconazole, interference with cytochrome P450 dependent metabolites (e.g. Cyclosporine) need to be considered [34].

6.6. Caspofungin

Caspofungin is active against *Candida* spp. and *Aspergillus* spp., but resistant against *Cryptococcus* species and zygomycetes (Table 1.). It is licensed for adult and pediatric patients, including neonates, for empirical antifungal therapy in persistently febrile neutropenic patients, for second-line pre-emptive therapy of suspected aspergillosis and for primary therapy in non-neutropenic patients with invasive *Candida* infections. The recommended dose regimen in adults consists of a single 70-mg loading dose on day 1, followed by 50 mg daily thereafter [34]. A dosage of 1 mg/kg for children has been suggested [31]. A favorable safety profile has been described, the most common drug-related adverse events were fever, increased ALT, and rash; few events were serious or required treatment discontinuation [40].

6.7. Micafungin

Micafungin was recently licensed for neonates, children and adults for prophylaxis and treatment of invasive candidiasis in patients with prolonged neutropenia and after hematopoietic stem cell transplantation [41]. The spectrum of activity is similar to that of Caspofungin (Table 1). The recommended dosage is 100 mg/day for invasive candidiasis (≤ 40 kg body weight: 2 mg/kg) with the option of dose escalation to 200 mg/day or 4 mg/kg/day; and 50 mg/day (≤ 40 kg: 1 mg/kg) in the preventive indication [34]. The most frequent adverse events include vomiting, high fever, diarrhea, nausea, and hypokalemia [41].

7. Conclusion

Although various guidelines on antifungal management have been published, we suggest using a simple approach, which is guided by local factors, such as the pattern of resistance and the availability of diagnostic tools. As newer strategies might soon be implemented, we are unable to assess the efficacy of our approach to date. Our report underlines that many

questions regarding antifungal treatment have to be addressed in future studies, such as the duration of treatment or the benefit of costly combination antifungal therapy.

Acknowledgements

We thank Kinderkrebshilfe Tirol und Vorarlberg for funding.

Author details

Roman Crazzolara*, Adrian Kneer, Bernhard Meister and Gabriele Kropshofer

*Address all correspondence to: roman.crazzolara@i-med.ac.at

Department of Pediatrics, Medical University of Innsbruck, Austria

References

- [1] Pui, C, Relling, M. V, & Downing, J. R. Mechanisms of disease: Acute lymphoblastic leukemia. *New England Journal of Medicine* (2004). , 1535-1548.
- [2] Arico, M, Valsecchi, M. G, Camitta, B, Schrappe, M, Chessells, J, Baruchel, A, et al. Outcome of treatment in children with philadelphia chromosome-positive acute lymphoblastic leukemia. *New England Journal of Medicine* (2000). , 998-1006.
- [3] Marr, K. A, Carter, R. A, Crippa, F, Wald, A, & Corey, L. Epidemiology and outcome of mould infections in hematopoietic stem cell transplant recipients. *Clinical Infectious Diseases* (2002). , 909-917.
- [4] Mcneil, M. M, Nash, S. L, Hajjeh, R. A, Phelan, M. A, Conn, L. A, Plikaytis, B. D, et al. Trends in mortality due to invasive mycotic diseases in the United States, *Clinical Infectious Diseases* (2001). , 1980-1997.
- [5] Zaoutis, T. E, Heydon, K, Chu, J. H, Walsh, T. J, & Steinbach, W. J. Epidemiology, outcomes, and costs of invasive aspergillosis in immunocompromised children in the United States, 2000. *Pediatrics* (2006). EE716., 711.
- [6] de PBWalsh TJ, Donnelly JP, Stevens DA, Edwards JE, Calandra T et al. Revised definitions of invasive fungal disease from the European Organization for Research and Treatment of Cancer/Invasive Fungal Infections Cooperative Group and the National Institute of Allergy and Infectious Diseases Mycoses Study Group (EORTC/MSG) Consensus Group. *Clin Infect Dis* (2008). , 1813-1821.

- [7] Ascioglu, S, Rex, J. H, De Pauw, B, Bennett, J. E, Bille, J, Crokaert, F, et al. Defining opportunistic invasive fungal infections in immunocompromised patients with cancer and hematopoietic stem cell transplants: An international consensus. *Clinical Infectious Diseases* (2002). , 7-14.
- [8] Lass-florl, C. The changing face of epidemiology of invasive fungal disease in Europe. *Mycoses* (2009). , 197-205.
- [9] Koch, S, Hohne, F. M, & Tietz, H. J. Incidence of systemic mycoses in autopsy material. *Mycoses* (2004). , 40-46.
- [10] Pagano, L, Caira, M, Candoni, A, Offidani, M, Fianchi, L, Martino, B, et al. The epidemiology of fungal infections in patients with hematologic malignancies: the SEI-FEM-2004 study. *Haematologica-the Hematology Journal* (2006). , 1068-1075.
- [11] Pfaller, M. A, & Diekema, D. J. Epidemiology of invasive candidiasis: a persistent public health problem. *Clinical Microbiology Reviews* (2007). , 133.
- [12] Franquet, T, Muller, N. L, Gimenez, A, & Guembe, P. de La TJ, Bague S. Spectrum of pulmonary aspergillosis: histologic, clinical, and radiologic findings. *Radiographics* (2001). , 825-837.
- [13] Walsh, T. J, Anaissie, E. J, Denning, D. W, Herbrecht, R, Kontoyiannis, D. P, Marr, K. A, et al. Treatment of aspergillosis: clinical practice guidelines of the Infectious Diseases Society of America. *Clin Infect Dis* (2008). , 327-360.
- [14] Pfeiffer, C. D, Fine, J. P, & Safdar, N. Diagnosis of invasive aspergillosis using a galactomannan assay: A meta-analysis. *Clinical Infectious Diseases* (2006). , 1417-1427.
- [15] Marr, K. A, Balajee, S. A, McLaughlin, L, Tabouret, M, Bentsen, C, & Walsh, T. J. Detection of galactomannan antigenemia by enzyme immunoassay for the diagnosis of invasive aspergillosis: Variables that affect performance. *Journal of Infectious Diseases* (2004). , 641-649.
- [16] Mennink-Kersten MASHKlont RR, Warris A, Op den Camp HJM, Verweij PE. Bifidobacterium lipoteichoic acid and false ELISA reactivity in aspergillus antigen detection. *Lancet* (2004). , 325-327.
- [17] Steinbach, W. J. Invasive aspergillosis in pediatric patients. *Current Medical Research and Opinion* (2010). , 1779-1787.
- [18] Senn, L, Robinson, J. O, Schmidt, S, Knaup, M, Asahi, N, Satomura, S, et al. Beta-D-glucan antigenemia for early diagnosis of invasive fungal infections in neutropenic patients with acute leukemia. *Clin Infect Dis* (2008). , 1, 3.
- [19] Karageorgopoulos, D. E, Vouloumanou, E. K, Ntziora, F, Michalopoulos, A, Rafailidis, P. I, & Falagas, M. E. beta-D-Glucan Assay for the Diagnosis of Invasive Fungal Infections: A Meta-analysis. *Clinical Infectious Diseases* (2011). , 750-770.

- [20] Mularoni, A, Furfaro, E, Faraci, M, Franceschi, A, Mezzano, P, Bandettini, R, et al. High Levels of beta-D-Glucan in Immunocompromised Children with Proven Invasive Fungal Disease. *Clinical and Vaccine Immunology* (2010). , 882-883.
- [21] Hummel, M, Spiess, B, Roder, J, Von Komorowski, G, Durken, M, Kentouche, K, et al. Detection of *Aspergillus* DNA by a nested PCR assay is able to improve the diagnosis of invasive aspergillosis in paediatric patients. *Journal of Medical Microbiology* (2009). , 1291-1297.
- [22] Lass-florl, C, Gunsilius, E, Gastl, G, Bonatti, H, Freund, M. C, Gschwendtner, A, et al. Diagnosing invasive aspergillosis during antifungal therapy by PCR analysis of blood samples. *J Clin Microbiol* (2004). , 4154-4157.
- [23] Suarez, F, Lortholary, O, Buland, S, Rubio, M. T, Ghez, D, Mahe, V, et al. Detection of Circulating *Aspergillus fumigatus* DNA by Real-Time PCR Assay of Large Serum Volumes Improves Early Diagnosis of Invasive Aspergillosis in High-Risk Adult Patients under Hematologic Surveillance. *Journal of Clinical Microbiology* (2008). , 3772-3777.
- [24] Cesaro, S, Stenghele, C, Calore, E, Franchin, E, Cerbaro, I, Cusinato, R, et al. Assessment of the lightcycler PCR assay for diagnosis of invasive aspergillosis in paediatric patients with onco-haematological diseases. *Mycoses* (2008). , 497-504.
- [25] Landlinger, C, Preuner, S, & Baskova, L. van GM, Hartwig NG, Dworzak M et al. Diagnosis of invasive fungal infections by a real-time panfungal PCR assay in immunocompromised pediatric patients. *Leukemia* (2010). , 2032-2038.
- [26] Lass-florl, C, Resch, G, Nachbaur, D, Mayr, A, Gastl, G, Auberger, J, et al. The value of computed tomography-guided percutaneous lung biopsy for diagnosis of invasive fungal infection in Immunocompromised patients. *Clinical Infectious Diseases* (2007). EE104., 101.
- [27] Taccone, A, Occhi, M, Garaventa, A, Manfredini, L, & Viscoli, C. Ct of Invasive Pulmonary Aspergillosis in Children with Cancer. *Pediatric Radiology* (1993). , 177-180.
- [28] Franquet, T, Muller, N. L, Oikonomou, A, & Flint, J. D. *Aspergillus* infection of the airways: computed tomography and pathologic findings. *J Comput Assist Tomogr* (2004). , 10-16.
- [29] Thomas, K. E, Owens, C. M, Veys, P. A, Novelli, V, & Costoli, V. The radiological spectrum of invasive Aspergillosis in children: a year review. *Pediatric Radiology* (2003). , 10.
- [30] Brodoefel, H, Vogel, M, Hebart, H, Einsele, H, Vonthein, R, Claussen, C, et al. Long-term CT follow-up in 40 non-HIV immunocompromised patients with invasive pulmonary aspergillosis: Kinetics of CT morphology and correlation with clinical findings and outcome. *American Journal of Roentgenology* (2006). , 404-413.

- [31] Groll, A. H, & Tragiannidis, A. Update on antifungal agents for paediatric patients. *Clin Microbiol Infect* (2010). , 1343-1353.
- [32] Lass-florl, C. Invasive fungal infections in pediatric patients: a review focusing on antifungal therapy. *Expert Review of Anti-Infective Therapy* (2010). , 127-135.
- [33] Lehrnbecher, T, Mousset, S, Sorensen, J, & Bohme, A. Current practice of antifungal prophylaxis and treatment in immunocompromised children and adults with malignancies: a single centre approach. *Mycoses* (2009). , 107-117.
- [34] Groll, A. H. Efficacy and safety of antifungals in pediatric patients. *Early Hum Dev* (2011). Suppl 1:SS74., 71.
- [35] Chiou, C. C, Walsh, T. J, & Groll, A. H. Clinical pharmacology of antifungal agents in pediatric patients. *Expert Opin Pharmacother* (2007). , 2465-2489.
- [36] Glasmacher, A, Prentice, A, Gorschluter, M, Engelhart, S, Hahn, C, Djulbegovic, B, et al. Itraconazole prevents invasive fungal infections in neutropenic patients treated for hematologic malignancies: Evidence from a meta-analysis of 3,597 patients. *Journal of Clinical Oncology* (2003). , 4615-4626.
- [37] Trifilio, S, Singhal, S, Williams, S, Frankfurt, O, Gordon, L, Evens, A, et al. Break-through fungal infections after allogeneic hematopoietic stem cell transplantation in patients on prophylactic voriconazole. *Bone Marrow Transplantation* (2007). , 451-456.
- [38] Trifilio, S, Pennick, G, Pi, J, Zook, J, Golf, M, Kaniecki, K, et al. Monitoring plasma voriconazole levels may be necessary to avoid subtherapeutic levels in hematopoietic stem cell transplant recipients. *Cancer* (2007). , 1532-1535.
- [39] Groll, A. H, & Walsh, T. J. Antifungal efficacy and pharmacodynamics of posaconazole in experimental models of invasive fungal infections. *Mycoses* (2006). , 49, 7-16.
- [40] Walsh, T. J, Viviani, M. A, Arathoon, E, Chiou, C, Ghannoum, M, Groll, A. H, et al. New targets and delivery systems for antifungal therapy. *Medical Mycology* (2000). , 38, 335-347.
- [41] Lehrnbecher, T, & Groll, A. H. Micafungin: a brief review of pharmacology, safety, and antifungal efficacy in pediatric patients. *Pediatr Blood Cancer* (2010). , 229-232.