

# We are IntechOpen, the world's leading publisher of Open Access books Built by scientists, for scientists

6,900

Open access books available

185,000

International authors and editors

200M

Downloads

Our authors are among the

154

Countries delivered to

TOP 1%

most cited scientists

12.2%

Contributors from top 500 universities



WEB OF SCIENCE™

Selection of our books indexed in the Book Citation Index  
in Web of Science™ Core Collection (BKCI)

Interested in publishing with us?  
Contact [book.department@intechopen.com](mailto:book.department@intechopen.com)

Numbers displayed above are based on latest data collected.  
For more information visit [www.intechopen.com](http://www.intechopen.com)



---

# Diabetic Foot Ulcer

---

Bardia Farzamfar, Reza Nazari and  
Saeed Bayanolhagh

Additional information is available at the end of the chapter

<http://dx.doi.org/10.5772/55588>

---

## 1. Introduction

Every emergency physician has seen diabetic foot ulcers in their nascent stage, at a stage requiring minimal treatment with good follow-up, when they require aggressive treatment, and at a stage when amputation is a foregone conclusion. Ulcerations of the foot in diabetics are common; most diabetics will get them. Not only are they disabling, they also are limb- and life-threatening. [1]

It is estimated that approximately 15% of diabetic people world-wide will at some stage develop diabetic foot ulceration. The prevalence of active foot ulceration varies from approximately 1% in certain European and North American studies to more than 11% in reports from some African countries (table 1). Although there have been many developments in recent years which encourage optimism for future improvement in diabetic foot care, there is still much to be done; the recent data from the Netherlands show that with a concerted team approach, it is possible to increase the numbers of foot clinics with the provision of podiatry services by more than 100%. However, many countries still lack proper podiatry and specialist nursing provision and there remains much to be done in the next millennium to improve the lot of the diabetic patient with foot problems. [2,3] In general, in diabetic patients, the incidence of foot ulcers ranges from 1.0% to 4.1%, and the incidence of lower-extremity amputations ranges from 2.1 to 13.7 per 1000. [4-6]

The nerves of the leg and foot serve to propel the body through the actions of the legs, feet, and toes while maintaining balance, both while the body is moving and when it is at rest. Sensory nerves are of course present throughout the lower extremities; however, with the exception of the bottom of the foot, they play a lesser role here than in the upper extremities. Primarily, this section of the peripheral nervous system sends and receives signals regarding

Study (country)	Population base	N	Prevalence (%)	Annual incidence <sup>a</sup> (%)	Ulcer definition	Ulcer ascertainment method
Rith-Najarian <i>et al.</i> (US)	Chippewa Indian residents with diabetes	266	-	0.6 (Non-neuropathic subjects)	Full thickness plantar foot lesion	Retrospective review of medical records/clinical examinations
Walters <i>et al.</i> (UK)	Registered patients with diabetes from 10 UK general practices	1077	2.9 (current) 7.4 (History of ulcer)	-	Wagner grade ≥1 foot lesion	Direct examination and structured interview
Moss <i>et al.</i> (US)	Population-based samples of persons with diabetes	1834	10.6 (History of ulcers at baseline)	2.2	???	Medical history questionnaire administered at baseline and 4 years later
Kumar <i>et al.</i> (UK)	Type 2 diabetes patients registered in three UK cities	811	1.4 (Current) 5.3 (History of ulcer)	-	Wagner grade ≥1 foot lesion	Direct exam by trained observers (current), and structured interview (history of ulcer)
Abbott <i>et al.</i> (UK)	Randomized controlled trial cohort	1035	-	3.6	Full-thickness lesion requiring hospital treatment	Direct examination at least every 13 weeks
Ramsey <i>et al.</i> (US)	Registered adult type 1 or 2 diabetes patients in a large HMO (1992-1995)	8905	-	1.9	ICD-codes: 707.1 (ulcer of lower leg)	Medical billing record audit
Abbott <i>et al.</i> (UK)	Registered type 1 and 2 diabetes patients in six UK districts	9710	1.7 (Current)	2.2	Wagner grade ≥1 foot lesion	Clinical examination (plus chart review)
Muller <i>et al.</i> (Netherland)	1993-1998 registered type 2 diabetes patients	3827 person-years	-	2.1	Full-thickness skin loss on the foot	Abstracted medical records
Centers for Disease Control and Prevention (US)	US BRFSS respondents with diabetes, 2000-2002 <sup>b</sup>	NS	11.8 (History of ulcer)	-	Foot sore that did not heal for >4 weeks	Random-digit-dialed telephone interview

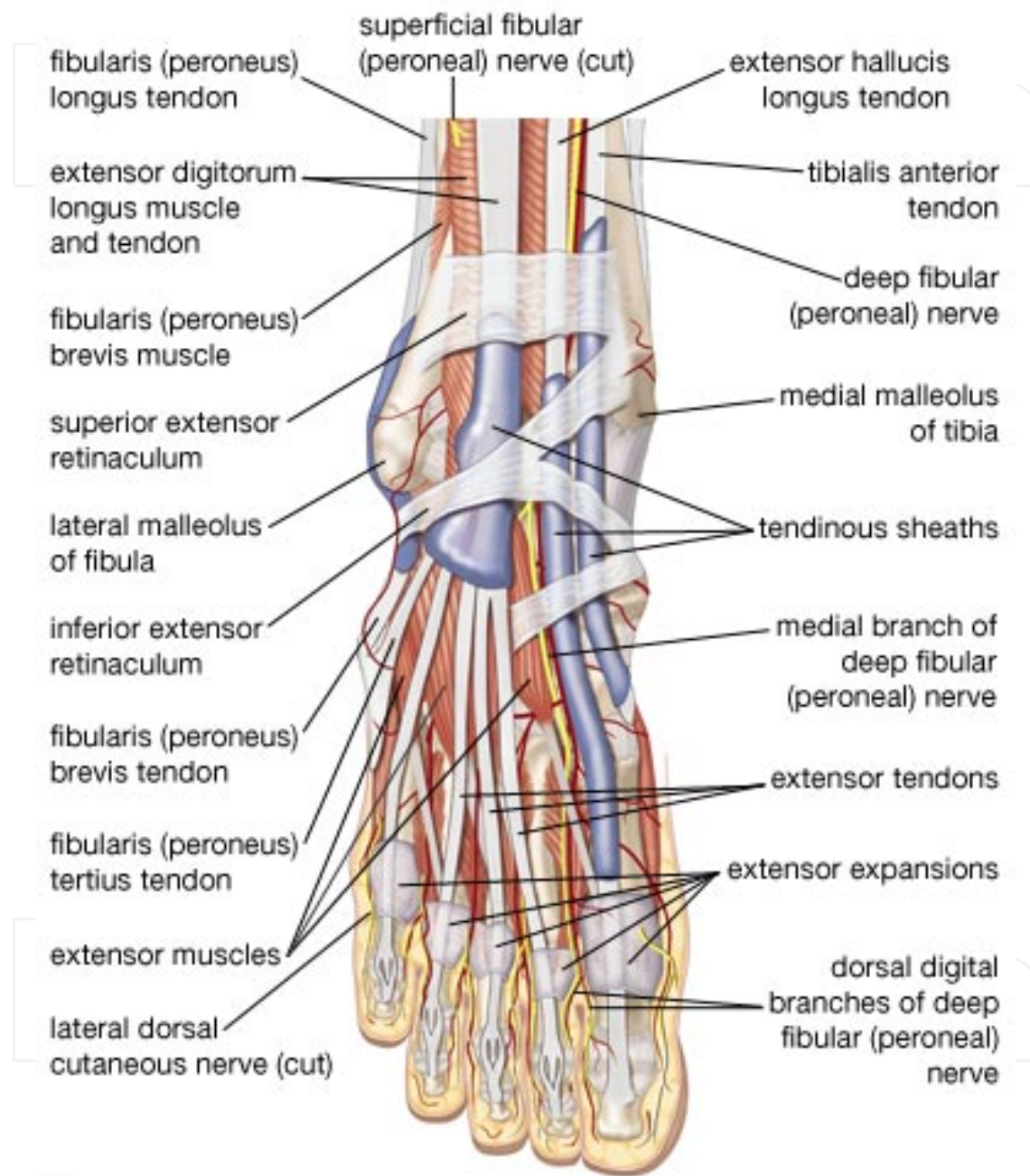
???, not specified.

<sup>a</sup> Incidence is annualized unless otherwise noted.

<sup>b</sup> BRFSS, Behavioral Risk Factor Surveillance Survey.

**Table 1.** Selected population-based studies estimating incidence and prevalence of diabetic foot ulcers (adapted from LeMaster and Reiber, 2006) [7]

locomotion of the body. Some of the impulses are sent from various parts of the brain and spinal cord; some come from sense organs located in the joints, ligaments, and tendons; and some come from the muscles themselves.



© 2007 Encyclopædia Britannica, Inc.

**Figure 1.** Nerves of foot. (adapted from Encyclopedia Britanica 2007)

The nerves of the leg and foot include the sacral plexus, lumbar plexus, femoral nerve, sciatic nerve, common fibular nerve, superficial fibular nerve, saphenous nerve, sural nerve, the deep and superficial peroneal nerves, and the tibial nerve (figure 1).

The nerves deliver messages to the brain that bring information about the angles and position of joints, the length and tension of muscles, or even the speed of movements so that through the interaction of the nervous system with the muscles of the lower extremities, balance may be maintained. The average nerve running from the base of the spine to the tip of a toe is about three feet long. This includes a major neural transmission network within the legs that produces contractions of groups of muscles and is responsible for larger muscular functions, such as running, walking or swimming. Finer nerve bundles command the many small bones of the toes to create the constant, subtle shifting of the feet that keeps us from falling down.

## 2. Peripheral neuropathy

Peripheral neuropathy is damage to nerves of the peripheral nervous system, which may be caused either by diseases of or trauma to the nerve or the side-effects of systemic illness.

The four cardinal patterns of peripheral neuropathy are polyneuropathy, mononeuropathy, mononeuritis multiplex and autonomic neuropathy. The most common form is (symmetrical) peripheral polyneuropathy, which mainly affects the feet and legs. The form of neuropathy may be further broken down by cause, or the size of predominant fiber involvement, i.e., large fiber or small fiber peripheral neuropathy. Frequently the cause of a neuropathy cannot be identified and it is designated as being idiopathic.

Neuropathy may be associated with varying combinations of weakness, autonomic changes, and sensory changes. Loss of muscle bulk or fasciculations, a particular fine twitching of muscle, may be seen. Sensory symptoms encompass loss of sensation and "positive" phenomena including pain. Symptoms depend on the type of nerves affected (motor, sensory, or autonomic) and where the nerves are located in the body. One or more types of nerves may be affected. Common symptoms associated with damage to the motor nerve are muscle weakness, cramps, and spasms. Loss of balance and coordination may also occur. Damage to the sensory nerve can produce tingling, numbness, and a burning pain. Pain associated with this nerve is described in various ways such as the following: burning, freezing, or electric-like, extreme sensitivity to touch. The autonomic nerve damage causes problems with involuntary functions leading to symptoms such as abnormal blood pressure and heart rate, reduced ability to perspire, constipation, bladder dysfunction (e.g., incontinence), and sexual dysfunction. [8-10]

## 3. Sensory neuropathy

Sensory neuropathy affects the nerves that carry messages from the skin, bones and muscles to the brain. As the name suggests, it tends to influence the senses, in particular touch, and affects how we feel temperature, pain and other sensations. It is the most common form of neuropathy, mainly occurring in nerves in the feet and legs, but can sometimes occur in the arms and hands. It can lead to a loss of feeling and a failure to sense pain. For example, if you

trod on something sharp, stepped in to a hot bath or wore ill-fitting shoes, you may not be aware of damage to your feet. This lack of sensation can lead to damage becoming worse, and the potential for infection. Neuropathic ulcers may also occur. [11]

The symptoms of sensory neuropathy can include pain and numbness, tingling in the hands, legs or feet and extreme sensitivity to touch. Some treatments are available to help with the pain and tablets that are usually used for depression but can also have a calming effect on the nerves.

A test should be carried out at least every year, to check for signs of this type of neuropathy.

#### **4. Motor neuropathy**

Motor neuropathy affects the nerves that transmit signals to the muscles enabling them to carry out movements like walking and moving the hands. Sometimes painful, it causes muscle weakness and, in areas like the thigh, muscle wasting can occur. However it is possible for some people to recover from this condition after a period of time.

If the nerves that supply the small muscles in your feet are affected, motor neuropathy can lead to the development of foot deformities and alteration in the pressure distribution with walking or activity. Wasting of these muscles may ultimately cause collapse of the arch and loss of stability, which results in forming the 'rocker bottom' or Charcot's foot, where a loss of sensation and weakened muscles cause bones in the foot to fracture or break when stressed. As you may not feel the damage, subsequently you may not heal properly and this can result in the shape of the foot becoming distorted. Your podiatrist will know more about treatments for this. [12]

#### **5. Autonomic neuropathy**

The final type of nerve problem is an "autonomic neuropathy." In this type of neuropathy, the nerves that control sweating are damaged. Dry skin occurs as a result of damage to these nerves. Sweating is important for heat reduction but it is also important for skin moisture balance. Without sweat, the skin dries out and cracks. This can be dangerous because germs can enter through the cracks and cause infection. Dry and cracked skin should be treated with prescription moisturizing creams and regular professional foot care. Autonomic neuropathy is a form of polyneuropathy which affects the non-voluntary, non-sensory nervous system (i.e., the autonomic nervous system) affecting mostly the internal organs such as the bladder muscles, the cardiovascular system, the digestive tract, and the genital organs. These nerves are not under a person's conscious control and function automatically. Autonomic nerve fibers form large collections in the thorax, abdomen and pelvis outside spinal cord, however they have connections with the spinal cord and ultimately the brain. Most commonly autonomic neuropathy is seen in persons with long-standing diabetes mellitus type 1 and 2. In most but



not all cases, autonomic neuropathy occurs alongside other forms of neuropathy, such as sensory neuropathy.

Autonomic neuropathy is one cause of malfunction of the autonomic nervous system, but not the only one; some conditions affecting the brain or spinal cord can also cause autonomic dysfunction, such as multiple system atrophy, and therefore cause similar symptoms to autonomic neuropathy.

The signs and symptoms of autonomic neuropathy include the following:

- Urinary bladder conditions: bladder incontinence or urine retention
- Gastrointestinal tract: dysphagia, abdominal pain, nausea, vomiting, malabsorption, fecal incontinence, gastroparesis, diarrhea, constipation
- Cardiovascular system: disturbances of heart rate (tachycardia, bradycardia), orthostatic hypotension, inadequate increase of heart rate on exertion
- Other areas: hypoglycemia unawareness, genital impotence, sweat disturbances. [9]

## 6. Diabetic neuropathy

Most diabetics experience some type of neuropathy, a leading predisposing factor to development of ulcers. More than 60% of diabetic foot ulcers are the result of underlying neuropathy. [11,13] Diabetics have altered peripheral sensation of the foot, with loss of the protective sensation that renders the individual unaware of the beginning of an ulcer or the actual ulceration process. Diabetic neuropathy also alters the microcirculation of the foot, resulting in a reduced distribution of blood to the areas of need. Nerve damage in diabetic neuropathy occurs when blood sugar is poorly controlled for prolonged periods of time. Involvement of these nerves results in loss of the normal protective sensation that we rely upon to avoid injury. Loss of the normal pain threshold may result in prolonged and repetitive trauma to the foot. Overcompensation by other muscles can lead to other foot deformities including 'hammer' or 'claw' toes. These abnormalities lead to pressure points that are then at great risk for ulceration. Even the dry, brittle skin caused by diminished sweating is due to neuropathy affecting specialized nerves within the skin. This makes the skin prone to cracking and fissuring, thus allowing entry of bacteria even in the absence of a large sore. Subsequent infection and abscess formation may damage far more tissue than is apparent from the overlying ulcer.

The development of neuropathy in affected patients has been shown in animal and *in vitro* models to be a result of hyperglycemia-induced metabolic abnormalities. One of the more commonly described mechanisms of action is the polyol pathway. In the development of neuropathy, the hyperglycemic state leads to an increase in action of the enzymes aldose reductase and sorbitol dehydrogenase. This results in the conversion of intracellular glucose to sorbitol and fructose. The accumulation of these sugar products results in a decrease in the synthesis of nerve cell myoinositol, required for normal neuron conduction. Additionally, the chemical conversion of glucose results in a depletion of nicotinamide adenine dinucleotide

phosphate stores, which are necessary for the detoxification of reactive oxygen species and for the synthesis of the vasodilator nitric oxide. There is a resultant increase in oxidative stress on the nerve cell and an increase in vasoconstriction leading to ischemia, which will promote nerve cell injury and death. Hyperglycemia and oxidative stress also contribute to the abnormal glycation of nerve cell proteins and the inappropriate activation of protein kinase C, resulting in further nerve dysfunction and ischemia.

Neuropathy in diabetic patients is manifested in the motor, autonomic, and sensory components of the nervous system. [14] Damage to the innervations of the intrinsic foot muscles leads to an imbalance between flexion and extension of the affected foot. This produces anatomic foot deformities that create abnormal bony prominences and pressure points, which gradually cause skin breakdown and ulceration.

As trauma occurs at the affected site, patients are often unable to detect the insult to their lower extremities. As a result, many wounds go unnoticed and progressively worsen as the affected area is continuously subjected to repetitive pressure and shear forces from ambulation and weight bearing. [15-20]

## 7. Vascular disease

Peripheral arterial disease is a contributing factor to the development of foot ulcers in up to 50% of cases. [21] It commonly affects the tibial and peroneal arteries of the calf. Endothelial cell dysfunction and smooth cell abnormalities develop in peripheral arteries as a consequence of the persistent hyperglycemic state. [22] There is a resultant decrease in endothelium-derived vasodilators leading to constriction. Further, the hyperglycemia in diabetes is associated with an increase in thromboxane A<sub>2</sub>, a vasoconstrictor and platelet aggregation agonist, which leads to an increased risk for plasma hypercoagulability. [23] There is also the potential for alterations in the vascular extracellular matrix leading to stenosis of the arterial lumen. [23] Moreover, smoking, hypertension, and hyperlipidemia are other factors that are common in diabetic patients and contribute to the development of peripheral arterial disease. [14] Cumulatively, this leads to occlusive arterial disease that results in ischemia in the lower extremity and an increased risk of ulceration in diabetic patients.

## 8. The extracellular matrix, fibroblast and keratinocyte

The extracellular matrix (ECM) is the non-cellular component present within all tissues and organs, and not only does it provides essential physical scaffolding for the cellular constituents but also initiates crucial biochemical and biomechanical cues that are required for tissue morphogenesis, differentiation and homeostasis. The importance of the ECM is vividly illustrated by the wide range of syndromes, which can be anything from minor to severe, that arise from genetic abnormalities in ECM proteins. Although, fundamentally, the ECM is composed of water, proteins and polysaccharides, each tissue has an ECM with a unique



composition and topology that is generated during tissue development through a dynamic and reciprocal, biochemical and biophysical dialogue between the various cellular components (e.g. epithelial, fibroblast, adipocyte, endothelial elements) and the evolving cellular and protein microenvironment. Indeed, the physical, topological, and biochemical composition of the ECM is not only tissue-specific, but is also markedly heterogeneous. Cell adhesion to the ECM is mediated by ECM receptors, such as integrins, discoidin domain receptors and syndecans. Adhesion mediates cytoskeletal coupling to the ECM and is involved in cell migration through the ECM. Moreover, the ECM is a highly dynamic structure that is constantly being remodeled, either enzymatically or non-enzymatically, and its molecular components are subjected to a myriad of post-translational modifications. Through these physical and biochemical characteristics the ECM generates the biochemical and mechanical properties of each organ, such as its tensile and compressive strength and elasticity, and also mediates protection by a buffering action that maintains extracellular homeostasis and water retention. In addition, the ECM directs essential morphological organization and physiological function by binding growth factors (GFs) and interacting with cell-surface receptors to elicit signal transduction and regulate gene transcription.

A fibroblast is a type of cell that synthesizes the extracellular matrix and collagen, the structural framework (stroma) for animal tissues, and plays a critical role in wound healing. Fibroblasts are the most common cells of connective tissue in animals. Inactive fibroblasts, which are also called fibrocytes, are smaller and spindle shaped. Although disjointed and scattered when they have to cover a large space, fibroblasts when crowded often locally align in parallel clusters.

Fibroblasts make collagens, glycosaminoglycans, reticular and elastic fibers, glycoproteins found in the extracellular matrix and cytokine TSLP. Growing individuals' fibroblasts are dividing and synthesizing ground substance. Tissue damage stimulates fibrocytes and induces the mitosis of fibroblasts. Unlike the epithelial cells lining the body structures, fibroblasts do not form flat monolayers and are not restricted by a polarizing attachment to a basal lamina on one side, although they may contribute to basal lamina components in some situations. Fibroblasts can also migrate slowly over substratum as individual cells, again in contrast to epithelial cells. While epithelial cells form the lining of body structures, it is fibroblasts and related connective tissues which sculpt the "bulk" of an organism.

Keratinocyte is the predominant cell type in the epidermis, the outermost layer of the skin, constituting 95% of the cells found there. Those keratinocytes found in the basal layer (Stratum germinativum) of the skin are sometimes referred to as "basal cells" or "basal keratinocytes."

Wounds to the skin will be repaired in part by the migration of keratinocytes to fill in the gap created by the wound. The first set of keratinocytes to participate in that repair come from the bulge region of the hair follicle and will only survive transiently. Within the healed epidermis they will be replaced by keratinocytes originating from the epidermis. At the opposite, epidermal keratinocytes, can contribute to *de novo* hair follicle formation during the healing of large wounds. Keratinocytes migrate with a rolling motion during the process of wound healing.

## 9. Extracellular matrix, fibroblast and keratinocyte in diabetic foot ulcer

Diabetic nephropathy (DN) is a serious complication in diabetes and is characterized by excessive deposition of extracellular matrix proteins in the mesangium and basement membrane. Major typical morphological changes are the result of changes in the extracellular matrix (ECM). One important ECM component, the proteoglycans (PGs), shows a more complex pattern of changes in DN. PGs in basement membranes are decreased. The amounts and structures of heparan sulfate chains are changed, and such changes affect levels of growth factors regulating cell proliferation and ECM synthesis, with cell attachment affecting endothelial cells. Enzymes modulating heparan sulfate structures, such as heparanase and sulfatases, are implicated in DN. Other enzyme classes also modulate ECM proteins and PGs, such as matrix metalloproteinases and serine proteases, such as plasminogen activator, as well as their corresponding inhibitors. The levels of these enzymes and inhibitors are changed in plasma and in the kidneys in DN. Several growth factors, signaling pathways, and hyperglycemia per se affect ECM synthesis and turnover in DN. Therefore, ECM components are being evaluated to be used as markers for DN. [24-27]

## 10. Matrix metalloproteinases

Matrix metalloproteinases (MMPs) are a family of nine or more highly homologous Zn(++)-endopeptidases that collectively cleave most if not all of the constituents of the extracellular matrix.

In diabetic foot ulcers there is an excess of MMPs and a decrease of the tissue inhibitors of MMPs (TIMPs). This imbalance is probably one cause of impaired healing. However, little is known about changes in MMPs during wound healing. A high level of MMP-1 seems essential to wound healing, while an excess of MMP-8 and -9 is deleterious, and could be a target for new topical treatments. The MMP-1/TIMP-1 ratio is a predictor of wound healing in diabetic foot ulcers. [28]

## 11. Risk factors in diabetic foot

Early recognition and management of risk factors is important for reducing morbidity of foot ulceration. These risk factors, as investigated by several teams, [29-33] include age, sex (being male), diabetes duration and type, insulin use, past history of diabetic foot ulcer (DFU) and amputation, lower limb bypass procedures, biomechanical factors such as glycaemia level and poor glycaemic control, dyslipidaemia, sensory and autonomic neuropathy (foot insensitivity to the 5.07 monofilament), absence of reflex and limited joint motion, muscle weakness, callus formation, Charcot deformity, hammer/claw toe deformity, abnormal Achilles tendon reflex, greater body mass ( $\geq 20\text{kg}$ ), arterial insufficiency, vascular disease, skin dryness and fissure (caused by autonomic neuropathy), reduced skin oxygenation and foot perfusion (defined as

ankle-brachial index  $ABI < 0.9$ , toe systolic pressure  $< 45$  mmHg, 13mmHg orthostatic blood pressure fall and 15mmHg higher dorsal foot transcutaneous  $PO_2$ ), diastolic hypertension, impaired vision, as well as socio-environmental risk factors in some communities, such as smoking habits, alcohol consumptions, lack of proper diabetes educations, low income, racial distribution (African Americans, Hispanic Americans and Native Americans face a higher risk), poor personal hygiene and self-care.

Smoking, hypertension, and hyperlipidemia are considered as risk factors due to their effects on the increased occurrence of peripheral arterial occlusive disease in diabetics, which typically involves the tibial and peroneal arteries, but leaves the dorsalis pedis artery unaffected. [14]

There are controversies on some other factor, as some studies could not find a relationship between them and DFU occurrence. They include height, hallux blood pressure, and other foot deformities. [34,35] Also, although some studies could not find a statistically significant association between the length of diabetes and the risk of DFU, other studies mentioned it could be predictive. [36]

Wounds that are penetrated to bone, wounds older than 30 days, recurrent wounds, and presence of peripheral vascular disease increase the risk of wound infections. [37]

The majority (80%) of DFUs is the consequences of neuropathies due to decreasing pain sensation and perception of pressure, to causing muscle imbalance that can lead to anatomic deformities, and to impairing the microcirculation and the integrity of the skin. Therefore, risk factors in neuropathy should also be considered as risk factors in DFU. They include unbalanced age, sex (male gender), duration of diabetes, higher glycemia level, higher levels of LDL and triglycerides, higher von Willebrand factor levels and urinary albumin excretion rate, hypertension, depression and atherosclerosis (ischemia). [34,38,39]

## 12. Symptoms and prediction

Diabetic foot ulcers usually start with the following symptoms:

- Atrophic integument
- Any break in the skin resulted from abnormal wear and tear, injury, or infection
- Sores, ulcers, or blisters on the foot or lower leg
- Persistent pain, which can be a symptom of sprain, strain, bruise, overuse, improperly fitting shoes, or underlying infection.
- Calluses and corns that may be a sign of chronic trauma to the foot
- A claudicating or difficulty walking that can be sign of joint problems, serious infection, or improperly fitting shoes
- Discoloration in feet: black, blue, or red
- Cold feet

- Absent pulses
- Swollen foot or ankle
- Odor
- Fever or chills in association with a wound that can be a sign of a limb-threatening or life-threatening infection
- Redness, which can be a sign of infection, especially when surrounding a wound, or of abnormal rubbing of shoes or socks.
- Swelling of the feet or legs, which can be a sign of underlying inflammation or infection, improperly fitting shoes, or poor venous circulation.
- New or lasting numbness in the feet or legs, a sign of nerve damage from diabetes
- Signs of poor blood circulation, such as:
  - Pain in the legs that increases with walking but improves with rest (claudication)
  - Absence of pedal hair or pallor on elevation (coupled with other symptoms)
  - Hard shiny skin on the legs
  - Toenail fungus, athlete's foot, and ingrown toenails, which may lead to more serious bacterial infections
- Drainage of pus from a wound is usually a sign of infection. Persistent bloody drainage is also a sign of a potentially serious foot problem.

### 13. Classification of foot ulcers

Several schemes have been used to classify diabetic foot ulcers, but none of them has been accepted universally. Following is a list of the most used classifications: [40]

Wagner-Meggitt, the most popular method that was described by Meggitt (1976) and Wagner (1982), [41,42] has been used for decades to classify DFUs in six grades based on the wound's depths and extent of gangrene (table 2):

Grade 0	Intact skin (only foot symptoms like pain exist)
Grade 1	Superficial ulcer
Grade 2	Deep ulcer to tendon, bone or joint
Grade 3	Deep ulcer with abscess or osteomyelitis
Grade 4	Forefoot gangrene
Grade 5	Whole foot gangrene

**Table 2.** Wagner-Meggitt grades of diabetic foot ulcer classification.

University of Texas classification, which has been developed by Armstrong and his colleagues, is a more comprehensive scale and includes risk stratification and expresses tissue breakdown, infection and gangrene separately (table 3). [42] The University of Texas scale showed a better correlation with prognosis and risk of amputation: [14]

Grade 0	Pre-ulcerative site, or healed ulcer.
Grade 1	Ulcer through the epidermis +/- dermis, but not to tendon, capsule or bone
	1A- without infection or ischaemia
	1B- with infection but no ischaemia
	1C- with ischaemia
Grade 2	1D- with ischaemia and infection
	Ulcer to capsule or tendon
	2A- without infection or ischaemia
	2B- with infection but no ischaemia
Grade 3	2C- with ischaemia
	2D- with ischaemia and infection
	Ulcer to bone or joint
	3A- without infection or ischaemia
Grade 3	3B- with infection but no ischaemia
	3C- with ischaemia
	3D- with ischaemia and infection

**Table 3.** University of Texas grades of diabetic foot ulcer classification

Although Texas classification describes the grade of wound in more details, it does not include measures of neuropathy or ulcer area.

S(AD) SAD system builds upon the Wagner classification to include several additional categories: size (area, depth), sepsis, arteriopathy and denervation. [43] Developed by an English group, the S(AD) SAD classification is a validated system with grades 0 to 3, [44] as shown in table 4:

Grade		Size	Sepsis	Arteriopathy	Denervation
Area	Depth				
0	Skin intact	Skin intact	None	Pedal pulses present	Pin pricks intact
1	< 1 cm2	Superficial (skin and subcutaneous tissue)	Surface	Pedal pulses reduced or one missing	Pin pricks reduced
2	1-3 cm2	Tendon, periosteum, joint capsule	Cellulitis	Absence of both pedal pulses	Pin pricks absent
3	> 3 cm2	Bone or joint space	Osteomyelitis	Gangrene	Charcot

**Table 4.** S(AD) SAD classification for diabetic foot ulcer



RYB Color Classification was developed for the nursing literature [45] and has obtained considerable popularity. The system relies purely on a color scheme with no additional considerations. R/Red wounds are those that exhibit pale pink to beefy red granulation tissue and are deemed to be in the inflammatory or proliferative phase. Y/Yellow wounds are marked by pale ivory, yellowish green or brown color, slough of necrotic but moist tissue, and wound exudates. B/Black wounds are marked by black, brown or tan color, and desiccated eschar. The RYB classification is an easy and widely accepted system in the nursing literature and shows the continuum from acute to chronic wounds. Conversely, it is non-specific with no consideration of depth or size, and no consideration of the contributing factor of neuropathy.

PEDIS classification was proposed by the International Working Group on the Diabetic Foot [46,47] and grades the wounds on the basis of five features: perfusions (arterial supply), extent (area), depth, infection and sensation. There are levels of 1 to 4 for each of these factors. The in-depth nature of this system is appropriate for the research community that desires this amount of detail. Every lesion is described (for example P2E1D2I1S2), according to table 5:

Grade	Perfusion (P)	Extent/size (E) (cm <sup>2</sup> )	Depth/tissue loss (D)	Infection (I)	Sensation (S)
1	no symptoms/ signs of PAD		Superficial full-thickness ulcer	no symptoms/signs	No loss of protective sensation
2	symptoms or signs of PAD, but not CLI		Ulcer penetrating below dermis to skin structures	Inflammation of skin only	Loss of protective sensation
3	CLI		All subsequent layers of foot, including bone/ joint	Extensive erythema deeper than skin	
4				Systemic inflammatory response syndrome (SIRS)	

**Table 5.** Grades of PEDIS classification for diabetic foot ulcer

Determination of the level of infection in PEDIS classification system is based on the Severity Classification guideline published by the Infectious Disease Society of America (IDSA), as shown in table 6:

Clinical Manifestation of Infection	Infection Severity	PEDIS Grade
Wound lacking purulence or any manifestations of inflammation.	Uninfected	1
Presence of ≥ 2 manifestations of inflammation (purulence, or erythema, pain, tenderness, warmth, or induration), but any cellulitis/erythema extends ≤ 2 cm around the ulcer, and infection is limited to the skin or superficial subcutaneous tissues; no other local complications or systemic illness.	Mild	2
Infection (as above) in a patient who is systemically well and metabolically stable, but which has ≥ 1 of the following characteristics: cellulitis extending > 2 cm, lymphangitic streaking, spread beneath the superficial fascia, deep-tissue abscess, gangrene, and involvement of muscle, tendon, joint, or bone.	Moderate	3
Infection in a patient with systemic toxicity or metabolic instability (e.g., fever, chills, tachycardia, hypotension, confusion, vomiting, leukocytosis, acidosis, severe hyperglycemia, or azotemia).	Severe	4

**Table 6.** Severity classification guideline according to IDSA

DEPA Scoring System, is the newest DFU classification system, in which D stands for depth of the ulcer, E for extent of bacterial colonization, P for phase of ulcer, and A for associated etiology (table 7). [48] Ascending scores, from 1 to 3, are assigned for increasing levels of intensity in each category (see the table below). For instance, an ulcer involving soft tissue receives a 2. Contamination of this ulcer receives a 1. The ulcer is in the inflammatory phase, generating a 2 score, and has an underlying bony deformity, generating another 2 score. Accordingly, this ulcer has a total score of 7. Ulcers with a total score of 6 or less are considered “low grade” ulcers. Recommended treatment measures include oral antibiotics (if infected), blood sugar control (type not specified) and debridement. Those with a total score of 7 to 9 are deemed “moderate grade” wounds that one would treat with parenteral antibiotics, insulin, debridement, healing promoting agents and pressure relieving methods. The “high grade” lesions, those with a total score between 10 and 12, require a conservative trial including parenteral antibiotics, insulin, debridement, healing promoting agents and vascular reconstruction. The authors of the DEPA classification system offered acute ischemia patients a below-knee amputation; however, other practitioners may offer revascularization or other interventions. The scores of 11 to 12 are prognostic for amputation and if these are heel ulcers, they were even more likely to lead to amputation. Scores of 10 or greater predict difficulty with healing, while scores of 6 or less indicate probable healing.

DEPA Score	Score		
	1	2	3
Depth of the ulcer	Skin	Soft tissue	Bone
Extent of bacterial colonization	Contamination	Infection	Necrotizing infection <sup>a</sup>
Phase of ulcer	Granulating <sup>b</sup>	Inflammatory <sup>c</sup>	Nonhealing <sup>d</sup>
Associated etiology	Neuropathy	Bone deformity	Ischemia <sup>e</sup>

<sup>a</sup> Infected ulcer with surrounding cellulitis or fasciitis.

<sup>b</sup> Evidence of granulation tissue formation.

<sup>c</sup> Hyperemic ulcer with no granulation tissue <2 weeks' duration.

<sup>d</sup> Nongranulating ulcer >2 weeks' duration.

<sup>e</sup> Clinical signs and symptoms of chronic lower-limb ischemia.

**Table 7.** Scores and definitions of DEPA scoring system

## 14. Vascular impaired in foot ulcers

Vascular impairment is one of the most important causes of DFU, and in addition to hyperglycemia, is the main impediment in healing the ulcers. Smoking cessation, diet improvement and controlling total and LDL cholesterol, antiplatelet drug treatment, and maintaining an optimum blood pressure will help reducing the impact of vascular impairment on ulcer healing. Vascular impairment in foot ulcers has been discussed in more details in 7.

## 15. Angiogenesis in foot ulcer

When a tissue is injured, blood from the broken capillaries streams into the wound. This blood carries platelets and fibrinogen. Fibrinogen is activated in response to the exposed epithelium to form a fibrin mesh that traps platelets. Platelets also adhere to the ruptured blood vessels, preventing further blood loss. Moreover, platelets come into contact with damaged ECM components; they release clotting factors, leading to the formation of a blood clot within the wound site. The activated platelets in the wound release chemical stimuli such as platelet-derived growth factor (PDGF), transforming growth factor- $\beta$  (TGF- $\beta$ ), and vascular endothelial growth factor (VEGF). [49,50] Fibroblasts stimulated by these chemoattractants produce

collagen, which is a major component of the ECM, a scaffold onto which the endothelial cells can migrate to create and extend the vascular network. Fibroblasts also secrete PDGF and TGF- $\beta$ , as well as VEGF. This cocktail of growth factors stimulates the endothelial cells of vessels in the nearby healthy tissue to release proteases such as MMPs. [51] MMPs digest the basement membrane, allowing endothelial cells to escape the confines of their parent vessels. [52] VEGF, EGF, bFGF, and TGF- $\beta$  stimulate the systematic rearrangement of endothelial cells from blood vessels. The cells proliferate, elongate, and align to form a capillary sprout, extending away from the original vessel. [49] This is the beginning of the angiogenesis process. Then, polarized endothelial cells are positioned with a luminal and an abluminal surface forming tubular structures, which act as a multipurpose barrier between the flowing blood and the extravascular tissue. Periendothelial cells, such as pericytes, fibroblasts, and smooth muscle cells, reinforce these tubular endothelial networks. This process is oxygen dependent. Oxygen is required for collagen deposition. Hypoxia causes the hypoxia-inducible factor (HIF) to up-regulate the production of VEGF.

Sprout extension is facilitated by endothelial cell proliferation and further migration toward the chemical attractant.

Vasculogenesis, the formation of blood vessels from the differentiation of progenitor cells, also plays a part in the formation of new blood vessels during this stage of wound healing. [53] Progenitor cells differentiate into early endothelial progenitor cells in the bone marrow and further differentiate into late endothelial progenitor cells in the vasculature system before arriving at the site of vessel formation. [52]

The joining of two capillary sprouts within a healing wound forms a loop through which blood can flow and new sprouts develop from this vessel thus propagating angiogenesis. [54] This capillary extension allows oxygen and other critical nutrients to be transported further into the injured region. This, in turn, allows the macrophage and fibroblast fronts to migrate further into the wound, and thus the healing unit progresses into the injured tissue. [54] When the unit has completely swept through the wound site, blood vessels are networked over the entire space and oxygen levels are returned to normal. Oxygen binds to HIF and leads to a decreased synthesis of VEGF. This ends the angiogenesis process. [49]

Usually diabetes causes excessive and deficient angiogenesis (table 8). Therapeutic factors that can regulate angiogenesis in the diabetic foot conditions are considered as successful treatments for DFU.

## 16. Diagnostic tests and prediction

A task force of the Foot Care Interest Group of the American Diabetes Association (ADA) released a report in 2008 that specifies recommended components of foot examinations for patients with diabetes (table 9). [55]

Defective angiogenesis		Excessive angiogenesis	
Phenotype	Causes	Phenotype	Causes
Reduced angiogenesis and collateral formation	Reduced VEGF, FGF, EPC circulation, cytokines, ECM/BM degradation; increased AGEs and MMP	Retinal capillary occlusion	Elevated intraocular pressure
Vascular occlusion, inflammation	Increased free fatty acids, polyol pathway, cytokines, ICAM, VCAM	Increased vascular permeability	Increased VEGF
Reduced wound healing; transplant failure	Reduced VEGF and growth factors; sorbitol-inositol imbalance; increased ACE, Ang-II and tissue factor mRNA	Capillary sprouting	Increased VEGF, FGF, PDGF; cytokines (TGF- $\beta$ ); integrins
Embryonic vasculopathy (anomalous vasculogenesis and angiogenesis)	Reduced VEGF, IL-1, TGF- $\beta$	Vascular remodeling	Increased laminin, fibronectin, collagen IV, ECM components, lipodosis

**Table 8.** Comparison of aberrant angiogenesis under diabetes.

Risk Category	Definition	Treatment Recommendation	Suggested Follow-up
0	No LOPS, no PAD, no deformity	Consider patient education on foot care, including information on appropriate footwear.	Annually (by generalist and/or specialist)
1	LOPS $\pm$ deformity	Consider prescriptive or accommodative footwear. Consider prophylactic surgery if deformity is not able to be safely accommodated in shoes. Continue patient education.	Every 3-6 months (by generalist or specialist)
2	PAD $\pm$ LOPS	Consider the use of accommodative footwear. Consider a vascular consultation for combined follow-up.	Every 2-3 months (by specialist)
3	History of ulcer or amputation	Consider patient education on foot care. Consider vascular consultation for combined follow-up if PAD present.	Every 1-2 months (by specialist)

LOPS, loss of protective sensation; PAD, peripheral arterial disease. Adapted from [55]

**Table 9.** Risk classification system of the Task Force of the Foot Care Interest Group of the ADA



Foot deformity is an important diagnostic sign for future foot ulcer. In addition to Charcot arthropathy, hyperextension of the metatarsal-phalangeal joint with interphalangeal or distal phalangeal joint flexion leads to hammer toe and claw toe deformities, respectively. The deformities may lead to ulceration by continuous improper contact with the footwear.

In examining for vascular abnormalities of the foot, the dorsalis pedis and posterior tibial pulses should be palpated and characterized as present or absent. Claudication, loss of hair, and the presence of pale, thin, shiny, or cool skin are physical findings suggestive of potential ischemia. [56] If vascular disease is a concern, measuring the ankle brachial index (ABI) can be used in the outpatient setting for determining the extent of vascular disease and need for referral to a vascular specialist. The ABI is obtained by measuring the systolic blood pressures in the ankles (dorsalis pedis and posterior tibial arteries) and arms (brachial artery) using a handheld Doppler and then calculating a ratio. However, in patients with calcified, poorly compressible vessels or aortoiliac stenosis, the results of the ABI can be complicated. [57]

The loss of pressure sensation in the foot has to be identified using a 10-gauge monofilament as a significant predictive factor for the likelihood of ulceration. [57]

High vibration perception thresholds (VPTs) using a biothesiometer or a tuning fork, high plantar pressure and 10-gauge monofilaments are used as reliable methods to identify those at risk of future ulceration. [36]

## 17. Foot amputation

Despite all efforts to treat ischemic and neuropathic ulcers, sometimes the lower-extremity is non-viable and amputation is inevitable. Non-traumatic amputations are high in poorer countries and in uneducated people in wealthy countries. Amputees suffer from direct surgical morbidity and mortality, inadequate and delayed rehabilitation. Also, amputees attract great amount of care from a multidisciplinary team and put additional pressure on countries' health systems and disability insurances.

The indications for amputation in patients with diabetes are often multiple, mostly a non-healing ulcer, or frequent gangrene and infection occurring simultaneously. [58] Whether primary minor amputation is beneficial in comparison with primary major amputation (below knee) is still controversial. Digital toe amputation eventually leads to limb loss, while a major amputation lowers the risk of re-amputation. [59] Re-amputation widely rates from 21% to 60%, and is greatest in the first 6 to 12 months after the first amputation. [60,61] Once hallux has gone under amputation, changes in mechanical force and pressure on the foot may increase the likelihood of developing further lesions, most probably within 6 months. [62] Studies by Byrne et al. 1992 and Yeager et al. 1998 showed that revascularization may not prevent re-amputation as patients undergoing revascularization procedures are likely to have severe ischaemic disease. [63,64]

## 18. Treatments

Any diabetic patient with a skin break below the knee that has not healed with appropriate care in 2 weeks should be referred urgently to a suitable specialist for an assessment. Assessment of the cause of an ulcer helps clinicians in determining the most appropriate treatment. The assessment includes testing for sensation, palpating for foot pulses, measuring the ankle-brachial pressure index (ABPI) and toe pressures, and often undertaking color-flow duplex ultrasonography. Patients with lower-limb tissue loss from ischemia should be assessed by a vascular surgeon. Magnetic resonance angiography (MRA) or conventional intra-arterial digital subtraction angiography could be needed to help plan the reconstruction. [65-68]

DFU can be successfully treated by a multidisciplinary team consists of diabetologist, shoemaker, orthopedist, psychologist, vascular and general surgeons, podologists, radiologists, educators, nurses and rehabilitation team. [35]

Surgeons (general, vascular, orthopaedic, plastic, podiatric) generally become involved in treating severe tissue infection, especially when gangrene or underlying osteomyelitis remain despite antibiotic treatment. [69] The main purpose of surgery is to remove infected and necrotic soft and bony tissue back to a healthy base that will support granulation tissue and allow healing by secondary intention.

Many diabetic patients with underlying ischemia will need revascularization to provide an adequate arterial blood supply in order to achieve a better healing and resolve underlying infection. Up to a 90% 10-year limb-salvage rate has been demonstrated with surgical bypass procedures of the lower extremity. [70] A standard treatment for ischemic ulceration is still femorodistal bypass with an autogenous tissue (usually saphenous vein), although this treatment is not readily available for all patients. However, it seems reasonable to attempt healing of ischemic and neuroischemic ulcers with drugs before considering revascularization.

Conventional treatments for diabetic peripheral neuropathy include tricyclic compounds, serotonin-norepinephrine reuptake inhibitors (e.g. duloxetine), anticonvulsants (e.g. pregabalin), opiates, membrane stabilizers, the antioxidant alpha lipoic acid and others. [33]

The selection of wound dressings is also an important component of diabetic wound care management. Advanced wound dressing products can help alter the wound environment to optimize healing conditions. Characteristics of a successful wound dressing will be discussed later.

If not managed properly, diabetic foot ulcers are at high risk for infection. Open wounds can be contaminated or infected with microorganisms and even virulent pathogens. The generally accepted clinical definition of infection is the presence of purulent secretions or at least two signs or symptoms of inflammation (erythema, warmth, tenderness, pain, and induration). While ischemia or neuropathy signs such as friable tissue, wound undermining, and foul odor imply infection. [71] Most diabetic foot infections do not produce systemic signs, such as fever

or leukocytosis, but when they are present, they typically suggest that any accompanying infection is severe.

To assess the infection, clinicians should obtain material for a wound culture. Tissue specimens are strongly preferred to wound swabs, because they provide more sensitive and specific results. Tissue can be obtained by scraping of the base of the ulcer with a scalpel or dermal curette (curettage) or by wound biopsy. Aseptically obtained aspirates of pus (purulent secretions) or tissue fluid can also provide good specimens for culture. The specimen should be processed for both aerobic and anaerobic cultures and a gram-stained smear, if possible. Blood obtained for a complete blood count (and leucocyte differential), basic serum chemistry panels, and inflammatory markers (erythrocyte sedimentation rate [ESR] or C-reactive protein) can help define the severity of the infection. [72]

Usually, plain radiographs of the foot will help to identify foreign bodies, gas in the tissues, or evidence of osteomyelitis. More sophisticated imaging tests (the best of which being MRI) might be needed to better define the presence or absence of bone or deep soft-tissue infection.

Infection of bone underlying a foot ulcer is an especially difficult diagnostic and therapeutic problem. Osteomyelitis is probably present if the bone is visible or palpable by probing. Bone infection must usually be present for at least 2 weeks before it can be regarded as the cause of abnormalities seen on plain radiographs. Most nuclear medicine tests (e.g., technetium bone scans or labeled leucocyte scans) are more sensitive than plain radiography, but are relatively non-specific and less accurate than MRI. The gold standard test for osteomyelitis is a bone biopsy sample processed for culture and histology. [73]

All available data are required to decide whether infections are safe to treat on an outpatient basis, or whether hospital care is needed for medical, diagnostic, surgical, or psychosocial reasons. [30]

Antibiotics are selected largely based on the probable causative organisms, taking into account any known local antibiotic resistance patterns. Patients with severe infections need parenteral treatment, at least initially; oral therapy is often adequate for those with mild or moderate infections. [74]

Topical antimicrobials are often effective for mildly infected ulcers, however, some topical antiseptics can impair wound healing, but dressings containing silver or iodine seem to be safe, and possibly useful (see later). [75]

The aim of antimicrobial therapy is to cure the infection, not to heal the wound; extended treatment increases the risk of drug-related toxic effects and development of antibiotic resistance. Antibiotic treatment without off-loading a plantar wound (i.e., the relieving of a mechanical load) is unlikely to result in ulcer healing (see later).

Bone infection is best treated by surgical resection of all infected and necrotic bone, but retrospective studies suggest that long-term treatment (at least for 4–6 weeks) with drugs that penetrate well into bone (e.g., fluoroquinolones) can often produce a remission of infection. [73]

## 19. Treatment-based classification system for the diabetic foot

Recently developed treatments for diabetic foot ulcers include the use of bone marrow-derived stem cells, [76] use of human or bioengineered skin equivalents, [77,78] growth-factor therapy (such as using PDGF or G-CSF) [79,80] and negative pressure wound therapy (NPWT) [81]. Hyperbaric oxygen treatment (HBOT) seems to reduce the risk of major amputation, but not the time to ulcer healing or the rate of minor amputation. [82,83] Routine debridement of devitalized tissue at follow-up visits is widely recommended. [84] Maggot (larval) biotherapy seems to be effective for debridement [85] and acceleration of healing, [86,87] and perhaps also in reducing antibiotic use and risk of amputation. [88] A recently developed natural-based medicine, ANGIPARS™, has shown excellent effects on wound closure and shortening the wound healing period in both diabetic foot ulcers [89-93] and pressure ulcers, [94,95] via strong angiogenesis, anti-oxidant, [96] anti-coagulant and properties.

Negative Pressure Wound Therapy (NPWT) is a sealed wound-care system and is particularly indicated for a large chronic persistent wounds and acute complicated wounds. The system consists of an electronically controlled pump and a foam dressing that drains the wound. [97] An adjustable negative pressure is applied via an airtight adhesive film that covers the wound. NPWT drains wound exudates and is thought to promote blood circulation and healing. [98] NPWT benefits include increased local blood flow, [99] rapid wound granulation, increased number of active fibroblasts and macrophages, [99] epithelial isolation, migration and contraction, [94,95] reduction of dressing changes, [100] reduced infection risk, [101] reduced treatment costs, [59] control of exudates that contain harmful fluid and by-products of tissue damage, [99,102] concurrent rehabilitation, [103] and better patient tolerance. [104] However, it is impossible to conclude from the studies that NPWT performs absolutely or relatively better than the control treatments in terms of wound healing. [105] Only one study showed a statistically significant difference in wound healing in the test group compared to the control. Although a few studies showed some NPWT effect in shortening the wound closure time, its total efficacy cannot be fully concluded because the studies were not properly designed in terms of methods of measurement, blinding and follow-ups. [106] There was high potential for bias and diagnostic heterogeneity in the studies. To approve if NPWT has a positive effect on wound healing, further research clinical trials of good methodological quality are required. Moreover, the FDA recently issued a report on six deaths and 77 other complications that were reported within a two-year period in connection with NPWT. All the deaths were caused by acute hemorrhages, and known contraindications for NPWT (e.g. a large blood vessel exposed) had clearly been overlooked. Many of the deaths occurred in outpatient care or care homes, which highlights the need to monitor therapy. [59,107]

Hyperbaric Oxygen Treatment (HBOT), which is used for Wagner Grade 3 diabetic wounds that have failed to resolve after a 30-day course of standard treatment, is the delivery of pure oxygen to patients at higher than normal atmospheric pressures to compensate shortage of blood oxygen due to vascular impairment. [83] The usual pressure for treating DFU is 1.4 to 3 atmospheres absolute pressure (ATA) - with an optimum of 2 ATA - for a compression time of 60 to 120 minutes - with an optimum of 90 minutes - during a course of multiple treatments.



[97,108,109] This high pressure results in an increase in the concentration of oxygen in the blood and an increase in the diffusion capacity to the tissues, which, in turn, stimulates neovascularization and fibroblast replication and increases phagocytosis and leukocyte-mediated killing of bacterial pathogens in the wound. [109] A long benefits list of increasing the tissue oxygen is made through several studies [50]: modulation of the production of nitric oxide, promotion of cellular proliferation, stimulation of capillary budding, alteration of ischemic effect, modification of the effect of growth factors and cytokines, acceleration of collagen deposition, reduction of edema, modulation of the immune system response, accelerated microbial oxidative killing, and enhancement of oxygen radical scavengers, thereby reducing ischemia reperfusion injury.

There is enough good evidence that HBOT decreases risk of amputation in patients with complicated or infected DFU. [110,111] Many studies have shown that HBOT results in partial or complete wound healing. Some studies also showed that HBOT in combination with surgery and antibiotics can be used to treat refractory osteomyelitis. HBOT is reasonably safe when administered by experienced practitioners after careful patient screening and selection. [112]

Wound dressing, widely used to cure the infected wounds, is the most important component of a successful wound care. There are a number of available dressing types to consider. Although there is a shortage of published trials to support the use of one type of dressing compared to another, [113] the characteristics of specific dressing types can prove beneficial depending on the characteristics of the individual wound. An ideal dressing should contribute to a moist wound environment, absorb excessive exudates, and not increase the risk for infections. [114] Dressing changes and wound inspection should occur on a daily basis. [113] Saline-soaked gauze dressings, for example, are inexpensive, well tolerated, and contribute to an atraumatic, moist wound environment. Foam and alginate dressings are highly absorbent and can aid in decreasing the risk for maceration in wounds with heavy exudates.

The process of autolysis is important in wound care. If an occlusive dressing is provided as a barrier to the outside environment, the body's own phagocytic processes will provide debridement of wounds. These products range from occlusive films such as Tegaderm, which are permeable to air and water vapor, but impermeable to fluid and microorganisms to hydrocolloids such as DuoDerm, which are also occlusive but provide absorption of exudates in addition to maintaining a moist environment for autolysis. For heavily exudative wounds, there are a range of absorptive products, including various hydrophilic foam dressings, hydrogels, hydrofibers, and alginates, which can absorb up to 20 times their weight. [115]

Silver dressings have been used for decades with little significant toxicity to cure infected wounds. Silver has a very broad spectrum of microbial coverage, including yeast, fungi, mold, and even antibiotic-resistant organisms, when used at appropriate concentrations. Silver ion binds to negatively charged particles such as proteins, DNA, RNA and chloride ions. [116,117] Introduced in 1968, silver sulfadiazine is known to release active silver ion gradually for a longer time. [118] Nanocrystalline silver dressing developed since 1990s to fix the shortcomings of this type of dressing. It contains two layers of high-density polyethylene net sandwiching a layer of rayon/polyester gauze. The outer layer is coated with a nanocrystalline (<20 nm), uncharged form of silver, and the inner layer helps maintain a moist environment for



wound healing. [116] This sandwich provides a sustained release of silver into the wound due to the low affinity of Ag<sup>0</sup> to the negatively-charged particles in the wound. Other advantage of nanocrystalline silver dressing is less frequency of dressing changes compared the standard silver dressings, which must be changed up to 12 times a day. This brings less disruption to the wound healing bed.

Growth factors play the most important role in orchestrating the cells in wound bed along the process of wound healing. When a wound occurs, platelets and fibroblasts recruited to the wound bed, start secreting growth factors, such as PDGF, VEGF, EGF, G-CSF (GM-CSF), and TGF- $\beta$ . G-CSF or GM-CSF has been found to enhance the activity of neutrophils, macrophages, keratinocytes, and fibroblasts, and increase VEGF production in diabetic patients. [119,120] A meta-analysis study revealed that, although the use of G-CSF did not significantly accelerate the resolution of infection in diabetic wounds, there was a decreased likelihood of amputation and the need for other surgical therapies in treated wounds. [121]

In a study by Steed et al., patients who were treated with recombinant human platelet-derived growth factor (rhPDGF) showed statistically significant higher percentage of wound healing (48% vs. 25% in control group), as well as greater reduction in wound size. Now, known as becaplermin or Regranex, rhPDGF is used in treatment regimens for DFU. [122,123]

Stem cell therapy has emerged as a promising treatment modality aiming to address the underlying pathophysiology of DFU. Stem cells secrete chemokines and growth factors (especially EGF, VEGF and fibronectin), which promote angiogenesis and ECM remodeling to mobilize wound healing. Stem cells that have been studied for wound healing can be classified in two groups of allogenic and autologous, based on where their origins are. Placental or amnion-derived mesenchymal stem cells and embryonic stem cells are categorized as allogenic stem cells. On the other hand, bone marrow-derived endothelial progenitor cells, bone marrow-derived mesenchymal stem cells, hematopoietic stem cells, and mesenchymal stem cells derived from adipose tissue are the autologous stem cells. [124] Placenta-derived MSCs are shown to be more effective in chronic wound healing. [125,126] Also, isolated ESC-derived EPCs were shown to improve re-epithelialization when injected subcutaneously into or applied topically on to the wound. [127] In another study, bone marrow-derived stem cells were applied on to chronic wounds that were not healed for more than a year. The treated wounds showed signs of closures within 2-4 weeks post-treatment, where there was a direct correlation between the number of cells applied and the percent decrease in wound size. [128] Another study also showed 81% limb salvage when bone marrow-derived stem cells were injected to the wounds that were otherwise candidates for amputations. [129] Hematopoietic stems cells (HSCs), harvested from either bone marrow or peripheral blood, are shown to enhance wounds healing in both the inflammatory and proliferative phases of DFU. [130] Despite promising results, the majority of these studies are conducted in animals and the few human studies are not providing enough documents to include the stem cell therapies in fixed treatments protocols of foot ulcers. More studies are required to demonstrate the safety, efficacy and improved healing rates. The main obstacle stem cell therapy strategies are facing is a proper system of delivering cells to the precise location within the wound. [124] One other

major reason for limited adoption of stem cells or their products is the cost of obtaining and preparing the cells. [74]

Bioengineered skin and skin grafts have also been investigated for wound healing. Tissue-engineered skin substitutes are usually categorized in allogenic cell-containing and autologous cell-containing matrices (both carry living keratinocytes or fibroblasts), as well as acellular matrices. They all release growth factors to stimulate wound healing. [131,132] Some degrees of healing have been demonstrated through some studies, [133-138] however, because the results were susceptible to bias due to the poor methodology, more studies are required to confirm those results. [139]

ANGIPARS™, an herbal-origin drug, has shown promising results during phase II and III, and post-marketing phase IV studies. [90-93,140] The main ingredient of this medicine is an herb, called *Melilotus officinalis* (yellow sweet clover). Melilotus extracts are shown to have anti-inflammation, anti-spasmodic, aromatic, carminative, diuretic, emollient, mildly expectorant, mildly sedative and vulnerary effects. Therefore, ANGIPARS™ was expected and proved to possess angiogenesis, anti-oxidative and anti-inflammatory properties, and to be able to improve the local blood circulation and provide trace elements effective in the wound healing. Excessive studies had shown that it was effective in treating DFU and decubitus ulcer, and in preventing from amputation. In those studies, an obvious wound healing was observed after a 4-week therapy period. The Producer suggests the following indications and clinical uses: [141]

- Adult patients with diabetes type 1 and 2 suffering from single and multiple foot ulcer(s) in Wagner's grade 1 and 2, and infection-controlled grade 3.
- Patients with foot ulcers that are caused due to peripheral neuropathy or other neuropathies, foot deformities, traumas, using unsuitable shoes, history of foot ulcer or amputation, joint movement limitation, uncontrolled hyperglycemia, prolonged diabetes, etc.

A widely-collective document registration on case reports is required to confirm ANGIPARS™ as a potent drug in DFU treatment. [74]

## 20. Foot care and management of foot ulcer

One of the easiest, least expensive and most effective ways for preventing foot complications could be careful inspection of the diabetic foot on a regular basis. [14]

Initial management consists of cleansing of the wound, debriding of any necrotic or gangrenous material, and the probing (preferably with a blunt sterile metal instrument) for foreign bodies or exposed bone.

There is no doubt that one of the most important parts of DFU treatments or prevention plans should be off-loading, meaning pressure relief on ulcer. High plantar pressure is usually caused by bony deformity or displacement of soft tissues, and may lead to ulceration and failure to heal. Ulcers can also be caused by contact between the dorsal surface of deformed toes and footwear that does not provide adequate toe room.

A successful off-loading through a total contact cast can decrease the pressure from 1000 kPa to less than 100 kPa. [142] Total casts should be properly made and changed at least weekly. It has been shown that patients bearing ulcer are not usually complaint with a removable off-loading device. [143] Various ambulatory braces, splints, modified shoes, and sandals can off-load the plantar surface or immobilize the foot and ankle or both. A modified half-shoe can help off-load pressure from half of the foot. Felted-foam, soft polymeric insoles and orthoses with load-isolation regions are also used to smoothen the inner layers of shoes. [144] For interdigital lesions, the close or overlapping toes must be separated. Ulcers on the plantar aspect of the heel take longer to heal than those on the forefoot in total contact casts and could benefit from special shoes without a rear-foot platform.

DFU patients are encouraged to reduce their activity levels temporarily. Patients are typically less active in total contact casts than in healing shoes, presumably because of the bulk and weight of the irremovable device. Increased activity, with the consequent high cumulative load, can delay or prevent ulcer healing. [145]

## 21. Prevention of diabetic ulcer formation

Lifetime prevalence of DFU development is estimated 25% [29,32]. Recurrence rate is also estimated to range from 28% at 12 months to 100% at 40 months. [146] At least 40% of amputations in diabetic patients can be prevented with a team approach to wound care.

Early detection of potential risk factors for ulceration can decrease the frequency of wound development. Diabetic patients should be educated regarding the importance of maintaining good glycemic control, wearing appropriate footwear, avoiding trauma, and performing frequent self-examination. They are also recommended to have their feet professionally examined at least annually (see table 9, according to the Foot Care Interest Group of the ADA) [55] to determine predisposing conditions to ulceration. In both self- and professionally-examining the foot, visual inspection of the bare foot should be performed in a well-lit room. The examination should include an assessment of the shoes; inappropriate footwear can be a contributing factor to the development of foot ulceration. In the visual inspection of the foot, the evaluator should check between the toes for the presence of ulceration or signs of infection. The presence of callus or nail abnormalities should be noted. Additionally, a temperature difference between feet is suggestive of vascular disease.

The foot should also be examined for deformities. The Charcot arthropathy is a commonly mentioned deformity in some affected diabetic patients.

Regardless ulcer treatment method, patients should slowly change to full activity and weight-bearing, using appropriate custom-made therapeutic footwear, while hyperglycemia, and neuron and vascular conditions are under a careful watch. Moreover, a proper patient and care-giver education, and regular foot care are of extreme importance in preventing DFU recurrence.

## Author details

Bardia Farzamfar<sup>1</sup>, Reza Nazari<sup>2</sup> and Saeed Bayanolhagh<sup>3</sup>

\*Address all correspondence to: farzamfar@inoclon.com

1 Research and Development Department, G. Innovative Biotech Co., Alborz Province, Iran

2 Dept. Laboratory Medicine and Pathobiology, University of Toronto, Ontario, Canada

3 Saeed Bayanolhagh, Iranian Research Center for HIV/AIDS, Tehran University of Medical Sciences, Tehran, Iran

## References

- [1] Jeffcoate WJ, Harding KG. Diabetic foot ulcers. *Lancet* 2003 May 3;361(9368):1545-1551.
- [2] Boulton AJ. The diabetic foot: a global view. *Diabetes Metab Res Rev* 2000 Sep-Oct;16 Suppl 1:S2-5.
- [3] Boulton AJ, Vileikyte L, Ragnarson-Tennvall G, Apelqvist J. The global burden of diabetic foot disease. *Lancet* 2005 Nov 12;366(9498):1719-1724.
- [4] Bartus CL, Margolis DJ. Reducing the incidence of foot ulceration and amputation in diabetes. *Curr Diab Rep* 2004 Dec;4(6):413-418.
- [5] Margolis DJ, Malay DS, Hoffstad OJ, Leonard CE, MaCurdy T, Tan Y, et al. Economic Burden of Diabetic Foot Ulcers and Amputations: Data Points #3. Data Points Publication Series Rockville (MD); 2011.
- [6] Ragnarson Tennvall G, Apelqvist J. Health-economic consequences of diabetic foot lesions. *Clin Infect Dis* 2004 Aug 1;39 Suppl 2:S132-9.
- [7] Lemaster JW, Reiber GE. Epidemiology and Economic Impact of Foot Ulcers. In: Boulton AJ, Cavanagh PR, Rayman G, editors. *The Foot in Diabetes*. 4th ed.: John Wiley & Sons; 2006. p. 3.
- [8] Kernich CA. Patient and family fact sheet. Peripheral neuropathy. *Neurologist* 2001 Sep;7(5):315-316.
- [9] Yagihashi S, Yamagishi S, Wada R. Pathology and pathogenetic mechanisms of diabetic neuropathy: correlation with clinical signs and symptoms. *Diabetes Res Clin Pract* 2007 Sep;77 Suppl 1:S184-9.
- [10] Peripheral Neuropathy. Available at: <http://www.ncbi.nlm.nih.gov/pubmedhealth/PMH0001619/>.

- [11] Zilliox L, Russell JW. Treatment of diabetic sensory polyneuropathy. *Curr Treat Options Neurol* 2011 Apr;13(2):143-159.
- [12] Garces-Sanchez M, Laughlin RS, Dyck PJ, Engelstad JK, Norell JE, Dyck PJ. Painless diabetic motor neuropathy: a variant of diabetic lumbosacral radiculoplexus Neuropathy? *Ann Neurol* 2011 Jun;69(6):1043-1054.
- [13] Real JT, Valls M, Ascaso P, Basanta ML, Viguer AA, Ascaso JF, et al. Risk factors associated to hospitalization in diabetic patients with foot ulcers. *Med Clin (Barc)* 2001 Nov 24;117(17):641-644.
- [14] Armstrong DG, Lavery LA. Diabetic foot ulcers: prevention, diagnosis and classification. *Am Fam Physician* 1998 Mar 15;57(6):1325-32, 1337-8.
- [15] Bowering CK. Diabetic foot ulcers. Pathophysiology, assessment, and therapy. *Can Fam Physician* 2001 May;47:1007-1016.
- [16] Efrati S, Gall N, Bergan J, Fishlev G, Bass A, Berman S, et al. Hyperbaric oxygen, oxidative stress, NO bioavailability and ulcer oxygenation in diabetic patients. *Undersea Hyperb Med* 2009 Jan-Feb;36(1):1-12.
- [17] Lavery LA, Peters EJ, Williams JR, Murdoch DP, Hudson A, Lavery DC, et al. Reevaluating the way we classify the diabetic foot: restructuring the diabetic foot risk classification system of the International Working Group on the Diabetic Foot. *Diabetes Care* 2008 Jan;31(1):154-156.
- [18] Schaper NC, Nabuurs-Franssen MH. The diabetic foot: pathogenesis and clinical evaluation. *Semin Vasc Med* 2002 May;2(2):221-228.
- [19] Frykberg RG. Diabetic foot ulcers: pathogenesis and management. *Am Fam Physician* 2002 Nov 1;66(9):1655-1662.
- [20] Searles JM, Jr, Colen LB. Foot reconstruction in diabetes mellitus and peripheral vascular insufficiency. *Clin Plast Surg* 1991 Jul;18(3):467-483.
- [21] Huijberts MS, Schaper NC, Schalkwijk CG. Advanced glycation end products and diabetic foot disease. *Diabetes Metab Res Rev* 2008 May-Jun;24 Suppl 1:S19-24.
- [22] Zochodne DW. Diabetic polyneuropathy: an update. *Curr Opin Neurol* 2008 Oct;21(5):527-533.
- [23] Paraskevas KI, Baker DM, Pompella A, Mikhailidis DP. Does diabetes mellitus play a role in restenosis and patency rates following lower extremity peripheral arterial revascularization? A critical overview. *Ann Vasc Surg* 2008 May-Jun;22(3):481-491.
- [24] Ziyadeh FN. The extracellular matrix in diabetic nephropathy. *Am J Kidney Dis* 1993 Nov;22(5):736-744.



- [25] Jackle-Meyer I, Szukics B, Neubauer K, Metze V, Petzoldt R, Stolte H. Extracellular matrix proteins as early markers in diabetic nephropathy. *Eur J Clin Chem Clin Biochem* 1995 Apr;33(4):211-219.
- [26] Mason RM, Wahab NA. Extracellular matrix metabolism in diabetic nephropathy. *J Am Soc Nephrol* 2003 May;14(5):1358-1373.
- [27] Striker GE, Eastman RD, Striker LJ. Diabetic nephropathy: molecular analysis of extracellular matrix and clinical studies update. *Nephrol Dial Transplant* 1996;11 Suppl 5:58-61.
- [28] Muller M, Trocme C, Lardy B, Morel F, Halimi S, Benhamou PY. Matrix metalloproteinases and diabetic foot ulcers: the ratio of MMP-1 to TIMP-1 is a predictor of wound healing. *Diabet Med* 2008 Apr;25(4):419-426.
- [29] Nyamu PN, Otieno CF, Amayo EO, McLigeyo SO. Risk factors and prevalence of diabetic foot ulcers at Kenyatta National Hospital, Nairobi. *East Afr Med J* 2003 Jan;80(1):36-43.
- [30] Morrison WB, Ledermann HP. Work-up of the diabetic foot. *Radiol Clin North Am* 2002 Sep;40(5):1171-1192.
- [31] Pecoraro RE, Reiber GE, Burgess EM. Pathways to diabetic limb amputation. Basis for prevention. *Diabetes Care* 1990 May;13(5):513-521.
- [32] Singh N, Armstrong DG, Lipsky BA. Preventing foot ulcers in patients with diabetes. *JAMA* 2005 Jan 12;293(2):217-228.
- [33] Tesfaye S, Selvarajah D. Advances in the epidemiology, pathogenesis and management of diabetic peripheral neuropathy. *Diabetes Metab Res Rev* 2012 Feb;28 Suppl 1:8-14.
- [34] Boyko EJ, Ahroni JH, Stensel V, Forsberg RC, Davignon DR, Smith DG. A Prospective Study of Risk Factors for Diabetic Foot Ulcer. *Diabetes Care* 1999;22(7):1036-1042.
- [35] Korzon-Burakowska A, Dziemidok P. Diabetic foot - the need for comprehensive multidisciplinary approach. *Ann Agric Environ Med* 2011 Dec;18(2):314-317.
- [36] Crawford F, Inkster M, Kleijnen J, Fahey T. Predicting foot ulcers in patients with diabetes: a systematic review and meta-analysis. *QJM* 2007 Feb;100(2):65-86.
- [37] Lavery LA, Armstrong DG, Wunderlich RP, Mohler MJ, Wendel CS, Lipsky BA. Risk factors for foot infections in individuals with diabetes. *Diabetes Care* 2006 Jun;29(6):1288-1293.
- [38] Al-Maskari F, El-Sadig M. Prevalence of risk factors for diabetic foot complications. *BMC Fam Pract* 2007 Oct 10;8:59.

- [39] Tesfaye S, Chaturvedi N, Eaton SE, Ward JD, Manes C, Ionescu-Tirgoviste C, et al. Vascular risk factors and diabetic neuropathy. *N Engl J Med* 2005 Jan 27;352(4):341-350.
- [40] Clayton W, Elasy TM. A Review of the Pathophysiology, Classification, and Treatment of Foot Ulcers in Diabetic Patients. *Clinical Diabetes* 2009;27(2):52-58.
- [41] Wagner FW,Jr. The diabetic foot. *Orthopedics* 1987 Jan;10(1):163-172.
- [42] Oyibo SO, Jude EB, Tarawneh I, Nguyen HC, Harkless LB, Boulton AJ. A comparison of two diabetic foot ulcer classification systems: the Wagner and the University of Texas wound classification systems. *Diabetes Care* 2001 Jan;24(1):84-88.
- [43] Treece KA, Macfarlane RM, Pound N, Game FL, Jeffcoate WJ. Validation of a system of foot ulcer classification in diabetes mellitus. *Diabet Med* 2004 Sep;21(9):987-991.
- [44] Macfarlane RM, Jeffcoate WJ. Classification of Diabetic Foot Ulcers: The S(AD) SAD system. *Diabetic Foot* 1999;2:123-131.
- [45] Cuzzell JZ. The new RYB color code. *Am J Nurs* 1988 Oct;88(10):1342-1346.
- [46] Schaper NC. Diabetic foot ulcer classification system for research purposes: a progress report on criteria for including patients in research studies. *Diabetes Metab Res Rev* 2004 May-Jun;20 Suppl 1:S90-5.
- [47] van Houtum WH, Rauwerda JA, Schaper NC, Bakker K. International Ulcer Classification for Research Purposes by The International Working Group on the Diabetic Foot. Proceedings of the 4th International Symposium on the Diabetic Foot. May 22–24, 2003 Noordwijkerhout, the Netherlands. *Diab Metab Res Rev* 2004;20(S1):S1.
- [48] Younes NA, Albsoul AM. The DEPA scoring system and its correlation with the healing rate of diabetic foot ulcers. *J Foot Ankle Surg* 2004 Jul-Aug;43(4):209-213.
- [49] Diegelmann RF, Evans MC. Wound healing: an overview of acute, fibrotic and delayed healing. *Front Biosci* 2004 Jan 1;9:283-289.
- [50] Sheffield,P.J., Smith,A.P.S. Physiological and pharmacological basis of hyperbaric oxygen therapy. In: Bakker,D.J., Cramer,F.S., editor. *Hyperbaric surgery*: Flagstaff, AZ: Best Publishing Company; 2002. p. 63-109.
- [51] Mantzaris NV, Webb S, Othmer HG. Mathematical modeling of tumor-induced angiogenesis. *J Math Biol* 2004 Aug;49(2):111-187.
- [52] Bauer SM, Bauer RJ, Velazquez OC. Angiogenesis, vasculogenesis, and induction of healing in chronic wounds. *Vasc Endovascular Surg* 2005 Jul-Aug;39(4):293-306.
- [53] Asahara T, Masuda H, Takahashi T, Kalka C, Pastore C, Silver M, et al. Bone marrow origin of endothelial progenitor cells responsible for postnatal vasculogenesis in physiological and pathological neovascularization. *Circ Res* 1999 Aug 6;85(3):221-228.

- [54] Byrne HM, Chaplain MA. Mathematical models for tumour angiogenesis: numerical simulations and nonlinear wave solutions. *Bull Math Biol* 1995 May;57(3):461-486.
- [55] Boulton AJ, Armstrong DG, Albert SF, Frykberg RG, Hellman R, Kirkman MS, et al. Comprehensive foot examination and risk assessment: a report of the task force of the foot care interest group of the American Diabetes Association, with endorsement by the American Association of Clinical Endocrinologists. *Diabetes Care* 2008 Aug;31(8):1679-1685.
- [56] Khan NA, Rahim SA, Anand SS, Simel DL, Panju A. Does the clinical examination predict lower extremity peripheral arterial disease? *JAMA* 2006 Feb 1;295(5):536-546.
- [57] American Diabetes Association. Peripheral arterial disease in people with diabetes. *Diabetes Care* 2003 Dec;26(12):3333-3341.
- [58] International Working Group on the Diabetic Foot, International consensus on the diabetic foot and practical guidelines on the management and the prevention of the diabetic foot. Amsterdam, the Netherlands. 2011; Available at: ([www.idf.org/bookshop](http://www.idf.org/bookshop)) or ([www.diabeticfoot.nl](http://www.diabeticfoot.nl)).
- [59] Apelqvist J, Armstrong DG, Lavery LA, Boulton AJ. Resource utilization and economic costs of care based on a randomized trial of vacuum-assisted closure therapy in the treatment of diabetic foot wounds. *Am J Surg* 2008 Jun;195(6):782-788.
- [60] Murdoch DP, Armstrong DG, Dacus JB, Laughlin TJ, Morgan CB, Lavery LA. The natural history of great toe amputations. *J Foot Ankle Surg* 1997 May-Jun;36(3):204-8; discussion 256.
- [61] Skoutas D, Papanas N, Georgiadis GS, Zervas V, Manes C, Maltezos E, et al. Risk factors for ipsilateral reamputation in patients with diabetic foot lesions. *Int J Low Extrem Wounds* 2009 Jun;8(2):69-74.
- [62] Norgren L, Hiatt WR, Dormandy JA, Nehler MR, Harris KA, Fowkes FG, et al. Inter-society consensus for the management of peripheral arterial disease. *Int Angiol* 2007 Jun;26(2):81-157.
- [63] Byrne RL, Nicholson ML, Woolford TJ, Callum KG. Factors influencing the healing of distal amputations performed for lower limb ischaemia. *Br J Surg* 1992 Jan;79(1):73-75.
- [64] Yeager RA, Moneta GL, Edwards JM, Williamson WK, McConnell DB, Taylor LM, Jr, et al. Predictors of outcome of forefoot surgery for ulceration and gangrene. *Am J Surg* 1998 May;175(5):388-390.
- [65] Caruana MF, Bradbury AW, Adam DJ. The validity, reliability, reproducibility and extended utility of ankle to brachial pressure index in current vascular surgical practice. *Eur J Vasc Endovasc Surg* 2005 May;29(5):443-451.

- [66] Faries PL, Teodorescu VJ, Morrissey NJ, Hollier LH, Marin ML. The role of surgical revascularization in the management of diabetic foot wounds. *Am J Surg* 2004 May; 187(5A):34S-37S.
- [67] Lepantalo M, Biancari F, Tukiainen E. Never Amputate without Consultation of a Vascular Surgeon. *Diabetes Metab Res Rev* 2000;16(suppl 1):S27-S32.
- [68] Teodorescu VJ, Chen C, Morrissey N, Faries PL, Marin ML, Hollier LH. Detailed protocol of ischemia and the use of noninvasive vascular laboratory testing in diabetic foot ulcers. *Am J Surg* 2004 May;187(5A):75S-80S.
- [69] Jude EB, Unsworth PF. Optimal treatment of infected diabetic foot ulcers. *Drugs Aging* 2004;21(13):833-850.
- [70] Shah DM, Darling RC, 3rd, Chang BB, Fitzgerald KM, Paty PS, Leather RP. Long-term results of in situ saphenous vein bypass. Analysis of 2058 cases. *Ann Surg* 1995 Oct; 222(4):438-46; discussion 446-8.
- [71] Edmonds M, Foster A. The use of antibiotics in the diabetic foot. *Am J Surg* 2004 May;187(5A):25S-28S.
- [72] Lipsky BA, International consensus group on diagnosing and treating the infected diabetic foot. A report from the international consensus on diagnosing and treating the infected diabetic foot. *Diabetes Metab Res Rev* 2004 May-Jun;20 Suppl 1:S68-77.
- [73] Jeffcoate WJ, Lipsky BA. Controversies in diagnosing and managing osteomyelitis of the foot in diabetes. *Clin Infect Dis* 2004 Aug 1;39 Suppl 2:S115-22.
- [74] Game F. Management of osteomyelitis of the foot in diabetes mellitus. *Nat Rev Endocrinol* 2010 Jan;6(1):43-47.
- [75] Sibbald RG, Orsted H, Schultz GS, Coutts P, Keast D, International Wound Bed Preparation Advisory Board, et al. Preparing the wound bed 2003: focus on infection and inflammation. *Ostomy Wound Manage* 2003 Nov;49(11):23-51.
- [76] Badiavas EV, Abedi M, Butmarc J, Falanga V, Quesenberry P. Participation of bone marrow derived cells in cutaneous wound healing. *J Cell Physiol* 2003 Aug;196(2): 245-250.
- [77] Saap LJ, Donohue K, Falanga V. Clinical classification of bioengineered skin use and its correlation with healing of diabetic and venous ulcers. *Dermatol Surg* 2004 Aug; 30(8):1095-1100.
- [78] Brem H, Balledux J, Bloom T, Kerstein MD, Hollier L. Healing of diabetic foot ulcers and pressure ulcers with human skin equivalent: a new paradigm in wound healing. *Arch Surg* 2000 Jun;135(6):627-634.
- [79] Smiell JM, Wieman TJ, Steed DL, Perry BH, Sampson AR, Schwab BH. Efficacy and safety of becaplermin (recombinant human platelet-derived growth factor-BB) in pa-

- tients with nonhealing, lower extremity diabetic ulcers: a combined analysis of four randomized studies. *Wound Repair Regen* 1999 Sep-Oct;7(5):335-346.
- [80] Steed DL. Clinical evaluation of recombinant human platelet-derived growth factor for the treatment of lower extremity ulcers. *Plast Reconstr Surg* 2006 Jun;117(7 Suppl):143S-149S; discussion 150S-151S.
  - [81] Venturi ML, Attinger CE, Mesbahi AN, Hess CL, Graw KS. Mechanisms and clinical applications of the vacuum-assisted closure (VAC) Device: a review. *Am J Clin Dermatol* 2005;6(3):185-194.
  - [82] Roeckl-Wiedmann I, Bennett M, Kranke P. Systematic review of hyperbaric oxygen in the management of chronic wounds. *Br J Surg* 2005 Jan;92(1):24-32.
  - [83] Thackham JA, McElwain DL, Long RJ. The use of hyperbaric oxygen therapy to treat chronic wounds: A review. *Wound Repair Regen* 2008 May-Jun;16(3):321-330.
  - [84] Steed DL, Donohoe D, Webster MW, Lindsley L. Effect of extensive debridement and treatment on the healing of diabetic foot ulcers. Diabetic Ulcer Study Group. *J Am Coll Surg* 1996 Jul;183(1):61-64.
  - [85] Wolff H, Hansson C. Larval therapy--an effective method of ulcer debridement. *Clin Exp Dermatol* 2003 Mar;28(2):134-137.
  - [86] Horobin AJ, Shakesheff KM, Pritchard DI. Maggots and wound healing: an investigation of the effects of secretions from *Lucilia sericata* larvae upon the migration of human dermal fibroblasts over a fibronectin-coated surface. *Wound Repair Regen* 2005 Jul-Aug;13(4):422-433.
  - [87] Rosales A, Vazquez JR, Short B, Kimbriel HR, Claxton MJ, Nixon BP, et al. Use of a maggot motility index to evaluate survival of therapeutic larvae. *J Am Podiatr Med Assoc* 2004 Jul-Aug;94(4):353-355.
  - [88] Armstrong DG, Salas P, Short B, Martin BR, Kimbriel HR, Nixon BP, et al. Maggot therapy in "lower-extremity hospice" wound care: fewer amputations and more antibiotic-free days. *J Am Podiatr Med Assoc* 2005 May-Jun;95(3):254-257.
  - [89] Farzamfar B, Madani H, Gharibdoust F, Farhadi M, Novitsky YA, Khorramkhorshid HR, et al, inventors. Anonymous Herbal Extract for Treatment of Chronic Wounds. USA patent US 2010/0233305 A1. 2010 Apr 23, 2010.
  - [90] Bahrami A, Kamali K, Ali-Asgharzadeh A, Hosseini P, Heshmat R, Khorram Khorshid HR, et al. Clinical application of oral form of ANGIPARS™ and in combination with topical form as a new treatment for diabetic foot ulcers: A randomized clinical trial. *Daru* 2008;16(Suppl. 1):41-48.
  - [91] Larijani B, Heshmat R, Bahrami A, Delshad H, Ranjbar Omrani G, Mohammad K, et al. Effects of intravenous Semelil (ANGIPARS) on diabetic foot ulcers healing: A multicenter clinical trial. *Daru* 2008;16(Suppl. 1):35-40.



- [92] Ebrahimi M, Bakhshayeshi S, Heshmat R, Shahbazi SA,M., Peimani M, Khushechin G, et al. Post marketing surveillance on safety and effectiveness of ANGIPARS in treatment of diabetic foot ulcers. *Daru* 2009;17(Suppl. 1):45-49.
- [93] Larijani B, Hasani Ranjbar S. Overview of diabetic foot; novel treatments in diabetic foot ulcer. *Daru* 2008;16(Suppl. 1):1-6.
- [94] Shamimi Nouri K, Heshmat R, Karimian R, Nasli E, Larijani B, Novitsky YA, et al. Intravenous Semelil (ANGIPARS™) as a novel therapy for pressure Ulcers: A randomized clinical trial. *Daru* 2008;16(Suppl. 1):49-53.
- [95] Shamimi Nouri K, Karimian R, Nasli E, Kamali K, Chaman R, Farhadi M, et al. Topical application of Semelil (ANGIPARS™) in treatment of pressure ulcers: A randomized clinical trial. *Daru* 2008;16(Suppl. 1):54-57.
- [96] Mousavi-Jazi M, Aslroosta H, Moayer AR, Baeeri M, Abdollahi M. Effects of Angipars on oxidative inflammatory indices in a murine model of periodontitis. *Daru* 2010;18(4):260-264.
- [97] Murphy PS, Evans GR. Advances in wound healing: a review of current wound healing products. *Plast Surg Int* 2012;2012:190436.
- [98] Argenta LC, Morykwas MJ. Vacuum-assisted closure: a new method for wound control and treatment: clinical experience. *Ann Plast Surg* 1997 Jun;38(6):563-76; discussion 577.
- [99] Buttenschoen K, Fleischmann W, Haupt U, Kinzl L, Buttenschoen DC. The influence of vacuum-assisted closure on inflammatory tissue reactions in the postoperative course of ankle fractures. *Foot Ankle Surg* 2001;7(3):165-173.
- [100] Moues CM, van den Bemd GJ, Meerding WJ, Hovius SE. An economic evaluation of the use of TNP on full-thickness wounds. *J Wound Care* 2005 May;14(5):224-227.
- [101] Leininger BE, Rasmussen TE, Smith DL, Jenkins DH, Coppola C. Experience with wound VAC and delayed primary closure of contaminated soft tissue injuries in Iraq. *J Trauma* 2006 Nov;61(5):1207-1211.
- [102] Braakenburg A, Obdeijn MC, Feitz R, van Rooij IA, van Griethuysen AJ, Klinkenbijn JH. The clinical efficacy and cost effectiveness of the vacuum-assisted closure technique in the management of acute and chronic wounds: a randomized controlled trial. *Plast Reconstr Surg* 2006 Aug;118(2):390-7; discussion 398-400.
- [103] Park CA, Defranzo AJ, Marks MW, Molnar JA. Outpatient reconstruction using integra\* and subatmospheric pressure. *Ann Plast Surg* 2009 Feb;62(2):164-169.
- [104] Hurd T, Chadwick P, Cote J, Cockwill J, Mole TR, Smith JM. Impact of gauze-based NPWT on the patient and nursing experience in the treatment of challenging wounds. *Int Wound J* 2010 Dec;7(6):448-455.

- [105] Ubbink DT, Westerbos SJ, Evans D, Land L, Vermeulen H. Topical negative pressure for treating chronic wounds. *Cochrane Database Syst Rev* 2008 Jul 16;(3)(3):CD001898.
- [106] Peinemann F, Sauerland S. Negative-pressure wound therapy: systematic review of randomized controlled trials. *Dtsch Arztebl Int* 2011 Jun;108(22):381-389.
- [107] Armstrong DG, Lavery LA, Diabetic Foot Study Consortium. Negative pressure wound therapy after partial diabetic foot amputation: a multicentre, randomised controlled trial. *Lancet* 2005 Nov 12;366(9498):1704-1710.
- [108] Program and abstracts. Undersea and Hyperbaric Medical Society annual scientific meeting. 23-27 June 1992, Bethesda, Maryland. *Undersea Biomed Res* 1992;19 Suppl: 1-161.
- [109] Eskes AM, Ubbink DT, Lubbers MJ, Lucas C, Vermeulen H. Hyperbaric oxygen therapy: solution for difficult to heal acute wounds? Systematic review. *World J Surg* 2011 Mar;35(3):535-542.
- [110] Faglia E, Favales F, Aldeghi A, Calia P, Quarantiello A, Oriani G, et al. Adjunctive systemic hyperbaric oxygen therapy in treatment of severe prevalently ischemic diabetic foot ulcer. A randomized study. *Diabetes Care* 1996 Dec;19(12):1338-1343.
- [111] Barnes RC. Point: hyperbaric oxygen is beneficial for diabetic foot wounds. *Clin Infect Dis* 2006 Jul 15;43(2):188-192.
- [112] Goldman RJ. Hyperbaric oxygen therapy for wound healing and limb salvage: a systematic review. *PM R* 2009 May;1(5):471-489.
- [113] Hilton JR, Williams DT, Beuker B, Miller DR, Harding KG. Wound dressings in diabetic foot disease. *Clin Infect Dis* 2004 Aug 1;39 Suppl 2:S100-3.
- [114] Foster AV, Eaton C, McConville DO, Edmonds ME. Application of OpSite film: a new and effective treatment of painful diabetic neuropathy. *Diabet Med* 1994 Oct; 11(8):768-772.
- [115] Morin RJ, Tomaselli NL. Interactive dressings and topical agents. *Clin Plast Surg* 2007 Oct;34(4):643-658.
- [116] Khundkar R, Malic C, Burge T. Use of Acticoat dressings in burns: what is the evidence? *Burns* 2010 Sep;36(6):751-758.
- [117] Atiyeh BS, Costagliola M, Hayek SN, Dibo SA. Effect of silver on burn wound infection control and healing: review of the literature. *Burns* 2007 Mar;33(2):139-148.
- [118] Stanford W, Rappole BW, Fox CL, Jr. Clinical experience with silver sulfadiazine, a new topical agent for control of pseudomonas infections in burns. *J Trauma* 1969 May;9(5):377-388.

- [119] Cruciani M, Lipsky BA, Mengoli C, de Lalla F. Are granulocyte colony-stimulating factors beneficial in treating diabetic foot infections?: A meta-analysis. *Diabetes Care* 2005 Feb;28(2):454-460.
- [120] Cianfarani F, Tommasi R, Failla CM, Viviano MT, Annessi G, Papi M, et al. Granulocyte/macrophage colony-stimulating factor treatment of human chronic ulcers promotes angiogenesis associated with de novo vascular endothelial growth factor transcription in the ulcer bed. *Br J Dermatol* 2006 Jan;154(1):34-41.
- [121] Sato N, Kashima K, Tanaka Y, Shimizu H, Mori M. Effect of granulocyte-colony stimulating factor on generation of oxygen-derived free radicals and myeloperoxidase activity in neutrophils from poorly controlled NIDDM patients. *Diabetes* 1997 Jan;46(1):133-137.
- [122] Margolis DJ, Bartus C, Hoffstad O, Malay S, Berlin JA. Effectiveness of recombinant human platelet-derived growth factor for the treatment of diabetic neuropathic foot ulcers. *Wound Repair Regen* 2005 Nov-Dec;13(6):531-536.
- [123] Steed DL. Clinical evaluation of recombinant human platelet-derived growth factor for the treatment of lower extremity diabetic ulcers. Diabetic Ulcer Study Group. *J Vasc Surg* 1995 Jan;21(1):71-8; discussion 79-81.
- [124] Blumberg SN, Berger A, Hwang L, Pastar I, Warren SM, Chen W. The role of stem cells in the treatment of diabetic foot ulcers. *Diabetes Res Clin Pract* 2012 Apr;96(1):1-9.
- [125] Tran TC, Kimura K, Nagano M, Yamashita T, Ohneda K, Sugimori H, et al. Identification of human placenta-derived mesenchymal stem cells involved in re-endothelialization. *J Cell Physiol* 2011 Jan;226(1):224-235.
- [126] Lu D, Chen B, Liang Z, Deng W, Jiang Y, Li S, et al. Comparison of bone marrow mesenchymal stem cells with bone marrow-derived mononuclear cells for treatment of diabetic critical limb ischemia and foot ulcer: a double-blind, randomized, controlled trial. *Diabetes Res Clin Pract* 2011 Apr;92(1):26-36.
- [127] Lee MJ, Kim J, Lee KI, Shin JM, Chae JI, Chung HM. Enhancement of wound healing by secretory factors of endothelial precursor cells derived from human embryonic stem cells. *Cytotherapy* 2011 Feb;13(2):165-178.
- [128] Falanga V, Iwamoto S, Chartier M, Yufit T, Butmarc J, Kouttab N, et al. Autologous bone marrow-derived cultured mesenchymal stem cells delivered in a fibrin spray accelerate healing in murine and human cutaneous wounds. *Tissue Eng* 2007 Jun;13(6):1299-1312.
- [129] Prochazka V, Gumulec J, Chmelova J, Klement P, Klement GL, Jonszta T, et al. Autologous bone marrow stem cell transplantation in patients with end-stage chronic critical limb ischemia and diabetic foot. *Vnitr Lek* 2009 Mar;55(3):173-178.

- [130] Capla JM, Grogan RH, Callaghan MJ, Galiano RD, Tepper OM, Ceradini DJ, et al. Diabetes impairs endothelial progenitor cell-mediated blood vessel formation in response to hypoxia. *Plast Reconstr Surg* 2007 Jan;119(1):59-70.
- [131] Ehrenreich M, Ruszczak Z. Update on tissue-engineered biological dressings. *Tissue Eng* 2006 Sep;12(9):2407-2424.
- [132] Alexiadou K, Doupis J. Management of diabetic foot ulcers. *Diabetes Ther* 2012 Nov;3(1):4.
- [133] Edmonds M, European and Australian Apligraf Diabetic Foot Ulcer Study Group. Apligraf in the treatment of neuropathic diabetic foot ulcers. *Int J Low Extrem Wounds* 2009 Mar;8(1):11-18.
- [134] Moustafa M, Bullock AJ, Creagh FM, Heller S, Jeffcoate W, Game F, et al. Randomized, controlled, single-blind study on use of autologous keratinocytes on a transfer dressing to treat nonhealing diabetic ulcers. *Regen Med* 2007 Nov;2(6):887-902.
- [135] Mahmoud SM, Mohamed AA, Mahdi SE, Ahmed ME. Split-skin graft in the management of diabetic foot ulcers. *J Wound Care* 2008 Jul;17(7):303-306.
- [136] Uccioli L, Giurato L, Ruotolo V, Ciavarella A, Grimaldi MS, Piaggese A, et al. Two-step autologous grafting using HYAFF scaffolds in treating difficult diabetic foot ulcers: results of a multicenter, randomized controlled clinical trial with long-term follow-up. *Int J Low Extrem Wounds* 2011 Jun;10(2):80-85.
- [137] Moustafa M, Simpson C, Glover M, Dawson RA, Tesfaye S, Creagh FM, et al. A new autologous keratinocyte dressing treatment for non-healing diabetic neuropathic foot ulcers. *Diabet Med* 2004 Jul;21(7):786-789.
- [138] Niezgoda JA, Van Gils CC, Frykberg RG, Hodde JP. Randomized clinical trial comparing OASIS Wound Matrix to Regranex Gel for diabetic ulcers. *Adv Skin Wound Care* 2005 Jun;18(5 Pt 1):258-266.
- [139] Martin BR, Sangalang M, Wu S, Armstrong DG. Outcomes of allogenic acellular matrix therapy in treatment of diabetic foot wounds: an initial experience. *Int Wound J* 2005 Jun;2(2):161-165.
- [140] Masoompour SM, Bagheri MH, Borhani Haghighi A, Novitsky YA, Sadeghi B, Gharibdoust F, et al. Effect of ANGIPARS™, a new herbal drug on diabetic foot ulcer: A phase 2 clinical study. *DARU* 2008;16(Suppl. 1):31-34.
- [141] Rose Pharmed Biotechnology Co. Available at: [www.rosepharmed.com](http://www.rosepharmed.com).
- [142] Petre M, Tokar P, Kostar D, Cavanagh PR. Revisiting the total contact cast: maximizing off-loading by wound isolation. *Diabetes Care* 2005 Apr;28(4):929-930.
- [143] Armstrong DG, Lavery LA, Kimbriel HR, Nixon BP, Boulton AJ. Activity patterns of patients with diabetic foot ulceration: patients with active ulceration may not adhere to a standard pressure off-loading regimen. *Diabetes Care* 2003 Sep;26(9):2595-2597.

- [144] Caravaggi C, Faglia E, De Giglio R, Mantero M, Quarantiello A, Sommariva E, et al. Effectiveness and safety of a nonremovable fiberglass off-bearing cast versus a therapeutic shoe in the treatment of neuropathic foot ulcers: a randomized study. *Diabetes Care* 2000 Dec;23(12):1746-1751.
- [145] Maluf KS, Mueller MJ. Novel Award 2002. Comparison of physical activity and cumulative plantar tissue stress among subjects with and without diabetes mellitus and a history of recurrent plantar ulcers. *Clin Biomech (Bristol, Avon)* 2003 Aug;18(7):567-575.
- [146] Mantey I, Foster AV, Spencer S, Edmonds ME. Why do foot ulcers recur in diabetic patients? *Diabet Med* 1999 Mar;16(3):245-249.



