

We are IntechOpen, the world's leading publisher of Open Access books Built by scientists, for scientists

6,900

Open access books available

186,000

International authors and editors

200M

Downloads

Our authors are among the

154

Countries delivered to

TOP 1%

most cited scientists

12.2%

Contributors from top 500 universities



WEB OF SCIENCE™

Selection of our books indexed in the Book Citation Index
in Web of Science™ Core Collection (BKCI)

Interested in publishing with us?
Contact book.department@intechopen.com

Numbers displayed above are based on latest data collected.
For more information visit www.intechopen.com



Surgical Treatment for Multiple Brain Metastases

Takeshi Okuda and Amami Kato

Additional information is available at the end of the chapter

<http://dx.doi.org/10.5772/52353>

1. Introduction

Brain metastasis occurs with a fairly high frequency, in 25–35% of cancer patients [1]. Because brain metastasis directly affects prognosis, quality of life (QOL), and performance status (PS), treatment is crucial. Survival time is reported to be 1 month in the case of untreated brain metastasis [2], 2 months with steroid treatment alone [3], and 3–6 months with whole-brain radiotherapy (WBRT) [4–7]. This shows that brain metastasis is a seriously life-threatening condition. Therapeutic approaches have become more varied with the appearance of stereotactic radiosurgery (SRS), and establishment of multiple treatment plans has become possible. In addition to surgical resection (SR), WBRT, and SRS, systemic chemotherapy (SC) is also an option. The ideal treatment is to control the brain metastasis and prevent destruction of the central nervous system using combinations of these therapeutic approaches. Among these multiple approaches, SR is effective in that it enables treatment of large tumors and early improvement of symptoms, which are not possible with other approaches. The indications for SR are expanded with the early improvement of symptoms, leading particularly to improved QOL from the palliative viewpoint. However, SR is also highly invasive compared with other treatments, and the indications are strict. The standard surgical indication is single brain metastasis, and patients with fairly good prognosis, such as those with good general condition, are selected [8]. Recently, however, partly as a result of advances in imaging, the number of cases of multiple brain metastases has been trending upward. This means that there are patients in whom SR is excluded as an indication because of findings for multiple brain metastases, and who cannot obtain the benefits of surgery. We provide aggressive treatment using the same surgical indications for cases of multiple brain metastases as for single metastasis. The present study therefore investigated treatment outcomes and reported on the effectiveness of SR for multiple brain metastases.

2. Methods

Subjects were 100 patients with brain metastasis who underwent craniotomy and surgical removal of tumors in the Department of Neurosurgery at Kinki University Hospital between 2004 and 2011. They included 54 patients with single brain metastasis and 46 with multiple brain metastases. Details are shown in Table 1.

Characteristic	Single	Multiple
No. of cases	54	46
Age (mean)	63.3	61.3
Range	39-81	46-81
Male-to-female ratio	31:23	22:24
Primary site		
Lung	29	22
Breast	9	13
Rectum	2	3
Colon	3	1
Kidney	2	1
Other	9	6
RPA classification		
I	18	10
II	21	12
III	15	24
Size (mm, mean)	34.1	28.7

Table 1. Clinical characteristics of patients with single and multiple brain metastases

Surgical indications are shown in Figure 1, and treatments following surgery were done in close conference with departments related to cancer, such as the Department of Radiation Oncology and the Department of Medical Oncology. Each case was treated using a tailor-made approach.

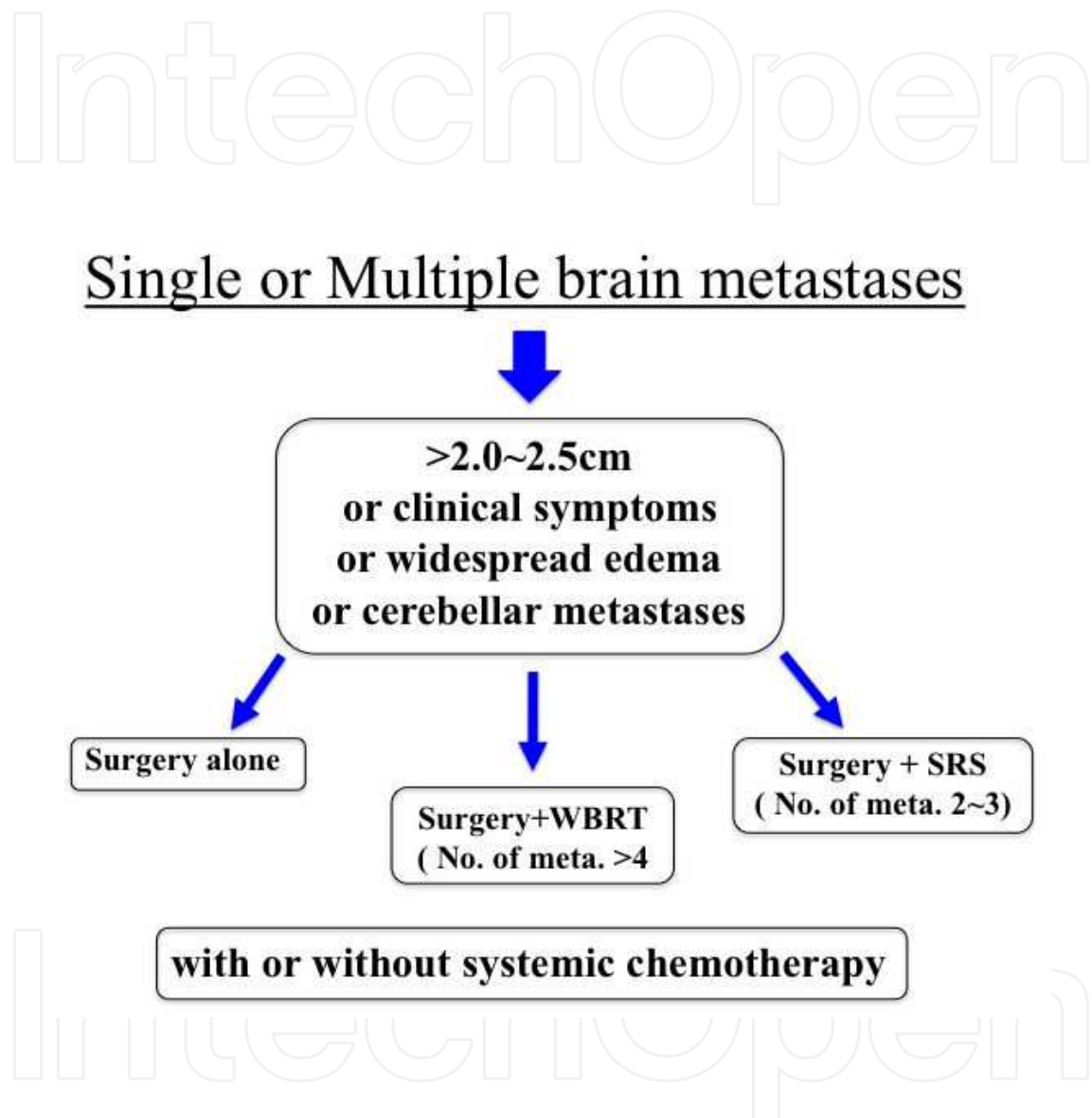


Figure 1. Therapeutic strategies in brain metastases

The basic surgery was en bloc resection, with resection of a single site even in cases of multiple metastases. During removal, we used fluorescence-guided surgery using fluorescein sodium with transformation to a solid-type tumor by hydrofiber dressing for cystic lesions [9-11]. In comparing survival time, duration of survival from the day of surgery until death was obtained using the Kaplan-Meier method, and significant differences were determined with the log-rank test. For all tests, a significance level of 5% was applied.

3. Results

Among the 100 patients, gross total resection was performed in 89%. Reasons for sub-total resection were invasion into blood vessels or dura mater, huge tumor size, or tumor involving an eloquent area. Follow-up treatments are shown in Figure 2. SC was also performed in 45 cases.

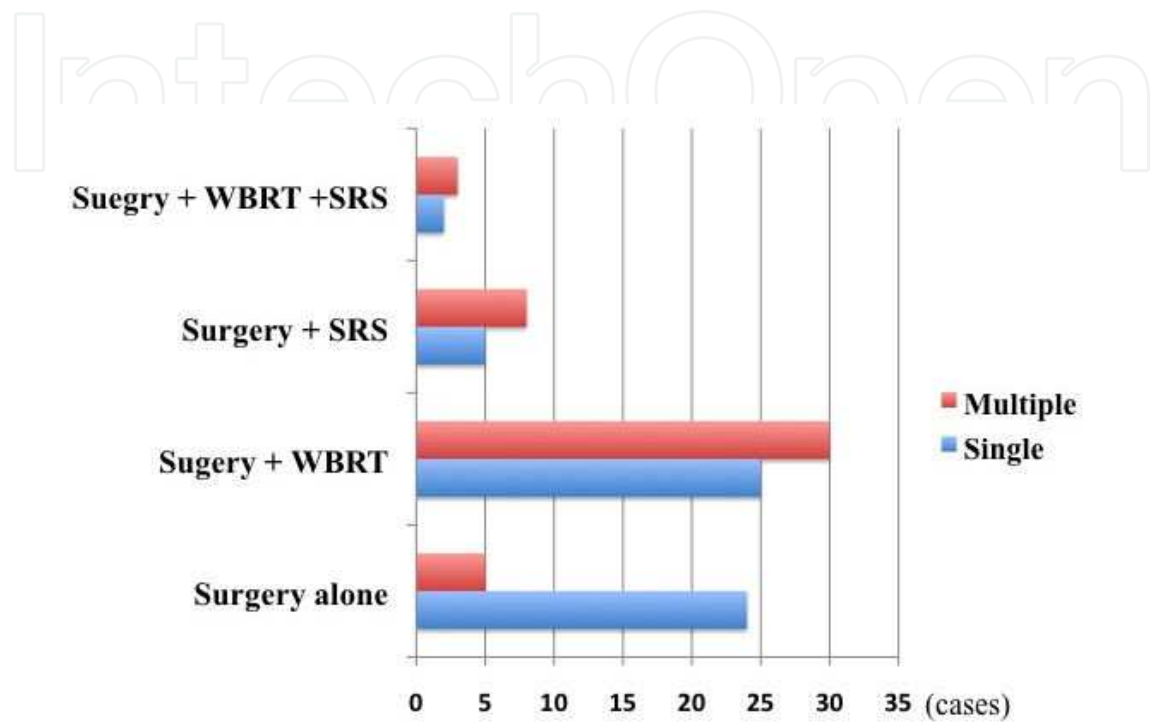


Figure 2. Postoperative treatments. Concurrent systematic chemotherapy was used in 45% of cases.

Central nervous system death occurred in 9% and 6 patients died within 3 months of surgery. Three of these patients showed exacerbation of the primary cancer and three showed poor control of brain metastases. For all 100 patients median survival time (MST) was 9.3 months, the 1-year survival rate was 45%, the 2-year survival rate was 10%. A comparison of single and multiple metastases is shown in Table 2.

	Single	Multiple
Median survival time (mo)	9.8	8.1
1- year survival rate (%)	44	46
2- year survival rate (%)	11	9

Table 2. Survival rate of single and multiple metastases

In this comparison by number of metastases, no significant differences were seen in survival time, including 1-year survival rate, 2-year survival rate, or MST (Fig. 3).

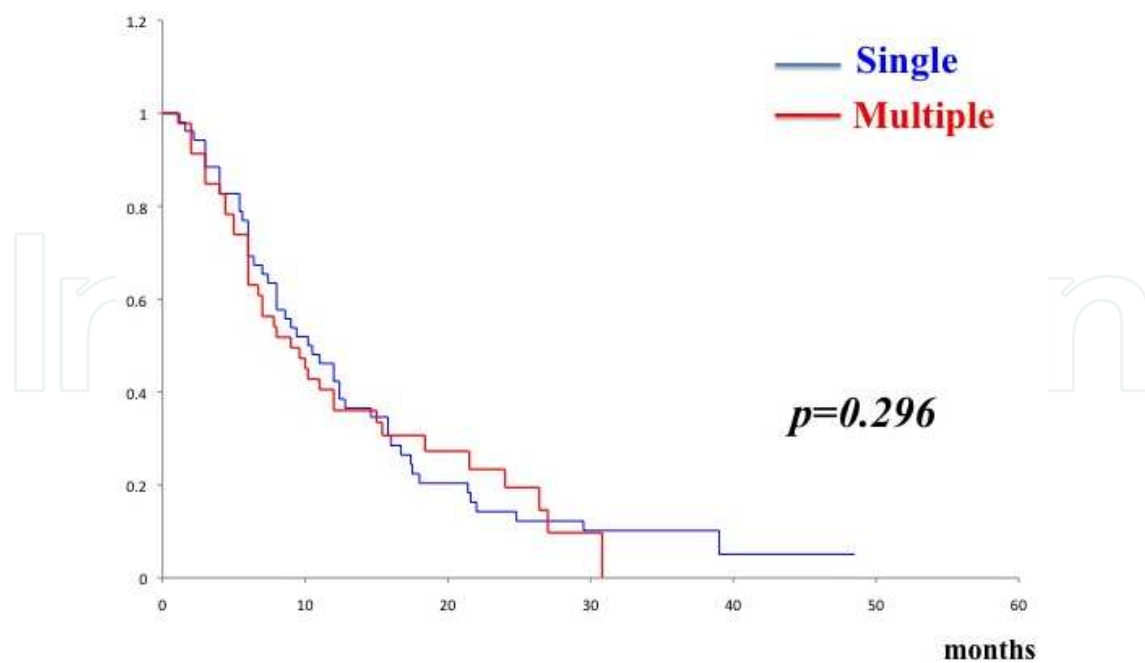


Figure 3. Comparison of survival times with single and multiple brain metastases. No statistically significant difference was confirmed between the 2 groups ($p=0.296$).

In a comparison by number of metastases in patients with multiple metastases, no significant difference in survival time was seen between patients with 2-3 metastases (MST, 8.8 months; $n=32$) and those with ≥ 4 metastases (MST, 8.0 months; $n=14$) (Fig. 4).

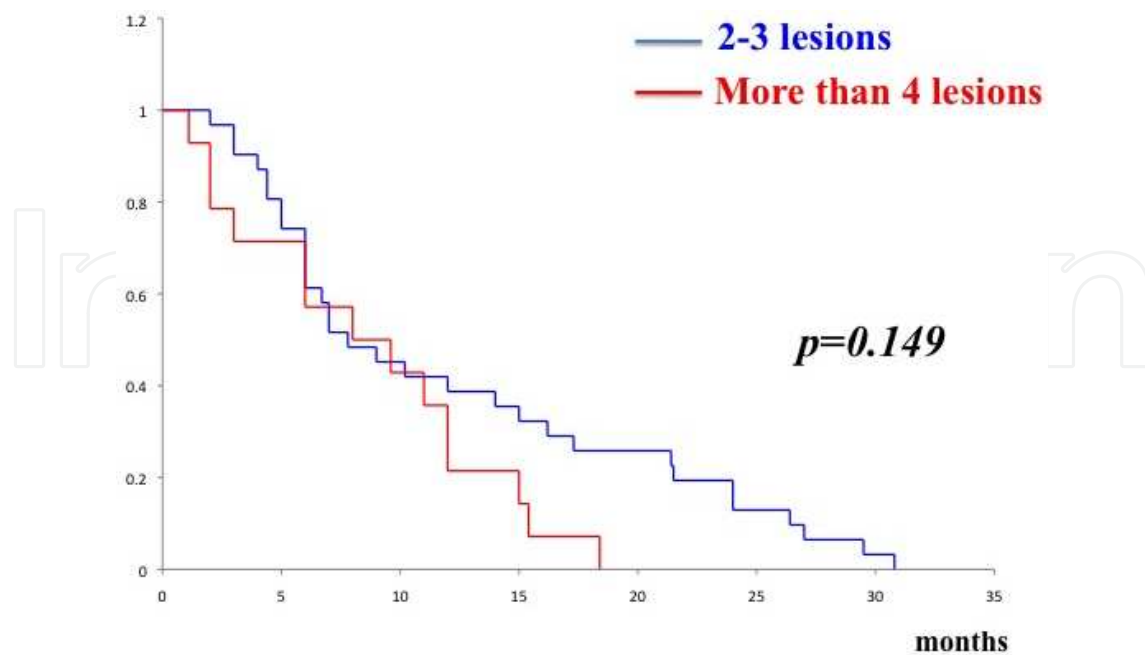


Figure 4. Comparison of survival times according to number of metastases in cases of multiple brain metastases. No statistically significant difference was confirmed between the 2 groups ($p=0.149$).

In addition, new pathological findings were revealed through pathological diagnosis obtained with SR, and the treatment strategy was changed in some cases. The case of a typical patient is described below.

This patient was a 49-year-old woman who was undergoing chemotherapy for lung cancer (adenocarcinoma). SC was continued for 4 courses, when she was switched to best supportive care because of a lack of efficacy. In screening tests for headache and visual impairment, six brain metastases were seen. At this point, multiple metastases to other organs were identified and she was expected to live less than 3 months (Fig. 5A-C).

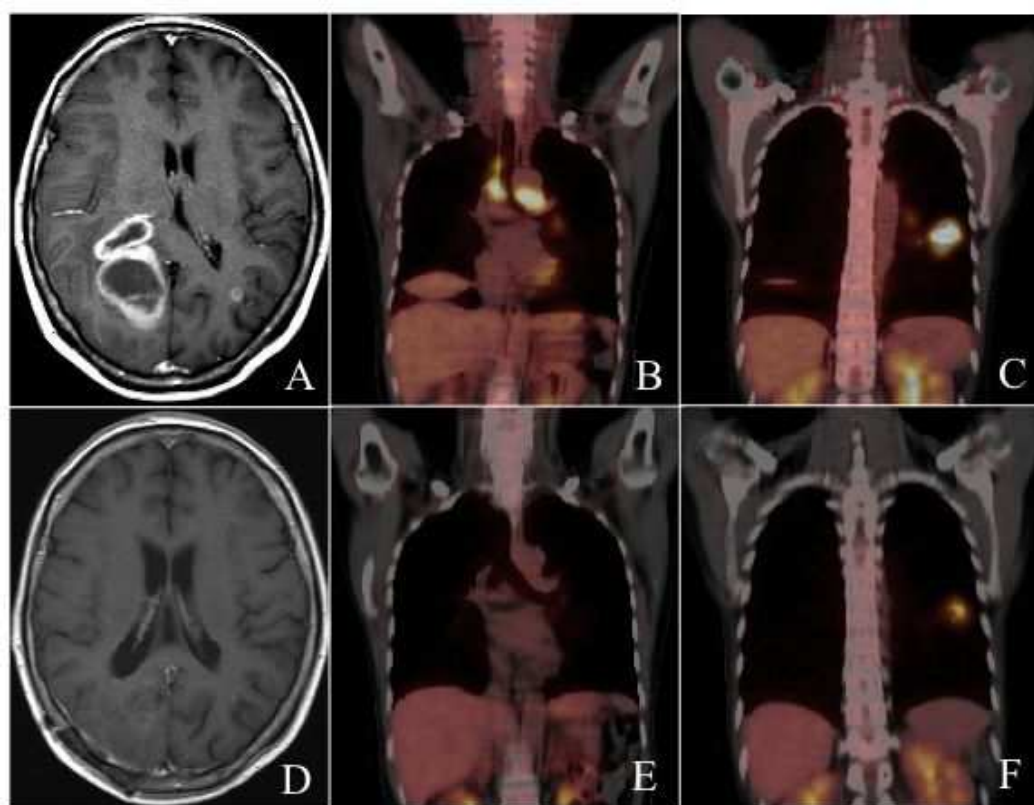


Figure 5. A) Contrast-enhanced MRI findings before treatment. A total of six metastases are seen, including a lesion ≥ 4 cm in diameter with ventricular invasion in the right occipital lobe. (B,C) Preoperative FDG-PET examination. Multiple metastases are seen in the lungs. (D) Contrast-enhanced MRI after treatment. All of the multiple lesions have disappeared. (E,F) FDG-PET examination following systemic chemotherapy. The lesions in the lungs are markedly reduced in size.

Headache associated with increased intracranial pressure is difficult to treat, and SR was performed for the right occipital lobe lesion with the aim of relieving symptoms. Symptoms rapidly improved after surgery, and the pathological diagnosis was small cell cancer. Initially, the diagnosis had been adenocarcinoma based on adenocarcinomatous tissue obtained from bronchoscopic biopsy of the primary lung cancer. In fact, however, the tumor represented mixed-type lung cancer with small cell cancer, and these brain metastases was thought to represent a recurrence of the small cell cancer. WBRT was performed postoperatively and SC

was applied using the approach used for small cell lung cancer. A marked decrease in systemic lesions was seen (Fig. 5D-F). Ultimately, the patient survived 19 months after surgery. This patient obtained a greater-than-expected benefit from surgery.

4. Discussion

Various biases are inherent in the treatment for brain metastasis, according to factors such as the primary cancer or general condition. Moreover, because of the problem of brain function, establishing a treatment plan can be difficult. In such circumstances, many reports with a fairly high evidence level have described results for single brain metastasis. Reports on level I include those of Patchell et al. [12] and Noordijk et al. [13] in the 1990s. SR + WBRT was established for single brain metastasis based on these reports. In a report by Bindal et al. [14], SR for multiple brain metastases was seen to be effective only in cases when all of the multiple brain metastases could be removed. However, when all lesions could not be removed, no significant difference was seen compared with WBRT alone, and SR was not considered effective. Based on these findings, the priority came to be placed on WBRT monotherapy in cases of multiple brain metastases, but treatment later diversified with active SRS intervention for brain metastasis and in 1999 Kondziolka et al. [15] reported WBRT + SRS combination radiotherapy for cases of multiple brain metastasis. With this approach, significantly longer survival times were obtained compared with WBRT alone, and WBRT + SRS became the general therapy for multiple brain metastases. In 2006, Aoyama et al. [16] also reported the efficacy of SRS monotherapy for brain metastasis with ≤ 4 lesions. Various treatment strategies have thus been reported, including not only conventional WBRT, but also combination with SRS and SRS monotherapy. Recent reports have also suggested the efficacy of SC for multiple brain metastases [17]. Up to this time, there has been little recognition of the efficacy of SC for brain metastasis. A response rate of 60% has been reported, but the effect is temporary and MST is less than 6 months in the majority of cases [18-20]. However, striking advances have recently been made in SC, with the emergence of molecularly targeted drugs as a major breakthrough. Drugs for lung cancer include gefitinib and erlotinib. The response rate to erlotinib is in cases of brain metastasis with EGFR mutation, showing very high efficacy. In breast cancer, the appearance of lapatinib is also reported to be effective against brain metastasis. SC will thus likely become necessary as one therapeutic approach in brain metastasis, particularly for patients with multiple brain metastases.

As mentioned above, various therapeutic approaches can be used for brain metastasis, including SR, WBRT, SRS, and SC, and various combinations. In this situation, at our hospital, we do not consider it necessary to select treatment based on the number of metastases, such as single or multiple, and aggressively perform SR in cases of multiple metastases just as in cases of single metastasis. Likewise in follow-up treatment, we implement tailor-made treatment strategies matched to the individual patients. The results have shown no differences in either MST or survival rate depending on the number of metastases, and good treatment outcomes have been obtained in cases of multiple brain metastases. Today, when various therapeutic approaches are available, performing SR to eliminate lesions at an early stage is

highly effective. Early improvement of symptoms leads to improved PS and QOL, producing new treatment opportunities. In addition, early elimination of brain metastatic lesions reduces the steroid dosage as well as the possibility of radiation necrosis. The result is thought to lead ultimately to longer survival times. In our investigation, prognosis tended to be better for the group with fewer brain metastases (2-3 lesions), but the difference did not reach the level of statistical significance. This suggests that there is no correlation between prognosis and the number of metastases, including even single brain metastases. This is also supported by the low probability of central nervous system death. The total number of patients in this study was low (100 patients) and it was not a randomized controlled trial, so the results of evaluation are not definitive. However, the advances in cancer treatment in recent years may necessitate a rethink of the policy of determining treatment plans based on the number of metastases.

5. Conclusions

The efficacy of SR in multiple brain metastases was investigated. Survival time and survival rate were not significantly different compared with single brain metastasis, and no significant difference was seen in a comparison of survival time according to number of metastases. The reasons are thought to be that tailor-made therapeutic strategies using the multimodalities advanced in recent years are effective. It may be time to rethink the approach of determining treatment plans based on the number of metastases in therapeutic strategies for brain metastases.

Author details

Takeshi Okuda and Amami Kato

*Address all correspondence to: okuda@neuro-s.med.kindai.ac.jp

Department of Neurosurgery, Kinki University School of Medicine, Osaka, Japan

References

- [1] Paek SH, Audu PB, Sperling MR, Cho J, Andrews DW. Reevaluation of surgery for the treatment of brain metastases: Review of 208 patients with single or multiple brain metastases treated at one institution with modern neurosurgical techniques. *Neurosurgery* 2005;56: 1021-1034.
- [2] Markesbery WR, Brooks WH, Gupta GD, Young AB. Treatment for patients with cerebral metastases. *Arch Neurol* 1978;35: 754-756.

- [3] Ruderman NB, Hall TC. Use of glucocorticoids in the palliative treatment of metastatic brain tumors. *Cancer* 1965;18: 298-306.
- [4] Cairncross JG, Kim JH, Posner JB. Radiation therapy for brain metastases. *Ann Neurol* 1980;7: 529-541.
- [5] Kurtz JM, Gelber R, Brady LW, Carella RJ, Cooper JS. The palliation of brain metastases in a favorable patient population: A randomized clinical trial by the Radiation Oncology Group. *Int J Radiat Oncol Biol Phys* 1981;7: 891-895.
- [6] Patchell RA, Tibbs PA, Regine WF, Dempsey RJ, Mohiuddin M, Kryscio RJ, Markesbery WR, Foon KA, Young B. Postoperative radiotherapy in the treatment of single metastases to the brain: A randomized trial. *JAMA* 1998;280: 1485-1489.
- [7] Sause WT, Crowley JJ, Morantz R, Rotman M, Mowry PA, Bouzaglou A, Borst JR, Selin H. Solitary brain metastasis: Results of an RTOG/SWOG protocol evaluation surgery plus RT versus RT alone. *Am J Clin Oncol* 1990;13: 427-432.
- [8] Mut M. Surgical treatment of brain metastasis: A review. *Clin Neurol Neurosurg* 2012;114(1): 1-8.
- [9] Okuda T, Kataoka K, Taneda M. Metastatic brain tumor surgery using fluorescein sodium: technical note. *Minim Invas Neurosurg* 2007;50: 382-384.
- [10] Okuda T, Teramoto Y, Yugami H, Kataoka K, Kato A. Surgical technique for a cystic-type metastatic brain tumor: transformation to a solid-type tumor using hydrofiber dressing. *Surg Neurol* 2009;72: 703-706.
- [11] Okuda T, Kataoka K, Yabuuchi T, Yugami H, Kato A. Fluorescence-guided surgery of metastatic brain tumors using fluorescein sodium. *J Clin Neurosci* 2010;17: 118-121.
- [12] Patchell RA, Tibbs PA, Walsh JW, Dempsey RJ, Maruyama Y, Kryscio RJ, Markesbery WR, Macdonald JS, Young B. A randomized trial of surgery in the treatment of single metastases to the brain. *N Engl J Med* 1990;322: 494-500.
- [13] Noordijk EM, Vecht CJ, Haaxma-Reiche H, Padberg GW, Voormolen JH, Hoekstra FH, Tans JT, Lambooi N, Metsaars JA, Wattendorff AR. The choice of treatment of single brain metastasis should be based on extracranial tumor activity and age. *Int J Radiat Oncol Biol Phys* 1994;29: 711-717.
- [14] Bindel RK, Sawaya R, Leavens ME, Lee JJ. Surgical treatment of multiple brain metastases. *J Neurosurg* 1993;79: 210-216.
- [15] Kondziolka D, Patel A, Lunsford LD, Kassam A, Flickinger JC. Stereotactic radiosurgery plus whole brain radiotherapy versus radiotherapy alone for patients with multiple brain metastases. *Int J Radiat Oncol Biol Phys* 1999;45: 427-434.
- [16] Aoyama H, Shirato H, Tago M, Nakagawa K, Toyoda T, Hatano K, Kenjyo M, Oya N, Hirota S, Shioura H, Kunieda E, Inomata T, Hayakawa K, Katoh N, Kobayashi G.

Stereotactic radiotherapy plus whole-brain radiation therapy vs stereotactic radiosurgery alone for treatment of brain metastases: a randomized controlled trial. *JAMA* 2006;295: 2483-2491.

- [17] Grimm SA. Treatment of brain metastases: chemotherapy. *Curr Oncol Rep* 2012;14(1): 85-90.
- [18] Drappatz J, Wen PY. Chemotherapy and targeted molecular therapies for brain metastases. *Expert Rev Neurother* 2006;6(10): 1465-1479.
- [19] van den Bent MJ. The role of chemotherapy in brain metastases. *Eur J Cancer* 2003;39(15): 2114-2120.
- [20] Walbert T, Gilbert MR. The role of chemotherapy in the treatment of patients with brain metastases from solid tumors. *Int J Clin Oncol* 2009;14(4): 299-306.

IntechOpen