

# We are IntechOpen, the world's leading publisher of Open Access books Built by scientists, for scientists

6,900

Open access books available

186,000

International authors and editors

200M

Downloads

Our authors are among the

154

Countries delivered to

TOP 1%

most cited scientists

12.2%

Contributors from top 500 universities



WEB OF SCIENCE™

Selection of our books indexed in the Book Citation Index  
in Web of Science™ Core Collection (BKCI)

Interested in publishing with us?  
Contact [book.department@intechopen.com](mailto:book.department@intechopen.com)

Numbers displayed above are based on latest data collected.  
For more information visit [www.intechopen.com](http://www.intechopen.com)



---

# Airways Disease in Sarcoidosis

---

Adam S. Morgenthau

Additional information is available at the end of the chapter

<http://dx.doi.org/10.5772/55010>

---

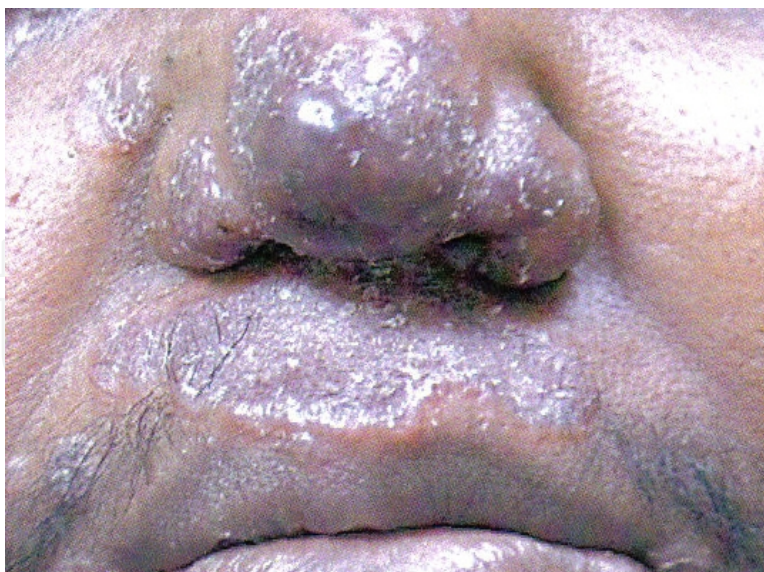
## 1. Introduction

### 1.1. Nasal sarcoidosis

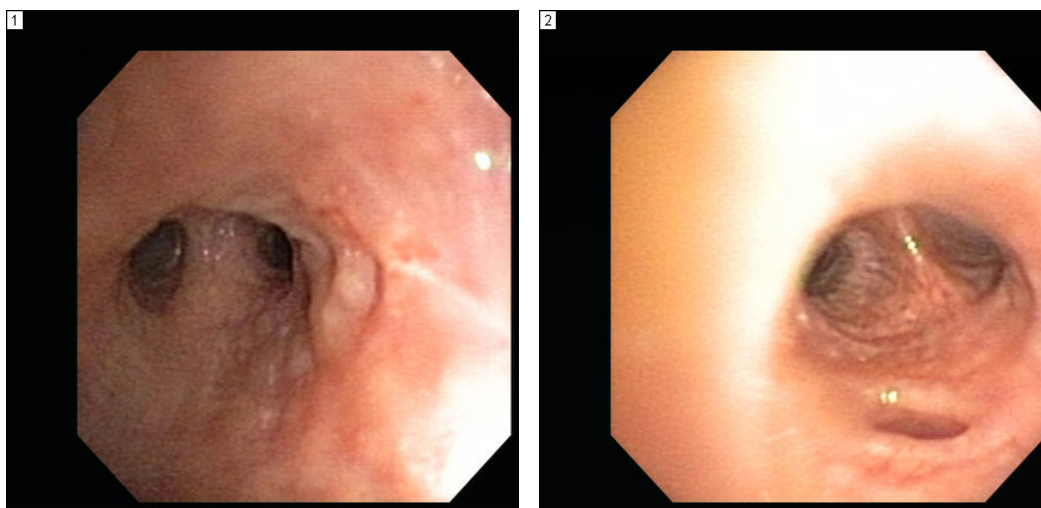
Lupus pernio was first described by Kreibich and Kraus in 1908. [6] Pathognomic for sarcoidosis, Lupus pernio is a plaque-like lesion that is usually swollen, scaly or shiny. Typically, it occurs on the nose, cheeks, lips or ears. [7] Lupus pernio is most commonly observed in African-American women [8] and approximately 20% of all sarcoidosis patients with the lesion have co-morbid upper respiratory tract disease. [9] The skin lesion often involves the nasal mucosa and sometimes the underlying cartilage and nasal bones are destroyed. [7]

Nasal disease is usually associated with sinus disease. [10, 11] However, the clinical manifestations of nasal granulomas differ from sinus granulomas. Nasal mucus membrane granulomas may cause nasal obstruction, [11] epistaxis, crusting, rhinorrhea, post-nasal drip, pain and anosmia. [3] Obstruction is usually the most common presenting symptom when polypoid granulomatous lesions involve the nasal septum and the inferior turbinate. Fergie and colleagues retrospectively reviewed eight patients with nasal sarcoidosis and found that epiphora was present in 4 patients. [12]

On examination, the nasal mucosa is usually hypertrophic, erythematous and granular. It may also contain polyps, masses and/or asymmetric crust-like patches. The nasal bones may demonstrate a variety of radiographic abnormalities. [9, 10] Septal perforation is rare but granulomatous inflammation of the nasal cartilage (figure 2) may result in the classic “saddle nose” deformity. [13] Occasionally, granulomatous lesions may erode through the hard or soft palate, creating intraoral lesions or oral-nasal fistulae. [14]



**Figure 1.** Sarcoidosis patient with Lupus Pernio.



**Figure 2.** Bronchoscopic appearance of endobronchial sarcoidosis demonstrating nodules and inflamed mucosa that narrows the right upper lobe bronchus.

## 2. Sinus sarcoidosis

The symptoms of nasal obstruction and chronic sinusitis often occur in patients concomitantly. [10, 11] The most common symptoms associated with sarcoidosis of the sinuses are recurrent infections, epistaxis, periorbital tenderness, post-nasal drip and headache. [15] Patients with sarcoidosis of the sinuses usually have involvement of multiple organ systems. [11] Sarcoidal lesions in the sinus mucosa are generally similar to those found in the nasal mucosa. Exami-

nation often demonstrates erythematous, friable, hypertrophied mucosa. Crusting, studding, plaque-like changes or polyps may also be visualized. Rarely, granulomatous lesions extend out of the sinuses and into the orbit, resulting in proptosis and/or decreased unilateral visual acuity. [16] Sarcoidosis of the sinuses is generally a chronic and recalcitrant form of the disease that requires prolonged systemic therapy. [6, 17, 18]

### 3. Laryngeal sarcoidosis

The epiglottis, aryepiglottic folds, arytenoids, false cords and subglottis are the most commonly affected regions in the larynx. The true vocal cords are relatively devoid of lymphatic tissue and are rarely ridden with disease. [19] Granulomatous involvement of the larynx may cause life-threatening stridor or dysphagia. [10] On examination, the involved laryngeal mucosa is typically pale pink, granular and edematous. Lesions vary in their size and shape. Localized submucosal induration, punctate nodules or polypoid masses may be present. In one review of 40 patients with laryngeal sarcoidosis, the presenting symptoms were: dysphagia (85%), hoarseness (63%), dyspnea or stridor (47%) and cough (13%). [20] Ulceration of the mucosa is rare. Patients also present with hoarseness, dysphonia, cough, dyspnea, a sensation of a lump in the throat and obstructive sleep apnea. [21]

Hoarseness is typically caused by granulomatous laryngitis. However, laryngeal sarcoidosis may cause hoarseness by two additional mechanisms. [22, 23] The first involves granulomatous infiltration of the vagus nerve, resulting in a polyneuropathy. Limited data suggests that vagal polyneuropathy is rare [24] and if present, is typically associated with other cranial neuropathies. [21] In rare cases, hoarseness may result from mediastinal lymphadenopathy that compresses the recurrent laryngeal nerve, resulting in vocal cord paralysis. The left recurrent laryngeal nerve is affected in more than 95% of cases. [21, 25] The predilection for left-sided injury results from the longer and more vulnerable course of the left recurrent laryngeal nerve through the mediastinum.

In one report, a young female presented with daytime hypersomnolence and snoring. [26]

Nasopharyngoscopy demonstrated an irregularly shaped and narrowed subglottis. Subsequent biopsy confirmed the presence of non-caseating granulomas. The patient was diagnosed with obstructive sleep apnea, secondary to laryngeal sarcoidosis. To determine the prevalence and risk factors for obstructive sleep apnea in sarcoidosis patients, 83 patients with sarcoidosis were prospectively evaluated. [27] The Epworth Sleepiness Scale was used to assess enrolled patients. A control group of 91 patients were similarly screened. Patients with a positive sleep questionnaire were referred for sleep studies. A total of 14 sarcoidosis patients (17%) were found to have sleep apnea, which was significantly higher than in the control group where 3/91 were found to have obstructive disease (3%,  $p < 0.001$ ). [27] Lupus pernio was significantly more frequent in the sleep apnea group. [27] Although granulomatous laryngitis may be associated with obstructive sleep apnea, obstructive sleep apnea in patients with sarcoidosis usually results from obesity secondary to the administration of chronic corticosteroids.

#### 4. Tracheal sarcoidosis

Sarcoidal involvement of the trachea is rare [28] and the literature on tracheal sarcoidosis is sparse. Tracheal stenosis and dystonia are the primary manifestations that have been described. [28, 29] Brandstetter and associates [30] described a patient who complained of deteriorating voice strength for 30 years and eventually, strident breathing that was refractory to corticosteroids. In 1949, Lemoine described tracheal dystonia (tracheal collapse most pronounced on expiration) in sarcoidosis. Ellefsen detailed a 44-year-old female who complained of progressive dyspnea for 4 years prior to admission to the hospital. [29] She eventually developed wheezing and a severe nonproductive cough. Physical exam showed stridor and wheezing.

#### 5. Bronchial sarcoidosis

Bronchial sarcoidosis was first described at autopsy by Bernstein and colleagues in 1929 and subsequently on bronchoscopy by Benedict and Castleman in 1941. [31] Numerous case series have followed. [32-37] Granulomatous lesions typically occur in the bronchial submucosa. [37] The bronchial mucosa often appears inflamed with small or large nodules containing granulomas. [37] (Figure 2) Granulomatous involvement of the bronchi may cause edema and/or an endobronchial masses that results in reversible narrowing of the large airways. [33, 36, 37] Irreversible narrowing, especially of the right middle lobe bronchus, results from cicatricial stenosis. [33] Reversible or irreversible bronchial stenosis occurs more commonly in the presence of end-stage pulmonary fibrosis. But bronchostenosis may occur in milder stages of the disease. [33, 36, 37] Bronchial sarcoidosis may be isolated (one stenotic point) or diffuse (multiple stenotic points) involving the lobar or segmental bronchi. Compressive mediastinal and/or bronchopulmonary lymphadenopathy is rarely a cause of stenoses at these locations within the airway. [38, 39]

Patients with bronchial sarcoidosis present with dyspnea, cough and wheezing that is often misdiagnosed as asthma. [10] The symptoms generally progress and are refractory to bronchodilators and inhaled corticosteroids. Bronchial sarcoidosis is suggested by obstructive airways disease (a reduced ratio of forced expiratory volume in 1 second [FEV1] to forced vital capacity [FVC]) that may be accompanied by airways hyperreactivity on pulmonary function tests. Bronchoscopic inspection of the airways with or without biopsy of the parenchyma is the most efficient method to confirm the diagnosis. Endobronchial involvement is common in sarcoidosis. Endobronchial biopsy has a yield comparable to transbronchial biopsy and can safely increase the diagnostic value of fiberoptic bronchoscopy. Performance of endobronchial biopsies should routinely be considered in cases of suspected sarcoidosis.

#### 6. Small airways sarcoidosis

Small airways disease is an underappreciated manifestation of pulmonary sarcoidosis. Regional air trapping, indicative of small airways disease, may be visualized on expiratory HRCT [40]

and newer imaging modalities such as hyperpolarized 3-H MRI, [41, 42] in patients with pulmonary sarcoidosis who have obstructive airways disease. Peripheral airway obstruction with involvement of small airways may be caused by the formation of granulomas in a perilymphatic distribution along the bronchovascular bundles. [41, 43] Small airways dysfunction can be measured by forced expiratory flow during the middle half of the forced expiratory curve ( $MMEF_{25-75\%}$ ), forced expiratory volume at 3 seconds ( $FEV_3$ ) ratio of the residual volume to the total lung capacity (RV/TLC). In one study, the extent of air trapping on HRCT correlated significantly with RV/TLC and  $MMEF_{25-75\%}$ . [41, 43] In other studies, however, these physiologic measurements were highly variable and provided limited clinical information. [43-45]

Patients with small airways disease typically present with progressive dyspnea, cough and wheeze. They may also exhibit strident breathing. Lung auscultation demonstrates wheezing, stridor or squeaks.

Skin of the Nose (Lupus Pernio)
Nares
Nasal Septum
Sinuses
Larynx
Vocal Cords
Trachea
Bronchi
Bronchioles

Table 1. Airway Involvement in Sarcoidosis

INFECTIOUS	NON-INFECTIOUS
Tuberculosis	Sarcoidosis
Atypical Mycobacterial Disease	Wegener’s Granulomatosis
Syphilis	Berylliosis
Leprosy	Silicosis
Aspergillosis	Hypersensitivity Pneumonitis
Histoplasmosis	Lymphoma
Rhinoscleroma	Cocaine
Coccidioidomycosis	Churg-Strauss Syndrome
Toxoplasmosis	Talc
Actinomycosis	Lymphoid Interstitial Pneumonia
Cryptococcosis	Rheumatoid Nodule

“Reprinted from Mukhopadhyay, S. et al..., Granulomatous Lung Disease: An Approach to the Differential Diagnosis. May 2010, Vol. 134, No. 5, pp. 667-690 with permission from *Archives of Pathology & Laboratory Medicine*. Copyright 2010. College of American Pathologists.”

Table 2. Differential Diagnosis of Granulomatous Airways Diseases

### 6.1. Airway Hyperreactivity (AHR)

The incidence of airway hyperreactivity (AHR) in sarcoidosis is highly variable. Airway hyperreactivity has been observed in approximately 20%--50% of sarcoidosis patients. [46, 47] The statistical discrepancy probably results from different patient populations, study designs and different definitions of sarcoidosis and AHR.

Airway hyperreactivity has important clinical and prognostic implications in sarcoidosis. [47] Many patients with sarcoidosis exhibit normal pulmonary function and imaging but complain of cough, dyspnea and wheeze. The wall of the airway may be narrowed and thickened as a result of airway hyperreactivity or may collapse from an extrinsic pathologic process in the lung. Airway hyperreactivity in sarcoidosis may also cause chronic airflow obstruction, which has been associated with a poor prognosis. [47, 48] Fixed airway obstruction has been shown to nearly double the risk of mortality. [47]

The prevalence of AHR, as demonstrated by a positive methacholine challenge test, is significantly higher in sarcoidosis patients compared to normal controls. [1, 47] It is unclear whether AHR is a physiologic manifestation of endobronchial sarcoidosis or reversible airways disease in asthma. Rarely, asthma may be associated with sarcoidosis. [49] Airway hyperreactivity in sarcoidosis and reversible airways disease in asthma may often be distinguished by response to inhaled corticosteroids and/or beta-agonists. Asthmatic reactive airways disease usually improves with these medications. But AHR in sarcoidosis commonly requires treatment with oral corticosteroids. [33, 47] In many cases, AHR in sarcoidosis does not improve with systemic corticosteroids.

Importantly, cough and wheeze secondary to AHR (as demonstrated by positive methacholine challenge testing) should not be confused with cough and wheeze unrelated to AHR. *Sarcoidal cough and wheeze unrelated to AHR* responds favorably to inhaled corticosteroids and/or beta-agonists as does *asthmatic cough and wheeze related to AHR*. [47] Sarcoidal cough and wheeze associated with AHR, however, may require treatment with oral corticosteroids, which is often ineffective.

Several studies suggests that AHR in sarcoidosis correlates with both the degree of alveolitis and angiotensin converting enzyme (ACE) levels in bronchoalveolar lavage (BAL) fluid and serum. [50] In addition, higher serum ACE levels were found in sarcoidosis patients with hyperreactivity. [47] Finally, patients with AHR were more likely to have a positive endobronchial biopsy (9/9, 100%) compared to individuals without hyperreactivity (15/33, 45.5%), which suggests that AHR is present in patients with more pronounced bronchial inflammation. [47]

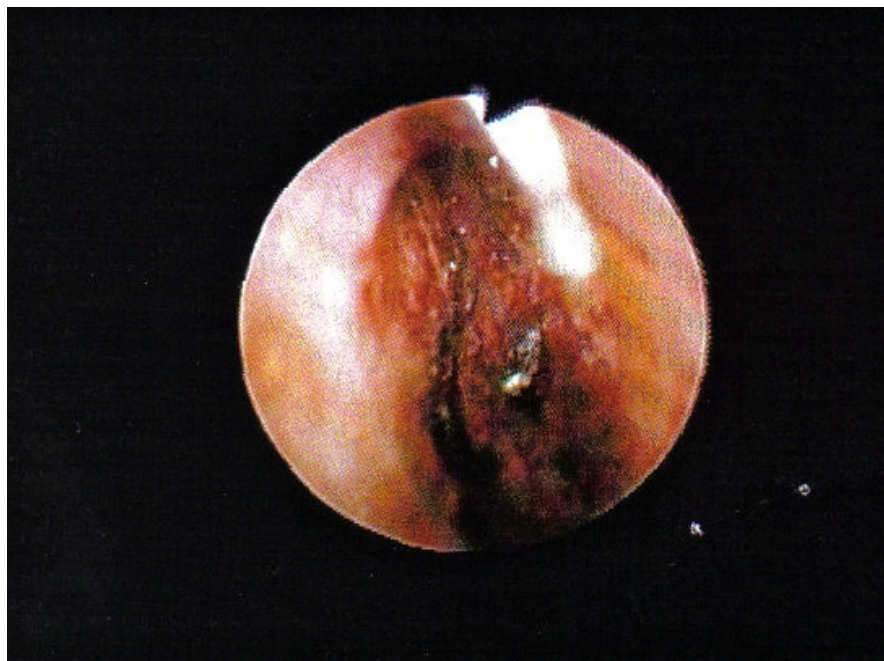### 6.2. Atelectasis

Lobar atelectasis may result from occlusion of a lobar bronchus. Bronchial obstruction may be caused by one of two mechanisms: endobronchial stenosis [37] or rarely, by extrinsic compression of the bronchus by enlarged lymph nodes. [51, 52] Atelectasis of the middle lobe is most common but atelectasis of the right upper lobe has also been reported. [53] The middle lobe is particularly susceptible to collapse because it has a small bronchial lumen, surrounded by many lymph nodes and emerges at a right angle from the bronchus intermedius. Collapse of the right

upper lobe may result in the radiographic S-sign of Golden, which is commonly associated with cancer. Resolution of atelectasis is variable and it may occur even after several years. [54]

### 6.3. Fibrosis

Chronic, progressive, end-stage, pulmonary fibrosis with traction bronchiectasis, often referred to as “honeycomb lung”, develops in approximately 25% of patients with chronic pulmonary sarcoidosis. [40, 55] The condition is characterized by parenchymal fibrosis, bronchiolectasis and enlarged, dilated air spaces. It usually occurs subpleurally within the upper regions of the lung [40, 56] (figure 3). Oxygenation and ventilatory function are impaired. Pulmonary function tests demonstrate severe restriction and gas transfer abnormalities. Importantly, fibrosis characterized by a stage IV radiographic pattern, rarely responds to treatment.



**Figure 3.** Sarcoidosis patient with granulomatous inflammation of the nasal cartilage

### 6.4. Bullous disease

Bullea (thin-walled air spaces in the lungs) may develop in patients with advanced pulmonary sarcoidosis. Most sarcoidosis patients with bullous disease do not exhibit an extensive smoking history and have airflow obstruction on pulmonary function tests. [10, 57] Dilatation and rupture of bullae probably results from granulomatous bronchostenosis. [58] Bullae may develop secondary to destruction of alveolar walls by alveolitis. [58] Bullous rupture may cause pneumothorax.

Giant bullous changes in sarcoidosis may rarely cause the Vanishing Lung Syndrome. [59] First described by Burke in 1937, the Vanishing Lung Syndrome describes an end stage of

diffuse panacinar emphysema in which large air spaces develop, further impairing lung function. [59] Miller and associates reported two cases of the Vanishing Lung Syndrome. Postmortem analysis of the lungs demonstrated that the bullae were quite different from the localized air spaces frequently seen in chronic pulmonary sarcoidosis. [10, 60]

### 6.5. Cavitory lung disease, bronchiectasis and mycetomas

Although the terms cyst and cavity have overlapping meanings and may be used interchangeably, the technical definitions of these terms are different. Cysts are clearly defined air-containing space surrounded by a relatively thin ( $\leq 4$  mm) wall. A cavity, in contrast, is meant to describe an air-containing lesion with a relatively thick ( $> 4$  mm) wall or within an area of a surrounding infiltrate or mass. The distinction is useful because there is a different diagnostic approach to these anatomic structures. [61]

True cavitory lung disease, which results from necrosis of granulomatous areas creating airspaces within thick walls or within a fibrotic mass, is rare in sarcoidosis. Sarcoidal cavities must be differentiated from those associated with mycobacterial infection. The radiographic cystic changes that occur in advanced sarcoidosis are typically consistent with saccular bronchiectasis, rather than true cavitations. [57, 61] Saccular or cylindrical bronchiectasis likely results from bronchial wall injury by granulomas, superimposed bronchial infection and radial traction by peribronchial scar tissue. Colonization of the bronchiectatic sacs by *Aspergillus* sp., may result in the development of an aspergilloma. Patients with aspergillomas complicating sarcoidosis may have life-threatening hemoptysis but, as a result of their advanced lung disease, are usually high-risk surgical candidates. [62]

Intracavitary instillation of antifungal agents is an alternative treatment in patients with severe pulmonary dysfunction who are poor operative risks. Percutaneous instillation of amphotericin B guided by CT scans may be effective for the treatment of aspergilloma. [63] In several cases, the intervention has led to resolution of hemoptysis. [63] The response to percutaneous injection of amphotericin B appears to be sustainable for several months. [63]

Israel and associates evaluated the role of surgery in 38 sarcoidosis patients with pulmonary aspergillomas, 10 of whom were considered satisfactory operative candidates. [64] Satisfactory candidates demonstrated a forced vital capacity greater than 50% predicted and a resting PaO<sub>2</sub> greater than 80 mmHg. The indication for surgical resection in satisfactory and unsatisfactory candidates was recurrent hemoptysis. Seven satisfactory and 7 unsatisfactory candidates underwent segmental resection, lobectomy or bilobectomy. The authors did not specify the type of procedure that each patient received. Patients were followed postoperatively for an unspecified duration. Among the 7 satisfactory candidates who underwent resection, 1 patient died from empyema immediately after surgery. Three of 7 patients with unsatisfactory pulmonary function died of respiratory failure 1 month, 11 months and 27 months, respectively, after surgery. Twenty-one patients with poor pulmonary function did not have surgery. Four patients died of recurrent hemorrhage 4 months to 3 years after discovery of the aspergilloma. Eleven patients died of respiratory failure and 6 survived at the time of publication (1982) although it is unclear when these patients were diagnosed with their aspergilloma. The principle complications of surgical resection were prolonged air leaks, bronchopleural fistulae

and empyema. The authors concluded that surgical resection should generally be avoided in patients with bilateral disease and compromised pulmonary function. The indication for surgery in all patients, especially those with poor pulmonary function, should be recurrent hemoptysis because it may cause exsanguinating hemorrhage, which poses a greater risk to the patient than surgical intervention. [64]

## 7. Imaging

Computed tomography (CT) is often the imaging method of choice for sarcoidosis of the upper and lower respiratory tract. [40] Braun and associates analyzed the CT findings of 15 patients with sinonasal sarcoidosis. [20] A spectrum of abnormalities were evaluated: nodular lesions of the septum and/or inferior turbinates; mucosal thickening and complete or subtotal opacification of the ethmoidal, maxillary and/or sphenoid sinuses; obstruction of the ostio-meatal units and of the upper part of the nasal cavities; turbinoseptal synechiae; destruction or erosion of the turbinates, nasal bones, septum, ethmoid air cells and sphenoid sinus.

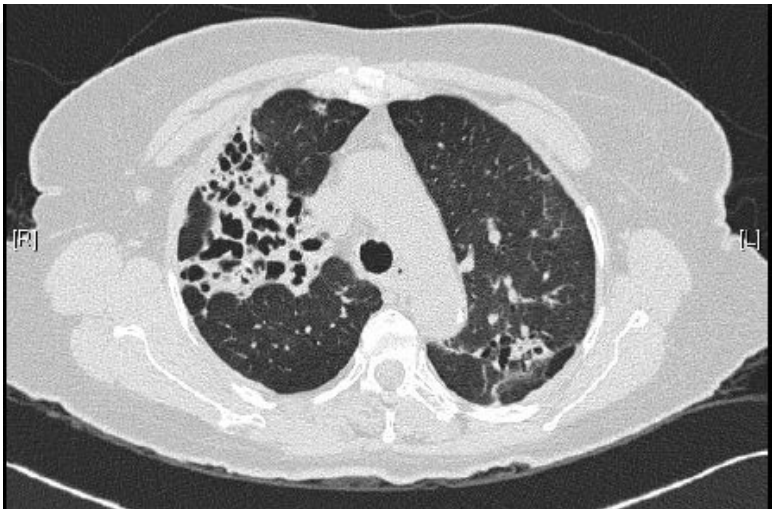
CT scan has a high sensitivity for detecting sarcoidosis of the larynx or trachea. [65] Typically, the CT demonstrates stenosis of the larynx and trachea.

Airways sarcoidosis produces a variety of abnormalities on CT scan of the lungs. Several CT studies performed at near residual volume (end expiration) have demonstrated air-trapping in pulmonary sarcoidosis. [40, 66, 67] Davies and colleagues reported that air-trapping on expiratory CT was present in 95% of 21 sarcoidosis patients and correlated with physiologic obstruction by percentage predicted residual volume (RV)/ total lung capacity (TLC) ( $p < 0.05$ ) and percentage predicted maximal mid-expiratory flow rate between 25% and 75% of the vital capacity (VC) ( $p < 0.05$ ). [41] The CT may also demonstrate focal bronchial lesions, atelectasis, bullous disease, fibrosis/honeycombing, cavitary lung disease, bronchiectasis (saccular or cylindrical) and mycetomas

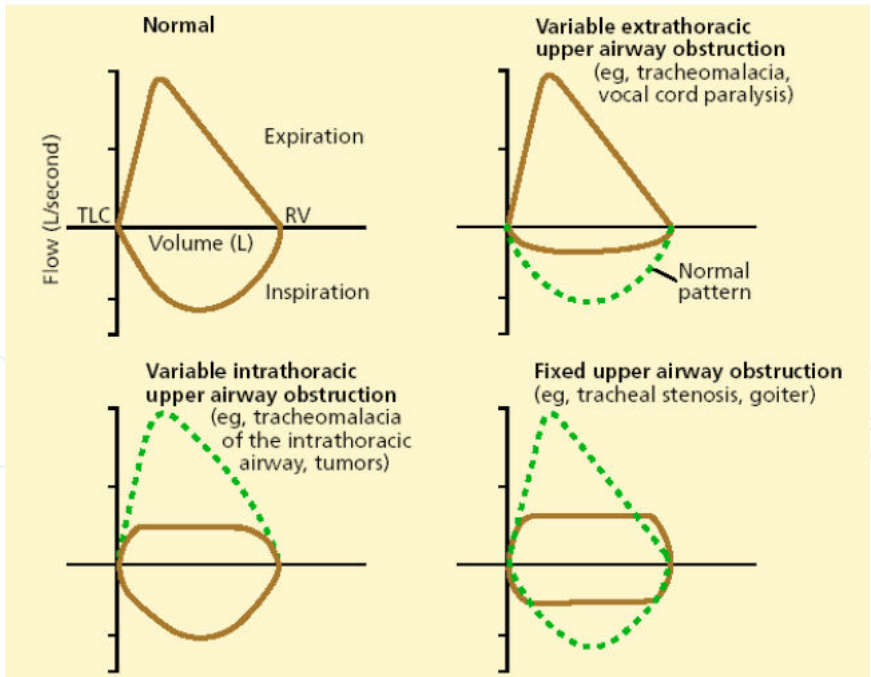
## 8. Physiology

The respiratory tract is typically divided into the upper and lower airways at the level of the vocal cords. The physiology of obstruction to the upper airways depends on the location of the obstruction (intrathoracic or extrathoracic) and whether it is fixed or variable within the respiratory cycle. Granulomatous involvement of the larynx results in a fixed upper airway obstruction. When tracheal sarcoidosis results in stenosis, it may cause a fixed upper airway obstruction (figure 4) or a variable extrathoracic or intrathoracic obstruction (figure 4) depending on whether it is located above (extrathoracic) or below (intrathoracic) the thoracic inlet (level of the supra-sternal notch). In a fixed upper airway obstruction, there is flattening of the inspiratory and expiratory limbs of the flow volume loop. A variable extrathoracic obstruction causes flattening of the inspiratory portion of the flow volume loop, while a variable intrathoracic obstruction causes flattening of the expiratory portion of the loop.

Spirometry commonly indicates restrictive ventilatory dysfunction. At least 50% of patients have concurrent obstructive airways disease, evidenced by a reduced ratio of forced expiratory volume in 1 second (FEV1) to forced vital capacity (FVC). [2, 68] Airway hyperreactivity assessed by methacholine challenge test occurs in 5-83% of patients. [47, 68]



**Figure 4.** Sarcoidosis patient with “honeycomb lung”.



TLC = Total Lung Capacity, RV = Residual Volume  
Adapted with permission from Kavuru et al...Essentials of Pulmonary and Critical care Medicine. 5<sup>th</sup> Edition. Philadelphia. Lippincott, Williams and Wilkins, 2005.

**Figure 5.** Flow volume loops demonstrating various types of airways obstruction.

## 9. Bronchoscopy

The diagnosis of sarcoidosis is confirmed by histologic evidence of non-caseating, epithelioid granulomas. Tissue is obtained from the upper airways by direct nasopharyngoscopy. Transbronchial and/or mucosal biopsies of the lower airways may be obtained by bronchoscopy, the diagnostic procedure of choice for sarcoidosis.

## 10. Treatment

There are no controlled studies that examine the variety of therapeutic agents, which are purported to be effective in the treatment of sarcoidosis. There is consensus by experienced physicians that corticosteroids are the most efficacious medication. None of the other therapies share this favorable level of support. Oral corticosteroids are given in the smallest possible dose to limit their adverse effects. Since upper airways obstruction occurs in chronic sarcoidosis, 'steroid-sparing' medications may be administered simultaneously to reduce the corticosteroid dose that would be needed if it is given for many months. Hydroxychloroquine has been used with some success for cutaneous sarcoidosis. [69] Minocycline is also effective for the treatment of skin lesions. [70, 71] Minocycline appears to inhibit metalloproteinases, angiogenesis, apoptosis and in vitro granuloma formation. [68, 72]

The treatment of sinus and nasal sarcoidosis should be tailored to the specific organ system or systems involved and to the extent of disease. [14, 16] Isolated sinonasal disease can be treated by topical corticosteroids and/or intra-lesional steroid injections. [73] Nasal irrigations and emollients may be used to ameliorate nasal crusting. Siltzbach and Teirstein used chloroquine to treat 14 patients with intrathoracic and cutaneous sarcoidosis. All of the patients showed relative improvement in their cutaneous lesions and most exhibited radiographic improvement of their intrathoracic disease. Johns and colleagues used hydroxychloroquine, a drug with less ocular toxicity, to treat mucosal lesions. [74] Patients taking hydroxychloroquine must have an ophthalmic exam every 6 months. Hassid reported a patient with biopsy-proven sarcoidosis of the paranasal sinuses who was successfully treated with hydroxychloroquine 200 mg orally, twice daily for one month and 200 mg per day for an additional 7 months. [75] Despite these results, the overall response rate for antimalarial drugs is probably less than 50% [76] and the drugs are often reserved for patients with cutaneous or sinonasal sarcoidosis, in whom the response to treatment can be easily observed. [76]

Methotrexate may also be used for the treatment of cutaneous sarcoidosis. In several case reports, skin lesions improved in patients who were treated with methotrexate 10 mg to 15 mg per week. [77] Although azathioprine has been commonly used as a corticosteroid-sparing agent for many forms of sarcoidosis, it has rarely been reported for the treatment of skin sarcoidosis. [7] Tumor necrosis factor- $\alpha$  (TNF- $\alpha$ ) antagonists have been reported to be useful in the treatment of sarcoidosis, including cutaneous sarcoidosis. [78] Infliximab appears to be the most efficacious of the biologics. It may be especially useful in the treatment of lupus pernio. [78]

The indication for surgical intervention of sinonasal granulomatous lesions is controversial.

While surgery may reduce symptoms, it does not eradicate or prevent recurrence of disease. [14, 17, 79] Neville and associates evaluated 34 patients with sarcoidosis of the upper respiratory tract, [9] 3 of whom, underwent submucous resection. In 2 of 3 patients the resection was complicated by nasal septal perforation. Aubart and colleagues operated on 7 patients. [17] Nasal and sinus involvement recurred in all of them and sinus symptoms worsened in 1 patient after surgery. But two additional studies suggest that endoscopic sinus surgery may have a therapeutic role in patients with nasal obstruction or chronic sinusitis caused by anatomic blockage from sinonasal sarcoidosis. [18, 80] Removal of the obstructing lesion(s) may facilitate improved sinonasal hygiene by permitting endoscopic debridement, nasal irrigation and topical administration of medicines into the sinonasal tract. Surgical intervention should not be used to treat patients with symptoms related to crusting, atrophy or bleeding. While surgery may improve one's quality of life by relieving severe symptoms and may even reduce the need for oral steroids, it is almost never curative.

Laryngeal sarcoidosis may cause life-threatening upper airway obstruction. As a result, early diagnosis and proper management is essential. The treatment of laryngeal sarcoidosis depends on the severity of the symptoms. Asymptomatic patients do not require therapy. [5, 19, 81] But close monitoring is warranted. It may be difficult to assess the efficacy of various treatment modalities because spontaneous remissions of disease punctuate the natural evolution of sarcoidosis. [51, 67] Systemic corticosteroids are the mainstay of treatment for laryngeal sarcoidosis, especially for impending laryngeal obstruction. [1, 10] Methotrexate has been used with some success in the treatment of laryngeal sarcoidosis. One patient with granulomatous laryngitis responded to treatment with azathioprine. Intra-lesional steroid injections of the larynx for selected patients with well-circumscribed disease is modestly effective. [5, 21] When the airway is compromised and stridor is present, emergent tracheostomy should be performed. [21] Tracheostomy may also be an appropriate for patients who develop marked adverse effects from systemic corticosteroids. [82] Tracheostomy is often used as a temporizing measure until corticosteroids are able to effectively reduce granulomatous inflammation. Surgical intervention for laryngeal sarcoidosis is effective for patients with well-localized, life threatening lesions. [5] Typically, the goals of surgery are to create an adequate airway, avoid aspiration, avoid tracheostomy and preserve the voice. [5, 83] Low-dose external beam radiation therapy (3000 rads during 6 weeks) has been utilized in selected patients. [5, 84] It is generally reserved for patients in whom intra-lesional steroids or local excision of granulomatous tissue are not feasible and/or in those who are refractory to or cannot tolerate systemic corticosteroids. [5, 82]

Tracheal involvement in sarcoidosis is limited to the description of tracheal dystonia [29] and tracheal stenosis. [29, 30] Brandstetter and colleagues used high-dose systemic corticosteroids to treat a patient with tracheal stenosis. The patient failed to stabilize with the treatment but ultimately underwent successful bronchoscopic tracheal dilatation. [30] Tracheal stents have been used with limited success for tracheobronchial obstruction in pediatric patients. [85]

Patients with bronchostenosis respond poorly to treatment with systemic corticosteroids. [33, 37, 46, 47, 53] Fouty and associates used a flexible fiberoptic bronchoscope and a Fogarty

embolectomy catheter to dilate multiple bronchial stenoses under direct vision. [86] The six patients who underwent the procedure were symptomatic and refractory to corticosteroids. All of them obtained subjective symptomatic benefit from the dilatation. Three of the patients required repeated dilatation on a long-term basis. Complications from the procedure were minimal. Collectively, these studies suggest that bronchial dilatation is a safe option for sarcoidosis patients with stenoses who are refractory to systemic corticosteroids.

The majority of patients with sarcoidosis improve with therapy. However, 10-30% of patients develop progressive pulmonary fibrosis, which may result in advanced airways disease such as bronchiectasis, bullae and cavitation. Rarely, patients with bronchiectasis will improve with corticosteroids, antibiotics and/or nonsteroidal anti-inflammatory medications. [87] If patients do respond, it is generally short-lived. Bullectomies performed for bullous sarcoidosis may improve pulmonary function and symptoms. [57, 58] Surgical resection of the cavity and removal of the fungus ball is the mainstay of treatment for aspergilloma(s). [88] The primary indication for resection is recurrent hemoptysis. Bronchial artery embolization is modestly effective in inoperable patients. [89] Taken together, advanced involvement in sarcoidosis is seldom responsive to medical therapy, moderately responsive to surgical therapy depending on the type of underlying disease and has an ominous prognosis. Finally, sarcoidosis patients with fibrotic lung disease and/or airways dysfunction often develop pulmonary hypertension, which often has an unfavorable prognosis.

## 11. Summary

Sarcoidosis is a chronic granulomatous disease of undetermined etiology that can involve any organ system within the body. Greater than 90% of patients with sarcoidosis have interstitial lung disease. [2] But the upper and lower respiratory tract is also affected. Sarcoidosis is one of a few interstitial lung diseases that involves the entire respiratory tract; beginning at the nose and ending at the terminal bronchioles.

Although many patients are asymptomatic, most complain of dyspnea, cough and/or wheezing. Patients with sarcoidosis of the upper respiratory tract present with a variety of symptoms, which are primarily determined by the anatomic location of the granulomatous inflammation and/or scarring that may result from chronic disease. The diagnosis of upper or lower respiratory tract disease is frequently ascertained by bronchoscopy.

Computed tomography (CT), the imaging method of choice for sarcoidosis of the upper and lower respiratory tract, may demonstrate lesions within the sinonasal tract, larynx and trachea, large and small airways or parenchyma. It may also reveal mediastinal and/or hilar lymphadenopathy.

The physiology of airways obstruction depends on the location of the obstruction (intrathoracic or extrathoracic) and whether it is fixed or variable within the respiratory cycle. Granulomatous involvement of the larynx results in a fixed upper airway obstruction. Tracheal sarcoidosis may cause a fixed upper airway obstruction, or a variable extrathoracic or intrathoracic

obstruction, depending on whether the lesion is located above (extrathoracic) or below (intrathoracic) the thoracic inlet (level of the supra-sternal notch).

Patients with pulmonary sarcoidosis may exhibit obstructive, restrictive, restrictive and obstructive, or gas transfer abnormalities. Corticosteroids are the mainstay of therapy for upper respiratory tract disease. However, other immunosuppressive treatments may be effective for the treatment of skin and sinonasal sarcoidosis. Patients with endobronchial or tracheal stenoses who are refractory to steroid therapy may derive some benefit from mechanical dilatation of the airways. [86] Surgical intervention may be required for treatment of bullous sarcoidosis and aspergilloma. [57, 58]

## Author details

Adam S. Morgenthau

Address all correspondence to: adam.morgenthau@mssm.edu

The Mount Sinai School of Medicine, Department of Medicine, Division of Pulmonary, Critical Care and Sleep Medicine, New York, NY, USA

Dr. Morgenthau discloses no conflicts of interest.

## References

- [1] Laohaburanakit, P, & Chan, A. Obstructive sarcoidosis. *Clin Rev Allergy Immunol.* (2003). Oct;; 25(2), 115-29.
- [2] Baughman, R. P, Teirstein, A. S, Judson, M. A, Rossman, M. D, & Yeager, H. Jr., Bresnitz EA, et al. Clinical characteristics of patients in a case control study of sarcoidosis. *Am J Respir Crit Care Med.* (2001). Nov 15;164(10 Pt 1):1885-9.\*\* A large study that discusses the clinical characteristics of patients with sarcoidosis.
- [3] Mccaffrey, T. V, & Mcdonald, T. J. Sarcoidosis of the nose and paranasal sinuses. *Laryngoscope.* (1983). Oct;; 93(10), 1281-4.
- [4] Rosell, A, Garcia-arranz, G, Romero, N, Sendra, J, & Fogue, L. Lupus pernio with involvement of nasal cavity and maxillary sinus. *ORL J Otorhinolaryngol Relat Spec.* (1998). Jul-Aug;; 60(4), 236-9.
- [5] Dean, C. M, Sataloff, R. T, Hawkshaw, M. J, & Pribikin, E. Laryngeal sarcoidosis. *J Voice.* (2002). Jun;; 16(2), 283-8.
- [6] Zeitlin, J. F, Tami, T. A, Baughman, R, & Winget, D. Nasal and sinus manifestations of sarcoidosis. *Am J Rhinol.* (2000). May-Jun;; 14(3), 157-61.

- [7] Marchell, R. M, & Judson, M. A. Cutaneous sarcoidosis. *Semin Respir Crit Care Med.* (2010). Aug;; 31(4), 442-51.
- [8] Maples, C. J, & Counselman, F. L. Lupus pernio. *J Emerg Med.* (2007). Aug;; 33(2), 187-9.
- [9] Neville, E, Mills, R. G, & James, D. G. Sarcoidosis of the upper respiratory tract and its relation to lupus pernio. *Ann N Y Acad Sci.* (1976). , 278, 416-26.
- [10] Polychronopoulos, V. S, & Prakash, U. B. Airway involvement in sarcoidosis. *Chest.* (2009). Nov;A review article that discusses airway involvement in sarcoidosis., 136(5), 1371-80.
- [11] Deshazo, R. D, Brien, O, Justice, M. M, & Pitcock, W. K. J. Diagnostic criteria for sarcoidosis of the sinuses. *J Allergy Clin Immunol.* (1999). May;103(5 Pt 1):789-95.
- [12] Fergie, N, Jones, N. S, & Havlat, M. F. The nasal manifestations of sarcoidosis: a review and report of eight cases. *J Laryngol Otol.* (1999). Oct,, 113(10), 893-8.
- [13] Shipchandler, T. Z, Chung, B. J, & Alam, D. S. Saddle nose deformity reconstruction with a split calvarial bone L-shaped strut. *Arch Facial Plast Surg.* (2008). Sep-Oct,, 10(5), 305-11.
- [14] Gurkov, R, & Berghaus, A. Nasal reconstruction in advanced sinunasal sarcoidosis. *Rhinology.* (2009). Sep;; 47(3), 327-9.
- [15] Reed, J, Deshazo, R. D, Houle, T. T, Stringer, S, Wright, L, & Moak, J. S. rd. Clinical features of sarcoid rhinosinusitis. *Am J Med.* (2010). Sep,, 123(9), 856-62.
- [16] Dessouky, O. Y. Isolated sinonasal sarcoidosis with intracranial extension: case report. *Acta Otorhinolaryngol Ital.* (2008). Dec;; 28(6), 306-8.
- [17] Aubart, F. C, Ouayoun, M, Brauner, M, Attali, P, Kambouchner, M, Valeyre, D, et al. Sinonasal involvement in sarcoidosis: a case-control study of 20 patients. *Medicine (Baltimore).* (2006). Nov;A study that discusses sinonasal sarcoidosis., 85(6), 365-71.
- [18] Long, C. M, Smith, T. L, Loehrl, T. A, Komorowski, R. A, & Toohill, R. J. Sinonasal disease in patients with sarcoidosis. *Am J Rhinol.* (2001). May-Jun,, 15(3), 211-5.
- [19] Devine, K. D. Sarcoidosis and Sarcoidosis of the Larynx. *Laryngoscope.* (1965). Apr,, 75, 533-69.
- [20] Braun, J. J, Gentine, A, & Pauli, G. Sinonasal sarcoidosis: review and report of fifteen cases. *Laryngoscope.* (2004). Nov;; 114(11), 1960-3.
- [21] Baughman, R. P, Lower, E. E, & Tami, T. Upper airway. 4: Sarcoidosis of the upper respiratory tract (SURT). *Thorax.* (2010). Feb;A review article that discusses upper airways disease in sarcoidosis., 65(2), 181-6.

- [22] Coffey, C. S, Vallejo, S. L, Farrar, E. K, Judson, M. A, & Halstead, L. A. Sarcoidosis presenting as bilateral vocal cord paralysis from bilateral compression of the recurrent laryngeal nerves from thoracic adenopathy. *J Voice*. (2009). Sep;; 23(5), 631-4.
- [23] Jaffe, R, Bogomolski-yahalom, V, & Kramer, M. R. Vocal cord paralysis as the presenting symptom of sarcoidosis. *Respir Med*. (1994). Sep;; 88(8), 633-6.
- [24] Teirstein, A. Neuromuscular sarcoidosis. *Semin Respir Crit Care Med*. (2002). Dec;; 23(6), 505-12.
- [25] Tobias, J. K, Santiago, S. M, & Williams, A. J. Sarcoidosis as a cause of left recurrent laryngeal nerve palsy. *Arch Otolaryngol Head Neck Surg*. (1990). Aug;; 116(8), 971-2.
- [26] Fuso, L, Maiolo, C, Tramaglino, L. M, Benedetto, R. T, Russo, A. R, Spadaro, S, et al. Orolaryngeal sarcoidosis presenting as obstructive sleep apnoea. *Sarcoidosis Vasc Diffuse Lung Dis*. (2001). Mar;; 18(1), 85-90.
- [27] Turner, G. A, Lower, E. E, Corser, B. C, Gunther, K. L, & Baughman, R. P. Sleep apnea in sarcoidosis. *Sarcoidosis Vasc Diffuse Lung Dis*. (1997). Mar;; 14(1), 61-4.
- [28] Miller, A, Brown, L. K, & Teirstein, A. S. Stenosis of main bronchi mimicking fixed upper airway obstruction in sarcoidosis. *Chest*. (1985). Aug;; 88(2), 244-8.
- [29] Ellefsen, P. Tracheal dystonia and sarcoidosis. *Acta Otolaryngol*. (1970). Nov-Dec;; 70(5), 438-42.
- [30] Brandstetter, R. D, Messina, M. S, Sprince, N. L, & Grillo, H. C. Tracheal stenosis due to sarcoidosis. *Chest*. (1981). Nov;;80(5):656.
- [31] Rockoff, S. D, & Rohatgi, P. K. Unusual manifestations of thoracic sarcoidosis. *AJR Am J Roentgenol*. (1985). Mar;; 144(3), 513-28.
- [32] Corsello, B. F, Lohaus, G. H, & Funahashi, A. Endobronchial mass lesion due to sarcoidosis: complete resolution with corticosteroids. *Thorax*. (1983). Feb;; 38(2), 157-8.
- [33] Hadfield, J. W, Page, R. L, Flower, C. D, & Stark, J. E. Localised airway narrowing in sarcoidosis. *Thorax*. (1982). Jun;; 37(6), 443-7.
- [34] Teo, F, Anantham, D, Feller-kopman, D, & Ernst, A. Bronchoscopic management of sarcoidosis related bronchial stenosis with adjunctive topical mitomycin C. *Ann Thorac Surg*. (2010). Jun;; 89(6), 2005-7.
- [35] Baba, K, Yamaguchi, E, Matsui, S, Niwa, S, Onoe, K, Yagi, T, et al. A case of sarcoidosis with multiple endobronchial mass lesions that disappeared with antibiotics. *Sarcoidosis Vasc Diffuse Lung Dis*. (2006). Mar;; 23(1), 78-9.
- [36] Yamada, G, Aketa, K, Takahashi, H, Satoh, M, & Abe, S. Endobronchial lesions of sarcoidosis. *Intern Med*. (2005). Aug;; 44(8), 909-10.
- [37] Chambellan, A, Turbie, P, Nunes, H, Brauner, M, Battesti, J. P, & Valeyre, D. Endoluminal stenosis of proximal bronchi in sarcoidosis: bronchoscopy, function, and evo-

- lution. *Chest*. (2005). Feb;A study that discusses endobronchial sarcoidosis., 127(2), 472-81.
- [38] Olsson, T, Bjornstad-pettersen, H, & Stjernberg, N. L. Bronchostenosis due to sarcoidosis: a cause of atelectasis and airway obstruction simulating pulmonary neoplasm and chronic obstructive pulmonary disease. *Chest*. (1979). Jun;, 75(6), 663-6.
- [39] Mendelson, D. S, Norton, K, Cohen, B. A, Brown, L. K, & Rabinowitz, J. G. Bronchial compression: an unusual manifestation of sarcoidosis. *J Comput Assist Tomogr*. (1983). Oct;, 7(5), 892-4.
- [40] Criado, E, Sanchez, M, Ramirez, J, Arguis, P, De Caralt, T. M, Perea, R. J, et al. Pulmonary sarcoidosis: typical and atypical manifestations at high-resolution CT with pathologic correlation. *Radiographics*. (2010). Oct;, 30(6), 1567-86.
- [41] Davies, C. W, Tasker, A. D, Padley, S. P, Davies, R. J, & Gleeson, F. V. Air trapping in sarcoidosis on computed tomography: correlation with lung function. *Clin Radiol*. (2000). Mar;, 55(3), 217-21.
- [42] Fain, S, Schiebler, M. L, McCormack, D. G, & Parraga, G. Imaging of lung function using hyperpolarized helium-3 magnetic resonance imaging: Review of current and emerging translational methods and applications. *J Magn Reson Imaging*. (2010). Dec;, 32(6), 1398-408.
- [43] Burgel, P. R. The role of small airways in obstructive airway diseases. *Eur Respir Rev*. (2011). Mar 1;, 20(119), 23-33.
- [44] Kamp, D. W. Physiologic evaluation of asthma. *Chest*. (1992). Jun;101(6 Suppl): 396S-400S.
- [45] Kabitz, H. J, Lang, F, Walterspacher, S, Sorichter, S, Muller-quernheim, J, & Windisch, W. Impact of impaired inspiratory muscle strength on dyspnea and walking capacity in sarcoidosis. *Chest*. (2006). Nov;, 130(5), 1496-502.
- [46] Pesola, G. R, Kurdi, M, & Olibrice, M. Endobronchial sarcoidosis and hyperreactive airways disease. *Chest*. (2002). Jun;121(6):2081; author reply
- [47] Shorr, A. F, Torrington, K. G, & Hnatiuk, O. W. Endobronchial involvement and airway hyperreactivity in patients with sarcoidosis. *Chest*. (2001). Sep;A study that discusses endobronchial disease and airways hyperreactivity in sarcoidosis., 120(3), 881-6.
- [48] Viskum, K, & Vestbo, J. Vital prognosis in intrathoracic sarcoidosis with special reference to pulmonary function and radiological stage. *Eur Respir J*. (1993). Mar;, 6(3), 349-53.
- [49] Westney, G. E, Habib, S, & Quarshie, A. Comorbid illnesses and chest radiographic severity in African-American sarcoidosis patients. *Lung*. (2007). May-Jun;, 185(3), 131-7.

- [50] Plusa, T, Chcialowski, A, Piechota, W, & Pirozynski, M. Activity of angiotensin I converting enzyme in sarcoidosis, atopic bronchial asthma and acute bronchitis. *Allergol Immunopathol (Madr)*. (1990). Jul-Aug,, 18(4), 217-21.
- [51] Naccache, J. M, Lavole, A, Nunes, H, Lamberto, C, Letoumelin, P, Brauner, M, et al. High-resolution computed tomographic imaging of airways in sarcoidosis patients with airflow obstruction. *J Comput Assist Tomogr*. (2008). Nov-Dec,, 32(6), 905-12.
- [52] Lavergne, F, Clerici, C, Sadoun, D, Brauner, M, Battesti, J. P, & Valeyre, D. Airway obstruction in bronchial sarcoidosis: outcome with treatment. *Chest*. (1999). Nov,, 116(5), 1194-9.
- [53] Witko, J, Strazzella, W. D, & Safirstein, B. H. Upper lobe collapse due to endobronchial sarcoidosis. *AJR Am J Roentgenol*. (1990). Apr,, 154(4), 897-8.
- [54] Stinson, J. M, & Hargett, D. Prolonged lobar atelectasis in sarcoidosis. *J Natl Med Assoc*. (1981). , 73(7), 669-71.
- [55] Sharma, O. P, & Izumi, T. The importance of airway obstruction in sarcoidosis. *Sarcoidosis*. (1988). Sep,, 5(2), 119-20.
- [56] Rosen, Y. Pathology of sarcoidosis. *Semin Respir Crit Care Med*. (2007). Feb;A review article that discusses the granuloma formation and histopathology in sarcoidosis., 28(1), 36-52.
- [57] Judson, M. A, & Strange, C. Bullous sarcoidosis: a report of three cases. *Chest*. (1998). Nov,, 114(5), 1474-8.
- [58] Jeebun, V, & Forrest, I. A. Sarcoidosis: an underrecognised cause for bullous lung disease? *Eur Respir J*. (2009). Oct,, 34(4), 999-1001.
- [59] Miller, A. The vanishing lung syndrome associated with pulmonary sarcoidosis. *Br J Dis Chest*. (1981). Apr;A review article that discusses the vanishing lung syndrome associated with sarcoidosis., 75(2), 209-14.
- [60] Miller, A, Teirstein, A. S, Jackler, I, Chuang, M, & Siltzbach, L. E. Airway function in chronic pulmonary sarcoidosis with fibrosis. *Am Rev Respir Dis*. (1974). Feb,, 109(2), 179-89.
- [61] Seaman, D. M, Meyer, C. A, Gilman, M. D, & McCormack, F. X. Diffuse Cystic Lung Disease at High-Resolution CT. *AJR Am J Roentgenol*. (2011). Jun,, 196(6), 1305-11.
- [62] Akbari, J. G, Varma, P. K, Neema, P. K, Menon, M. U, & Neelakandhan, K. S. Clinical profile and surgical outcome for pulmonary aspergilloma: a single center experience. *Ann Thorac Surg*. (2005). Sep,, 80(3), 1067-72.
- [63] Judson, M. A. Noninvasive Aspergillus pulmonary disease. *Semin Respir Crit Care Med*. (2004). Apr,, 25(2), 203-19.

- [64] Israel, H. L, Lenchner, G. S, & Atkinson, G. W. Sarcoidosis and aspergilloma. The role of surgery. *Chest*. (1982). Oct;; 82(4), 430-2.
- [65] Glastonbury, C. M. Non-oncologic imaging of the larynx. *Otolaryngol Clin North Am*. (2008). Feb;vi., 41(1), 139-56.
- [66] Hansell, D. M, Milne, D. G, Wilsher, M. L, & Wells, A. U. Pulmonary sarcoidosis: morphologic associations of airflow obstruction at thin-section CT. *Radiology*. (1998). Dec;; 209(3), 697-704.
- [67] Handa, T, Nagai, S, Hirai, T, Chin, K, Kubo, T, Oga, T, et al. Computed tomography analysis of airway dimensions and lung density in patients with sarcoidosis. *Respiration*. (2009). , 77(3), 273-81.
- [68] Iannuzzi, M. C, Rybicki, B. A, & Teirstein, A. S. Sarcoidosis. *N Engl J Med*. (2007). Nov 22;A clinical review article on sarcoidosis., 357(21), 2153-65.
- [69] Jones, E, & Callen, J. P. Hydroxychloroquine is effective therapy for control of cutaneous sarcoidal granulomas. *J Am Acad Dermatol*. (1990). Sep;23(3 Pt 1):487-9.
- [70] Miyazaki, E, Ando, M, Fukami, T, Nureki, S, Eishi, Y, & Kumamoto, T. Minocycline for the treatment of sarcoidosis: is the mechanism of action immunomodulating or antimicrobial effect? *Clin Rheumatol*. (2008). Sep;; 27(9), 1195-7.
- [71] Bachelez, H, Senet, P, Cadranet, J, Kaoukhov, A, & Dubertret, L. The use of tetracyclines for the treatment of sarcoidosis. *Arch Dermatol*. (2001). Jan;; 137(1), 69-73.
- [72] Sapadin, A. N, & Fleischmajer, R. Tetracyclines: nonantibiotic properties and their clinical implications. *J Am Acad Dermatol*. (2006). Feb;; 54(2), 258-65.
- [73] Siltzbach, L. E, & Teirstein, A. S. Chloroquine therapy in 43 patients with intrathoracic and cutaneous sarcoidosis. *Acta Med Scand Suppl*. (1964). , 425, 302-8.
- [74] Johns, C. J, & Michele, T. M. The clinical management of sarcoidosis. A 50-year experience at the Johns Hopkins Hospital. *Medicine (Baltimore)*. (1999). Mar;A review article that discusses the management of sarcoidosis., 78(2), 65-111.
- [75] Hassid, S, Choufani, G, Saussez, S, Dubois, M, Salmon, I, & Soupart, A. Sarcoidosis of the paranasal sinuses treated with hydroxychloroquine. *Postgrad Med J*. (1998). Mar;; 74(869), 172-4.
- [76] Baughman, R. P, & Costabel, U. du Bois RM. Treatment of sarcoidosis. *Clin Chest Med*. (2008). Sep;ix-x.\* A review article that discusses the treatment of sarcoidosis., 29(3), 533-48.
- [77] Baughman, R. P, & Lower, E. E. Evidence-based therapy for cutaneous sarcoidosis. *Clin Dermatol*. (2007). May-Jun;; 25(3), 334-40.

- [78] Stagaki, E, Mountford, W. K, Lackland, D. T, & Judson, M. A. The treatment of lupus pernio: results of 116 treatment courses in 54 patients. *Chest*. (2009). Feb;; 135(2), 468-76.
- [79] Preminger, B. A, Hiltzik, D. H, Segal, J, & Morrison, N. G. An operative approach to the treatment of refractory cutaneous nasal sarcoid: a case report and review of the literature. *Ann Plast Surg*. (2009). Dec;; 63(6), 685-7.
- [80] Kay, D. J, & Har-el, G. The role of endoscopic sinus surgery in chronic sinonasal sarcoidosis. *Am J Rhinol*. (2001). Jul-Aug;; 15(4), 249-54.
- [81] Benjamin, B, Dalton, C, & Croxson, G. Laryngoscopic diagnosis of laryngeal sarcoid. *Ann Otol Rhinol Laryngol*. (1995). Jul;; 104(7), 529-31.
- [82] Levey, M. Extensive sarcoidosis involving the upper respiratory tract. *Int Surg*. (1979). Apr;; 64(3), 73-7.
- [83] Gallivan, G. J, & Landis, J. N. Sarcoidosis of the larynx: preserving and restoring airway and professional voice. *J Voice*. (1993). Mar;; 7(1), 81-94.
- [84] Fogel, T. D, Weissberg, J. B, Dobular, K, & Kirchner, J. A. Radiotherapy in sarcoidosis of the larynx: case report and review of the literature. *Laryngoscope*. (1984). Sep;; 94(9), 1223-5.
- [85] Anton-pacheco, J. L, Cabezali, D, Tejedor, R, Lopez, M, Luna, C, Comas, J. V, et al. The role of airway stenting in pediatric tracheobronchial obstruction. *Eur J Cardiothorac Surg*. (2008). Jun;; 33(6), 1069-75.
- [86] Fouty, B. W, Pomeranz, M, Thigpen, T. P, & Martin, R. J. Dilatation of bronchial stenoses due to sarcoidosis using a flexible fiberoptic bronchoscope. *Chest*. (1994). Sep;; 106(3), 677-80.
- [87] ten Hacken NHWijkstra PJ, Kerstjens HA. Treatment of bronchiectasis in adults. *BMJ*. (2007). Nov 24;; 335(7629), 1089-93.
- [88] Panjabi, C, Sahay, S, & Shah, A. Aspergilloma formation in cavitary sarcoidosis. *J Bras Pneumol*. (2009). May;; 35(5), 480-3.
- [89] Corr, P. Management of severe hemoptysis from pulmonary aspergilloma using endovascular embolization. *Cardiovasc Intervent Radiol*. (2006). Sep-Oct;; 29(5), 807-10.