

We are IntechOpen, the world's leading publisher of Open Access books Built by scientists, for scientists

6,900

Open access books available

186,000

International authors and editors

200M

Downloads

Our authors are among the

154

Countries delivered to

TOP 1%

most cited scientists

12.2%

Contributors from top 500 universities



WEB OF SCIENCE™

Selection of our books indexed in the Book Citation Index
in Web of Science™ Core Collection (BKCI)

Interested in publishing with us?
Contact book.department@intechopen.com

Numbers displayed above are based on latest data collected.
For more information visit www.intechopen.com



Treatment with Methotrexate in Patients with Sarcoidosis

Sonoko Nagai and Takateru Izumi

Additional information is available at the end of the chapter

<http://dx.doi.org/10.5772/55042>

1. Introduction

Sarcoidosis is a systemic inflammatory disease of unknown etiology. The hallmark histological feature of the disease is epithelioid cell granuloma derived from activated T cells and macrophages triggered by unknown immune stimuli such as bacterial protein or beryllium metal [1, 2]. Various inflammatory cytokines and growth factors can participate in the pathophysiological processes of sarcoidosis [1].

Sarcoidosis is fundamentally a chronic inflammatory disease. The pathological and clinical courses vary widely from spontaneous regression to fibrotic progression leading to various patterns of organ dysfunction [3].

Any of the following may be selected as therapeutic targets for sarcoidosis, depending on the pathophysiology and evolution of the disease: 1) delete the etiological agents, 2) attenuate the hyperimmune reactions directly underlying the epithelioid cell granuloma formation, 3) arrest any pathophysiological processes that tend to persist, 4) relieve functional disturbances caused by fibrotic lesions, 5) replace disabled organs by transplantation.

It is critical to grasp or predict the whole clinical course of sarcoidosis when considering therapies.

Corticosteroids, the established standard therapy for sarcoidosis, have drawbacks. While corticosteroids are reliably therapeutic, some patients manifest adverse effects during treatment or functional declines in spite of treatment [4]. Corticosteroids may also disturb the defensive function of granulomas surrounding etiological antigens or disturb healing processes by attenuating various inflammatory processes homogeneously.

In this article we review the widely variable clinical courses sarcoidosis is known to take. We also try to propose a therapeutic strategy for stably managing chronic sarcoidosis, especially for patients with involvement of vital organs such as the lung and heart.

2. Therapeutic problems and clinical courses

The clinical courses of sarcoidosis vary considerably. The disease spontaneously regresses in about 10-20 % of patients, persists in chronic form in another 30-50 %, relapses and recurs in another 20-30 %, and deteriorates in about 10 % [3].

The clinical phenotypes associated with the various clinical courses have been proposed based on a review of 400 sarcoidosis cases collected all over the world. The WASOG Task Force classified 9 phenotypes according to evaluations of clinical courses up to 5 years after detection (see Fig. 1) [5]. Among cases in Japan, sarcoidosis is presumed to reach the chronic stage when chest radiographic abnormalities persist for five years after detection [3]. According to the clinical phenotypes classified by WASOG, 17 % of cases spontaneously regress, 8 % deteriorate, 34 % manifest minimal remaining lesions with or without therapies, and 34 % progress to the chronic stage with or without treatment [5]. Among the patients who receive treatment, 40 % reportedly relapse after the corticosteroids are tapered or discontinued altogether [6]. The ACCESS study reported multiple lesion sites, lesion frequency by site, and various associations of clinical characteristics with the patient age, sex, number of lesions, and population differences [7]. Though the frequencies vary, functional deterioration has been reported in all affected organs. The clinical course of sarcoidosis is stable in 80 % of cases at 2 years after detection, though the prognosis tends to be worse in African Americans [8].

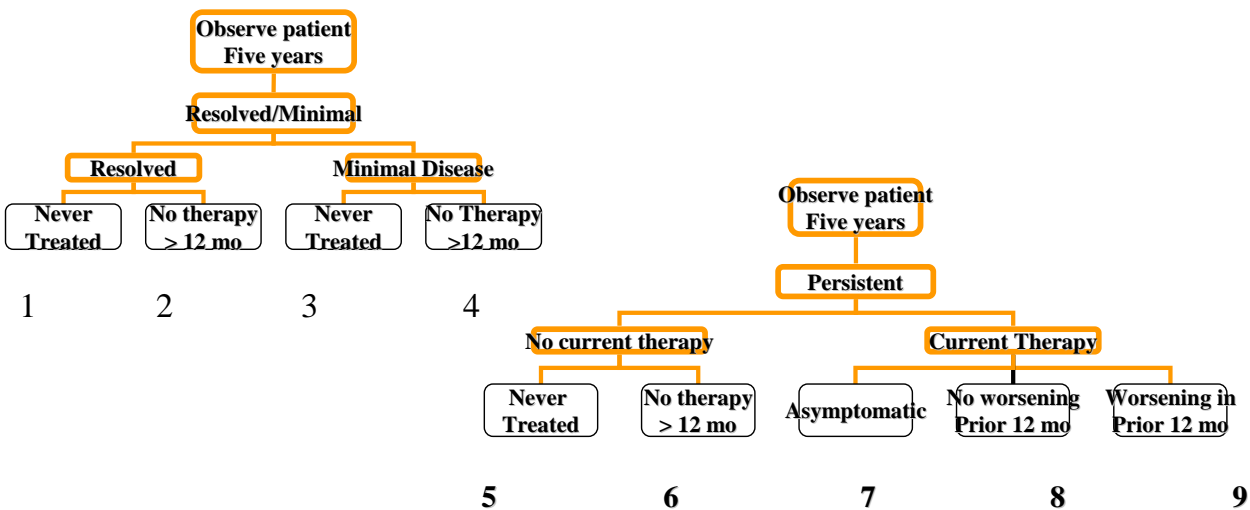


Figure 1. Clinical phenotypes of sarcoidosis patients proposed by WASOG 2005. Minimal disease is defined as less than 25 % of maximal lesions

3. Sarcoidosis therapy

Therapy is indicated for sarcoidosis patients with lesions of the heart, with pulmonary fibrosis in bronchovascular bundle areas, with neurosarcoidosis, and with systemic symptoms such as fever, malaise, and ocular lesions. The therapies administered tend to be prolonged in most patients with chronic lesions.

According to a meta-analysis by Reich, excessive corticosteroid therapy may unfavorably influence the long-term course of the disease in some individuals [9]. Among 948 sarcoidosis patients retrospectively reviewed by our group, 28 had advanced pulmonary sarcoidosis, 13 of those 28 advanced cases died, and 9 of those deceased cases had received corticosteroids [3]. Another retrospective study from Japan reported corticosteroid response in 70-80 % of 195 sarcoidosis patients, although the rate was lower, that is, only 48 %, in patients with cardiac sarcoidosis [4].

Methotrexate, one of the alternative drug treatments for sarcoidosis, is prescribed mainly for chronic sarcoidosis and can be expected to confer a steroid-sparing effect in addition to an immunomodulatory effect [10]. Methotrexate is reported to be therapeutically effective mainly in cases with skin lesions [11], ocular lesions [12], neuromuscular lesions [13], etc. In our clinical experience the agent is therapeutically effective, albeit incompletely, for sarcoidosis involving lesions of the lung, heart, and neuromuscular system. Long-term therapy is mandatory for chronic sarcoidosis, especially for the prevention of functional declines that can lead to congestive cardiac failure or sudden death in cases with cardiac lesions. Corticosteroid therapy may fail to prevent functional deteriorations longitudinally [12]. The Delphi study offered no precise guidance on how to treat sarcoidosis with corticosteroids or alternative agents [14,15].

In this chapter we try to introduce our own clinical experience with pulmonary and cardiac sarcoidosis.

3.1. Treatment for pulmonary sarcoidosis

Patients with sarcoidosis present with various types of pulmonary lesions, some of which spontaneously regress and some of which show fibrotic deterioration [16,17]. Fibrotic lesions situated along the bronchovascular bundle of the lung are likely to result in chronic airflow limitations [18] and bronchial distortions of a type often associated with infections such as nontuberculous mycobacterium, pseudomonas aeruginosa, and aspergillus fumigatus [16,19]. Some patients with pulmonary fibrosis also develop pulmonary hypertension [20]. Lung transplantation is considered when the disease progresses to a severe stage in patients under 60 years old [21,22].

Therapy itself might cause opportunistic infection under these circumstances. No medicines available at present are definitively effective at attenuating the fibrotic progression along the bronchovascular bundles. It usually takes 5-10 years before the fibrotic progression leads to chronic respiratory failure [3]. Longitudinal management and treatment must continue for long durations without adverse effects, as chronic respiratory failure persists for several years after it first manifests [3]. From this standpoint, methotrexate may be an available option for

pulmonary sarcoidosis. Unlike methotrexate therapy for rheumatoid arthritis, methotrexate for sarcoidosis has seldom led to drug-related pneumonia in our clinical experience.

Presentation of two cases

Case 1: 59-year-old male, never-smoker, no occupational exposure

Patient 1 visited our institution, Central Clinic, with complaints of a severe cough and exertional dyspnea. His chest radiograph showed diffuse pulmonary lesions with fibrosis mainly distributed on the upper and middle lung fields (Figure 2). Transbronchial lung biopsy revealed epithelioid cell granuloma. Having found no obvious infection at the initial examination, we started the patient on prednisolone (10 mg /day) and methotrexate (6 mg/week). After therapy his symptoms gradually attenuated. The opacities decreased during treatment in radiological images, but not drastically on CT findings (Figure 3). Pulmonary function results showed improved diffusion capacity and the patient reported an abatement of his cough and exertional dyspnea. The airflow limitation, however, gradually worsened (Table 1).

	Initial exam.	3 years	5 years
%FVC (%)	55.6	58.2	55.0
FEV1 (l)	1.88 l	1.56 l	1.48 l
FEV1% (%)	89.9	79.6	76.2
%DLCO (%)	51.3	61.5	61.4
EF	67.6	53.9	57.4
Reg.	I	I	I
sPAP mmHg	32.9	31.8	42.4
ACE	14.1	14.3	15.3
1,25-(OH)2VD	75.3		

FVC: forced vital capacity, FEV1: forced expiratory vital capacity one second,
DLCO: diffusion lung capacity carbon monoxide
EF: ejection fraction, Reg. : regurgitation, sPAP : systolic pulmonary artery pressure
ACE: angiotensin converting enzyme, 1,25-(OH)2 VD: 1,25-(OH)2 vitamine D

Table 1. Change in the functional or blood markers over time: 59 M Ns

No pulmonary hypertension appeared in a cardiac echogram. No blood markers suggestive of disease activity (serum ACE, 1,25-(OH)2 vitamin D) appeared in association with the treatment course (Table 1). The patient’s symptoms almost wholly abated and his prednisolone and methotrexate were tapered to 3 mg/day and 2 mg/week, respectively. No adverse effects were found during treatment.

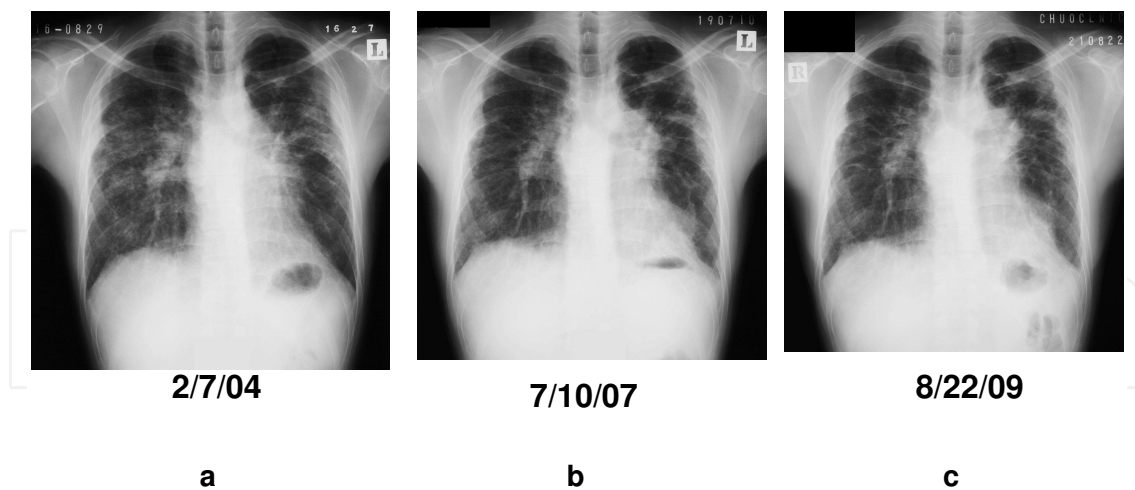


Figure 2. Longitudinal course of pulmonary fibrosis in patients with sarcoidosis: Plain chest radiograph 59-year-old male, nonsmoker, chief complaints of cough and exertional dyspnea a : when corticosteroids and methotrexate were introduced b: after 3 years of treatment c: after 5 years of treatment

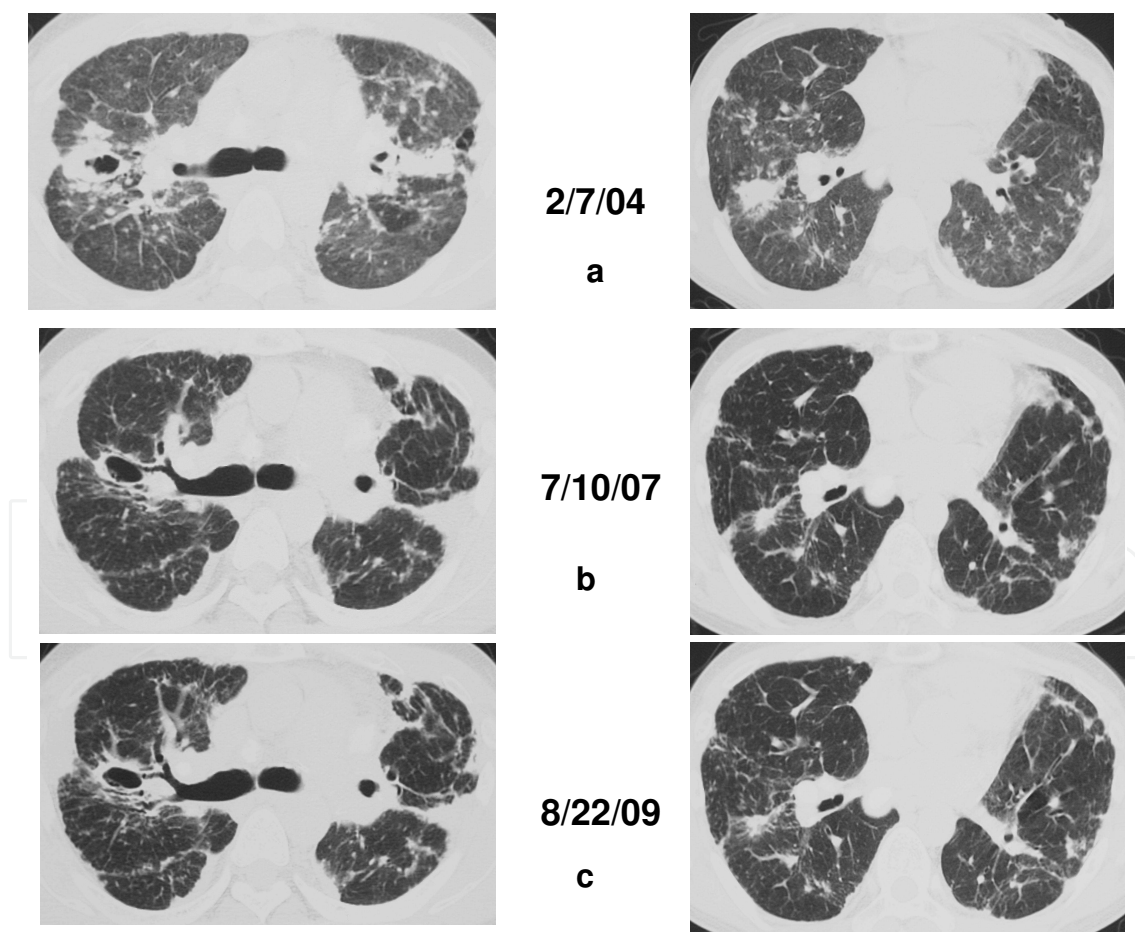


Figure 3. Longitudinal course of pulmonary fibrosis in patients with sarcoidosis: High-resolution CT findings a : when corticosteroids and methotrexate were introduced b: after 3 years of treatment c: after 5 years of treatment

Case 2. 60-year-old male, ex-smoker, no occupational exposure

Ocular lesions and BHL were detected by a health survey 27 years earlier, in 1982. A trans-bronchial lung biopsy at the time revealed epithelioid cell granuloma, and few parenchymal lesions of the lung were evident on HRCT. After an initial examination at Kyoto University, the patient moved away from Kyoto for his work. In the intervening 27 years we had no opportunity to follow his condition. In 2008, the patient visited our clinic because of exertional dyspnea and a severe cough with sputum production. Bilateral fibrotic lung lesions had developed on his upper lungs (Figure 4). Having detected no obvious infection, we started the patient on prednisolone (5 mg/day) and methotrexate (6 mg/week). His symptoms improved considerably by the end of the third month after treatment and he remained stable thereafter. Pulmonary function results also demonstrated a mild increase in %DLCO 18 months after the treatment commenced (Table 2).

	27 yrs before	PSL+MTX	3 mos	12 mos	18 mos
%FVC (%)	68.2	61.3	66.1	70.4	69.1
FEV1 (l)	2.02	1.85	2.04	2.08	1.92
FEV1% (%)	86.3	86.0	ND	84.2	79.7
%DLCO (%)	ND	39.6	39.3	41.0	49.0
DOE	Grade 3	Grade 3	Grade 2	Grade 2	Grade 1
cough	severe	severe	moderate	mild	mild

FVC: forced vital capacity, FEV1: forced expiratory vital capacity one second,
DLCO: diffusion lung capacity carbon monoxide
DOE: dyspnea on exertion
Grade : Hugh Johns grade of exertional dyspnea

Table 2. Change in his symptoms and functions over time: 60, M, Ex, Eye, BHL, Lung 31 yrs,

While the therapeutic effects in these cases were by no means stellar, they did bring about symptomatic relief, relatively good functional stabilization, and improved radiographic findings. It remains unsolved whether antifibrotic drugs such as pirfenidone are effective for fibrotic lesions in patients with sarcoidosis.

3.2. Treatment for cardiac sarcoidosis

Cardiac lesions can be patchily distributed in the four chambers of the heart. The dysfunctions they cause range from arrhythmia to right bundle block, left bundle block, and complete atrioventricular block leading to cardiac failure or cardiac arrest [23].

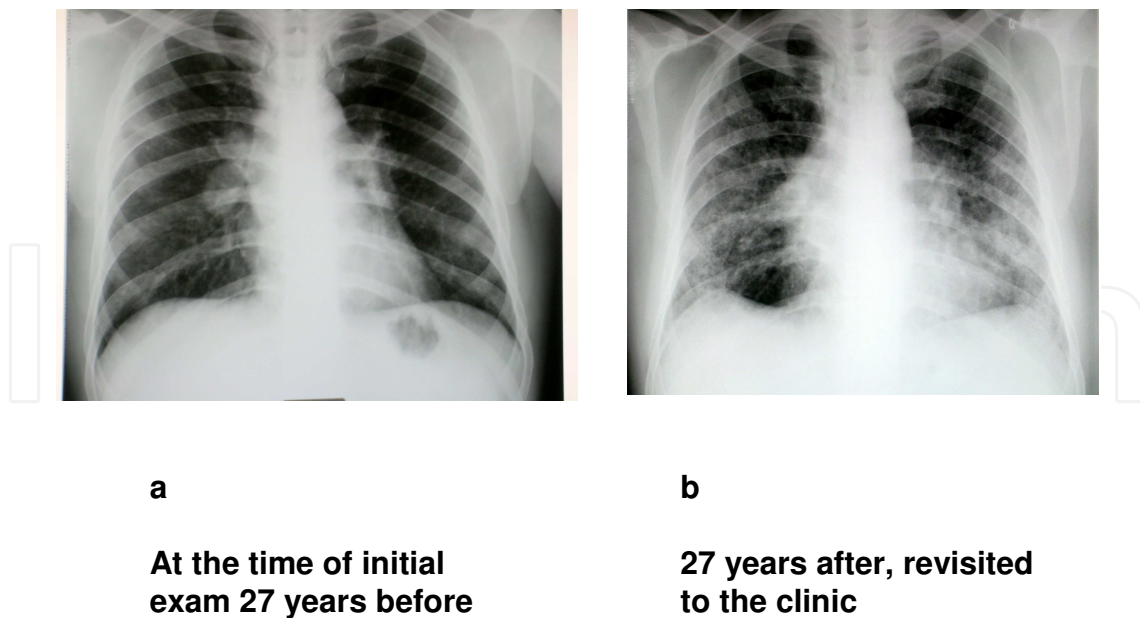


Figure 4. Longitudinal course of pulmonary fibrosis in patients with sarcoidosis: Plain chest radiograph 60-year-old male, ex-smoker, chief complaints of cough and exertional dyspnea Eye, BHL, and lung (30-year duration) a : at the initial exam in Kyoto University 27 years earlier b: at the revisit to the clinic 27 years later

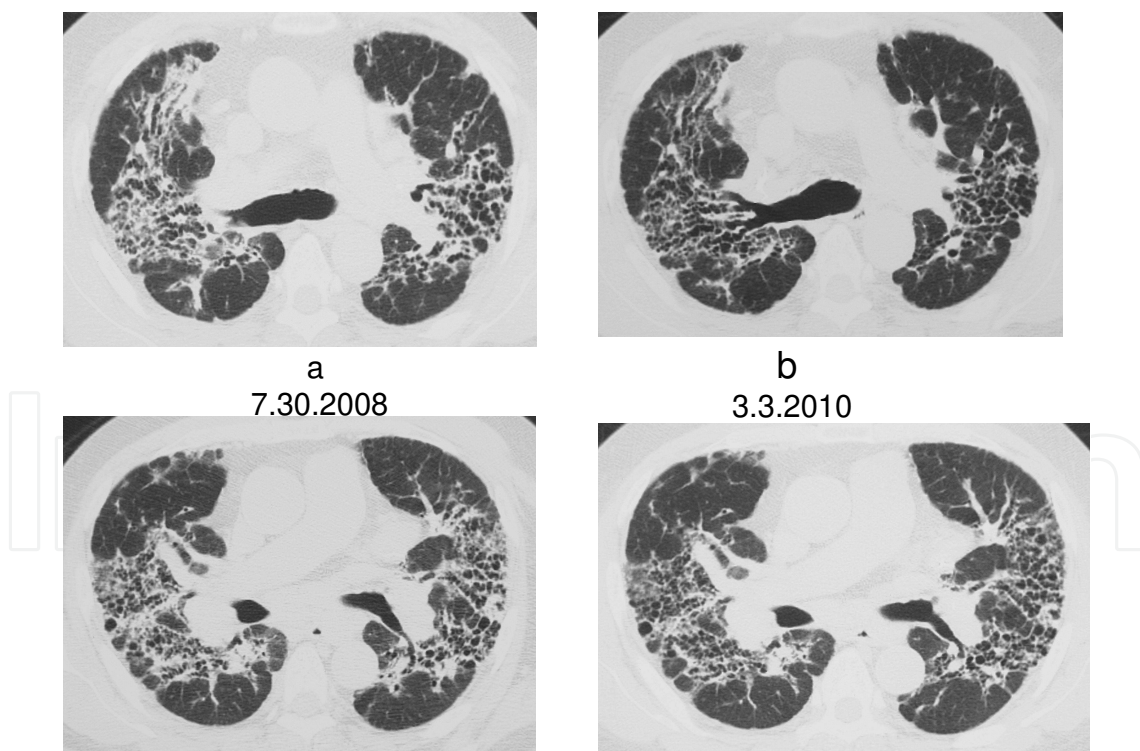


Figure 5. Longitudinal course of pulmonary fibrosis in patients with sarcoidosis: High-resolution CT findings 60-year-old male, ex-smoker, chief complaints of cough and exertional dyspnea Eye, BHL, and lung (30-year duration) a : when corticosteroids and methotrexate were introduced b: after 2 years of therapy

The Japanese Society of Sarcoidosis and Other Granulomatous Disorders published revised guidelines for the diagnosis of cardiac sarcoidosis [24]. These guidelines proposed criteria for definite diagnosis and clinical diagnosis: 1) Definite group, histological diagnosis by cardiac biopsy; 2) Clinical diagnosis group, negative biopsy with proven extracardiac sarcoidosis and satisfaction of 1 of 4 major criteria and 2 or more minor criteria. The major criteria were advanced AV block, basal thinning of the ventricular septum, positive cardiac gallium uptake, and left ventricular ejection fraction of less than 50 %. The minor criteria were abnormal ECG findings (ventricular tachycardia, multifocal frequent premature ventricular contractions, complete right bundle branch block pathologic Q waves, or abnormal axis deviation, UCG abnormality (regional wall motion abnormalities, ventricular aneurysm, or unexplained increase in wall thickness), perfusion defects detected by myocardial scintigraphy, delayed gadolinium enhancement of the myocardium on cardiac MRI scanning, and interstitial fibrosis or monocyte infiltration greater than moderate grade by endomyocardial biopsy. As the positive biopsy rate seems to be lower, the aforesaid guidelines are useful in a patients with proven noncardiac sarcoidosis and suspected cardiac involvement [23].

Regarding treatment, published data on several uncontrolled series of patients with cardiac sarcoidosis have suggested that steroids may be a valuable therapy for this condition. Yet no randomized control data are available to support this. In a retrospective series of 48 cases of cardiac sarcoidosis from Japan, high-dose steroid therapy seemed to be ineffective for patients with a pretreatment left ventricular ejection fraction of less than 30%, whereas improvement in ejection fraction and a decrease in left ventricular end-diastolic volume was seen in patients with a pretreatment ejection fraction of between 30% and 55% [4]. In a retrospective study from France, corticosteroid therapy improved abnormal echocardiographic parameters in 78% of cases and symptoms completely resolved in 9 of 17 patients presenting with congestive heart failure [25]. In a retrospective study of cardiac sarcoidosis in 30 Japanese patients who received 40 mg or more of prednisone daily and 45 patients who received less than 30 mg/d, there was no apparent survival benefit of high-dose prednisone over the lower dose [13].

No data are available to support the efficacy of additional immunosuppressive therapy for cardiac sarcoidosis with cyclophosphamide, methotrexate, or cyclosporine. Infliximab and etanercept, agents used against rheumatoid arthritis via their actions against tumor necrosis factor- α , have recently been proposed as treatments for some forms of chronic, refractory sarcoidosis [26].

3.3. Methotrexate for the treatment of cardiac sarcoidosis

This chapter presents the findings of a small open label comparative study by our group.

Long-term functional changes of ejection fraction on echocardiography were compared between patients who received combination therapy (low-dose prednisolone and methotrexate) and patients who received corticosteroids only.

As shown in table 3, there were no significant differences in sex distribution, duration of sarcoidosis, the number of lesions, or the frequency of pace maker implantation, though the age at the time of drug introduction tended to be higher in the patients treated with cortico-

	CS only	CS+MTX	p-value
No of the cases	7	13	
Age (years)	67±12.5*	56.5±13.7	0.07
M:W	2:05	5:08	0.66
duration (mos)	92.1±70.4	64.7±41.0	0.63
No of the extracardiac lesion	3.86±1.26	3.85±1.52	0.83
pace maker	6	11	0.95

CS:corticosteroid, MTX: methotrexate

M:man, W:woman, duration: from the detection to the introduction of the therapy,

* Figures express mean±standard deviation (SD)

p-value: less than 0.05 as statistically significant

Table 3. Clinical profiles in patients studied

steroids. There were no significant differences in the number of lesion sites, except for the number renal stones (higher in patients on corticosteroids). There were no significant differences in abnormal findings on electrocardiogram between the two groups (Table 4). Guided by these findings, we followed the ejection fraction (%) at one-year intervals after the introduction of the therapy. As shown in Table 5, ejection fraction stabilized in the combination therapy group 3 to 5 years after the first treatment.

	CS only	CS+MTX	p-value
Af	0	1	
PVC		1	0.463
CRBB	0	2	
LBBS	6	7	
CAVB			
basal thinning	7	9	0.101

Af:atrial fibrillation, PVC: premature ventricular contractions

CRBBB : complete right bundle branch block, LBBS: left bundle branchblock

CAVB: complete atrioventricular block

Basal thinning: basal thinning of the ventricular septum

p-value: less than 0.05 as statistically significant

Table 4. Comparison of the electrocardiographic abnormalities between the steroid treated and the combination therapy

EF %	CS only	CS+MTX	p-value
0*	56.1±13.1	58.4±15.3	0.812
12	48.0±16.7	55.5±15.3	0.383
36	41.2±9.8	58.6±11.6	0.007
60	41.0±13.1	56.2±12.3	0.069
96	48.7±9.2	55.0±25.2	

EF : ejection fraction (%) on echocardiography
CS: corticosteroid, MTX: methotrexate
* months from the intorduction of the treatment
Figures express mean±standard deviation (SD)
p-value: less than 0.05 as statistically significant

Table 5. Comparison of the ejection fraction on echocardiography between the steroid treated and the combination therapy

In the corticosteroid group, cardiac enlargement was found on plain chest radiographs at 3 to 5 years after the commencement of therapy in association with a decrease in ejection fraction (see, for example, **Figs. 6** and **7**). Meanwhile, combination therapy restored or stabilized the ejection fraction and cardiac enlargement on chest radiograph (see, for example, **Figs. 8** and **9**).

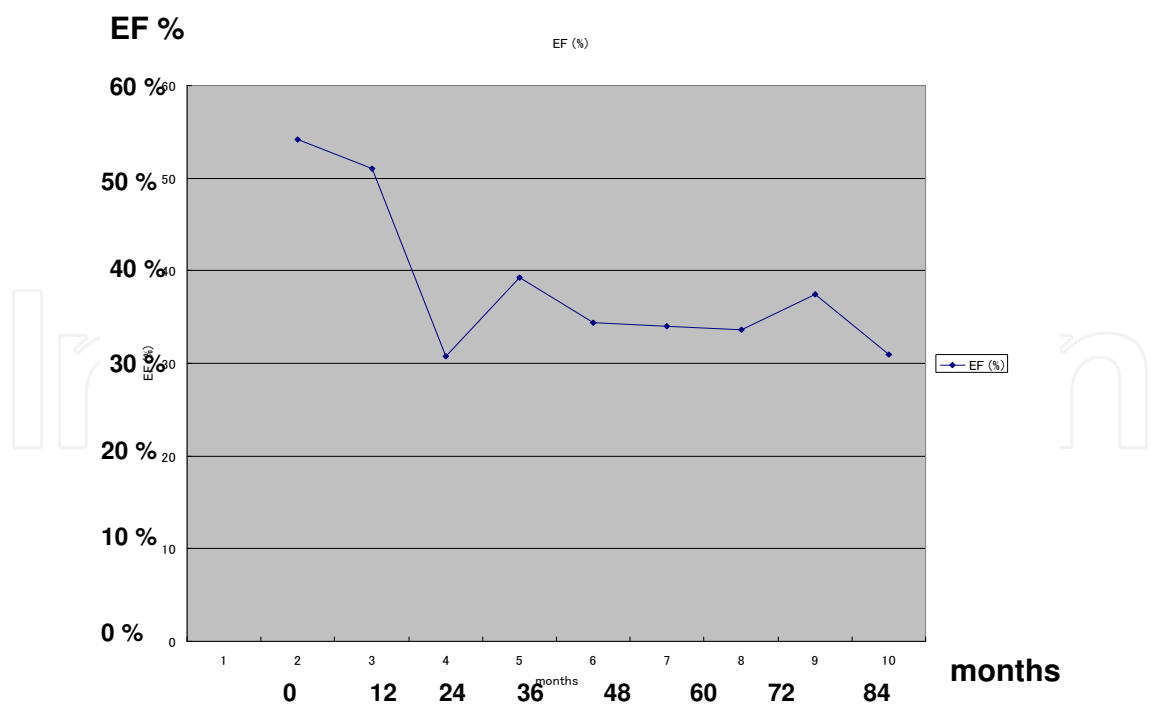


Figure 6. Longitudinal course of the ejection fraction on UCG 74-year-old female, nonsmoker, eye, renal stone, BHL, ACE 28.3, heart with complete AV block Ordinate: ejection fraction (%) on echocardiography Abscissa: months from the introduction of therapy

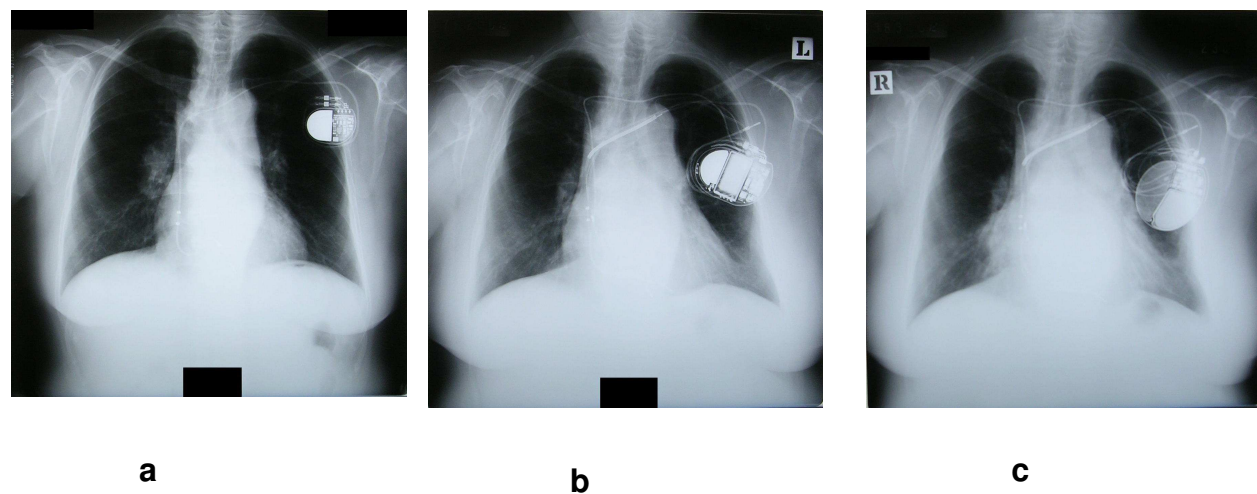


Figure 7. Longitudinal course of plain chest radiograph 74-year-old female, nonsmoker, eye, renal stone, BHL, ACE 28.3, heart with complete AV block a: when the corticosteroid therapy was introduced, b: after 5 years of treatment, c: after 7 years of treatment

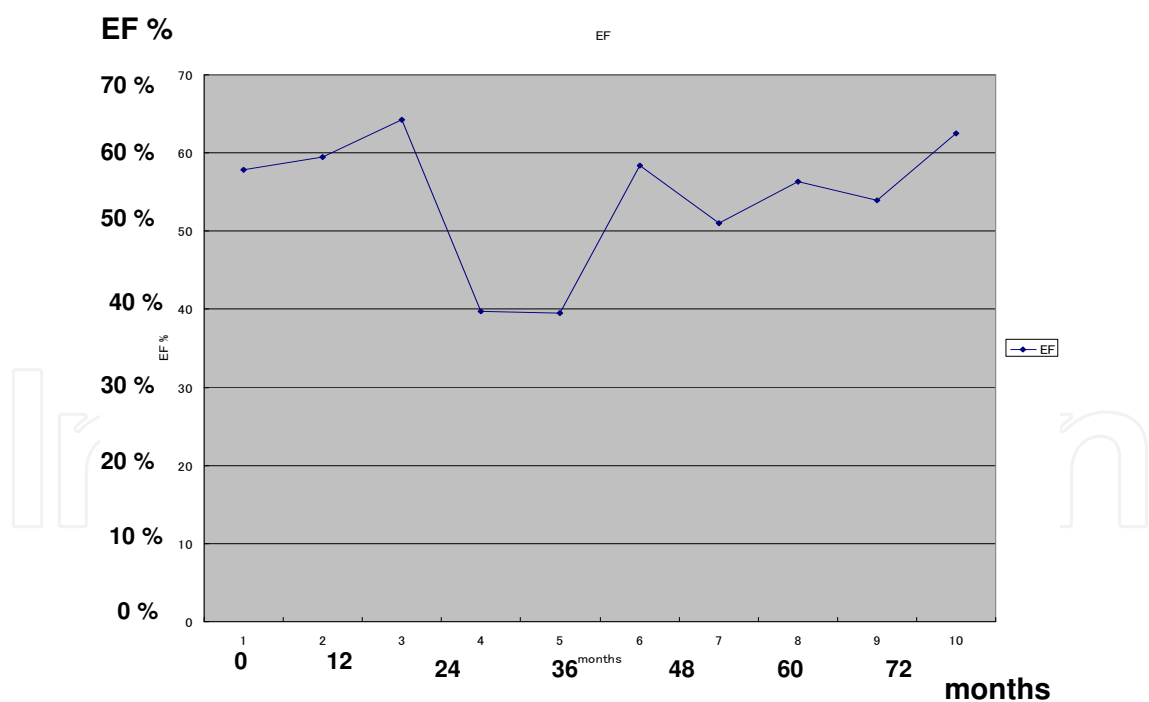


Figure 8. Longitudinal course of the ejection fraction on UCG 62-year-old female, nonsmoker, BHL, lung, ACE 29.0, heart with complete AV block Ordinate: ejection fraction (%) on echocardiography Abscissa: months from the introduction of therapy

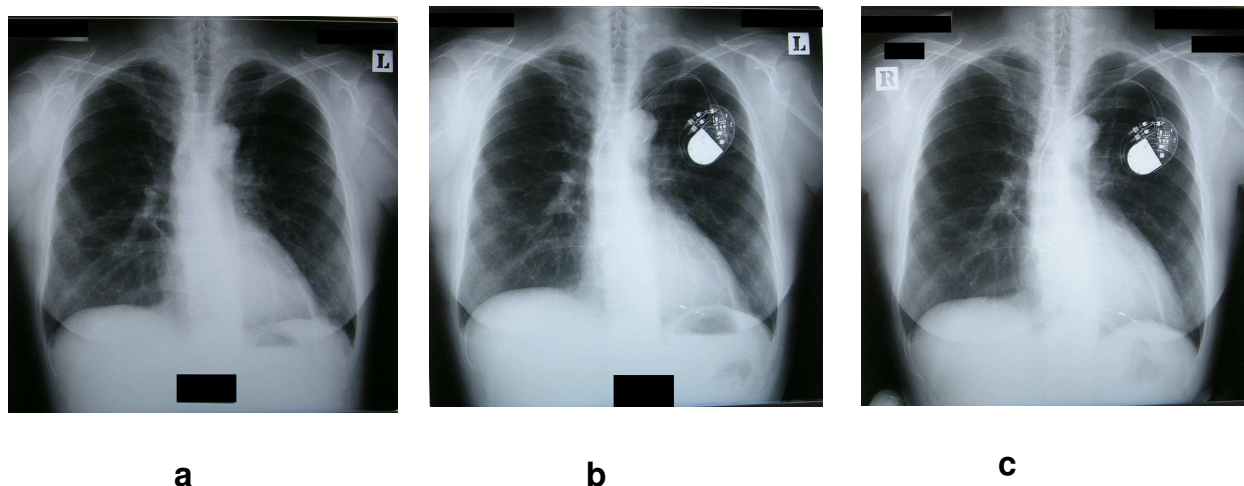


Figure 9. Longitudinal course of plain chest radiograph 62-year-old female, nonsmoker, BHL, lung, ACE 29.0, heart with complete AV block, a: when the introduction of corticosteroid and methotrexate therapy was introduced, b: after 2 years of treatment c: after 5 years of treatment

Eight patients received methotrexate in our clinic after treatment with corticosteroid therapy in another hospital. Some presented with decreased ejection fraction suggestive of congestive heart failure when they came to our clinic. Yet even for those patients, the add-on methotrexate improved the ejection fraction over a period years.

During long-term treatment with methotrexate and low-dose of prednisolone, there were no serious adverse effects such as bone marrow suppression, opportunistic infection, or drug-related pneumonia in our series.

At present we propose the following therapeutic strategy: in patients with cardiac sarcoidosis (especially those with pace makers because of complete AV block), a combination therapy of low-dose prednisolone and methotrexate as the initial treatment following long-term maintenance therapy will stabilize cardiac function with few adverse effects. A large-scale controlled prospective study to assess this approach will of course be warranted.

4. Conclusion

It is important to evaluate the whole clinical course in patients with sarcoidosis. Therapeutic decisions should be based on the clinical course, especially for chronic patients who need long-term treatment. As our studies on patients with cardiac lesions and patients with fibrotic pulmonary lesions demonstrate, weekly methotrexate therapy with or without small doses of corticosteroids may stabilize the deterioration without eliciting adverse effects during long-term treatment.

Nomenclature

WASOG: World Association of Sarcoidosis and Other Granulomatous Disorders

ACCESS: A Case Control Etiologic Study of Sarcoidosis

ACE: Angiotensin converting enzyme

1,25-(OH)₂ vitamin D: 1,25-dihydroxy- vitamin D

HRCT: High Resolution Computed Tomography

DLCO: diffusion capacity for carbon monoxide

AV block: atrioventricular block

ECG: Electrocardiography

UCG: ultrasound cardiography

FVC: forced vital capacity, FEV₁: forced expiratory volume one second,

EF: ejection fraction, Reg.: regurgitation, sPAP : systolic pulmonary artery pressure

DOE: dyspnea on exertion

Grade : Hugh Johns grade of exertional dyspnea

CS:corticosteroid, MTX: methotrexate

M:man, W:woman

Af:atrial fibrillation, PVC: premature ventricular contractions

CRBBB : complete right bundle branch block, LBBB: left bundle branchblock

CAVB: complete atrioventricular block

Acknowledgements

We thank all of our colleagues and staffs who support our clinical work longitudinally.

Author details

Sonoko Nagai and Takateru Izumi

Central Clinic, Clinical Research Center, Kyoto, Japan

References

- [1] Hunninghake, G. W, Costabel, U, Ando, M, Baughman, R, & Cordier, J. F. du Bois R, Eklund A, Kitaichi M, Lynch J, Rizzato G, Rose C, Selroos O, Semenzato G, Sharma OP.ATS/ERS/WASOG statement on sarcoidosis. American Thoracic Society/European Respiratory Society/World Association of Sarcoidosis and other Granulomatous Disorders. *Sarcoidosis Vasc Diffuse Lung Dis.* (1999). , 16(2), 149-73.
- [2] Ishige, I, Eishi, Y, Takemura, T, Kobayashi, I, Nakata, K, Tanaka, I, Nagaoka, S, Iwai, K, Watanabe, K, Takizawa, T, & Koike, M. *Propionibacterium acnes* is the most common bacterium commensal in peripheral lung tissue and mediastinal lymph nodes from subjects without sarcoidosis. *Sarcoidosis Vasc Diffuse Lung Dis.* (2005). , 22(1), 33-42.
- [3] Nagai, S, Handa, T, Ito, Y, Ohta, K, Tamaya, M, & Izumi, T. Outcome of sarcoidosis. *Clin Chest Med.* (2008). , 29(3), 565-574.
- [4] Sugisaki, K, Yamaguchi, T, Nagai, S, Ohmichi, M, Takenaka, S, Morimoto, S, Ishihara, M, Tachibana, T, & Tsuda, T. Clinical characteristics of 195 Japanese sarcoidosis patients with oral corticosteroids. *Sar Vasculitis Dissuse Lung Disease.* (2003). , 20(3), 222-226.
- [5] Baughman, R. P, Nagai, S, Balter, M, Costabel, U, & Drent, M. du Bois R, Grutters JC, Judson MA, Lambiri I, Lower EE, Muller-Quernheim J, Prasse A, Rizzato G, Rottoli P, Spagnolo P, Teirstein A. Defining the clinical outcome status (COS) in sarcoidosis: results of WASOG Task Force. *Sarcoidosis Vasc Diffuse Lung Dis.* (2011). , 28(1), 56-64.
- [6] Gottlieb, J. E, Israel, H. L, Steiner, R. M, Triolo, J, & Patrick, H. Outcome in sarcoidosis. The relationship of relapse to corticosteroid therapy. *Chest.* (1997). , 111(3), 623-31.
- [7] Baughman, R. P, Teirstein, A. S, Judson, M. A, & Rossman, M. D. Yeager H Jr, Bresnitz EA, DePalo L, Hunninghake G, Iannuzzi MC, Johns CJ, McLennan G, Moller DR, Newman LS, Rabin DL, Rose C, Rybicki B, Weinberger SE, Terrin ML, Knatterud GL, Cherniak R; Case Control Etiologic Study of Sarcoidosis (ACCESS) research group. Clinical characteristics of patients in a case control study of sarcoidosis. *Am J Respir Crit Care Med.* (2001). Pt 1):1885-9
- [8] Judson, M. A, Baughman, R. P, Thompson, B. W, Teirstein, A. S, Terrin, M. L, & Rossman, M. D. Yeager H Jr, McLennan G, Bresnitz EA, DePalo L, Hunninghake G, Iannuzzi MC, Johns CJ, Moller DR, Newman LS, Rabin DL, Rose C, Rybicki BA, Weinberger SE, Knatterud GL, Cherniak R; ACCESS Research Group. Two year prognosis of sarcoidosis: the ACCESS experience. *Sarcoidosis Vasc Diffuse Lung Dis.* (2003). , 20(3), 204-11.

- [9] Reich, J. M. Mortality of intrathoracic sarcoidosis in referral vs population-based settings: influence of stage, ethnicity, and corticosteroid therapy. *Chest*. (2002). , 121(1), 32-39.
- [10] Baughman, R. P, & Lower, E. E. A clinical approach to the use of methotrexate for sarcoidosis. *Thorax* (1999). , 54, 742-746.
- [11] Myers, T. D, Werthheim, M. S, Egan, R. A, Shults, W. T, & Rosenbaum, J. T. Use of corticosteroid spring systemic immunosuppression for treatment of corticosteroid dependent optic neuritis not associated with demyelinating disease. *Br J Ophthalmol* (2004). , 88, 673-680.
- [12] Kaye, O, Palazzo, E, Grossin, M, Bourgeois, P, Kahn, M. F, & Malaise, M. G. Low dose methotrexate : an effective corticosteroid-sparing agent in the musculoskeletal manifestations of sarcoidosis. *Br J Rheumatolo* (1995). , 34, 642-644.
- [13] Yazaki, Y, Isobe, M, Hiroe, M, Morimoto, S, Hiramitsu, S, Nakano, T, & Izumi, T. Sekiguchi M; Central Japan Heart Study Group. Prognostic determinants of long-term survival in Japanese patients with cardiac sarcoidosis treated with prednisone. *Am J Cardiol*. (2001). , 88(9), 1006-1010.
- [14] Hamzeh, N. Y, Wamboldt, F. S, & Weinberger, H. D. Management of cardiac sarcoidosis in the United States: a delphi study. *Chest*. (2012). , 141(1), 154-62.
- [15] Schutt, A. C, Bullington, W. M, & Judson, M. A. Pharmacotherapy for pulmonary sarcoidosis: a Delphi consensus study. *Respir Med*. (2010). , 104(5), 717-23.
- [16] Akira, M, Kozuka, T, Inoue, Y, & Sakatani, M. Long-term follow-up CT scan evaluation in patients with pulmonary sarcoidosis. *Chest*. (2005). , 127(1), 185-91.
- [17] Lynch, J. P. rd, Kazerooni EA, Gay SE. Pulmonary sarcoidosis. *Clin Chest Med*. (1997).
- [18] Handa, T, Nagai, S, Fushimi, Y, Miki, S, Ohta, K, Niimi, A, Mishima, M, & Izumi, T. Clinical and radiographic indices associated with airflow limitation in patients with sarcoidosis. *Chest* (2006). , 130(6), 1851-6.
- [19] Nardi, A, Brillet, P. Y, Letoumelin, P, Girard, F, Brauner, M, Uzunhan, Y, Naccache, J. M, Valeyre, D, & Nunes, H. Stage IV sarcoidosis: comparison of survival with the general population and causes of death. *Eur Respir J*. (2011). , 38(6), 1368-73.
- [20] Handa, T, Nagai, S, Miki, S, Fushimi, Y, Ohta, K, Mishima, M, & Izumi, T. Incidence of pulmonary hypertension and its clinical relevance in patients with sarcoidosis. *Chest*. (2006). , 129(5), 1246-1252.
- [21] The registry of the international society for heart and lung transplantation: 27 annual report 2010J Heart and Lung Transplantation (2010). , 29, 1083-1141.
- [22] Shlobin, O. A, & Nathan, S. D. Management of end-stage sarcoidosis: pulmonary hypertension and lung transplantation. *Eur Respir J*. (2012). Epub ahead of print]

- [23] Dubrey, S. W, & Falk, R. H. Diagnosis and management of cardiac sarcoidosis. *Prog in Cardiovascular Dis.* (2010). , 52, 336-346.
- [24] Soejima, K. Yada H: The work-up and management of patients with apparent or sub-clinical cardiac sarcoidosis: with emphasis on the associated heart rhythm abnormalities. *J Cardiovasc Electrophysiol* (2009). , 20, 578-583.
- [25] Chapelon-abric, C, De Zuttere, D, Duhaut, P, Veyssier, P, Wechsler, B, Huong, D. L, De Gennes, C, Papo, T, Blétry, O, Godeau, P, & Piette, J. C. Cardiac sarcoidosis : a retrospective study of 41 cases. *Medicine* (2004). , 83, 315-334.
- [26] Baughman, R P, Drent, M, Kavuru, x, Judson, M, Costabel, M. A, Du, U, Bois, R. M, Albera, C, Brutsche, M, Davis, G, Donohue, J. F, Müller-quernheim, J, Schlenker-herceg, R, Flavin, S, Hung, K, & Oemar, L. B. Barnathan ES and on behalf of the Sarcoidosis Investigators Infliximab Therapy in Patients with Chronic Sarcoidosis and Pulmonary Involvement *Am J Respir Crit care Med* (2006). , 795-802.