

We are IntechOpen, the world's leading publisher of Open Access books Built by scientists, for scientists

6,900

Open access books available

185,000

International authors and editors

200M

Downloads

Our authors are among the

154

Countries delivered to

TOP 1%

most cited scientists

12.2%

Contributors from top 500 universities



WEB OF SCIENCE™

Selection of our books indexed in the Book Citation Index
in Web of Science™ Core Collection (BKCI)

Interested in publishing with us?
Contact book.department@intechopen.com

Numbers displayed above are based on latest data collected.
For more information visit www.intechopen.com



Overview of the Application of EMG Recording in the Diagnosis and Approach of Neurological Disorders

Yunfen Wu, María Ángeles Martínez Martínez and
Pedro Orizaola Balaguer

Additional information is available at the end of the chapter

<http://dx.doi.org/10.5772/56030>

1. Introduction

The Electromyography (EMG) is a neurophysiological technique for examining the electrical activity of skeletal muscles. The source of electrical signal in EMG is the muscle membrane potential. The muscle fibers innervated by the axonal branches of a motor neuron form a motor unit (MU). The muscle fibers of each motor unit are intermingled with fibers of other MUs [1]. The summation of action potentials of MUs is called motor unit action potential (MUAP) [2]. The biosignal recorded from a muscle or its fibers reflects the anatomical and physiological properties of the motor system. As such, EMG recording and analysis are powerful neurophysiological techniques that can be employed to: a) identify the health status of the motor system; b) localize and typify peripheral and central abnormalities and lesions; c) determine the temporal course and the severity of motor system abnormalities, and d) determine and evaluate the effectiveness of treatment strategies.

Muscle activity can be detected during resting state or during voluntary movement. In addition, induction of compound action potential (CMAP) and motor evoked potential (MEP) can be obtained by means of peripheral nerve stimulation (PNS) and cortical stimulation, respectively. While PNS provides measurement of integrity of the peripheral motor system, cortical stimulation through techniques such as Transcranial Magnetic Stimulation (TMS), permit examining the integrity of the corticospinal tract.

Furthermore, the value of EMG recording as an Intraoperative neuromonitoring method has been described since the late 1970's [3]. To date, EMG recording is a useful technique to prevent neurological damage during diverse surgical procedures.

2. EMG recording techniques

EMG devices record the electrophysiological activity of MUs. EMG recordings can be performed by means of intramuscular (needle) or non-invasive (surface) electrodes.

2.1. Needle EMG (nEMG)

nEMG permits local recording from deep muscles by means of insertion of a needle electrode into the muscle tissue. The needle insertion point is located by identifying anatomic landmarks which may be confirmed through the proper contraction of the selected muscle. nEMG can be used to assess individual MUs and has greater sensitivity and accuracy in the recording of high-frequency signals such as different types of spontaneous activity [4].

However, nEMG has several limitations. First, it reflects the activity of only a small number of active MUs whose fibers are close to the position of the detection site (not representative of all the fibers in the MU, due to its small detection volume). An adequate sample is needed to ensure adequate power (sensitivity and specificity) of the analysis of MUAPs. Moreover, standard sample size is difficult in exploring small muscles [5]. Second, nEMG is painful especially during muscle activation, and prolonged nEMG recording is not possible. In rare cases, local trauma (e.g., pneumothorax) could occur during the examination of some delicate regions [6]. Furthermore, nEMG is time and temperature sensitive. In this regard, the detected signal in nEMG may vary as a function elapsed time from the onset of the nerve injury [7]. Since the temperature exerts a profound influence on neuromuscular transmission and propagation of the action potential along the muscle fibers, a low temperature at the examination area modifies the parameters and characteristics of the recorded signals [8].

2.2. Surface EMG (sEMG)

sEMG is a technique to measure muscle activity noninvasively using surface electrodes placed on the skin overlying the muscle, and has several advantages. First, sEMG recording is painless, especially when used in the absence of peripheral nerve stimulation. Furthermore, sEMG electrodes record from a wide area of muscle territory providing a more global view of MUs. Finally, it allows prolonged simultaneous recordings of muscle activity from multiple sites.

However, sEMG has a relatively low-signal resolution, is highly susceptible to movement artifacts [9] and body temperature. In addition, sEMG signals are dominated by the contributions of superficial MUs, while deeper MUs are not assessed; conditions that increase skin resistance subsequently disturb the sEMG signal (e.g. obesity and edema).

3. EMG study

3.1. Muscle voluntary contraction recording

In depolarization, the summation of action potentials of the MUs (MUAPs) can be assessed by analysis of their parameters (fig. 1).

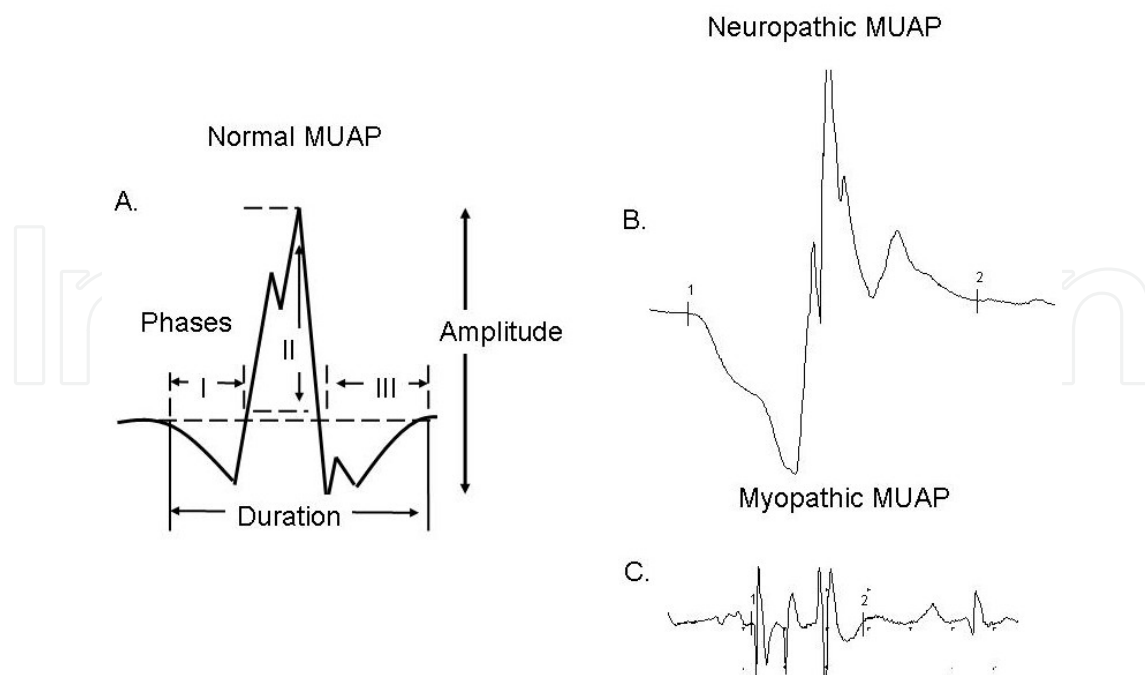


Figure 1. Morphology and parameters of a motor unit action potential (MUAP) measured during nEMG recording. A. A normal MUAP with three phases. B. A polyphasic, high amplitude and enlarged MUAP recorded in chronic neuropathy with reinnervation. C. In some myopathic and neuromuscular junctions (NMJ) disorders, the resulted MUAPs are of short duration, small amplitude and also polyphasic.

Duration is measured from the initial deflection from baseline to the terminal deflection back to baseline; it reflexes the synchrony and also the muscle fiber density in an MU. The average duration of MUAPs increases from infancy to adult (related to the increased width of the endplate zone), and even more during old age; the percentage depends on the specific muscle [2,10]. Abnormalities of MUAP duration can be shown in pathological conditions:

- Short-duration MUAPs are often detected in disorders with loss of muscle fibers [11].
- Long-duration MUAPs are typically found in chronic neuropathic disorders and polymyositis [12,13].
- A mixed pattern (coexisting MUAPs of long and short duration) can be observed in rapidly progressing motor neuron disease and chronic myositis [14].

Morphology (number of phases) is defined as the number of baseline crossings of an MUAP and reflects the firing synchrony of the muscle fibers within an MU. Normally, an MUAP has two to four phases. A MUAP of more than four phases is named polyphasic potential. MUAPs with abnormal morphology can be recorded in neuromuscular disorders:

- An abnormally increased polyphasia is a non-specific signal of both myopathic and neuropathic disorders [2,12].
- Satellite potentials are observed in subacute processes and result from denervated muscle fibers that are reinnervated by collateral sprouts from adjacent unmyelinated or thinly myelinated fibers in early reinnervation stage [15].

Stability of the firing of all muscle fibers of the MU reflects the effective transmission across the neuromuscular junctions (NMJs) corresponding to each generated action potential. Abnormalities on MUAP stability indicate increased variability of an MUAP, either in its amplitude, morphology or both; this finding can be shown in primary disorders of the NMJ (e.g., myasthenia gravis, Lambert-Eaton syndrome); as well as often being observed as secondary phenomena in neuropathic (e.g., early reinnervation) or myopathic disorders.

A special technique called “single fiber EMG (SFEMG)” allows assessment of the abnormalities in the physiological variation of transmission time in the motor end-plate, and in the propagation velocity along the muscle and nerve fibers. This method is based on obtaining a single muscle fiber action potential by means of a special electrode with a small recording area. SFEMG is the most sensitive test to demonstrate an impaired neuromuscular transmission in myasthenia gravis. However, this technique is not specific in differentiating between myopathies and neuropathies, or between pre- and postsynaptic NMJ disorders [16-18].

Amplitude is commonly measured from peak to peak. It is proportional to the distance from the recording electrode to the muscle fiber, reflecting only those few depolarized fibers nearest to the recording electrode [19]. The progressive loss of MUs, unless in some muscle groups as of the seventh decade of life, results in MUAPs of smaller amplitude [20]. This phenomenon is especially noticeable in extensor digitorum brevis muscle. An MUAP can show abnormal amplitude in the following conditions:

- Reduced amplitude of MUAP is a usual finding in some myopathies.
- In chronic neuropathies, the MUAP amplitude can be increased due to reinnervation process [12].

Recruitment refers to the increase of the firing rate from incorporation of additional MUs [21,22]. MUAP recruitment is reduced primarily in neuropathic diseases and rarely in severe end-stage myopathies [12] (fig 2).

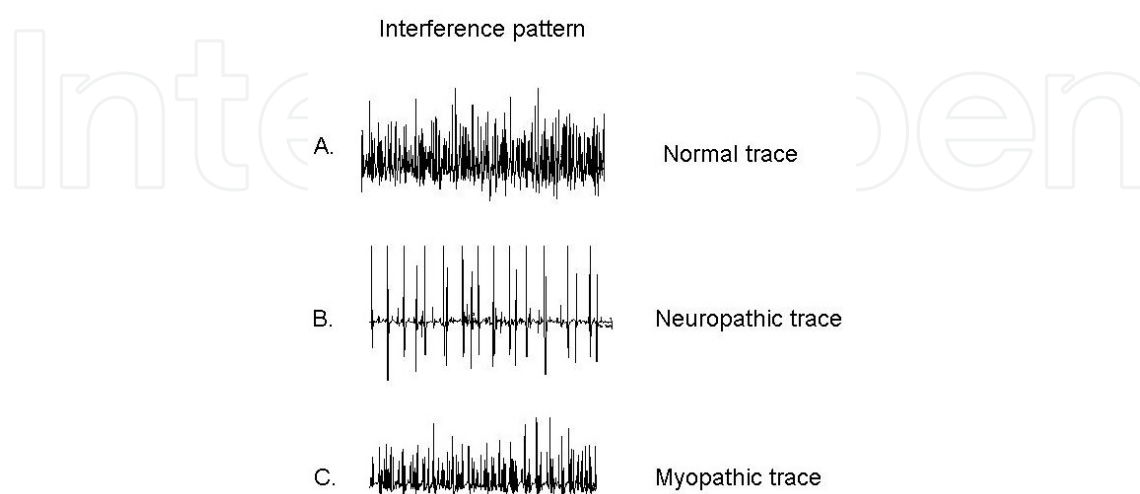


Figure 2. EMG signals recorded from maximum muscle contraction.

Activation is a measurement of the ability to increase firing rate. It depends on the effort exerted by the patient and the examined muscle (e.g. gastrocnemius muscle has some difficulty in its activation). This is a central process [21]. Poor activation may be seen in diseases of the central nervous system (CNS) or as a manifestation of provoked pain (poor collaboration during nEMG).

3.2. Resting state recording

At resting state, muscle activity can be recorded using either intramuscular (needle) or non-invasive (surface) detection systems. The difference between these two detection modalities is based on the volume conductor that separates the muscle fibers from the recording electrodes.

In a healthy muscle at rest, spontaneous physiological activity can be recorded by means of nEMG:

- End-plate potentials: result from the synchronization of miniature end-plate potentials, and can be recorded near the end-plate zone.
- Insertional activity: induced by mechanical depolarization of muscle fiber due to needle electrode insertion (fig 3).

Abnormal spontaneous activity provides information about the topography, diagnosis, time course (spontaneous activity is detected in acute and sub-acute stages of the nerve lesion) and also about the severity in neurogenic, myopathic and NMJ disorders [14,23,24] (fig. 3).

The most described abnormal spontaneous activities include:

- Fibrillation potentials, positive sharp waves, complex repetitive and myotonic discharges resulting from single denervated muscle fibers with an unstable membrane potential that fire individually without axonal stimulation.
- Fasciculation, neuromyotonic and myokymic discharges generating from disturbance of a group of muscle fibers.

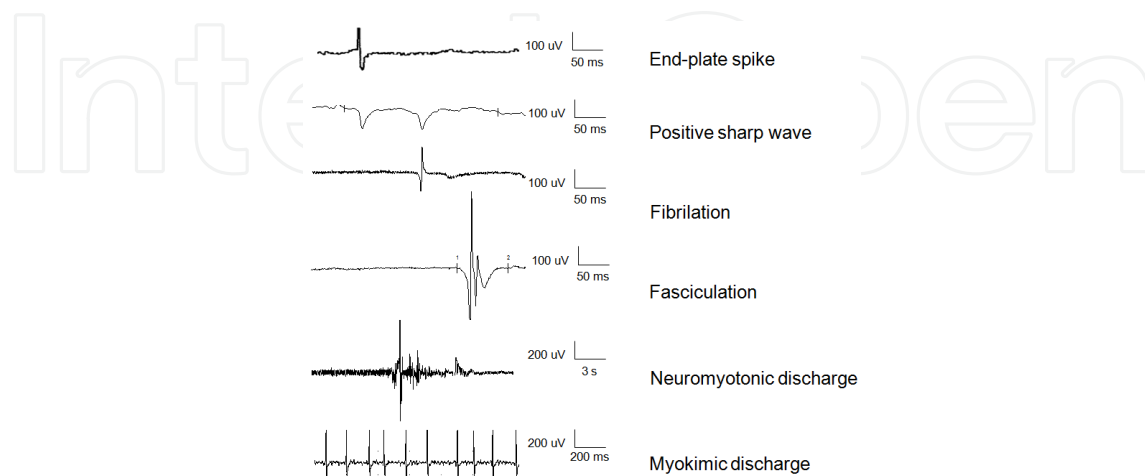


Figure 3. Some examples of spontaneous activity (nEMG recording).

On the other hand, resting sEMG recording is helpful in differentiating several types of tremors, myoclonus, and dystonia. The mean rectified sEMG signal varies linearly with the force generated at constant length and velocity. This linear relationship is maintained even in pathological conditions. sEMG may be used to classify movement disorders through measurement of frequency and amplitude of MUAPs. This technique can provide information about MU recruitment and synchronization, and also determine the relationship of the involved muscles, whether antagonists discharge simultaneously or alternately to produce some movement disorders [9,25-27] (fig 4).

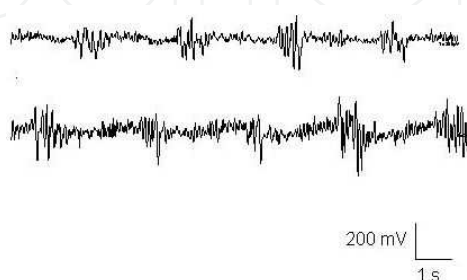


Figure 4. In resting sEMG recording, an alternative movement at 4-5 Hz over extensor (upper trace) and flexor (lower trace) musculature of the wrist is recorded in a patient with a diagnosis of Parkinson's disease.

3.3. EMG analysis

The analysis of MUAPs can be performed on a qualitative or quantitative basis. At least 20 samples from each studied muscle is widely accepted as representative [5].

3.3.1. Qualitative analysis

Visual recognition only provides limited information, detecting alterations in few components of MUAPs. The effectiveness of this method depends on the experience of the performer, as the accuracy in measurements is limited by the presence of background noise and depends on collaboration from the patients. To perform qualitative MUAP analysis, the number of phases of a single MUAP and recruitment during voluntary activity are visually analyzed from the MUAPs.

3.3.2. Semi-quantitative analysis

The classical method consists of manual measurement of duration, amplitude, and number of phases of individual MUAPs; and then comparison of these data with a set of normal values for the studied muscle and age group.

3.3.3. Quantitative analysis

The parametric method establishes a comparison between sample mean values and reference intervals (standard deviation), while the nonparametric method considers both extremes of

the samples ("outliers"). Both methods offer different sensitivities. The combination of outliers and mean values may be the optimal way to detect abnormalities in a sample [28,29].

The principal measurements during a voluntary contraction include:

- *Count of "turns"*: consists of the number of turns recorded in one second. It generally reflects the number of active MUAPs, their complexity and frequency of discharge. A "turn" was traditionally defined as any amplitude change signal of 100 μ V [30]. It is important to take in account that a turn may correspond to a peak within an MUAP, an interaction between superimposed MUAPs, as well as background noise.
- *Mean amplitude between turns (A/T)* and the *number of turns divided by the mean amplitude between turns (T^2/A)* are indicators for identifying neuropathies and myopathies, and also establishing severity [30,31].
- *Upper centil amplitude* defines the upper limit of the peak-to-peak amplitude; the spikes with amplitude that exceeds by 1% are identified. This parameter is normal or decreased in some myopathies, whereas it is normal or increased in neuropathies [30,32].
- *Activity parameter* measures the 'fullness' of the interference pattern, and is the sum of the duration of specific segments [30,32].
- *Number of small segments (NSS)* quantifies the small inflexions of MUAPs, including the smallest segment between subsequent turns. NSS increases with the number of MUAP discharges, but reaches a constant value at higher MUAP discharge rates. This parameter has been shown as increased in myopathic and normal or decreased in neuropathic conditions [30].
- *Spectral analysis (SA)* traditionally consists of a fast Fourier transformation of the EMG signals; the output displays the range and amplitude of the component frequencies. SA is been used extensively in the study of muscle fatigue. The diagnostic value varies according to different power frequencies [33,34].
- *Automatic decomposition electromyography* comprises the extraction of MUAPs from EMG interference pattern employing digital filtering; the decomposition and analysis of validated MUAPs. Measured parameters include duration, amplitude, rise time, area, ratio, area/amplitude, number of phases, turns and fire rates [35-37].
- *Computer-aided MU nerve estimation*: high density multichannel EMG recording provides the spatio-temporal information for MUAPs. This technique allows the assessment of the number of functioning MUs [38].

3.4. EMG recording in peripheral nerve stimulation

Electroneurography (ENG) assesses the function and integrity of peripheral motor nerve structures by means of sEMG recording after electrical stimulation. ENG contributes to localize, typify (axonal or demyelinating nature), and establish the course and the severity of the lesion, and is temperature sensitive [39]. On the other hand, magnetic stimulation is also a tool for the electrical stimulation of peripheral nerves and spinal roots [40].

The summation of all underlying individual muscle fiber action potentials after electrical stimulation of a peripheral nerve is called compound muscle action potential (CMAP). Abnormalities of its components are useful in the diagnostic evaluation of neurological disorders (fig 5).

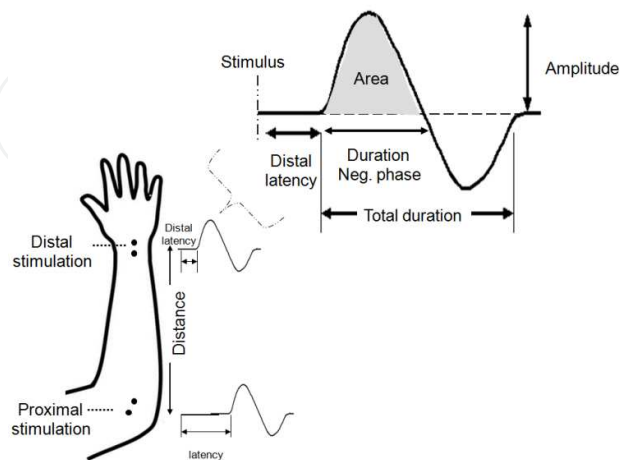


Figure 5. Parameters of a schematic CMAP assessed in motor nerve conduction study.

Special recording techniques are required when significantly different CMAP amplitude is recorded between two nerve segments in order to rule out the presence of anatomical variants [41-44].

On the other hand, the proximal segment of the peripheral motor nerve system can be assessed by means of determination of late responses: H-waves (elicited by subthreshold activation of muscle spindle afferents) and F-waves (elicited by supramaximal antidromic activation of motor neurons) (fig 6). Nevertheless, sensibility and specificity are limited in both tests [44,45].

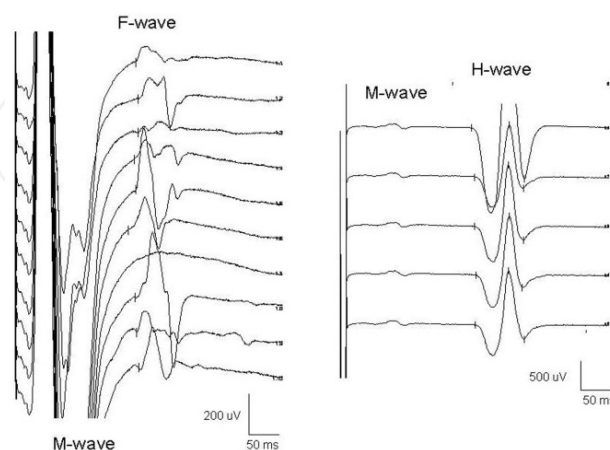


Figure 6. Late responses. Left: F-wave evoked from supramaximal stimulation of median nerve at the wrist, recording in abductor pollicis brevis muscle. Right: H-wave recorded over the soleus muscle from submaximal stimulation of tibial nerve in the popliteal fossa.

The integrity of some cranial nerves can be assessed by specific tests [46]:

- Electrical elicited Blink Reflex allows the evaluation of the trigeminal-facial reflex arc by means of stimulating the first division of the trigeminal nerve (fig 7).

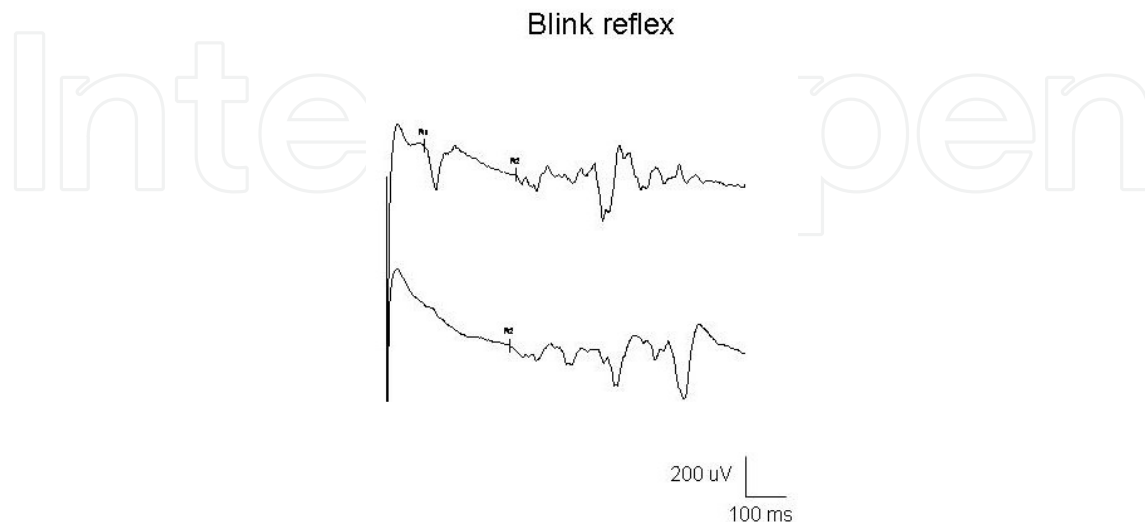


Figure 7. Blink reflex. Normal ipsilateral early (R1) with ipsilateral late (R2) responses, and contralateral R2 response recorded over both orbicularis oculi muscles, by left supraorbital nerve stimulation.

- Masseter reflex is elicited by a brisk tap to the lower jaw and allows assessment of the motor component of the trigeminal nerve.

However, motor nerve conduction studies have some limitations. First, selectivity is lacking in the assessment of small muscles and some nerves are not accessible. Second, the greater the intensity of the stimulation, the greater the chance of the stimulus being perceived as painful by the patient, especially during proximal stimulation in the assessment of root and plexus. In addition, stimulation is more difficult in patients who are obese, edemic, or have unusually thick or calloused skin. Third, variability due to examiner and side differences also exists [47].

Several parameters of a CMAP can be measured:

Latency refers the time from the stimulus to the initial negative deflection from baseline. In peripheral motor nerve stimulation, the latency obtained from the stimulation of the most distal segment of the nerve is named "distal latency (DL)". DL reveals nerve conduction time from the stimulus site to the NMJ, the time delay across the NMJ, and the depolarization time across the muscle and reflects only the conduction of the fastest conducting motor fibers. Pathological conditions with delayed CMAPs include:

- Demyelinating diseases [48].
- Axonal degeneration with primary damage of the largest and fastest myelinated fibers [44,49].

Amplitude is commonly measured from baseline to negative peak. It is proportional to the distance from the recording electrode to the muscle fiber. CMAP amplitude reflects only those

depolarized fibers nearest to the recording electrode, and is the most studied outcome measurement.

Abnormalities of CMAP amplitude can be observed in:

- Axonal neuropathies: characterized by axon loss, can show CMAPs of reduced amplitude. In chronic axonal neuropathies, CMAP amplitude reflects the functioning muscle mass [44,45].
- NMJ disorders: amplitude of CMAPs is a fundamental parameter in the assessment of the integrity of neuromuscular transmission by means of repetitive nerve stimulation (RNS). This technique consists of applying repetitive stimulation at low and high rates, and determining the decreasing or increasing CMAP responses that in conjunction with the CMAP at baseline, allows a diagnosis of pre- or postsynaptic NMJ disorders to be established [49] (Fig. 8).

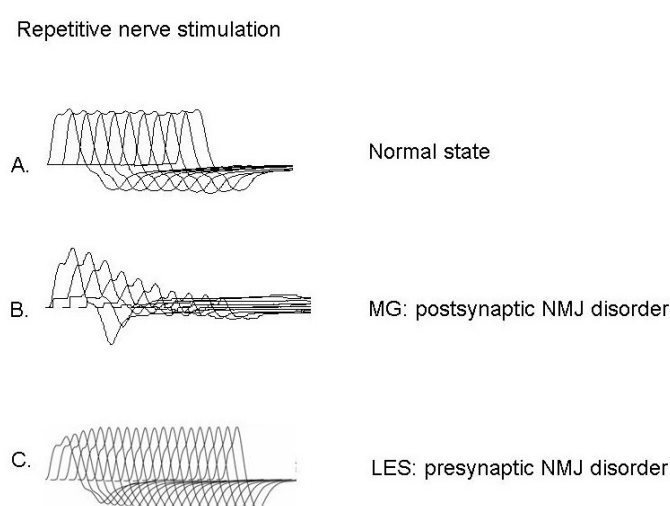


Figure 8. Repetitive stimulation of ulnar nerve: recording over the abductor digiti minimi muscle. A. In normal subjects, compound muscle action potential (CMAP) amplitude remains very stable. B. In a myasthenia gravis (MG) patient, CMAP amplitude is normal at rest but decreases during low-rate repeated stimulation at 3 Hz. C. In a patient with Lambert–Eaton syndrome (LES), the initial CMAP amplitude is reduced. During high-rate repeated stimulation at 20 Hz, CMAP amplitude dramatically increases. NMJ: neuromuscular junction.

- Demyelinating lesions: Impediment to the conduction of the action potential without axonal degeneration is named conduction block (CB). No absolute expert agreement has been established in the definition criteria of CB [49]. Nevertheless, a decay of proximal CMAP amplitude/area of at least 50% has been observed in patients with nerve CB in some studies, and has even been proposed as criteria for CB. [51-53].

Duration is measured from the initial deflection from baseline to the first baseline crossing, but can also be measured from the initial to the terminal deflection back to baseline. It is a parameter that indicates the synchrony of the activated muscle fibers. It increases in conditions that result in slowing of some motor nerve fibers but not others (e.g., in a demyelinating lesion) [44,54].

Area is conventionally measured between the baseline and the negative peak and represents a combination of the amplitude and the duration; the calculation is performed by computerized software. Therefore, CMAP area reflects also the number and synchrony of the muscle fibers activated close to the recording electrode. "Temporal dispersion" results from the spatial distribution of the scattered motor end-plates of a MU, and depends on the individual distance and time of conduction along the muscle fibers. This phenomenon is observed with more proximal stimulation, while the distance from the recording electrodes increases [55].

Motor conduction Velocity (MCV) obtained from standard recording techniques reflects only the conduction of the fastest conducting fibers. The determination of true motor conduction velocity must not include the NMJ transmission and muscle depolarization times. Conduction velocity along the studied segment is usually calculated with the following formula: (distance between the proximal and distal stimulation sites) divided by (proximal latency - distal latency) [44]. MCV is dependent on internode distance and also on the total fiber diameter (axon plus myelin), since MCV increases proportionally with myelin thickness [56]. MCV increases progressively during the first 5 years of life, in relation to physiological maturation of myelination process. Otherwise, there is a progressive and slight decrease of MCV in relation with increase of age over 20-30 years [44,57,58].

MCV is an important parameter in the determination of demyelinating disease. In hereditary demyelinating neuropathies, a uniformly slowed MCV has been shown; whereas in acquired demyelinating neuropathies, slowed MCV is observed in a patchy way [44]. In reinnervation process, the slowing in conduction velocity results from the regenerating nerve fibers that contain thinner axons and myelin sheaths and shorter internodal lengths [59].

3.5. EMG recording in cortical stimulation

Motor evoked potential (MEP) is defined as an EMG response obtained by means of activation of the corticospinal tract by means of stimulation to the motor cortex. Transcranial Magnetic Stimulation (TMS), a painless (unlike Transcranial Electrical Stimulation) method is widely used with this aim [60].

The following components of MEP elicited by single pulse TMS, are measured to evaluate the integrity of corticospinal pathways:

Latency refers to the time between the delivery of a TMS pulse over the scalp (area corresponding to the primary motor cortex – M1) and the appearance of MEP at the periphery. MEP latency is mainly reflective of the efficiency of conduction between the stimulated motor cortical area and the peripheral target muscle [61].

Central motor conduction time (CCT) can be obtained by two methods of calculation. The CCT calculated by subtracting the CMAP latency obtained by stimulation of the spinal (cervical or lumbar) motor root from the latency of MEP [62] includes the time for central motor conduction, the synaptic delay at the spinal level and time from the proximal root to the intervertebral foramen. More precise central conduction time can be calculated by use of F-wave latency [60]. On the other hand, CCT is significantly influenced by the motor system maturation [63], and

partially dependent upon the subject height. A significant interside difference indicates a lateralized prolonged CCT even if still within normal values (Fig 9).

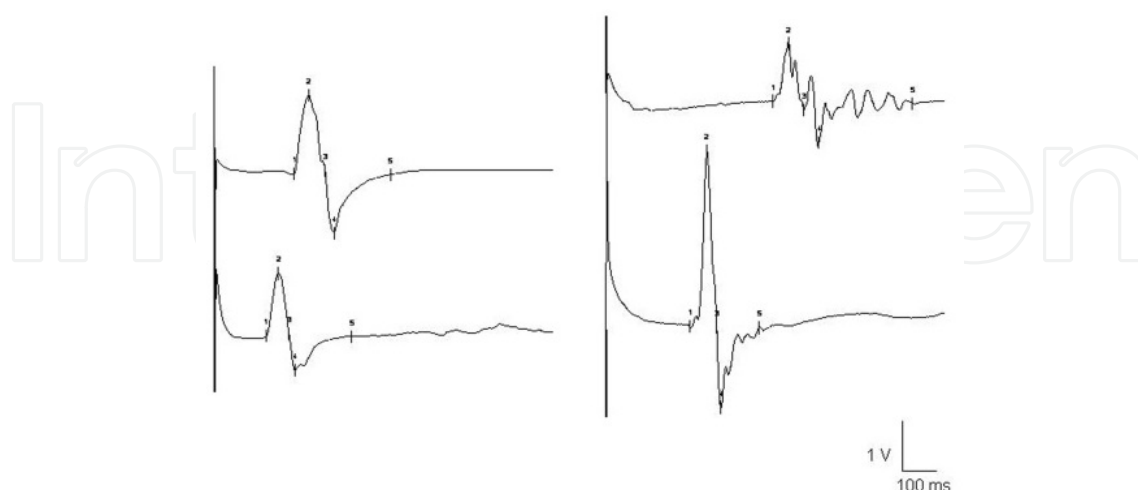

Figure 9. Left: MEP recorded from abductor pollicis brevis muscle. The top trace shows the MEP evoked by single pulse TMS over the corresponding M1. The lower trace shows the MEP elicited by ipsilateral cervical (motor root) stimulation. Right: MEP recorded from extensor digitorum brevis muscle. The top trace shows the MEP induced by cortical stimulation. The lower trace shows the MEP elicited by ipsilateral lumbar stimulation.

Amplitude is often measured from peak-to-peak amplitude. MEP amplitude can also be measured from baseline EMG activity to the first positive or negative deflection. Amplitude of MEP reflects the integrity and excitability of motor cortex, corticospinal tract, nerve roots and peripheral motor pathway to the muscles [64]. Dispersion of the alpha-motoneuron response to the descending volley in the corticospinal tract, leads to a broad range of normal values. The triple stimulation technique (TST) provides a more precise assessment of corticospinal tract conduction by suppressing desynchronization of MEPs. The TST involves three stimuli (transcranial, distal and proximal on the peripheral nerve) timed to produce two collisions. The TMS descending impulses collide with the antidromic impulses from the distal stimulus. Proximal stimulation on the nerve evokes orthodromic impulses, which cancel out any uncollided impulses from the distal stimulus. The response from the third stimulus therefore reflects the number of peripheral neurons activated from TMS [65].

Lengthening of MEP latency and CCT suggests impairment of the white matter fibers, while abnormalities of MEP amplitude or absence of responses are more suggestive of loss of neurons or axons. TMS has the potential to facilitate early diagnosis of myelopathy by detecting signals of demyelination of the pyramidal tract [66,67], plexus entrapment and injuries [62]. Moreover, MEP abnormalities may be useful objective markers of progression of amyotrophic lateral sclerosis (ALS) [68], and effective parameters in spinal pathology for deciding the timing of the surgical intervention [69].

TMS can however be performed using single pulse or pair pulse paradigm in order to explore the reactivity of the motor cortex. Since motor threshold (MT) is believed to reflect membrane examine of corticospinal neurons, motor neurons in the spinal cord, NMJs and muscle [70], it

is used as benchmark for the intensity of TMS. MT is usually defined by the lowest intensity of stimulation required to generate 50% probability of MEPs of more than 50 μ V [60].

Silent period (SP) is defined as the period of EMG suppression; normally it refers to the time from the end of the MEP to the return of voluntary EMG activity, after a single suprathreshold TMS pulse applied to the M1 corresponding to the active target muscle. The first 50–60 ms of the SP has been supposedly contributed to spinal inhibition and the late part originates most likely in the motor cortex, termed *cortical silent period* [71]. Abnormalities of SP have been shown in patients with various movement disorders [72,73]. In patients with a diagnosis of ALS, shortened PS has been observed [74].

Transcallosal conduction (TC): Application of a single suprathreshold TMS pulse to the M1 can suppress tonic voluntary EMG activity in ipsilateral hand muscles, by transcallosal inhibition. Delayed or absent TC suggests lesions of the corpus callosum [75]. In addition, application of single stimuli to both motor cortexes at a short interval, allows assessment of the interhemispheric interactions and also the TC [76].

Short interval intracortical inhibition (SICI) can be accessed by combining a subthreshold (60–80% of resting MT) conditioning (first) stimulus with a suprathreshold (second) test stimulus over M1, at short inter-stimulus intervals of 1–6 ms [77]. Significantly reduced SICI has been observed in patients with dystonia and Parkinson's disease [78,79].

Intracortical facilitation (ICF) reflects the excitatory phenomenon occurring in the M1, and is elicited by applying a conditioning subthreshold TMS pulse and a suprathreshold test stimulus over M1 with inter-stimulus intervals between 6 and 20 ms [80]. Significantly enhanced ICF has been recorded from amputated limbs in patients with neuropathic pain [81].

In addition to the study of the pathophysiology of diverse neurological diseases, paired-pulse TMS has been widely used to explore the effects of central nervous system (CNS)-active drugs on the motor cortex [70].

3.6. EMG recording in Intraoperative neuromonitoring

Intraoperative neuromonitoring includes mapping and true monitoring techniques. Mapping techniques are used intermittently during surgery for functional identification and preservation of anatomically ambiguous nervous tissue. On the other hand, true monitoring techniques permit a continuous assessment of the functional integrity of neural pathways [82].

In posterior fossa and brainstem surgeries, mapping the floor of the fourth ventricle allows the surgeon to find a safe entry to the brainstem, and therefore, helps to identify and preserve cranial nerves and their motor nuclei. Traditionally, Intraoperative monitoring of the facial nerve has been employed in operations for acoustic tumors to reduce the risk of neural damage. To date, EMG recording of the activity of selective cranial nerve muscles is currently included in the intraoperative set during surgical manipulation of the brainstem. [83,84].

During brain surgery, neurophysiological mapping techniques have been employed in the identification of eloquent areas such as the motor areas. In addition, these techniques have been introduced in surgery for deep-seated gliomas, insular tumors and lesions involving the

cerebral peduncle [82,84]. The goal is an aggressive resection of such lesions to the greatest extent as possible, to improve the patient’s survival chance and the postoperative life quality. With this aim, monopolar or bipolar stimulation of cortical and subcortical areas is applied carefully. Visual detection of the elicited movement of the limb contralateral to the operative side is usually employed during the mapping of motor areas. However, it is difficult to detect visually a subtle twitch over an entire contralateral limb at once, specially during awake surgery (because of the specific patient positioning). EMG recording is more sensitive than the visual detection of muscle twitch. EMG signals precede the visually observed motor activity, since the applied stimulation may weakly activate motor pathways enough to elicit EMG responses and yet not recruit a sufficiently large pool of motor neurons to produce visible muscle movement. Moreover, multichannel EMG recording has three important advantages: First, it facilitates the monitoring of the face, upper and lower extremities simultaneously, detecting motor responses that may not be observed during gross inspection (Fig.10). This advantage is particularly important during mapping of subcortical pathways. Second, EMG recording also improves the ability to detect subclinical ictal events (EMG activity elicited by stimulation that persists after the end of the stimulation). In addition, EMG—complementary to electrocorticography— allows the early detection of spreading muscle activation over a limb as a sign of seizure. The immediate removal of stimulation diminishes the likelihood of the progression of a seizure. Third, the sensitivity of EMG recording allows the application of lower intensity and duration of stimuli during mapping procedures [85-87].

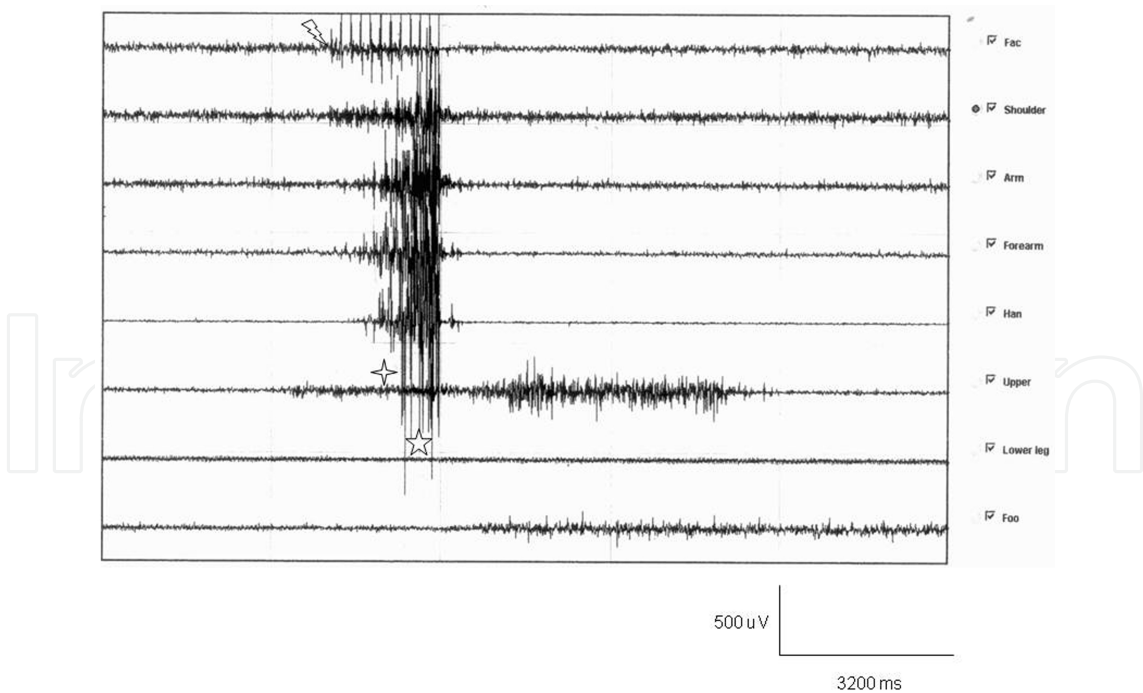


Figure 10. Multichannel EMG recording during mapping for glioma surgery. Stimuli artifact. (⚡) Muscle activity (☆) recorded preceding visual muscle twitch (☆).

EMG as a monitoring technique has a high sensitivity but a low specificity. To date, some limitations of EMG recording have been overcome using multimodality intraoperative monitoring, including motor evoked potentials, somatosensory evoked potentials and some reflex responses (H-reflex, blink reflex, etc). Transcranial MEP elicited by transcranial multipulse electric stimulation of the motor cortex (TcMEP) are currently the most effective means of continuous monitoring of the functional integrity of corticospinal and corticobulbar pathways in diverse surgical procedures [82,84].

During spinal procedures, free running EMG (frEMG) and stimulus-triggered EMG (stEMG) are basic monitoring tools to assess the functional integrity of nerve roots, plexus and peripheral nerves. Train activity or neurotonic discharges recorded by means of spontaneous EMG indicate excessive direct or indirect nerve contact during manipulation; therefore, adjustment should be made to avoid nerve injury. Recently, frEMG or stEMG have been included in the intraoperative set applied during minimally invasive surgeries such as transposas approaches. On the other hand, stEMG have been used to control the correct pedicular screw placement during orthopedic surgery [88]. Unlike the CMAPs recorded in neurophysiological laboratories, intraoperative CMAP are typically elicited using submaximal stimulation and are recorded as highly complex polyphasic responses with variable onset latencies and amplitudes. Stimulus threshold however can provide some information about the proximity to the nerve root [89].

TMS is likewise an advantageous optional technique in planning brain surgery, based on non-invasive mapping. TMS mapping consists of locating where the largest MEP responses can be measured by using suprathreshold single stimuli applied to the assumed area (M1) of the optimal stimulation site [90]. There is some evidence of the reliability of this planning method in correlation with the gold standard "direct cortical stimulation" described previously [91,92]. Interestingly, a recent report has provided the first result of the reliability of TMS, in the assessment of the plasticity changes of the involved M1 concurrent with multistage surgery, in a patient with a diagnosis of low grade glioma. However, further studies should confirm the power of this non-invasive mapping technique, in regard to patient-specific variation, and especially to functional anatomy [93].

4. Conclusion

Virtually all primary neuromuscular diseases result in changes in the electric activity recorded from the muscle fibers. The pattern of abnormalities can usually mark the underlying pathology as neuropathic (e.g. disorders affecting the CNS, nerve roots, plexuses and peripheral nerves), myopathic, or NMJ disorder, etc. EMG recording allows measurement of the severity of the injury, and provides prognostic information.

In the field of intraoperative neuromonitoring, to date, EMG recording – despite its low specificity – continues to be a valuable tool included in a multimodal monitoring set during diverse neurosurgical and orthopedic procedures.

Acknowledgements

We thank the Service of Clinical Neurophysiology, University Hospital "Marqués de Valdecilla", Spain; and Faranak Farzan Ph.D for their collaboration in the elaboration of this chapter.

Author details

Yunfen Wu*, María Ángeles Martínez Martínez and Pedro Orizaola Balaguer

*Address all correspondence to: yfenwufriendship@hotmail.com

Clinical Neurophysiology department, University Hospital "Marqués de Valdecilla", Spain

References

- [1] Enoka RM. Morphological features and activation patterns of motor units. *J Clin Neurophysiol* 1995; 12(6) 538–559.
- [2] Buchthal. Electromyography in the evaluation of muscle diseases. *Methods in Clinical Neurophysiology* 1991; 2 25-45.
- [3] Delgado TE, Bucheit WA, Rosenholtz HR, Chrissian S. Intraoperative monitoring of facila muscle evoked responses obtained by intracranial stimulation of the facila nerve: a more accurate technique for facila nerve dissection. *Neurosurgery* 1979; 4(5) 418-421.
- [4] Merletti R, Farina D. Analysis of intramuscular electromyogram signals. *Philos Transact A Math Phys Eng Sci* 2009; 367(1887): 357-68. [http://www4.fct.unesp.br/docentes/fisio/augusto/artigos% 20cient% EDficos/2009% 20% 20Analyssis% 20of% 20intramuscular% 20electromyogram% 20signals.full.pdf](http://www4.fct.unesp.br/docentes/fisio/augusto/artigos%20cient%EDficos/2009%20%20Analyssis%20of%20intramuscular%20electromyogram%20signals.full.pdf) (accessed 24 October 2012).
- [5] Podnar S, Mrkaić M. Size of motor unit potential sample. *Muscle Nerve*. 2003; 27(2) 196-201.
- [6] Reinstein L, Twardzik FG, Mech KF Jr. Pneumothorax: a complication of needle electromyography of the supraspinatus muscle. *Arch Phys Med Rehabil* 1987; 68(9) 561-562.
- [7] Quan D, Bird SJ. Nerve Conduction Studies and Electromyography in the Evaluation of Peripheral Nerve Injuries. *The University of Pennsylvania Orthopaedic Journal* 1999; 12 45–51.
- [8] Rutkove SB. Effects of temperature on neuromuscular electrophysiology. *Muscle Nerve* 2001; 24(7) 867-882.

- [9] Pullman SL, Goodin DS, Marquinez AI, Tabbal S, Rubin M. Clinical utility of surface EMG: report of the therapeutics and technology assessment subcommittee of the American Academy of Neurology. *Neurology* 2000; 55(2) 171-177.
- [10] Sacoo G, Buchthal F, Rosenfalck P. Motor unit potentials at different ages. *Arch Neurol* 1962; 6 366-373.
- [11] Liguori R, Fuglsang-Frederiksen A, Nix W, Fawcett PR, Andersen K. Electromyography in myopathy. *Neurophysiol Clin* 1997; 27(3) 200-203.
- [12] Izzo KL, Aravabhumi S. Clinical electromyography. Principles and practice. *Clin Podiatr Med Surg* 1990; 7(1) 179-194.
- [13] Uncini A, Lange DJ, Lovelace RE, Solomon M, Hays AP. Long-duration polyphasic motor unit potentials in myopathies: a quantitative study with pathological correlation. *Muscle Nerve* 1990; 13(3) 263-267.
- [14] Daube JR, Rubin DI. Needle electromyography. *Muscle Nerve* 2009; 39(2) 244-270.
- [15] Lateva ZC, McGill KC. Satellite potentials of motor unit action potentials in normal muscles: a new hypothesis for their origin. *Clin Neurophysiol* 1999; 110(9) 1625-1633.
- [16] Farrugia ME, Weir AI, Cleary M, Cooper S, Metcalfe R, Mallik A. Concentric and single fiber needle electrodes yield comparable jitter results in myasthenia gravis. *Muscle Nerve* 2009; 39(5) 579-585.
- [17] Benatar M, Hammad M, Doss-Riney H. Concentric-needle single-fiber electromyography for the diagnosis of myasthenia gravis. *Muscle Nerve* 2006; 34(2)163-168.
- [18] Tanhehco JL. Single-fiber electromyography. *Phys Med Rehabil Clin N Am* 2003; 14(2) 207-229.
- [19] Nandedkar SD, Barkhaus PE, Sanders DB, Stålberg EV. Analysis of amplitude and area of concentric needle EMG motor unit action potentials. *Electroencephalogr Clin Neurophysiol* 1988; 69(6) 561-567.
- [20] McNeil CJ, Doherty TJ, Stashuk DW, Rice CL. Motor unit number estimates in the tibialis anterior muscle of young, old, and very old men. *Muscle Nerve* 2005; 31(4) 461-467.
- [21] Barnes WS. The relationship of Motor-unit activation to isokinetic muscular contraction at different contractile velocities. *Phys Ther* 1980; 60(9) 1152-1158.
- [22] Ounjian M, Roy RR, Eldred E, Garfinkel A, Payne JR, Armstrong A, Toga AW, Edgerton VR. *Neurol Clin*. Physiological and developmental implications of motor unit anatomy. *J Neurobiol* 1991; 22(5) 547-559.
- [23] Preston DC, Shapiro BE. Needle electromyography. Fundamentals, normal and abnormal patterns. *Neurol Clin* 2002; 20(2) 361-396.

- [24] Daube JR. AAEM minimonograph #11: Needle examination in clinical electromyography *Muscle Nerve* 1991; 14(8) 685-700.
- [25] Grimaldi G, Manto M. Neurological tremor: sensors, signal processing and emerging applications. *Sensors* (Basel) 2010; 10(2) : 1399-1422. <http://www.ncbi.nlm.nih.gov/pmc/articles/PMC3244020/pdf/sensors-10-01399.pdf> (accessed 23 October 2012).
- [26] Kojovic M, Cordivari C, Bhatia K. Myoclonic disorders: a practical approach for diagnosis and treatment. *Ther Adv Neurol Disord* 2011; 4(1) 47-62.
- [27] Piboolnurak P, Yu QP, Pullman SL. Clinical and neurophysiologic spectrum of orthostatic tremor: case series of 26 subjects. *Mov Disord* 2005; 20(11) 1455-1461.
- [28] Podnar S. Comparison of parametric and nonparametric reference data in motor unit potential analysis. *Muscle Nerve* 2008; 38(5) 1412-1419.
- [29] Stålberg E, Bischoff C, Falck B. Outliers, a way to detect abnormality in quantitative EMG. *Muscle Nerve* 1994; 17(4) 392-329.
- [30] Abel EW, Zacharia PC, Forster A, Farrow TL. Neural network analysis of the EMG interference pattern. *Med Eng Phys* 1996; 18(1) 12-17.
- [31] Stålberg E, Chu J, Bril V, Nandedkar S, Stålberg S, Ericsson M. Automatic analysis of the EMG interference pattern. *Electroencephalogr Clin Neurophysiol* 1983; 56(6) 672-681.
- [32] Nandedkar SD, Sanders DB, Stålberg EV. Simulation and analysis of the electromyographic interference pattern in normal muscle. Part II: Activity, upper centile amplitude, and number of small segments. *Muscle Nerve* 1986; 9(6) 486-490.
- [33] Yaar I, Niles L. EMG interference pattern power spectrum analysis in neuro-muscular disorders. *Electromyogr Clin Neurophysiol* 1989; 29(7-8) 473-484.
- [34] Rønager J, Christensen H, Fuglsang-Frederiksen A. Power spectrum analysis of the EMG pattern in normal and diseased muscles. *J Neurol Sci* 1989; 94(1-3) 283-294.
- [35] McGill KC, Cummins KL, Dorfman LJ. Automatic decomposition of the clinical electromyogram. *IEEE Trans Biomed Eng* 1985; 32(7) 470-477.
- [36] Le Fever RS, Xenakis AP, De Luca CJ. A procedure for decomposing the myoelectric signal into its constituent action potential. Part II: execution and test for accuracy. *IEEE Trans Biomed Eng* 1982; 29 158-164.
- [37] Doherty TJ, Stashuk DW. Decomposition-based quantitative electromyography: methods and initial normative data in five muscles. *Muscle Nerve* 2003; 28(2) 204-211.
- [38] Nandedkar SD, Barkhaus PE, Charles A. Multi-motor unit action potential analysis (MMA). *Muscle Nerve* 1995; 18(10) 1155-1166.

- [39] Rutkove SB. Effects of temperature on neuromuscular electrophysiology. *Muscle Nerve* 2001; 24(7) 867-882.
- [40] Abdeen MA, Stuchly MA. Modeling of magnetic field stimulation of bent neurons. *IEEE Trans Biomed Eng.* 1994; 41(11) 1092-5.
- [41] Pyun SB, Kwon HK. The effect of anatomical variation of the sural nerve on nerve conduction studies. *Am J Phys Med Rehabil* 2008; 87(6) 438-442.
- [42] Beheiry EE. Anatomical variations of the median nerve distribution and communication in the arm. *Folia Morphol (Warsz)* 2004; 63(3) 313-318.
- [43] Rayegani SM, Daneshtalab E, Bahrami MH, Eliaspour D, Raeissadat SA, Rezaei S, Babae M. Prevalence of accessory deep peroneal nerve in referred patients to an electrodiagnostic medicine clinic. *J Brachial Plex Peripher Nerve Inj* 2011; 6(1) 3.
- [44] Falck B, Stålberg E. Motor nerve conduction studies: measurement principles and interpretation of findings. *J Clin Neurophysiol* 1995; 12(3) 254-279.
- [45] Fisher MA. F response latencies and durations in upper motor neuron syndromes. *Electromyogr Clin Neurophysiol* 1986; 26(5-6) 327-332.
- [46] Hopf HC. Topodiagnostic value of brain stem reflexes. *Muscle Nerve* 1994; 17(5) 475-484.
- [47] Kimura J. Long and short of nerve conduction measures: reproducibility for sequential assessments. *J Neurol Neurosurg Psychiatry* 2001; 71(4) 427-430.
- [48] Logigian EL, Kelly JJ Jr, Adelman LS. Nerve conduction and biopsy correlation in over 100 consecutive patients with suspected polyneuropathy. *Muscle Nerve* 1994; 17(9) 1010-1020.
- [49] Zivković SA, Shipe C. Use of repetitive nerve stimulation in the evaluation of neuromuscular junction disorders. *Am J Electroneurodiagnostic Technol* 2005; 45(4) 248-261.
- [50] Franssen H, van den Bergh PY. Nerve conduction studies in polyneuropathy: practical physiology and patterns of abnormality. *Acta Neurol Belg* 2006; 106(2) 73-81
- [51] Feasby TE, Brown WF, Gilbert JJ, Hahn AF. The pathological basis of conduction block in human neuropathies. *J Neurol Neurosurg Psychiatry* 1985; 48(3) 239-244.
- [52] Olney RK, Lewis RA, Putnam TD, Campellone JV Jr; American Association of Electrodiagnostic Medicine. Consensus criteria for the diagnosis of multifocal motor neuropathy. *Muscle Nerve* 2003; 27(1) 117-121.
- [53] Rhee EK, England JD, Sumner AJ. A computer simulation of conduction block: effects produced by actual block versus interphase cancellation. *Ann Neurol* 1990; 28(2) 146-156.
- [54] Iose S, Kuwabara S, Kokubun N, Sato Y, Mori M, Shibuya K, Sekiguchi Y, Nasu S, Fujimaki Y, Noto Y, Sawai S, Kanai K, Hirata K, Misawa S; Tokyo Metropolitan Neu-

- romuscular Electrodiagnosis Study Group. Utility of the distal compound muscle action potential duration for diagnosis of demyelinating neuropathies. *J Peripher Nerv Syst* 2009; 14(3)151-158.
- [55] Olney RK, Budingen HJ, Miller RG. The effects of temporal dispersion on compound muscle action potential area in human peripheral nerve. *Muscle Nerve* 1987; 10 728-733.
- [56] Smith RS, Koles ZJ. Myelinated nerve fibers: computed effect of myelin thickness on conduction velocity. *Am J Physiol* 1970; 219(5) 1256-1258.
- [57] García A, Calleja J, Antolín FM, Berciano J. Peripheral motor and sensory nerve conduction studies in normal infants and children. *Clin Neurophysiol* 2000; 111(3) 513-520.
- [58] Hakamada S, Kumagai T, Watanabe T, Koike Y, Hara K, and Miyazaki S. The conduction velocity of slower and the fastest fibres in infancy and childhood. *J Neurol Neurosurg Psychiatry* 1982; 45(9) 851-853.
- [59] Waxman SG. Determinants of conduction velocity in myelinated nerve fibers. *Muscle Nerve* 1980; 3(2)141-150.
- [60] Rossini PM, Barker AT, Berardelli A, Caramia MD, Caruso G, Cracco RQ, Dimitrijević MR, Hallett M, Katayama Y, Lücking CH, et al. Non-invasive electrical and magnetic stimulation of the brain, spinal cord and roots: basic principles and procedures for clinical application: report of an IFCN committee. *Electroencephalogr Clin Neurophysiol* 1994; 91(2) 79-92.
- [61] Hess CW, Mills KR, Murray NM. Responses in small hand muscles from magnetic stimulation of the human brain. *J. Physiol* 1987; 388 397-419.
- [62] Rayegani SM, Hollisaz MT, Hafezi R, Nassirzadeh S. Application of magnetic motor stimulation for measuring conduction time across the lower part of the brachial plexus. *J Brachial Plex Peripher Nerve Inj* 2008; 3 7.
- [63] Muller K, Homberg V, Lenard HG. Magnetic stimulation of motor cortex and nerve roots in children. Maturation of cortico-motoneuronal projections. *Electroencephalogr Clin Neurophysiol* 1991; 81: 63-70
- [64] Morita H, Olivier E, Baumgarten J, Petersen NT, Christensen LO, Nielsen JB (2000) Differential changes in corticospinal and Ia input to tibialis anterior and soleus motor neurones during voluntary contraction in man. *Acta Physiol Scand* 170(1) 65-76.
- [65] Magistris MR, Rösler KM, Truffert A, Myers P. Transcranial stimulation excites virtually all motor neurons supplying the target muscle. A demonstration and a method improving the study of motor evoked potentials. *Brain* 1998; 121 437-450.
- [66] Chen R, Cros D, Curra A, et al. The clinical diagnostic utility of transcranial magnetic stimulation: report of an IFCN committee. *Clin Neurophysiol* 2008; 119(3) 504-532.

- [67] Ogino H, Tada K, Okada K, et al. Canal diameter, anteroposterior compression ratio and spondylotic myelopathy of the cervical spine. *Spine* 1983; 8 1–15.
- [68] Floyd AG, Yu QP, Piboolnurak P, Tang MX, Fang Y, Smith WA, Yim J, Rowland LP, Mitsumoto H, Pullman SL. Transcranial magnetic stimulation in ALS: utility of central motor conduction tests. *Neurology* 2009; 72(6) 498-504.
- [69] Nakamae T, Tanaka N, Nakanishi K, Fujimoto Y, Sasaki H, Kamei N, Hamasaki T, Yamada K, Yamamoto R, Izumi B, Ochi M. Quantitative assessment of myelopathy patients using motor evoked potentials produced by transcranial magnetic stimulation. *Eur Spine J* 2010; 19(5) 685-690.
- [70] Ziemann U, Lönnecker S, Steinhoff BJ, Paulus W. Effects of antiepileptic drugs on motor cortex excitability in humans: a transcranial magnetic stimulation study. *Ann Neurol* 1996; 40(3) 367-378.
- [71] Chen R, Lozano AM, Ashby P. Mechanism of the silent period following transcranial magnetic stimulation. Evidence from epidural recordings. *Exp Brain Res* 1999; 128(4) 539-542.
- [72] Rona S, Berardelli A, Vacca L, Inghilleri M, Manfredi M. Alterations of motor cortical inhibition in patients with dystonia. *Mov Disord* 1998; 13 118–124.
- [73] Berardelli A, Rona S, Inghilleri M, Manfredi M. Cortical inhibition in Parkinson's disease. A study with paired magnetic stimulation. *Brain* 1996; 119 (Pt 1) 71-17.
- [74] Caramia MD, Palmieri MG, Desiato MT, Iani C, Scalise A, Telera S, Bernardi G. Pharmacologic reversal of cortical hyperexcitability in patients with ALS. *Neurology* 2000; 54(1) 58-64.
- [75] Meyer BU, Rörich S, Gräfin von Einsiedel H, Kruggel F, Weindl A. Inhibitory and excitatory interhemispheric transfers between motor cortical areas in normal humans and patients with abnormalities of the corpus callosum. *Brain* 1995; 118 (Pt 2) 429-440.
- [76] Ferbert A, Priori A, Rothwell JC, Day BL, Colebatch JG, Marsden CD. Interhemispheric inhibition of the human motor cortex. *J Physiol* 1992; 453 525-546.
- [77] Kujirai T, Caramia MD, Rothwell JC, et al. Corticocortical inhibition in human motor cortex. *J Physiol* 1993; 471 501–519.
- [78] Ridding MC, Sheean G, Rothwell JC, Inzelberg R, Kujirai T. Changes in the balance between motor cortical excitation and inhibition in focal, task specific dystonia. *J Neurol Neurosurg Psychiatry* 1995; 59(5) 493-438.
- [79] Ridding MC, Inzelberg R, Rothwell JC. Changes in excitability of motor cortical circuitry in patients with Parkinson's disease. *Ann Neurol* 1995; 37(2) 181-188.
- [80] Ziemann U, Rothwell JC, Ridding MC. Interaction between intracortical inhibition and facilitation in human motor cortex. *J Physiol* 1996; 496(Pt 3) 873–881.

- [81] Schwenkreis P, Witscher K, Janssen F, Dertwinkel R, Zenz M, Malin JP, Tegenthoff M. Changes of cortical excitability in patients with upper limb amputation. *Neurosci Lett* 2000; 293(2) 143-146.
- [82] Sala F, Lanteri P. Brain surgery in motor areas: the invaluable assistance of intraoperative neurophysiological monitoring. *J Neurosurg Sci* 2003; 47 79-88.
- [83] Moller, A.R. Monitoring and mapping the cranial nerves and the brainstem, In: Deletis, V, and Shils, J.L., eds.: *Neurophysiology in Neurosurgery: A Modern Intraoperative Approach*, Chapter 13, pp 283-310, Amsterdam, 2002, Academic Press.
- [84] Sala F, Manganotti P, Tramontano V, Bricolo A, Gerosa M. Monitoring of motor pathways during brain stem surgery: what we have achieved and what we still miss? *Neurophysiol Clin* 2007; 37(6) 399-406.
- [85] Szelényi A, Bello L, Duffau H, Fava E, Feigl GC, Galanda M, Neuloh G, Signorelli F, Sala F; Workgroup for Intraoperative Management in Low-Grade Glioma Surgery within the European Low-Grade Glioma Network. Intraoperative electrical stimulation in awake craniotomy: methodological aspects of current practice. *Neurosurg Focus* 2010; 28(2) E7.
- [86] González-Hidalgo M, Saldaña CJ, Alonso-Lera P, Gómez-Bustamante G. The usefulness of electromyographical monitoring with intraoperative brain mapping during motor lesionectomy. *Rev Neurol* 2009; 16-30; 48(12) 620-624.
- [87] Yingling CD, Ojemann S, Dodson B, Harrington MJ, Berger MS. Identification of motor pathways during tumor surgery facilitated by multichannel electromyographic recording. *J Neurosurg* 1999; 91(6) 922-927.
- [88] Gonzalez AA, Jeyanandarajan D, Hansen C, Zada G, Hsieh PC: Intraoperative neurophysiological monitoring during spine surgery: a review. *Neurosurg Focus* 2009; 27(4) E6.
- [89] Holland NR. Intraoperative electromyography. *J Clin Neurophysiol* 2002; 19(5) 444-453.
- [90] Wilson SA, Thickbroom GW, Mastaglia FL. Transcranial magnetic stimulation mapping of the motor cortex in normal subjects. The representation of two intrinsic hand muscles. *J Neurol Sci* 1993; 118(2)134-144.
- [91] Forster MT, Hattingen E, Senft C, Gasser T, Seifert V, Szelényi A. Navigated transcranial magnetic stimulation and functional magnetic resonance imaging: advanced adjuncts in preoperative planning for central region tumors. *Neurosurgery* 2011; 68(5) 1317-1324.
- [92] Picht T, Schmidt S, Brandt S, Frey D, Hannula H, Neuvonen T, Karhu J, Vajkoczy P, Suess O. Preoperative functional mapping for rolandic brain tumor surgery: comparison of navigated transcranial magnetic stimulation to direct cortical stimulation. *Neurosurgery* 2011; 69(3) 581-588.

- [93] Takahashi S, Jussen D, Vajkoczy P, Picht T. Plastic relocation of motor cortex in a patient with LGG (low grade glioma) confirmed by NBS (navigated brain stimulation). *Acta Neurochir (Wien)* 2012 Sep 4.

IntechOpen

IntechOpen

