

# We are IntechOpen, the world's leading publisher of Open Access books Built by scientists, for scientists

6,900

Open access books available

185,000

International authors and editors

200M

Downloads

Our authors are among the

154

Countries delivered to

TOP 1%

most cited scientists

12.2%

Contributors from top 500 universities



WEB OF SCIENCE™

Selection of our books indexed in the Book Citation Index  
in Web of Science™ Core Collection (BKCI)

Interested in publishing with us?  
Contact [book.department@intechopen.com](mailto:book.department@intechopen.com)

Numbers displayed above are based on latest data collected.  
For more information visit [www.intechopen.com](http://www.intechopen.com)



---

# **Application of Optical Coherence Tomography and Macular Holes in Ophthalmology**

---

Robert J. Lowe and Ronald C. Gentile

Additional information is available at the end of the chapter

<http://dx.doi.org/10.5772/53535>

---

## **1. Introduction**

Optical coherence tomography (OCT) has revolutionized how we understand macular holes. The purpose of this chapter is to describe the integration of OCT in the diagnosis, classification, and management of macular holes.

## **2. Definitions of macular holes**

A macular hole is a full thickness defect, or hole, in the neurosensory retina located within, or just eccentric to the center of the fovea.

An impending macular hole, also known as a stage 1 macular hole, is considered the precursor to a full thickness idiopathic macular hole. Impending macular holes have a splitting of the inner retina with the clinical appearance of a foveolar cyst or pseudocyst. In some cases, this inner splitting can be associated with a defect in the underlying outer retina (Lee, Kang et al. 2011). An impending macular hole with a defect in the outer retina can have a very thin intact inner retina referred to as the roof of the impending macular hole. These impending macular holes can progress to become full thickness macular hole once a break in the inner retina or roof occurs.

Most macular holes, unless otherwise specified, refer to idiopathic macular holes. Idiopathic macular holes occur from tractional forces on the foveola at the vitreoretinal interface not associated with other causes. Other types of macular holes include those associated with

trauma, high myopia, retinal detachments, lasers accidents, lightning strikes, diabetic retinopathy, and epiretinal membranes.

### **3. Types of macular holes**

#### **3.1. Idiopathic macular holes**

Idiopathic macular holes are the most common type of macular hole. A population based chart review of patients with macular holes reported that 92% of macular holes were idiopathic. Mean age in this study was 68.6 (range 47.5–89.6) years. The prevalence of idiopathic macular holes ranges from 0.02% to 0.8%. The incidence of idiopathic macular holes was found to be 8.5 persons per 100,000 population per year (McCannel, Ensminger et al. 2009).

#### **3.2. Traumatic macular holes**

Macular holes can be associated with ocular trauma and are often referred to as traumatic macular holes. In the same population based study mentioned above, only 2% of all macular holes were traumatic macular holes (McCannel, Ensminger et al. 2009).

The formation of a traumatic macular hole is believed to be related to the rapid changes at the vitreofoveal interface that occur during the traumatic event. In a study from the Walter Reed Army Medical Center, 3% of soldiers who sustained combat related ocular trauma were found to have full thickness macular holes (Weichel and Colyer 2009). In contrast to the formation of idiopathic macular holes that may occur over the course of weeks to months, the formation of traumatic macular holes is quicker. (Johnson, McDonald et al. 2001).

Other associated findings seen in traumatic macular holes, not present in idiopathic macular holes, include retinal pigment epithelium (RPE) mottling with damaged to the RPE. Damage to the RPE appears to be directly related to the trauma. Despite the presence of RPE damage, visual recovery is still possible (Chow, Williams et al. 1999; Johnson, McDonald et al. 2001). Fortunately, the surgical closure rate (96%) and visual improvement in traumatic macular holes is similar to that found with idiopathic macular hole closure (Johnson, McDonald et al. 2001).

#### **3.3. Myopic macular holes**

Macular holes can be associated with high myopia and are referred to as myopic macular holes. High myopia is most commonly defined as a refractive error equal to or greater than  $-6.00$  diopters of axial myopia with an axial length of greater than 26 mm (Wu and Kung 2011).

Highly myopic patients seem to be at higher risk for developing macular holes that have unique features and associations. Myopic macular holes develop as the refractive error increases (Kobayashi, Kobayashi et al. 2002) and can be associated with retinal detachments and myopic schisis. The association with retinal detachment appears greatest in the presence of a posterior staphaloma and longer axial length (greater than or equal to 30 mm).

The success rate of surgical repair of myopic macular holes is not as high as the surgical closure rate of macular holes in non-myopic eyes. Some studies have reported success rates as low as 60% and 62.5% (Patel, Loo et al. 2001; Wu and Kung 2011) compared to the 90% success rates seen in idiopathic macular hole repair. The lower success rate is believed to be related to a foreshortened retina within the staphaloma that can create residual tractional forces on the retina despite surgery (Ikuno, Sayanagi et al. 2003; Wu and Kung 2011).

### **3.4. Macular holes following retinal detachment surgery**

Rarely, macular holes can form after retinal detachment surgery. The prevalence of macular hole formation after any type of retinal detachment surgery has been reported to be 0.9% (Benzerroug, Genevois et al. 2008). In eyes that underwent retinal detachment surgery with pars plana vitrectomy, the prevalence has ranged between 0.2% to 1.1% (Lee, Park et al. 2010; Fabian, Moisseiev et al. 2011). For reasons not well understood, macular holes forming after retinal detachment surgery tend to occur more often in macula-off retinal detachments (Benzerroug, Genevois et al. 2008). In one study, the prevalence of macular holes after retinal detachment surgery is more than 3 times greater than the prevalence of macular holes due to idiopathic causes (0.3%) (Fabian, Moisseiev et al. 2011). Fortunately, the surgical closure rate in eyes with macular holes after retinal detachment surgery is similar to the success rate of idiopathic macular hole closure, around 90% success (Benzerroug, Genevois et al. 2008; Lee, Park et al. 2010).

## **4. Histopathology of idiopathic macular holes**

Histopathological analysis of macular holes in the 1980s helped elucidate how macular holes form. Idiopathic macular holes were found to be associated with an epiretinal membrane (ERM) leading to the wrinkling of the internal limiting membrane of the inner retina. Furthermore, cystoid macular edema within the inner nuclear and outer plexiform layers of the retina, located around these idiopathic macular holes, were also discovered. An operculum of glial cells have been found over the macular holes (Frangieh, Green et al. 1981).

From these histopathological studies, the ILM, ELM formation, and cystoid macular edema were believed to play a role in the pathogenesis of idiopathic macular holes. Many felt that vitreous traction may be implicated in the pathogenesis of macular holes, especially in cases

where an operculum of glial tissue was seen on the posterior hyloid face of the vitreous (Frangieh, Green et al. 1981). Anterior-posterior traction from a posterior vitreous detachment can also convert a macular cyst to a macular hole (McDonnell, Fine et al. 1982).

At the time of these histological studies, surgical repair of macular holes was not an option. Macular holes that have closed were due to spontaneous closure. Histopathology of spontaneously closed macular holes have revealed proliferation of fibroglial cells filling and bridging the macular hole (Frangieh, Green et al. 1981). This finding may be seen in surgically closed macular holes as well.

## 5. Gass classification of idiopathic macular holes

Donald Gass and Robert Johnson in the late 1980s and early 1990s created a classification system for idiopathic macular holes. They divided idiopathic macular holes into 4 stages based on clinical findings using contact lens biomicroscopy. Remarkably, this was done before the clinical use of optical coherence tomography (OCT).

### 5.1. Stage 1

Stage 1 macular holes, also known as impending macular holes, are considered precursors of full thickness macular holes. Stage 1 macular holes are divided into 2 substages, 1A and 1B (Gass 1988). Stage 1A appears as a yellow spot in the center of the fovea (Gass 1995). The foveal yellow spot ranges between 100 to 200  $\mu\text{m}$  in diameter and has flattening of the normal foveal depression (Gass 1988). Stage 1B appears as a yellow ring that measures roughly 200 to 350  $\mu\text{m}$  in diameter. The yellow ring is believed to be due to the centrifugal displacement of the xanthophylls and foveal retinal tissue (Gass 1995). Visual acuity in patients with a stage 1 (impending) macular holes are usually good, but can range from 20/25 to 20/70. Retinal angiography using fluorescein dye (fluorescein angiography, or FA) of stage 1 macular holes is usually normal or may show early hyperfluorescence without late staining or leakage (Gass 1988).

### 5.2. Stage 2

Progression from stage 1 to a stage 2 can occur over weeks to months. Stage 2 macular holes (early hole formation) are full thickness holes of less than 400  $\mu\text{m}$  in size. An early stage 2 macular hole can be located within, or just eccentric to the center of the fovea. When located centrally the holes are usually round. When the holes are located eccentric, they can be oval or crescent shaped (Gass 1995). Gass hypothesized that stage 2 macular holes start as a break located either eccentrically at one end of the yellow ring or in 2 peripheral locations. This break could enlarge along the ring and may lead to a release of an operculum of neuronal tissue into the vitreous cavity. However, if the break started centrally and enlarged, an operculum may not be found. Stage 2 macular holes are consistently hyperfluorescent early on

FA without late staining or leakage (Gass 1988). Vision is usually between 20/70 and 20/200 (Gass 1988).

### 5.3. Stage 3 and 4

Progression from a stage 2 to a stage 3 hole can occur over the course of several months with varying degrees of vitreofoveal separation. Stage 3 macular holes are full thickness holes of  $\geq 400 \mu\text{m}$  in size without a complete posterior vitreous detachment. A stage 3 macular hole becomes a stage 4 macular hole once a complete posterior vitreous detachment occurs with detachment of the posterior vitreous hyaloid from the entire macula and optic disc (Gass 1995). Progression from a stage 3 to a stage 4 macular hole may take several years (Gass 1988). Vision usually deteriorates to about 20/200.

## 6. Introduction of optical coherence tomography

Optical coherence tomography (OCT) is considered the gold standard in diagnosing and classifying macular holes (Dayani, Maldonado et al. 2009). OCT scans display cross sectional, in vivo, representations of the retina. Remarkably, early histological work and Gass' clinical observations on macular holes correlate very well with what is seen on OCT. Before the advent of OCT, physicians diagnosed and characterized macular holes based on biomicroscopy and used visual acuity, amsler grid, Watzke-Allen sign, and FA testing to help confirm the diagnosis (McDonnell, Fine et al. 1982).

The advent of OCT made diagnosing macular holes easier and can distinguish macular holes from other macular pathology that, prior to OCT, was difficult. For example, OCT can differentiate macular holes from lamellar holes and pseudoholes. Also, OCT is superior to biomicroscopy in eyes with limited macular pigmentation or depigmentation. Decreased contrast between the retina, RPE and choroid (i.e. chorioretinal atrophy) when there is less pigmentation makes the biomicroscopic evaluation and diagnosis of macular holes difficult. This is especially true in the setting of high myopia and a posterior staphaloma (Coppe, Ripandelli et al. 2005; Wu and Kung 2011). In addition, the detection of an operculum has been facilitated and made more reliable with OCT. Without OCT, finding an operculum in the vitreous cavity can be difficult using biomicroscopy alone (Yuzawa, Watanabe et al. 1994).

OCTs have evolved with improvements in both resolution and acquisition times. Due to these improvements, commercially available time-domain (TD) OCT has been replaced with the newer spectral-domain (SD) OCT. Resolution of the OCT system, dependent on the bandwidth of the light source used, have increased the axial resolution of the OCT images from 10 - 20  $\mu\text{m}$  in the TD OCTs to 5 - 6  $\mu\text{m}$  in the SD OCTs (Sano, Shimoda et al. 2009). In addition, since SD OCTs measure the interferometric signal detected as a function of optical frequencies, it has imaging speeds 50 times faster than TD OCT and can provide a greater number of images per unit area. With SD OCT, 512 x 170 scans (horizontal x vertical) in a 6 x 6  $\text{mm}^2$  area can be made to ensure that all dimensions of the macular hole are not missed (Masuyama, Yamakiri et al. 2009).

## 7. Mechanism of macular hole formation

### 7.1. Idiopathic macular hole formation

Based on clinical observations, Gass proposed a mechanism of macular hole formation that involved vitreous traction on the fovea. Vitreous traction would start anteriorly from the retina and was followed by a tangential traction as the vitreous cortex above the fovea contracted (Gass 1988). The traction would create the stage 1A macular hole with continued traction causing the macular hole to progress from stage 1A to stage 4.

The high resolution imaging from OCT has lead to a better understanding of the relationship between the vitreous and retina during the formation of a macular hole. Using OCT the pathophysiology of a macular hole can be divided into three phases and one pivotal event. The first phase, or formation phase, is the initiating event. The first phase is followed by the pivotal event that determines if the macular hole enters the second phase, or the progression phase. The third phase, or closure phase, most often occurs surgically. In some cases, the closure phase can occur spontaneously.

Anterior –posterior contraction of the cortical vitreous from the fovea in time-lapsed OCT morphing videos appears to be the initiating event, or phase 1, in idiopathic macular hole formation. In phase 1 the anterior-posterior traction comes from the detachment of the posterior hyaloid from the fovea. The anterior-posterior traction may cause a break in the ILM and/or ELM. If a break occurs in both the ILM and ELM, the foveal integrity can become destabilized, and the pivotal event occurs.

After the pivotal event, fluid may enter the breaks in the ILM and ELM and cause hydration of the neurosensory retina with cystic formation at the edges of the macular hole. This accumulation of cystic fluid, or phase 2, leads to progression and enlargement of the macular hole. This cystic hydration leads to further elevation of the edges of the macular hole off the RPE with progressive enlargement of the macular hole. In phase 3, or closure phase, migration of glial cells over the macular hole leads to closure of the macular hole and subsequent reabsorb the cystic and subretinal fluid by the RPE pump (Gentile, Landa et al. 2010).

### 7.2. Traumatic macular hole formation

It was hypothesized that formation of traumatic macular holes occur when the blunt ocular trauma causes a rapid compression of the cornea and expansion of the globe. This force leads to expansion of the equator, flattening of the posterior pole, and subsequent posterior expansion of the posterior pole. The tractional force on the thin fovea is thought to lead to the formation of a macular hole (Johnson, McDonald et al. 2001). This mechanism can occur without a posterior vitreous detachment. OCT of traumatic macular holes have shown a full thickness macular hole without a posterior vitreous detachment in patients who report immediate vision loss after the trauma (Yamashita, Uemara et al. 2002). If there is a delay in vision loss and a delay in the formation of the macular hole after trauma, this might occur if there is persistent vitreous adhesion to the fovea after the

trauma. The persistent vitreous adhesion, as demonstrated on OCT, can cause traction on the fovea and lead to delayed dehiscence with later onset of vision loss. Once the persistent vitreous adhesion resolves, traumatic macular holes have been shown to spontaneously close (Yamashita, Uemura et al. 2002).

### **7.3. Macular hole formation in high myopia**

OCT has been utilized to help understand how macular holes form in highly myopic eyes. Macular hole formation in highly myopic eyes can arise from macular retinoschisis (Sun, Liu et al. 2010). Retinoschisis is a splitting of the retinal layers and was first described in highly myopic eyes with posterior staphylomas using OCT (Takano and Kishi 1999). It is hypothesized that macular holes develop in highly myopic eyes from macular retinoschisis and overlying vitreofoveal traction (Benhamou, Massin et al. 2002; Shimada, Ohno-Matsui et al. 2006; Sun, Liu et al. 2010). Two patterns of macular hole formation from myopic macular retinoschisis have been described and are differentiated by the location of the initial lamellar defect. Pattern 1 starts with an outer retinal lamellar defect that unroofs and leads to a full thickness macular hole. Pattern 2 starts with an inner retinal lamellar defect with the defect progressing posteriorly to the RPE to become a full thickness macular hole. Time to progression of pattern 1 and 2 to become a full thickness macular hole can be 11 and 9 months, respectively (Sun, Liu et al. 2010).

### **7.4. Macular hole formation after pars plana vitrectomy**

The mechanism of macular hole formation after pars plana vitrectomy is unclear. This poses interesting challenges to the belief that the inciting mechanism of idiopathic macular hole formation is from anterior-posterior vitreous traction. Vitreous traction is not present in these eyes because they have already undergone vitrectomy and in most cases a posterior vitreous detachment has already occurred.

Furthermore, macular holes seen after retinal detachment repair tend to occur in macula-off retinal detachments. It is unclear if having subretinal fluid under the fovea plays a role in macular hole formation in these cases (Benzerroug, Genevois et al. 2008).

Various mechanisms have been proposed to help explain how macular holes form after pars plana vitrectomy for retinal detachment repair. These mechanisms include traction during the surgical repair or traction from the ILM, ERM or residual vitreous cortex (Fabian, Moiseiev et al. 2011).

### **7.5. Formation of aborted macular holes**

In addition to fully understanding how macular holes develop, it is also important to visualize how macular holes can abort. The mechanism of aborted macular holes depends on the occurrence of a posterior vitreous foveal detachment during stage 1 of the macular hole. If the posterior vitreous detaches from the fovea after formation of a stage 1 macular hole, progression to stage 2 macular hole is aborted about 50% of the time (Gass 1995).

In these cases, there may be improvement or stabilization of visual acuity to 20/30 or better. Clinically there is also improvement in the yellow ring seen on biomicroscopy, and in some cases resolution of the early hyperfluorescence seen on FA (Gass 1988). However, despite resolution of the foveal elevation seen in stage 1, a lamellar defect of the inner retinal layers can still occur. In these cases, an operculum over a lamellar defect or a vitreous opacity overlying a normal fovea may be present in 1/3 of cases (Johnson and Gass 1988; Gass 1995).

## **8. Optical coherence tomography characterization of stage 1 through 4 macular holes**

### **8.1. Stage 1A**

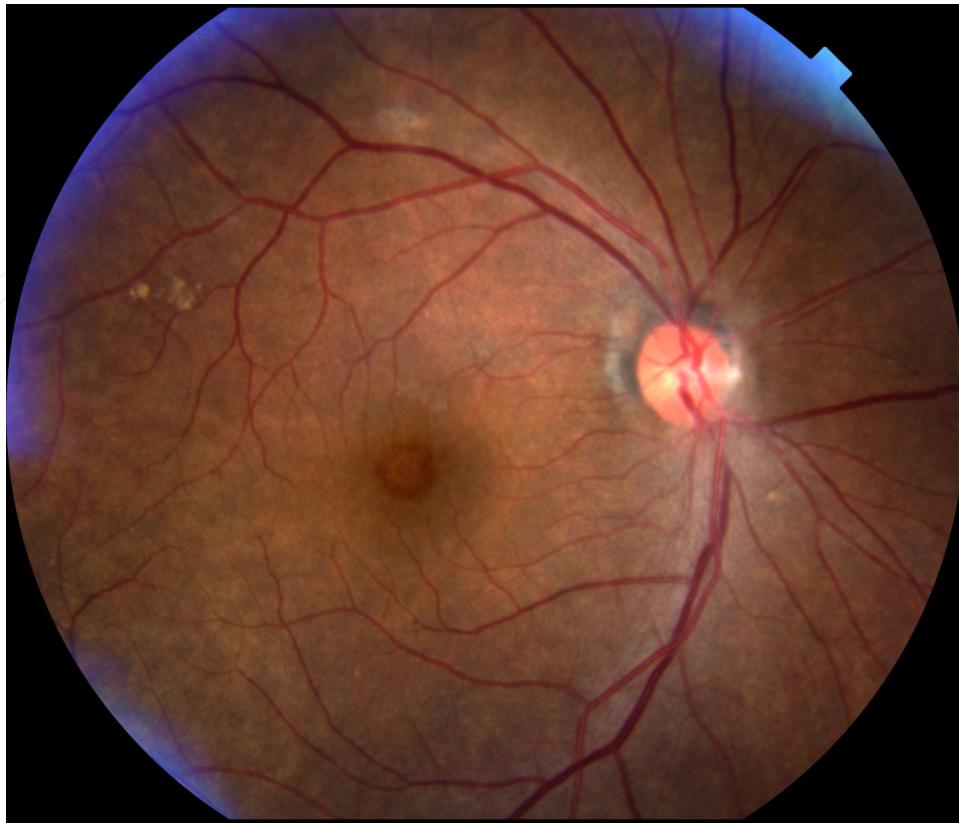
The use of OCT has given us an *in vivo* visualization of macular holes that we could never have achieved clinically. New descriptions of findings have been characterized based on OCT. For example, stage 1A macular holes were found to have a triangular detachment of the foveola on OCT. The mean width of the foveolar detachment was further characterized as 167.7  $\mu\text{m}$  with a range between 146 and 205  $\mu\text{m}$ . The triangular detachment of the foveola was felt to be a detachment of the posterior tips of the cone outer segments (COST) (Takahashi, Nagaoka et al. 2011).

The COST and its relationship to macular holes were further described using OCT. The anterior-posterior vitreal traction onto the fovea may extend through the Müller cells of the retina onto the photoreceptors to cause a localized photoreceptor detachment or COST detachment (Takahashi, Nagaoka et al. 2010). The COST detachment can enlarge horizontally and anteriorly to involve the inner segment/outer segment junction (Takahashi, Nagaoka et al. 2011).

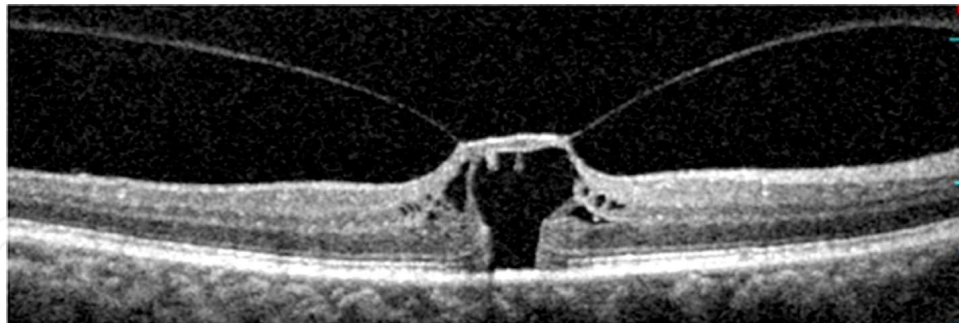
After complete posterior vitreous detachment, a stage 1A macular hole can abort and become an aborted macular hole. The triangular detachment of the COST and yellow spot may resolve. Also in some cases a residual defect in the outer retina, specifically the junction between the inner segments and outer segments, can be seen underneath the fovea in the aborted macular holes (Takahashi, Nagaoka et al. 2011).

### **8.2. Stage 1B**

Stage 1B (Figures 1 and 2) macular holes, compared to Stage 1A macular holes, were found to involve both the inner and outer retinal layers of the fovea (Takahashi, Nagaoka et al. 2011). The roof or inner layer of the stage 1B macular hole remains intact, and the outer layer develops a break with the RPE layer becoming devoid of photoreceptors (Takahashi, Nagaoka et al. 2011). A portion of the detached outer retina consisting of cone photoreceptors may even become part of the roof of the macular hole (Takahashi, Nagaoka et al. 2010).



**Figure 1.** Fundus photo of a stage 1B macular hole



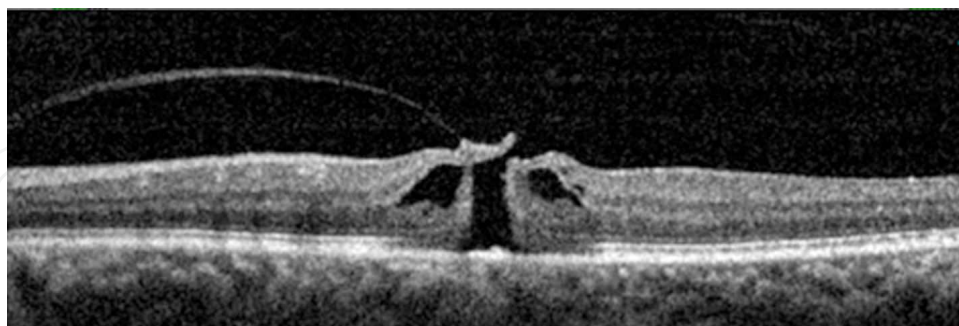
\*All OCT images in the book chapter were obtained using the Cirrus HD-OCT Model 4000, Carl Zeiss Meditec, Inc. or Spectral OCT SLO, Opko/OTI, Inc.

**Figure 2.** OCT\* of the same eye from figure 1 showing a stage 1B macular hole. There is a defect in the outer layers of the retina.

### 8.3. Stage 2

OCT can show a break in the roof of a stage 2 full thickness macular hole (Figure 3). The patient, a 69 year old woman, had a decrease in visual acuity (VA) to 20/100 (Figure 3). After

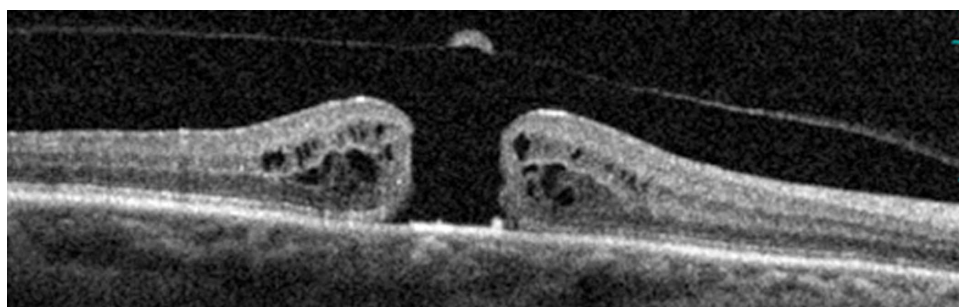
a pars plana vitrectomy (PPV), ILM peel, gas tamponade and eventual cataract surgery, vision improved to 20/20.



**Figure 3.** OCT of a stage 2 macular hole with a break in the roof and cystoid hydration.

#### 8.4. Stage 3

OCT can show a full thickness macular hole with an operculum. Figure 4, a 70 year old woman, with a VA of Finger Count had surgical repair of the macular hole and subsequent cataract surgery. VA improved to 20/40, 1 year after her primary surgery.



**Figure 4.** Full thickness stage 3 macular hole with overlying operculum. This macular hole would be classified as stage 4 if the posterior vitreous completely detached from the macula and optic nerve.

### 9. Surgical repair of macular holes

In 1991, Kelly and Wendel reported on the surgical management of macular holes. This involved a pars plana vitrectomy, creation of a posterior vitreous detachment if one was not already present, removal of an ERM if present, gas tamponade, and face down positioning. Initial anatomical success rates were reported to be 58% with improvement in visual acuity (Kelly and Wendel 1991). Success rates improved to 73% in a later report by the same group. Overall, greater success of anatomical closure was found in smaller macular holes with symptoms that were less than 6 months in duration (Wendel, Patel et al. 1993).

### **9.1. Internal limiting membrane peeling during surgical repair**

Following Kelly and Wendel's initial report, peeling the ILM layer of the innermost portion of the retina was published. In 1999, Park et al. described a case series of 58 eyes who underwent an ERM peel or ILM peel if an ERM was not present. A 91% anatomical success rate was reported. They suggested that removing the ILM aided in relieving tangential traction. This traction may come from contractile myofibroblastic cells that proliferate over the ILM (Park, Sipperley et al. 1999).

In order to remove traction from the myofibroblastic cells over the ILM, the ILM must also be removed during macular hole surgery. Furthermore, it is thought that contraction from the ILM displaces photoreceptors that may lead to enlargement of the macular hole. Once the ILM is surgically removed, the photoreceptors may be able to return towards the center of the hole and promote macular hole closure (Sano, Shimoda et al. 2009).

In a comparison of macular hole repair with and without ILM peeling, an anatomical success rate of 100% (116/116 eyes) with ILM peeling vs 82% success rate (36/44 eyes) without ILM peeling was reported. However, in the cases without ILM peeling, an ERM if present was not removed. The remaining ERM may have adversely affected the closure rate in these patients (Brooks 2000).

In a randomized clinical control trial performed in the United Kingdom, patients with idiopathic stage 2 or 3 macular holes were randomized to ILM peeling vs no ILM peeling. In the ILM peeling group, the ILM was stained with 0.15% trypan blue to aid in the visualization of the transparent ILM. The rate of macular hole closure in the ILM peeling group vs no ILM peeling at 1 month was 84% and 48%, respectively. The rate of macular hole reoperation in the ILM peeling group vs no ILM peeling by 6 months was 12% and 48%, respectively. At the conclusion of the study, the authors recommended ILM peeling in the repair of macular holes. ILM peeling was felt to be safe and more cost effective, with a higher success rate for macular hole closure (Lois, Burr et al. 2011).

### **9.2. The use of intraoperative optical coherence tomography**

OCT has been used as an adjunctive tool in the operating room. It has helped shed light on the change in the contour of macular holes before and after ILM peeling. OCT before and after ILM peeling at the edge of the macular hole in one patient documented the relaxation and elevation of the edge of the macular hole that was thought to aid in the surgical repair of the macular hole. After removal of the ILM, the base diameter of the macular holes decreased while the height increased (Dayani, Maldonado et al. 2009). Intraoperative OCT also demonstrated a decrease in macular hole base diameter immediately after air-fluid exchange. Macular hole closure was even seen intraoperatively in a stage 3 macular hole and in a traumatic macular hole during the air-fluid exchange (Hayashi, Yagou et al. 2011).

### **9.3. The use of optical coherence tomography in gas filled eyes**

Recently, there have been reports of imaging macular holes after repair in gas filled eyes. This was difficult before the advent of the newer generation SD OCT. Before SD OCT, the

older TD OCTs were unable to image eyes under gas tamponade due to the excessive light reflectivity of the gas-retinal interface and difficulty in imaging the correct area, easily missed with TD OCT (Masuyama, Yamakiri et al. 2009).

Imaging the macular hole area is accomplished more easily using SD OCT. SD OCT can quickly perform serial scans over the macular area. Using SD OCT, it was found that imaging through gas was easier with a complete gas fill. Once the gas level decreased to a 70% fill, the light reflex from the lower meniscus of the gas made imaging of the macular hole more difficult. Imaging became possible again once the gas fill reached 50% (Masuyama, Yamakiri et al. 2009).

A recent study examining how quickly macular holes can close postoperatively using OCT found closed macular holes in 10 of 13 eyes (76.9%) on postoperative day 1 and an additional 2 eyes that closed by postoperative day 2 (Masuyama, Yamakiri et al. 2009). Sano et al. had similar experiences with SD OCT imaging of macular holes through gas. Of the over 90% of eyes they were able to image on postoperative day 1, over 90% were found to be closed (Sano, Inoue et al. 2011).

After the vitrectomy and ILM peeling for the surgical repair of macular holes, patients were instructed to remain in a face down position so that the gas will be juxtaposed against the macular hole. The use of SD OCT in the immediate postoperative period may help in limiting the amount of face down positioning needed. Patients may consider stopping their face down positioning once the macular hole appears closed on OCT, which may be as early as postoperative day 1 (Masuyama, Yamakiri et al. 2009; Sano, Inoue et al. 2011).

#### **9.4. Silicone oil tamponade**

For some patients, face down positioning may be impossible. In such patients, silicone oil tamponade can be a viable option. Oster et al. demonstrated using SD OCT that there was no difference in silicone oil tamponade with face forward or face down positioning in 75% of the study eyes (Oster, Mojana et al. 2010).

The use of silicone oil for myopic macular hole repair without face down positioning has been shown to be successful in the closure of myopic macular holes with subsequent improvement of vision. Myopic macular holes were successfully closed in 22 of 24 eyes (92%) using silicone oil after ILM peeling. These eyes had an average axial length of  $29.6 \pm 1.8$  mm and an average of  $23.3 \pm 14.0$  months of tamponade (Nishimura, Kimura et al. 2011).

Furthermore, Jumper et al. found similar OCT findings of early post-surgical macular hole closure through silicone oil tamponade as compared to gas tamponade. As early as the first postoperative day in eyes with silicone oil tamponade, flattening of the edges of the macular hole has been shown using OCT. This flattening of the edges was accompanied by a decrease in both the size of the intraretinal cystic spaces and in the subretinal fluid located at the cuff of the macular hole (Jumper, Gallemore et al. 2000).

However, Oster et al. has demonstrated that silicone oil tamponade may have some limitations when compared with gas tamponade. Supine positioning may cause the silicone oil to

rise anteriorly and a fluid pocket to form between the macular hole and silicone oil interface. In 7 of 10 eyes, the silicone oil bridged the macular hole while in the remaining 3 eyes, the silicone oil filled the macular hole and was in contact with the RPE. If the silicone oil fills the macular hole, it may prevent the complete close of the macular hole. Furthermore, silicone oil contact with the RPE may be toxic to the subfoveal RPE. This potential damage to the RPE does not occur with gas tamponade (Oster, Mojana et al. 2010).

## **10. Two OCT classifications to define macular hole closure**

OCT has helps characterize macular hole closure. Two groups have described their own classification for macular hole closures.

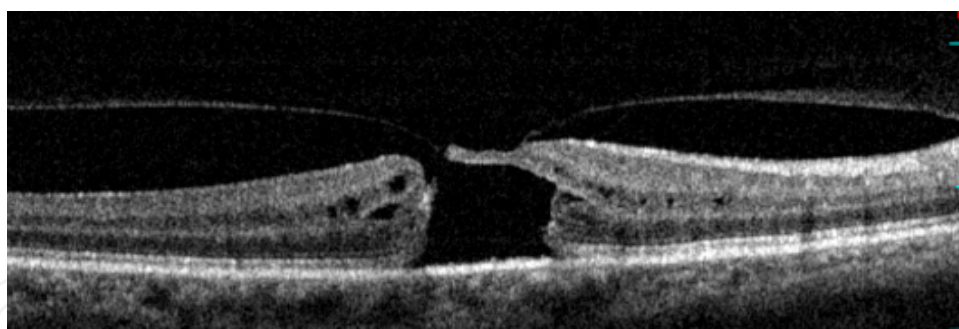
Kang et. al. described macular hole closure as either type 1 or type 2 as imaged on OCT. Type 1 closure is defined as the presence of a continuous layer of retinal tissue bridging the macular hole. Normal foveal contour is seen in type 1 macular hole closures. Type 2 closure is defined as an interruption of retinal tissue between the edges of the macular hole. On OCT, the edges of the macular hole were attached to the underlying RPE without subretinal fluid. According to Kang et al. type 1 and 2 closures represent successful anatomical closure of macular holes (Kang, Ahn et al. 2003). As expected, type 1 closure was associated with better visual outcomes than type 2 closure. Larger macular holes (mean diameter: 674  $\mu\text{m}$ ) were associated with type 2 closures, while smaller holes (mean diameter: 469  $\mu\text{m}$ ) were more associated with type 1 closures (Kang, Ahn et al. 2003).

Tornambe et. al. provided a similar OCT classification system divided also into type 1 and type 2 macular hole closures. Type 1 represented a flat and closed macular hole configuration. Type 2 closure is an open macular hole with flat edges. Both types were considered successful macular hole closure. In comparison, a failed macular hole closure was seen as an open macular hole with the edges being elevated by the subretinal fluid underneath (Tornambe, Poliner et al. 1998).

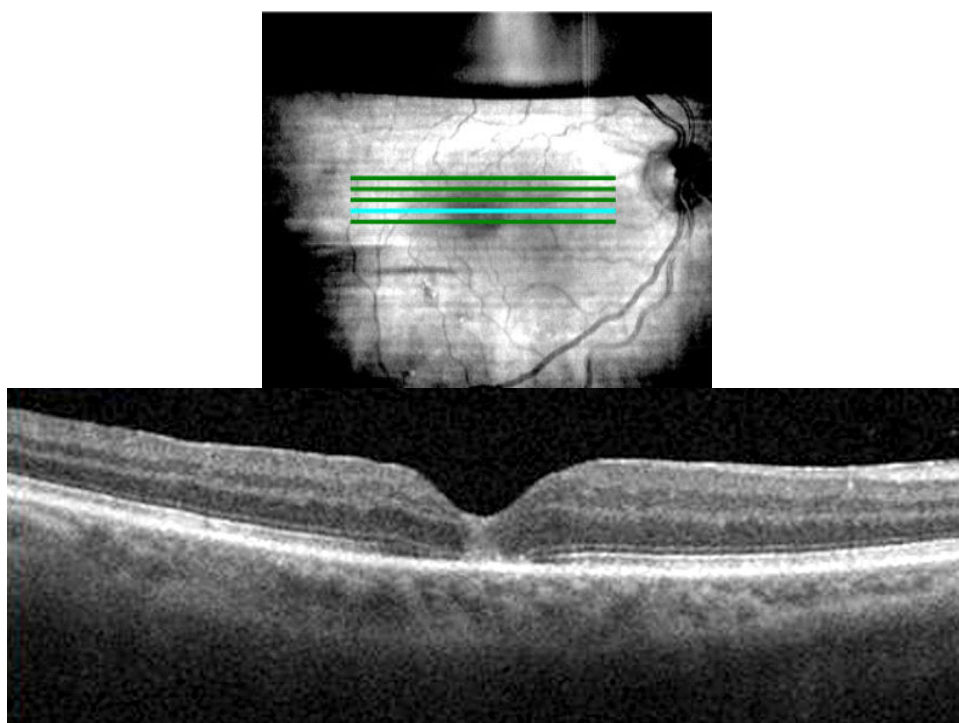
## **11. Cases of surgical repair of macular holes**

### **11.1. Idiopathic macular hole**

A 69 year old woman presented with an idiopathic macular hole. The macular hole was stage 2 with a break in the overlying roof with cystoid hydration at the edges of the macular hole (Figure 5). Visual acuity was Finger Count. The patient underwent a PPV, indocyanine green (ICG) staining of the ILM, ILM peeling and gas tamponade. After face down positioning, the macular hole closed (Figure 6). After subsequent cataract surgery, 6 months after initial macular hole surgical repair, vision improved to 20/60.



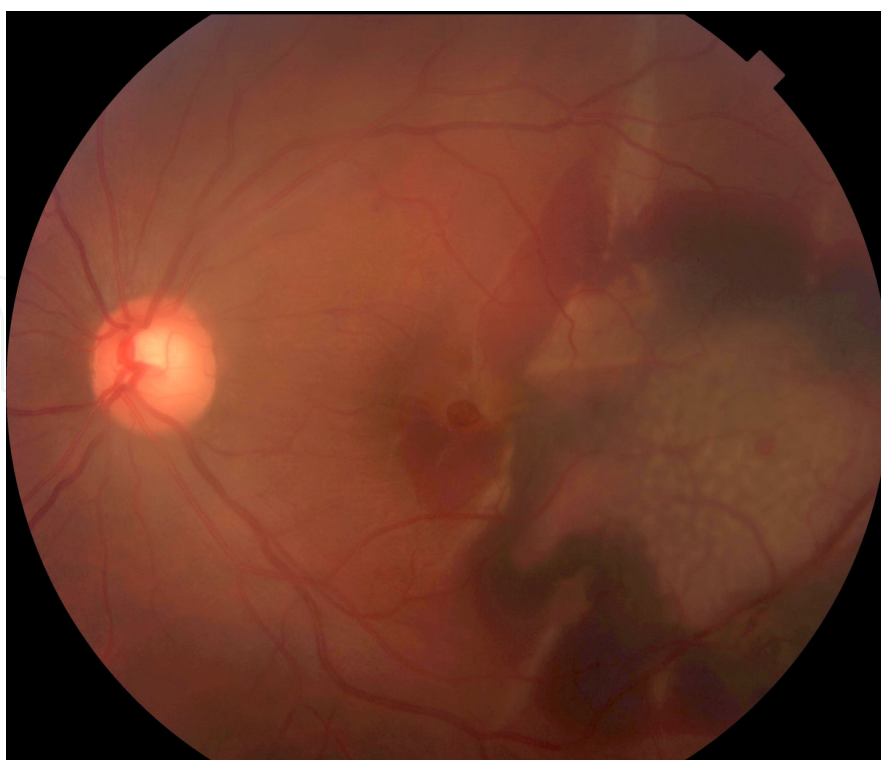
**Figure 5.** Preoperative OCT of an eccentric stage 2 macular hole with vitreous adhesion to the roof of the macular hole



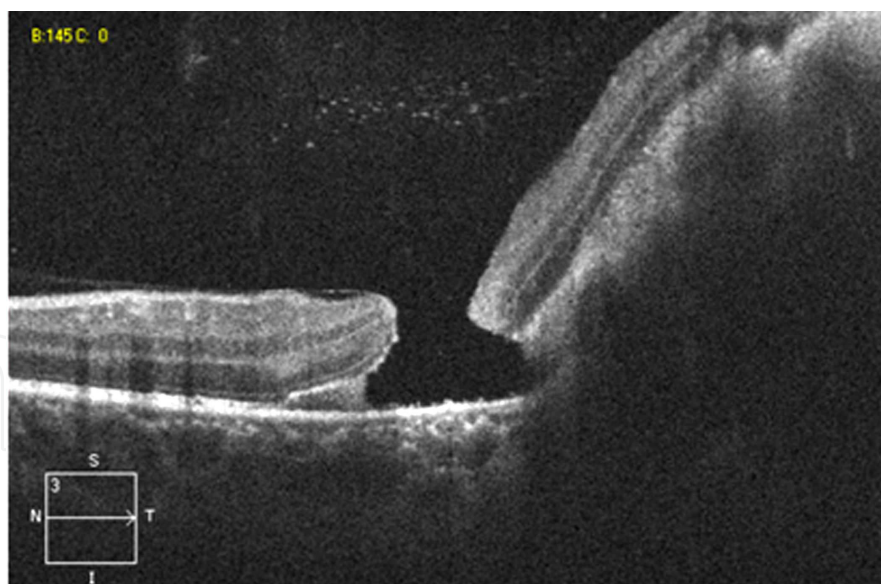
**Figure 6.** Postoperative OCT of the closed macular hole one month after surgical repair. Note the residual gas bubble obscuring view of the superior retinal blood vessels at the top photo.

### 11.2. Traumatic macular hole

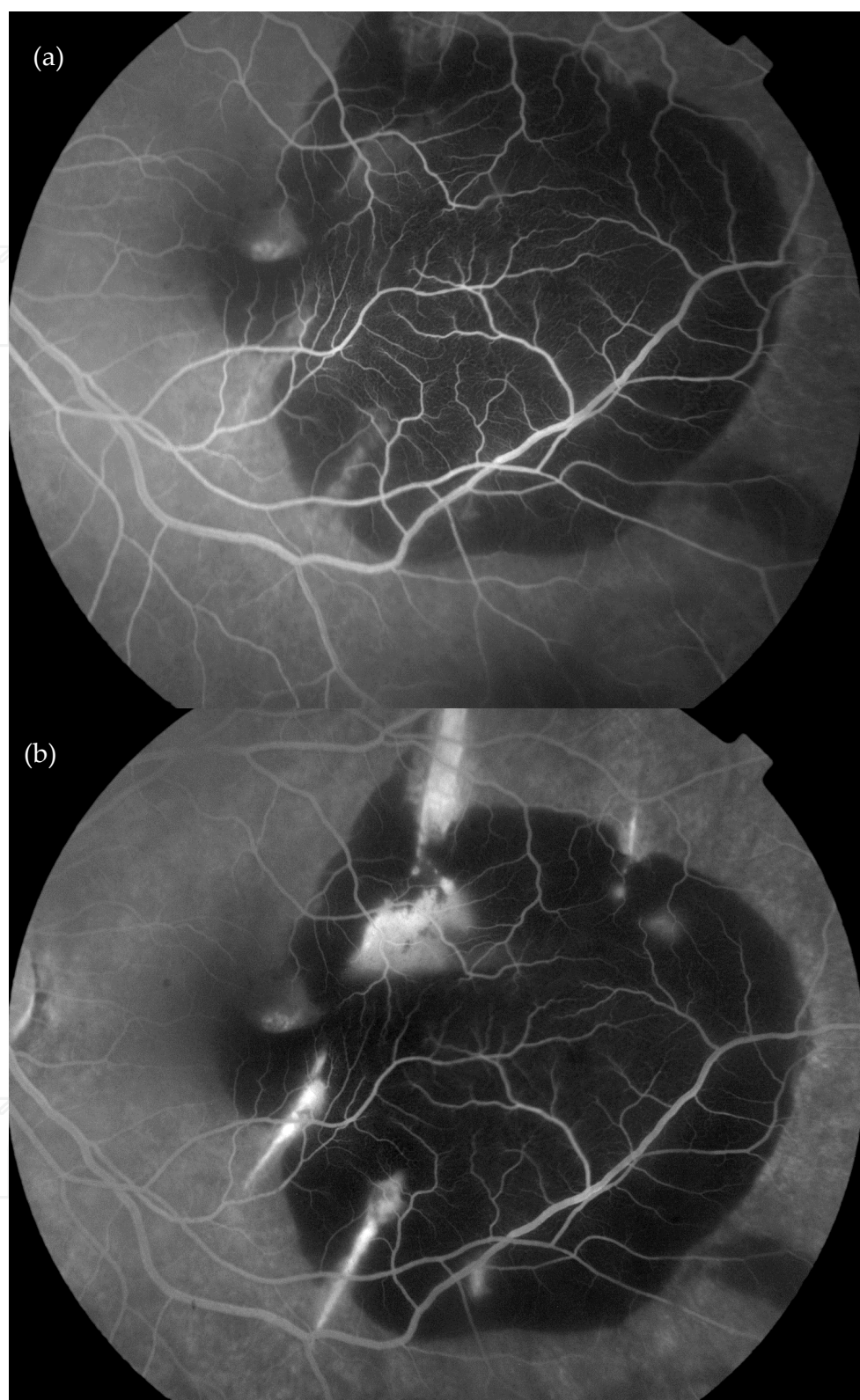A 31 year old man presented with a traumatic macular hole following an airbag injury (Figure 7). Vision initially was 20/100 with OCT (Figure 8) revealing a full thickness macular hole with subretinal hemorrhage. There was an associated choroidal rupture (Figure 9). Despite no change in visual acuity, repeat OCT two weeks later revealed progressive cystoid hydration at the edges of the macular hole with subretinal fluid (Figure 10). The patient underwent repair of the macular hole with PPV, ILM peeling, and gas tamponade with closure of the macular hole (Figure 11) and improvement in vision to 20/30.



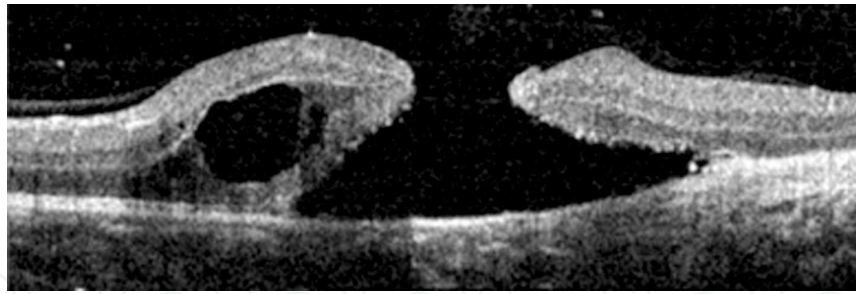
**Figure 7.** Fundus photo of the traumatic macular hole with associated subretinal hemorrhage and choroidal rupture



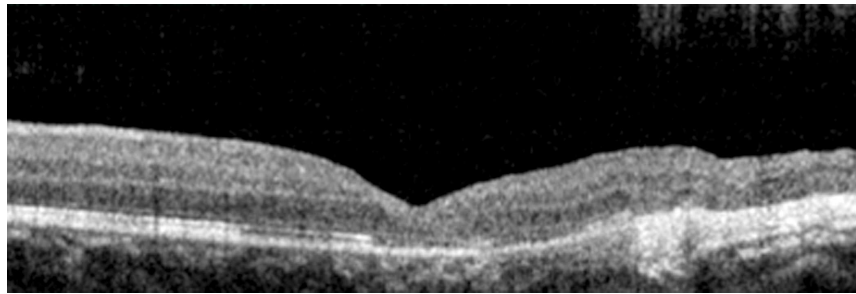
**Figure 8.** OCT of the traumatic macular hole and subretinal hemorrhage



**Figure 9.** FA of an early and late frame showing the initial hyperfluorescence of the macular hole (a) with an increase in hyperfluorescence of the choroidal rupture (b). The area of decreased fluorescence corresponds to the subretinal hemorrhage.



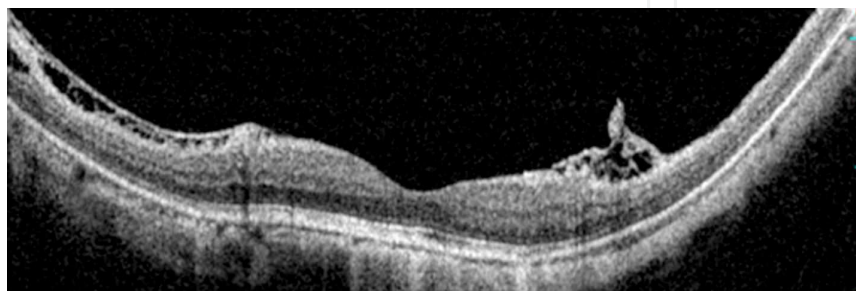
**Figure 10.** OCT showing enlargement of the macular hole with subretinal fluid and cystic hydration



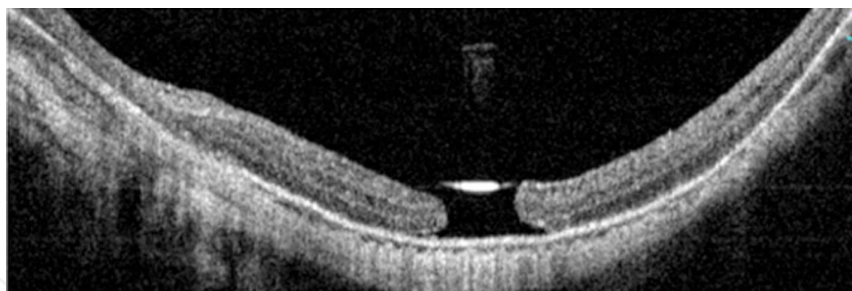**Figure 11.** OCT showing closure of the macular hole and improvement of the vision after PPV, ILM peel, and gas tamponade

### 11.3. High myopic macular hole and retinal detachment

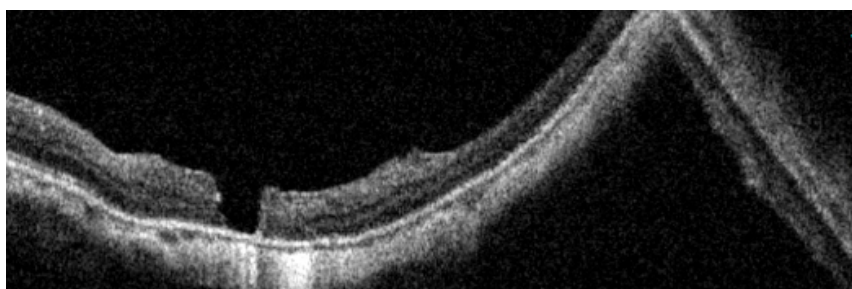
Retinal detachment repair from a macular hole in an eye with high myopia can be challenging. A 68 year old, highly myopic women presented with a macular hole and retinal detachment. Vision was Finger Count. Her fellow eye had myopic macular retinoschisis (Figure 12). She underwent a PPV and ILM peel with silicone oil tamponade to repair her retinal detachment and macular hole. Two weeks after retinal detachment repair, the vision improved to 20/150 (Figure 13). One month after retinal detachment repair, she subsequently underwent removal of the silicone oil with additional ILM peel and gas tamponade to repair the macular hole. Two weeks after macular hole repair, her OCT revealed a closed/flat macular hole configuration (Figure 14). Six months after macular hole repair, the visual acuity was 20/100.



**Figure 12.** Myopic retinoschisis in the fellow eye



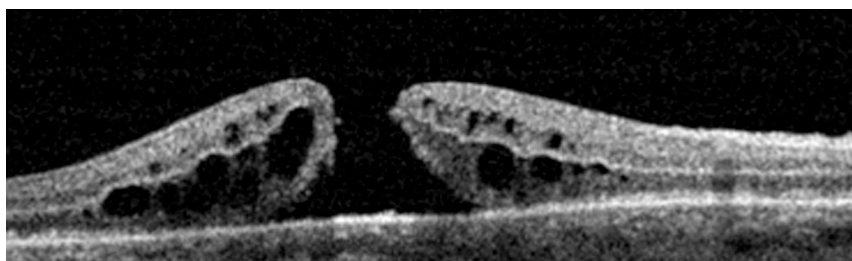
**Figure 13.** OCT showing an open macular hole after retinal detachment repair with membrane peel and silicone oil tamponade. Note the high reflective layer of the edge of the silicone oil tamponade over the macular hole.



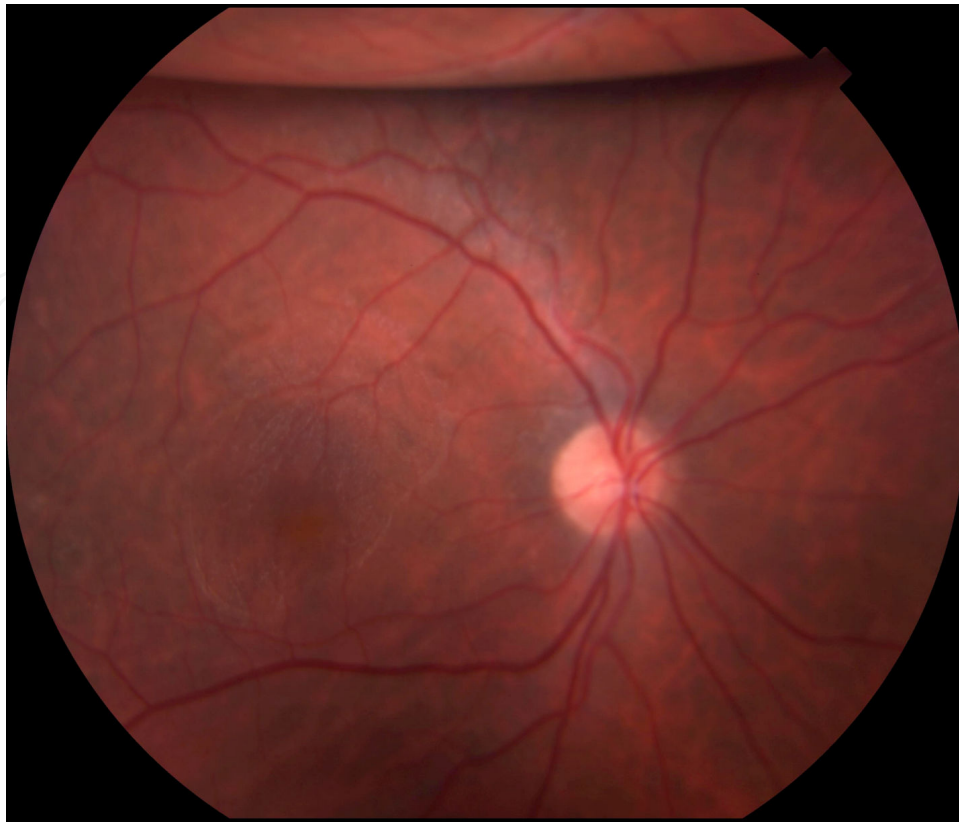
**Figure 14.** OCT of a flat and closed macular hole closure configuration after macular hole repair.

#### 11.4. Macular hole formation after retinal detachment repair

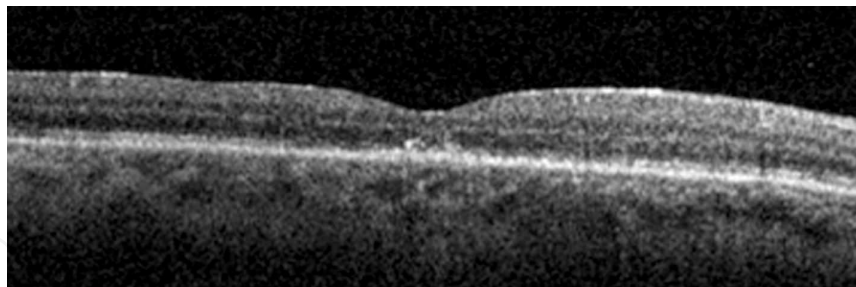
A macular hole can occur after retinal detachment repair. A 60 year old patient presented with a macula involving retinal detachment and a visual acuity of Finger Count. Three weeks after retinal detachment repair, central vision did not improve and a macular hole was present (Figure 15). Subsequently, the patient underwent ICG staining, ILM peeling, and gas tamponade (Figure 16 and 17). Visual acuity improved to 20/400 six months after macular hole closure.



**Figure 15.** Macular hole formed after retinal detachment repair.



**Figure 16.** One month after macular hole repair: Fundus photograph showing an area of the macula devoid of ILM after ILM peel with residual superior gas bubble



**Figure 17.** One month after macular hole repair: OCT showing a closed macular hole after ILM peel and gas tamponade

## 12. Mechanism of macular hole closure

### 12.1. Postsurgical macular hole closure

The mechanism of macular hole closure is better understood with the aid of OCT. Masuyama et. al. proposed that the formation of a bridge of tissue over the hole begins the macular hole closure. Neural tissue bridges the macular hole after the removal of the internal limit-

ing membrane and during the interaction of the hole with the gas tamponade. After bridge formation, a seal is created and the subretinal and intraretinal fluid is reabsorbed to close the macular hole (Masuyama, Yamakiri et al. 2009). This subsequent reabsorption of the cystic edema and then subretinal fluid leads to the return of the foveal contour (Gentile, Landa et al. 2010). Until the gliotic wound matures, this neural tissue bridge may be unstable (Masuyama, Yamakiri et al. 2009) and the macular hole can reopen (Takahashi and Kishi 2000). Wound healing may continue through the formation of a mature gliotic plug that joins the two ends of the bridge to seal the hole. The gliotic plug that forms to close the macular hole has also been documented on histopathology (Funata, Wendel et al. 1992).

## 12.2. Spontaneous macular hole closure

### 12.2.1. *Spontaneous idiopathic macular hole closure*

In an observational case series of 97 eyes, Yuzawa, et. al. reported 6% of study eyes experienced a spontaneous resolution of their macular hole with improvement of their vision from 20/100 - 20/200 to 20/20 - 20/60. This occurred after an average of 25 months (range, 7 to 41 months). Better visual outcomes were seen if reattachment occurred before 24 months. Reasons attributed to the disappearance of the macular hole included the contraction of an epiretinal membrane over the macular hole, fibroglial tissue growth, retinal pigment epithelial hyperplasia over the hole, and reattachment of the operculum after posterior vitreous detachment (Yuzawa, Watanabe et al. 1994).

A subsequent observation of spontaneous macular hole closure using OCT was reported by Takahashi et. al. They proposed a mechanism of spontaneous macular hole closure that was similar to surgical macular hole closure. Macular hole closure occurred spontaneously after resolution of vitreal-foveal traction. The formation of a bridge of retinal tissue that emerged from the edge of the macular hole extended centrally over 3 to 6 weeks and closed the hole. After formation of the bridge, the subfoveal and intraretinal cystic fluid was absorbed by the RPE pump by 8 months (Takahashi and Kishi 1999).

### 12.2.2. *Spontaneous traumatic macular hole closure*

OCT has also been used to formulate a possible mechanism for spontaneous traumatic macular hole closure. Spontaneous closure of traumatic macular holes has been reported to occur between 3 to 6 months after the trauma. These cases were in young patients ranging from 11 to 19 years of age in macular holes that were less than 1/3 disc diameter in size without any cuff of subretinal fluid. The mechanism of hole closure was thought to be proliferation of glial and RPE cells at the edges of the hole (Yamada, Sakai et al. 2002). Another series of 18 patients with traumatic macular holes were followed by Yamashita et al. Eight patients (44%), age ranging from 11 to 21 years, had spontaneous closure of the macular hole. These cases also involved smaller macular holes of less than 1/3 disc diameters in size. Holes had closed between 1 week to 4 months after the trauma with improvement in visual acuity (Yamashita, Uemara et al. 2002). The mechanism of bridging tissue seen after surgical repair has also been documented in spontaneous traumatic macular hole closure (Menchini, Virgili et al. 2003).

### 13. Morphological changes after macular hole closure

OCT imaging of surgically closed macular holes has been showed to aid in predicting visual outcome. The preservation of the external limiting membrane (ELM) layer and photoreceptor inner and outer segment (IS/OS) junction seems to predict visual acuity and photoreceptor cell survival (Shimozono, Oishi et al. 2011). This is believed to be because the ELM represents the junction between the Müller cells and photoreceptor cells (Bottoni, De Angelis et al. 2011) and the IS/OS junction represents the integrity of photoreceptor alignment. Furthermore, the outer foveal thickness measured between the ELM and inner layer of the RPE may be a surrogate to outer segment regeneration (Shimozono, Oishi et al. 2011). An increase in outer foveal thickness 6 months after surgery is associated with better visual outcomes. In addition, ELM and IS/OS defects are associated with worse visual acuity after macular hole surgical repair (Shimozono, Oishi et al. 2011).

Visual recovery after macular hole closure is thought to occur after the detached photoreceptors at the edges of the macular hole reattach to the RPE (Yuzawa, Watanabe et al. 1994). Overall, vision improves when the outer segments elongate (increase in outer foveal thickness) with subsequent realignment of the photoreceptors (return of the IS/OS junction) as seen on OCT. An intact ELM (viable photoreceptor cells) needs to be present before the process of visual recovery begins (Shimozono, Oishi et al. 2011). After macular hole closure, the ELM appears before the IS/OS layer returns. In a study by Bottoni, et. al., there were no cases seen where there was a continuous IS/OS junction and a discontinuous ELM after macular hole closure (Bottoni, De Angelis et al. 2011). Early disruption of the ELM during the postoperative period may be indicative of a poor visual outcome (Shimozono, Oishi et al. 2011).

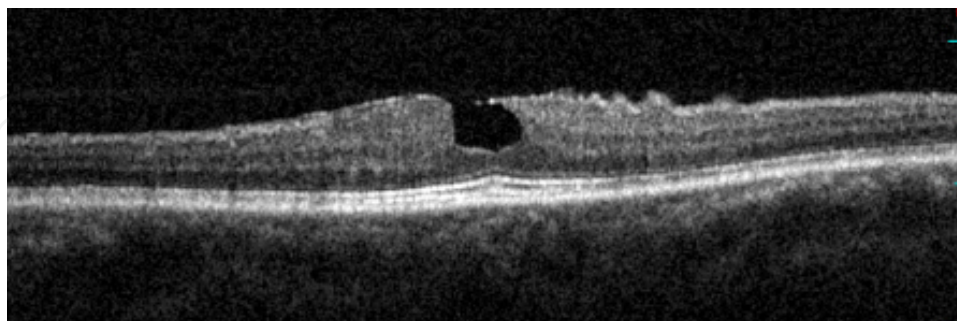
Despite the successful reapproximation of the photoreceptors during macular hole closure, the status of the IS/OS layer on OCT can still vary (Sano, Shimoda et al. 2009). When comparing the continuity or discontinuity of the IS/OS layer, a continuous IS/OS in the fovea was associated with better visual outcomes at 6 months. A discontinuous IS/OS layer appears to represent damaged and/or missing photoreceptor outer segments (Sano, Shimoda et al. 2009).

### 14. Masquerades and differential diagnosis

OCT has helped in differentiating macular holes from clinically similar diagnoses. Making the correct diagnosis is important and will determine the medical and surgical management of these conditions.

Pseudoholes from an ERM and lamellar holes may be difficult to distinguish from full thickness macular holes without the aid of OCT. On OCT, an overlying contracted epiretinal membrane may show the vertical edges of a pseudohole with the neurosensory retina still intact above the RPE. Pseudoholes from an ERM (Figure 18) are more likely to have normal central foveal thickness with thickened perifoveal retina compared to lamellar holes that

usually have a thinner and irregular center with normal perifoveal thickness (Haouchine, Massin et al. 2004).



**Figure 18.** 60 year old woman with an ERM and pseudohole and 20/50 vision.

Lamellar macular holes are not true holes. Instead, they consist of defects in the inner retina with varying degrees of foveal thinning (Yeh, Chen et al. 2010). OCT has greatly enhanced our ability to diagnose lamellar holes, especially in highly myopic eyes. (Tanaka, Shimada et al. 2011). Findings on OCT include a discontinuous inner retinal layer, splitting of the inner retinal layer, and an irregular foveal contour. Lamellar macular holes are believed in some cases to be the result of aborted macular holes. Inner retinal defects may be due to the rupture and subsequent loss of the roof of an inner cyst of a stage 1 macular hole (Yeh, Chen et al. 2010).

However, lamellar macular holes progressing to full thickness holes have occurred (Takahashi and Kishi 2000; Tanaka, Shimada et al. 2011). These lamellar macular holes tend to have a horizontal split between the inner and outer retina that emanate from the center (Haouchine, Massin et al. 2004).

In addition, OCT can quantify the extent of vitreofoveal traction and differentiate vitreomacular traction syndrome from stage 1A or stage 1B macular holes. Vitreomacular traction syndromes have a much broader based of vitreal-retinal adhesions compared to the focal areas of vitreal-foveal adhesions seen in stage 1A or 1B macular holes (Comander, Gardiner et al. 2011). Furthermore, OCT has helped in differentiating the yellow spot seen on biomicroscopy in stage 1A macular holes from the yellow spots seen in central serous chorioidopathy, ERM, or vitelliform dystrophy (Gass 1995).

Solar retinopathy can also have an appearance similar to a small full thickness macular hole. When solar retinopathy initially presents after solar exposure, it has the appearance of a yellow spot similar to what is seen in a stage 1A macular hole. Late findings in solar retinopathy involve a rectangular shaped outer retinal defect with straight edges that encompass an area from the RPE to the external limiting membrane. This outer retinal defect may be difficult to distinguish from a closed macular hole with a persistent similarly shaped outer retinal defect (Comander, Gardiner et al. 2011).

## 15. Conclusion

Our understanding of macular holes has come a long way from the initial descriptions by Gass to our current imaging with OCT. OCT has provided an in vivo ability to see changes in the retina that we were not able to obtain without histopathology. Correlating clinical findings, understanding the mechanism of macular hole formation and closure, and differentiating masquerades have been made possible with the aid of OCT technology.

## Author details

Robert J. Lowe<sup>1,2</sup> and Ronald C. Gentile<sup>1</sup>

1 The New York Eye and Ear Infirmary, New York, USA and New York Medical College, Valhalla, NY, USA

2 Kaiser Permanente Medical Group, Walnut Creek, California, USA

## References

- [1] Benhamou, N., P. Massin, et al. (2002). "Macular retinoschisis in highly myopic eyes." *Am J Ophthalmol* 133(6): 794-800.
- [2] Benzerroug, M., O. Genevois, et al. (2008). "Results of surgery on macular holes that develop after rhegmatogenous retinal detachment." *Br J Ophthalmol* 92(2): 217-219.
- [3] Bottoni, F., S. De Angelis, et al. (2011). "The dynamic healing process of idiopathic macular holes after surgical repair: a spectral-domain optical coherence tomography study." *Invest Ophthalmol Vis Sci* 52(7): 4439-4446.
- [4] Brooks, H. L., Jr. (2000). "Macular hole surgery with and without internal limiting membrane peeling." *Ophthalmology* 107(10): 1939-1948; discussion 1948-1939.
- [5] Chow, D. R., G. A. Williams, et al. (1999). "Successful closure of traumatic macular holes." *Retina* 19(5): 405-409.
- [6] Comander, J., M. Gardiner, et al. (2011). "High-Resolution Optical Coherence Tomography Findings in Solar Maculopathy and the Differential Diagnosis of Outer Retinal Holes." *Am J Ophthalmol*.
- [7] Coppe, A. M., G. Ripandelli, et al. (2005). "Prevalence of asymptomatic macular holes in highly myopic eyes." *Ophthalmology* 112(12): 2103-2109.
- [8] Dayani, P. N., R. Maldonado, et al. (2009). "Intraoperative use of handheld spectral domain optical coherence tomography imaging in macular surgery." *Retina* 29(10): 1457-1468.

- [9] Fabian, I. D., E. Moisseiev, et al. (2011). "Macular Hole After Vitrectomy for Primary Rhegmatogenous Retinal Detachment." *Retina*.
- [10] Frangieh, G. T., W. R. Green, et al. (1981). "A histopathologic study of macular cysts and holes." *Retina* 1(4): 311-336.
- [11] Funata, M., R. T. Wendel, et al. (1992). "Clinicopathologic study of bilateral macular holes treated with pars plana vitrectomy and gas tamponade." *Retina* 12(4): 289-298.
- [12] Gass, J. D. (1988). "Idiopathic senile macular hole. Its early stages and pathogenesis." *Arch Ophthalmol* 106(5): 629-639.
- [13] Gass, J. D. (1995). "Reappraisal of biomicroscopic classification of stages of development of a macular hole." *Am J Ophthalmol* 119(6): 752-759.
- [14] Gentile, R. C., G. Landa, et al. (2010). "Macular hole formation, progression, and surgical repair: case series of serial optical coherence tomography and time lapse morphing video study." *BMC Ophthalmol* 10: 24.
- [15] Haouchine, B., P. Massin, et al. (2004). "Diagnosis of macular pseudoholes and lamellar macular holes by optical coherence tomography." *Am J Ophthalmol* 138(5): 732-739.
- [16] Hayashi, A., T. Yagou, et al. (2011). "Intraoperative changes in idiopathic macular holes by spectral-domain optical coherence tomography." *Case Report Ophthalmol* 2(2): 149-154.
- [17] Ikuno, Y., K. Sayanagi, et al. (2003). "Optical coherence tomographic findings of macular holes and retinal detachment after vitrectomy in highly myopic eyes." *Am J Ophthalmol* 136(3): 477-481.
- [18] Johnson, R. N. and J. D. Gass (1988). "Idiopathic macular holes. Observations, stages of formation, and implications for surgical intervention." *Ophthalmology* 95(7): 917-924.
- [19] Johnson, R. N., H. R. McDonald, et al. (2001). "Traumatic macular hole: observations, pathogenesis, and results of vitrectomy surgery." *Ophthalmology* 108(5): 853-857.
- [20] Jumper, J. M., R. P. Gallemore, et al. (2000). "Features of macular hole closure in the early postoperative period using optical coherence tomography." *Retina* 20(3): 232-237.
- [21] Kang, S. W., K. Ahn, et al. (2003). "Types of macular hole closure and their clinical implications." *Br J Ophthalmol* 87(8): 1015-1019.
- [22] Kelly, N. E. and R. T. Wendel (1991). "Vitreous surgery for idiopathic macular holes. Results of a pilot study." *Arch Ophthalmol* 109(5): 654-659.
- [23] Kobayashi, H., K. Kobayashi, et al. (2002). "Macular hole and myopic refraction." *Br J Ophthalmol* 86(11): 1269-1273.

- [24] Lee, S. H., K. H. Park, et al. (2010). "Secondary macular hole formation after vitrectomy." *Retina* 30(7): 1072-1077.
- [25] Lee, S. W., S. W. Kang, et al. (2011). "Vitreous surgery for impending macular hole." *Retina* 31(5): 909-914.
- [26] Lois, N., J. Burr, et al. (2011). "Internal limiting membrane peeling versus no peeling for idiopathic full thickness macular hole: a pragmatic randomized controlled trial." *Invest Ophthalmol Vis Sci* 52(3): 1586-1592.
- [27] Masuyama, K., K. Yamakiri, et al. (2009). "Posturing time after macular hole surgery modified by optical coherence tomography images: a pilot study." *Am J Ophthalmol* 147(3): 481-488 e482.
- [28] McCannel, C. A., J. L. Ensminger, et al. (2009). "Population-based incidence of macular holes." *Ophthalmology* 116(7): 1366-1369.
- [29] McDonnell, P. J., S. L. Fine, et al. (1982). "Clinical features of idiopathic macular cysts and holes." *Am J Ophthalmol* 93(6): 777-786.
- [30] Menchini, U., G. Virgili, et al. (2003). "Mechanism of spontaneous closure of traumatic macular hole: OCT study of one case." *Retina* 23(1): 104-106.
- [31] Nishimura, A., M. Kimura, et al. (2011). "Efficacy of primary silicone oil tamponade for the treatment of retinal detachment caused by macular hole in high myopia." *Am J Ophthalmol* 151(1): 148-155.
- [32] Oster, S. F., F. Mojana, et al. (2010). "Dynamics of the macular hole-silicone oil tamponade interface with patient positioning as imaged by spectral domain-optical coherence tomography." *Retina* 30(6): 924-929.
- [33] Park, D. W., J. O. Sipperley, et al. (1999). "Macular hole surgery with internal-limiting membrane peeling and intravitreal air." *Ophthalmology* 106(7): 1392-1397; discussion 1397-1398.
- [34] Patel, S. C., R. H. Loo, et al. (2001). "Macular hole surgery in high myopia." *Ophthalmology* 108(2): 377-380.
- [35] Sano, M., M. Inoue, et al. (2011). "Ability to determine postoperative status of macular hole in gas-filled eyes by spectral domain-optical coherence tomography." *Clin Experiment Ophthalmol*.
- [36] Sano, M., Y. Shimoda, et al. (2009). "Restored photoreceptor outer segment and visual recovery after macular hole closure." *Am J Ophthalmol* 147(2): 313-318 e311.
- [37] Shimada, N., K. Ohno-Matsui, et al. (2006). "Natural course of macular retinoschisis in highly myopic eyes without macular hole or retinal detachment." *Am J Ophthalmol* 142(3): 497-500.

- [38] Shimozono, M., A. Oishi, et al. (2011). "Restoration of the photoreceptor outer segment and visual outcomes after macular hole closure: spectral-domain optical coherence tomography analysis." *Graefes Arch Clin Exp Ophthalmol*.
- [39] Sun, C. B., Z. Liu, et al. (2010). "Natural evolution from macular retinoschisis to full thickness macular hole in highly myopic eyes." *Eye (Lond)* 24(12): 1787-1791.
- [40] Takahashi, A., T. Nagaoka, et al. (2010). "Foveal anatomic changes in a progressing stage 1 macular hole documented by spectral-domain optical coherence tomography." *Ophthalmology* 117(4): 806-810.
- [41] Takahashi, A., T. Nagaoka, et al. (2011). "Stage 1-A macular hole: a prospective spectral-domain optical coherence tomography study." *Retina* 31(1): 127-147.
- [42] Takahashi, H. and S. Kishi (1999). "Optical coherence tomography images of spontaneous macular hole closure." *Am J Ophthalmol* 128(4): 519-520.
- [43] Takahashi, H. and S. Kishi (2000). "Tomographic features of a lamellar macular hole formation and a lamellar hole that progressed to a full thickness macular hole." *Am J Ophthalmol* 130(5): 677-679.
- [44] Takahashi, H. and S. Kishi (2000). "Tomographic features of early macular hole closure after vitreous surgery." *Am J Ophthalmol* 130(2): 192-196.
- [45] Takano, M. and S. Kishi (1999). "Foveal retinoschisis and retinal detachment in severely myopic eyes with posterior staphyloma." *Am J Ophthalmol* 128(4): 472-476.
- [46] Tanaka, Y., N. Shimada, et al. (2011). "Natural history of lamellar macular holes in highly myopic eyes." *Am J Ophthalmol* 152(1): 96-99 e91.
- [47] Tornambe, P. E., L. S. Poliner, et al. (1998). "Definition of macular hole surgery end points: elevated/open, flat/open, flat/closed." *Retina* 18(3): 286-287.
- [48] Weichel, E. D. and M. H. Colyer (2009). "Traumatic macular holes secondary to combat ocular trauma." *Retina* 29(3): 349-354.
- [49] Wendel, R. T., A. C. Patel, et al. (1993). "Vitreous surgery for macular holes." *Ophthalmology* 100(11): 1671-1676.
- [50] Wu, T. T. and Y. H. Kung (2011). "Comparison of anatomical and visual outcomes of macular hole surgery in patients with high myopia vs. non-high myopia: a case-control study using optical coherence tomography." *Graefes Arch Clin Exp Ophthalmol*.
- [51] Yamada, H., A. Sakai, et al. (2002). "Spontaneous closure of traumatic macular hole." *Am J Ophthalmol* 134(3): 340-347.
- [52] Yamashita, T., A. Uemura, et al. (2002). "Spontaneous closure of traumatic macular hole." *Am J Ophthalmol* 133(2): 230-235.
- [53] Yeh, P. T., T. C. Chen, et al. (2010). "Formation of idiopathic macular hole-reappraisal." *Graefes Arch Clin Exp Ophthalmol* 248(6): 793-798.

- [54] Yuzawa, M., A. Watanabe, et al. (1994). "Observation of idiopathic full thickness macular holes. Follow-up observation." *Arch Ophthalmol* 112(8): 1051-1056.

IntechOpen

IntechOpen

