

We are IntechOpen, the world's leading publisher of Open Access books Built by scientists, for scientists

6,900

Open access books available

185,000

International authors and editors

200M

Downloads

Our authors are among the

154

Countries delivered to

TOP 1%

most cited scientists

12.2%

Contributors from top 500 universities



WEB OF SCIENCE™

Selection of our books indexed in the Book Citation Index
in Web of Science™ Core Collection (BKCI)

Interested in publishing with us?
Contact book.department@intechopen.com

Numbers displayed above are based on latest data collected.
For more information visit www.intechopen.com



Lumbar Intervertebral Disc Endoscopy

Ștefan Cristea, Florin Groseanu,
Andrei Prundeanu, Dinu Gartonea, Andrei Papp,
Mihai Gavrilă and Dorel Bratu

Additional information is available at the end of the chapter

<http://dx.doi.org/10.5772/54544>

1. Introduction

Unlike any other arthroscopic procedure this doesn't rely on the existence of a distension liquid or gaseous medium. In fact we visualize more or less bleeding regions that cannot be distended [6], [7].

The procedure is mini-invasive and it addresses to the herniated intervertebral lumbar disc.

Because of the evolution of the human species, the development of the vertebral curves, the standing position, the dehydration of the intervertebral disc, the degeneration processes following aging discal suffering occurs. The most frequent form is the lumbar herniated disc mainly located in the L4-L5 and L5-S1 motion segments [1], [3].

2. Anatomical features of the lumbar spine

2.1. Functional spinal unit (FSU) or motion segment

A functional spinal unit (FSU) is the smallest physiological motion unit of the spine to exhibit biomechanical characteristics similar to those of the entire spine (Fig. 1). A FSU consists of two adjacent vertebrae, the intervertebral disc and all adjoining ligaments between them and excludes other connecting tissues such as muscles. The intervertebral ligaments are (anterior to posterior): anterior longitudinal ligament, posterior longitudinal ligament, facet capsular ligaments, interspinous ligament, ligamentum flavum (yellow ligament), and supraspinous ligament.

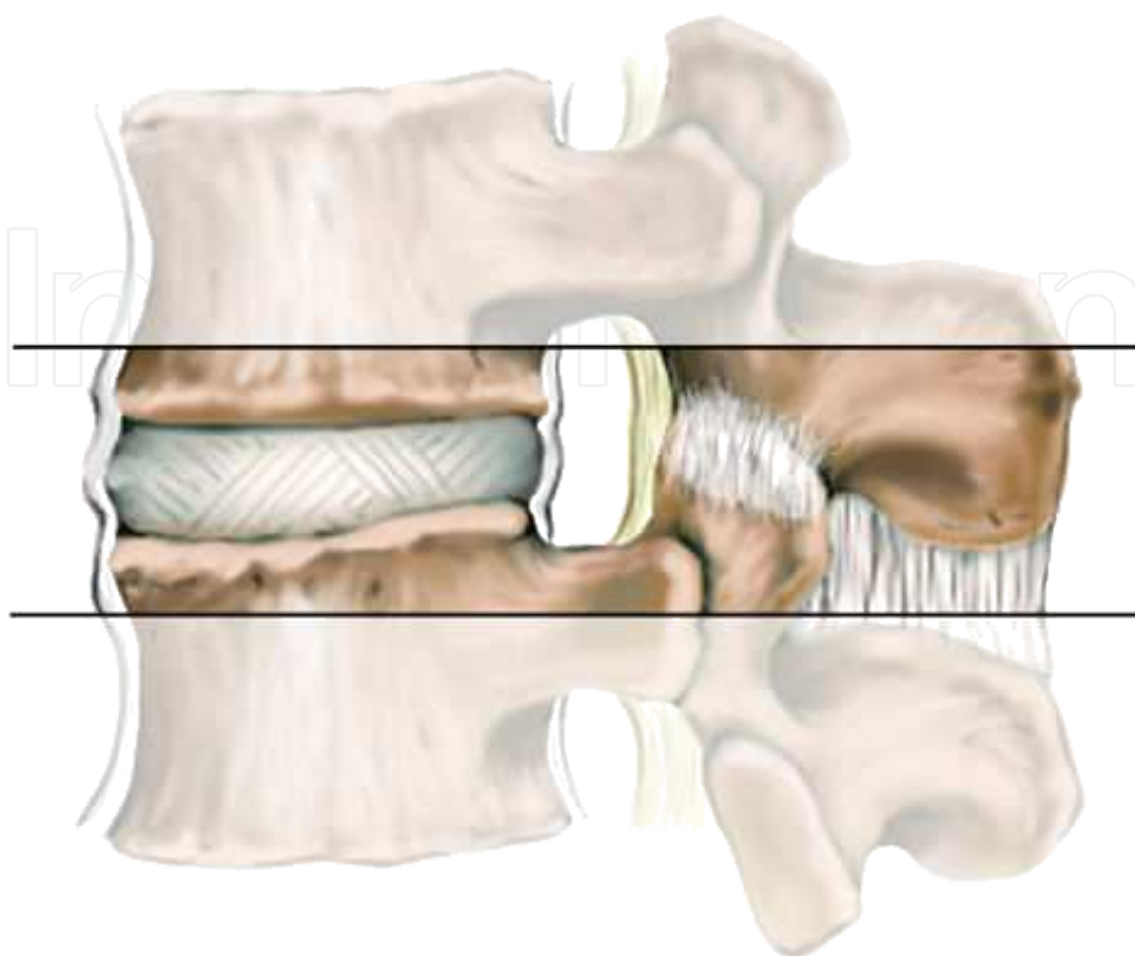


Figure 1. Motion segment (FSU) [1],[5],[11]

Another term for the FSU is spinal motion segment.

Each intervertebral motion segment displays the following movements:

- inclination of one vertebra to the other
- slip
- axial rotation.

So the movements are:

- Flexion – extension
- Axial rotation
- Lateral inclination left – right of one vertebra to the other

The motion segments are specialized for a certain type of motion, depending on the anatomical region. All the lumbar pieces realize 10° - 15° of axial rotation, 80° of flexion – extension, 30° of lateral inclination [2],[11].

The areas where the curves are reversed, where there are areas of different mobility are the election site of the traumatic lesions, especially in the lumbo-sacral region. Demand is very high in the L5 disc from the changing of the region of motion and curves – lumbar lordosis over the sacrococcygeal piece kyphosis. The upper plateau of the sacrum is 30° - 60° inclined from horizontal. Lumbar lordosis curvature is quite opposite to the sacro-coccygeal curvature. All the weight above the lumbosacral level is cushioned by the L5 disc and then successively gradually by L4, L3... These stresses are exacerbated naturally in human by standing and sitting positions. These are added to the repeated stresses by bending, weight lifting, falls from height. Gradually with age, biochemical changes occur, dehydration, responsible for degenerative lesions at these levels.

2.2. The intervertebral discs

The intervertebral discs in the lumbar region are at least 10 mm thick representing a third of the lumbar vertebral body height.

The vertebral discs form one of the anterior aspects of the vertebral foramen and as the spinal nerves pass through the foramen they are just behind the corresponding discs. In addition, the discs take part in the anterior wall of the vertebral canal thus any posterior herniation of the disc can compress the spinal cord and the corresponding spinal nerves.

Every disc is structurally characterized by three structures: the central nucleus pulposus, the annulus fibrosus and the cartilaginous end plates. The disc is anchored to the vertebral body by the fibres of the annulus fibrosus and the cartilaginous endplates.

The nucleus pulposus consists of soft tissue, highly hydrophilic, placed in the centre of the disc. There is not a clear separation between the nucleus pulposus and the annulus fibrosus, the main difference being the density of the fibres, the nucleus having large extrafibrillar spaces with a highly glycosaminoglycan content which allows the water retention. The nucleus pulposus position varies from a region to other, being more posterior in the lumbar region. Its position is related with several functional aspects.

The nucleus pulposus consists of a tridimensional network of collagen fibres embedded in a highly hydrated proteoglycan containing gel. The loss of this proteoglycan gel with aging decreases the water content until, in the advanced degenerated discs, the total loss of proteoglycan. This is the major change accompanying the dehydration with age. At the beginning of life the water content is 80-88% and it decreases to 70% in the fourth decade. Loss of proteoglycan and matrix disorganization has other important mechanical effects; because of the subsequent loss of hydration, degenerated discs no longer behave hydrostatically under load.

The annulus fibrosus is located at the outer disc. This is made up of a series of concentric rings called lamellae, with the collagen fibers lying parallel within each lamella. The fibers are oriented at approximately 30° to the horizontal axis, alternating to the left and to the right of it in adjacent lamellae, thus resulting in a 120° change in angle between plans (Fig. 2). These have a special role, with different tensioning, in the mobility and determine an increased resistance. The structure is similar to a tire sustaining high forces of compression, torsion and traction [1], [5], [11].

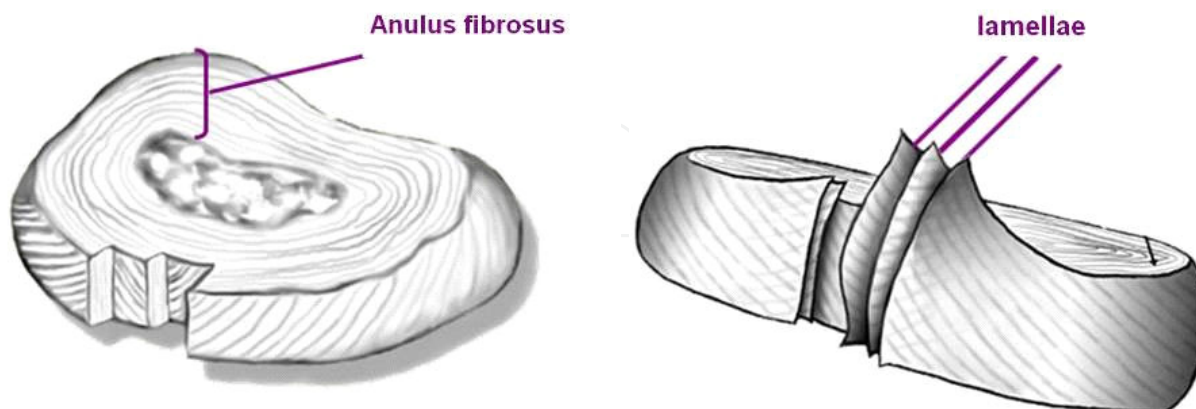


Figure 2. Intervertebral disc structure [1],[5],[11]

The density of the fibro-cartilaginous lamellae varies according to the place in the annulus fibrosus, thus being denser anteriorly and posteriorly than on the lateral sides. The lamellae do not form complete circles, but they divide themselves or merge with each other to connect with other strips. The postero-lateral region of the annulus tends to be more irregular and less ordered. With age, the structure of the annulus becomes weaker in this area predisposing to the herniation of the nucleus.

Elastin fibers are also found in the composition of the nucleus pulposus and of the annulus fibrosus. In the annulus they are disposed circularly, obliquely and vertically.

The annulus attachment to the vertebrae is made by passing over the edges of the cartilage endplates and then goes up beyond the compact bone and the edges of adjacent vertebral body and its periosteum, forming stable connections between adjacent vertebral bodies. These perforating fibers are interwoven with fibrillar lamellae of trabecular bone.

According to Modic [10], the altered signal intensity detected by MR imaging is not, in and of itself, the causal pathologic process but rather a reflection of the causal process, which is some type of biomechanical stress or instability. A formal classification was subsequently provided by Modic et al in 1988 [10], based on a study of 474 patients, most of whom had chronic low back pain (LBP). These authors described 2 types of endplate and marrow changes: Type 1 changes were hypointense on T1-weighted imaging (T1WI) and hyperintense on T2-weighted imaging (T2WI) and were shown to represent bone marrow edema and inflammation (Fig.3).

Type 2 changes were hyperintense on T1WI and isointense or slightly hyperintense on T2WI and were associated with conversion of normal red hemopoietic bone marrow into yellow fatty marrow as a result of marrow ischemia (Fig.4).

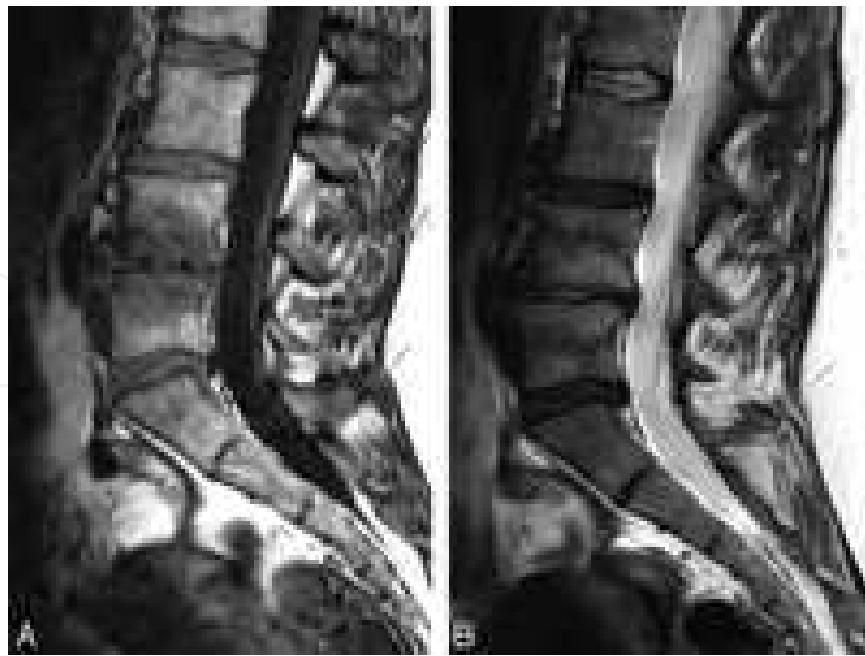


Figure 3. Modic type 1 changes are hypointense on T1WI (A) and hyperintense on T2WI (B).

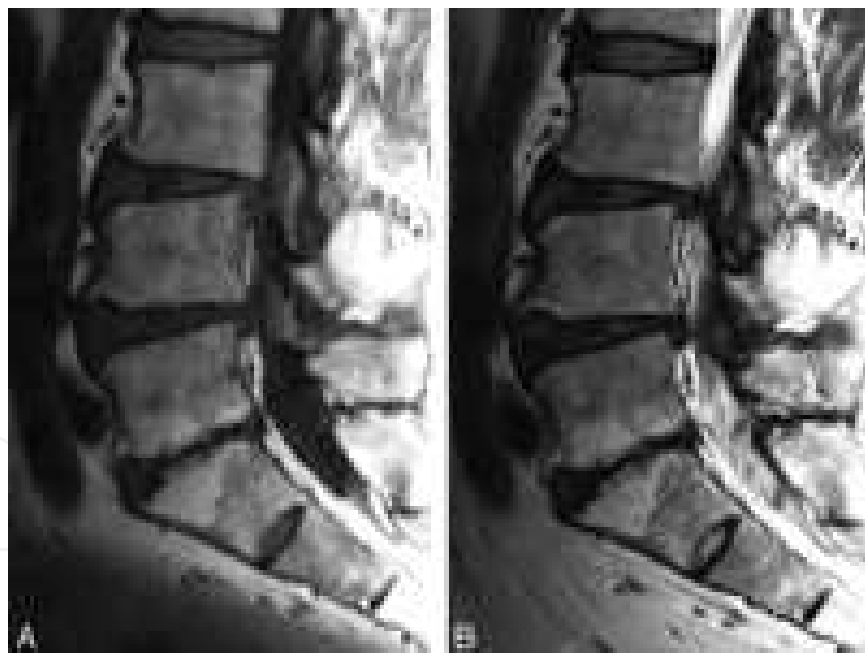

Figure 4. Modic type 2 changes are hyperintense on T1WI (A) and isointense or hyperintense on T2WI (B).

Modic type 3 changes were subsequently described as hypointense on both T1WI and T2WI and were thought to represent subchondral bone sclerosis. Mixed-type 1/2 and 2/3 Modic changes have also been reported, suggesting that these changes can convert from one type to another and that they all represent different stages of the same pathologic process. The absence

of Modic changes, a normal anatomic appearance, has often been designated Modic type 0 (Fig.5).

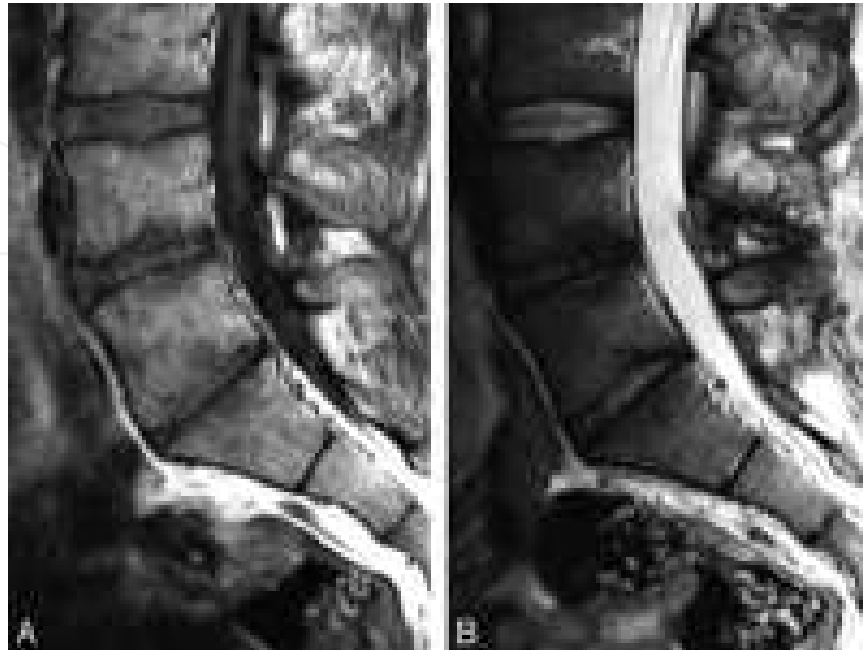


Figure 5. Modic type 3 changes are hypointense on both T1WI (A) and T2WI (B).

2.3. Ligaments

Vertebral bodies are secured together by the longitudinal ligaments that extend the whole length of the spine. The ligaments are multifunctional and bind the osseous pieces together. They protect the vertebral column and the nevrax from injuries. They are multilayered, composed of elastin and collagen fibers. Ligaments do not oppose compressive forces. They limit the range of every motion for not exceeding the physiological limits.

There are seven ligaments attached (Fig.6) to the motion segment:

1. Anterior longitudinal ligament
2. Posterior longitudinal ligament
3. Yellow ligament (ligamentum flavum)
4. Facet capsulary ligaments
5. Intertransverse ligament
6. Interspinous ligament
7. Supraspinous ligament

Degenerative ligament lesions reduce the range of motion between two adjacent vertebral pieces. On the other hand, excessive ligament tension may result in abnormal segmental

movement as it happens in young gymnasts and acrobats. This abnormality can produce degenerative lesions, osteofites that can cause canal stenosis [1], [3], and [13].

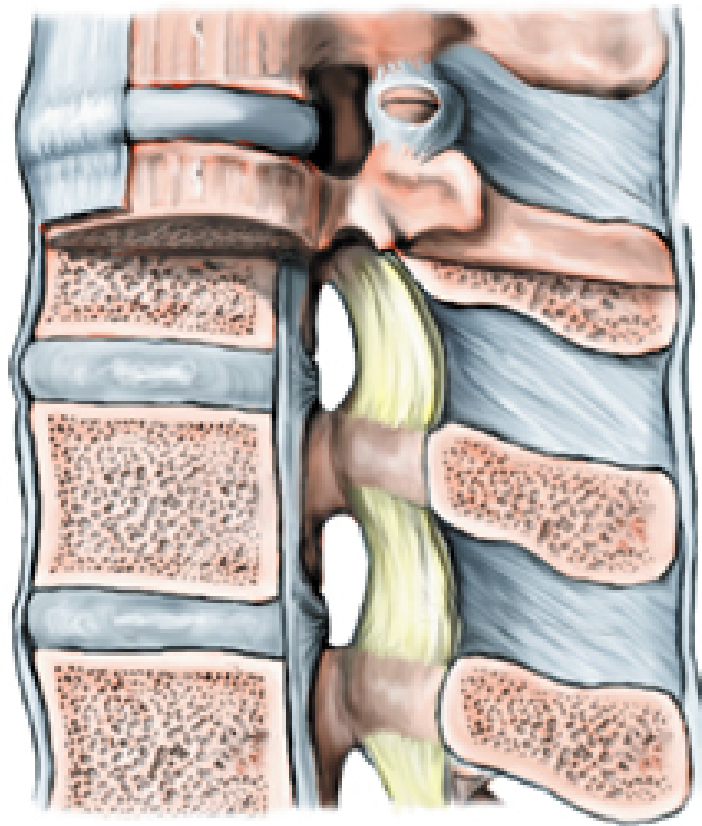


Figure 6. Motion segment ligaments [1],[5],[11]

2.4. Spinal nerve structures, Meninges

As part of the Central Nervous System (CNS), the spinal cord is located immediately below the brain stem and extends from the foramen magnum to L1.

At L1 the spinal cord terminates as the conus medularis. Below L1, the thick but flexible dural sac contains the spinal nerves collectively known as the cauda equina.

Also contained within the cauda equina is the filum terminale, which extends from the conus medularis to the coccyx and acts as an anchor to keep the lower spinal cord in its normal shape and position.

The individual nerve roots of the cauda equina are suspended in spinal fluid. At this level, it is possible to pass a needle safely into the thecal sac for evaluation of spinal fluid or injection of various materials such as drugs, anesthetics, or radiologic substances.

Within the spinal canal, the spinal cord is surrounded by the epidural space. This space is filled with fatty tissue, veins, and arteries. The fatty tissue acts as a shock absorber and keeps the spinal cord away from the bony tissue of the vertebrae.

The brain and spinal cord are covered by three layers of material called meninges. The main function of these layers is to protect and feed the delicate neurological structures (Fig. 7).

The dura mater is the outermost meningeal layer and is made up of strong connective tissue. The dura mater, also called the dura, is gray in color and is generally easy to identify within the spinal canal. The dura extends around each nerve root and becomes contiguous with the epineurium, a membrane covering the spinal nerves.

The subdural space is a very small space between the dura and the next meningeal layer, the arachnoid layer. The arachnoid layer is highly vascularized with a web of arteries and veins that give the impression of a spider web. It is thinner than the dura and is subject to injury.

Below the arachnoid layer is the subarachnoid space, which is filled with cerebrospinal fluid (CSF). The CSF helps to protect the nerve structures by acting as a shock absorber. It also contains various electrolytes, proteins, and glucose. A spinal tap can be inserted into the subarachnoid space to retrieve CSF for various chemical analyses.

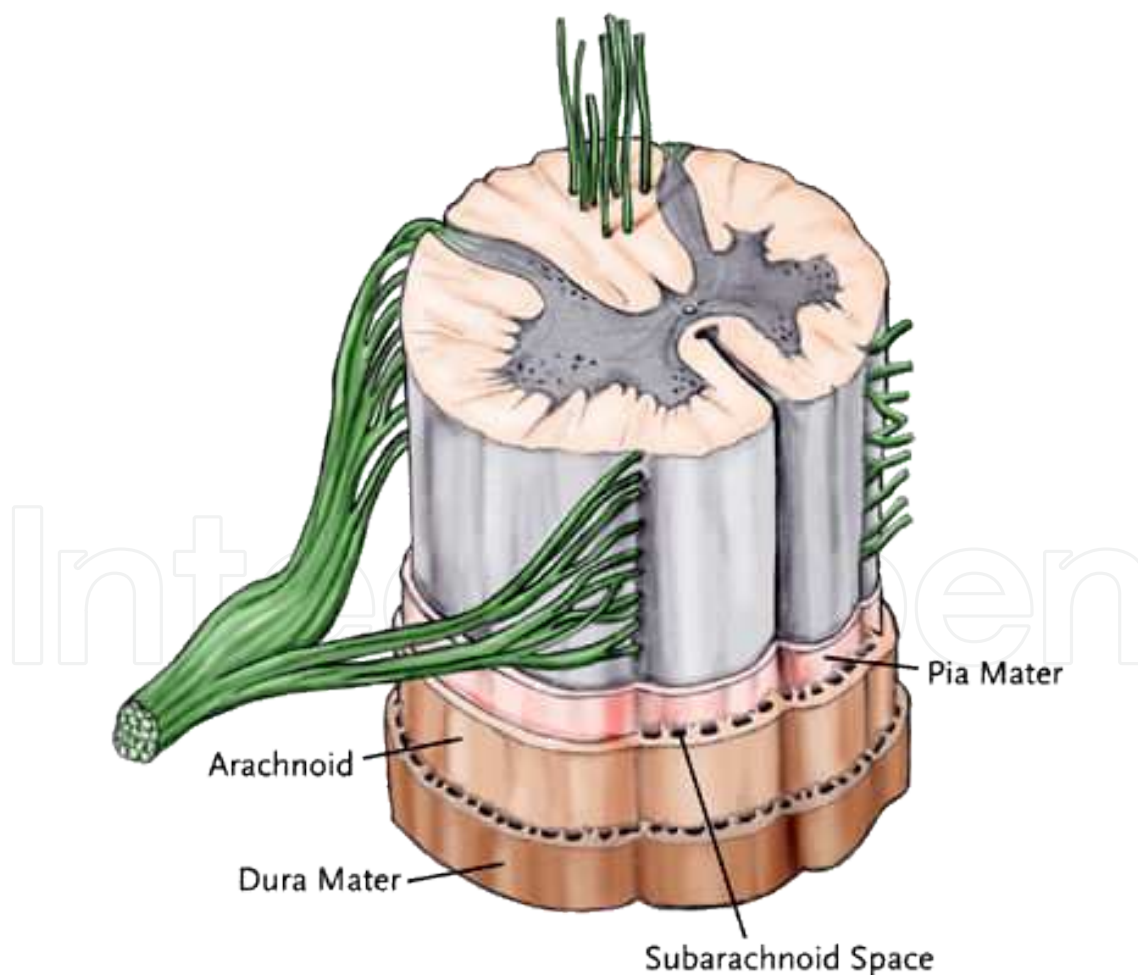


Figure 7. Meningeal structure [1],[5],[11]

The innermost lining of the meninges is called the pia mater. It is closely adhered to the spinal cord and the individual nerve roots. It is highly vascular and gives blood supplies to the neurological structures [1], [3], and [13].

2.5. Topography

There are 31 pairs of spinal nerves: 8 cervical, 12 thoracic, 5 lumbar, 6 sacrococcygeal. The first cervical nerve root exits between the skull (C0) and C1. The 8th cervical nerve root exits between C7 and T1. Thereafter, all nerve roots exit at the same level as the corresponding vertebrae. For example, the L1 nerve root exits between L1 and L2.

The nerve roots emerge from the spinal cord higher than their actual exit through the intervertebral foramen. This means that the spinal nerves must often pass downwards adjacent to the spinal cord before exiting through the intervertebral foramen. This leaves the nerves exposed to risk of compression by protruding disc material. Therefore, it is possible to have a compression of the L5 nerve root at the L4-L5 disc space.

Each spinal nerve root has both motor nerves and sensory nerves. Motor nerves conduct information and orders from the brain to the peripheral nervous system to excite a muscular contraction. Sensory nerves receive information from the periphery (skin, fasciae, tendons, ligaments, muscles) and send the information towards the brain.

Motor fibers are located on the anterior aspect of the spinal cord. Multiple filaments of motor fibers are called ventral roots or anterior roots. The cell bodies or control centers of the motor nerve roots are located within the spinal cord. Damage or injury to the anterior roots or motor cell bodies may result in the loss of musculoskeletal function.

Sensory fibers are located on the posterior aspect of the spinal cord. Each collection of sensory fibers is called a dorsal root or posterior root. The sensory nerves have a special accumulation of cell bodies called the dorsal root ganglia. The ganglia are the control centers of the sensory nerves and are located outside but close to the spinal cord. Just beyond the ganglia, the anterior and posterior roots become joined in a common dural sheath. It is at this point that the peripheral nerve is formed [4], [11].

2.6. Vascularization and innervations

The spinal column receives segmental arterial vascularization from the adjacent vessels: for the lumbar region from lumbar and iliolumbar arteries and for the pelvic region from lateral sacral arteries. All these branches anastomose and give anterior and posterior spinal arteries that irrigate the marrow.

It is interesting that the intervertebral disc is a poorly vascularized structure. It receives nutrition by passive diffusion through the central vertebral endplates.

The vascularisation of the vertebral body is different in its structure. The most poorly vascularized region is adjacent to the disc. As we approach the central area it becomes more vascularized. The central region can be divided into a nutritive artery vascularized area and a metaphyseal arteries vascularized area. The peripheral region is vascularized by short peripheral

arteries. Oxygenation and metabolic feeding of the disc is regional and determines the lamellae and fibrous ring arrangement. Fluid located between the blades is channeled vertically. Frequent movement of blades may increase the diffusion. One of the aging consequences is arterial occlusion and diminished blood flow.

Diminished blood flow at the delicate lumbar arteries, especially at the fifth pair, through aging and occlusion by disc compression, explains the degenerative pathology of the L5 disc.

The veins form communicative plexuses all along the spine. The plexuses drain in the lumbar and the lateral sacral veins. The internal vertebral plexuses form a continuous network between the dura mater and the vertebral canal walls. Two anterior branches, one on each side of the posterior longitudinal ligament make an anastomosis in front of the ligament and receive the basivertebral vein. They are interconnected with the basilar and occipital sinuses. Internal posterior plexuses merge lamella and the yellow ligaments level. There are anterior and posterior communications between the internal and external plexuses.

The Azygos system communicates with a valveless venous network known as Batson's plexus, or Crock veins (Fig.8). When the vena cava is partially or totally occluded, Batson's plexus provides an alternate route for blood return to the heart. Because of the azygos system, patient positioning is very important in posterior lumbar spine surgery. The patient's abdomen should always hang free and without abdominal pressure. An increase in pressure will diminish flow through the azygos system and the vena cava. This results in an increase of venous flow into Batson's plexus with a corresponding increase of blood loss. Furthermore, increased bleeding makes it difficult to visualize the spinal cord, nerve roots, and disc during surgery. The vessels of Batson's plexus may be referred to as epidural veins and are often cauterized during posterior interbody procedures. However, these vessels are difficult to identify and cauterize, even when there is no increased abdominal pressure.

Innervation of the intervertebral disc, ligament structures and fibrous connective tissue of the spinal canal, has great clinical importance. It is provided by a recurrent nerve, the sinuvertebral nerve. In many ways it can be considered equivalent to the recurrent meningeal branch of the cranial nerves. It has dual origin from spinal nerves and sympathetic system. The spinal part arises distal to the dorsal root ganglion and reenter the spinal canal reaching back into the median, then gives rise to discal branches, for the disc above and below. At the same time innervates the medial facet of the interapofizal joint capsule. C and A- δ fibers are involved in pain transmission, these structures explain the pain caused by compression of the anterior and posterior nerve fibers on the periphery of the ring [1],[4],[13].

2.7. Important anatomical related structures

It should be noted that the spinal cord ends at the disc between L1 - L2. Below this level is cauda equina (horse tail), covered by meninges to the S2.

Anterior to the lumbar vertebrae are the large abdominal vessels – the aorta and vena cava.

The aorta bifurcates into the common iliac arteries at L4 level. Here also the origins of the middle sacral artery and branches of the iliolumbar artery from the internal iliac artery. These arteries irrigate L5 and the sacrococcygeal area.

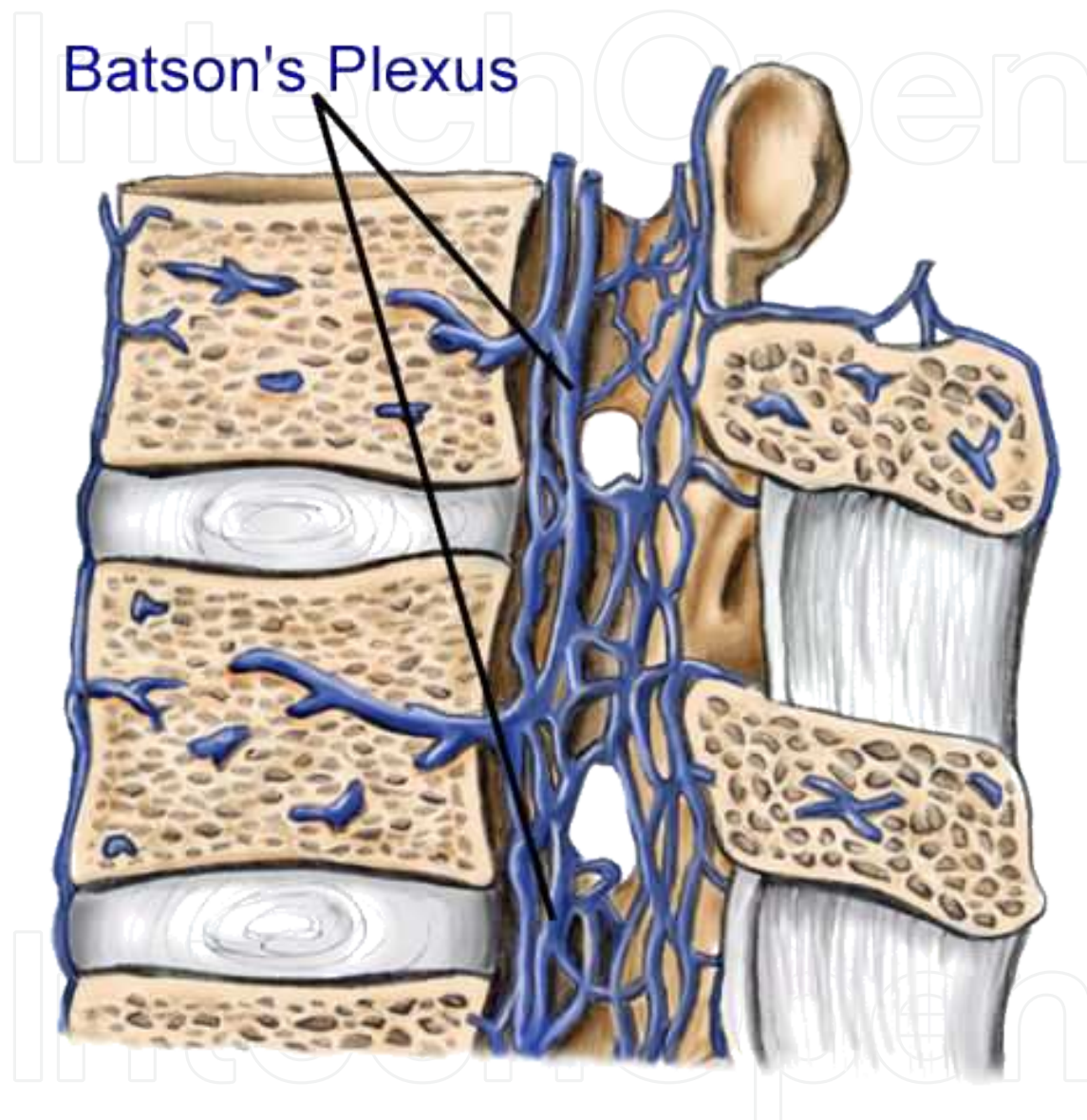


Figure 8. Venous vascularisation [1],[5],[11]

Vena cava originates at the level of L4, by the convergence of left and right common iliac vein. It is located on the right side of the spine, going through the abdomen and thorax to the heart. Common iliac veins results from internal and external iliac veins. The iliac veins can be injured during the anterior arthrodesis of L3-L4 and L4-L5. The common iliac veins are thick and strong but the iliac veins are thin and sinuous and special attention should be taken with the surgical gestures near them.

The endoscopic surgery must take account of these relationships because if the iliac vessels are damaged it is hard to obtain haemostasis. The surgery must be converted into a classical open one.

The second lumbar vertebrae have contact with the kidneys in the lateral-superior side and more anteriorly with the digestive tube.

At lumbar level the posterior paravertebral muscles are well represented and the thoracolumbar fascia is thick and strong.

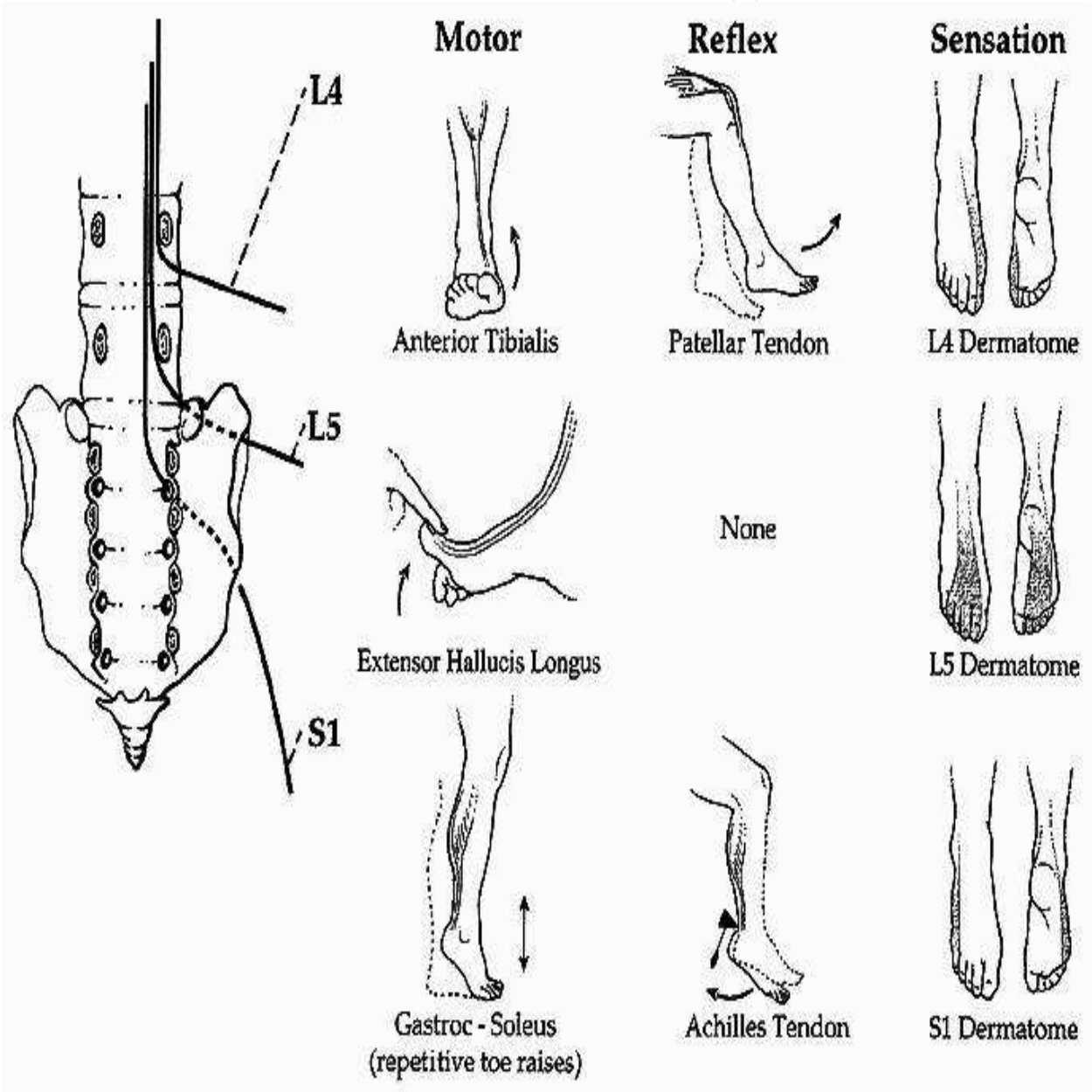


Figure 9. L4S1-Nerve roots

Endoscopic surgery must be performed only after complete and qualified clinical examination (Fig.9), followed by postero-anterior and lateral view X-rays, CT and MRI exam with Modic [10] stage classification of the modified disc.

3. History

In 1934 Mixer and Barr accomplished the first discectomy by hemilaminectomy; in 1948 Ottolenghi performed a vertebral puncture. The first decompression of the vertebral disc by dorsal approach was made by Kabin in 1973. In 1975 the first percutaneous nucleotomy was performed by Hihikata using fine cannulae. In 1976 HJ Leu accomplished the puncture of the disc by dorsolateral approach, using in the same manner two long and fine cannulae with trocar [5],[9],[12].

Our days the newly endoscopic device was developed based on the ordinary arthroscope with 0 degree telescope in 1994, by French neurosurgeon Jean Desandau [6],[7], on the principle of microsurgery, then taken over and improved by the Storz Company in 2004.

The first endoscopy of a lumbar disc hernia in Romania was performed in 2005 [5].

4. Indications for treatment [5], [6], [7]

Basically 90-95% of all disc lesions are successfully treated by conservatory means. Only 5-10 % of lesions who do not respond to conservative treatment will be surgically treated.

The conservative treatment is used between a minimum of 4-6 weeks and a maximum of 3-6 months. It consists of relative resting on a hard bed, flexing the hips and the knees for relaxation in hyperlordosis, administering non steroidal anti-inflammatory drugs accompanied by gastric protection, muscle relaxers, anti-inflammatory and decontracting physiotherapy, epidural anaesthesia, and possible vertebral manipulations with the mechanical reinsertion of the disc.

The treatment is applied gradually, progressively, and after the decrease of pain we can try medical gymnastics for toning the paravertebral and abdominal muscles.

If the conservative treatment was applied correctly without a response from the patient, we will intervene more aggressively.

4.1. The surgical options are numerous:

- percutaneous discectomy
- chemonucleolysis using chemopapain
- automated percutaneous lumbar suction discectomy, like laser disc decompression – suction and intervertebral decompression, reducing the pressure will momentarily diminish the pain, followed by the aggravation of the degenerative symptoms, producing advanced

of arthrosis to the interapophyseal and intra-articular joints with the posterior segment actually bearing the overweight.

- Microscopic discectomy
- Intervertebral endoscopy
- radiofrequency techniques
- electrotermical interdiscal therapy
- limited laminectomy
- percutaneous intersomatic arthrodesis PLIF - TLIF - ALIF + BMP / growth factors + computer guided surgery
- artificial disc
- morfogenic biological Bone solutions protein BMP / growth factors

Technically the **surgical indications** are:

1. onset of sphincter disorders
2. paresis – motor weakness
3. increased conduction velocity of nerve root
4. the persistence/increased pain although it is properly treated for 4 weeks
5. recurrence of pain after a period of relief

5. Indications for lumbar disc endoscopy

Basically one can successfully intervene in any phase (subligamentar protrusive or extrusive or transligamentar) of discopathy without borders. Furthermore in the lumbar canal stenosis the canal can be endoscopically recalibrated even in cases of sequestration of the herniated disc, also for foraminal hernia.

Most authors perform a partial ablation of the herniated material, similarly to an arthroscopic meniscectomy.

The endoscopic approaches are:

- dorsal approach – the most popular
- ventral approach
- postero-lateral approach
- lateral approach

The dorsal endoscopic approach is derived from the intervertebral dorsal approaches for laminectomy performed by neurosurgeons and orthopaedists in the surgical treatment of the herniated disc.

The approach used is intraseptal paraspinous described by Wiltze in 1988. An interlaminar window is created through foraminectomy.

The equipment was developed based on the ordinary arthroscope with 0 degree telescope, by French neurosurgeon Jean Desandau [6], [7], on the principle of microsurgery, later improved by Storz Inc (Fig.10).

The surgeon's training should be complex and requires a learning curve.

Occasionally the discal endoscopy could be converted into classical surgery due to possible complications or for transpedicular stabilization.

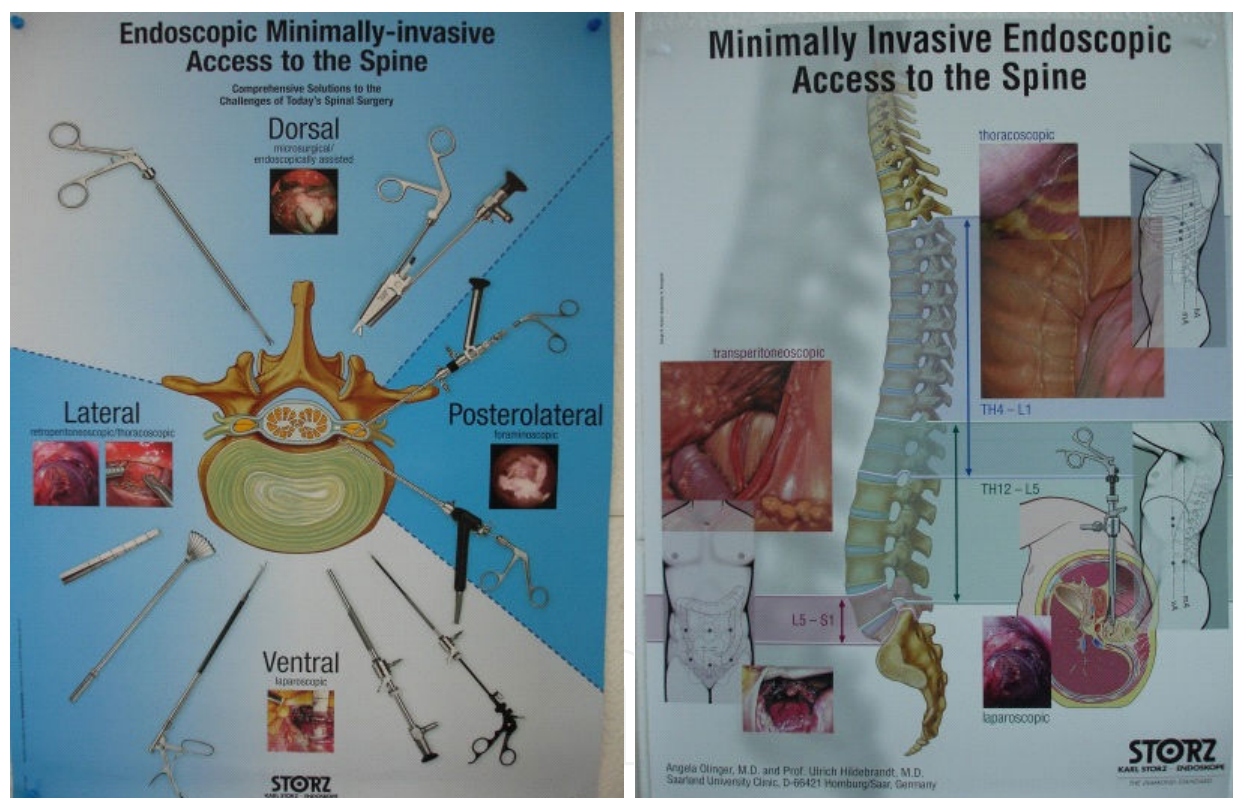


Figure 10. Endoscopic MIS approaches

5.1. Patient positioning

The patient under general anesthesia is in prone position on a radiotransparent surgical table. The level for the surgical approach is established by clinical and radiological criteria. Using special cushions the abdominal pressure is released, the cava pressure is released, the hips and the knees are in hyperflexion so that the intervertebral spaces are opened along with the hy-

perflexion of the lumbar spine. Thus the bone resection is kept to a minimum and the migrated disc can be reached (Fig11).

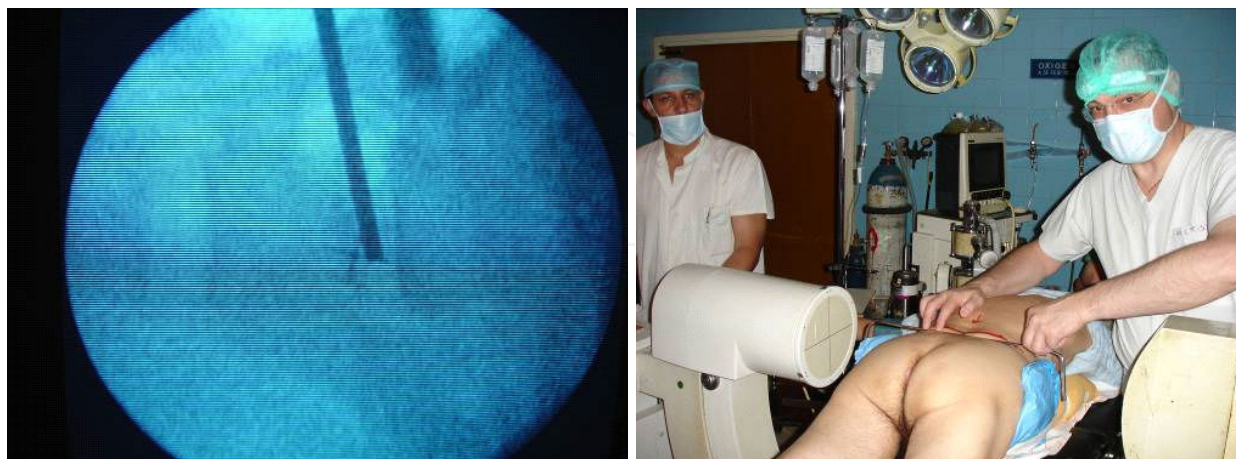


Figure 11. Fluoroscopic guidance – landmark of the level for the surgical approach

5.2. Surgical technique

The approach is similar to classic discal surgery. A local anesthetic is infiltrated to decrease bleeding. A paravertebral 3 cm incision is performed on the migrated disc's side, shown by the CT and MRI exams, followed by a lateral paravertebral muscle dissection. Haemostatic compresses are inserted at both end of the incision, a trocared speculum is inserted, deep to the vertebral plane then the trocar is removed and replaced with the optic component.(Fig 12 a,b,c,d)

A foraminectomy is performed and an interlaminary window is done.(Fig 12c,d). The nerve root is retracted (Fig 12 e,f) and released from the scar tissue, it is centrally reclined and the herniated disc is spotted. Discectomy is performed. (Fig 12 g,h)

The yellow ligaments are excised. The root is highlighted, and released from the scar tissue, it is centrally reclined and the herniated disc is highlighted. Disc ablation is performed. Some authors excise strictly the herniated, compressive material, others excise the entire disc but intersomatic fusion must be performed otherwise the forces become unbalanced, overloading the posterior arch. Hemostasis is performed with specially adapted bipolar forceps. The compresses are removed then fascia, aponeurosis and skin sutured and bandaged (Fig.12i).

Another posterior transforaminal technique with dilators (Fig. 13) with direct light was developed by Wolfe & Metronic. The surgical details are similar, but several dilators are used.

In Switzerland, Dr. Leu imagined a more laborious technique by lateral approach, performing two mini-invasive lateral portals with special instruments, long and with small diameter. One portal is for visualizing and the other is the working portal. Low efficiency, high price and additional risks decreased the practice of this lateral technique (Fig.14).

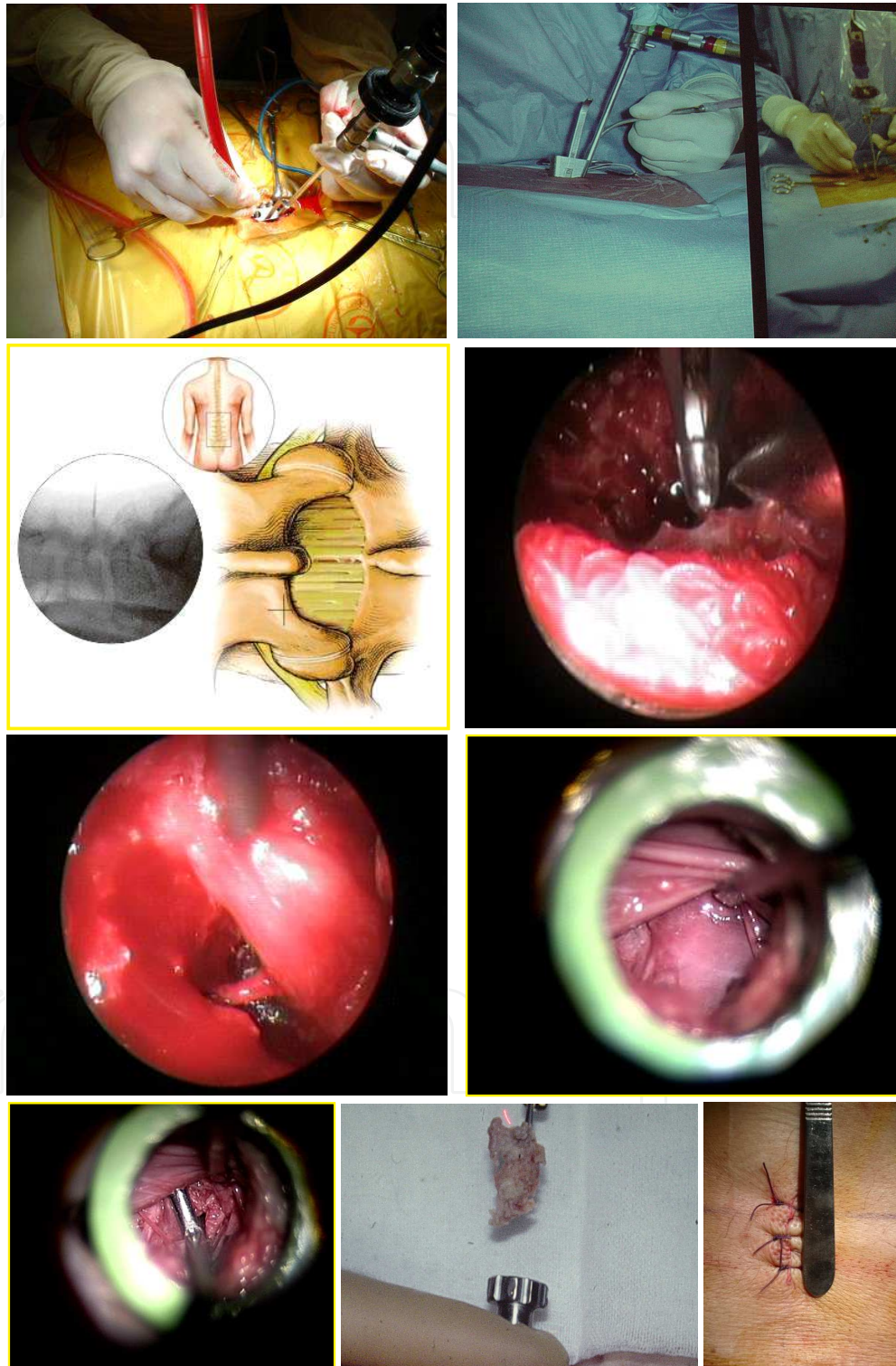


Figure 12. Intraoperative aspects (a-i)

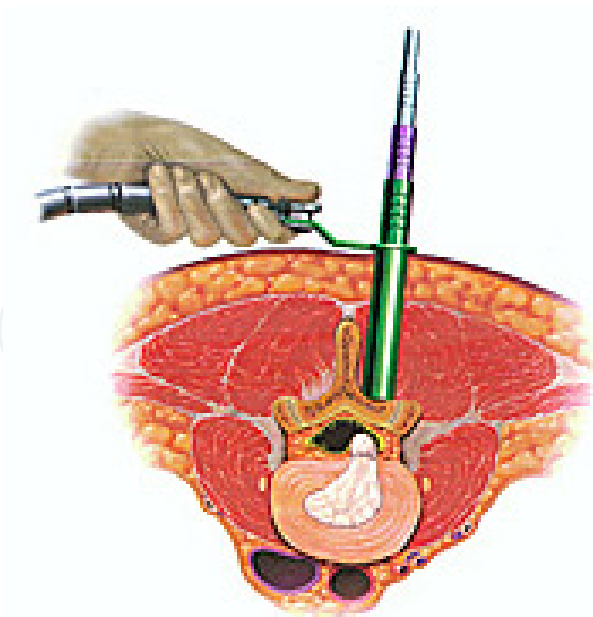


Figure 13. Wolfe & Metronic technique

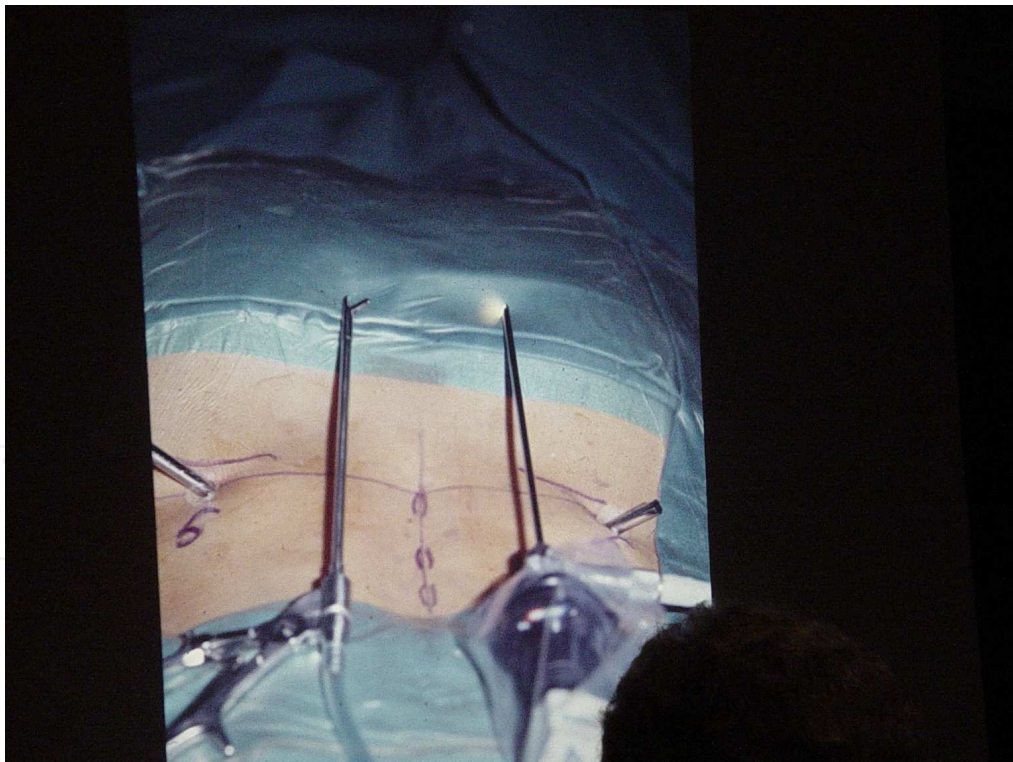


Figure 14. Leu's lateral technique

With endoscopic control intervertebral fusions can be performed either transperitoneal or by thoracoscopy.

5.3. Author’s experience and statistical analysis

Between 2006-2011 we had 40 patients with endoscopic discectomy for lumbar disc. 24 males and 16 females, mean age 48 years (35 – 72), lumbar stenosis was associated in 11 cases. Mean follow-up was 15 months.

One patient was reoperated for a fistula of cerebro-spinal fluid, and the defect was sutured using a combined fascial and haemostatic patch. Three patients required revision for a post-operative hematoma or remaining hernia fragment. Hospital stay was in average 3,3 days (2,5). The Waddel score was excellent or good for 91% of patients and Prolo score was excellent or good for 84%. Mean improvement compare with the preoperative status was 65%, as assessed by Oswestry score (Fig.15).

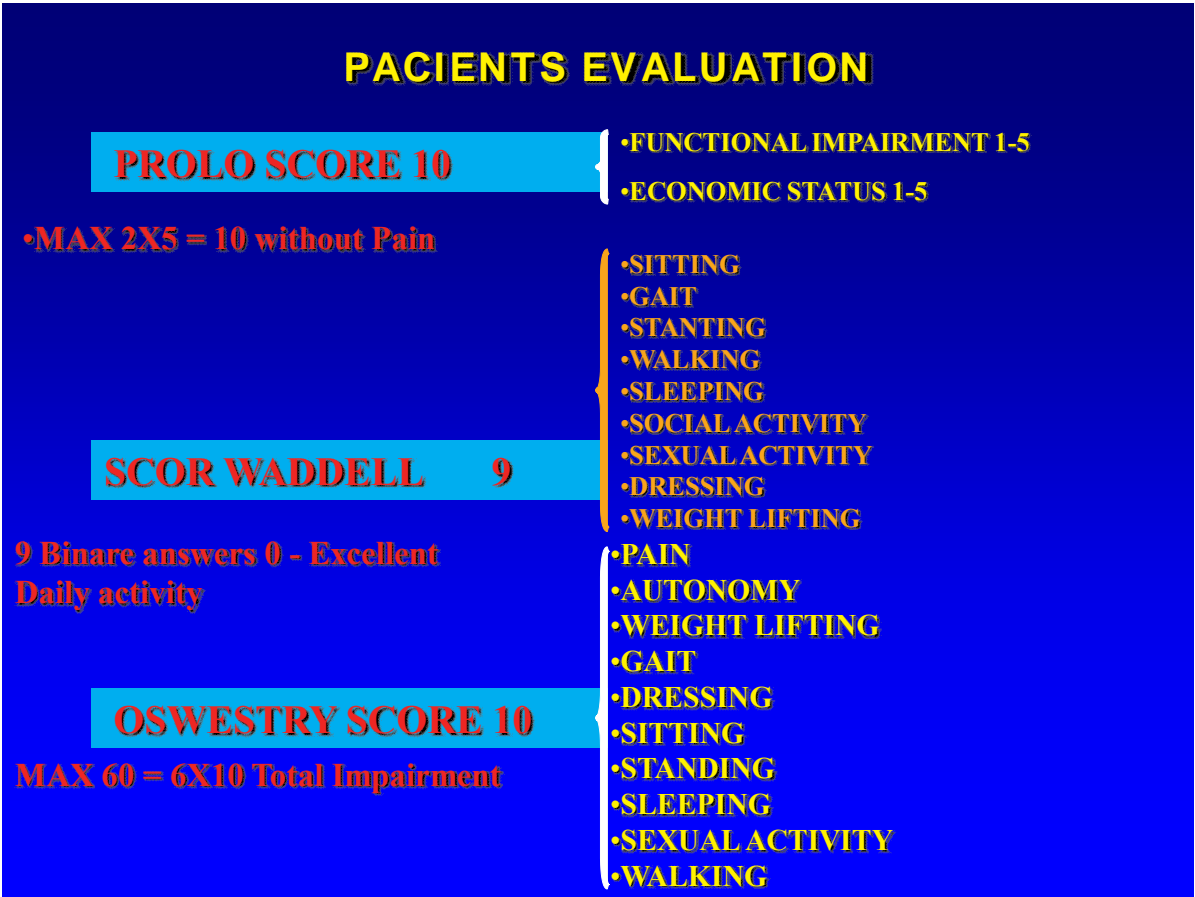


Figure 15. Clinical and Functional evaluation scores

We use anticoagulant therapy for thrombembolism profilaxy. There were no DVT or pulmonary embolism (PE) complications in our series.

We have a type II D anomalous origin nerve roots according to Kadish LJ [8]. About those anomalies, an AOTA Study(1997) on 300 IRM review 20 anomalies (6,7%): 14 conjoint roots, 5 barrel roots and 1 intracanalicular anastomosis (Fig.16).




Figure 16. Nerve roots anatomical anomalies [8]

5.4. Postoperative care

5.4.1. Deep venous thrombosis (DVT) prevention

In spite of minimal surgery, in this spinal surgery DVT is not a rare complication (Weinstein P.R. - 1982).

The use of one of the low-molecular-weight heparins is advisable. One should prolong their use for more than 3 weeks until the complete mobilisation of the patient.

5.4.2. Mobilisation

In general, immediate postoperative mobilisation of the patient is achieved. Administration of NSAID is prolonged till 3 days after surgery.

5.4.3. Weight-bearing

In general, walking with weight-bearing is possible after 1 day. Weight lifting is forbidden even 1 month postoperatively, in obese patients or those with osteoporotic bone even more.

5.4.4. Complications

The risk of infection is reduced due to: minimal dissection and antibiotics.

Fistula of cerebro-spinal fluid, could be even more frequent comparing to classical surgery, but a revision could be necessary, if the dressing after 2 day is still wet, and fascial patch resolve that. The postoperative hematoma or remaining hernia fragment, are also indications of revision. Nerve roots sectioning or nerve palsy is rare but possible. Mistake of the herniate level, is avoided by fluoroscopic control.

6. Conclusion

This kind of minimal surgery, by endoscopic herniated disc ablation provide an excellent visualisation, like „the eye is inside”, by a small skin incision, with rapid resumption of activities and a better post-operative comfort.

A bipolar hemostasis could be done.

This surgery is indicated in all stages of herniated lombar disc, with or without canal stenosis.

There is a lower rate of infectious or bleeding complications.

A single dose of antibiotics is administrated during surgery and anticoagulant for thrombembolism prophylaxis is done.

Author details

Ștefan Cristea, Florin Groseanu, Andrei Prundeanu, Dinu Gartonea, Andrei Papp, Mihai Gavrilă and Dorel Bratu

Clinic of Orthopaedic and Trauma Surgery, St. Pantelimon Hospital, Bucharest, Romania

References

- [1] Anthony P.Schnuerer, Julio Gallego, Cristie Manuel – Core Curriculum for Basic Spinal Training – ed. 2009
- [2] Antonescu Dinu Mihai, Mihail Buga, Ioan Constantinescu, Nicolae Iliescu – Metode de calcul și tehnici experimentale de analiza tensiunilor în Biomecanică ed Tehnică București 1986
- [3] Bar Charts – Quick Study Anatomy Test ed 1998
- [4] Bullough P.G. and Boachie-Adjei O. – Atlas of Spinal Diseases – Harcourt Publishers Limited. Ed 1988

- [5] Cristea Ștefan, Groseanu F., Prundeanu A. - Caiet De Tehnici Chirurgicale Vol 4 – Tehnici de ortopedie artroscopica ed. medicala Buc 2011 – ISBN 978-973-39-0650-6 si ISBN 978-973-39-0710-7 - pag 257 – 268
- [6] Destandau J. "First International Course about Endoscopic Lumbar Microdiscectomy and Lumbar Canal Decompression" 2004 March 25th-26th BORDEAUX
- [7] Destandau Jean Microendoscopic surgery DVD 04 2005 ISBN 3-89756-808-X Storz
- [8] Kadish L.J., Simmons E.H. - Anomalies of the lumbosacral nerve roots. An anatomical investigation and myelographic study. - J Bone Joint Surg Br. 1984 May;66(3):411-6.
- [9] Kieser CW, Jackson R W. Severin Nordentoft: The first arthroscopist. *Arthroscopy* 2001, 17(5):532-5.
- [10] Modic MT, Steinberg PM, Ross JS, et al. Degenerative disk disease: Assessment of changes in vertebral body marrow with MR imaging. *Radiology* 1988;166:193–99
- [11] Nigel Palastanga, Derek Field, Roger Soames – Anatomy and Human Movement – Structure and Function, Butterworth – Heinemann Ltd. Oxford ed. – 1990
- [12] Watanabe M: History arthroscopic surgery. In Shahriaree H (first edition): O'Connor's Textbook of Arthroscopic surgery. Philadelphia, J.B. Lippincott Co., 1983.
- [13] Weinstein P.R. – Anatomy of the lumbar spine . Lumbar Disc Disease – Hardy R.W. ed 1982