

We are IntechOpen, the world's leading publisher of Open Access books Built by scientists, for scientists

6,900

Open access books available

186,000

International authors and editors

200M

Downloads

Our authors are among the

154

Countries delivered to

TOP 1%

most cited scientists

12.2%

Contributors from top 500 universities



WEB OF SCIENCE™

Selection of our books indexed in the Book Citation Index
in Web of Science™ Core Collection (BKCI)

Interested in publishing with us?
Contact book.department@intechopen.com

Numbers displayed above are based on latest data collected.
For more information visit www.intechopen.com



Infectious Causes of Vasculitis

Jacques Choucair

Additional information is available at the end of the chapter

<http://dx.doi.org/10.5772/55189>

1. Introduction

1.1. Infectious vasculitis

The vasculitides are a heterogeneous group of clinicopathological entities that share the common feature of vascular inflammation and injury. There is no universally acceptable classification of this group of disorders. While a number of underlying causes can be identified in some disorders, the aetiology is unknown in many. The pathogenetic mechanisms involved are mainly immunological, immune complex mediated tissue injury being the most commonly incriminated factor.

In 1952, Zeek [1] became the first author to incorporate a clinicopathological assessment based on the size of the vessels involved in the inflammatory process in her classification of necrotizing vasculitis. A number of alternative classification systems were proposed later and a major break was made in the 1990s with the 1990 American College of Rheumatology criteria (ACR 1990 criteria); and the elaboration of a uniform terminology for naming, defining, classifying and diagnosing vasculitic disorders at the Chapel

Hill Conference 1992 (1992 CHC definitions). The 1990 ACR criteria were reviewed in 1996 by Hunder [2]. The 1992 CHC definitions now include immunodiagnostically significant markers [e.g. ANCA in Wegener's granulomatosis (WG) and immunohistological findings (e.g. IgA-dominant immune deposits in Henoch-Schönlein purpura) which are specific for certain diseases and were described by Jennette *et al.* [3]

The major problem with previous classification schemes was the lack of standardized diagnostic terms and definitions. As a consequence, different names had been applied to the same disease and the same name to different diseases. Therefore, the CHC committee—comprised of internists, rheumatologists, nephrologists, immunologists and pathologists who have in common extensive experience with diagnosing vasculitides—proposed the names and definitions given in Table 3.

Large vessel vasculitis ^a	
Giant cell (temporal) arteritis	Granulomatous arteritis of the aorta and its major branches, with a predilection for the extracranial branches of the carotid artery. <i>Often involves the temporal artery. Usually occurs in patients older than 50 yr and often is associated with polymyalgia rheumatica.</i>
Takayasu arteritis	Granulomatous inflammation of the aorta and its major branches. <i>Usually occurs in patients younger than 50 yr.</i>
Medium-sized vessel vasculitis ^a	
Polyarteritis nodosa ^b (classic polyarteritis nodosa)	Necrotizing inflammation of medium-sized or small arteries without glomerulonephritis or vasculitis in arterioles, capillaries, or venules.
Kawasaki disease	Arteritis involving large-, medium-sized, and small arteries, and associated with mucocutaneous lymph node syndrome. <i>Coronary arteries are often involved. Aorta and veins may be involved. Usually occurs in children.</i>
Small vessel vasculitis ^a	
WG ^c	Granulomatous inflammation involving the respiratory tract, and necrotizing vasculitis affecting small- to medium-sized vessels (e.g. capillaries, venules, arterioles, and arteries). <i>Necrotizing glomerulonephritis is common.</i>
CSS ^c	Eosinophil-rich and granulomatous inflammation involving the respiratory tract, and necrotizing vasculitis affecting small- to medium-sized vessels, and associated with asthma and eosinophilia.
MPA ^{b,c} (microscopic polyarteritis)	Necrotizing vasculitis, with few or no immune deposits affecting small vessels (i.e. capillaries, venules, or arterioles). <i>Necrotizing arteritis involving small- and medium-sized arteries may be present. Necrotizing glomerulonephritis is very common. Pulmonary capillaritis often occurs.</i>
Henoch-Schönlein purpura	Vasculitis, with IgA-dominant immune deposits, affecting small vessels (i.e. capillaries, venules, or arterioles). <i>Typically involves skin, gut, and glomeruli, and is associated with arthralgias or arthritis.</i>
Essential cryoglobulinaemic vasculitis	Vasculitis, with cryoglobulin immune deposits, affecting small vessels (i.e. capillaries, venules, or arterioles), and associated with cryoglobulins in serum. <i>Skin and glomeruli are often involved.</i>
Cutaneous leucocytoclastic angiitis	Isolated cutaneous leucocytoclastic angiitis without systemic vasculitis or glomerulonephritis.

^aLarge vessel refers to the aorta and the largest branches directed towards major body regions (e.g. to the extremities and the head and neck); medium-sized vessel refers to the main visceral arteries (e.g. renal, hepatic, coronary, and mesenteric arteries); small vessel refers to venules, capillaries, arterioles, and the intraparenchymal distal arterial radicals that connect with arterioles. Some small and large vessel vasculitides may involve medium-sized arteries, but large- and medium-sized vessel vasculitides do not involve vessels smaller than arteries. Essential components are represented by normal type; italicized type represent usual, but not essential components.

^bPreferred term.

^cStrongly associated with ANCA.

Reproduced from [4] with permission.

Table 1. Names and definitions of vasculitides adopted by the Chapel Hill Consensus Conference on the Nomenclature of Systemic Vasculitis

2. Immunopathogenesis

Most of the vasculitic syndromes are mediated by immunopathogenic mechanisms ('immune vasculitides') and most 'immune vasculitides' are idiopathic (= 'primary' vasculitis).

The immunopathogenic mechanisms of vasculitides have been classified into the four types of hypersensitivity reaction described by Coombs and Gell [4]; this classification was reviewed recently [5]. Accordingly, clinicopathological and immunohistochemical studies have led to the terms allergic angiitis (I), antibody-mediated angiitis, including the 'new' group of ANCA-associated vasculitides (II), immune complex vasculitis (III), and vasculitis associated with T-cell-mediated hypersensitivity (IV). Eosinophilia and elevated IgE in the blood and tissues (*in situ*) are characteristically associated with allergic angiitis and granulomatosis ('Churg–Strauss syndrome'; CSS); in 'ANCA-associated vasculitides' (AAV) few or no immune deposits are found *in situ* ('pauci-immune vasculitis').

By contrast, immune complex deposits *in situ* are the hallmark of immune complex vasculitis, which is frequently associated with low complement levels. Granulomatous arteritis is characterized by an inflammatory infiltrate induced by Th1 cells. The predominant immune phenomena in systemic vasculitides associated with the major hypersensitivity reaction type are given in Fig. 1.

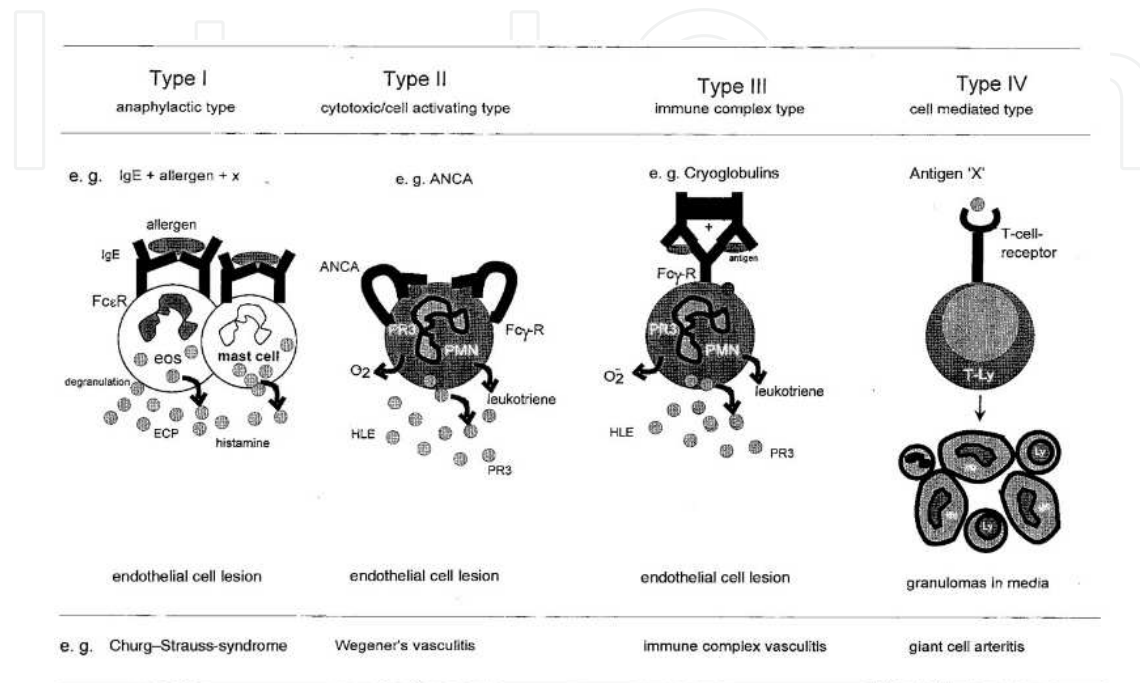


Figure 1. Please add caption

While some forms of vasculitides may be ascribed to underlying factors like infections, malignancy, drug reactions or connective tissue disorders, the cause may remain undetermined in many vasculitic syndromes. Immunologic damage by immune-complex deposition or cell-mediated hypersensitivity is responsible in the majority of cases.

The possible immunopathologic mechanism in the causation of vasculitis are:

1. **Deposition of circulating antigen-antibody complex** or in -situ formation of immune complex within the vessel wall. This leads to complement activation and chemotactic attraction of neutrophils by complement components. Subsequent phagocytosis of such complexes with liberation of neutrophil granular products leads to vascular damage.
2. **Cell-mediated hypersensitivity:** Antigenic exposure may attract lymphocytes which liberate cytokines causing tissue damage and further activation of macrophages and lymphocytes.
3. Failure to clear the antigen may lead to persistent inflammation and eventual formation of epithelioid cells and giant cells, giving rise to a **granulomatous tissue reaction**.

Whatever the underlying mechanism, vascular inflammation and necrosis ensues which is often accompanied by thrombosis. These pathologic changes result in tissue ischaemia,

necrosis and infarction, leading to a variety of clinical manifestations depending on the anatomic structures involved

3. Pathology

Perivascular cellular infiltration is a common histological finding in many disease entities, but for a definitive diagnosis of vasculitis, the presence of vascular damage, particularly in the form of fibrinoid degeneration, is necessary.

Vasculitis may involve blood vessels of varying calibers and this feature forms the basis of a useful pathological classification of vasculitis. An infiltrate, composed of a variety of cell types, like neutrophils, lymphocytes, and histiocytes may invade the vessel wall and the surrounding tissue. Extravasation of red cells is a prominent feature in many vasculitides. Granulomatous inflammation with giant cell formation is a characteristic finding in some types.

4. Classification

Vasculitis is a taxonomist's nightmare. Diseases with diverse causes and pathology may share the same symptomatology. On the other hand, a disease may show different histopathologic features at different periods in its evolution. Many diseases have overlapping features and it is impossible to formulate a classification scheme that unifies clinicopathological, etiological and immunological features of different diseases.

4.1. Immunopathologic classification

- i. Immune- complex mediated vasculitis:
 - Polyarteritis nodosa
 - Microscopic polyangiitis
 - Hypersensitivity vasculitis
 - (Leukocytoclastic vasculitis)
 - Henoch-Schonlein purpura
- ii. Vasculitis due to cellular hypersensitivity (Granulomatous vasculitis)
 - Giant cell arteritis
 - Takayasu's arteritis
 - Churg-Strauss disease (allergic granulomatosis)
 - Wegener's granulomatosis
 - Isolated CNS vasculitis

4.2. Classification based on caliber of blood vessel involved

- i. Large vessel vasculitis:
 - Giant cell arteritis
 - Takayasu's arteritis
- ii. Medium vessel vasculitis:
 - Polyarteritis nodosa
 - Kawasaki disease
- iii. Small vessel vasculitis:
 - Microscopic polyangiitis
 - Leukocytoclastic vasculitis
 - Wegener's granulomatosis
 - Churg-Strauss disease

4.3. Classification based on cellular composition of the infiltrate

- i. *Leukocytoclastic vasculitis* (LCV): Neutrophils are predominant. Cellular fragments and nuclear debris (leukocytoclasia) are found in the infiltrate.
 - Polyarteritis nodosa
 - Henoch-Schonlein purpura
 - Vasculitis due to drugs, infections, and connective tissue diseases
 - Erythema elevatum diutinum
 - Granuloma faciale etc.
- ii. Lymphocytic vasculitis:
 - Lupus erythematosus
 - Lymphoma
 - Pityriasis lichenoides
- iii. Eosinophilic vasculitis :
 - Churg-Strauss vasculitis
- iv. Granulomatous vasculitis :
 - Wegener's granulomatosis and Churg-Strauss
- v. Giant cell arteritis:
 - Temporal arteritis

- Takayasu's arteritis

4.4. Clinical classification

i. Systemic necrotizing vasculitis :

- Polyarteritis nodosa
 - Classical
 - Microscopic polyangiitis
 - Allergic granulomatosis
 - Polyangiitis overlap

- Wegener's granulomatosis

ii. Giant cell vasculitis

- Temporal arteritis
- Takayasu's disease

iii. Predominantly Cutaneous small vessel vasculitis :

a. Idiopathic

b. Secondary:

- **Infection:** (Streptococcus, Staph, TB, Leprosy, Hep.B and C, HIV, Subacute bacterial endocarditis, EBV, parvovirus, Rickettsia)
- **Drugs:** Penicillin, sulpha, phenytoin, allopurinol, gold, thiazide, NSAIDs, Frusemide, quinidine, thiouracils, mefloquine
- **Connective tissue disease** (SLE, Sjogren's syndrome, RA, Scleroderma, Dermatomyositis)
- **Malignancy** (Lymphoma, leukemia, solid organ tumors)
- **Other diseases:** Cryoglobulinemia, complement deficiency, alpha1 antitrypsin deficiency Inflammatory bowel disease, Chronic active hepatitis, intestinal bypass surgery, primary biliary cirrhosis, Relapsing polychondritis

c. Clinical syndromes with leukocytoclastic vasculitis:

- Henoch-Schonlein purpura
- Urticarial vasculitis
- Serum sickness
- Erythema elevatum diutinum
- Granuloma faciale

- Hyperimmunoglobulinemia D
- Acute hemorrhagic edema of children
- Familial Mediterranean fever.

iv. Other vasculitic syndromes:

- Behcet's disease Buerger's disease
- Kawasaki's disease
- Isolated CNS vasculitis
- Cogan's syndrome

5. Immunodiagnostic approach

Primary systemic vasculitides were reclassified based on ANCA serology, the presence of immune deposits *in situ*, and the size of the vessels involved. WG, MPA and CSS were subsumed in the group of ANCA-associated vasculitides, which are characterized clinically by a WG, CSS or non-granulomatous MPA inflammation commonly involving the respiratory tract and ear–nose–throat (ENT) region and by a necrotizing pauci-immune (= no or minimal immune deposits) vasculitis typically affecting small- to medium-sized vessels.

ANCA are a heterogeneous group of autoantibodies that can be subdivided by indirect immunofluorescence tests (IFTs) and by enzyme-linked immunosorbent assays (ELISAs). IFTs can distinguish two major fluorescence patterns on ethanol-fixed human granulocytes: one of these patterns, classic cANCA, is highly specific for WG, while the other, perinuclear pANCA, is commonly seen in MPA (rarely in WG), but may be detected in a wide variety of other autoimmune conditions (e.g. systemic lupus erythematosus, rheumatoid arthritis, Felty's syndrome and chronic inflammatory bowel diseases with associated disorders).

The clinical utility of cANCA as a diagnostic marker for WG was recently confirmed in a large prospective European study undertaken with sera from vasculitis patients (sensitivity 60%, specificity 95%) [6]. However, when employed as a routine screening method for WG (defined according to ACR criteria) in patients with suspected vasculitis, the sensitivity of cANCA in a recent prospective single-centre study on 346 consecutive patients was only 28% (specificity for WG: 98%). The sensitivity rose to 83% if only biopsy-proven WG was considered [7]. A meta-analysis of 15 studies comprising 13 652 patients (including 736 cases of WG) yielded a pooled sensitivity of 66% and a specificity of 98% [8]. Taken together, these data show that the value of cANCA testing is limited by a rather low sensitivity; the greatest utility of cANCA testing may be in patients with suspected, but not yet proven, WG. This view is supported by a recent analysis of ANCA results in a large routine laboratory (Regional Immunology Laboratory, Belfast, UK). The overall positive predictive value for primary systemic vasculitides was 38% for all cANCA and only 20% for all pANCA. Specificity improved when only antinuclear antibody (ANA)-negative samples with a high ANCA titre were considered

(cANCA 90%, pANCA 60%) [9]. In most, but not all cases, titres correlated with disease activity. Rising titres should alert the clinician to an increased risk of exacerbation, but are generally not regarded as an indication for intensifying therapy [10].

ELISAs are used to specify further the target antigens of ANCA, namely proteinase 3 (PR3; cANCA-positive samples have a 99% specificity for WG), myeloperoxidase (MPO; 80% specificity for MPA) [6], as well as less important target antigens such as cathepsin G, lactoferrin, lysozyme and human leucocyte elastase, which are not specific for any particular vasculitic disorder. Whether anti-bactericidal permeability increasing protein (BPI) ANCA offer further diagnostic perspectives in vasculitis is still unclear [11-13].

So, ANCA are not specific for ANCA-associated vasculitides and despite the high specificity of cANCA/PR3-ANCA for WG and of MPO-pANCA for MPA, an increasing number of 'false-positive' PR3-/MPO-ANCA have been described [10]. More recently, we and others have observed PR3-ANCA in subacute bacterial endocarditis, a condition sometimes associated with vasculitis [14]. Still, because ANCA test results are usually available before histological analyses are completed, ANCA serology remains the most important tool in the diagnostic repertoire for ANCA-associated vasculitides, especially in seriously ill patients suspected of having vasculitis. Under life-threatening conditions, therefore, therapy should be commenced based on clinical and serological findings! An overview of predominant immune phenomena in systemic vasculitides associated with the hypersensitivity reaction types (and the serological markers) is given in Table 2.

The incidence of ANCA in CSS is much lower than in WG and MPA, and their immunodiagnostic significance is limited [6]. However, active CSS is characterized by increased eosinophils in conjunction with strongly elevated IgE and eosinophil cationic protein values [15].

Furthermore, endothelial cell damage in active AAV is indicated by markedly increased serum thrombomodulin (sTM) values [15]: in CSS, high levels of sTM correlate closely with the soluble interleukin-2 receptor, which has been shown to be a promising seromarker of disease activity in WG [16].

Because intermittent infections are a major differential diagnostic problem in seriously ill AAV patients (Table 3), a marker that distinguishes between the two conditions is urgently needed. Procalcitonin was recently shown to be normal in active autoimmune rheumatic disorders, but strongly elevated in concomitant bacterial infections and sepsis [17]. However, these findings have yet to be confirmed [18].

6. The mycotic process in endocarditis

Infective endocarditis (IE) is defined as an infection of the endocardial surface of the heart, which may include one or more heart valves, the mural endocardium, or a septal defect. Its intracardiac effects include severe valvular insufficiency, which may lead to intractable

	Henoch-Schönlein purpura	Cryoglobulin. vasculitis	MPA	WG	CSS
IgA immune deposits	+	-	-	-	-
in vessels					
IgG immune deposits	-	+	-	-	-
in vessels					
Cryoglobulins in	-	+	-	-	-
blood and vessels					
Hepatitis C viral genomes	-	HCV-RNA	-	-	-
in blood ^b and vessels					
ANCA in blood	-	-	MPO-ANCA	PR3-ANCA	(+) ^a
Missing Ig deposits ('pauci-immune')	-	-	+	+	+/-
Necrotizing	-	-	-	c	+ ^c
granulomas					
Asthma/eosinophilia (>10%)	-	-	-	-	+

^aIn about 30% of patients MPO-ANCA or PR3-ANCA were detected.

^bOr in the cryoprecipitates.

^cIn particular in the respiratory tract.

Modified from [16].

Table 2. Differential diagnostic features of small vessel vasculitides

congestive heart failure and myocardial abscesses. IE also produces a wide variety of systemic signs and symptoms through several mechanisms, including both sterile and infected emboli and various immunological phenomena [19-21].

IE develops most commonly on the mitral valve, closely followed in descending order of frequency by the aortic valve, the combined mitral and aortic valve, the tricuspid valve, and, rarely, the pulmonic valve. Mechanical prosthetic and bioprosthetic valves exhibit equal rates of infection.

All cases of IE develop from a commonly shared process, as follows:

1. Bacteremia (nosocomial or spontaneous) that delivers the organisms to the surface of the valve

Wagner, 1991 [36]	GN, Osler nodes	Foc. segm. cresc. GN (IgM and C3 deposits)	<i>Streptococcus viridans</i>	nd	Recovery, ANCA neg.
Soto, 1994 [37]	Purpura, fever, weakness, haematuria, aneurysm	nd	<i>Streptococcus bovis</i>	Thickening of aortic valve	Mycotic intra-cran. cran. aneurysm. rupture
Subra, 1998 [38]	Nephrotic syndrome	Membranoproliferative GN	n.i.	Vegetations (mitral, aortic valves)	Improvement ANCA (+)
Subra, 1998 [38]	Fever, anaemia, purpura, GN	Foc. segm. cresc. GN (C1q and C3 deposits)	n.i.	Aortic vegetations	Improvement ANCA neg.
Choi, 2000 [39]	Fever, malaise, weight loss, splenomegaly	nd	<i>Streptococcus sanguis</i>	Mitral vegetations	Complete recovery ANCA neg.
Choi, 2000 [39]	Purpura, weight loss, malaise	nd	<i>S. viridans</i>	Mitral valve thickening	Complete recovery ANCA neg.

GN, glomerulonephritis; Foc. segm. cresc, focal segmental crescentic; nd, not done; s., *Streptococcus*; n.i., not isolated; cran., cranial; aneurysm., aneurysmatic; neg., negative; nd, not defined.

Reviewed and modified from [39].

Table 3. Summary of subacute bacterial endocarditis associated with PR3-ANCA

2. Adherence of the organisms

3. Eventual invasion of the valvular leaflets

The common denominator for adherence and invasion is nonbacterial thrombotic endocarditis, a sterile fibrin-platelet vegetation. The development of subacute IE depends on a bacterial inoculum sufficient to allow invasion of the preexistent thrombus. This critical mass is the result of bacterial clumping produced by agglutinating antibodies.

In acute IE, the thrombus may be produced by the invading organism (ie, *S aureus*) or by valvular trauma from intravenous catheters or pacing wires (ie, NIE/HClE). *S aureus* can invade the endothelial cells (endotheliosis) and increase the expression of adhesion molecules and of procoagulant activity on the cellular surface. Nonbacterial thrombotic endocarditis may result from stress, renal failure, malnutrition, systemic lupus erythematosus, or neoplasia.

The Venturi effect also contributes to the development and location of nonbacterial thrombotic endocarditis. This principle explains why bacteria and the fibrin-platelet thrombus are deposited on the sides of the low-pressure sink that lies just beyond a narrowing or stenosis.

In patients with mitral insufficiency, bacteria and the fibrin-platelet thrombus are located on the atrial surface of the valve. In patients with aortic insufficiency, they are located on the ventricular side. In these examples, the atria and ventricles are the low-pressure sinks. In the case of a ventricular septal defect, the low-pressure sink is the right ventricle and the thrombus is found on the right side of the defect.

Nonbacterial thrombotic endocarditis may also form on the endocardium of the right ventricle, opposite the orifice that has been damaged by the jet of blood flowing through the defect (ie, the MacCallum patch).

1. Inflammatory diseases of unknown aetiology
 - Systemic autoimmune diseases (e.g. vasculitides associated with systemic lupus erythematosus, Sjögren's syndrome, Behçet disease, and rheumatoid vasculitis)
 - Local chronic inflammatory diseases (e.g. ulcerative colitis)
 - Chronic granulomatous inflammation (Crohn's disease, sarcoidosis, etc.)
2. Infectious diseases
 - Viruses (e.g. vasculitides associated with HIV, CMV, etc.)
 - Bacteria (e.g. spirochaetales, mycobacteria, streptococci, tropheryma, whippeli, etc.)
 - Parasites (e.g. *Ascaris* etc.)
 - Fungi (e.g. *Aspergillus*)
3. Neoplasia
 - Non-Hodgkin lymphoma
 - Myeloproliferative diseases
 - Solid tumours
 - Atrial myxomas
4. Drug abuse (intoxication)
 - Opioids (cocaine, morphine, etc.)
5. Drug-induced (casuistic)
 - Antihypertensive (hydralazine)
 - Antithyroid drugs (propylthiouracil, methimazole, carbamazepine)
 - Antibiotics (azithromycin, minocycline)
 - Antifibrotic (penicillamine)
 - Leukotriene receptor antagonist (zafirlukast, montelukast, pranlukast)

CMV, cytomegalovirus.

Table 4. Secondary vasculitides

The microorganisms that most commonly produce endocarditis (ie, *S aureus*; *Streptococcus viridans*; group A, C, and G streptococci; enterococci) resist the bactericidal action of complement and possess fibronectin receptors for the surface of the fibrin-platelet thrombus. Among the many other characteristics of IE-producing bacteria demonstrated in vitro and in vivo, some features include the following:

- Increased adherence to aortic valve leaflet disks by enterococci, *S viridans*, and *S aureus*
- Mucoid-producing strains of *S aureus*
- Dextran-producing strains of *S viridans*
- *S viridans* and enterococci that possess FimA surface adhesin

- Platelet aggregation by *S aureus* and *S viridans* and resistance of *S aureus* to platelet microbicidal proteins

Bacteremia (either spontaneous or due to an invasive procedure) infects the sterile fibrin-platelet vegetation described above. BSIs develop from various extracardiac types of infection, such as pneumonias or pyelonephritis, but most commonly from gingival disease. Of those with high-grade gingivitis, 10% have recurrent transient bacteremias (usually streptococcal species). Most cases of subacute disease are secondary to the bacteremias that develop from the activities of daily living (eg, brushing teeth, bowel movements).

Bacteremia can result from various invasive procedures, ranging from oral surgery to sclerotherapy of esophageal varices to genitourinary surgeries to various abdominal operations. The potential for invasive procedures to produce a bacteremia varies greatly. Procedures, rates, and organisms are as follows:

- Endoscopy - Rate of 0-20%; coagulase-negative staphylococci (CoNS), streptococci, diphtheroids
- Colonoscopy - Rate of 0-20%; *Escherichia coli*, *Bacteroides* species
- Barium enema - Rate of 0-20%; enterococci, aerobic and anaerobic gram-negative rods
- Dental extractions - Rate of 40-100%; *S viridans*
- Transurethral resection of the prostate - Rate of 20-40%; coliforms, enterococci, *S aureus*
- Transesophageal echocardiography - Rate of 0-20%; *S viridans*, anaerobic organisms, streptococci

Bacterial adherence to intravascular catheters depends on the response of the host to the presence of this foreign body, the properties of the organism itself, and the position of the catheter. Within a few days of insertion, a sleeve of fibrin and fibronectin is deposited on the catheter. *S aureus* adheres to the fibrin component.

S aureus also produces an infection of the endothelial cells (endotheliosis), which is important in producing the continuous bacteremia of *S aureus* BSIs. Endotheliosis may explain many cases of persistent methicillin-susceptible *S aureus* (MSSA) and methicillin-resistant *S aureus* (MRSA) catheter-related BSIs without an identifiable cause.

S aureus catheter-related BSIs occur even after an infected catheter is removed, apparently attributable to specific virulence factors of certain strains of *S aureus* that invade the adjacent endothelial cells. At some point, the staphylococci re-enter the bloodstream, resulting in bacteremia [22].

Four days after placement, the risk of infection markedly increases. Lines positioned in the internal jugular are more prone to infection than those placed in the subclavian vein. Colonization of the intracutaneous tract is the most likely source of short-term catheter-related BSIs. Among lines in place for more than 2 weeks, infection of the hub is the major source of bacteremia. In some cases, the infusion itself may be a reservoir of infection.

Colonization of heart valves by microorganisms is a complex process. Most transient bacteremias are short-lived, are without consequence, and are often not preventable. Bacteria rarely adhere to an endocardial nidus before the microorganisms are removed from the circulation by various host defenses.

Once microorganisms do establish themselves on the surface of the vegetation, the process of platelet aggregation and fibrin deposition accelerate at the site. As the bacteria multiply, they are covered by ever-thickening layers of platelets and thrombin, which protect them from neutrophils and other host defenses. Organisms deep in the vegetation hibernate because of the paucity of available nutrients and are therefore less susceptible to bactericidal antimicrobials that interfere with bacterial cell wall synthesis.

Complications of subacute endocarditis result from embolization, slowly progressive valvular destruction, and various immunological mechanisms. The pathological picture of subacute IE is marked by valvular vegetations in which bacteria colonies are present both on and below the surface.

The cellular reaction in SBE is primarily that of mononuclear cells and lymphocytes, with few polymorphonuclear cells. The surface of the valve beneath the vegetation shows few organisms. Proliferation of capillaries and fibroblasts is marked. Areas of healing are scattered among areas of destruction. Over time, the healing process falls behind, and valvular insufficiency develops secondary to perforation of the cusps and damage to the chordae tendineae. Compared with acute disease, little extension of the infectious process occurs beyond the valvular leaflets.

Levels of agglutinating and complement-fixing bactericidal antibodies and cryoglobulins are markedly increased in patients with subacute endocarditis. Many of the extracardiac manifestations of this form of the disease are due to circulating immune complexes. Among these include glomerulonephritis, peripheral manifestations (eg, Osler nodes, Roth spots, subungual hemorrhages), and, possibly, various musculoskeletal abnormalities. Janeway lesions usually arise from infected microemboli.

The microscopic appearance of acute bacterial endocarditis differs markedly from that of subacute disease. Vegetations that contain no fibroblasts develop rapidly, with no evidence of repair. Large amounts of both polymorphonuclear leukocytes and organisms are present in an ever-expanding area of necrosis. This process rapidly produces spontaneous rupture of the leaflets, of the papillary muscles, and of the chordae tendineae.

The complications of acute bacterial endocarditis result from intracardiac disease and metastatic infection produced by suppurative emboli. Because of their shortened course, immunological phenomena are not a part of acute IE.

William Osler first used the term *mycotic aneurysm* in his 1885 Gulstonian Lecture series [23] to refer to an aneurysm resulting from an infectious process of the arterial wall, although a more accurate term might have been *endovascular infection* or *infective vasculitis*, because mycotic aneurysms are not due to a fungal organism.

Intracranial mycotic aneurysms (ICMAs) complicate about 2% to 3% of infective endocarditis (IE) cases, although as many as 15% to 29% of patients with IE have neurologic symptoms [24-26]. Of all intracerebral aneurysms, only 2% to 6% have an infectious etiology. Signs and symptoms of mycotic aneurysms may be misleading during the early stages, resulting in misdiagnosis and delays in treatment [27]. Early diagnosis of ICMA is the cornerstone of effective treatment.

Mycotic aneurysms can be divided into 4 types: [1] *embolic*, secondary to bacterial endocarditis (*embolomycotic aneurysms*); [2] *extravascular*, secondary to extension of contiguous infection from a septic focus neighboring an artery; [3] *cryptogenic* or primary bacteremic; and [4] direct contamination following arterial wall trauma, which may be postprocedural [28]. Aneurysms can occur in the cerebral circulation, usually at points of vessel bifurcation, or in the systemic circulation [29].

In IE-associated mycotic aneurysms, septic emboli are released from infected cardiac vegetations. These tiny septic emboli occlude the vasa vasorum or entire arterial lumen, which leads to damage to the muscular layer of the vessel. ICMA tend to occur in the more distal portions of the middle cerebral artery, near the surface of the brain, involving the secondary and tertiary branches. In contrast, berry aneurysms occur at proximal branch points in or near the circle of Willis [26]. The outcome depends upon the anatomical location of the embolus, the causative bacteria and associated virulence of the organism, underlying host defenses, and appropriate antibiotic therapy. Mycotic aneurysms can decrease, increase, remain the same in size, or even disappear during treatment for endocarditis [30].

Patients with bacterial intracranial aneurysms have variable neurological symptoms, and early symptoms of infection may be subtle. In ICMA, patients may have symptoms ranging from nonspecific, general complaints, including fever or headache, to neurological deficits or catastrophic intracranial hemorrhage. Laboratory results are typically suggestive of an underlying inflammatory process and may include leukocytosis, elevated erythrocyte sedimentation rate and/or C-reactive protein concentration, and anemia. Blood cultures are almost universally positive for microbial growth.

Computed tomographic angiography, magnetic resonance angiography (MRA), and catheter angiography are used to study the size, location, and morphology of intracranial aneurysms. Aneurysms 5 mm in diameter or larger can be detected by CTA and MRA. Smaller aneurysms are detected less reliably or detected in retrospect after comparison with cerebral angiography.[31-33]. Cerebral angiography is the gold standard and is often used in preoperative assessment and in determining prognosis[34]; however, it is not routinely recommended due to risk of complications associated with it. The size of the aneurysm during therapy can be safely and accurately monitored using CTA and MRA. In our patient, CTA was selected as the diagnostic tool.

Treatment of ICMA is controversial, in that the appropriate patients for surgical intervention, need for follow-up imaging, and most efficacious treatment are not well delineated in the medical literature. The appropriate treatment always involves medical and sometimes surgical therapies [35]. Moreover, there is no single uniformly accepted approach to the treatment of

ICMA in IE. The aim of therapy is to cure the underlying infection and avoid complications from the aneurysm. Some lesions will resolve with antibiotic therapy alone. The decision to pursue surgical management is complex and involves a number of factors, including the number, site, and anatomy of the aneurysm(s) and the comorbidities of the patient. Treatment options for unruptured aneurysms include observation or surgical approaches, such as craniotomy and clipping or endovascular coiling [36,37]. The surgical choice of treatment for ICMA is controversial, patient-specific, and is generally beyond the scope of this article. Four- to 6-week courses of pathogen-specific intravenous antibiotic are recommended. In addition, medical therapy should include control of hypertension and seizures. Therapy should be monitored with serial CTA or MRA, and surgical intervention is generally recommended for enlarging aneurysms in accessible locations. Ruptured aneurysms are treated emergently with surgery to prevent rebleeding if possible.

Staphylococcus aureus (~30%), *Salmonella* species (~15%), and less commonly viridans group streptococci are some of the causative organisms of mycotic aneurysms in the postantibiotic era [38].

Recent reports suggest *Streptococcus pneumoniae*, including penicillin-resistant strains, are re-emerging as a cause of mycotic aneurysms [39]. Our patient was infected with *Streptococcus bovis*, a gram-positive cocci classified as group D streptococci. Endocarditis is the most significant clinical infection associated with *S bovis*, but bacteremia from enteric origins also occurs. *S bovis* accounts for 2% to 6% of streptococcal bloodstream isolates from hospitalized patients and for 2.4% to 25% of organisms associated with IE [40-44]. *S bovis* is a rare cause of ICMA, however. Interestingly, *S bovis* endocarditis or bacteremia is associated with concomitant undiagnosed gastrointestinal (GI) tumors in up to 56 % of patients [45]. GI diseases associated with *S bovis* endocarditis include colonic cancers, gastric ulcers, gastric cancer, duodenal ulcers, inflammatory bowel disease, colonic diverticula, angiodysplasia, and liver cirrhosis [40,46-48]. Thus, any patient with *S bovis* bacteremia should undergo screening for occult GI malignancy. Although our patient died before such screening could be completed, he did have a family history of gastric cancer and a personal history of colon cancer.

7. Bacterial causes of vasculitis

Bacterial seeding of vessels may lead to necrosis through direct bacterial action. Vessels may be seeded intraluminally at sites of endothelial injury or flow turbulence. Seeding of vasa vasora may cause destruction of vessels from the outside in. An injury of a large vessel by this mechanism is classically termed a "mycotic aneurysm."

Contiguous spread from an infected site to a vessel may occur. Vessels may also be seeded from within the lumen, as in subacute bacterial endocarditis in which septic emboli embed within the wall of smaller vessels, causing a "mycotic" process via a luminal route. Immune response to bacteria or to bacterial components may also lead to vasculitis, usually by immune-complex-mediated mechanisms [24].

In subacute bacterial endocarditis, direct spread via septic emboli and immune complex injury may occur.

Patients may present with evidence of elevated acute-phase reactants, fever, malaise, myalgia, arthralgia, Osler's nodes, Janeway lesions, and septic infarcts [49,50].

Staphylococcus and streptococcus infections are common causes. Gram-negative organisms, other gram-positive cocci, fungi, and parasites may be causative as well, and their occurrence depends on the clinical setting [51-57].

Mycotic aneurysms resulting from septic emboli are common with staphylococcus, streptococcus, and *Salmonella* species [58-60]. Patients with subacute infections may develop cryoglobulins [61-63]. Bacteremia may present as leukocytoclastic vasculitis [64,65]. Small-vessel vasculitis may be associated with post-streptococcal infection, distinct from endocarditis [66, 67].

The *Rickettsiae* are a group of obligate intracellular bacteria with tropism for vascular endothelium [68]. Infection results in widespread microvascular leak, local thrombosis, and ultimately multisystem failure if untreated. [69, 70].

Treponema pallidum and *Borrelia burgdorferi* are also rare causes of infectious vasculitis [71].

In the lung, necrosis of vessels may occur from septic emboli or from contiguous spread in primary pneumonias. In the latter setting, *Pseudomonas aeruginosa* and *Legionella pneumophila* often cause direct necrosis via contiguous spread [72]. The presentation, however, is that of pneumonia.

Mycobacterial or fungal pulmonary infections may mimic Wegener's granulomatosis or Churg-Strauss vasculitis in eliciting a granulomatous reaction in vessels [73].

Spread of *Mycobacterium tuberculosis* to the aorta may be seen as a cause of tuberculous aortitis, coronary arteritis, and mycotic aneurysm [74-76]. *Aspergillus aeruginosa*, *Aspergillus fumigatus*, and *Mucor* may be characterized by direct vessel invasion and necrosis [59, 77, 78]. *Coccidioides immitis* meningitis may be associated with vasculitis that can be confused with central nervous system

Angitis [79, 80]. *Coccidioides immitis* may also present as an immune-complex-mediated disease with erythema nodosum, periartthritis predominantly of the ankles, and bihilar lymphadenopathy [81, 82]. This presentation is often confused with Löfgren's syndrome of sarcoidosis. While sarcoidosis as a cause of Löfgren's syndrome is more prevalent in eastern United States populations, *Coccidioides immitis* is a more likely cause of a Löfgren's-like presentation in the western United States.

Neisseria species may be associated with small-vessel vasculitis. In *Neisseria gonorrhea* infection, cutaneous papules vesiculate, then become necrotic [83]. In *N meningitidis* infections, vasculitis may manifest in the skin and gastrointestinal tract with the endothelium showing necrosis and thrombosis [84-86]. In immunocompromised hosts, *Pseudomonas aeruginosa* and other gram-negative organisms can present as a large 1- to 5-cm macular erythema that develops central necrosis and peripheral edema and induration—a condition termed "ecthyma gangrenosum." Vessel thrombosis results from direct bacterial invasion of the vessels. Similar lesions may be seen in immunocompromised patients with disseminated *Pseudomonas*,

Nocardia, *Aspergillus*, *Mucor*, *Curvularia*, *Pseudallescheria*, *Fusarium*, *Morganella*, *Metarrhizium*, *Xanthomonas*, *Klebsiella*, *E coli*, and *Aeromonas* infections.[87-99].

Before AIDS, syphilis was the infectious agent known as the “great imposter,” presenting as large- or medium size vessel disease (aortitis or coronary arteries) or as the small-vessel rash of secondary lues. Aortic aneurysms were insidious in clinical presentation. *Treponema pallidum* spirochetes were rarely detected in fibrosed and scarred vessels [100-102]. At least briefly, *Borrelia burgdorferi*, the causative agent of Lyme disease, was known as an “imposter.” Vasculitic changes may be seen in the central nervous system, retina, and temporal arteries [103-116].

8. Viral causes of vasculitis

Our knowledge of viral pathogenesis has exploded in the last quarter of the twentieth century, accelerated in large part by epidemics of “emerging” viral diseases. Hepatitis C virus, discovered in 1989, has worldwide prevalence [25]. The 10- to 20-year latent period before hepatic or rheumatic manifestations of disease explains the increasing number of cases of hepatitis C virus-mediated vasculitis currently being seen in the United States following the epidemic of new infections in the 1980s [26]. Prior to the discovery and characterization of hepatitis C virus in the late 1980s, the triad of arthritis, palpable purpura, and type II cryoglobulinemia was given the sobriquet “essential mixed cryoglobulinemia” and considered an idiopathic vasculitis.

Availability of diagnostic testing for hepatitis C virus demonstrated that almost all of these cases were associated with hepatitis C virus infection. Immune response to the virus elicits a response to the Fc portion of immunoglobulin with the majority of elicited antibody having the Wa idiotype [27,28].

Immune complexes of anti-Fc Wa idiotypic antibody and pre-existing antibody, and virus have the peculiar physical property of precipitating out of solution in the cold (“cryoglobulins”). Presumably, Wa idiotype recognizes a cross-reactive epitope found on hepatitis C virus and immunoglobulin. Extremities and skin are sufficiently cold so as to explain a predilection for small-vessel leukocytoclastic vasculitis of the skin; gravity enhances vascular injury in dependent distal vessels, giving rise to palpable purpura predominantly in the lower extremities. More severe cases may manifest visceral organ involvement including membranoproliferative glomerulonephritis and bowel involvement. Small- and medium-sized arteries may be involved as well, especially in the kidneys.

Hepatitis B virus (HBV) infection provides the classic example of virally mediated immune complex disease. A lymphocytic venulitis or neutrophilic vasculitis of small vessels with leukocytoclastic or fibrinoid changes presents typically as an “urticaria-arthritis syndrome.” [29].

Immune complexes of hepatitis B virus surface antigen (HBsAg) and antibodies to hepatitis B virus surface antigen (HBsAb) circulate in the blood and are found deposited in vessels in association with complement [30, 31]. The long latency period of HBV allows time for an

immune response to occur. Viral replication increases HBsAg load, and is temporally associated with jaundice [32]. The immune complexes eventually no longer form in antigen excess, and the serum sickness-like illness resolves. HBV has also been associated with large-vessel polyarteritis nodosa-like illness [33]. Onset is early in the course of chronic HBV hepatitis.

Immune complexes containing HBsAg, HBsAb, and complement are found in the vessel wall [34]. The determinants of small vessel versus larger vessel disease in the two syndromes of HBV infection are unknown.

Human immunodeficiency virus (HIV) patients may present with a variety of vasculitides. However, it is difficult to specifically attribute the various vasculitides seen to HIV because of frequent co-infections with other agents that may cause vasculitis in the absence of HIV infection.

Human T lymphotropic virus 1 infection may cause retinal, cutaneous, or central nervous system vasculitis [35-38].

The herpesviruses (cytomegalovirus, varicella-zoster, herpes simplex viruses 1 and 2, and herpes hominis) may be associated with retinal vasculitis in immunocompromised patients [39-45]. Varicella-zoster may also cause a diffuse central nervous system small arterial granulomatous vasculitis, or a small- and/or large-artery vasculopathy [46-48, 117]. Herpes simplex viruses 1 and 2 have been associated with cutaneous vasculitis and necrotizing arteritis of small and medium vessels [118-120]. Epstein-Barr virus has been suggested as a cause of both small- and large-vessel disease in a number of cases and short series [121-126]. However, the ability to demonstrate causality in many instances is made all the more difficult by the latency of herpesvirus infection.

Varicella zoster virus and CMV have been as well implicated in the etiopathogenesis of various vasculitides via numerous and overlapping mechanisms including direct microbial invasion of endothelial cells, immune complex mediated vessel wall damage and stimulation of autoreactive B and/or T cells through molecular mimicry and superantigens [71].

Vasculitis following varicella-herpes zoster infection occasionally develops in the form of a central neurological deficiency (locomotor deficiency with or without aphasia around one month after an ophthalmologic herpes zoster) or involving the retina or, more rarely, the skin or the kidneys. Vasculitis associated with cytomegaloviral infection, predominantly observed in immunodepressed patients, is diffuse and basically involving the digestive tube, notably the colon, the central nervous system and the skin [127].

Parvovirus B19 has been suggested as the causative agent of Wegener's granulomatosis and polyarteritis nodosa in a number of cases and short series [128-133]. However, the issue of latency and the failure to eliminate B19 from pooled blood products provides a cautionary note when considering causality [134-137]. Rare cases of vasculitis have similarly been reported following rubella virus, adenovirus, echovirus, coxsackievirus, parainfluenza virus, herpes simplex viruses, and hepatitis A virus infections [23, 138-148].

Ziegler et al demonstrated the presence of vasculitis in infected falcons by the West Nile virus. West Nile virus (WNV) is a zoonotic flavivirus that is transmitted by blood-suckling mosquitoes with birds serving as the primary vertebrate reservoir hosts (enzootic cycle). Some bird species like ravens, raptors and jays are highly susceptible and develop deadly encephalitis while others are infected subclinically only. Pathological findings in infected birds consistently included splenomegaly, non-suppurative myocarditis, meningoencephalitis and vasculitis. By immunohistochemistry WNV-antigens were demonstrated intraluminally. These results impressively illustrate the devastating and possibly deadly effects of WNV infection in falcons, independent of the genetic lineage and dose of the challenge virus used. Due to the relatively high virus load and long duration of viremia falcons may also be considered competent WNV amplifying hosts, and thus may play a role in the transmission cycle of this zoonotic virus.

Rare cases of vasculitis have similarly been reported following rubella virus, adenovirus, echovirus, coxsackievirus, parainfluenza virus, herpes simplex viruses, and hepatitis A virus infections [23, 138-148].

9. Parasitic causes of vasculitis

Toxocara canis presented in an adolescent as palpable purpura with additional features suggesting Henoch-Schönlein purpura [149]. *Cysticercus* has caused vasculitis and arachnoiditis as it infects the central nervous system [150] *Angiostrongylus* nematodes apparently caused a Wegener's granulomatosis-like pulmonary angiitis [151]. Loa loa, a filarial parasite, presented with cutaneous leukocytoclastic vasculitis

Author details

Jacques Chouair

Hotel Dieu de France hospital, Beirut, Lebanon

References

- [1] Zeek, P. M. Periarthritis nodosa: a critical review. Am J Clin Pathol(1952). , 22, 777-90.
- [2] Hunder, G. G. Vasculitis: diagnosis and therapy. Am J Med(1996). suppl. A);, 37-45.
- [3] Jennette, J. C, Falk, R, Andrassy, K, et al. Nomenclature of systemic vasculitis. Proposal of an international conference. Arthritis Rheum(1994). , 37, 187-92.

- [4] Coombs RRA, Gell PGH. The classification of allergic reactions underlying disease. In: Clinical aspects of immunology. Gell PGH, Coombs RRA, eds. Philadelphia: Davis, (1963).
- [5] Hagen, E. C, Daha, M. R, Hermans, J, et al. Diagnostic value of standardized assays for anti-neutrophil cytoplasmic antibodies in idiopathic systemic vasculitis. Clin Nephrol(1998). , 53, 743-53.
- [6] Rao, J. K, Allen, N. B, Feussner, J. R, & Weinberger, M. A prospective study of anti-neutrophil cytoplasmic antibody (cANCA) and clinical criteria in diagnosing Wegener's granulomatosis. Lancet(1995). , 346, 926-31.
- [7] Rao, J. K, Weinberger, M, Oddone, E. Z, Allen, N. B, Lansman, P, & Feussner, J. R. The role of antineutrophil cytoplasmic antibody (cANCA) testing in the diagnosis of Wegener's granulomatosis. Ann Intern Med(1995). , 123, 925-32.
- [8] Hagen, E. C, Daha, M. R, Hermans, J, et al. Diagnostic value of standardized assays for anti-neutrophil cytoplasmic antibodies in idiopathic systemic vasculitis. Clin Nephrol(1998). , 53, 743-53.
- [9] Edgar J, DMMcMillan SA, Bruce JN, Caulan SK. An audit of ANCA in routine clinical practice. Postgrad Med J(1995). , 71, 605-12.
- [10] Csernok, W. L, & Immunodiagnostic, E. and pathophysiologic aspects of antineutrophil cytoplasmic antibodies in vasculitis. Curr Opin Rheumatol(1995). , 7, 11-9.
- [11] Zhao, M. H, Jones, S. J, & Lockwood, C. M. Bactericidal/permeability increasing protein (BPI) is an important antigen for antineutrophil cytoplasmic autoantibodies (ANCA) in vasculitides. Clin Exp Immunol(1995). , 99, 49-56.
- [12] Stoffel, M. P, Csernok, E, Herzberg, C, Johnston, T, Carroll, S. F, & Gross, W. L. Anti-neutrophil cytoplasmic antibodies (ANCA) directed against bactericidal/permeability increasing protein (BPI): A new seromarker for inflammatory bowel disease and associated disorders. Clin Exp Immunol(1996). , 104, 54-9.
- [13] Schultz H, Csernok E, Johnston TW, Lockwood CM, Gross WL. Use of native and recombinant bactericidal/permeability increasing protein (BPI) as antigens for detection of BPI-ANCA. J Immunol Methods 1997;205:127-33.
- [14] Lamprecht, P, Gadola, S, Schnabel, A, & Gross, W. L. ANCA, infectious endocarditis, glomerulonephritis and cryoglobulinemic vasculitis. Clin Nephrol(1998). letter).
- [15] Schmitt, W. H, Csernok, E, Kobayashi, S, & Klinkenborg, A. Reinhold-Keller E, Gross WL. Churg-Strauss Syndrome: Serum markers of lymphocyte activation and endothelial damage. Arthritis Rheum(1997). , 41, 445-52.
- [16] Schmitt, W. H, Heesen, C, Csernok, E, Rautmann, A, & Gross, W. L. Elevated serum levels of soluble interleukin-2 receptor (sIL-2R) in Wegener's granulomatosis (WG): Association with disease activity. Arthritis Rheum(1992). , 35, 1088-96.

- [17] Stroemann, A, Künzel, K, Hiepe, S, Beier, W, Burmester, G. R, & Krause, A. Procalcitonin: Marker for bactericidal infections in patients with rheumatic diseases. *Z Rheumatol*(1996). suppl. 1):86.
- [18] Moosig, F, & Csernok, E. Reinhold-Keller E, Schmitt WH, Gross WL. Elevated procalcitonin levels in active Wegener's granulomatosis. *J Rheumatol*(1998). , 25, 1531-3.
- [19] Brusch, J. L. Infective endocarditis and its mimics in the critical care unit. In: Cunha BA, ed. *Infectious Diseases in Critical Care*. 2nd ed. New York, NY: Informa Healthcare; (2007). , 2007, 261-2.
- [20] Karchmer, A. W. Infective endocarditis. In: *Braunwald's Heart Disease: A Textbook of Cardiovascular Medicine*. 7th ed. WB Saunders Co; (2005). , 2005, 1633-1658.
- [21] Karchmer, A. W. Infective endocarditis. In: *Harrison's Principles of Internal Medicine*. 16th ed. McGraw-Hill; (2005). , 2005, 731-40.
- [22] Xiong, Y. Q, Fowler, V. G, Yeaman, M. R, Perdreau-remington, F, Kreiswirth, B. N, & Bayer, A. S. Phenotypic and genotypic characteristics of persistent methicillin-resistant *Staphylococcus aureus* bacteremia in vitro and in an experimental endocarditis model. *J Infect Dis*. Jan 15 (2009). , 199(2), 201-8.
- [23] Osler, W. Malignant endocarditis (Gulstonian Lecture I). *Lancet*. (1885). , 1, 415-418.
- [24] Chan, F. Y, Crawford, E. S, Coselli, J. S, & Safi, H. J. Williams TW Jr. In situ prosthetic graft replacement for mycotic aneurysm of the aorta. *Ann Thorac Surg*. (1989). , 47(2), 193-203.
- [25] Bohmfalk, G. L, Story, J. L, & Wissinger, J. P. Brown WE Jr. Bacterial intracranial aneurysm. *J Neurosurg*. (1978). , 48(3), 369-382.
- [26] Jones HR JrSiekert RG. Neurological manifestations of infective endocarditis. Review of clinical and therapeutic challenges. *Brain*. (1989). Pt 5):1295-1213.
- [27] Leo, P. J, Pearl, J, & Tsang, W. Mycotic aneurysm: a diagnostic challenge. *Am J Emerg Med*. (1996). , 14(1), 70-73.
- [28] Cloft, H. J, Kallmes, D. F, Jensen, M. E, Lanzino, G, & Dion, J. E. Endovascular treatment of ruptured, peripheral cerebral aneurysms: parent artery occlusion with short guglielmi detachable coils. *AJNR Am J Neuroradiol*. (1999). , 20(2), 308-310.
- [29] Shaikholeslami, R, Tomlinson, C. W, Teoh, K. H, Molot, M. J, & Duke, R. J. Mycotic aneurysm complicating staphylococcal endocarditis. *Can J Cardiol*. (1999). , 15(2), 217-222.
- [30] Ziment, I. Nervous system complications in bacterial endocarditis. *Am J Med*. (1969). , 47(4), 593-607.
- [31] Walsh, D. W, Ho, V. B, & Haggerty, M. F. Mycotic aneurysm of the aorta: MRI and MRA features. *J Magn Reson Imaging*. (1997). , 7(2), 312-315.

- [32] Huston, J. rd, Nichols DA, Luetmer PH, et al. Blinded prospective evaluation of sensitivity of MR angiography to known intracranial aneurysms: importance of aneurysm size. *AJNR Am J Neuroradiol.* (1994). , 15(9), 1607-1614.
- [33] Schwartz, R. B, Tice, H. M, Hooten, S. M, Hsu, L, & Stieg, P. E. Evaluation of cerebral aneurysms with helical CT: correlation with conventional angiography and MR angiography. *Radiology.* (1994). , 192(3), 717-722.
- [34] Benjamin, M. E. Cohn EJ Jr, Purtill WA, Hanna DJ, Lilly MP, Flinn WR. Arterial reconstruction with deep leg veins for the treatment of mycotic aneurysms. *J Vasc Surg.* (1999). , 30(6), 1004-1015.
- [35] Johnston, S. C, Wilson, C. B, Halbach, V. V, et al. Endovascular and surgical treatment of unruptured cerebral aneurysms: comparison of risks. *Ann Neurol.* (2000). , 48(1), 11-19.
- [36] Bederson, J. B, Awad, I. A, Wiebers, D. O, et al. Recommendations for the management of patients with unruptured intracranial aneurysms: a statement for healthcare professionals from the Stroke Council of the American Heart Association. *Stroke.* (2000). , 31(11), 2742-2750.
- [37] Johnston, S. C, Zhao, S, Dudley, R. A, Berman, M. F, & Gress, D. R. Treatment of unruptured cerebral aneurysms in California. *Stroke.* (2001). , 32(3), 597-605.
- [38] Brown, S. L, Busuttil, R. W, Baker, J. D, Machleder, H. I, Moore, W. S, & Barker, W. F. Bacteriologic and surgical determinants of survival in patients with mycotic aneurysms. *J Vasc Surg.* (1984). , 1(4), 541-547.
- [39] Brouwer, R. E, Van Bockel, J. H, & Van Dissel, J. T. *Streptococcus pneumoniae*, an emerging pathogen in mycotic aneurysms? *Neth J Med.* (1998). , 52(1), 16-21.
- [40] Ballet, M, Gevigney, G, Gare, J. P, Delahaye, F, Etienne, J, & Delahaye, J. P. Infective endocarditis due to *Streptococcus bovis*. A report of 53 cases. *Eur Heart J.* (1995). , 16(12), 1975-1980.
- [41] Murray, H. W, & Roberts, R. B. *Streptococcus bovis* bacteremia and underlying gastrointestinal disease. *Arch Intern Med.* (1978). , 138(7), 1097-1099.
- [42] Selton-suty, C, Hoen, B, Delahaye, F, et al. Comparison of infective endocarditis in patients with and without previously recognized heart disease. *Am J Cardiol.* (1996). , 77(12), 1134-1137.
- [43] Cabell, C. H, Jollis, J. G, Peterson, G. E, et al. Changing patient characteristics and the effect on mortality in endocarditis. *Arch Intern Med.* (2002). , 162(1), 90-94.
- [44] Roberts, R. B. Streptococcal endocarditis: the viridans and beta hemolytic streptococci. In: Kaye D, ed. *Infective Endocarditis*. 2nd ed. New York: Raven Press; (1992).

- [45] Hoen, B, Briancon, S, Delahaye, F, et al. Tumors of the colon increase the risk of developing *Streptococcus bovis* endocarditis: case-control study. *Clin Infect Dis.* (1994). , 19(2), 361-362.
- [46] Zarkin, B. A, Lillemoe, K. D, Cameron, J. L, Effron, P. N, Magnuson, T. H, & Pitt, H. A. The triad of *Streptococcus bovis* bacteremia, colonic pathology, and liver disease. *Ann Surg.* (1990). , 211(6), 786-791.
- [47] Kupferwasser, I, Darius, H, Muller, A. M, et al. Clinical and morphological characteristics in *Streptococcus bovis* endocarditis: a comparison with other causative microorganisms in 177 cases. *Heart.* (1998). , 80(3), 276-280.
- [48] Friedrich, I. A, Wormser, G. P, & Gottfried, E. B. The association of remote *Streptococcus bovis* bacteremia with colonic neoplasia. *Am J Gastroenterol.* (1982). , 77(2), 82-84.
- [49] Kodo, K, Hida, M, Omori, S, Mori, T, Tokumura, M, Kuramochi, S, et al. Vasculitis associated with septicemia: case report and review of the literature. *Pediatr Nephrol* (2001). , 16, 1089-1092.
- [50] Conti, T, & Barnet, B. The diagnostic challenge of infective endocarditis: cutaneous vasculitis leading to the diagnosis of infective endocarditis. *J Am Board Fam Pract* (2001). , 14, 451-456.
- [51] Mylonakis E CSBInfective endocarditis in adults. *N Engl J Med* (2001). Steitz A, Orth T, Feddersen A, Fischer T, Marker-Hermann E, Husmann M. A case of endocarditis with vasculitis due to *Actinobacillus actinomycetemcomitans*: a 16S rDNA signature for distinction from related organisms. *Clin Infect Dis* 1998; 27:224-225., 345(18), 1318-1330.
- [52] Steitz, A, Orth, T, Feddersen, A, Fischer, T, Marker-hermann, E, & Husmann, M. A case of endocarditis with vasculitis due to *Actinobacillus actinomycetemcomitans*: a 16S rDNA signature for distinction from related organisms. *Clin Infect Dis* (1998). , 27, 224-225.
- [53] Cohen, C. A, Almeder, L. M, Israni, A, & Maslow, J. N. *Clostridium septicum* endocarditis complicated by aortic-ring abscess and aortitis. *Clin Infect Dis* (1998). , 26, 495-496.
- [54] Elzouki, A. Y, Akthar, M, & Mirza, K. Brucella endocarditis associated with glomerulonephritis and renal vasculitis. *Pediatr Nephrol* (1996). , 10, 748-751.
- [55] Bani-sadr, F, Hamidou, M, Richard, P, Tiab, M, Lalande, S, & Grolleau, J. Y. Cutaneous vasculitis and acute renal failure disclosing endocarditis caused by *Actinobacillus actinomycetemcomitans*. *Presse Med* (1993).
- [56] Gladstone, J. L, Friedman, S. A, Cerruti, M. M, & Jomain, S. L. Treatment of *Candida* endocarditis and arteritis. *J Thorac Cardiovasc Surg* (1976). , 71, 835-838.

- [57] Martinez, A. J, Sotelo-avila, C, Alcala, H, & Willaert, E. Granulomatous encephalitis, intracranial arteritis, and mycotic aneurysm due to a free-living ameba. *Acta Neuropathol (Berl)* (1980). , 49, 7-12.
- [58] Vyas, S. K, Law, N. W, & Loehry, C. A. Mycotic aneurysm of left subclavian artery. *Br Heart J* (1993). , 69, 455-456.
- [59] Jenckes GA III *Aspergillus* aortitis. *J Thorac Cardiovasc Surg* (1990). , 99, 375-376.
- [60] Julke, M, & Leu, H. J. Extra-aortic aneurysms. Analysis of 163 aneurysms in 142 patients). *Schweiz Med Wochenschr* (1985). , 115, 10-13.
- [61] La Civita LFadda P, Olivieri I, Ferri C. Cryoglobulinaemic vasculitis as presenting manifestation of infective endocarditis. *Ann Rheum Dis* (2002). , 61, 89-90.
- [62] Yerly, P, Chuard, C, Pugin, P, & Regamey, C. Cryoglobulins and endocarditis, a case report.) *Rev Med Suisse Romande* (2001). , 121, 573-576.
- [63] Agarwal, A, Clements, J, Sedmak, D. D, & Imler, D. Nahman NS Jr, Orsinelli DA, et al. Subacute bacterial endocarditis masquerading as type III essential mixed cryoglobulinemia. *J Am Soc Nephrol* (1997). , 8, 1971-1976.
- [64] Lum, P. N, Woo, P. C, Wong, S. S, & Yuen, K. Leukocytoclastic vasculitis complicating *Klebsiella pneumoniae* bacteremia. *Diagn Microbiol Infect Dis* (2000). , 37, 275-277.
- [65] Garcia-porrúa, C, & Gonzalez-gay, M. A. Bacterial infection presenting as cutaneous vasculitis in adults. *Clin Exp Rheumatol* (1999). , 17, 471-473.
- [66] Houston, T. P. Small-vessel vasculitis following simultaneous influenza and pneumococcal vaccination. *N Y State J Med* (1983). , 83, 1182-1183.
- [67] David, J, Ansell, B. M, & Woo, P. Polyarteritis nodosa associated with streptococcus. *Arch Dis Child* (1993). , 69, 685-688.
- [68] Walker, D. H, Cain, B. G, & Olmstead, P. M. Laboratory diagnosis of Rocky Mountain spotted fever by immunofluorescent demonstration of *Rickettsia* in cutaneous lesions. *Am J Clin Pathol* (1978). , 69, 619-623.
- [69] George, F, Brouqui, P, Boffa, M. C, Mutin, M, Drancourt, M, Brisson, C, et al. Demonstration of *Rickettsia conorii*-induced endothelial injury in vivo by measuring circulating endothelial cells, thrombomodulin, and von Willebrand factor in patients with Mediterranean spotted fever. *Blood* (1993). , 82, 2109-2116.
- [70] Davi, G, Giammarresi, C, Vigneri, S, Ganci, A, & Ferri, C. Di Francesco L, et al. Demonstration of *Rickettsia conorii*-induced coagulative and platelet activation in vivo in patients with Mediterranean spotted fever. *Thromb Haemost* (1995). , 74, 631-634.
- [71] *Clin Dev Immunol*(2004). Sep-Dec;11(3-4):227-31
- [72] Reich, J. M. Pulmonary gangrene and the air crescent sign. *Thorax* (1993). , 48, 70-74.

- [73] Henocq, E, Hutinel, B, Jacob, J, & Olivier, C. Immunopathologic aspects of recurrent phlebitis and nodular vasculitis. Therapeutic applications). *Phlebologie* (1976). , 29, 125-132.
- [74] Strnad, B. T, McGraw, J. K, Heatwole, E. V, & Clark, P. Tuberculous aneurysm of the aorta presenting with uncontrolled hypertension. *J Vasc Interv Radiol* (2001). , 12, 521-523.
- [75] Allins, A. D, Wagner, W. H, Cossman, D. V, Gold, R. N, & Hiatt, J. R. Tuberculous infection of the descending thoracic and abdominal aorta: case report and literature review. *Ann Vasc Surg* (1999). , 13, 439-444.
- [76] Tuder, R. M, Renya, G. S, & Bensch, K. Mycobacterial coronary arteritis in a heart transplant recipient. *Hum Pathol* (1986). , 17, 1072-1074.
- [77] Nenoff, P, Kellermann, S, Horn, L. C, Keiner, S, Bootz, F, & Schneider, S. al. Case report. Mycotic arteritis due to *Aspergillus fumigatus* in a diabetic with retrobulbar aspergillosis and mycotic meningitis. *Mycoses* (2001). , 44, 407-414.
- [78] Oaks, T. E, Pae, W. E, Pennock, J. L, Myers, J. L, & Pierce, W. S. Aortic rupture caused by fungal aortitis: successful management after heart transplantation. *J Heart Transplant* (1988). , 7, 162-164.
- [79] De Carvalho, C. A, Allen, J. N, Zafranis, A, & Yates, A. J. Coccidioidal meningitis complicated by cerebral arteritis and infarction. *Hum Pathol* (1980). , 11, 293-296.
- [80] Kobayashi, R. M, Coel, M, Niwayama, G, & Trauner, D. Cerebral vasculitis in coccidioidal meningitis. *Ann Neurol* (1977). , 1, 281-284.
- [81] Whitaker, D. C, & Lynch, P. J. Erythema nodosum and coccidioidomycosis. *Ariz Med* (1979). , 36, 887-889.
- [82] Body, B. A. Cutaneous manifestations of systemic mycoses. *Dermatol Clin* (1996). , 14, 125-135.
- [83] Mastrolonardo, M, Loconsole, F, Conte, A, & Rantuccio, F. Cutaneous vasculitis as the sole manifestation of disseminated gonococcal infection: case report. *Genitourin Med* (1994). , 70, 130-131.
- [84] Garcia-patos, V, Barnadas, M. A, Domingo, P, Esquiús, J, & De Moragas, J. M. Cutaneous vasculitis during bacteremia caused by meningococcus serogroup B). *Rev Clin Esp* (1992). , 190, 311-313.
- [85] Dearaujomartins-romeo, D, Garcia-porrúa, C, & Gonzalez-gay, M. A. Cutaneous vasculitis is not always benign. *Rev Rhum Engl Ed* (1999).
- [86] Seaton, R. A, Nathwani, D, Dick, J, & Smith, D. Acute meningococcaemia complicated by late onset gastrointestinal vasculitis. *J Infect* (2000). , 41, 190-191.

- [87] Versapuech, J, Leaute-labreze, C, Thedenat, B, Taieb, A, & Ragnaud, J. M. Ecthyma gangrenosum caused by *Pseudomonas aeruginosa* without septicemia in a neutropenic patient). Rev Med Interne (2001). , 22, 877-880.
- [88] Bonduel, M, Santos, P, Turienzo, C. F, Chantada, G, & Paganini, H. Atypical skin lesions caused by *Curvularia* sp. and *Pseudallescheria boydii* in two patients after allogeneic bone marrow transplantation. Bone Marrow Transplant (2001). , 27, 1311-1313.
- [89] Mull, C. C, Scarfone, R. J, & Conway, D. Ecthyma gangrenosum as a manifestation of *Pseudomonas* sepsis in a previously healthy child. Ann Emerg Med (2000). , 36, 383-387.
- [90] Wu, B. Y, Peng, C. T, Tsai, C. H, & Chiu, H. H. Community-acquired *Pseudomonas aeruginosa* bacteremia and sepsis in previously healthy infants. Acta Paediatr Taiwan (1999). , 40, 233-236.
- [91] Fergie, J. E, Huang, D. B, Purcell, K, & Milligan, T. Successful treatment of *Fusarium solanae* ecthyma gangrenosum in a child with acute lymphoblastic leukemia in relapse. Pediatr Infect Dis J (2000). , 19, 579-581.
- [92] Del Pozo JGarcia-Silva J, Almagro M, Martinez W, Nicolas R, Fonseca E. Ecthyma gangrenosum-like eruption associated with *Morganella morganii* infection. Br J Dermatol (1998). , 139, 520-521.
- [93] Burgner, D, Eagles, G, Burgess, M, Procopis, P, Rogers, M, Muir, D, et al. Disseminated invasive infection due to *Metarrhizium anisopliae* in an immunocompromised child. J Clin Microbiol (1998). , 36, 1146-1150.
- [94] Repiso, T, Garcia-patos, V, Martin, N, Creus, M, Bastida, P, & Castells, A. Disseminated fusariosis. Pediatr Dermatol (1996). , 13, 118-121.
- [95] Martino, P, Gastaldi, R, Racciah, R, & Girmenia, C. Clinical patterns of *Fusarium* infections in immunocompromised patients. J Infect Dis (1994). Suppl 1):7-15.
- [96] Jang, T. N, Wang, F. D, Wang, L. S, Liu, C. Y, & Liu, I. M. *Xanthomonas maltophilia* bacteremia: an analysis of 32 cases. J Formos Med Assoc (1992). , 91, 1170-1176.
- [97] Stotka, J. L, & Rupp, M. E. *Klebsiella pneumoniae* urinary tract infection complicated by endophthalmitis, perinephric abscess, and ecthyma gangrenosum. South Med J (1991). , 84, 790-793.
- [98] Edelstein, H, & Cutting, H. O. *Escherichia coli* as cause of ecthyma gangrenosum. Postgrad Med (1986). , 79, 44-45.
- [99] Harris, R. L, Fainstein, V, Elting, L, Hopfer, R. L, & Bodey, G. P. Bacteremia caused by *Aeromonas* species in hospitalized cancer patients. Rev Infect Dis (1985). , 7, 314-320.
- [100] Cheng, T. O. Syphilitic aortitis is dying but not dead. Catheter Cardiovasc Interv (2001). , 52, 240-241.

- [101] Aizawa, H, Hasegawa, A, Arai, M, Naganuma, F, Hatori, M, Kanda, T, et al. Bilateral coronary ostial stenosis and aortic regurgitation due to syphilitic aortitis. *Intern Med* (1998). , 37, 56-59.
- [102] Samson, L, Chalaoui, J, & Paradis, B. Case of the day. General. Syphilitic aortitis, with saccular aneurysm of the descending aorta and fusiform aneurysm of the ascending aorta. *Radiographics* (1990). , 10, 508-510.
- [103] Oksi, J, Kalimo, H, Marttila, R. J, Marjamaki, M, Sonninen, P, Nikoskelainen, J, et al. Intracranial aneurysms in three patients with disseminated Lyme borreliosis: cause or chance association? *J Neurol Neurosurg Psychiatry* (1998). , 64, 636-642.
- [104] Keil, R, Baron, R, Kaiser, R, & Deuschl, G. Vasculitis course of neuroborreliosis with thalamic infarct). *Nervenarzt* (1997). , 68, 339-341.
- [105] Oksi, J, Kalimo, H, Marttila, R. J, Marjamaki, M, Sonninen, P, Nikoskelainen, J, et al. Inflammatory brain changes in Lyme borreliosis. A report on three patients and review of literature. *Brain* (1996). , 119, 2143-2154.
- [106] Leys, A. M, Schonherr, U, Lang, G. E, Naumann, G. O, Goubau, P, Honore, A, et al. Retinal vasculitis in Lyme borreliosis. *Bull Soc Belge Ophtalmol* (1995). , 259, 205-214.
- [107] Giang, D. W. Central nervous system vasculitis secondary to infections, toxins, and neoplasms. *Semin Neurol* (1994). , 14, 313-319.
- [108] Smith, J. L, Winward, K. E, Nicholson, D. F, & Albert, D. W. Retinal vasculitis in Lyme borreliosis. *J Clin Neuroophthalmol* (1991). , 11, 7-15.
- [109] Lang, G. E, Schonherr, U, & Naumann, G. O. Retinal vasculitis with proliferative retinopathy in a patient with evidence of *Borrelia burgdorferi* infection. *Am J Ophthalmol* (1991). , 111, 243-244.
- [110] Pizzarello, L. D. MacDonald AB, Semlear R, DiLeo F, Berger B. Temporal arteritis associated with *Borrelia* infection. A case report. *J Clin Neuroophthalmol* (1989). , 9, 3-6.
- [111] Lock, G, Berger, G, & Grobe, H. Neuroborreliosis: progressive encephalomyelitis with cerebral vasculitis). *Monatsschr Kinderheilkd* (1989). , 137, 101-104.
- [112] Veenendaal-hilbers, J. A, Perquin, W. V, Hoogland, P. H, & Doornbos, L. Basal meningovascularitis and occlusion of the basilar artery in two cases of *Borrelia burgdorferi* infection. *Neurology* (1988). , 38, 1317-1319.
- [113] Meier, C, & Grehl, H. Vasculitic neuropathy in the Garin-Bujadoux- Bannwarth syndrome. A contribution to the understanding of the pathology and pathogenesis of the neurological complications in Lyme borreliosis). *Dtsch Med Wochenschr* (1988). , 113, 135-138.
- [114] Uldry, P. A, Regli, F, & Bogousslavsky, J. Cerebral angiopathy and recurrent strokes following *Borrelia burgdorferi* infection. *J Neurol Neurosurg Psychiatry* (1987). , 50, 1703-1704.

- [115] MacDonald AB Giant cell arteritis and *Borrelia* infection. J Clin Neuroophthalmol (1987). , 7, 180-181.
- [116] Camponovo, F, & Meier, C. Neuropathy of vasculitic origin in a case of Garin-Bouja-doux-Bannwarth syndrome with positive *Borrelia* antibody response. J Neurol (1986). , 233, 69-72.
- [117] Caruso, J. M, Tung, G. A, & Brown, W. D. Central nervous system and renal vasculitis associated with primary varicella infection in a child. Pediatrics (2001). E9.
- [118] Koo, E. H, & Massey, E. W. Granulomatous angiitis of the central nervous system: protean manifestations and response to treatment. J Neurol Neurosurg Psychiatry (1988). , 51, 1126-1133.
- [119] Schmitt, J. A, Dietzmann, K, Muller, U, & Krause, P. Granulomatous vasculitis-an uncommon manifestation of herpes simplex infection of the central nervous system). Zentralbl Pathol (1992). , 138, 298-302.
- [120] Shiozi, Y, Takeshima, M, Itoshima, T, Nose, S, & Hamaya, K. Granulomatous angiitis of the central nervous system complicated by the syndrome of inappropriate antidiuretic hormone). No To Shinkei (1995). , 47, 595-599.
- [121] Ban, S, Goto, Y, Kamada, K, Takahama, M, Watanabe, H, Iwahori, T, et al. Systemic granulomatous arteritis associated with Epstein-Barr virus infection. Virchows Arch (1999). , 434, 249-254.
- [122] Lande, M. B, Mowry, J. A, & Houghton, D. C. White CR Jr, Borzy MS. Immune complex disease associated with Epstein-Barr virus infectious mononucleosis. Pediatr Nephrol (1998). , 12, 651-653.
- [123] Murakami, K, Ohsawa, M, Hu, S. X, Kanno, H, Aozasa, K, & Nose, M. Large-vessel arteritis associated with chronic active Epstein-Barr virus infection. Arthritis Rheum (1998). , 41, 369-373.
- [124] Nakagawa, A, Ito, M, Iwaki, T, Yatabe, Y, Asai, J, & Hayashi, K. Chronic active Epstein-Barr virus infection with giant coronary aneurysms. Am J Clin Pathol (1996). , 105, 733-736.
- [125] Muso, E, Fujiwara, H, Yoshida, H, Hosokawa, R, Yashiro, M, Hongo, Y, et al. Epstein-Barr virus genome-positive tubulointerstitial nephritis associated with Kawasaki disease-like coronary aneurysms. Clin Nephrol (1993). , 40, 7-15.
- [126] Kikuta, H, Sakiyama, Y, Matsumoto, S, Hamada, I, Yazaki, M, Iwaki, T, et al. Detection of Epstein-Barr virus DNA in cardiac and aortic tissues from chronic, active Epstein-Barr virus infection associated with Kawasaki disease-like coronary artery aneurysms. J Pediatr (1993). , 123, 90-92.
- [127] Cohen, P, & Guillevin, L. Presse Med. (2004). Nov 6;33(19 Pt 2):1371-84.

- [128] Naides, S. J. Rheumatic manifestations of parvovirus B19 infection. *Rheum Dis Clin North Am* (1998). , 24, 375-401.
- [129] Aygoren-pursun, E, & Scharrer, I. A multicenter pharmacosurveillance study for the evaluation of the efficacy and safety of recombinant factor VIII in the treatment of patients with hemophilia A. German Kogenate Study Group. *Thromb Haemost* (1997). , 78, 1352-1356.
- [130] Corman, L. C, & Dolson, D. J. Polyarteritis nodosa and parvovirus B19 infection. *Lancet* (1992).
- [131] Delannoy, D, Balquet, M. H, & Savinel, P. Vasculitis with mixed cryoglobulin in a case of human parvovirus B19 infection. *Presse Med* (1993).
- [132] Finkel, T. H, Torok, T. J, Ferguson, P. J, Durigon, E. L, Zaki, S. R, et al. Chronic parvovirus B19 infection and systemic necrotizing vasculitis: opportunistic infection or aetiological agent? *Lancet* (1994). , 343, 1255-1258.
- [133] Martinelli, C, Azzi, A, Buffini, G, Comin, C. E, & Leoncini, F. Cutaneous vasculitis due to human parvovirus B19 in an HIV-infected patient: report of a case. *AIDS* (1997). , 11, 1891-1893.
- [134] Erdman, D. D, Anderson, B. C, Torok, T. J, Finkel, T. H, & Anderson, L. J. Possible transmission of parvovirus B19 from intravenous immune globulin. *J Med Virol* (1997). , 53, 233-236.
- [135] Prowse, C, Ludlam, C. A, & Yap, P. L. Human parvovirus B19 and blood products. *Vox Sang* (1997). , 72, 1-10.
- [136] Yee, T. T, Cohen, B. J, Pasi, K. J, & Lee, C. A. Transmission of symptomatic parvovirus B19 infection by clotting factor concentrate. *Br J Haematol* (1996). , 93, 457-459.
- [137] Flunker, G, Peters, A, Wiersbitzky, S, Modrow, S, & Seidel, W. Persistent parvovirus B19 infections in immunocompromised children. *Med Microbiol Immunol* (1998). , 186, 189-194.
- [138] Inman, R. D, Hodge, M, Johnston, M. E, Wright, J, & Heathcote, J. Arthritis, vasculitis, and cryoglobulinemia associated with relapsing hepatitis A virus infection. *Ann Intern Med* (1986). , 105, 700-703.
- [139] Press, J, Maslovitz, S, & Avinoach, I. Cutaneous necrotizing vasculitis associated with hepatitis A virus infection. *J Rheumatol* (1997). , 24, 965-967.
- [140] Costa, M. M, Lisboa, M, Romeu, J. C, Caldeira, J, & De Q, V. Henoch-Schönlein purpura associated with coxsackie-virus B1 infection. *Clin Rheumatol* (1995). , 14, 488-490.
- [141] Okano, M, Thiele, G. M, Sakiyama, Y, Matsumoto, S, & Purtilo, D. T. Adenovirus infection in patients with Kawasaki disease. *J Med Virol* (1990). , 32, 53-57.

- [142] Embil, J. A, Mcfarlane, E. S, Murphy, D. M, Krause, V. W, & Stewart, H. B. Adenovirus type 2 isolated from a patient with fatal Kawasaki disease. *Can Med Assoc J* (1985).
- [143] Chia, J. K, & Bold, E. J. Life-threatening leukocytoclastic vasculitis with pulmonary involvement due to echovirus 7. *Clin Infect Dis* (1998). , 27(5), 1326-1327.
- [144] Riikonen, R. S. Retinal vasculitis caused by rubella. *Neuropediatrics* (1995). , 26, 174-176.
- [145] Duhaut, P, Bosshard, S, Calvet, A, Pinede, L, Demolombe-rague, S, Dumontet, C, et al. Giant cell arteritis, polymyalgia rheumatica, and viral hypotheses: a multicenter, prospective case-control study. *Groupe de Recherche sur l'Arterite a Cellules Geantes. J Rheumatol* (1999). , 26, 361-369.
- [146] Forster, W, Bialasiewicz, A. A, Busse, H, & Coxsackievirus, B. associated panuveitis. *Br J Ophthalmol* (1993). , 77, 182-183.
- [147] Corbeel, L, Gewillig, M, & Baeten, E. Casteels-Van Daele M, Eggermont E. Carotid and coronary artery involvement in infantile periarteritis nodosa possibly induced by Coxsackie B4 infection. Favourable course under corticosteroid treatment. *Eur J Pediatr* (1987). , 146, 441-442.
- [148] Roden, V. J, Cantor, H. E, Connor, O, Schmidt, D. M, & Cherry, R. R. JD. Acute hemiplegia of childhood associated with Coxsackie A9 viral infection. *J Pediatr* (1975). , 86, 56-58.
- [149] Hamidou, M. A, Gueglio, B, Cassagneau, E, Trewick, D, & Grolleau, J. Y. Henoch-Schönlein purpura associated with *Toxocara canis* infection. *J Rheumatol* (1999). , 26, 443-445.
- [150] Revuelta, R, Juambelz, P, Balderrama, J, & Teixeira, F. Contralateral trigeminal neuralgia: a new clinical manifestation of neurocysticercosis: case report. *Neurosurgery* (1995). , 37, 138-139.
- [151] Pirisi, M, Gutierrez, Y, Minini, C, Dolcet, F, Beltrami, C. A, Pizzolito, S, et al. Fatal human pulmonary infection caused by an *Angiostrongylus*-like nematode. *Clin Infect Dis* (1995). , 20, 59-65.