

# We are IntechOpen, the world's leading publisher of Open Access books Built by scientists, for scientists

6,900

Open access books available

185,000

International authors and editors

200M

Downloads

Our authors are among the

154

Countries delivered to

TOP 1%

most cited scientists

12.2%

Contributors from top 500 universities



WEB OF SCIENCE™

Selection of our books indexed in the Book Citation Index  
in Web of Science™ Core Collection (BKCI)

Interested in publishing with us?  
Contact [book.department@intechopen.com](mailto:book.department@intechopen.com)

Numbers displayed above are based on latest data collected.  
For more information visit [www.intechopen.com](http://www.intechopen.com)



---

# Kidney Transplantation Techniques

---

Farzad Kakaei, Saman Nikeghbalian and  
Seyed Ali Malekhosseini

Additional information is available at the end of the chapter

<http://dx.doi.org/10.5772/54829>

---

## 1. Introduction

First successful kidney transplantation was done over 60 years ago and now because of major advances in immunosuppressive medicine, this represents the treatment of choice for patients with end-stage renal disease (ESRD). The kidney was the first organ to be transplanted regularly, and it remains the most common organ transplanted today but the surgical technique has changed very little from the original pelvic operation during this long period.

In most cases kidney is placed retroperitoneally and the iliac arteries and veins are used for perfusion of this organ and the ureter is transplanted directly to the bladder. But the sophisticated intensive care units and advanced perioperative anesthetic techniques lead to the use of more marginal donors for more complicated recipients. Now using a kidney graft from a donor after cardiac death or proceeding to kidney transplantation as a part of multivisceral or other abdominal organ transplantation is a routine procedure in the major transplant centers of the world. In such conditions the kidney grafts are not harvested in an optimized preoperative planning and may be damaged during the surgery. Then we may confront with a graft with 2 or more delicate or very short arteries or veins, ruptured capsule or transected ureter. We may use grafts with congenital anomalies such as horseshoe kidneys or duplicated ureteral system. Also the recipient procedure may be her or his second, third or more transplantation surgery and no more iliac vessels remained for anastomosis and the bladder may be so damaged that makes the anastomosis of the ureter to the bladder impossible. The transplant surgeon should always be ready to conquer such challenges. Using an intraperitoneal space, using the aorta or inferior vena cava or other major arteries and veins such as splenic vessels, and the native ureters for reconstruction of the urine outflow should be an in-hand procedure for every transplant surgeon.

In this chapter we will review basic steps of the standard approach to recipient's procedure from preparing the graft, then the skin incision till the skin closure with special attention to basic vascular and urinary tract re-establishment techniques and also intraoperative care of the patient. Then we proceed to the special and unusual situations including: complex vascular and ureteral reconstruction techniques, using kidneys with congenital and other anatomical anomalies, en bloc double kidney transplantation, using other vasculature for transplanting the kidney in different intraperitoneal spaces, and kidney transplantation conjoint with other abdominal organs.

## 2. Graft preparation

Preservation of the viability of the graft during the time between explantation and implantation is vital for early and late graft function after transplantation. Most kidney transplant teams consist of at least two separate groups. One group prepares the donor and the other team is doing the recipient operation at the same time or with some delay depending on the duration needs for transferring the graft from the donor operating room to the recipient operation theatre. In many countries such as the United States or in the Euro Zone the kidney grafts from the deceased donors are transferred between hospitals, cities or even countries according to the Human Leukocyte Antigen (HLA) matching or other important criteria for attributing the graft to a preferred recipient. In such conditions it's better to use every effort to improve the graft longevity. Using better preservation solutions or automatic machine perfusion systems are among the routine measurements in such conditions which are discussed in other chapters of this book. The surgeons and coordinators should shorten the ischemic time of the graft as long as possible and during all of this period the temperature of the graft should be maintained between 1-4° centigrade to decrease the injury to the graft.

Simple hypothermia is not enough for preserving the viability of the graft and evacuation of the graft blood and replacing it with a preservation solution is a mandatory step in the graft preparation. Graft cold irrigation in the deceased donors is done during the harvesting operation by irrigation of the clamped aorta and the solution used for this irrigation may be any of the pre-prepared solutions such as Belzer University of Wisconsin's (UW), Histidine-Tryptophan-Ketoglutarate (HTK, Bretschneider or Custodiol), Euro-Collins, Celsior or other newer solutions such as Biolasol® (Dolińska B, et al, 2012)[1]. Table 1 shows the compositions of some of these solutions. All of the blood should be evacuated from the graft during this phase. In the living donor, all of the irrigation is done after removing the graft the donor body in an iced cold basin. In the countries that the living donor still forms over 75% of the donor pool such as China or India, irrigation of the living donor graft is done by more simple solutions such as lactated Ringer's solution and many studies shows that when the total ischemic time is less than 60 minutes (as in most living donor programs) the long-term graft survival is not impacted significantly by using these simple solutions comparing with more complex solutions (Prasad GS, et al, 2007)[2]. In our center we add lidocaine (100 mg/liter), sodium bicarbonate (10 meq/liter) and heparin (5000 IU/liter) to this simple solution. Also, we use intravenous Mannitol and Furosemide in the donor just before the arterial clamping for better diuresis before nephrectomy.

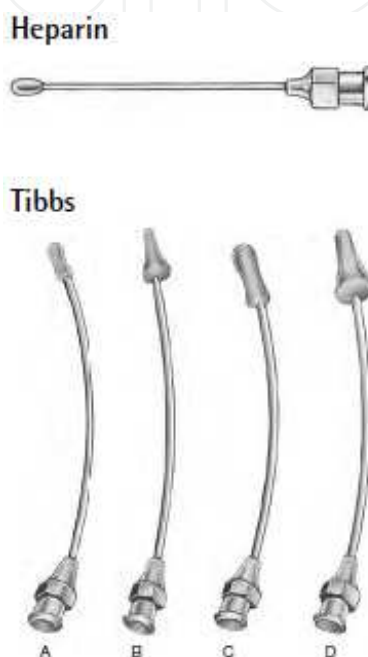
Name	Composition	Claimed advantages
<b>Belzer UW solution (Viaspan®)</b>	Potassium lactobionate: 100 mmol/l KH <sub>2</sub> PO <sub>4</sub> : 25 mmol/l MgSO <sub>4</sub> : 5 mmol/l Raffinose: 30 mmol/l Adenosine: 5 mmol/l Glutathione: 3 mmol/l Allopurinol: 1 mmol/l Hydroxyethyl starch: 50 g/l	Allows for kidney preservation time up to 48 hours Allows for liver preservation time up to 24 hours Allows for pancreas preservation time up to 24 hours Provides enough time to admit patients from distant locations Provides enough time to improve recipient matching Provides enough time to operate in a semi-elective situation
<b>Histidine-Tryptophan-Ketoglutarate (Custodiol®)</b>	Sodium chloride: 15 mmol/l Potassium chloride: 9 mmol/l Potassium hydrogen 2-Ketoglutarate: 1mmol/l Magnesium chloride: 4 mmol/l Histidine · HCl:18.0 mmol/l Histidine: 180 mmol/l Tryptophan: 2 mmol/l Mannitol: 30 mmol/l Calcium chloride: 0.015 mmol/l	Rapid homogenous cooling due to low viscosity Superior recovery of function Excellent ischemic tolerance Virtual absence of side effects Simple perfusion technique (ready-to-use, no additives or preparation)
<b>Celsior</b>	Mannitol 60 mmol/l Lactobionic Acid 80 mmol/l Glutamic Acid 20 mmol/l Histidine 30 mmol/l Calcium Chloride 0.25 mmol/l Potassium Chloride 15 mmol/l Magnesium Chloride 13 mmol/l Sodium Hydroxide 100 mmol/l Reduced Glutathione 3 mmol/l	low potassium comparing with UW prevention of tissue edema prevention of free radical damage prevention of calcium overload with adequate buffer Better for heart and lung transplantation (as depicted by its manufacturer, Genzyme)
<b>Euro-Collins (Renograf®)</b>	Potassium phosphate 42.5 mmol.l Potassium chloride 15 mmol/l Sodium bicarbonate 10 mmol/l Anhydrous glucose 35 g/l Mannitol 31.7 mmol/l Raffinose 3.5 mmol/l	Preserves the kidney up to 48 hours An out of date solution in most US and European centers

**Table 1.** Composition of the more common organ preservation solutions.

When possible, the donor team should report the detailed graft anatomy (including number of arteries, veins and ureters and any anatomical anomaly or inadvertent injury to the graft during the donor operation) to the recipient team, especially when the graft is transferred from another hospital locally or regionally. It is very important to prevent any more injury to the graft and its capsule, vessels or ureter during the back table procedure, especially in case of deceased donor grafts which usually accompanied with other abdominal organs or at least covered by the peritoneum or peri-renal fats or other non-important tissues. Direct contact of the ice with the graft should be prevented by inserting the graft in a separate basin or organ bag filled with a cold solution and then inserting this bag in another iced filled basin.

First of all, for irrigation of the living donor graft, the surgeon should find the artery and canulate it with an atraumatic olive-headed heparin irrigation needle as shown in figure 1. Using other devices such as Angiocath®, Baranule® or any types of intravenous needles for

irrigation should be discouraged because of risk of intimal injury induced by such cannulas. In many cases, it may be difficult to find the artery first because it is hidden by other hilar tissues or retracted to the deeper hilar areas of the graft. In such conditions the irrigation may be started by cannulation the more accessible renal vein, till the surgeon finds the artery. All the dissections should better be done after complete irrigation. At this point all of the renal parenchyma will appear in yellow-pink color. All of the dissections should be done delicately by using atraumatic or microvascular instruments, without any more injury to the vessels intima or their major branches and any more unusual traction of the vessel wall.



**Figure 1.** Special olive-headed needles for irrigation (Courtesy of GEISTER Medizintechnik GmbH, Tuttlingen/ Germany)

When using the left kidney of the living donor the adrenal and gonadal vein should be on the graft in order to have a longer vein for future anastomosis. In both right or left kidneys or living donor or deceased donor grafts, the surgeon should make every effort to preserve the connective tissues between the ureter and the gonadal vein to prevent ischemic injury to the delicate collateral vessels of the ureter. Always the ureter should be accompanied by at least one centimeter of the peri-ureteral tissues and also the hilar inferior triangle (e.g. the window between the inferior pole of the graft and the ureteral origin from the renal pelvis) should be maintained intact. Removing peri-renal fat or other tissues should be postponed till complete renal revascularization. These tissues are protective for handling of the graft and might be used for graft covering or anchoring during or after revascularization.

The window between the renal artery and vein in the renal hilum is full of accessory branches and lymphatic vessel. All of the major arterial branches especially of the inferior pole should be maintained intact. Any injury to this branches leads to regional ischemia or necrosis of the kidney or ureter which may lead to future graft dysfunction or ischemia – induced hypertension in the donor or ureteral necrosis, ureteral anastomosis disruption or urine leakage. Some surgeons

suggest that all of the major lymphatic vessels should be ligated to prevent future lymphocele, however, the most important measurement for preventing the lymphocele is avoiding excessive dissections around the iliac artery during the preparing the implantation site.

The best approach for prevention of arterial branch injury is to start with dissection of the renal vein and follow its wall through the hilum until sufficient length is achieved by ligating the minor veins. We suture-ligate the accessory minor vein branches and also the major lumbar veins by 6-0 Prolene suture for prevention of postoperative bleeding from hilar vessels.

If the graft has more than one artery, vein or ureter, the surgeon should decide which type of reconstruction is suitable according to the condition of the graft and the recipient. In the deceased donor it's better to use a Carrel patch of aorta and inferior vena cava in line with the graft vessels. But this has two major impacts on future graft implantation. First, this results in a longer than usual artery (especially in the right side) or vein (especially in the left side) which may be results in kinking (and future thrombosis or hypertension) after the anastomosis. And second, it will results in a large Carrel patch in some cases. The surgeon has to remove a large patch from the recipient's vessels for a good anastomosis. If complicated by graft non-function, then future removal of the graft will result in a large defect of the recipient vessels which will be dangerous or even limb life threatening. Also, the Carrel patch of the aorta may be severely atherosclerotic and could not be used for a safe anastomosis. Any reconstruction will elongate the total ischemic time of the graft, and we should do every effort to prevent this by postponing unnecessary dissections and reconstructions to the time after at least partial reperfusion of the graft.

According to these important issues, when possible, we prefer to use no reconstruction prior to implantation to decrease the ischemic time. Every transplant surgeon should be fully trained and familiar with microvascular techniques in such conditions. Every arterial branch should be anastomosed separately. The major artery is anastomosed first usually to the internal iliac artery, which provides a longer arterial conduit and allow more free movements of the graft for venous anastomosis. Smaller arteries are anastomosed after reperfusion of the graft to the external iliac artery or even to the smaller arteries such as inferior epigastric artery (El-Sherbiny M, et al, 2008)[3]. When all arterial branches have the same size, then reperfusion is postponed till the end of anastomosis of all of the arterial branches usually to the external iliac artery but if the kidney has a large artery and some other smaller arteries then reperfusion is started after completion of the large artery anastomosis. Arteries less than 1 mm could be ligated specially in the upper pole. Also ligation of the arteries with resultant ischemic area of less than 15% of the upper or middle pole is acceptable and by reducing the total operation duration will reduce the complications in the recipient comparing with adding a long microvascular anastomosis to the operation. Arteries larger than 1 mm in the lower pole should be reperfused by anastomosis if possible to prevent ischemia of the ureter.

If the surgeon decides to reconstruct the arteries before implantation then multiple varieties of techniques could be used: side to side anastomosis of the same size arteries or end to side anastomosis of a small artery to a larger artery. Using microvascular techniques with a good illumination and at least 4.5X magnification and 7-0 or 8-0 Prolene sutures, all of the ties should be placed out of the intimal surface and the lumen should be protected by a smooth metal probe to prevent inadvertent back-wall suturing. In the deceased donor, the surgeon can use



freely every small bifurcated or trifurcated donor artery (such as the celiac artery) for these delicate reconstructions. In such complex situations such as severe atherosclerosis of the renal artery orifice when eversion endarterectomy is not possible (Nghiem DD, Choi SS, 1992) [4] or results in a damaged artery, the best approach for salvage of the graft is transecting the diseased part of the renal artery and using a small branch of the donor artery such as the left gastric or splenic artery as an elongation conduit of the renal artery. In the case of living donors, a short segment of the recipient saphenous vein may be a good choice for this purpose but it has a real risk of future aneurismal transformation in the future (Sharma A, et al, 2010) [5]. Sometimes we could use a combination of these techniques. For example when the graft has 2 large-size and 1 small-size artery, the best option is to perform an anastomosis between the small-size artery and one of the larger size branches and then perform two separate anastomoses in the recipient. This action will reduce the total operative time of the recipient.

Approach to the vein branches is a little different because of intra-parenchymal communications between the vein branches. We could ligate non-major venous branches, but when the vein branches are in the same size we should reconstruct them before venous anastomosis. Some surgeons prefer to mobilize the external iliac vein by ligating the internal iliac vein or superior gluteal vein or other side branches of this vein, but usually these maneuvers are futile in providing better window for venous anastomosis especially when we use the right kidney from a living donor. In such conditions we prefer to perform the venous anastomosis first or placing the graft in an upside down direction (ureter in the upper part) (Webb J et al, 2003) [6]. In the deceased donor, using a part of the donor external iliac, internal jugular or inferior vena cava as an extension graft is more preferable for adding the length of the vein graft. Such reconstructions should be done in the back table prior to implantation.

In our opinion, ureteral reconstruction also should be discouraged in case of multiple graft ureters. When the ureters have insufficient length, or denuded in their entire length, mobilization of the recipient bladder or using of the recipient ureter is preferred.

At the end of graft preparation some authors suggest that the graft should be wrapped in iced or cold saline soaked surgical gauzes or cloth stockinet or surgical glove to remain cold throughout the implantation procedure. In our opinion this is a time consuming and fruitless maneuver when the surgeons could do the anastomoses rapidly. Also using the ice packets in the site of implantation is not necessary.

### 3. Implantation site

So many factors impact the surgeon's decision on which site he could implant the kidney graft (table 2). These factors include: the graft size comparing with the recipient, the size, length and number of graft arteries, veins and/or ureters, previous surgeries (for example previous failed kidney transplantation, previous pelvic exploration for bladder reconstruction or anti-reflux surgeries), associated abdominal organ (liver, pancreas or small bowel) transplantation, laterality of the donor kidney (left or right), anomalies of the donor graft (horseshoe kidney, double pelvis, double ureter, etc.), and at last the number of kidney grafts (double kidney from a pedia-

tric or old age or marginal donor). Traditionally the right iliac fossa is the standard fossa for a kidney transplantation procedure and the left iliac fossa is the preferred site for simultaneous kidney-pancreas transplantation. In the pediatric recipient when the graft is larger than usual we should use the main abdominal fossa for implantation. The most important limiting factor for each of these procedures is the length of the renal vein and also the length of the donor ureter and mobility of the recipient urinary bladder. In most instances when the recipient internal iliac artery is used as the arterial inflow, it provides a good length for mobilization and would not be a limiting factor. The right iliac fossa is the preferred site because of the more superficial position of the external iliac vein. The deep branches of the iliac vein can be suture ligated and cut if more superficialization is needed. If the recipient ureter is not diseased it can be used for urinary outflow reconstruction if the donor ureter is short.

Factor	Preferred Site	Rationale
Graft size comparing with the recipient	Abdominal fossa if the graft is very large	Prevention of kidney compartment syndrome
The size, length and number of graft arteries and veins	Iliac fossa is preferred	Prevention of entering to the abdominal cavity and postoperative ileus
The size, length and number of ureters	Iliac fossa is preferred if the recipient ureter is not diseased. Retrovesical area if the ureters are short but vessels are long enough	Prevention of urine leakage or ureteral stricture
Previous surgeries	Opposite iliac fossa	Prevention of vessel or visceral injury, prevention of lymphocele, shorter operative time
Associated abdominal organ transplantation	Left iliac fossa and in the retroperitoneal space Abdominal cavity for en bloc or composite grafts	Prevention of adding the complications of each graft on the other graft
Laterality of the donor kidney (left or right)	It's better to use right iliac fossa	More superficial position of iliac vein Some authors use the opposite side because of position of the transplanted graft for future percutaneous interventions on the urinary system
The number of kidney grafts	Retroperitoneal space of right iliac fossa	If the iliac arteries are not large enough it's better to use the abdominal aorta and inferior vena cava
Anomalies of the donor graft	Abdominal cavity if the graft is large, if the graft is small iliac fossa is better.	Enough space for the graft and enough stations for vascular anastomosis

**Table 2.** Factors influencing the choice of implantation site

4. Skin preparation and incision

Skin preparation and drape is not so different from other clean abdominal operations. The patient should bathe before entering the operation theatre. Hair removal is better done with



hair clippers immediately before surgery. We use scrub povidone iodine or any types of alcoholic or polyethylene glycol type solutions (e.g. Decocept®) for initial washing and then normal povidone iodine for 2 times for the final preparation. Also we use a sterile (Opsite®) drape for complete covering of the incision region. The standard skin incision is the traditional hockey-stick Gibson incision or an oblique Rutherford Morison in the right iliac fossa. Gibson incision starts at the tubercle of pubis and continued laterally transverse to inguinal ligament and then upward in a curvilinear manner in the lateral border of the rectus abdominis muscle till 1-2 cm above the level of umbilicus. In larger adults extension till the anterior superior iliac spine may be enough. The epigastric vessels and the round ligament in females usually need to be ligated and transected, but the spermatic cord simply retracted medially by releasing the border of inguinal canal. The surgeon should avoid entering the peritoneal space and any defect in the peritoneum should be repaired before continuing the incision.

All the dissections should be accompanied by strict hemostasis and avoiding extreme injury to the abdominal wall muscles to simplify the future abdominal wall repair at the end of the procedure. All the bleeding sites should be completely hemostatized during this time because at the end of the procedure hemostasis will be very difficult. Also most renal failure patients has bleeding tendency due to platelet dysfunction specially in the first 2 hours after the hemodialysis or in those patient who underwent preemptive renal transplantation. If hemostasis is not complete wound or peri-graft hematoma is inevitable which will lead to the other complications such as infection, dehiscence, hydronephrosis or kidney compartment syndrome due to compression to the graft.

After entering the retroperitoneal space and revealing the anatomy of the iliac vessels and their suitability for transplantation, the iliac vein should be prepared first by ligating all lymphatics around it. It's better to avoid the first major deep iliac lymph node (Cloquet's node). Dissections around the external iliac artery should be limited and if the internal iliac artery has a good contour and length, it's better to use it as the arterial inflow. If this artery has atherosclerotic plaques an endarterectomy could be done. We use the external iliac artery only when the internal iliac artery of the other side is used previously, or when a large size discrepancy is revealed or severe atherosclerosis reduce the arterial flow to a very low and crucial level. Using the internal iliac artery slightly increases the postoperative lymphocele because of more dissections needed for its releasing, but if the surgeon ligate all the lymphatics it would not be a major problem.

Without a good exposure, transplantation is a very difficult procedure and using a, Denis-Browne (Figure 2), Kirschner (Figure 3) or Bookwalter-type (Figure 4) self retaining retractor is a critical step in the implantation procedure. Many manufacturers have invented more powerful retractors. Some of them like Thompson® retractor, although are very useful and unique for liver or kidney-pancreas transplantation, but their use for kidney transplantation alone is time consuming and is best limited to super-obese recipients. Some of them such as Henley or Darling or Gosset abdominal retractor only are useful in pediatric or thin patients with a shallow pelvis. Balfour and Balfour-Baby, Collin and Baby Collin, Ricard and Sullivan- O'Connor have the same problem. Some of them such as Omni-Flex® (Omni-Tract® surgical, Minnesota Scientific, MN, USA) or SynFrame® retractor systems (Synthes® Spine Inc., PA, USA) are modifications to the original Thompson retractor but their use may be more sophisticated.

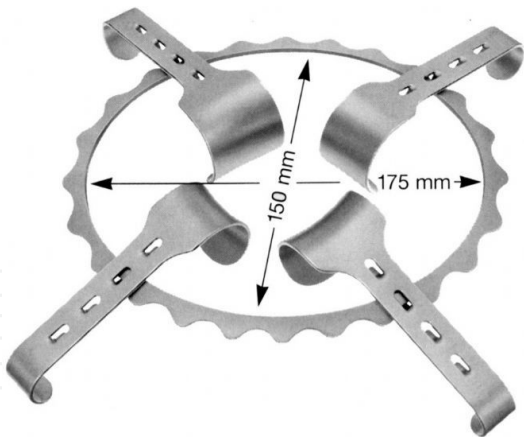


Figure 2. Denis-Browne retractor

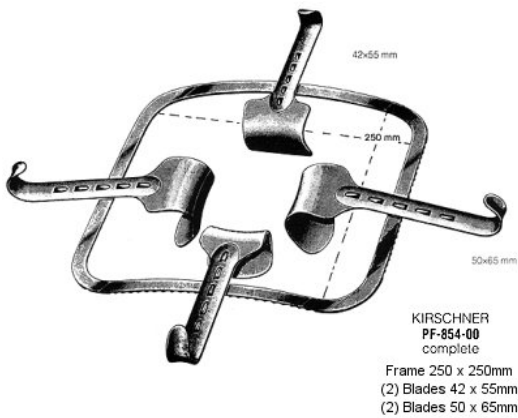


Figure 3. Kirschner retractor



Figure 4. Bookwalter retractor

## 5. Vascular anastomosis

After preparation of the place of the implantation, the surgeon should transfer the graft to its position transiently for better evaluation of the anastomoses sites. Some authors suggest that slush ice should be put in the bed of the graft in the recipient, but we absolutely disagree with this opinion, because the total vascular reconstruction time is usually less than 20 minutes and adding ice only increases the risk of local hypothermic injury. The surgeon should do his best efforts to reduce the total arterial and venous clamping time. First the site of each anastomosis and the position of the graft should be specified accurately according to the size and length of the vessels and also the length of the ureter and position of the recipient bladder or ureter and the final position of the implanted kidney. As described previously, we prefer to use the internal iliac artery and external iliac vein for vascular anastomoses. For reducing the vein clamping time (with subsequent risk of deep vein thrombosis), we perform the arterial anastomosis first. But when the vein is shorter than usual or when the left iliac fossa is used for implantation, or when the abdominal cavity and aorta and inferior vena cava or the external iliac artery are used for implantation, it's better to perform the venous anastomosis first.

The principles of vascular anastomosis are not different from any standard vascular surgery. The best suture size is usually 5-0 and 6-0 Prolene® sutures for venous and arterial anastomosis. The size of the needles depends of the location of the anastomosis but in most cases the needle should be taper-point or taper-cutting-tip round-bodied 3/8 circle with 11 – 13 mm length for better performance. For smaller arteries 7-0 or 8-0, 1/2 circle, 7-9.3 mm needles may be more suitable. For severe atherosclerotic arteries use of special visible Ethicon Visi-Black® Everpoint®, or Tapercut® needles with spatulated heads which is more firm and crash-resistant is needed.

After confirming the exact length and position of the anastomosis site to prevent kinking or rotation, vascular clamps are applied to the first vessel. We prefer to use Bulldog clamps to the internal iliac artery and iliac veins and Satinsky clamps for side-clamping of external iliac and common iliac artery or aorta or inferior vena cava. We discourage systemic heparinization before clamping because of bleeding tendency in chronic renal failure patients, but other authors recommend this. Heparinized saline is enough for irrigation of the vessels during the anastomosis.

For end-to-side anastomoses a patch from the vessel should be removed for preventing future constriction. This patch is removed from the arteries by No. 3, 4 or 5 aortic punches depending on the arterial size and by special Metzenbaum or Potts scissors from the veins. Also we should avoid the venous valve site in the external iliac vein, if possible. The wall of the vein is very thin proximal to the venous valves (sinuses of Valsalva) and may be ruptured during the anastomosis.

For end-to side anastomosis of a renal artery to the external iliac or common iliac or aorta, the graft artery should be spatulated in the direction of its lower corner. For end-to-end anastomosis of the renal artery to the internal iliac artery, the renal artery should be spatulated from

the upper corner and the internal iliac artery should be spatulated in the direction of the opposite lower corner (in other words in the direction the deep part of the artery). Renal vein usually needs no spatulation.

An endarterectomy should be done with extreme caution after cutting the internal iliac artery or entering the external iliac artery. No intimal flaps in the opposite direction of the blood flow should be remained at the end of endarterectomy. If such flap is remained, then the surgeon should decide to change the arterial anastomosis site, if possible, or at least the flap must completely secured to the arterial wall with a tagging U-stitch.

Special attention should be paid to the length of the right artery and left renal vein of the deceased donor. They are both too long for anastomosis and if not trimmed or shortened, kinking will be inevitable which will result in postoperative renal dysfunction and hypertension.

Arterial anastomosis is started by two corner stitch in each side of the vessel as described first by Carrel in 1902. Care is taken to include equal bites of all layers of the arterial wall in each passage of the needle and the adventitia remained outside. For this purpose we perform a 1 mm adventitiectomy of both arteries and use microvascular forceps, scissors and needle holders for arterial anastomosis and also recommend using a 4.5-6X loop for magnification and surgical headlights for better illumination. It's so important that the posterior layer suturing of the arterial anastomosis is done first and from outside. The needle should move from inside to outside of the more diseased artery (usually the recipient artery) to tag the intima to the media of the artery and preventing from creating an intimal flap which will be a good trigger point for future thrombosis. The upper suture is tied but the lower is maintained untied till the end of the anastomosis. The posterior layer is sutured first and then anterior layer anastomosis is started from both corners. In the children or for small arteries at least one half of the anastomosis should be done by separate sutures. In all other continuous anastomoses (artery or vein), we tie the last suture loosely and preserve a "Growth factor" or "expansion factor" to prevent purse-string effect of the continuous suture on constricting the anastomosis as first described by Starzl in the portal anastomosis of liver transplantation (Starzl TE, 1984, Zomorodi, et al, 2012) [7, 8] [7].

For vein anastomosis we use a somewhat different technique. After inserting the two corner stitches, an anchoring or stay suture is used in the midpoint of the anterior layer of the venotomy site of the external iliac vein to maintain the orifice of the anastomosis site totally exposed and prevent from inadvertent catching of the posterior suture line in the anterior suture line. All the anastomosis is performed circumferentially by a single stitch that used as the proximal corner stitch. Then the surgeon should be cautious when tying this suture that the two remaining part are in the same length. The anastomosis is started from the proximal part by entering tying the corner stitch. Then the needle is entered from the posterior layer of the internal iliac vein into its lumen. Then a four-point technique is used for approximating the two intimal layers of the renal vein and external iliac vein. After completing the posterior layer then the anastomosis is continued from distal and proximal corner to the anterior layer and the anchoring stitch is removed. Again a "Growth factor" is necessary to prevent the purse string effect and also in the pediatric group, the anterior layer stitches should be in separate manner for make future growth possible. If the venotomy site is larger than the orifice of the

renal vein, then after completing the posterior layer, the excessive part should be repaired before starting the anterior layer, preferably by another suture line.

## 6. Unusual situations

In case of thrombosed or fibrotic external iliac vein (due to multiple previous femoral vein canulations or previous DVT) or severe atherosclerotic iliac arteries, the best approach is to use the abdominal major vasculature for renal transplantation. The surgeon may decide to use the common iliac artery or vein if spared from the disease or close the wound and explore the opposite iliac fossa if preoperative Investigations or intraoperative sonography were negative for the same complication. In extreme cases when the IVC is also thrombosed or fibrotic, or when the infrarenal aorta also is atretic or severely atherosclerotic, using the splenic or native renal vein and artery may be an option, provided that the native ureters has a normal function and anatomy.

Another unusual case is the horseshoe kidney. Anomalous vasculature is the rule in these cases. Crossed fused or non-fused ectopic kidneys have the same problem. One option for approaching this type of anomaly is to incise the isthmus between the two conjoined kidneys and use each kidney for a separate recipient. The major problem is the resultant two grafts with so many arterial and venous branches and also short and multiple ureters. Because of shortage of donor organs most centers prefer this approach. But sometimes dividing the horseshoe kidney is so difficult and may results in damaging both kidneys. In these cases it's better to use the anomalous kidney as an individual graft and use the aorta and IVC as the arterial inflow and venous outflow of the graft. Such large size graft often could not be placed retroperitoneally and should be implanted in an intraperitoneal space. The same principle is applied to double kidney grafts from a pediatric or old age or more marginal donors such as donation after cardiac death (DCD) donors: transplanting each unit separately or using the aorta and IVC as the vascular conduits of the graft. Circumaortic or retroaortic renal veins are other problematic vascular anomalies that make the transplantation procedure more difficult. In experienced hands, these anomalies per se are not contraindication for donation even from the living donors

When a suspicious lesion is found on the kidney graft, it should be incised or excised and sent for frozen section pathologic investigation. Hemostasis could be done by sutures or argon beam coagulators, following the principles of any standard partial nephrectomy. Benign lesions should be removed completely and grafts with any non-benign pathology should be discarded. Solitary cysts are very common and if small, needs no investigation. There are many case reports in the literature about transplanting kidneys from deceased donors with adult polycystic kidney disease, without any short-term complications. These grafts should only be used when the donor kidney function is good and the recipient is fully aware of the donor disease. These cases are best suitable for sedentary recipients with a short life expectancy, provided that no other contraindication such as HLA mismatch is found.



Kidney transplantation may be accompanied by pancreas, liver (Nadim MK, et al, 2012)[9], heart (Florman S, Kim-Schluger L.,2012) [10], lung (Rana RK, et al, 2011) [11] or multiorgan transplantation. In such situations usually the more important transplantation (heart, lung, liver, pancreas or small bowel) is done first. And after stability of the recipient, kidney transplantation is performed. Even when the abdomen is entered during the first procedure, it's better to use the retroperitoneal iliac fossa for the second transplant by the same incision. This will reduce the complications associated with urine leakage. In case of simultaneous kidney –pancreas transplantation the kidney transplant is done first in the left iliac fossa and during the time of this procedure, the other team prepares the pancreas graft by ex vivo surgery for the second transplantation which is usually use the right common or external iliac artery as the inflow. The kidney transplantation combined with multivisceral transplantation is usually is an en-bloc transplantation. This means that the kidney is not separated from the donor aorta and inferior vena cava (IVC). All major vascular anastomoses are done by aorta as the inflow artery and IVC and/or portal vein as the venous outflow. The urinary reconstruction is performed after complete reperfusion of all abdominal organs.

## 7. Declamping and reperfusion

After completing the vascular anastomoses, the opposite corner stay sutures remained untied until reperfusion. The recipient systolic blood pressure should be at least 120 mmHg and the central venous pressure between 10 to 14 cm H<sub>2</sub>O. The use of vasopressors such as dopamine for increasing the blood pressure is controversial. Immunosuppressant is best infused before declamping according to the protocols of each transplant ward. Some authors suggests some over-hydration, infusing Furosemide and Mannitol and correction of acid-base imbalance according to the last arterial blood gas base deficit before declamping to prevent the so called “reperfusion syndrome”. Unlike liver or small bowel transplantation, in most cases reperfusion syndrome will not be a problematic issue, because the kidney graft is relatively small, except when using an adult kidney for a pediatric recipient or in cases of a long implantation time with complete aortic or common or external iliac artery clamping time. In such cases the cause of “reperfusion syndrome” is transient ischemia of the lower limbs. The anesthesiologist should prepare sodium bicarbonate, calcium gluconate, and insulin with 50% Glucose before declamping for managing this complication and obtain an arterial blood gas before and after the declamping for estimating the severity of acidosis and monitor the electrocardiogram for diagnosis of hyperkalemia.

Arterial declamping is done first and after complete filling of the graft, veins are also opened. In this phase brisk bleeding is a rule, especially when we applied “growth factors” to the last ties. Most of the bleeding will be stopped spontaneously after complete dilatation of the anastomotic lines. Small bleeding sites may be covered by small parts of any hemostatic agent such as Surgicel®, N-butyl cyanoacrylate glues, Tachosil® or similar agents (Sageshima J, et al, 2011) [13]. All the other larger bleeding sites should be transligated or repaired by fine Prolene® sutures especially near the hilum, but extreme caution should be paid not to include the delicate hilar arterial branches in the sutures.



The kidney should be firm and well-perfused after 1-2 minutes and urine flow usually starts after that. If the graft is flaccid and the patient's blood pressure is good, arterial kinking is the first differential diagnosis. This usually is resolved by repositioning of the graft. Also the surgeon could transiently clamp the renal vein or the distal part of the external iliac artery. If not, thrombosis must be considered and ruled out as soon as possible.

## 8. Urinary reconstruction

After completing the reperfusion stage usually the urine flow is started. Sometimes, especially in case of deceased donors or when the nephrectomy has been performed with difficulty in the living donors, the urine flow will be delayed. If the color and contour of the graft look good and the arterial and venous flow is good with a well-palpable thrill in the hilum, the surgeon should proceed to urinary reconstruction.

First of all the urinary bladder should be filled with sterile normal saline serum through previously installed urinary catheter. Some surgeons add 10ml/lit povidone iodine and 80 mg/lit Gentamicin or 500 mg/lit Amikacin to the irrigation fluid for better sterility of the bladder (Salehipour M, et al, 2010) [13] but its effect is controversial. The kidney should be positioned in its final expected place to prevent the tension on the remained ureter before cutting the excess length of the ureter. It's better to use the smallest possible length of the ureter to reduce future ischemic complications. If this step is forgotten the final length of ureter may be shorter than expected and this will result in kinking of the vasculature and changing the location of the kidney from its ideal position.

The surgeon has many options for urinary reconstruction: ureteroneocystostomy, uretero-oureterostomy, pyeloureterostomy, and pyelocystostomy or even ureteroenterostomy to an ileal conduit or Koch (Manassero F, et al, 2011) [14] or pyelopyelostomy in case of orthotopic kidney transplantation or complicated case (Wagner M, et al, 1994) [15]. The type of reconstruction depends on the position of the graft, the length, condition and number of the donor ureter(s), the condition of the recipient's bladder or bladder substitute (including its capacity and continence), previous operations on the recipient bladder or ureter (and its antireflux condition). The anastomosis should be done by absorbable sutures, usually polydioxanone sutures. Because of the risk of infection, use of any types of stents, such as double J stents or newer antireflux stents are controversial (Parapiboon W, et al, 2012) [16], but we use it in our center and remove it after 3 weeks. At least 4 techniques and their modifications are discussed in the literature for ureteroneocystostomy (Kayler L, et al, 2010) [17]. Prevention of leakage, stricture and reflux is the final goal of all of these techniques. The two most common types are transvesical or Leadbetter-Politano (LP) technique and the extravesical or modified Lich-Gregoir (LG) technique. We use and recommend the second technique because it needs fewer dissections and use only one small cystostomy incision (comparing with 2 large cystostomy incision needs for LP technique) with comparable antireflux characteristics and fewer complications. The LG technique can be performed in a very shorter time. After distending the bladder, the

detrusor muscle dissected bluntly in the dome of the bladder approximately for a length of 3 cm till the mucosa bulges out. The ureter shortened to its ideal length and spatulated for a length of 2 cm in its anti-mesoureteral direction and then the bladder mucosa incised. Anastomosis is started near the heel of the spatulated ureter 2-3 mm in the opposite direction of the corner of the ureter. In this manner, the tie is placed outside and with some distance from the corner. The mucosa of the bladder is then sutured to the ureteral end with simple continuous sutures. After completing the anastomosis, an absorbable suture is used for approximating the detrusor muscle to close over the anastomosis and creating a small submucosal tunnel for its antireflux mechanism. The LP techniques and the two other extravesical techniques are better described in the literature (Kayler L, et al, 2010) [17]. In the LP technique, a large anterior cystostomy is done for visualization of the bladder interior and the ureter is transferred through another small posterior cystostomy and then through the mucosa and after anchoring the distal end to the mucosa, the bladder is closed in 2 layers with absorbable sutures. Another extravesical technique is the single or double U-stitch technique. In these techniques after opening the submucosal tunnel by creating by dissection of detrusor muscle and incising the bladder mucosa only 1 U-stitch (Shanfield, 1972) [18] at the toe or 2 U-stitch (MacKinnon et al, 1968) [19] at the toe and heel of the trimmed ureter is used for anchoring the ureter to bladder mucosa and then the detrusor muscle closed as the same manner of the LG technique.

Another extravesical technique uses two parallel incisions in the detrusor muscle, first posterior for transferring the ureter in a submucosal tunnel and the second incision for anastomosis of the ureter to the ureteral mucosa (Barry JM, 1983) [20]. In the last technique, the ureter is anastomosed to the bladder full-thickness wall without any antireflux mechanism (Starzl, et al, 1989) [21]. In our opinion, the surgeon should be familiar with all of these methods and use them as needed, but we have the most experience with the modified LG technique without any major urologic complication (Davari HR, et al, 2006) [22].

When the graft ureter is short, ischemic, or denuded, the surgeon should use the native ureters for ureteroureterostomy or pyeloureterostomy if they are completely in a healthy condition (no stricture, no infection, no dilation or no reflux) or decide to perform a pyeloneocystostomy. This should be done with extreme caution to prevent kinking or pressure on the graft vasculature or repositioning of the graft. A Boari flap or psoas hitch is often necessary in all cases.

In case of previous bladder surgery such as antireflux surgeries or cystoplasty or bladder augmentation, it's very important that the site of final urinary reconstruction is fully depicted before proceeding with vascular anastomosis, or even before proceeding with nephrectomy in the living donor. Also the blood supply of the tissues used for augmentation should be considered. Creating a submucosal flap in the augmented bladder may results in ischemia of the tissues used for augmentation and if possible it's better to use the native bladder area for ureteral anastomosis.

In case of double or multiple ureters (such as horseshoe kidneys or en bloc transplantation of two kidneys), the ureters can be anastomosed separately to the bladder, or one to the bladder and the shorter ones to the native ureter. Another option is anastomosis of the ureters to each

other and then anastomosis of the conjoined ureter to the bladder. In our opinion using separate anastomoses (if possible) reduces the future complications.

## 9. Wound closure

Wound closure is the final step of the procedure. Closing is done by 2-layer repair of the abdominal muscles (first transverse and internal oblique as one layer and then the external oblique muscle), by a No. 0 loop Nylon suture. Using any drain before closure is controversial but if used it should be a closed suction drain such as a Jackson-Pratt drain and every effort should be used that the drain has no compression effect on the renal vasculature and the ureter. The exit site also should be assessed for bleeding. Every bleeding site should be assessed and repaired before closure to prevent postoperative hematoma. Diffuse oozing at the end of operation may be the result of platelet dysfunction or heparin overdose and should be managed accordingly by desmopressin and protamine sulfate, respectively. Excess perirenal fat should be removed, and the graft should be placed in a retroperitoneally created pouch parallel with the psoas muscle, to prevent compression of the kidney between the abdominal wall and the pelvic bones. If the kidney volume is greater than this space, or the renal vasculature or ureter is shorter than usual, then “compartment syndrome” is inevitable if the abdominal muscles are repaired in the usual manner. In such situation, the renal artery inflow is good but the outflow will be disturbed because of pressure of the abdominal wall on the renal vein. Renal venous pressure increases and then the graft will be congested and the urine flow will decrease. If remained unmanaged, this will eventually lead to decreasing renal artery flow and finally to renal artery thrombosis and graft loss. If the surgeon could not reposition the graft in to the suprapubic area and anchor it to the abdominal wall without vascular kinking, many other options should be tried. One option is to incise the rectus sheath after closing the muscles. Another option is to close the abdominal wall from distal and proximal and let the part which is covering the kidney remains unclosed or closed by an artificial mesh which is used for hernia repair. The last option is to let abdominal musculature remain completely opened and only covered by the skin. The resultant incisional hernia will be repaired in the future, usually 3 months after the transplantation. The best treatment of such conditions is “prevention” by matching the size of the donor and recipient and special attention to the length of the graft vasculature and ureter and also creating the pouch as the first step during the procedure.

## Author details

Farzad Kakaei<sup>1</sup>, Saman Nikeghbalian<sup>2</sup> and Seyed Ali Malekhosseini<sup>2</sup>

1 Tabriz University of Medical Sciences, Tabriz, Iran

2 Shiraz University of Medical Sciences, Shiraz, Iran

## References

- [1] Dolińska B, Ostróżka-Cieślik A, Caban A, Cierpka L, Ryszka F. Comparing the effect of Biolasol® and HTK solutions on maintaining proper homeostasis, indicating the kidney storage efficiency prior to transplantation. *Ann Transplant*. 2012 Jun 29;17(2):74-8.
- [2] Prasad GS, Ninan CN, Devasia A, Gnanaraj L, Kekre NS, Gopalakrishnan G.: Is Euro-Collins better than ringer lactate in live related donor renal transplantation? *Indian J Urol*. 2007 Jul;23(3):265-9.
- [3] El-Sherbiny M, Abou-Elela A, Morsy A, Salah M, Foda A. The use of the inferior epigastric artery for accessory lower polar artery revascularization in live donor renal transplantation. *Int Urol Nephrol*. 2008;40(2):283-7.
- [4] Nghiem DD, Choi SS. Eversion endarterectomy of the cadaver donor renal artery: a method to increase the use of elderly donor kidney allografts. *J Urol*. 1992 Mar;147(3):653-5.
- [5] Sharma A, King AL, Lee HM, Posner MP. Saphenous vein graft aneurysm after renal transplantation: a case report. *Transplantation*. 2010 May 15;89(9):1162-3.
- [6] Webb J, Soomro N, Jaques B, Manas D, Talbot D. The upside down transplant kidney. *Clin Transplant*. 2003 Oct;17(5):484.
- [7] Starzl TE, Iwatsuki S, Shaw BW Jr. A growth factor in fine vascular anastomoses. *Surg Gynecol Obstet*. 1984 Aug;159(2):164-5.
- [8] Zomorodi A, Kakei F, Farshi A, Zomorodi S (2012) Is Placing an Expansion Space at the Anastomosing Site of the Vessel for Prevention of Pseudoaneurysm, Safe? *J Transplant Technol Res* 2:113. doi:10.4172/2161-0991.1000113
- [9] Nadim MK, Sung RS, Davis CL, Andreoni KA, Biggins SW, Danovitch GM, Feng S, Friedewald JJ, Hong JC, Kellum JA, Kim WR, Lake JR, Melton LB, Pomfret EA, Saab S, Genyk YS Simultaneous Liver-Kidney Transplantation Summit: Current State and Future Directions. *Am J Transplant*. 2012 Jul 23.
- [10] Florman S, Kim-Schluger L. Organ transplantation update, part II: heart and kidney. *Mt Sinai J Med*. 2012 May-Jun;79(3):303-4.
- [11] Rana RK, Ghandehari S, Falk JA, Simsir SA, Ghaly AS, Cheng W, Cohen JL, Peng A, Czer LS, Schwarz ER, Chaux GE. Successful combined heart-bilateral lung-kidney transplantation from a same donor to treat severe hypertrophic cardiomyopathy with secondary pulmonary hypertension and renal failure: case report and review of the literature. *Transplant Proc*. 2011 Sep;43(7):2820-6. Review.
- [12] Sageshima J, Ciancio G, Uchida K, Romano A, Acun Z, Chen L, Burke GW 3rd. Absorbable cyanoacrylate surgical sealant in kidney transplantation. *Transplant Proc*. 2011 Sep;43(7):2584-6.

- [13] Salehipour M, Salahi H, Fathikalajahi A, Mohammadian R, Emadmarvasti V, Bahador A, Nikeghbalian S, Kazemi K, Dehghani M, Malek-Hosseini SA. Is perioperative intravesically applied antibiotic solution effective in the prophylaxis of urinary tract infections after renal transplantation? *Urol Int*. 2010;85(1):66-9. Epub 2010 Mar 17
- [14] Manassero F, Di Paola G, Mogorovich A, Giannarini G, Boggi U, Selli C. Orthotopic bladder substitute in renal transplant recipients: experience with Studer technique and literature review. *Transpl Int*. 2011 Sep;24(9):943-8. Epub 2011 Jul 1. Review.
- [15] Wagner M, Dieckmann KP, Klän R, Fielder U, Offermann G. Rescue of renal transplants with distal ureteral complications by pyelo-pyelostomy. *J Urol*. 1994 Mar;151(3):578-81.
- [16] Parapiboon W, Ingsathit A, Disthabanchong S, Nongnuch A, Jearanaipreprem A, Charoenthanakit C, Jirasiritham S, Sumethkul V. Impact of early ureteric stent removal and cost-benefit analysis in kidney transplant recipients: results of a randomized controlled study. *Transplant Proc*. 2012 Apr;44(3):737-9.
- [17] Kayler L, Kang D, Molmenti E, Howard R: Kidney transplant ureteroneocystostomy techniques and complications: review of the literature. *Transplant Proc*. 2010 Jun;42(5): 1413-20.
- [18] Schanfield I: New experimental methods for implantation of the ureter in bladder and conduit. *Transplant Proc* 4:637, 1972
- [19] MacKinnon KJ, Oliver JA, Morehouse DD, et al: Cadaver renal transplantation: emphasis on urological aspects. *J Urol* 99:486, 1968
- [20] Barry JM: Unstented extravesical ureteroneocystostomy in kidney transplantation. *J Urol* 129:918, 1983.
- [21] Starzl TE, Shapiro R, Tzakis A, et al: A new technique of extravesical ureteroneocystostomy for renal transplantation. *Transplant Proc* 21:3856, 1989
- [22] Davari HR, Yarmohammadi H, Malek-hosseini SA, Salahi H, Bahador A, Salehipour M. Urological complications in 980 consecutive patients with renal transplantation. *Int J Urol*. 2006 Oct;13(10):1271-5.