

# We are IntechOpen, the world's leading publisher of Open Access books Built by scientists, for scientists

6,900

Open access books available

186,000

International authors and editors

200M

Downloads

Our authors are among the

154

Countries delivered to

TOP 1%

most cited scientists

12.2%

Contributors from top 500 universities



WEB OF SCIENCE™

Selection of our books indexed in the Book Citation Index  
in Web of Science™ Core Collection (BKCI)

Interested in publishing with us?  
Contact [book.department@intechopen.com](mailto:book.department@intechopen.com)

Numbers displayed above are based on latest data collected.  
For more information visit [www.intechopen.com](http://www.intechopen.com)



---

# Management of Prosthetic Infection According to Organism

---

Trisha Peel, Kirsty Buising, Michelle Dowsey and Peter Choong

Additional information is available at the end of the chapter

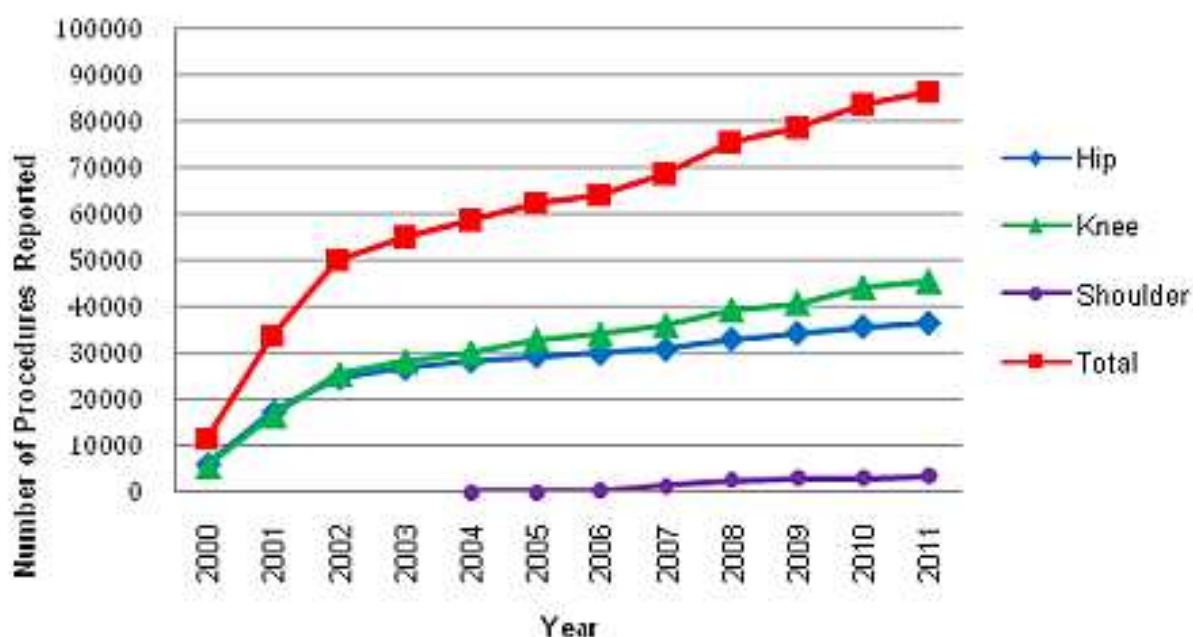
<http://dx.doi.org/10.5772/53244>

---

## 1. Introduction

Since the advent of prosthetic joint replacement surgery, patients with arthritis have had significant improvement in pain-relief, mobility and quality of life. Approximately 90,000 Australians undergo joint replacement surgery each year [1]. With an ageing population, this number will increase (figure 1). Similar data from USA predicts that by 2030 the number of procedures per year will increase to 4.05 million [2]. Despite the overall success of this surgery, infection of the prosthesis remains a devastating complication [3]. Of concern, the incidence of prosthetic joint infection is increasing, in proportion to the number of procedures being performed [4]. Significant patient morbidity is associated with prosthetic joint infections, including the need for further operative procedures, long-term antibiotic therapy with associated toxicity, and prolonged hospitalisation [3]. In addition, the cost to the health system is substantial. The cost of treating infection is 3-5 times the cost of primary arthroplasty [5, 6]. In Australia, the annual additional expenditure incurred as a result of this devastating complication is estimated at AUD \$90 million per year [6]. In the United States, the annual cost of treatment of prosthetic joint infection is projected to exceed US\$1.6 billion dollars by 2020[7].

The incidence of prosthetic joint infection is estimated at 1-3% of all prosthetic joint replacements [3]. In prosthetic hip replacement, the rate of infection is estimated at 0.88% and in knee replacement at 0.92%[4]. The incidence of prosthetic joint infections is higher for upper limb arthroplasty; in shoulders the incidence of infection is 1.8-4% and in elbow replacements the incidence of infection is 3-7.5% of patients [8-10].



**Figure 1.** Prosthetic Joint Replacement Surgery in Australia (adapted from AOA National Joint Replacement Registry[1])

A number of pre-operative factors have been implicated in the development of prosthetic joint infection, including revision arthroplasty, diabetes mellitus and rheumatoid arthritis [11-16]. The risk factors for prosthetic joint infection differ according to the joint replaced. Obesity plays a greater role in the evolution of prosthetic joint infection in lower limb arthroplasty [17-19]. The presence of post-operative wound complications, including high drain tube losses, wound discharge and superficial surgical site infection have been implicated as risk factors for development of prosthetic joint infection in hip and knee arthroplasty [11, 20]. In addition the presence of a drain tube appears to be protective for prosthetic knee infections [17, 18]. Underlying inflammatory arthritis and concomitant steroid use increases the risk of infections in all arthroplasty surgery but the association is particularly marked in the upper limb [16, 17]. In addition male gender has been identified as a risk factor in shoulder arthroplasty infection, potentially through the interaction with *Propionibacterium acnes* (see below)[12].

## 2. Pathogenesis

There are two main mechanisms of acquisition of prosthetic joint infection; (i) direct inoculation of the prosthesis at the time of surgery or with manipulation of the joint and (ii) seeding from the blood stream at a later time[3]. The pathogenesis of prosthetic joint infections differs to that of many other bacterial infections through the property of microorganisms to form biofilms[3]. Microorganisms can exist in two phenotypic forms: the planktonic form which is encountered in the majority of acute bacterial infections such as bacterial septicaemia or pneumonia, and the sessile form associated with medical device

infections such as prosthetic joint infections[21]. In medical device associated infections, the planktonic bacteria seed the device and undergo a phenotypic change transforming into the sessile bacteria. The biofilm is comprised of the sessile bacteria and the extracellular matrix they secrete[21]. This matrix protects the microorganisms from antibiotics and the host immune response and is thought to be the underlying reason for persistence of infections[21].

### 3. Microbiology

*Staphylococcus aureus* and coagulase negative *Staphylococcus* species are the most common aetiological agents of prosthetic joint infections. The incidence of methicillin resistant strains such as methicillin resistant *Staphylococcus aureus* (MRSA) differ globally; the rate of MRSA prosthetic joint infections across Europe and the Americans MRSA ranges from 8% to 30%[22-24]. In Australia, 26% of prosthetic joint infections are due to MRSA. In addition, methicillin resistant coagulase negative *Staphylococci* account for a further 22% of isolates [25, 26].

Gram negative bacilli such as *Escherichia coli* and *Pseudomonas aeruginosa* are the next most common isolates[3, 26]. Other microorganisms such as enterococci, streptococci, corynebacterium, fungal species and mycobacterial species are reported less commonly [3, 27]. Of note, the microbiology of prosthetic joint infection differs between upper limb and lower limb arthroplasty: *Propionibacterium acnes* is one of the most common microorganisms encountered in shoulder prosthetic joint infection, occurring in up to 40% of shoulder arthroplasty infections [16, 28, 29]. This association may be due to the increased occurrence of *Propionibacterium acnes* around the head and neck, in particular in the sebaceous glands and hair bulbs [12].

From a review of 6,282 prosthetic hip and knee replacements performed at St Vincent's Hospital Melbourne (SVHM) between 2000 and 2012, there were 138 definite infections (table 1). Prosthetic joint infection was defined by the typical diagnostic criteria which include those discussed further in table 2. Microorganisms were defined as the causative pathogen/s if isolated on two or more intra-operative specimens.

The microbiology of hip and knee prosthetic joint infection was similar, except for an increased number of culture negative infections in prosthetic knee joints and increased isolation of *Enterococcus faecalis* from prosthetic hip infections. From SVHM data there was an increased rate of incisional surgical site infections in knee arthroplasties that later developed prosthetic joint infections compared to hip arthroplasty (28% versus 12%)[17, 30]. Therefore it is postulated that the increased number of culture negative infections in the knee replacement patients may reflect increased antibiotic exposure for superficial wound complications or for unrecognised prosthetic joint infection.

	Number (%) of Prosthetic Knee Infections (n=66)	Number (%) of Prosthetic Hip Infections (n=72)	Number (%) of All Prosthetic Joint Infections (n=138)
Gram positive organisms	48 (73%)	60 (83%)	108 (78%)
<i>Staphylococcus aureus</i>	25 (38%)	35 (49%)	60 (43%)
Methicillin sensitive	16 (24%)	17 (24%)	33 (24%)
Methicillin resistant	9 (14%)	18 (25%)	27 (20%)
CNS	14 (21%)	13 (18%)	26 (19%)
Methicillin sensitive	1 (2%)	0	1 (1%)
Methicillin resistant	13 (20%)	13 (18%)	26 (19%)
Streptococcus species	4 (6%)	2 (3%)	6 (4%)
<i>Enterococcus faecalis</i>	4 (6%)	10 (14%)	14 (10%)
Other gram positive organisms*	3 (5%)	1 (1%)	4 (3%)
Gram negative organisms	9 (14%)	14 (19%)	23 (17%)
<i>Escherichia coli</i>	1 (2%)	3 (4%)	4 (3%)
<i>Morganella morganii</i>	4 (6%)	0	4 (3%)
<i>Klebsiella pneumoniae</i>	0	1 (1%)	1 (1%)
<i>Serratia marcescens</i>	2 (3%)	0	2 (1%)
<i>Pseudomonas aeruginosa</i>	0	1 (1%)	1 (1%)
<i>Citrobacter koseri</i>	0	1 (1%)	1 (1%)
<i>Enterobacter cloacae</i>	0	3 (4%)	3 (2%)
<i>Proteus mirabilis</i>	2 (3%)	4 (6%)	6 (4%)
<i>Bacteroides fragilis</i>	0	1 (1%)	1 (1%)
Culture negative	17 (26%)	11 (15%)	28 (20%)

CNS = Coagulase negative Staphylococcus species

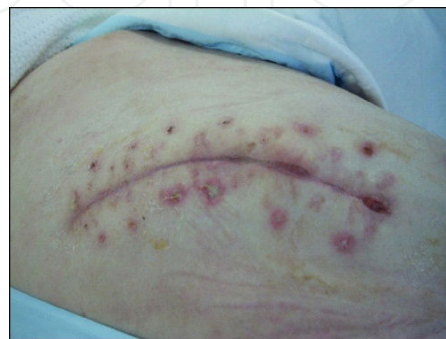\* Other gram positive isolates included 1 Peptostreptococcus species, 1 Bacillus cereus and 2 Corynebacterium species

**Table 1.** Microbiology of 138 prosthetic hip and knee joint infections seen at SVHM between 2000 and 2012

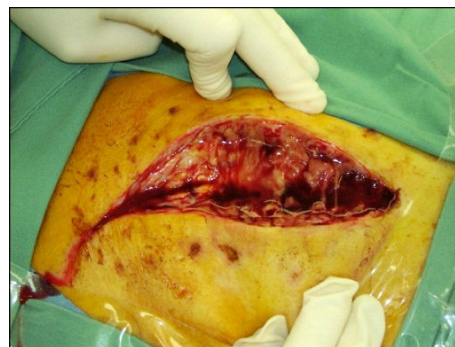#### 4. Clinical classification and presentation

Prosthetic joint infections are classified as (i) early (developing in the first three months after implantation), (ii) delayed (occurring 3 to 24 months after surgery) and (iii) late (greater than 24 months) or (iv) haematogenous [3]. Haematogenous seeding of the prosthesis typically occur late (after 24 months) but can occur at any time point following implantation [3, 31].

The clinical manifestation differs according to time of presentation. In early prosthetic joint infection, patients typically present with surgical wound complications such as purulent discharge, erythema and swelling of the affected joint (Figure 2) [3, 32]. In delayed and late infections, pain is the predominant feature with patients reporting a history of slowly increasing pain involving the prosthetic joint [32]. Haematogenous infections in contrast, typically are associated with a history of a joint that was free of any problems for several months to years before an acute onset of fever, erythema around the surgical wound and pain in the affected joint[33].



A



B

**Figure 2.** Early Prosthetic Hip Joint Infection (A) at presentation with infection showing wound erythema, swelling and purulent discharge and (B) intra-operative appearance showing purulence surrounding the prosthetic joint.

The presentation of shoulder arthroplasty infection due to *Propionibacterium acnes* is generally delayed or late[12]. The classic features of infection are frequently absent with pain and stiffness of the joint the predominant symptoms [12, 34]. Bruising along the surgical wound has been described as a pathognomonic sign of *Propionibacterium acnes* shoulder arthroplasty infection [34].

## 5. Diagnosis of prosthetic joint infections

The diagnosis of infections is challenging due to the absence of an internationally accepted gold standard for defining arthroplasty infection. Current definitions rely on a number of parameters including clinical, microbiological and histopathological features (Table 2) [3, 35-39].



Prompt recognition and diagnosis of prosthetic joint infection is imperative to minimize patient suffering and to improve patient outcomes [40]. Isolation of the causative microorganism is the most important diagnostic test as it allows confirmation of diagnosis and assessment of antimicrobial susceptibilities. Infection of the prosthesis is suggested by the isolation of the same microorganism from 2 or more intra-operative specimens [3, 35, 36] To increase the likelihood of diagnosis,  $\geq 5$  peri-prosthetic tissue specimens should be obtained intra-operatively with each specimen placed in separate sterile containers [35, 36]. This is of particular importance for skin commensals such as *Propionibacterium acnes* and coagulase negative Staphylococcus species to aid in distinguishing true infection from specimen contamination.

The diagnosis of prosthetic joint infection should be considered in patients with any of the following [3, 36-39]:  
Presence of peri-prosthetic purulence observed intra-operatively; OR  
Isolation of indistinguishable micro-organism/s on  $\geq 2$  intra-operative specimens (tissue or joint aspirate cultures); OR  
Presence of a sinus tract in communication with the prosthetic joint; OR  
Histopathological features of acute infections with  $\geq 5$  neutrophils per-high power field (x 500 magnifications) in 5 different microscopic fields.

**Table 2.** Diagnosis of Prosthetic Joint Infection

Prior exposure to antibiotic therapy increases the risk of culture negative prosthetic joint infection [30, 37, 41]. Therefore antibiotic therapy should not be commenced until after obtaining multiple intra-operative specimens, except in the case of the septic patient in whom commencement of antibiotic therapy should not be delayed. In patients with delayed and late infections, who have received antibiotic therapy prior to obtainment of intra-operative cultures, definitive surgery may be delayed for 2-4 weeks after cessation of antibiotics to increase the intra-operative yield[30, 37, 41].

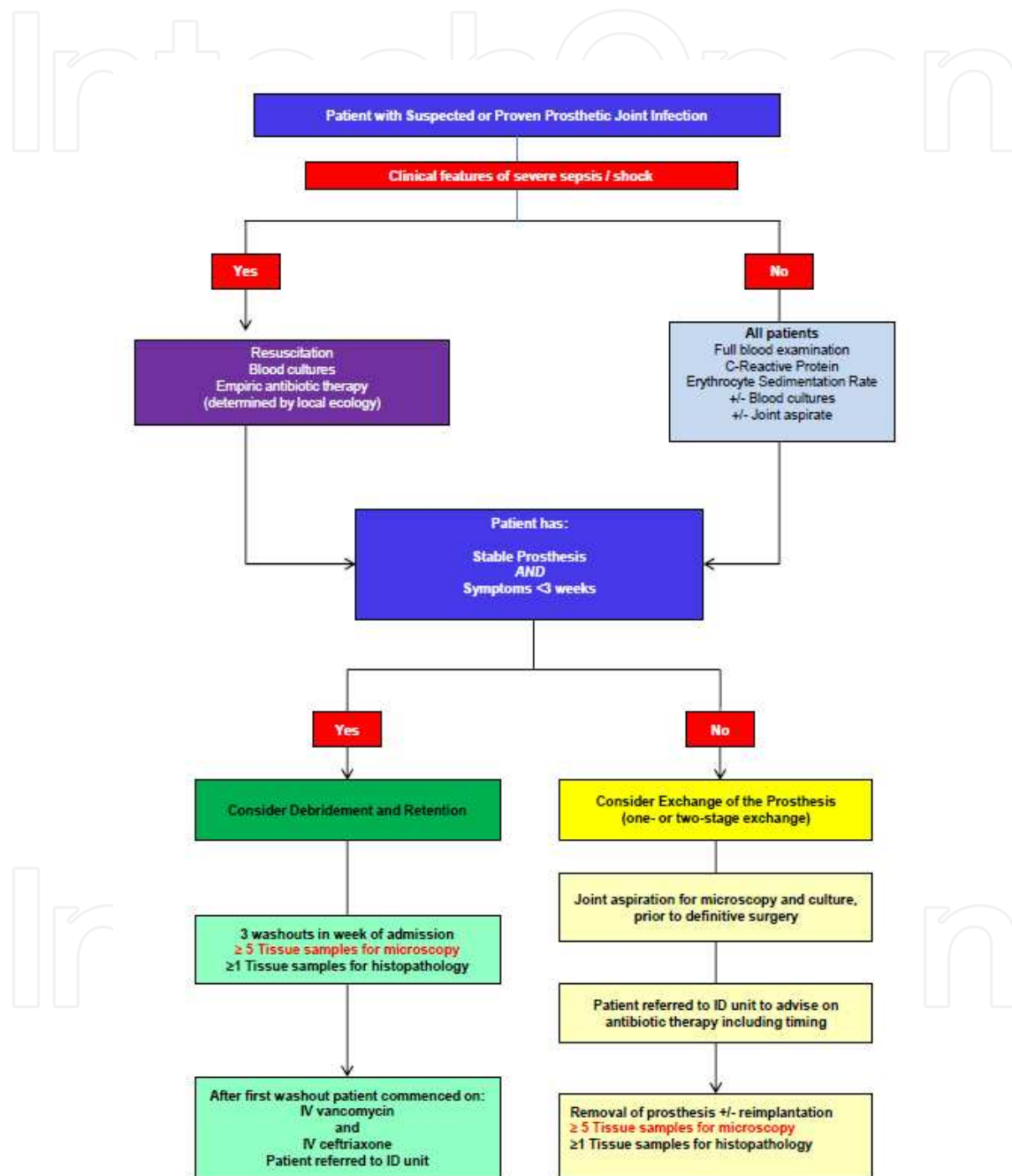
Sonication of the explanted prosthesis disrupts the biofilm and may increase the diagnostic yield of microbiological culture. Sonication is particularly useful in patients who have received antibiotics in 14 days preceding surgery [37]. Prolongation of microbiological cultures from 3 to 14 days also increases the diagnostic yield, particularly of more fastidious organisms such as *Propionibacterium acnes* [42].

## 6. Management of prosthetic joint infection

The goal of treatment of prosthetic joint infection is to eradicate the biofilm dwelling microorganisms, whilst maintaining function of the joint and patient quality of life[3].

The surgical strategies to manage prosthetic joint infection include: (i) one-stage or two-stage exchange procedures, (ii) debridement and retention of the prosthesis in conjunction with biofilm active antibiotics, (iii) removal of the prosthesis +/- arthrodesis, (iv) amputation of the affected limb and (v) chronic suppression without surgical debridement of the infected joint. Removal of the prosthesis and amputation are associated with significant impair-

ment of mobility. Chronic suppression is association with a high rate of recurrence of infection. Therefore these strategies are reserved for patients with significant co-morbidities or in patients with recalcitrant infection [3, 33]. Exchange procedures and debridement and retention are the two strategies that best meet the goals of treatment [3, 33].



**Figure 3.** SVHM Protocol Algorithm for Management of Prosthetic Joint Infection

Given the heterogeneous nature of prosthetic joint infections there are no large randomized control trials to guide recommendations. Surgical strategies differ significantly worldwide; ex-



change procedures are the favoured treatment modality in Northern America, whereas debridement and retention is more commonly performed in Australia and parts of Europe [3, 26, 33]. A number of treatment algorithms exist to guide management decisions and these are based on factors such as duration of symptoms, the stability of implant, patient co-morbidities and the type of infecting microorganism [3, 33]. Compared to the exchange procedures, patients managed with debridement and retention of the implant undergo fewer and less extensive surgical procedures and have shorter duration of hospitalisation and immobilisation [3, 33, 43]. Therefore early and haematogenous infections can be managed by debridement and retention. However, if the implant is loose, if the duration of symptoms prior to presentation exceed 21 days or if the isolated pathogen is resistant to biofilm-active antibiotics, the likelihood of treatment success for debridement and retention is markedly reduced [3, 33]. Therefore if the patient has any of the above features, expert opinion recommends patients undergo prosthesis exchange (either as a one-stage or two-stage procedure). Delayed or late prosthetic joint infections should be managed by one- or two-stage exchange; debridement and retention of the prosthesis in this setting is associated with a high failure rate [3, 33].

At SVHM, a management protocol was established through collaboration between the Orthopaedic and Infectious Diseases Departments. The abbreviated algorithm is shown in Figure 3. The antibiotic regimens for different pathogens are detailed in Table 3. At SVHM patients managed by debridement and retention of the prosthesis undergo 3 debridements of the infected joint. The liner is changed, where feasible, but other mobile parts are not routinely changed. This differs from other protocols for debridement and retention, in which patients undergo a single debridement with exchange of all mobile parts and liners [33]. Regardless of technique, the aim of the debridement/s is to reduce the microbial burden prior to instigation of antibiotic therapy with activity against the biofilm-dwelling microorganisms.

## 7. *Staphylococcus aureus* and coagulase negative *Staphylococcus* species

Rifampicin has excellent activity against Staphylococcal biofilms and is the mainstay of treatment in these infections, particularly with debridement and retention [3, 33, 44-46]. Older treatment algorithms recommended against debridement and retention for MRSA however, emerging evidence suggests that this is a suitable strategy in carefully selected patients [33, 46, 47].

*Staphylococcus* becomes rapidly resistant to rifampicin if this antibiotic is used alone, therefore rifampicin must always be administered with a second agent (companion drug) [48]. Fluoroquinolones, such as ciprofloxacin, are frequently used as companion drugs however fluoroquinolone resistance is increasing thus limiting the utility of this combination [25]. Alternate companion drugs for rifampicin include fusidic acid, trimethoprim-sulfamethoxazole, minocycline, daptomycin and linezolid [33, 47-52]. There are no clinical studies comparing the efficacy of different drugs used in combination with rifampicin. In Australia including SVHM, fusidic acid is commonly prescribed as a companion drug for rifampicin [47] [26].

Rifampicin based regimens are recommended even for methicillin sensitive isolates. Given the high oral bioavailability of rifampicin, a move to oral therapy is suggested as soon

as the patient can reliably take oral diet after completion of surgical debridements. For those few patients who are bacteraemic, however, more prolonged intravenous therapy may be required along with appropriate investigation to exclude other foci of infection, such as endocarditis.

In patients with MRSA infections managed with two-stage exchange; the insertion of a spacer should be avoided as there is an increased rate of treatment failure [3, 33, 53]. In addition, an association between the presence of a spacer and the development of rifampicin resistance in MRSA strains has been reported [53].

## 8. Streptococcus

Streptococcus are the causative agent in 8% of prosthetic joint infections[26]. In general the treatment outcomes are excellent for all surgical strategies for Streptococcal arthroplasty infection [54-58]. However, the outcomes with group B streptococcal infections are mixed with some studies reporting poorer outcomes with these isolates [58-60]. In general intravenous benzylpenicillin or ceftriaxone can be used (often for 2 weeks) before a shift to high dose oral amoxicillin. In some circumstances, with typable streptococci where susceptibility to rifampicin is expected, rifampicin can be added to the amoxicillin as part of the oral regimen although the evidence for this practice is still not clear.

## 9. Enterococcus

Enterococcus is an uncommon cause of prosthetic joint infection however, the incidence of these infections is increasing[61]. At our institution, *Enterococcus faecalis* was isolated in 10% of all infections. It is a common isolate in polymicrobial infections of the prosthetic hip joint. There are little published data to guide treatment of enterococcal prosthetic joint infection. Some experts recommend treatment strategies extrapolated from other enterococcal infections, in particular enterococcal endocarditis [61]. Beta-lactam antibiotics, such as penicillin are bacteriostatic against enterococci, therefore combination therapy with aminoglycosides such as gentamicin, is recommended for management of enterococcal endocarditis[62]. However data from retrospective studies suggest there is no additional benefit with combination therapy with aminoglycosides in enterococcal prosthetic joint infections and, of great concern, there was significant nephrotoxicity and ototoxicity associated with aminoglycoside therapy[61]. Euba et al examined the role of ampicillin-ceftriaxone combination therapy, however, only 3 patients with enterococcal prosthetic joint infection were included in this study and 2 of those patients had late infections[63]. Therefore the role of this combination therapy remains unclear and further studies are required. Recent in-vitro models have suggested rifampicin in combination either with ciprofloxacin or linezolid are the most efficacious antibiotic combinations against biofilm dwelling *Enterococcus faecalis*, although there are no reports at present of the use of these combinations in patients[64].

*Enterococcus faecium* is infrequently involved in prosthetic joint infections; however, it presents significant treatment challenges, owing to increased resistance when compared to *Enterococcus faecalis*. In particular, *Enterococcus faecium* is increasingly resistant to benzylpenicillin and amoxicillin[62]. There is little clinical data outlining management approaches for *Enterococcus faecium*, however, exchange procedures are likely to be the optimal strategy in these infections. Other resistant enterococcal prosthetic joint infection including vancomycin resistant enterococcus (VRE), also are very uncommon. In a statewide review of 163 prosthetic joint infections, VRE was isolated once (0.6%). Two-stage exchange of the prosthesis is recommended for VRE arthroplasty infections in conjunction with agents such as daptomycin, linezolid or pristinamycin. In all enterococcal infections, including VRE, the use of spacers in two-stage exchange procedures is not recommended due to the increased risk of treatment failure [3, 33].

## 10. Gram negative bacilli

For gram-negative bacilli infections, ciprofloxacin has been shown to be effective in guinea pig tissue cage models[65]. There is conflicting data on the clinical outcomes of gram-negative bacilli infections, particularly with debridement and retention. The reported success rate for debridement and retention ranges from 27%-94% with a similar range reported for exchange procedures [66-70]. The likelihood of success may relate to the quality of the debridement and meticulous care should be taken to ensure removal of all dead and devitalised tissue and removal of all cement in the exchange procedures [69]. In addition, gram-negative bacteria, particularly *Pseudomonas aeruginosa*, have a propensity to develop resistance to fluoroquinolones in-vivo[62]. In light of this, many experts recommend a 2-4 week course of beta-lactam antibiotic prior to commencement of ciprofloxacin to reduce the bacterial load and thus reduce the likelihood of generation of in-vivo resistance [33].

## 11. Propionibacterium

As with all other infections, the duration of symptoms dictates the most appropriate surgical strategy for *Propionibacterium acnes* prosthetic joint infection. In *Propionibacterium* arthroplasty infection, the majority of cases are delayed or late presentations, with a long duration of symptoms[12]. Therefore prosthesis exchange is the surgical modality of choice.

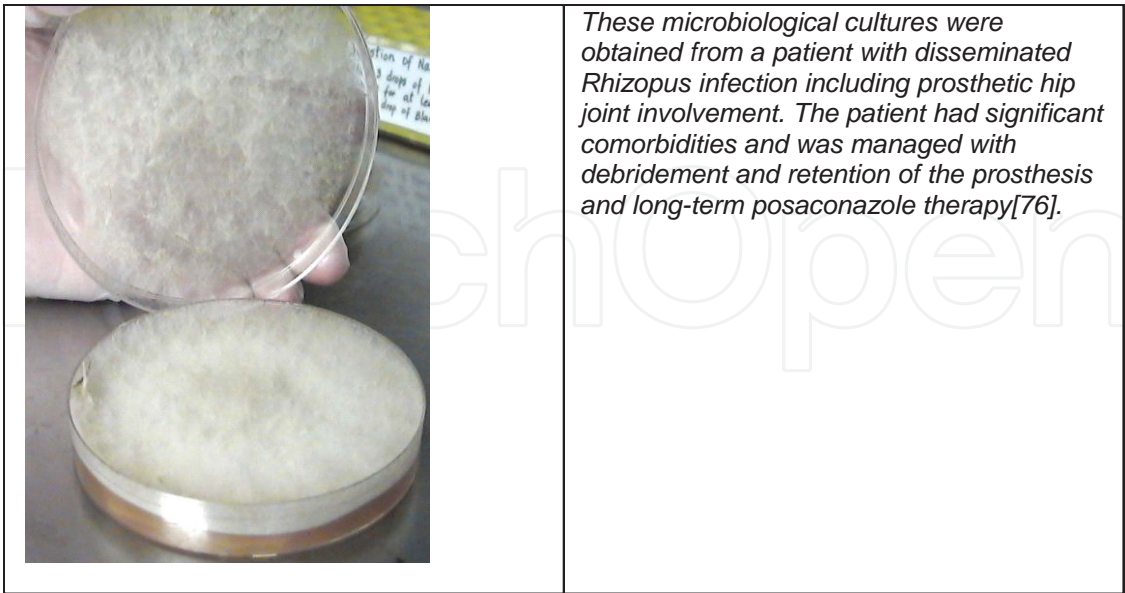
Evidence of the ability of *Propionibacterium acnes* to form biofilms is emerging. A number of in-vitro models have been developed to assess the activity of antibiotics against biofilm-associated *Propionibacterium*. As with staphylococcal biofilm models, the activity of rifampicin is preserved with *Propionibacterium* biofilms[71]. The emergence of rifampicin resistance with monotherapy has not been demonstrated[71]. In one study combination therapy with daptomycin and rifampicin was the most effective treatment regimen[71]. Other studies have demonstrated penicillin alone or combination therapy with rifampicin and linezolid are also effective against *Propionibacterium* biofilms[72].

The antibiotic regimens reported to treat patients with *Propionibacterium acnes* prosthetic joint infection are diverse and include: penicillin, amoxicillin, ceftriaxone, clindamycin and rifampicin-fluoroquinolone or rifampicin-clindamycin combination therapy [73, 74]. In general, we recommend IV benzylpenicillin followed by high dose oral amoxicillin combined with rifampicin.

## 12. Fungi

Fungal prosthetic joint infections are rare. The majority of fungal prosthetic joint infections are due to *Candida* species however, other fungal species have been reported including *Aspergillus* species, *Cryptococcus neoformans*, *Zygomycetes*, *Histoplasma capsulatum*, *Rhodotorula minuta* [75-78] (figure 4).

The results for debridement and retention and exchange procedures for management of fungal prosthetic joint are poor. In treatment guidelines from the Infectious Diseases Society of America, resection arthroplasty is recommended for prosthetic joint infection due to candidal species[79]. In addition, the use of a spacer following resection of the prosthesis is associated with a high rate of failure and should be avoided [75, 80]. If reimplantation is considered following prosthesis resection, a prolonged period (3-6 months) prior to reinsertion is recommended [81]. Finally, in candidal prosthetic joint infections, there is emerging evidence that the activity of caspofungin is better preserved in the presence of biofilm, compared to fluconazole [80, 82]. For other non candidal fungi, individualized expert advice should be sought to guide antimicrobial choice.



**Figure 4.** *Rhizopus* species cultured from an infected prosthetic hip joint. Photo courtesy of Dr Harsha Sheorey, Microbiology Department, St Vincent’s Hospital Melbourne.

### 13. Culture negative

One of the greatest challenges in management is the 'culture negative' prosthetic joint infection. In published case series, the reported rate of culture-negative prosthetic joint infection ranges from 5-41% [3, 27, 83]. A number of factors contribute to the failure of microbiological cultures to isolate a pathogen including poor culture technique (including obtaining fewer than 5 intra-operative specimens), fastidious organisms that are difficult to culture and prior antibiotic exposure that impedes bacterial growth. Of these mechanisms, prior antibiotic exposure is the most common reason for failing to isolate a causative pathogen. In some studies, 44% of patients with culture negative prosthetic joint infection were receiving antibiotic therapy at the time of obtainment of microbiological specimens[30]. Indeed, the receipt of antibiotics in the 3 months prior to presentation with prosthetic joint infection, lead to a 5-fold increased chance of culture-negative prosthetic joint infection [41].

The choice of antibiotic treatment in culture negative prosthetic joint infection should be guided by local ecology. In addition, if patients had prior exposure to antibiotic therapy, the spectrum of these antibiotics may also influence subsequent antibiotic selection. The results for culture negative prosthetic joint infection are generally similar to culture positive prosthetic joint infection [41].

### 14. Conclusion

With an ageing population and the increasing popularity of arthroplasty, prosthetic joint infection will continue to present a diagnostic and management challenge to clinicians. Treatment approaches for arthroplasty infection are still under debate, in particular, optimal treatment strategy for different microorganisms. Increasing understanding of the role of biofilm in the pathogenesis of prosthetic joint infections and investigation of the activity of different antimicrobial agents against biofilm associated microorganisms will provide important information to guide therapy. In addition, multicentre studies and collaborative research groups are key to providing more detailed treatment particularly for less commonly encountered pathogens.

### Author details

Trisha Peel, Kirsty Buising, Michelle Dowsey and Peter Choong

University of Melbourne, St. Vincent's Hospital Melbourne, Australia



## References

- [1] Australian Orthopaedic Association. National Bone and Joint Registry Annual Report 2011. Adelaide 2011.
- [2] Kurtz S, Ong K, Lau E, Mowat F, Halpern M. Projections of primary and revision hip and knee arthroplasty in the United States from 2005 to 2030. *Journal of Bone and Joint Surgery* 2007;89-A(4):780-5.
- [3] Zimmerli W, Trampuz A, Ochsner PE. Prosthetic-joint infections. *New England Journal of Medicine*. 2004;351(16):1645-54.
- [4] Kurtz SM, Lau E, Schmier J, Ong KL, Zhao K, Parvizi J. Infection burden for hip and knee arthroplasty in the United States. *Journal of Arthroplasty*. 2008;23(7):984-91.
- [5] Bozic KJ, Ries MD. The impact of infection after total hip arthroplasty on hospital and surgeon resource utilization. *Journal of Bone and Joint Surgery*. 2005;87-A(8):1746-51.
- [6] Peel TN, Dowsey MM, Buising KL, Liew D, Choong PF. Cost analysis of debridement and retention for management of prosthetic joint infection. *Clinical Microbiology and Infection*. 2011;in press.
- [7] Kurtz SM, Lau E, Watson H, Schmier JK, Parvizi J. Economic burden of periprosthetic joint infection in the United States. *Journal of Arthroplasty*. 2012;in press.
- [8] Coste JS, Reig S, Trojani C, Berg M, Walch G, Boileau P. The management of infection in arthroplasty of the shoulder. *Journal of Bone and Joint Surgery* 2004;86-Br(1):65-9.
- [9] Vergidis P, Greenwood-Quaintance KE, Sanchez-Sotelo J, Morrey BF, Steinmann SP, Karau MJ, et al. Implant sonication for the diagnosis of prosthetic elbow infection. *Journal of Shoulder and Elbow Surgery*. 2011;20(8):1275-81.
- [10] Achermann Y, Vogt M, Spormann C, Kolling C, Remschmidt C, Wust J, et al. Characteristics and outcome of 27 elbow periprosthetic joint infections: results from a 14-year cohort study of 358 elbow prostheses. *Clinical Microbiology and Infection*. 2011;17(3):432-8.
- [11] Berbari EF, Hanssen AD, Duffy MC, Steckelberg JM, Ilstrup DM, Harmsen WS, et al. Risk factors for prosthetic joint infection: case-control study. *Clinical Infectious Diseases*. 1998;27(5):1247-54.
- [12] Kanafani ZA, Sexton DJ, Pien BC, Varkey J, Basmania C, Kaye KS. Postoperative joint infections due to *Propionibacterium* species: a case-control study. *Clinical Infectious Diseases*. 2009;49(7):1083-5.
- [13] Poss R, Thornhill TS, Ewald FC, Thomas WH, Batte NJ, Sledge CB. Factors influencing the incidence and outcome of infection following total joint arthroplasty. *Clinical Orthopaedics and Related Research*. 1984;182:117-.



- [14] Bengtson S, Knutson K. The infected knee arthroplasty. *Acta Orthopaedica Scandinavica*. 1991;62(4):301-11.
- [15] Yang K, Yeo SJ, Lee BP, Lo NN. Total knee arthroplasty in diabetic patients: a study of 109 consecutive cases. *Journal of Arthroplasty*. 2001;16(1):102-6.
- [16] Topolski MS, Chin PYK, Sperling JW, Cofield RH. Revision shoulder arthroplasty with positive intraoperative cultures: the value of preoperative studies and intraoperative histology. *Journal of Shoulder and Elbow Surgery*. 2002;15(4):402-6.
- [17] Peel TN, Dowsey MM, Daffy JR, Stanley PA, Choong PF, Buising KL. Risk factors for prosthetic hip and knee infections according to arthroplasty site. *Journal of Hospital Infection*. 2011;79(2):129-33.
- [18] Dowsey MM, Choong PFM. Obese diabetic patients are at substantial risk for deep infection after primary TKA. *Clinical Orthopaedics and Related Research*. 2009;467(6):1577-81.
- [19] Dowsey MM, Choong PF. Obesity is a major risk factor for prosthetic infection after primary hip arthroplasty. *Clinical Orthopaedics and Related Research*. 2008;466(1):153-8.
- [20] Surin VV, Sundholm K, Backman L. Infection after total hip replacement. With special reference to a discharge from the wound. *Journal of Bone and Joint Surgery* 1983;65-Br(4):412-8.
- [21] Costerton JW. Bacterial biofilms: a common cause of persistent infections. *Science*. 1999;284(5418):1318-22.
- [22] Parvizi J, Ghanem E, Azzam K, Davis E, Jaber F, Hozack W. Periprosthetic infection: are current treatment strategies adequate? *Acta Orthopædica Belgica*. 2008;74(6):793-800.
- [23] Pulido L, Ghanem E, Joshi A, Purtill JJ, Parvizi J, Pulido L, et al. Periprosthetic joint infection: the incidence, timing, and predisposing factors. *Clinical Orthopaedics and Related Research*. 2008;466(7):1710-5.
- [24] Moran E, Masters S, Berendt aR, McLardy-Smith P, Byren I, Atkins BL. Guiding empirical antibiotic therapy in orthopaedics: The microbiology of prosthetic joint infection managed by debridement, irrigation and prosthesis retention. *Journal of Infection*. 2007;55(1):1-7.
- [25] Nimmo GR, Pearson JC, Collignon PJ, Christiansen KJ, Coombs GW, Bell JM, et al. Prevalence of MRSA among *Staphylococcus aureus* isolated from hospital inpatients, 2005: report from the Australian Group for Antimicrobial Resistance. *Communicable Diseases Intelligence*. 2007;31(3):288-96.
- [26] Peel TN, Cheng AC, Buising KL, Choong PF. The microbiological aetiology, epidemiology and clinical profile of prosthetic joint infections: are current antibiotic prophylaxis

laxis guidelines effective? *Antimicrobial Agents and Chemotherapy*. 2012;56(5):2386-91.

- [27] Steckelberg JM, Osmon DR. Prosthetic Joint Infections. In: Waldvogel FA, Bisno AL, editors. *Infections Associated with Indwelling Medical Devices*. 3rd ed. Washington DC: ASM Press; 2000. p. 173-209.
- [28] Weber P, Utzschneider S, Sadoghi P, Andress HJ, Jansson V, Muller PE. Management of the infected shoulder prosthesis: a retrospective analysis and review of the literature. *International Orthopaedics*. 2011;35(3):365-73.
- [29] Piper KE, Jacobson MJ, Cofield RH, Sperling JW, Sanchez-Sotelo J, Osmon DR, et al. Microbiologic diagnosis of prosthetic shoulder infection by use of implant sonication. *Journal of Clinical Microbiology*. 2009;47(6):1878-84.
- [30] Berbari EF, Marculescu C, Sia I, Lahr BD, Hanssen AD, Steckelberg JM, et al. Culture-negative prosthetic joint infection. *Clinical Infectious Diseases*. 2007;45(9):1113-9.
- [31] Murdoch DR, Roberts SA, Fowler VG, Shah MA, Taylor SL, Morris AJ, et al. Infection of orthopedic prostheses after *Staphylococcus aureus* bacteremia. *Clinical Infectious Diseases*. 2001;32(4):647-9.
- [32] Inman RD, Gallegos KV, Brause BD, Redecha PB, Christian CL. Clinical and microbial features of prosthetic joint infection. *American Journal of Medicine*. 1984;77(1):47-53.
- [33] Trampuz A, Zimmerli W. Diagnosis and treatment of implant-associated septic arthritis and osteomyelitis. *Current Infectious Disease Reports*. 2008;10(5):394-403.
- [34] Kanafani ZA. Invasive *Propionibacterium* infections. In: UpToDate, Basow, DS (Ed), UpToDate, Waltham, MA; 2012.
- [35] Atkins BL, Athanasou N, Deeks JJ, Crook DWM, Simpson H, Peto TEA, et al. Prospective evaluation of criteria for microbiological diagnosis of prosthetic-joint infection at revision arthroplasty. *Journal of Clinical Microbiology* 1998;36(10):2932-9.
- [36] Parvizi J, Zmistowski B, Berbari E, Bauer T, Springer B, Della Valle C, et al. New definition for periprosthetic joint infection: from the workgroup of the musculoskeletal infection society. *Clinical Orthopaedics and Related Research*. 2011;469(11):2992-4.
- [37] Trampuz A, Piper KE, Jacobson MJ, Hanssen AD, Unni KK, Osmon DR, et al. Sonication of removed hip and knee prostheses for diagnosis of infection. *New England Journal of Medicine*. 2007;357(7):654-63.
- [38] Mirra JM, Amstutz HC, Matos M, Gold R. The pathology of the joint tissues and its clinical relevance in prosthesis failure. *Clinical Orthopaedics and Related Research*. 1976;117:221-40.
- [39] Peel TN, Buising KL, Choong PF. Diagnosis and management of prosthetic joint infection. *Current Opinion in Infectious Diseases*. 2012;in press.

- [40] Marculescu CE, Berbari EF, Hanssen AD, Steckelberg JM, Harmsen SW, Mandrekar JN, et al. Outcome of prosthetic joint infections treated with debridement and retention of components. *Clinical Infectious Diseases*. 2006;42(4):471-8.
- [41] Malekzadeh D, Osmon DR, Lahr BD, Hanssen AD, Berbari EF. Prior use of antimicrobial therapy is a risk factor for culture-negative prosthetic joint infection. *Clinical Orthopaedics and Related Research*. 2010;468(8):2039-45.
- [42] Schafer P, Fink B, Sadow D, Margull A, Berger I, Frommelt L. Prolonged bacterial culture to identify late periprosthetic joint infection: a promising strategy. *Clinical Infectious Diseases*. 2008;47(11):1403-9.
- [43] Brandt CM, Sistrunk WW, Duffy MC, Hanssen AD, Steckelberg JM, Ilstrup DM, et al. *Staphylococcus aureus* prosthetic joint infection treated with debridement and prosthesis retention. *Clinical Infectious Diseases*. 1997;24(5):914-9.
- [44] Zimmerli W, Frei R, Widmer AF, Rajacic Z. Microbiological tests to predict treatment outcome in experimental device-related infections due to *Staphylococcus aureus*. *Journal of Antimicrobial Chemotherapy*. 1994;33:959-67.
- [45] Zimmerli W, Widmer AF, Blatter M, Frei R, Ochsner PE. Role of rifampin for treatment of orthopedic implant-related staphylococcal infections: a randomized controlled trial. *Journal of the American Medical Association*. 1998;279(19):1537-41.
- [46] Senneville E, Joulie D, Legout L, Valette M, Dezeque H, Beltrand E, et al. Outcome and predictors of treatment failure in total hip/knee prosthetic joint infections due to *Staphylococcus aureus*. *Clinical Infectious Diseases*. 2011;53(4):334-40.
- [47] Aboltins CA, Page MA, Buising KL, Jenney AWJ, Daffy JR, Choong PFM. Treatment of staphylococcal prosthetic joint infections with debridement, prosthesis retention and oral rifampicin and fusidic acid. *Clinical Microbiology and Infection*. 2007;13(6):586-91.
- [48] Forrest GN, Tamura K. Rifampin combination therapy for nonmycobacterial infections. *Clinical Microbiology Reviews*. 2010;23(1):14-34.
- [49] Segreti J, Nelson JA, Trenholme GM. Prolonged suppressive antibiotic therapy for infected orthopedic prostheses. *Clinical Infectious Diseases*. 1998;27(4):711-3.
- [50] Soriano a, Gomez J, Gomez L, Azanza JR, Perez R, Romero F, et al. Efficacy and tolerability of prolonged linezolid therapy in the treatment of orthopedic implant infections. *European Journal of Clinical Microbiology and Infectious Diseases*. 2007;26(5):353-6.
- [51] Rao N, Regalla DM. Uncertain efficacy of daptomycin for prosthetic joint infections. *Clinical Orthopaedics and Related Research*. 2006;451:34-7.
- [52] John A-K, Baldoni D, Haschke M, Rentsch K, Schaerli P, Zimmerli W, et al. Efficacy of daptomycin in implant-associated infection due to methicillin-resistant *Staphylo-*

coccus aureus: importance of combination with rifampin. *Antimicrobial Agents and Chemotherapy*. 2009;53(7):2719-24.

- [53] Achermann Y, Clauss M, Derksen L, Raffener P, Zellweger C, Eigenmann K, et al. Risk factors for rifampin resistance of staphylococci causing periprosthetic joint infections S 7.4. 29th Annual Meeting of the European Bone and Joint Infection Society; September 2 – 4 Heidelberg, Germany 2010.
- [54] Deirmengian C, Greenbaum J, Stern J, Braffman M, Lotke PA, Booth RE, Jr., et al. Open debridement of acute gram-positive infections after total knee arthroplasty. *Clinical Orthopaedics and Related Research* 2003;416(11):129-34.
- [55] Meehan AM, Osmon DR, Duffy MC, Hanssen AD, Keating MR. Outcome of penicillin-susceptible streptococcal prosthetic joint infection treated with debridement and retention of the prosthesis. *Clinical Infectious Diseases*. 2003;36(7):845-9.
- [56] Everts RJ, Chambers ST, Murdoch DR, Rothwell AG, McKie J. Successful antimicrobial therapy and implant retention for streptococcal infection of prosthetic joints. *ANZ Journal of Surgery* 2004;74(4):210-4.
- [57] Gaunt PN, Seal DV. Group G streptococcal infection of joints and joint prostheses. *Journal of Infection*. 1986;13(2):115-23.
- [58] Sendi P, Christensson B, Uckay I, Trampuz A, Achermann Y, Boggian K, et al. Group B streptococcus in prosthetic hip and knee joint-associated infections. *Journal of Hospital Infection*. 2011;79(1):64-9.
- [59] Zeller V, Lavigne M, Leclerc P, Lhotellier L, Graff W, Ziza JM, et al. Group B streptococcal prosthetic joint infections: a retrospective study of 30 cases. *Presse Medicale*. 2009;38(11):1577-84.
- [60] Zeller V, Lavigne M, Biau D, Leclerc P, Ziza JM, Mamoudy P, et al. Outcome of group B streptococcal prosthetic hip infections compared to that of other bacterial infections. *Joint Bone Spine*. 2009;76(5):491-6.
- [61] El Helou OC, Berbari EF, Marculescu CE, El Atrouni WI, Razonable RR, Steckelberg JM, et al. Outcome of enterococcal prosthetic joint infection: is combination systemic therapy superior to monotherapy? *Clinical Infectious Diseases* 2008;47(7):903-9.
- [62] Mandell GL, Bennett JE, Dolin R. *Principles and Practice of Infectious Diseases*. 7th ed. Philadelphia, PA, USA: Churchill Livingstone Elsevier; 2010.
- [63] Euba G, Lora-Tamayo J, Murillo O, Pedrero S, Cabo J, Verdaguer R, et al. Pilot study of ampicillin-ceftriaxone combination for treatment of orthopedic infections due to *Enterococcus faecalis*. *Antimicrobial Agents and Chemotherapy*. 2009;53(10):4305-10.
- [64] Holmberg A, Morgelin M, Rasmussen M. Effectiveness of ciprofloxacin or linezolid in combination with rifampicin against *Enterococcus faecalis* in biofilms. *Journal of Antimicrobial Chemotherapy*. 2012;67(2):433-9.

- [65] Widmer AF, Wiestner A, Frei R, Zimmerli W. Killing of nongrowing and adherent *Escherichia coli* determines drug efficacy in device-related infections. *Antimicrobial Agents and Chemotherapy*. 1991;35(4):741-6.
- [66] Hsieh P-H, Lee MS, Hsu K-Y, Chang Y-H, Shih H-N, Ueng SW. Gram-negative prosthetic joint infections: risk factors and outcome of treatment. *Clinical Infectious Diseases*. 2009;49(7):1036-43.
- [67] Aboltins CA, Dowsey MM, Buising KL, Peel TN, Daffy JR, Choong PF, et al. Gram-negative prosthetic joint infection treated with debridement, prosthesis retention and antibiotic regimens including a fluoroquinolone. *Clinical Microbiology and Infection*. 2011;17(6):862-7.
- [68] Legout L, Senneville E, Stern R, Yazdanpanah Y, Savage C, Roussel-Delvallez M, et al. Treatment of bone and joint infections caused by gram-negative bacilli with a cefepime-fluoroquinolone combination. *Clinical Microbiology and Infection*. 2006;12(10):1030-3.
- [69] McDonald DJ, Fitzgerald RH, Ilstrup DM. Two-stage reconstruction of a total hip arthroplasty because of infection. *Journal of Bone and Joint Surgery*. 1989;71(6):828-34.
- [70] Salvati EA, Chekofsky KM, Brause BD, Wilson PD. Reimplantation in infection. *Clinical Orthopaedics and Related Research*. 1982;170:62-75.
- [71] Tiffin UF, Corvec S, Betrisey B, Zimmerli W, Trampuz A. Role of rifampin against *Propionibacterium acnes* biofilm in vitro and in an experimental foreign-body infection model. *Antimicrobial Agents and Chemotherapy* 2012;56(4):1885-91.
- [72] Bayston R, Nuradeen B, Ashraf W, Freeman BJ. Antibiotics for the eradication of *Propionibacterium acnes* biofilms in surgical infection. *Journal of Antimicrobial Chemotherapy* 2007;60(6):1298-301.
- [73] Lutz MF, Berthelot P, Fresard A, Cazorla C, Carricajo A, Vautrin AC, et al. Arthroplastic and osteosynthetic infections due to *Propionibacterium acnes*: a retrospective study of 52 cases, 1995-2002. *European Journal of Clinical Microbiology and Infectious Diseases* 2005;24(11):739-44.
- [74] Zeller V, Ghorbani A, Strady C, Leonard P, Mamoudy P, Desplaces N. *Propionibacterium acnes*: an agent of prosthetic joint infection and colonization. *Journal of Infection*. 2007;55(2):119-24.
- [75] Azzam K, Parvizi J, Jungkind D, Hanssen A, Fehring T, Springer B, et al. Microbiological, clinical, and surgical features of fungal prosthetic joint infections: a multi-institutional experience. *Journal of Bone and Joint Surgery*. 2009;91-A Suppl 6:142-9.
- [76] Peel T, Daffy J, Thursky K, Stanley P, Buising K. Posaconazole as first line treatment for disseminated zygomycosis. *Mycoses*. 2008;51(6):542-5.
- [77] Johannsson B, Callaghan JJ. Prosthetic hip infection due to *Cryptococcus neoformans*: case report. *Diagnostic Microbiology and Infectious Disease*. 2009;64(1):76-9.



- [78] Marculescu CE, Berbari EF, Cockerill FR, 3rd, Osmon DR. Fungi, mycobacteria, zoonotic and other organisms in prosthetic joint infection. *Clinical Orthopaedics and Related Research*. 2006;451(10):64-72.
- [79] Rex JH, Walsh TJ, Sobel JD, Filler SG, Pappas PG, Dismukes WE, et al. Practice guidelines for the treatment of candidiasis. *Infectious Diseases Society of America. Clinical Infectious Diseases*. 2000;30(4):662-78.
- [80] Garcia-Oltra E, Garcia-Ramiro S, Martinez JC, Tibau R, Bori G, Bosch J, et al. Prosthetic joint infection by *Candida* spp. *Rev Esp Quimioter*. 2011;24(1):37-41.
- [81] Phelan DM, Osmon DR, Keating MR, Hanssen AD. Delayed reimplantation arthroplasty for candidal prosthetic joint infection: a report of 4 cases and review of the literature. *Clinical Infectious Diseases*. 2002;34(7):930-8.
- [82] Uppuluri P, Srinivasan A, Ramasubramanian A, Lopez-Ribot JL. Effects of fluconazole, amphotericin B, and caspofungin on *Candida albicans* biofilms under conditions of flow and on biofilm dispersion. *Antimicrobial Agents and Chemotherapy*. 2011;55(7):3591-3.
- [83] Bejon P, Berendt A, Atkins BL, Green N, Parry H, Masters S, et al. Two-stage revision for prosthetic joint infection: predictors of outcome and the role of reimplantation microbiology. *Journal of Antimicrobial Chemotherapy*. 2010;65(3):569-75.



