

# We are IntechOpen, the world's leading publisher of Open Access books Built by scientists, for scientists

6,900

Open access books available

186,000

International authors and editors

200M

Downloads

Our authors are among the

154

Countries delivered to

TOP 1%

most cited scientists

12.2%

Contributors from top 500 universities



WEB OF SCIENCE™

Selection of our books indexed in the Book Citation Index  
in Web of Science™ Core Collection (BKCI)

Interested in publishing with us?  
Contact [book.department@intechopen.com](mailto:book.department@intechopen.com)

Numbers displayed above are based on latest data collected.  
For more information visit [www.intechopen.com](http://www.intechopen.com)



---

# **The Role of Human Papillomavirus in Pre-Cancerous Lesions and Oral Cancers**

---

Danilo Figueiredo Soave, Mara Rubia Nunes Celes,  
João Paulo Oliveira-Costa, Giorgia Gobbi da Silveira,  
Bruna Riedo Zanetti, Lucinei Roberto Oliveira and  
Alfredo Ribeiro-Silva

Additional information is available at the end of the chapter

<http://dx.doi.org/10.5772/55943>

---

## **1. Introduction**

The head and neck squamous cell carcinomas (HNSCC) are the sixth most frequent malignancy worldwide. It is properly established as heterogeneous solid tumor, composed by cells with different phenotypic features with malignant potential. Oral squamous cell carcinoma (OSCC) is a significant subset of the worldwide burden of HNSCCs. It is essential the understanding of the OSCC biology and biological behavior of pre-cancerous conditions and pre-cancerous lesions that may be responsible for malignant transformation. Heterogeneity in prevalence and anatomic distribution are associated to demographic differences in the habits of exposure tobacco and alcohol. The use of tobacco and alcohol are often established as risk factors for OSCC, but this phenomenon could also emerge in individuals not exposed to them. As OSCC, the pre-cancerous lesions also present a strict connection to tobacco consumption. However, a relationship between alcohol carcinogenic effect and pre-cancer lesions are not clear. These populations that develop the pre-cancer lesions or OSCC in the absence of prior contact with risk factors suggest that others factors can play a role in head and neck carcinogenesis. There is a longstanding analysis, over the past 2 decades, whether the human papilloma virus (HPV) infection could have a role in the OSCC carcinogenesis. HPV were first established as cancer development agent in cervical cancer, succeeding reports established the HPV infection in mucosal tissues of the oral cavity upper gastrointestinal tract, anogenital tract. In cervical cancer the categorization subdivided the HPV types into low-risk high-risk types, only the types 16, 18, 31, 33, 35, 39, 45, 51, 52, 56, and 58 are consistently grouped as high risk. The high-

risk types 16 and 18, as in the cervical and anogenital cancer, are the most common entities detected in pre-cancerous and HNSCC lesions. Miller & Johnstone [1] describe that likelihood of detecting HPV, comparing pre-cancerous lesions and HNSCC to normal epithelium, was three times higher in pre-cancerous lesions and four a five times higher in HNSCC. In despite of large number of studies, the accurate role of HPV in the HNSCC development and progression has been controversial so as in OSCC. HPVs are a circular virion enclosed in a small capsid. The carcinogenic process occurs through the HPV-DNA integration into host cell. Usually, the viral oncoproteins codified by HPV-DNA, leads a functional alteration in p53 and pRb pathways, and consequently genomic instability. However, the oncoproteins expression alone is not sufficient to induce neoplastic transformation suggesting the requirement of supplementary genetic modifications. Increased understanding of the role of HPV antigens in neoplastic pathogenesis confirms the HPV as an etiological agent for cancers and, the knowledge of HPV cancer biology consequently will provide the development of preventive vaccines and antiviral treatment. The HPV vaccines have been formulated as a result of core technologies implementation that is able to construct virus-like particles (VLPs) equivalent to natural virions but, at the same time, are not capable to induce an infectious process. In addition, in this chapter we will discuss the HPV relationship with the pre-cancerous lesions and OSCC. The present data summarize the knowledge regarding the epidemiology, behavior, biology, malignant transformation mechanisms, and prognosis of HPV infection.

## 2. A brief history of papillomavirus and cancer

Human Papillomavirus infection was firstly identified from the embalmed body of a 12<sup>th</sup> century B.C. ancient Egyptian worker [2]. During the mummy necropsy procedure Scientists observed a wart on the sole of his foot. This evidences demonstrated that HPV infection occurred [3]. Medical literary tidings regard skin and genital warts were described in classical Greek and Roman literature [2]. However, association between viral origin of warts and sexual transmission was only confirmed in 19<sup>th</sup> century [2]. Rigoni-Stern (1842) hypothesized that cervical cancer could be promoted through sexual contacts. The Italian physician postulated this conception through the observation of high rates on cervical cancer in sexually active women, in comparison with non-sexually active women. [4]. Essays to establish relationship between cervical cancer and HPV-infections were initiated in 1972, this hypothesis was supported by a rare description of condylomata acuminata malignant transformation into squamous cell carcinomas highlighting the carcinogenic potential of hpv [4]. Harald zur Hausen, in 1975 [5], published that HPV could have a pivotal role in human cervix carcinogenesis. Eight year after, Hausen et al. identified the subtypes HPV16 and 18 on cervix cancer.

HPV infection was well established as etiologic factor of almost 100% of cervical malignancies [6]. After this appointment, several studies have addressed to find presence and prevalence of HPV infection in different tumor sites, including skin, urethra, nasal cavity, paranasal sinus, larynx, tracheobronchial mucosa and oral cavity [7]. In 1983, a series of studies presented by Syrjänen et al. [8] highlighted the possible correlation between HPV and oral lesions (non-neoplastic, benign and malignant lesions). At the same year, a light microscopy study

provided by Syrjänen et al. [9-11] firstly suggested a link among HPV infection, HNSCC and OSCC, through the examination of 40 biopsy specimens. These authors described morphological alterations caused by HPV infection in 16 cases; this observation gives supports to HPV involvement in the development of OSCC. However, the confirmatory evidence of HPV-DNA in the oral lesions was presented only in 1985 [6,12]. Although the presence of HPV DNA has been suggested as a possible etiologic factor of oral pre-cancer and cancer, this association has not been as reliable as in cervical cancers.

### 3. HPV biology: General considerations

HPV represent a group of DNA viruses that was recently recognized to form their own family, Papillomaviridae that initially, together with polyomaviruses, was grouped in the Papovaviridae family [13]. They are an ancient family of pathogens and are known to infect epithelial tissues of amphibians, reptiles, birds and mammals [14]. The virus is formed by a non-enveloped icosahedral capsid with circular double-stranded DNA [15-16]. The genome is small, comprising to 8.000 base pairs, but it is complex, composed of three distinct regions: early region (E), late region (L) and upstream regulatory region (URR) or long region control (LCR).

The E region contains from seven to eight genes (E1, E2, E3, E4, E5, E6, E7 and E8), of which E1 is related with viral replication, E2 with viral transcription and DNA replication, E4 with maturation and alteration of extracellular matrix cell and E5, E6 and E7 are involved in cellular transformation. The E3 and E8 genes have been recently described only in a few HPV types but their function is unknown [16-18]. The L region containing two genes, L1 and L2, which encode structural proteins necessary for viral capsid formation in the final stages of replication. Both E and L are coding region therefore called open reading frames (ORF), however the region URR does not fit in this description because it is a non-coding region. The URR region is found between E and L region and contain promoter and enhancer DNA sequences critical to regulate viral replication and transcription by both viral and cellular genes [19].

Based on phylogenetic analysis, the HPV is classified into genera (alpha, beta, gamma, mu and nu), species and types [15]. The classification of HPV types is based mainly on analyses of the L1 gene, which is the most conserved gene in all known papillomaviruses. When the DNA sequence of the L1 ORF differs by more than 10% from the closest known virus type, a new papillomavirus is recognized. Differences between 2% and 10% homology define a subtype and less than 2% a variant. A viral variant can differ between 2% in coding regions and 5% in non-coding regions [13,15]. Currently, approximately 150 different types are recognized and 120 HPV types are fully sequenced [18]. Types classified as members of the same species with approximately 80-90% of similarities trend to share biological properties such as the tissue tropism, disease manifestation, and pathogenicity [14].

According to their tropism, the HPV also can be classified as cutaneous and mucosal type. The cutaneous type are associated with skin lesions, being HPVs 1, 2 and 4 the most prevalent in common and plantar warts, and the types 5, 8, 9, 12, 14, 15, 17, 19-25, 36, 46 and 47 the most

frequent in epidermodysplasia verruciforme. HPV-5 and -8 are associated with skin carcinoma [20-21]. HPV with mucous tropism infects the anogenital tract, upper aero digestive tract, other head and neck mucosa and are generally subdivided into high-risk and low-risk type based on their oncogenical potential. The most relevant low-risk type are HPV-6 and 11, however the types 40, 42, 43, 44, 54, 61, 70, 72 can be observed in genital benign lesions. Among the high-risk types, the HPV 16 and 18 are most common; especially type 16, which can be found in various cancers such as cervical, oropharyngeal and penile carcinomas. Types 31, 33, 35, 52, 58 and 67 belong to a category of moderate to high-risk [20,22-24].

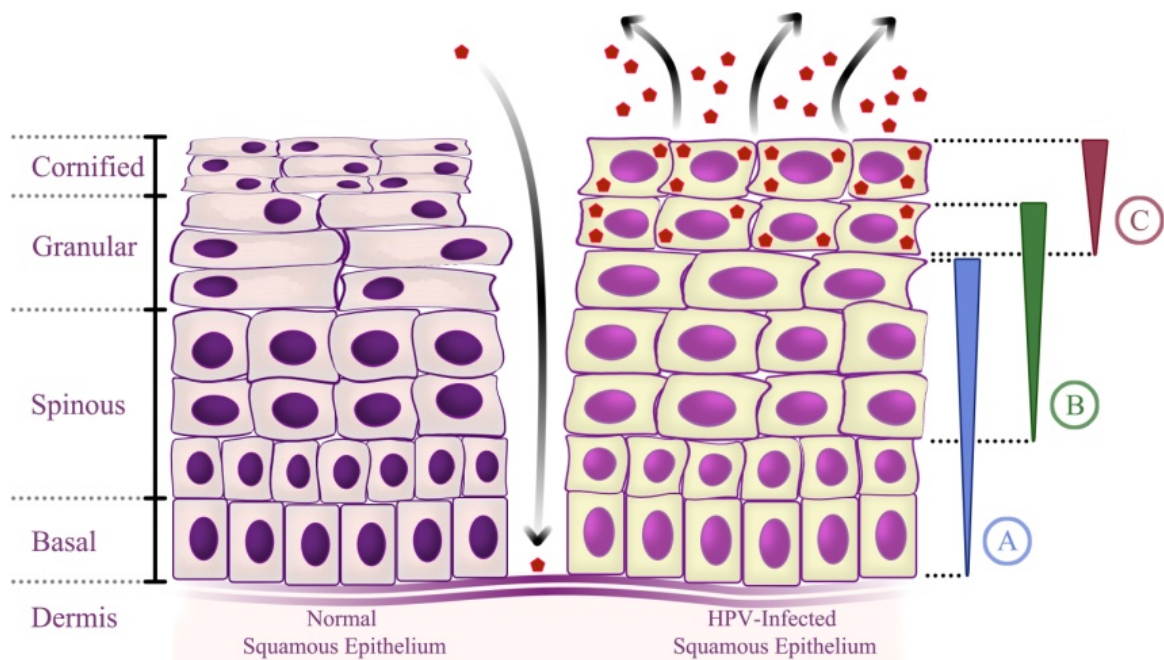
HPV life cycle is closely linked to the differentiation program of infected epithelial cells, more specifically the keratinocytes. Infection is initiated through microlesions in the epithelium, which allow virions come in contact with the basal cell layer by direct HPV receptor connection to surface host cell ligands. The receptors involved are not fully identified, but some data revealed a role for  $\alpha 6$  integrin and heparin sulfate. Following infection, the virus probably maintains its genome as a low copy number episome in the basal cells of the epithelium, providing a reservoir of viral DNA for further use in cell divisions. When infected basal cells begin to divide, viral DNA is distributed among the daughter cells with a massive upregulation of expression of all early genes mainly the E6 and E7. After mitosis some daughter cells may persist in the basal layers, whereas other move toward the upper layers of the epithelium and begin to differentiate. During this differentiation process there is viral DNA replication that amplifies the amount of virus at least 1000 copies per cell, and finally expression of the coat proteins L1 and L2 followed by assembly of infectious virus [25-28].

The mechanism of viral-induced cell growth is analogous to other tumors viruses that deregulate the cell cycle. Cancer appearance in lesions with persistent HPV is related to the overexpression of E6 and E7 proteins. E6 interfere with the function of p53 whereas E7 with the function of Rb protein, leading to abnormal cells growth by promoting inhibition of apoptosis and dysregulation of cell cycle, respectively. [28]. Basically, HPV infection occurs through sexual contact, non-sexual contact and maternal contact. In healthy individuals most (around 80%) HPV infections clear spontaneously but in some cases, HPV infection persist, leading to cancer development [26,29]. A series of events allows the viral persistence: differentiation-specific organization of the virus life cycle, mechanisms to maintain genome copy-number in undifferentiated cells, angiogenesis promotion, and strategies to evade both innate and adaptive immune surveillance [28].

#### 4. HPV and head and neck sites

Twenty-five percent of HNSCC are associated with HPV [30]. There is increasing evidences that sexual practices are the means by which HPV-Positive HNSCC patients are exposed to virus. Therefore, changes in sexual practices (young people with their first sexual experience at an earlier age, numbers of sexual partners and higher probability of engaging in oral sex compared to individuals from earlier decades) may be associated with HPV-infection prevalence [31].





**Figure 1.** Human Papillomavirus Life Cycle: A: Early gene expression E1, E2, E6 and E7; B: Viral genome amplification; C: Virion assembly and release (Adapted from Moody & Laimins 2010).

Recently, a specific correlation between HPV-positive patients and sexual behavior has been established in HNSCC [32]. This study shown, in patients with HNSCC, that high-risk HPV-16 was correlated with vaginal/oral sex partners, casual sex habits and infrequent users of barriers during vaginal/oral sex. Heck et al. [31] presents association between HNSCC subtypes and sexual behavior. In Oropharynx Cancer the prevalence of HPV infection is close to 36% [30] and this entity was associated with the number of sexual partners and lifetime oral sex partners [31]. A similar result was described by D'Souza et al. [33], which presented an association between HPV-16 measurements and presence of oral HPV-infection. The authors has also found HPV-16–positive oropharyngeal cancer correlated with oral-sex or vaginal-sex partners, engagement in casual sex, early age at first intercourse, and infrequent use of condoms. In tonsillar cancers, Hemminki et al. [34] demonstrated that women with cervical lesions present an increased risk of tonsillar cancer. In addition, increased risk was also found among husbands of women with invasive cervical malignancies. Heck et al., [31] has also found correlation among tonsillar cancers, number of oral sex partners, and earlier age at sexual debut. At the same study, another subtype of HNSCC (Cancer of the Base of the Tongue) was associated with sexual behavior; it was related with oral sex among women, number of sexual partners, and among men presenting history of same-sex sexual contact.

The sexual behavior has been associated with oral HPV-infection. Univariate analysis showed that oral HPV-infection was significantly increased with the lifetime number of oral/vaginal sex partners. Multivariate analysis demonstrated that oral HPV-infection was significantly elevated among individuals who reported having either 10 oral or 25 vaginal sex partners during their life [35]. In addition, a curious fact was demonstrated: the open-

mouthed kissing was associated with oral HPV-infections and could contribute to HPV-infection among individuals who might not otherwise be exposed. To summarize, all these findings suggests that HPV- infection sexually transmitted could play an important role in HNSCC carcinogenesis [35].

5. Oral premalignant lesions

The transformation of normal oral mucosa in OSCC entities can be linked to the emergence of Pre-Cancerous lesion [36]. This association with several oral mucosa disorders such as oral leukoplakia, oral erythroplakia, oral lichen planus, nicotine stomatitis, tobacco pouch keratosis and oral submucous fibrosis (Table1) could be seen. However, that kind of disorders presents a varied spectrum of malignant transformation potential [37]. Reviewing the clinical features of oral Pre-Cancerous lesions and OSCC, the literature emphatically agrees that the early detection is the most important strategy for diagnosis and prevention of OSCC [37]. Applying this diagnosis strategy the OSCC-patients reduces the treatment in advanced stages, thereby increasing the chances of cure [36]. One of the extensive efforts in the clinical management of patients diagnosed with Pre-Cancerous lesions is to delineate clinical outcome, since it is difficult to separate lesions that follow a benign transformation from the entities that are predisposed to malignant course [38]. However, can be observed only a subset of Pre-Cancerous lesions following the malignant course blowing in OSCC.

Disease Name	Malignant Potential
Proliferative Verrucous Leukoplakia (PVI)	6
Nicotine Palatinus in Reverse Smokers	5
Erythroplakia	5
Oral Submucous Fibrosis	5
Erythroleukoplakia	4
Granular Leukoplakia	4
Laryngeal Keratosis	3
Actinic Cheilosis	3
Smooth. Thick leukoplakia	2
Smooth. Red Tongue of Plummer-Vinson Syndrome	2
Smokeless Tobacco Keratosis	1
Lichen Planus (erosive forms)	1
Smooth Thin Leukoplakia	+/-

Table 1. Malignant transformation Potential of *Precancerous Lesions* (adapted from Neville et al. 2009).

The role of HPV in cancer has been exhausted discuss during the recent years. However, HPV in Pre-Cancerous lesions malignant transformation remains under study. Currently, some of the most studied Pre-Cancerous lesions in the literature are: Oral leukoplakia, Oral erythroplakia, Oral lichen planus Oral submucous fibrosis and Smokeless tobacco keratosis. Aimed to understand the malignant potential of theses lesions some author have attempted to relate the disorder progression with HPV malignant mechanism. Even so, the complete knowledge of viral infection and malignant transformation still remains obscure and controversial.

### 5.1. Oral leukoplakia and HPV

Oral leukoplakia (OL) is considered an uncommon potentially malignant lesion of the oral mucosa. In 1978, Kramer and colleagues defined Oral leukoplakia as “a white patch or plaque that cannot be characterized clinically or histopathologically, as any other disease” [39]. Observing only oral Pre-Cancerous Lesions, OL is the most frequent potentially malignant lesion of this mucosa, represents 85% of oral Pre-Cancerous Lesions presenting a predilection to male gender [40-42]. However, additional reports found no differences among gender [43]. OL affects 3% of white adults [42] with age distribution in the developed countries between the fourth and seventh decades of life, whilst in the developing countries might occur up to 5-10 years earlier [41].

Clinically, OL can be separated in homogeneous and non-homogeneous leukoplakias entities. The first group (homogeneous) was classified into flat, corrugated, wrinkled and pumice-like, and the latter group of leukoplakias (non-homogeneous) was classified into verrucous, nodular, ulcerated and erythroleukoplakia. The authors has also describes that a non-homogeneous leukoplakias presents an increased malignant potential when compared to homogeneous entities [44]. OL can be microscopically characterized by a hyperkeratosis of squamous epithelium. This hyperkeratosis consists of hyperparakeratosis or hyperorthokeratosis; however, a combination between hyperparakeratosis and hyperorthokeratosis also can be seen. In spite of hyperkeratosis, the underlying epithelium layer can show atrophy or thinning. However, spinous layer can presents acanthosis process and the subjacent connective tissue can present a chronic inflammatory infiltrate, ranging from spread foci of inflammatory cells presented in smooth leukoplakia to the numerous foci observed on speckled leukoplakia [42].

Through the years, OL increases the tendency to malignant transformation [45]. The causes of OL remain unclear, in spite of that tobacco intake is considered the most common risk factor for oral leukoplakia development [41-42]. This relation seems to be universal; it appears both in the developing and developed world [41,46]. HPV-infection was well established as etiologic factor of almost 100% of cervical malignancies [6]. Through this establishment, several studies have addressed to find presence and prevalence of HPV-infection in different tumor sites. In the oral cavity, benign lesions have been associated with 24 types of HPV (1, 2, 3, 4, 6, 7, 10, 11, 13, 16, 18, 30, 31, 32, 33, 35, 45, 52, 55, 57, 59, 69, 72 and 73) and malignant entities have been associated with HPV types 2, 3, 6, 11, 13, 16, 18, 31, 33, 35, 52 and 57 [47-48].

Presence of HPV-DNA was more frequent in pre-cancerous lesions and OSCC when compared with control samples. However, only pre-cancerous lesions reach a statistical significance ( $P = 0.0216$ ) [49]. Comparing OSCC and control samples with pre-cancerous lesions pre-cancerous



lesions the authors also found a significant prevalence of Low- risk HPV in pre-cancerous lesions. Significant prevalence of Low-risk HPV in pre-cancerous lesions has also observed by Miller & Johnstone [1] meta-analysis. They reported that low-risk HPV DNA was more prevalent in OL and; on the contrary, observed that high-risk HPVs was 2.8 times more frequent in OSCC.

The presence of HPV has been analyzed in potentially malignant lesions, and HPV DNA has been found in different proportions. Sugiyama et al. [50] detected HPV-16 and -18 in normal, dysplastic, and malignant oral epithelium and found statistical significance between the HPV-16 detection in epithelial dysplasia group and OSCC group. A study comparing normal oral mucosa, OL and OSCC was coordinated by Llamas-Martinez et al. [51], aiming to determinate the HPV genome as an independent clinicopathological factor and detect different HPV-genotypes. The data do not show relationship between HPV-genotypes and clinicopathological factors. However, the presence of HPV-16 was increased in OL and OSCC (14/35 cases 40%, 11/33 cases 33.3% ( $p=0,0005$ ); respectively). These results suggest that HPV-16 is related with OL and OSCC pathogenesis. Campisi et al. [52] investigating the relation among High-Risk HPV infection, apoptosis (bcl-2 and survivin) and proliferation biomarkers (PCNA) observed HPV-DNA in 38.1% of samples. HPV infection was associated with survivin and PCNA suggesting the interference of HPV on epithelial maturation. A year before, Lo Muzio et al. [53] showed increased rates of HPV-positive OL related with a survivin expression and suggested an unfavorable clinical outcome to these lesions. This unfavorable behavior was induced by influence of survivin on apoptosis process.

In conclusion, the correlation between OL malignant transformation and HPV infection were not totally understood. However, these data suggests that HPV-infection could play an important role in oral carcinogenesis leading to OL malignant transformation.

## 5.2. Oral erythroplakia and HPV

The expression 'erythroplasia' initially was used to describe a reddish precancerous lesion that develops on the glans of penis [55]. Due to clinical and histopathological similarities with genital process, the reddish precancerous oral lesion has also named erythroplakia. The *Oral erythroplakia* (OE) is presented like an unknown-causes lesion. However, it is assumed the same association with OSCC [42]. The authors has also describes that OE presents an increased malignant potential when compared with others pre-cancerous entities [42,55], Older men are predominantly affected by OE with peak prevalence in the sixth decade of life (65 to 74 years). Floor of mouth, tongue, and soft palate are the most common sites of involvement [42].

Clinically, OE may be associated with leukoplakia (erythroleukoplakia) and OSCC [56]. Usually, the lesions do not present symptoms but, is not uncommon some patients reporting a burning sensation and/or sore. The altered mucosa can present a well-demarcated erythematous macule or plaque with a soft, velvety texture [55]. Microscopically, reddish color of erythroplakia can be explained by a combination of features. Red color is presented by underlying microvasculature, and additionally, this color can be due to low keratinization and epithelial thinness [42]. Generally, OE can be associated to severe epithelial dysplasia and, at the time of biopsy, may presents 'carcinoma in situ' or 'invasive carcinoma' [55].

Information about the role of HPV infection in OE is limited. Reichart & Philipsen (2004) discussed the role of hpv infection in OE together with p53 alterations [56]. Nielsen et al. [57] immunohistochemically detected hpv-infection (by situ hybridisation and PCR) in potentially malignant oral lesions. Fifty percent of OE studied cases were HPV-positive. The authors suggest that HPV may be an etiologic co-factor involved in development of oral cancer. However, we can not assume that HPV is the major etiologic factor involved in malignant transformation of OE

### 5.3. Oral lichen planus and HPV

In 1869, Dr. Erasmus Wilson provided the first medical report about the chronic dermatologic disorder *lichen planus*. The British physician appointed the disorder "*lichen planus*" because the skin lesions appear to be quite similar to the symbiotic algae and fungi relationship (*lichen*) [42]. *Oral lichen planus* (OLP) is a chronic mucocutaneous disorder presenting a potentially premalignant behavior. However, less than 1% of OLP progress to malignancy state [58]. This injury is most common in middle-aged adults within preponderance for female gender (3:2 ratio) [42]. Mattila et al. [58] characterized the OLP in 6 variants: reticular, papular, plaque-type, atrophic, erosive and bullous. Clinically, Neville et al. [42] mentioned reticular and erosive forms as the most common variants presented in the oral mucosa. Although, not common as reticular and erosive, the bullous form was considered a rare oral disorder [59]. Three most common oral mucosa sites involved in OLP are: buccal mucosa, gingivae and lateral borders of the tongue. Additionally, its can be originated in any site of oral mucosa and frequently, is seen as bilateral lesions [59].

Microscopically, the OLP is presented like a non-specific lesion. Moreover, some oral disorders may also demonstrate a similar histopathologic pattern to the OLP-lesions. The injured epithelium may present orthokeratosis and parakeratosis. A spinous cells layer thickness can be observed in different degrees. The rete ridges may be presented as a classically "saw toothed" shape. Due to hydropic degeneration is evident a destruction of the epithelium basal cell layer and, subjacent to epithelium an intense T lymphocytes band-like infiltrate can be observed [42].

Some authors attempt to elucidate the correlation between HPV-infection and malignant transformation of OLP; however, results from pertinent literature are conflicting. The High-risk HPV-16 was described in 26.3% of OLP, with significant statistical difference between High-risk HPV-16 prevalence and OLP when compared to control samples [60]. A study performed by Sand et al. [61] demonstrated the High-Risk HPV-18 in approximately 27% of lichen planus cases but do not found statistical difference between HPV infection and oral lesions suggesting the unclear pathologic correlation between HPV and OLP. On the other hand, Campisi et al. [62] demonstrated the presence of HPV-DNA in 19.7% (n = 14/71) of patients with OLP, with significant statistical difference in comparison with controls cases (5/90; 5.6%) (P = 0.005). In the present study, the High-risk HPV-18 was the most frequent genotype found, it was present in 71.4% (10/14) of samples. In a second analysis, all of cases were pooled in 2 clinical groups: (1) atrophic-erosive (AE) (atrophic, erosive, bullous, and mixed AE variants); and (2) nonatrophic-erosive (non-AE) (reticular, plaque-like, popular, and

mixed non-AE variants) to evaluate the association between OLP variants and HPV-infection. However, this analysis failed to find particular correlation between OLP variants and HPV-infection. Analyzing 82 patients diagnosed with atrophic OLP, Mattila et al. [58] found that HPV-infection was present in 15,9% of lesions and was related with High-risk HPV-16. In addition, the HPV-positive cases presented a higher proliferation index and overexpression of Topoisomerase IIa (protein responsible for removal of DNA positive supercoils) in supra-basal layers in comparison with HPV-negative cases.

Ostwald et al. [63] studying prevalence and influence of Low-risk Hpv 6/11 and high-risk Hpv16/18 in benign oral lesions and OSCC detected the HPV-infection in 15.4% of OLP cases. Low-risk HPV presented the higher prevalence in OLP, whereas the High-Risk HPV presented the higher prevalence in OSCC. These interesting results demonstrated that High-risk HPV infection was successively increased from low-level premalignant lesion to OSCC, suggesting a correlation between High-Risk HPV and malignant potential [64]. The conflicting results of studies involving HPV-infection and malignant transformation of OLP lesions may occur due to differences in sample size of patients, associated comorbidities, and other external factors.

#### 5.4. Oral submucous fibrosis and HPV

The name “*Oral submucous fibrosis*” (OSF) was firstly presented by Joshi in 1953; however, Schwartz had described this condition in five cases originated from Kenya, a year before, as ‘*atropica idiopathica mucosae oris*’ [65]. OSF is frequently found in South Asian and South-East Asian patients (India, Bangladesh, Sri Lanka, Pakistan, Taiwan, Southern China) aged of 20–40 years [63]. This potentially malignant disorder has been close related to chronic consumption of Betel quid and Paan [42].

Microscopically, OSF can be characterized by the submucosal deposition of connective tissue. This deposition is extremely dense and presents a reduced vascular tissue. In early-stage lesion, sub-epithelial vesicles can be observed. On the other hand, the older-stage lesion presents epithelial atrophy with hyperkeratosis. In conjunction with these epithelial changes, 10% to 15% of biopsied tissues present epithelial dysplasia [42].

Although, OSF presents a multifactorial etiology, Betel quid and Paan consumption are considered the major causative agents. In pertinent literature only four studies evaluating the HPV and OSF were found: two studies evaluating an Indian population; one study analyzing differences between HPV-infection prevalence in OCSS and pre-malignant lesion; one study comparing two different HPV detection methods). Study performed by Luo et al. [49] presented only two cases of OSF infected by HPV-virion. Although, the lesions had been positive for HPV-infection was not possible to perform other conclusions, because this study used a small number of cases. Chaudhary et al. [66], comparing two HPV-detection methods identified around of 27% (total of 208 cases) of OSF patients’ positive for HPV-infection. These two reports do not allow us to establish any positive correlation between HPV-infection and malignant transformation. In addition, evaluation of a hundred thirteen cases of OSF, designed by Mehrotra et al. [67], to assess the relationship of human papilloma virus infection and OSF showed no significant correlation between these two entities. Although, the hpv-infection do not show association with OSF an Indian population study, investigating the prevalence of

HPV-16 in OSF and OSCC cases, found a 91% prevalence of HPV-DNA in OSF and speculated that epithelium lesions in OSF could be an important factor to integration of HPV in basal cells genome (Jalouli et al. [68]. In conclusion, these studies do not have strength to sustain the idea that HPV has an important role in the malignant transformation of OSF.

### 5.5. Smokeless tobacco keratosis and HPV

Several oral manifestations have been associated to use of *Smokeless Tobacco*. Oral manifestations occur at the site of Smokeless Tobacco placement including mucosal lesions (Smokeless Tobacco Keratosis “STK”) and gingival-periodontal disorders such as gingival recession, gingival inflammation, changes in gingival blood flow and interproximal periodontal attachment loss [69]. The use of *Smokeless Tobacco* and the STK has been suggested to be involved in development of oral cancers [70].

Clinically, the site of Smokeless Tobacco placement presents a leukoplakic lesion referred as “snuff dippers” lesions [71] STK presents a non-specific histopathologic appearance [42]. Squamous epithelium is hyper keratinized [42,70] and acanthotic; in addition, the intra-cellular edema is not uncommon on superficial cells glycogen-rich. In some cases, subjacent connective tissue can present an amorphous eosinophilic material. An increased sub-epithelial vascularity and vessel engorgement also can be seen. [42]. In STK the epithelial dysplasia does not common. In a study conducted by Leopardi et al. [72] they not evidenced cases of epithelial dysplasia. However, when present, epithelial dysplasia is usually mild [42]. Studies on STK pointed to three clinical grades [73].

Studies on smokeless tobacco keratosis pointed to three clinical grades: 1) Grade I superficial lesions presenting modest wrinkling and no mucosal thickening. Grade I lesions tends to present similar color to the surrounding mucosa. 2) Grade II superficial whitish lesions with undulating areas displaying moderate wrinkling and no mucosal thickening. 3) Grade III white entities with normal mucosal color areas, STK Grade III shows mucosal thickening and wrinkling [71]. However, this lesion is reversible when the product is discontinued [42]. Related to HPV a work aimed to detect p16 (INK4a) protein expression in smokeless tobacco keratosis as reliable precancerous marker. The author detected HPV-DNA in 15 of 62 (24%) cases and an apparent relation between the three standard grades of STK lesions and HPV-infection was observed. [71]

## 6. Malignant oral lesions and HPV

In the oral cavity, 24 types of HPV (1, 2, 3, 4, 6, 7, 10, 11, 13, 16, 18, 30, 31, 32, 33, 35, 45, 52, 55, 57, 59, 69, 72 and 73) have been associated with benign lesions and 12 types (2, 3, 6, 11, 13, 16, 18, 31, 33, 35, 52 and 57) with malignant lesions [47-48]. Since the first report of the presence of HPV DNA in head and neck cancer, 65 high-risk types have been consistently detected at different sites; however, these types are specifically found in transcriptionally active tumor cells [74]. According to data from a review, 99% of HPV-infections in head and neck cancers are by high-risk types 16, 18, 31 and 33 [75]. Infection with HPV 33 accounts for up to 10% of



positive head and neck cancers; however, the HPV 16 type is by far the most common subtype detected in head and neck cancer ([75-77], and also, oropharyngeal cancer (OPC) is more likely to have HPV 16 than other types at head and neck sites. Just to demonstrate the high levels of HPV-16 genotype in OPC, this genotype accounts for 78% to 100% of positive cases, while HPV-18 accounts for only 1% of cases [75]. An interesting prevalence profile of the HPV types has been observed in some investigations in the countryside of Sao Paulo state in Brazil, where a higher prevalence of HPV 18 than HPV 16 was found in oral and cervical carcinomas. Furthermore, the presence of HPV 18 was found to be associated with metastasis to the lymph nodes and shorter patient survival [78-80].

Several HNSCC have been analyzed for the presence of HPV, and HPV-DNA has been found in different proportions of tumors from different head and neck sites [75,81]. Some evidence has indicated that some subtypes of HPV are specifically linked to head and neck cancer, especially those arising from specific oropharyngeal subsites (e.g., tonsil and the base of the tongue) [82]. The HPV prevalence in HNSCC ranges from 3% to 40% and could vary more according to the specific site and HPV has been found in 4-80% of oral squamous cell carcinoma. Brazilian observations in the countryside of São Paulo state have found a low prevalence of HPV in tumors of the larynx [83] and an increase in the presence of HPV-DNA in oral cavity cancers during the past two decades [79-80,84]. The wide variation in HPV prevalence can be attributed to different detection techniques, small sample numbers, differences in the lesions and sampling techniques and epidemiological characteristics of the populations studied [85]. Among the many methods to detect HPV infections, both polymerase chain reaction (PCR) and in situ hybridization assays have been well validated, although not perfect.

In terms of incidence, it is now believed that HPV-infection could be responsible for approximately 20% of oral cancers and 60-80% of OPC. Recently, in 2011, International Agency of Research of Cancer (IARC) declared that there is sufficient evidence that HPV-16 is causally associated with oral cancer cases [86]. More important, these HPV-related oral cancers are now considered to be completely different entities, differing remarkably from HPV-negative tumors in their clinical response and overall survival [76,87].

Currently, the identification of distinct epidemiological profiles in HPV-positive and HPV-negative HNSCCs is possible. The main factors studied are heavy or no tobacco/marijuana exposure, heavy or mild alcohol consumption, poor or intact dentition, low or high oral sex exposure, age > 50 years or < 45 years, lower or higher socioeconomic status and decreasing or increasing incidence [82]. The epidemiological trend suggests that HPV-positive HNSCC occurs more often in younger patients (age < 50 years), which differs from the typical characteristics of head and neck cancer (which is more frequent in men above 40 years old). Tumors that show association with the presence of HPV usually appears strawberry-like and exophytic lesions on gross inspection and occur more frequently in the tonsil and the base of tongue with a basaloid aspect, poor differentiation and cystic changes within metastatic lymph nodes [82]. In addition, gene expression profiles are known to be different in HPV- positive OPCs compared with HPV-negative cases [88].

Molecular evidences have shown that HPV-associated oral tumors differ significantly from the classic “tobacco and alcohol”-associated oral tumors. First, HPV-positive HNSCCs harbor



wild type p53, while classical HNSCC have usually a mutated form of the protein, in accordance with the expected better development of HPV-associated lesions. Indeed, among HPV-positive tumors, the worst outcome is related to smoking, showing evidence that tobacco-derived carcinogens could potentiate the transformation effect of HPV [89-90]. But p53 status in HPV-related tumors, especially those presenting HPV-16 infection led to a confusion involving HPV detection methods and even HPV-related carcinogenesis itself. Initially, it was expected that HPV-16 positive tumors to have a predominantly mutated p53 status, given that HPV-16 E6 inactivates p53, and therefore, mutations in TP53 would be, and indeed are rarely present in cervical carcinomas. But in HNSCC, TP53 is mutated in 60-80% of all cases, and it was expected that HPV-infected tumors would be among the 20-40% of wild-type TP53, although this is not what was found in HNSCC. These findings highlighted the importance of the detection method of HPV infections. For example, the HPV DNA PCR assay is too sensitive, since it detects only a few copies of viral DNA, and may detect more than oncogenic infections, but also productive infections, laboratory artefacts and virions [91]. The following additional techniques can also provide data regarding the presence of HPV: light and electron microscopy, ELISA, gene expression by DNA microarray, Dot blot, Southern blot, hybrid capture and ligase chain reaction for probe amplification. Due to the existence of numerous options for HPV detection in HNSCC, a standardization of procedures for routine application has yet to be developed [77,85]. Among other important pathways in HPV-induced HNSCC are: (1) p53 and pRb pathways, involved in cell cycling; (2) EGFR pathway, which are an important therapeutic target in other cancers (as breast and lung cancers); (3) TGF $\beta$  pathway; (4) PI3K-PTEN-AKT pathway and (5) angiogenesis and hypoxia pathways [91].

Aimed to investigate the HPV frequency in Brazilian patients diagnosed with OSCC we performed a study to establish the HPV clinicopathological profile and its possible influence on prognosis of disease [84]. HPV expression in primary tumors (PTs), and their matched samples (MSs) of recidives, lymph nodal metastasis (LNM) or necropsies were correlated with survival of patients. Through polymerase chain reaction using one general and two type-specific HPV primers, 87 PTs and their corresponding MSs were tested. As first step, HPV-DNA detection was performed, using a GP5+/GP6+ primer (Bioneer Inc.) to amplify a 150-bp fragment from L1 gene of general HPV types (GP5+, 5'-TTTGTT ACTGTGGT AGA T ACT AC-3'; GP6+, 5'-GAAAAATAAACTGTAAATCATATTC-3'). At second step, PCR reaction was performed on HPV-positive DNA samples to determine if contained the genotypes -16 and -18, using specific primers targeting ~100 bp in the E7 ORF: HPV-16E7.667 (5'-GAT-GAAATAGATGGTCCAGC-3'), HPV-16E7.774 (5'-GCTTTGTACGCACAACCGAAGC-3'), HPV-18E7.696 (5'-AAGAAAACGATGAAATAGATGGA-3') and HPV-18E7.799 (5'-GGCTTCACACTTACAACACA-3') (Bioneer Inc.). All of 87 OSCC patients analyzed, 17 (19.5%) presented tumors HPV-DNA positive. Analyses of all paraffin-embedded samples (87 primary tumors plus 87 matched samples) revealed the presence of HPV-DNA in 18 of 174 samples (10.4%), 10 samples (11.5%) from PTs, and 8 samples (9.2%) from MSs. In addition, no virus infection was detected in 7 (8.1%) MSs samples, and only one patient has demonstrated HPV-DNA positivity in both samples. HPV genotypes -16 and -18 were detected in 4 (22.2%) and 3 (16.7%) of the positive samples, respectively. Infection with both genotypes was found in 6 (33.3%) investigated samples, and HPV genotype was not identified in 5 (27.8%)

samples. The most prevalent infected anatomical site was the tongue. The main result of the present study was the significant number of positive HPV samples among non-smoking patients and although, a possible influence of HPV infection on carcinogenesis cannot be ruled out, the low frequency of HPV-positive OSCC cases found in our analysis leads us to suggest that this virus has not the same etiological influence on patients, as tobacco consumption does. Although we cannot to exclude a possible transient role for HPV in the OSCC induction, we believe that occasional detection of HPV-infection in OSCC resulting from the incidental colonization of tumoral lesions might reflect the true correlation of HPV in most analysis. [84].

## 7. HPV — Prognosis and treatment

In last decades no significant improvement of overall survival has been observed in patients with HNSCCs. It is believed that loco-regional recurrences, distant metastases and a second primary tumor are factors for this phenomenon [91]. Several studies have now established that head and neck HPV-positive tumors have better prognoses [76,88] and treatment-response rates when compared with HPV-negative tumors [88]. In a study comparing tumors in the same stage Leemans et al., [91] observed favorable prognoses after treatment of HPV-infected HNSCCs as compared to HPV-negative tumors. Univariate analyses for 5-year survival rate have pointed that HPV-positive patients surviving longer than HPV-negative patients ( $p < 0.05$ ); the 5-year survival rate was 54% for HPV-positive versus 33% for HPV-negative tumors [92]. In addition, a study performed by Fakhry et al. [76] evaluating the correlation between HPV infection and survival rate suggested that HPV-positive HNSCC have a significantly better survival (5-year survival of approximately 70%) when compared with HPV-negative patients (5-year survival of approximately 35%). Dayyani et al. [87] published a Meta-analysis, analyzing the impact of human papillomavirus (HPV) on head and neck squamous cell carcinomas, described that patients HPV-positive presented increased risk for HNSCC (adjusted OR = 1.83; 95% CI = 1.04-2.62;  $p < 0.0001$ ). However, survival rate was improved in HPV-positive patients when compared to HPV-negative patients (HR = 0.42; 95% CI = 0.27-0.56,  $p < 0.0001$ ). In other example, evaluation of prognosis and response rates to chemotherapy of oropharyngeal or laryngeal carcinomas showed that HPV-positive tumors present a significantly better overall 2-year survival rate than HPV-negative patients (2-year survival rate of HPV-positive tumors 95% (95% CI = 87%-100%), and 2-year survival rate of HPV-negative tumors 62% (95% CI = 49%- 74%)). The same study found that HPV-positive oropharyngeal carcinomas present higher response rates to chemotherapy compared with HPV-negative (82% vs 55%, difference = 27%, 95% CI = 9.3% to 44.7%,  $P = .01$ ). Additionally, Dayyani et al. [87] described that HPV-positive head and neck squamous cell carcinomas presented an improved response to radiotherapy (non-adjusted OR = 4.07; 95% CI = 1.48-11.18,  $p = 0.006$ ) and had a better response to chemo-radiation (non- adjusted OR = 2.87; 95% CI = 1.29-6.41,  $p = 0.01$ ) as compared to HPV-negative head and neck squamous cell carcinomas.

A meta-analysis performed by Ragin & Taioli [93] aimed to analyze the impact of tumor HPV status on survival outcomes showed that patients diagnosed with head and neck squamous cells carcinoma HPV-positive had a lower risk of dying in comparison with HPV-negative

tumors (combined HR: 0.85, 95% CI: 0.7–1.0). At the same study, HPV-positive patients had lower risk of disease-failure (recurrence of tumor) as compared to HPV-negative patients (meta HR, 0.62; 95%CI, 0.5–0.8). The evidence for association of OSCC with HPV-infection and its possible role as an oncogenic agent remains controversial. Schwartz et al. (2001) evaluating the HPV-16 influence on survival rate in OSCC demonstrated that patient's HPV-16 positive presented significantly reduced disease-specific mortality in OSCC (HR = 0.17, 95% CI = 0.04, 0.76) when compared with HPV-16 negative patients. This result suggests the HPV-16 infection could be associated with a favorable prognosis in OSCC. However, the mechanism responsible for this improved prognosis conferred by HPV is still unclear [94].

Several hypotheses have been proposed to explain the improved prognosis in tumors HPV-positive. The benefit on survival rate has been attributed to an enhanced radiosensitivity of tumors HPV-positive [95-96], and an improvement of apoptotic secondary response to the presence of unmutated p53 in HPV-associated tumors [95,97]. The improvement of disease-specific survival rate could be associated with a reduction risk of second primary tumor, since these HPV-positive patients tend to have no prior history of tobacco and/or high alcohol consumption [95]. This finding reduces the field cancerization process (upper respiratory epithelium repeatedly exposed to carcinogens) [98].

## 8. HPV vaccines (Therapeutic and prophylactic)

Several epithelial lesions are originated by infection with human papillomaviruses (HPVs), mainly benign hyperplasia with low malignant potential like warts or papillomas. However, there is a subgroup of HPVs that are associated with precancerous lesions, which could become a cancer in a small fraction of people [99]. As example of those high-risk HPV subtypes, HPV 16 and 18 [100] are responsible for approximately 70% of cervical cancer cases and are present in more than 60% of HPV-infected penile cancer and HPV-16 is the genotype most frequently detected in head and neck carcinomas, found in up to 90% of HPV-positive cases [99]. Other high-risk HPV types account for virtually all of the remaining cases of cervical cancer, although in other primary sites they do not appear to have a similarly important role [101]. Therefore, cancer of the uterine cervix is most widely accepted malignancy as being associated with HPV infection. HPV high-risk subtypes are also associated with some others anogenital carcinomas, including penile, anal and vulvar cancers [102-103] and a subset of head-and-neck squamous cell carcinomas [104].

Taken together, these findings supports in several countries, vaccination against some HPV types on girls and young women with the goal of protecting them against HPV-induced cervical cancer [105-106]. Trials with vaccines against cervical cancer shown that cross-protection is possible, because this vaccines also have the potential to prevent other cancers that are caused by the same types of HPV, including some of head and neck cancers [107], and the most of anogenital cancers outside the cervix, including cancer of the vulva, vagina, penis, and anus [108-109]. In theory, these vaccines should target the same viruses at other anatomical sites, as head and neck. This approach could provide important information about the final proof of HPV etiology in these tumors [110].

Prophylactic vaccines work primarily by inactivating HPV before the virus infects the host cells, stimulating humoral immunity [111]. Nowadays, there are two types of prophylactic HPV vaccine available in United States: the quadrivalent vaccine (Gardasil®) and bivalent vaccine (Cervarix®). The quadrivalent vaccine was first licensed for use in females to prevent cervical, vaginal and vulvar cancers and are effective against infection with HPV types 6, 11, 16 and 18 [112]. In 2009 the licensure was expanded to include males demonstrating effectiveness to prevent genital warts in both genders [113]. Bivalent vaccine was licensed for use in the U.S. in 2009 providing cervical cancers protection against HPV types 16 and 18 [114]. The impact of HPV prophylactic vaccination will address not only the incidence of cervical and anogenital cancers in women and men but also the incidence of some head and neck tumors. Growing number of head and neck cancers HPV-positive highlights the importance of routine prophylactic vaccination against HPV and, associated with alcohol and tobacco control, may be crucial in head and neck cancer prevention [115].

Also, therapeutic vaccines against HPV have to request cell mediated immunity and can also help prevent the progression of low-grade disease and lead existing lesions to regress, avoiding the recurrence of cancer lesions after treatment [116,117]. However, recent studies demonstrated the reduced effectiveness of therapeutic HPV-vaccine in established tumors. This could be explained by the fact that they have especially been tested in patients with compromised immune systems due advanced stage cancer [118]. A vaccine that possesses both prophylactic and therapeutic properties could be most effective HPV-vaccine strategy, preventing new and clear established HPV-infections. Additionally, the vaccine could be administered in, sexually inexperienced young individuals or older individuals HPV-infected, benefiting them [119].

## 9. Final considerations

In recent decades, controversial results were not being able to provide the real role of HPV infection in OSCC genesis. An interesting fact that supports the controversial role of HPV-infection in OSCC is the highly fluctuating HPV-prevalence in comparison with cervical cancer. It may be due to HPV-detection influenced by: a reduced number of viral-copies, a viral-infection in a particular cell population, biopsy samples and detection methods (numerous methods and protocols for detection). Several details elucidating the relationship between pre-cancerous lesions, OSCC with HPV-infection must to be understood. The genomic detection of HPV-DNA, primarily in Pre-Cancerous lesions, provides stronger support for a viral etiology of HNSCC and OSCC. However the correlation between malignant transformation of Pre-Cancerous lesions and HPV-infection were not completely elucidated. Recently, numerous studies have suggested that HPV-infection could play an important role in oral carcinogenesis through the Oral leukoplakia malignant transformation. Although some synergies between HPV oncogenes and other carcinogens have been hypothesized, some researchers have showed, specifically in oral mucosa, that positive HPV-infection in OSCC might not result from viral infection but rather from an incidental HPV colonization. In addition, targeted therapy for HNSCCs and OSCC currently request an increased number of predictive biomarkers, such as the HPV-infection status and mutation-status of crucial genes,



to personalize the treatment for individual patients. However, for a better understanding about real therapeutic implications of HPV-status of tumors on OSCC clinical outcome, the next generation of clinical trials could be significantly improved and standardized in their design. According to exposed in the present issue, and defended by our research group and other authors [36-37], we believe that diagnosis strategy based in early detection in oral Pre-Cancerous lesions and OSCC reduces the treatment at the advanced stage, thereby increasing the cancer cure chances. Our group also believes that the increasing effects of HPV vaccination in several cancers could help to reduce the number of new HNSCC and OSCC cases. Although knowledge of the accurate effects of HPV vaccination on cancer incidence will probably continue for several years, monitoring the current effects of HPV vaccination is crucial, not only in cervical cancer, but also in HNSCC and OSCC.

## Author details

Danilo Figueiredo Soave<sup>1\*</sup>, Mara Rubia Nunes Celes<sup>2</sup>, João Paulo Oliveira-Costa<sup>3</sup>,  
Giorgia Gobbi da Silveira<sup>3</sup>, Bruna Riedo Zanetti<sup>3</sup>, Lucinei Roberto Oliveira<sup>4</sup> and  
Alfredo Ribeiro-Silva<sup>3</sup>

\*Address all correspondence to: [dsoave@usp.br](mailto:dsoave@usp.br)

- 1 Department of Pathology – Ribeirão Preto Medical School – University of Sao Paulo, Brazil
- 2 Institute of Tropical Pathology and Public Health, Federal University of Goiás, Brazil
- 3 Department of Pathology – Ribeirão Preto Medical School – University of Sao Paulo, Brazil
- 4 Department of Pathology – Vale do Rio Verde University, Brazil

## References

- [1] Miller CS, Johnstone BM. Human papillomavirus as a risk factor for oral squamous cell carcinomas: a meta-analysis 1982–1997. *Oral Surg Oral Med Oral Pathol Oral Radiol Endod* 2001 91:622–635
- [2] Onon TS. History of human papillomavirus, warts and cancer: what do we know today? *Best Pract Res Clin Obstet Gynaecol*. 2011 Oct;25(5):565-74. Epub 2011 Jun 25.
- [3] McCaffery M. Autopsy of a mummy - warts and all. . *Can Fam Physician*. 1974 Sep; 20(9):89-91.
- [4] zur Hausen H. Papillomaviruses in the causation of human cancers - a brief historical account. *Virology*. 2009 Feb 20;384(2):260-5. Epub 2009 Jan 8.



- [5] zur Hausen H, Gissmann L, Steiner W, Dippold W, Dreger I. Human papilloma viruses and cancer. *Bibl Haematol.* 1975 Oct;(43):569-71.
- [6] Kumaraswamy, K. L. & Vidhya, M. (2011). Human papilloma virus and oral infections: An update. *Journal of Cancer Research and Therapeutics*, 7, 2, pp. 120-127, DOI: 10.4103/0973-1482.82915.
- [7] Chang F, Syrjänen S, Kellokoski J, Syrjänen K. Human papillomavirus (HPV) infections and their associations with oral disease. *J Oral Pathol Med.* 1991 Aug;20(7):305-17.
- [8] Syrjänen KJ, Syrjänen SM, Lamberg MA, Pyrhönen S. Human papillomavirus (HPV) involvement in squamous cell lesions of the oral cavity. *Proc Finn Dent Soc.* 1983;79(1):1-8.
- [9] Syrjänen KJ, Syrjänen SM, Lamberg MA, Happonen RP. Local immunological reactivity in oral squamous cell lesions of possible HPV (human papillomavirus) origin. *Arch Geschwulstforsch.* 1983;53(6):537-46.
- [10] Syrjänen KJ, Pyrhönen S, Syrjänen SM, Lamberg MA. Immunohistochemical demonstration of human papilloma virus (HPV) antigens in oral squamous cell lesions. *Br J Oral Surg.* 1983 Jun;21(2):147-53.
- [11] Syrjänen K, Syrjänen S, Lamberg M, Pyrhönen S, Nuutinen J. Morphological and immunohistochemical evidence suggesting human papillomavirus (HPV) involvement in oral squamous cell carcinogenesis. *Int J Oral Surg.* 1983 Dec;12(6):418-24.
- [12] Cox MF, Scully C, Maitland N. Viruses in the aetiology of oral carcinoma? Examination of the evidence. *Br J Oral Maxillofac Surg.* 1991 Dec;29(6):381-7.
- [13] Lizano, M., Berumen, J., García-Carrancá, A. HPV-related carcinogenesis: basic concepts, viral types and variants. *Archives of medical research, Arch Med Res.* 2009 Aug;40(6):428-34.
- [14] Chow, L. T., Broker, T. R., Steinberg, B. M. The natural history of human papilloma virus infections of the mucosal epithelia. *APMIS: acta pathologica, microbiologica, et immunologica Scandinavica*, 2010 Jun;118(6-7):422-49.
- [15] de Villiers, E.-M., Fauquet, C., Broker, T. R., Bernard, H.-U., Zur Hausen, H. Classification of papillomaviruses. *Virology* 2004 Jun 20;324(1):17-27.
- [16] Buck, C. B., Cheng, N., Thompson, C. D., Lowy, D. R., Steven, A. C., Schiller, J. T., Trus, B. L. Arrangement of L2 within the papillomavirus capsid. *Journal of virology*, 2008 Jun;82(11):5190-7. Epub 2008 Mar 26.
- [17] Zur Hausen, H. Papillomaviruses and cancer: from basic studies to clinical application. *Nat Rev Cancer*, 2002 May;2(5):342-50.
- [18] Rautava, J., Syrjänen, S. Biology of human papillomavirus infections in head and neck carcinogenesis. *Head Neck Pathol.* 2012 Jul;6 Suppl 1:3-15. Epub 2012 Jul 3..

- [19] Stanley, M. Pathology and epidemiology of HPV infection in females. *Gynecol Oncol.* 2010 May;117(2 Suppl):S5-10.
- [20] Cardoso, J. C., Calonje, E. Cutaneous manifestations of human papillomaviruses: A review. *Acta Dermatovenerol Alp Panonica Adriat.* 2011 Sep;20(3):145-54.
- [21] Lazarczyk, M., Cassonnet, P., Pons, C., Jacob, Y., & Favre, M. The EVER proteins as a natural barrier against papillomaviruses: a new insight into the pathogenesis of human papillomavirus infections. *Microbiol Mol Biol Rev.* 2009 Jun;73(2):348-70.
- [22] Stoler, M. H. Human papillomaviruses and cervical neoplasia: a model for carcinogenesis. *International journal of gynecological pathology: official journal of the International Society of Int J Gynecol Pathol.* 2000 Jan;19(1):16-28.
- [23] Kreimer, A. R., Clifford, G. M., Boyle, P., & Franceschi, S. Human papillomavirus types in head and neck squamous cell carcinomas worldwide: a systematic review. *Cancer epidemiology, biomarkers & prevention: a publication of the American Association for Cancer Research, cosponsored by the American Society of Preventive Oncology*, 2005 Feb;14(2):467-75.
- [24] Miralles-Guri, C., Bruni, L., Cubilla, A L., Castellsagué, X., Bosch, F. X., de Sanjosé, S. Human papillomavirus prevalence and type distribution in penile carcinoma. *J Clin Pathol.* 2009 Oct;62(10):870-8. Epub 2009 Aug 25.
- [25] Doorbar, J. The papillomavirus life cycle. *Journal of clinical virology: the official publication of the Pan American Society for Clinical Virology*, 2005 Mar;32 Suppl 1:S7-15.
- [26] Vidal, L., & Gillison, M. L. Human papillomavirus in HNSCC: recognition of a distinct disease type. *Hematology/oncology clinics of North America*, 2008 Dec;22(6): 1125-42, vii
- [27] Moody CA, Laimins LA. Human papillomavirus oncoproteins: pathways to transformation. *Nat Rev Cancer.* 2010 Aug;10(8):550-60. Epub 2010 Jul 1.
- [28] Bodily, J., Laimins, L. A. Persistence of human papillomavirus infection: keys to malignant progression. *Trends in microbiology*, 2011 Jan;19(1):33-9. Epub 2010 Nov 1.
- [29] Lacour, D. E., Trimble, C. Human papillomavirus in infants: transmission, prevalence, and persistence. *Journal of pediatric and adolescent gynecology*, 2012 Apr; 25(2):93-7. Epub 2011 May 20.
- [30] Ragin, C.; Edwards, R.; Larkins-Pettigrew, M.; Taioli, E.; Eckstein, S.; Thurman, N.; Bloome, J. & Markovic, N. (2011). Oral HPV Infection and Sexuality: A Cross-Sectional Study in Women. *International Journal of Molecular Science*, 12, 6, pp. 3928-3940.
- [31] Heck, J.E.; Berthiller, J.; Vaccarella, S.; Winn, D.M.; Smith, E.M.; Shan'gina, O.; Schwartz, S.M. et al. Sexual behaviours and the risk of head and neck cancers: a pooled analysis in the International Head and Neck Cancer Epidemiology (IN-

- HANCE) consortium. *International Journal of Epidemiology* 2010. 39, 1, pp. 166–181, DOI:10.1093/ije/dyp350.
- [32] Gillison, M.L.; D'Souza, G.; Westra, W.; Sugar, E.; Xiao, W.; Begum, S. & Viscidi, R. Distinct risk factor profiles for human papillomavirus type 16-positive and human papillomavirus type 16-negative head and neck cancers. *Journal of the National Cancer Institute* 2008.100, 6, pp. 407–420, DOI: 10.1093/jnci/djn025.
  - [33] D'Souza, G.; Kreimer, A.R.; Viscidi, R.; Pawlita, M.; Fakhry, C.; Koch, W.M. et al. (2007). Case-control study of human papillomavirus and oropharyngeal cancer. *The New England journal of medicine*, 356, 19, pp. 1944–1956.
  - [34] Hemminki K, Dong C, Frisch M. Tonsillar and other upper aerodigestive tract cancers among cervical cancer patients and their husbands. *Eur J Cancer Prev* 2000; 9:433–7.
  - [35] D'Souza G, Agrawal Y, Halpern J, Bodison S, Gillison ML. Oral sexual behaviors associated with prevalent oral human papillomavirus infection. *J Infect Dis* 2009;199:1263–9.
  - [36] Mishra R. Biomarkers of oral premalignant epithelial lesions for clinical application. *Oral Oncol.* 2012 Jul;48(7):578–84. Epub 2012 Feb 18.
  - [37] Neville BW, Day TA. Oral cancer and precancerous lesions. *CA Cancer J Clin* 2002;52(4):195–215.
  - [38] William WN Jr. Oral premalignant lesions: any progress with systemic therapies? *Curr Opin Oncol.* 2012 May;24(3):205–10.
  - [39] Kramer IRH, Lucas RB, Pindborg JJ, Sobin LH. Definition of leukoplakia and related lesions: an aid to studies on oral pre- cancer. *Oral Surg Oral Med Oral Pathol* 1978 Oct;46(4): 518–39.
  - [40] Baric JM, Alman JE, Feldman RS et al. Influence of cigarette, pipe, and cigar smoking, removable partial dentures, and age on oral leukoplakia. *Oral Surg Oral Med Oral Pathol* 1982 Oct;54(4):424–9.
  - [41] Napier SS, Speight PM. Natural history of potentially malignant oral lesions and conditions: an overview of the literature. *J Oral Pathol Med* 2008 Jan;37(1):1–10.
  - [42] Neville BW., Damm DD., Allen CM., Bouquot JE. *Oral & Maxillofacial Pathology*. Philadelphia-W.B. Saunders Company; 2009.
  - [43] Cowan CG, Gregg TA, Napier SS et al. Potentially malignant oral lesions in northern Ireland: a 20-year population- based perspective of malignant transformation. *Oral Dis* 2001 Jan;7(1):18–24.
  - [44] Pindborg JJ., Reichart PA., Smith CJ. *Histological typing of cancer and precancer of the oral mucosa*. Berlin-Springer; 1997

- [45] Liu W, Shi LJ, Wu L, Feng JQ, Yang X, Li J, Zhou ZT, Zhang CP. Oral Cancer Development in Patients with Leukoplakia – Clinicopathological Factors Affecting Outcome PLoS One. 2012;7(4):e34773. Epub 2012 Apr 13.
- [46] Lim K, Moles DR, Downer MC, Speight PM. Opportunistic screening for oral cancer and precancer in general dental practice: results of a demonstration study. Br Dent J 2003; 194: 497–502.
- [47] Bouda, M.; Gorgoulis, V.G.; Kastrinakis, N.G.; Giannoudis, A.; Tsoli, E.; Danassi-Afentaki, D. et al. "High risk" HPV types are frequently detected in potentially malignant and malignant oral lesions, but not in normal oral mucosa. Modern Pathology, 2000 Jun;13(6):644-53.
- [48] Kojima, A.; Maeda, H.; Sugita, Y.; Tanaka, S. & Kameyama, Y. (2002). Human papillomavirus type 38 infection in oral squamous cell carcinomas. Oral Oncology, 2002 Sep;38(6):591-6.
- [49] Luo CW, Roan CH, Liu CJ. Human papillomaviruses in oral squamous cell carcinoma and pre-cancerous lesions detected by PCR-based gene-chip array. Int J Oral Maxillofac Surg. 2007 Feb;36(2):153-8. Epub 2006 Nov 15.
- [50] Sugiyama M, Bhawal UK, Dohmen T, Ono S, Miyauchi M, Ishikawa T. Detection of human papillomavirus-16 and HPV-18 DNA in normal, dysplastic, and malignant oral epithelium. Oral Surg Oral Med Oral Pathol Oral Radiol Endod. 2003 May;95(5):594-600.
- [51] Llamas-Martínez S, Esparza-Gómez G, Campo-Trapero J, Cancela-Rodríguez P, Bascones-Martínez A, Moreno-López LA, García-Núñez JA, Cerero-Lapiedra R. Genotypic determination by PCR-RFLP of human papillomavirus in normal oral mucosa, oral leukoplakia and oral squamous cell carcinoma samples in Madrid (Spain). Anti-cancer Res. 2008 Nov-Dec;28(6A):3733-41.
- [52] Campisi G, Di Fede O, Giovannelli L, Capra G, Greco I, Calvino F, Maria Florena A, Lo Muzio L. Use of fuzzy neural networks in modeling relationships of HPV infection with apoptotic and proliferation markers in potentially malignant oral lesions. Oral Oncol. 2005 Nov;41(10):994-1004. Epub 2005 Aug 29.
- [53] Lo Muzio L, Campisi G, Giovannelli L, Ammatuna P, Greco I, Staibano S, Pannone G, De Rosa G, Di Liberto C, D'Angelo M. HPV DNA and survivin expression in epithelial oral carcinogenesis: a relationship? Oral Oncol. 2004 Aug;40(7):736-41.
- [54] Campisi G, Panzarella V, Giuliani M, Lajolo C, Di Fede O, Falaschini S, Di Liberto C, Scully C, Lo Muzio L. Human papillomavirus: its identity and controversial role in oral oncogenesis, premalignant and malignant lesions (review). Int J Oncol. 2007 Apr;30(4):813-23.

- [55] Villa A, Villa C, Abati S. Oral cancer and oral erythroplakia: an update and implication for clinicians. *Aust Dent J*. 2011 Sep;56(3):253-6. doi: 10.1111/j.1834-7819.2011.01337.x. Epub 2011 Jul 10.
- [56] Reichart PA, Philipsen HP. Oral erythroplakia—a review. *Oral Oncol*. 2005 Jul;41(6):551-61. Epub 2005 Apr 9.
- [57] Nielsen H, Norrild B, Vedtofte P, Praetorius F, Reibel J, Holmstrup P. Human papillomavirus in oral premalignant lesions. *Eur J Cancer B Oral Oncol*. 1996 Jul;32B(4):264-70.
- [58] Mattila R, Rautava J, Syrjänen S. Human papillomavirus in oral atrophic lichen planus lesions. *Oral Oncol*. 2012 Jun 1. [Epub ahead of print]
- [59] Epstein JB, Wan LS, Gorsky M, Zhang L. Oral lichen planus: Progress in understanding its malignant potential and the implications for clinical management. *Oral Surg Oral Med Oral Pathol Oral Radiol Endod*. 2003 Jul;96(1):32-7.
- [60] O'Flatharta C, Flint SR, Toner M, Butler D, Mabruk MJ. Investigation into a possible association between oral lichen planus, the human herpesviruses and the human papillomaviruses. *Mol Diagn* 2003;7:73-83.
- [61] Sand L, Jaiouli J, Larsson PA, Hirsch JM. Human papilloma viruses in oral lesions. *Anticancer Res*. 2000 Mar-Apr;20(2B):1183-8.
- [62] Campisi G, Giovannelli L, Aricò P, Lama A, Di Liberto C, Ammatuna P, D'Angelo M. HPV DNA in clinically different variants of oral leukoplakia and lichen planus. *Oral Surg Oral Med Oral Pathol Oral Radiol Endod*. 2004 Dec;98(6):705-11.
- [63] Ostwald C, Rutsatz K, Schweder J, Schmidt W, Gundlach K, Barten M. Human papillomavirus 6/11, 16 and 18 in oral carcinomas and benign oral lesions. *Med Microbiol Immunol*. 2003 Aug;192(3):145-8. Epub 2002 Nov 1.
- [64] Szarka K, Tar I, Fehér E, Gáll T, Kis A, Tóth ED, Boda R, Márton I, Gergely L. Progressive increase of human papillomavirus carriage rates in potentially malignant and malignant oral disorders with increasing malignant potential. *Oral Microbiol Immunol*. 2009 Aug;24(4):314-8.
- [65] More CB, Das S, Patel H, Adalja C, Kamatchi V, Venkatesh R. Proposed clinical classification for oral submucous fibrosis. *Oral Oncol*. 2012 Mar;48(3):200-2. Epub 2011 Nov 8. Review
- [66] Chaudhary AK, Pandya S, Mehrotra R, Bharti AC, Singh M, Singh M. Comparative study between the Hybrid Capture II test and PCR based assay for the detection of human papillomavirus DNA in oral submucous fibrosis and oral squamous cell carcinoma. *Virol J*. 2010 Sep 23;7:253.



- [67] Mehrotra R, Chaudhary AK, Pandya S, Debnath S, Singh M, Singh M. Correlation of addictive factors, human papilloma virus infection and histopathology of oral sub-mucous fibrosis. *J Oral Pathol Med*. 2010 Jul;39(6):460-4. Epub 2010 Jan 8.
- [68] Jalouli J, Ibrahim S, Mehrotra R, Jalouli MM, Sapkota D, Larsson P, Hirsch J. Prevalence of viral (hpv, ebv, hsv) infections in oral submucous fibrosis and oral cancer from India. *Acta Otolaryngol*. 2010 Nov;130(11):1306-11.
- [69] Chu YH, Tataakis DN, Wee AG. Smokeless Tobacco Use and Periodontal Health in a Rural Male Population. *J Periodontol*. 2010 Jun;81(6):848-54.
- [70] Accortt NA, Waterbor JW, Beall C, Howard G. Cancer incidence among a cohort of smokeless tobacco users. *Cancer Causes and Control* 2005; 16: 1107– 1115.
- [71] Greer RO Jr, Meyers A, Said SM, Shroyer KR. Is p16INK4a protein expression in oral ST lesions a reliable precancerous marker? *Int J Oral Maxillofac Surg*. 2008 Sep;37(9): 840-6. Epub 2008 Jul 7.
- [72] Leopardi EA, Poulson TC, Nieger BL, Lindenmuth JE, Greer RO. Smokeless tobacco usage patterns and male athlete sequelae: A Report of two surveys and associated intervention strategies among Utah adolescents. *J Cancer Ed* 1989; 4: 125–134.
- [73] Greer RO, Poulson TC. Oral changes associated with the use of smokeless tobacco by teenagers. *Oral Surg Oral Med Oral Pathol Oral Radiol Endod* 1983; 56: 275–284.
- [74] Vidal, L. & Gillison, M.L. Human papillomavirus in HNSCC: recognition of a distinct disease type. *Hematol Oncol Clin North Am*. 2008 Dec;22(6):1125-42, vii. DOI: 10.1016/j.hoc.2008.08.006.
- [75] Kreimer, A.R.; Clifford, G.M.; Boyle, P. & Franceschi, S. Human papillomavirus types in head and neck squamous cell carcinomas worldwide: a systematic review. *Cancer Epidemiol Biomarkers Prev*. 2005 Feb;14(2):467-75. Review. DOI: 10.1158/ 1055-9965.
- [76] Fakhry C, Westra WH, Li S, et al. Improved survival of patients with human papillomavirus-positive head and neck squamous cell carcinoma in a prospective clinical trial. *J Natl Cancer Inst*. 2008;100:261–9.
- [77] Snow, A.N. & Laudadio, J. Human Papillomavirus Detection in Head and Neck Squamous Cell Carcinomas. *Adv Anat Pathol*. 2010 Nov;17(6):394-403. Review. DOI: 10.1097/PAP.0b013e3181f895c1.
- [78] Guimarães, M.C.; Soares, C.P.; Donadi, E.A.; Derchain, S.F.; Andrade, L.A.; Silva, T.G. et al. Low Expression of Human Histocompatibility Soluble Leukocyte Antigen-G (HLA-G5) in Invasive Cervical Cancer With and Without Metastasis, Associated With Papilloma Virus (HPV). *J Histochem Cytochem*. 2010 May;58(5):405-11. Epub 2009 Sep 28. DOI: 10.1369/jhc.2009.954131.
- [79] Lira, R.C.; Miranda, F.A.; Guimarães, M.C.; Simões, R.T.; Donadi, E.A.; Soares, C.P. & Soares, E.G. BUBR1 expression in benign oral lesions and squamous cell carcinomas:

Correlation with human papillomavirus. *Oncol Rep.* 2010 Apr;23(4):1027-36. DOI: 10.3892/or\_00000729.

- [80] Mazon, R.C.; Gerbelli, T.R.; Neto, C.B.; de Oliveira, M.R.B.; Donadi, E.A.; Goncalves, M.A.G. et al. Abnormal cell-cycle expression of the proteins p27, mdm2 and cathepsin B in oral squamous-cell carcinoma infected with human papillomavirus. *Acta Histochem.* 2011 Feb;113(2):109-16. Epub 2009 Oct 6. DOI: 10.1016/j.acthis.2009.08.008.
- [81] Syrjänen, S. Human papillomavirus (HPV) in head and neck cancer. *J Clin Virol.* 2005 Mar;32 Suppl 1:S59-66.DOI: 10.1016/j.jcv.2004.11.017.
- [82] Gillespie, M.B.; Rubinchik, S.; Hoel, B. & Sutkowski, N. Human Papillomavirus and Oropharyngeal Cancer: What You Need to Know in 2009. *Curr Treat Options Oncol.* 2009 Dec;10(5-6):296-307. Epub 2009 Sep 19. DOI: 10.1007/s11864-009-0113-5.
- [83] Miranda, F.A.; Hassumi, M.K.; Guimarães, M.C.; Simões, R.T.; Silva, T.G.; Lira, R.C. et al. Galectin-3 Overexpression in Invasive Laryngeal Carcinoma, Assessed by Computer-assisted Analysis. *J Histochem Cytochem.* 2009 Jul;57(7):665-73. Epub 2009 Mar 30.DOI: 10.1369/jhc.2009.952960.
- [84] Oliveira, L.R.; Silva, A.R.; Ramalho, L.N.Z.; Simões, A.L. & Zucoloto, S. HPV infection in Brazilian oral squamous cell carcinoma patients and its correlation with clinicopathological outcomes. *Mol Med Report.* 2008 Jan-Feb;1(1):123-9.
- [85] Feller, L.; Wood, N.H.; Khammissa, R.A. & Lemmer, J. Human papillomavirus-mediated carcinogenesis and HPV-associated oral and oropharyngeal squamous cell carcinoma. Part 2: Human papillomavirus associated oral and oropharyngeal squamous cell carcinoma. *Head Face Med.* 2010 Jul 15;6:15. DOI: 10.1186/1746-160X-6-15.
- [86] IARC Monographs on the Evaluation of Carcinogenic Risks to Humans. Part B: biological agents LYON, France 2011, Volume 100B pp. 278–80
- [87] Dayyani F, Etzel CJ, Liu M, et al. Meta-analysis of the impact of human papillomavirus (HPV) on cancer risk and overall survival in head and neck squamous cell carcinomas (HNSCC). *Head Neck Oncol.* 2010;2:15. Published online 2010 June 29.
- [88] Lajer, C.B. & Von Buchwald, C. The role of human papillomavirus in head and neck cancer. *APMIS.* 2010 Jun;118(6-7):510-9. Review. DOI: 10.1111/j.1600-0463.2010.02624.x.
- [89] Ang, K.K.; Harris, J.; Wheeler, R.; Weber, R.; Rosenthal, D.I.; Nguyen-Tân, P.F. et al. Human Papillomavirus and Survival of Patients with Oropharyngeal Cancer. *N Engl J Med.* 2010 Jul 1;363(1):24-35. Epub 2010 Jun 7.DOI: 10.1056/NEJMoa0912217.
- [90] Sinha, P.; Logan, H.L. & Mendenhall, W.M. (2011). Human papillomavirus, smoking, and head and neck cancer. *Am J Otolaryngol.* 2012 Jan-Feb;33(1):130-6. Epub 2011 May 5. Review. DOI: 10.1016/j.amjoto.2011.02.001.

- [91] Leemans CR, Braakhuis BJ, Brakenhoff RH. The molecular biology of head and neck cancer. *Nat Rev Cancer*. 2011;11:9–22. Review
- [92] Hannisdal, K.; Schjølberg, A.; De Angelis, P.M.; Boysen, M. & Clausen, O.P. Human papillomavirus (HPV)-positive tonsillar carcinomas are frequent and have a favourable prognosis in males in Norway. *Acta Otolaryngol*. 2010 Feb;130(2):293-9.
- [93] Ragin CC, Taioli E. Survival of squamous cell carcinoma of the head and neck in relation to human papillomavirus infection: review and meta-analysis. *Int J Cancer*. 2007 Oct 15;121(8):1813-20.
- [94] Hennessey, P.T.; Westra, W.H. & Califano, J.A. Human papillomavirus and head and neck squamous cell carcinoma: recent evidence and clinical implications. *J Dent Res*. 2009 Apr;88(4):300-6.
- [95] Gillison ML, Koch WM, Capone RB, Spafford M, Westra WH, Wu L, et al. Evidence for a causal association between human papillomavirus and a subset of head and neck cancers. *J Natl Cancer Inst*. 2000 May 3;92(9):709-20.
- [96] Lindel K, Beer KT, Laissue J, Greiner RH, Aebersold DM. Human papillomavirus positive squamous cell carcinoma of the oropharynx: a radiosensitive subgroup of head and neck carcinoma. *Cancer*. 2001 Aug 15;92(4):805-13.
- [97] Butz K, Geisen C, Ullmann A, Spitkovsky D, Hoppe-Seyler F. Cellular responses of HPV-positive cancer cells to genotoxic anti-cancer agents: repression of E6/E7-oncogene expression and induction of apoptosis. *Int J Cancer*. 1996 Nov 15;68(4):506-13.
- [98] Califano J, van der Riet P, Westra W, Nawroz H, Clayman G, Piantadosi S, et al. Genetic progression model for head and neck cancer: implications for field cancerization. *Cancer Res* 1996;56:2488–92
- [99] Psyrri A, DiMaio D. Human papillomavirus in cervical and head-and-neck cancer. *24 Nat Clin Pract* 5: 24-31.
- [100] IARC Working Group on the Evaluation of Carcinogenic Risks to Humans (1995) Human papillomaviruses. *IARC Monogr Eval Carcinog Risks Hum* 64: 1–378.
- [101] zur Hausen H. Papillomaviruses and cancer: from basic studies to clinical application. *Nat Rev Cancer*. 2002 May;2(5):342-50. Review.
- [102] Crum CP, McLachlin CM, Tate JE, Mutter GL. Pathobiology of vulvar squamous neoplasia. *Curr Opin Obstet Gynecol*. 1997 Feb;9(1):63-9.
- [103] Kayes O, Ahmed HU, Arya M, Minhas S. Molecular and genetic pathways in penile cancer. *Lancet Oncol*. 2007 May;8(5):420-9. Review.
- [104] Gillison ML, Koch WM, Capone RB, Spafford M, Westra WH, Wu L, Zahurak ML, Daniel RW, Viglione M, Symer DE, Shah KV, Sidransky D. Evidence for a causal association between human papillomavirus and a subset of head and neck cancers. *J Natl Cancer Inst*. 2000 May 3;92(9):709-20.

- [105] Villa, L.L.; Costa, R.L.; Petta, C.A.; Andrade, R.P.; Ault, K.A.; Giuliano, A.R. et al. Prophylactic quadrivalent human papillomavirus (types 6, 11, 16, and 18) L1 virus-like particle vaccine in young women: a randomized double-blind placebo- controlled multicentre phase II efficacy trial. *Lancet Oncol.* 2005 May;6(5):271-8. DOI: 10.1016/S1470-2045 (05)70101-7.
- [106] Muñoz, N.; Kjaer, S.K.; Sigurdsson, K.; Iversen, O.E.; Hernandez-Avila, M.; Wheeler, C.M. et al. Impact of human papillomavirus (HPV)-6/11/16/18 vaccine on all HPV-associated genital diseases in young women. *J Natl Cancer Inst.* 2010 Mar 3;102(5): 325-39. Epub 2010 Feb 5. DOI: 10.1093/jnci/djp534.
- [107] Herrero, R. Human papillomavirus and cancer of the upper aerodigestive tract. *J Natl Cancer Inst Monogr.* 2003;(31):47-51.
- [108] Daling, J.R.; Madeleine, M.M.; Johnson, L.G.; Schwartz, S.M.; Shera, K.A.; Wurscher, M.A. et al. Penile cancer: importance of circumcision, human papillomavirus and smoking in situ and invasive disease. *Int J Cancer* 2005 Sep 10;116(4):606-16.
- [109] Gross, G. & Pfister, H. Role of human papillomavirus in penile cancer, penile intraepithelial squamous cell neoplasias and in genital warts. *Med Microbiol Immunol.* 2004 Feb;193(1):35-44. Epub 2003 Jun 28.
- [110] Syrjänen, S. The role of human papillomavirus infection in head and neck cancers. *Ann Oncol.* 2010 Oct;21 Suppl 7:vii243-5.
- [111] Zinkernagel, R.M. On natural and artificial vaccinations. *Annu Rev Immunol.* 2003;21:515-46. Epub 2001 Dec 19.
- [112] U.S. Food and Drug Administration, a. FDA Licenses Quadrivalent Human Papillomavirus (Types 6, 11, 16, 18) Recombinant Vaccine (Gardasil) for the Prevention of Cervical Cancer and Other Diseases in Females Caused by Human Papillomavirus [Online]. Available at: <http://www.fda.gov/AboutFDA/CentersOffices/CDER/ucm095647.htm>. Accessed May 10, 2011.
- [113] Centers for Disease Control and Prevention (CDC), 2010b. FDA licensure of quadrivalent human papillomavirus vaccine (HPV4, Gardasil) for use in males and guidance from the Advisory Committee on Immunization Practices (ACIP). *MMWR Morb. Mortal. Wkly. Rep.* 59, 630–632.
- [114] U.S. Food and Drug Administration. FDA News Release: FDA approved new vaccine for prevention of cervical cancer. [Online]. Available at: <http://www.fda.gov/NewsEvents/Newsroom/PressAnnouncements/ucm187048.htm>. Accessed November 30, 2009.
- [115] Klozar, J.; Tachezy, R.; Rotnáglová, E.; Koslabová, E.; Saláková, M. & Hamsíková, E. Human papillomavirus in head and neck tumors: epidemiological, molecular and clinical aspects. *Wien Med Wochenschr.* 2010 Jun;160(11-12):305-9. DOI: 10.1007/s10354-010-0782-5.

- [116] Chu, R.N. Therapeutic vaccination for the treatment of mucosotropic human papillomavirus-associated disease. *Expert Opin Biol Ther.* 2003 Jun;3(3):477-86.
- [117] Stanley, M. Genital human papillomavirus infections—current and prospective therapies. *J Natl Cancer Inst Monogr.* 2003;(31):117-24. Review.
- [118] Brinkman, J.A.; Caffrey, A.S.; Muderspach, L.I.; Roman, L.D. & Kast, W.M. The impact of anti-HPV vaccination on cervical cancer incidence and HPV-induced cervical lesions: consequences for clinical management. *Eur J Gynaecol Oncol.* 2005;26(2): 129-42.
- [119] Franceschi, S. The International Agency for Research on Cancer (IARC) commitment to cancer prevention: the example of papillomavirus and cervical cancer. *Recent Results Cancer Res.* 2005;166:277-97.

IntechOpen



