

We are IntechOpen, the world's leading publisher of Open Access books Built by scientists, for scientists

6,900

Open access books available

186,000

International authors and editors

200M

Downloads

Our authors are among the

154

Countries delivered to

TOP 1%

most cited scientists

12.2%

Contributors from top 500 universities



WEB OF SCIENCE™

Selection of our books indexed in the Book Citation Index
in Web of Science™ Core Collection (BKCI)

Interested in publishing with us?
Contact book.department@intechopen.com

Numbers displayed above are based on latest data collected.
For more information visit www.intechopen.com



Liver Tumors in Infancy

Julio C. Wiederkehr, Izabel M. Coelho,
Sylvio G. Avilla, Barbara A. Wiederkehr and
Henrique A. Wiederkehr

Additional information is available at the end of the chapter

<http://dx.doi.org/10.5772/51764>

1. Introduction

Hepatic tumors in children are relatively rare, accounting for 1 to 4% of all pediatric solid tumors. [1] Primary liver masses constitute the third most common group of solid abdominal tumors of childhood [2] with an incidence of 0.4 to 1.9 per million children each year. [3,4]

Liver masses in children can be malignant, benign, or indeterminate and they are a diverse group of epithelial and mesenchymal tumors whose incidence can vary considerably with patient age. [5] Two thirds of liver tumors in children are malignant. [6] Unlike liver tumors in adults, in which the predominant histology is hepatocellular carcinoma, hepatoblastoma accounts for two thirds of liver tumors in children. [7] Other liver malignancies in children include sarcomas, germ cell tumors, and rhabdoid tumors, as well as the more familiar hepatocellular carcinoma. Benign tumors of the liver in children include vascular tumors, hamartomas, adenomas, and focal nodular hyperplasia. The histology and anatomy of a pediatric liver tumor guides the treatment and prognosis. [8]

In this chapter we outline the epidemiology, etiology, pathology, clinical presentation, diagnosis and management of each of the most important types of liver tumor. Also aspects of the surgical anatomy and resection techniques and other ways to improve resectability in liver tumors in childhood will be described such as portal vein thrombosis, chemotherapy and transarterial chemoembolization (TACE).

2. Epidemiology

The incidence of hepatic tumors in childhood is consistently quoted from many series as being in the region of 0.5-2.5 per million population [9] and approximately 100–150 new cases

of liver tumors are diagnosed in the U.S. annually. [7] Two thirds of liver tumors in children are malignant. [6] accounting for slightly more than 1% of all pediatric malignancies and among those there is a male preponderance of 1.8 : 1. [7,10]

Hepatoblastoma presents in a younger age group, being a uncommon diagnosis over the age of 4 years. Hepatocellular carcinoma has its peak onset in early adolescence, although the range is wide. The older age at onset for hepatocarcinoma may well reflect its close association with other underlying disease processes. [10]

There are several suggestions that the incidence of malignant liver tumors is increasing in the U.S. Surveillance, Epidemiology, and End Results data from 1972–1992 showed a 5% annual increase. [7] Liver cancer represented 2% of all malignancies in infants in the early 1980s with the incidence doubling to 4% 10 years later. [11]

At a population level, there has been a dramatic increase in survival in countries in which a modern health system has been implemented, although the increased survival is lower for hepatocarcinoma in comparison with hepatoblastomas. [10] According to Litten & Tomlinson [8], it has been suggested that the improvements in technology, care, and outcomes for premature infants have been driving forces in the increase of the incidence in hepatic tumors. Hepatoblastoma is more commonly diagnosed in children with a history of prematurity than in full-term infants. Interestingly, those tumors that arise in ex-premature infants do not present at a younger age than those of term infants. [8]

3. Hepatoblastoma

Hepatoblastoma is the most common malignant tumor of the liver in children and is an embryonal tumor in the classic sense of incomplete differentiation; [12] accounts for 1% of all pediatric malignancies and for 79% of all liver cancers in children under age. [13] Its overall incidence is 0.5–1.5 per million, however the incidence in children under the age of 18 months is 11.2 cases per million. [14]

Hepatoblastoma is diagnosed in very young children with a peak in the newborn period reflecting those tumors that developed prenatally, and an overall median age at diagnosis of 18 months; 90 percent of cases are manifest by the fourth birthday, several have been present at birth, and there is an hypothesized association with prematurity. [15] Only 5% of new hepatoblastoma cases are diagnosed in children >4 years of age. [8]

The increased incidence of HB in children born before 28 weeks gestation (with birth weight <1500 g) compared with term gestations, may be explained by the exposure of rapidly dividing hepatoblasts to endogenous metabolites and hormones as well as exogenous chemicals that would normally be eliminated via the placenta. Inefficiency and compromise of the immature detoxification mechanisms could produce multiple somatic mutations and epigenetic (ie, methylation) modifications of the genome. [16, 17]

For poorly understood reasons, hepatoblastoma occurs in males significantly more frequently than it does in females with a male:female ratio that ranges from 1.2 to 3.6:1. [14] Most

commonly, these tumors present in the right lobe of the liver. [18] There is an increased incidence of hepatoblastoma in Beckwith-Wiedemann Syndrome, which has a relative risk of 2280 suggesting a role for genetic aberrations of chromosome 11 in the pathogenesis of hepatoblastoma,[19, 20] hemihypertrophy, and familial adenomatous polyposis (FAP) which has a relative risk of 1220 suggesting a role for aberrations of chromosome 5 in the pathogenesis. [21] Screening for cases in FAP kindred families is recommended by testing for germline mutations in the APC tumor suppressor gene. [22, 23] Inactivation of the APC tumor-suppressor gene (found on chromosome 5) is found in 67–89% of sporadic hepatoblastoma [24, 25] This gene is known to regulate B-catenin and modulate the wnt signaling pathway, suggesting a role for this signaling pathway in the development of hepatoblastoma. [26] Additional biologic markers may include Trisomy 2, 8, and 20 and translocation of the NOTCH2 gene on chromosome 1. [27]

Many etiological factors have been linked with the development of malignant hepatic tumors in childhood (Table 1). Broadly speaking, genetic influences are particularly important in the development of hepatoblastoma, whereas environmental factors and coexisting liver disease are strongly associated with hepatocellular carcinoma. [10]

Hepatoblastoma	Hepatocellular carcinoma
Beckwith-Wiedemann Syndrome	Hepatitis B
Hemihypertrophy	Hepatitis C
Familial adenomatous polyposis (FAP)	Hereditary tyrosinemia
	α_1 -Antitrypsin deficiency
Gardner syndrome	Cirrhosis secondary to biliary atresia
Glycogen storage disease type I	Glycogen storage disease type I
Trisomy 18	Neurofibromatosis
Fetal alcohol syndrome	
Prematurity and low birth weight	Familial adenomatous polyposis
Maternal exposure to:	Drug/toxin exposure:
Oral contraceptives	Androgens
Gonadotropins	Oral contraceptives
Metals	Methotrexate
Petroleum products	Aflatoxins
Paints and pigments	
Paternal exposure to:	Fanconi anemia
Metals	
Meckel diverticulum	

Table 1. Conditions associated with hepatoblastoma and hepatocellular carcinoma.

Hepatoblastomas are composed of cells resembling the developing fetal and embryonic liver, hence the classification as an embryonal tumor. Indeed, the cells comprising hepatoblastoma mark similarly to hepatic stem cells, defined as pluripotent hepatoblasts capable of differentiating into hepatocytes or cholangiocytes. [28, 29]

According to the Childhood Epithelial Liver Tumors – International Criteria (CEL TIC) group, the pathology of hepatoblastoma is classified into four groups based on the work of Weinberg and Finegold: fetal, embryonal, macrotrabecular and small-cell undifferentiated. [10]

Histologically, these tumors can be divided into epithelial (56%) or mixed epithelial/mesenchymal tissue. The epithelial group is further subdivided into fetal (31%), embryonal (19%), macrotrabecular (3%) and small-cell undifferentiated subtypes (3%). The majority of hepatoblastomas is epithelial and consist of a mixture of embryonal and fetal cell types (Fig. 1). [8, 30]

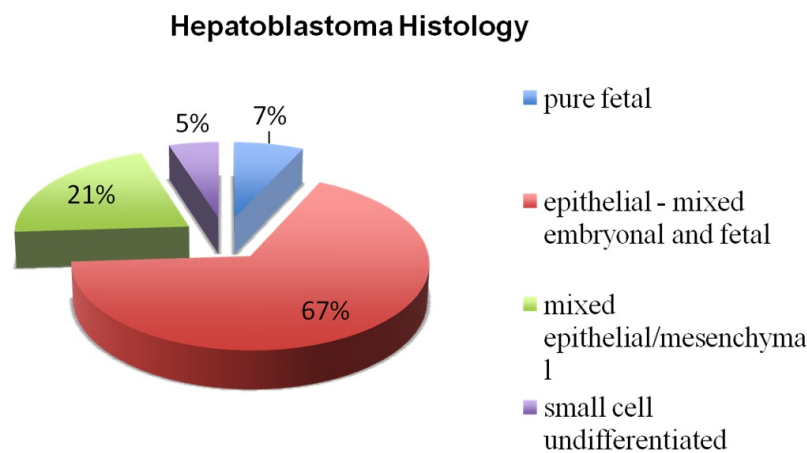


Figure 1. Distribution of histologic subtypes of hepatoblastoma. The majority are epithelial and consist of embryonal and fetal cell types. Pure fetal histology accounts for approximately 7% of hepatoblastomas and is associated with a favorable prognosis. Small cell undifferentiated hepatoblastoma accounts for 5% of hepatoblastoma cases and is associated with a poor prognosis. [8]

Of the five histologic subtypes—pure fetal, embryonal, mixed epithelial, mesenchymal/macrotrabecular, and small cell undifferentiated—fetal carries the most favorable prognosis. [31] Approximately 5% of hepatoblastomas are of the small cell undifferentiated subtype. This subtype is associated with a worse prognosis. [32] In the mixed epithelial/ mesenchymal type, the presence of mesenchymal elements is associated with improved prognosis and the most common mesenchymal elements are cartilage and osteoid. [33]

Hepatoblastomas usually presents as a palpable asymptomatic mass with abdominal distension. [10] Less common presentations include weight loss, anorexia, emesis and abdominal pain and usually indicate advanced disease. [34] One of the more unusual presenting features of hepatoblastoma is its association with sexual precocity due to the release of human chorionic gonadotropic hormone (β -HCG) by the tumor. Osteoporosis is said to occur in up to 20% of the cases and when severe can lead to bone fractures and vertebral compression. [35] The tumor may rupture spontaneously, producing an acute abdomen and hemoperitoneum. [10]

Approximately 90% of patients demonstrate elevated serum AFP levels and there is a correlation between AFP levels and extent of disease. [36]

The right lobe of the liver is most commonly involved with disease but in 35% of patients there is bilateral disease. [37] Distant metastasis are present in 20% of patients at the time of diagnosis with the lung being the most common site of metastasis; other common sites are the brain and bone and metastasis occur more commonly with disease relapse. [38]

	Hepatoblastoma (%)	Hepatocellular carcinoma (%)
Abdominal mass	71	58
Weight loss	24	21
Anorexia	22	22
Pain	18	16
Vomiting	13	10
Jaundice	7	10

Table 2. Signs and symptoms of liver tumors in children. [10]

Overall, the diagnosis is based on laboratory tests (such as full blood count, liver function tests, α -Fetoprotein – AFP and other markers), imaging (abdominal radiography, ultrasonography, computer tomography, magnetic resonance imaging, hepatic angiography, chest radiography and positron-emission tomography – PET) and biopsy.

The full blood count can reveal anemia (usually normocytic, normochromic) in at least 50% of children with hepatoblastoma. [13, 39] The platelet count is also often abnormal with up to one-third of patients demonstrating thrombocytosis and fewer patients having thrombocytopenia. Thrombocytosis is thought to be related to increased levels of circulating thrombopoietin. [40]

Liver function tests are commonly normal in hepatoblastoma. [10] The serum alpha-fetoprotein (AFP) level is elevated in 90% of children with hepatoblastoma and tumors that fail to express AFP at diagnosis are felt to be biologically more aggressive. [41, 42] AFP levels must be interpreted with caution because AFP is commonly elevated in normal neonates up to 6 months of age and may be slightly elevated in other tumors, as well as after hepatic damage or during regeneration of liver parenchyma.

The imaging study is important in evaluation liver neoplasms. CT, MRI and ultrasound are the most commonly used modalities for pediatric doctors in their medical researches as well as their clinical practice. Ultrasound is accepted as a first-line imaging method because of its less irradiation, greater convenience and better real-time. [43] Ultrasound is extremely valuable in detecting much smaller lesions, especially in detecting fluid and blood-flow in a lesion, and it also can evaluate the hepatic vascular anatomy.[44] As a rule, the initial diagnosis of live tumor is usually made by the abdominal ultrasound examination, which will identify the liver as the organ of origin. Hepatoblastoma are seen as a hyperechoic, solid, intrahepatic mass on US. [45]

Both CT and MRI define the extent of tumor involvement showing its segmental extension and its proximity to the portal vein, to help determine the resectability. Evaluation with CT demonstrates a delineated hypoattenuated mass compared with the surrounding normal tissue and allows identification of calcifications. [46] The use of contrast allows assessment of vascular involvement by the tumor. Combined MRI and contrast enhanced MR-angiography gives the best evaluation of the vascular structures and the tumor blood supply, and this best enables the planning of a resection. A diagnostic biopsy is recommended in all children with a suspected hepatoblastoma. Given the potential side effects of chemotherapy, it is not a good clinical practice to start therapy in a patient in the absence of a tissue diagnosis. Additionally, it is necessary to rule out HCC. Although it is rare, HCC have been reported in children under the age of three and they carry a worse prognosis. [47]

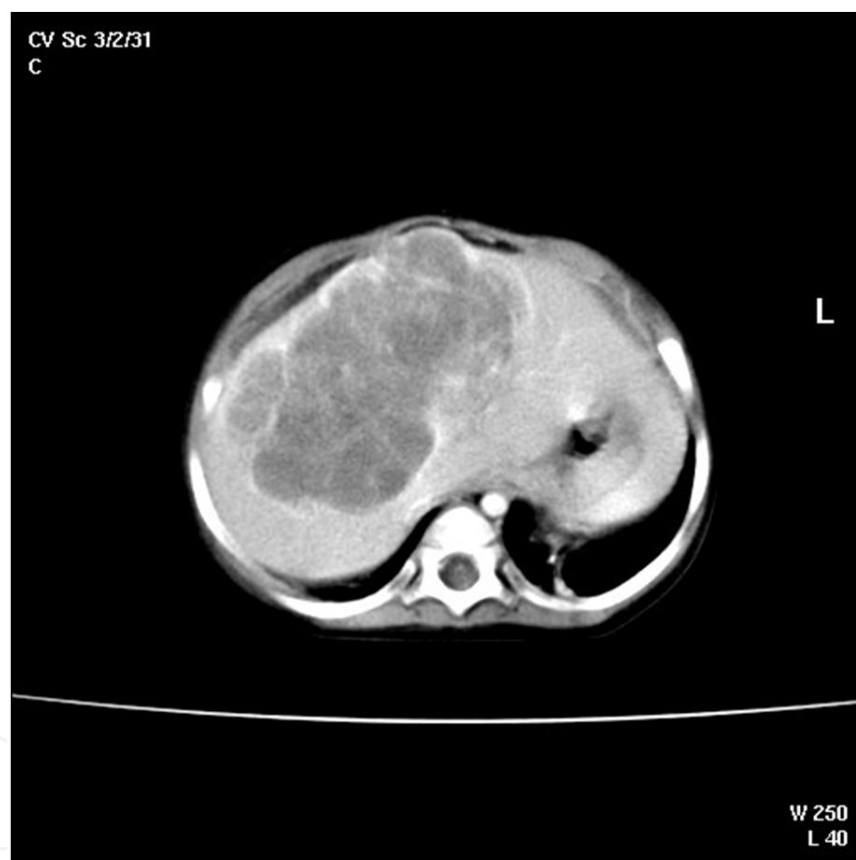


Figure 2. CT scan of an infant with a large central hepatoblastoma.

Large multinodular expansile masses, hepatoblastomas radiographically appear well demarcated from the normal liver but are not encapsulated. They may invade hepatic veins, disseminate to the lungs, or penetrate the liver capsule to reach contiguous tissues. [12]

Historically, North Americans have staged liver tumors similar to other solid tumors, staging system continues to be used by the children's oncology group (COG) and depends upon extent of surgery at the time of initial diagnosis.

Relative number of patients presenting in each stage in the COG trial 9645 (1999–2003) is as follows: Stage I (22%) indicates complete resection at diagnosis, Stage II (0.5%) microscopic residual after attempted complete resection at diagnosis, Stage III (53%) biopsy at diagnosis with gross residual tumor, and Stage IV (23%) metastatic disease at diagnosis.[48, 49] The traditional COG staging system has been criticized for being rather subjective, depending to a large extent on the surgeon rather than the tumor.[12, 50] To address this concern specific surgical guidelines have been proposed by the COG liver tumor committee which define the anatomic and biologic characteristics of a tumor for which resection at diagnosis is recommended. In addition the upcoming COG hepatoblastoma (AHEP 0731) protocol will add a risk-based stratification of treatment as follows: low risk (Stage I/II lacking any unfavorable biologic feature); intermediate risk (Stage III or Stage I/II with small cell undifferentiated histology); and high risk (Stage IV or Stage I/II/III with AFP <100 at diagnosis). [12]

3.1. Stage Information

There are two standard surgical staging systems for pediatric liver tumors. The Childhood Liver Tumour Strategy Group (SIOPEL) uses a presurgical-based staging system, while the Children's Oncology Group (COG) uses a postsurgical-based staging system. The staging systems support different treatment strategies. The presurgical staging system is used with neoadjuvant chemotherapy followed by definitive surgery (with the exception of Pretreatment Extent of Disease [PRETEXT] stage 1), while the postsurgical staging system has surgery as the initial strategy.

Both systems are used in the United States. In a retrospective comparison of the two staging systems at diagnosis using data from patients entered on a North American randomized trial, both staging systems predicted outcome. The presurgical PRETEXT staging system may add prognostic information for patients staged postsurgically at stage 3. [51] The COG is investigating the use of PRETEXT stage before and after chemotherapy to determine the optimal surgical approach. [52]

3.2. Presurgical Staging for Hepatoblastoma and Hepatocellular Carcinoma

The PRETEXT staging system for hepatoblastoma categorizes the primary tumor based on extent of liver involvement at diagnosis. The staging system was devised for use in an international hepatoblastoma treatment program in which only children with PRETEXT stage 1 hepatoblastoma undergo initial resection of tumor. All others are treated with chemotherapy prior to attempted resection of the primary tumor. The liver tumors are staged by interpretation of computerized tomography or ultrasound with or without additional imaging by magnetic resonance. The presence or absence of metastases is noted in addition to the PRETEXT stage, but does not alter the PRETEXT stage. Tumor involvement of the vena cava, hepatic veins, and portal vein, and extrahepatic extension are also noted.

The imaged liver is divided into four quadrants and involvement of each quadrant with tumor is determined. Stage increases and prognosis decreases as the number of quadrants radiologically involved with tumor increases from one to four. [53, 50] Experienced radiologist review is

important because it may be difficult to discriminate between real invasion beyond the anatomic border of a given sector and displacement of the anatomic border. [50, 43]

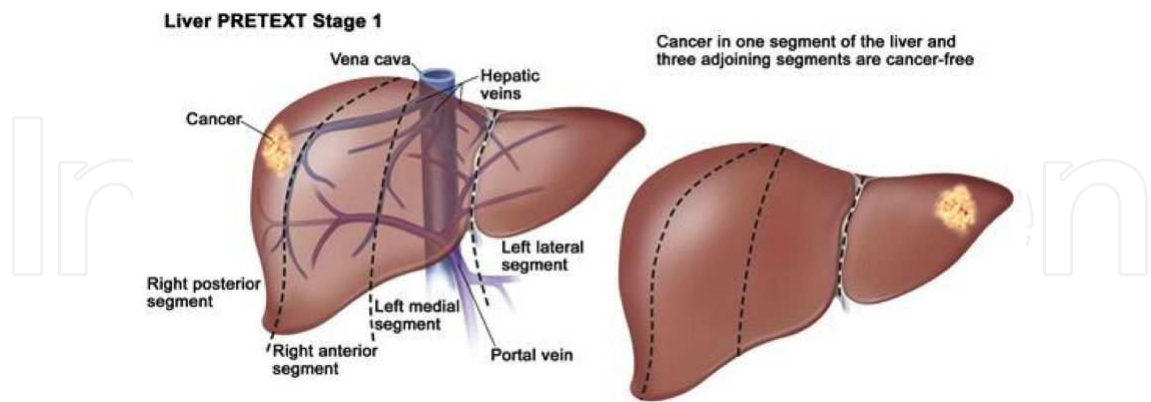


Figure 3. Pretext stage 1 - Tumor involves only one quadrant; three adjoining liver quadrants are free of tumor. [http://www.cancer.gov/PublishedContent/MediaLinks/308970.html]

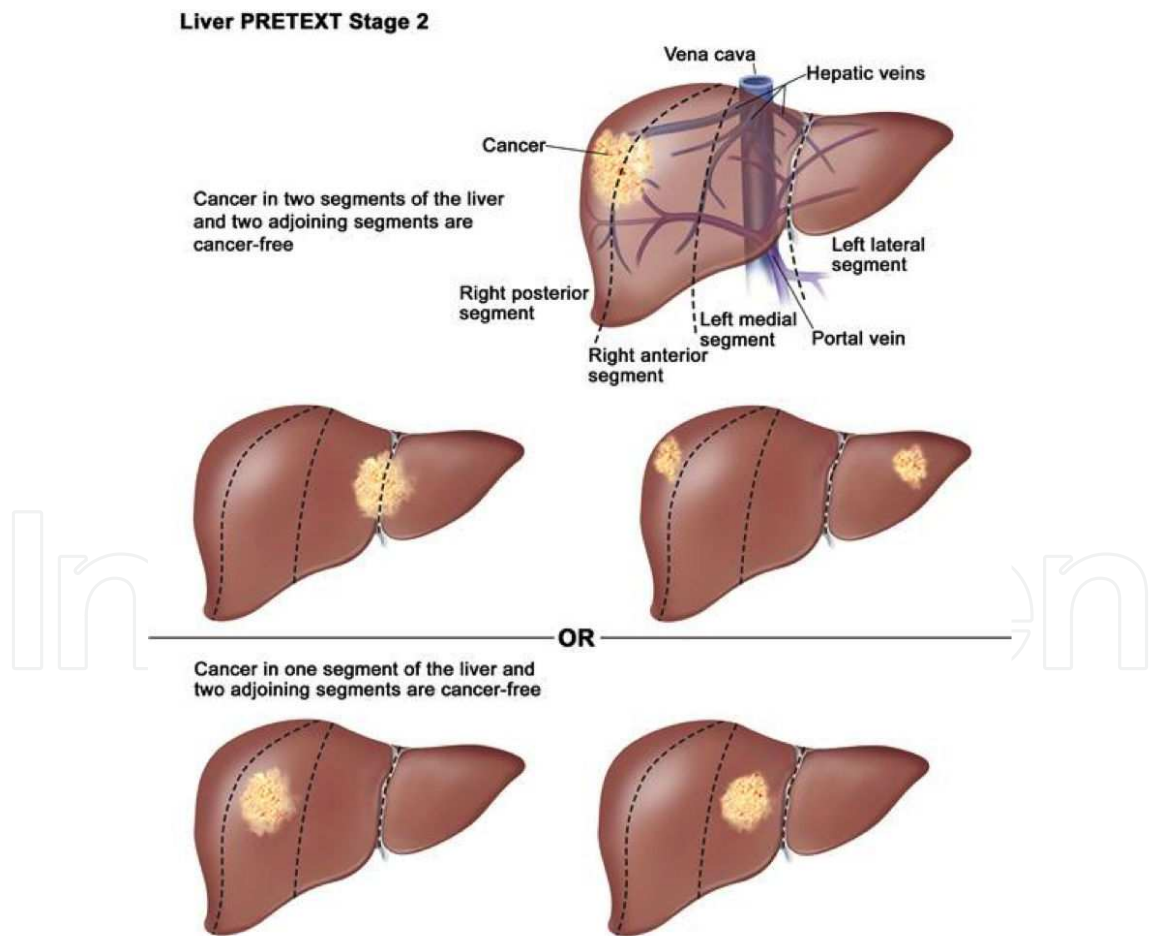


Figure 4. Pretext stage 2 - Tumor involves one or two quadrants; two adjoining quadrants are free of tumor. [http://www.cancer.gov/PublishedContent/MediaLinks/308970.html]

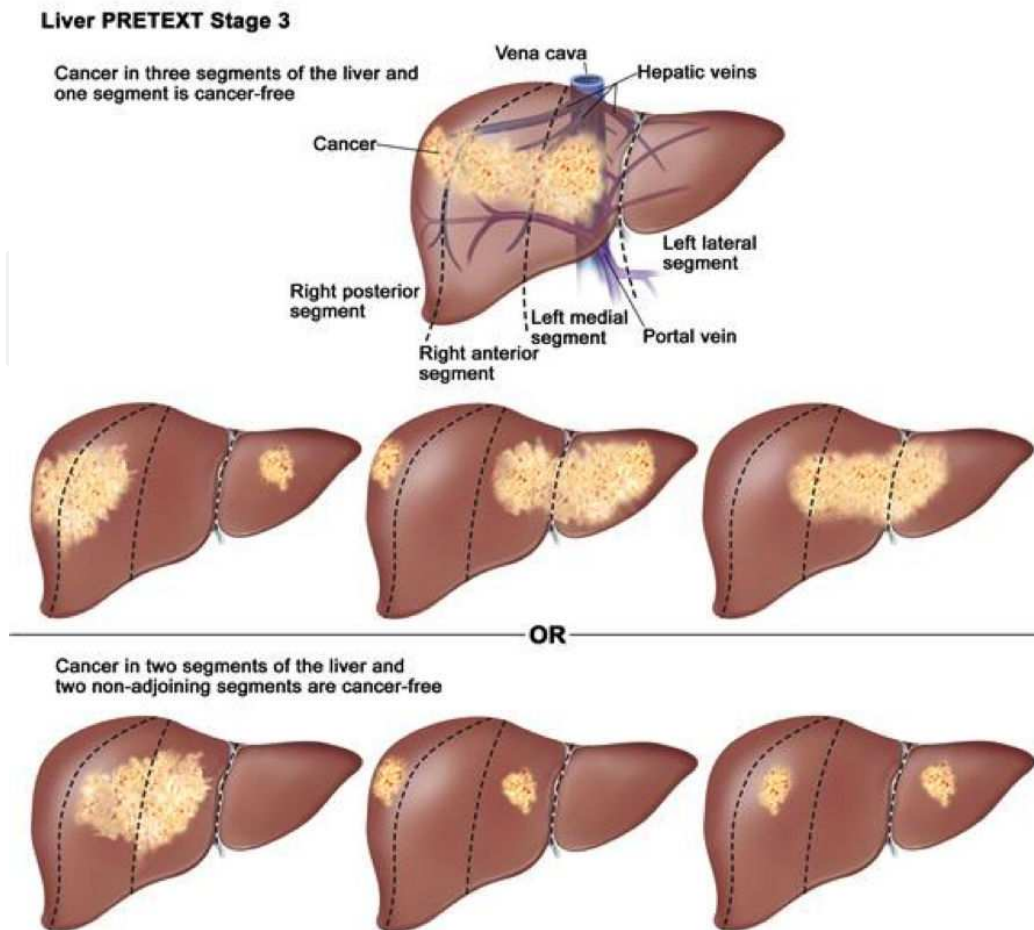


Figure 5. Pretext stage 3 - Tumor involves three quadrants and one quadrant is free of tumor or tumor involves two quadrants and two nonadjoining quadrants are free of tumor. [<http://www.cancer.gov/PublishedContent/MediaLinks/308970.html>]

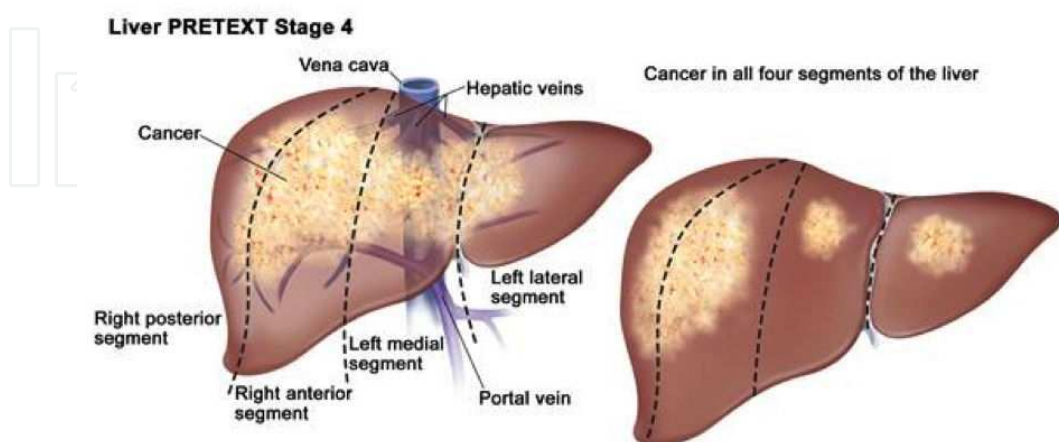


Figure 6. Pretext stage 4 - Tumor involves all four quadrants; there is no quadrant free of tumor. [<http://www.cancer.gov/PublishedContent/MediaLinks/308970.html>]

3.3. Treatment - Chemotherapy

During the past 30 years, there has been an improved survival for patients with HB based on refinements in surgical techniques, a better understanding of the hepatic segmental anatomy, advances in chemotherapy, and the advent of liver transplantation as a therapeutic modality for patients with unresectable disease. HB is a surgical neoplasm and only complete tumor resection results in a realistic hope for cure. Long-term disappearance of tumor with complete remission with chemotherapy alone has been anecdotally observed. However, chemotherapy is a cornerstone in the management of HB. [55]

Although chemosensitivity varies between patients, it is an essential component of the management and complementary to radical surgical resection to affect a cure. In general, surgeons agree that preoperative chemotherapy helps to reduce the size of most tumors and obtains better demarcation between the tumor and surrounding liver tissue. [56, 57, 58] Consequently, tumors are more likely to be completely resected without increasing perioperative morbidity or mortality. It is also speculated that residual microscopic disease may behave more aggressively under the influence of hepatotrophic factors stimulating liver regeneration if preoperative chemotherapy has not been used. [58] On the other hand, von Schweinitz et al. [59] have shown that there is little to be gained from prolonging chemotherapy beyond the planned treatment regimen, which incurs the risk of developing chemoresistance. [55]

Even if unresectable at diagnosis, most hepatoblastomas are unifocal and chemosensitive, especially to “platinum” derivative chemotherapeutic agents. With the routine addition of cisplatin to the chemotherapy in the late 1980s, overall survival in hepatoblastoma increased from 30% to 70%. [60, 61] Twenty years later, cisplatin remains the backbone of the chemotherapy regimen. In current trials by COG (America), SIOPEL (Europe, South America), GPOH (German), and JPLT (Japan) chemotherapeutic agents used in combination with cisplatin have differed slightly. Although most use some form of doxorubicin, COG currently recommends Cisplatin/5FU/Vincristin (C5V) for low-risk tumors, C5V+Doxorubicin for intermediate risk, and hopes to investigate new agents with up-front window therapy in high-risk tumors. [48, 49] Irinotectan, with or without doxorubicin, has been used in both America and Europe for patients with relapse. [62] Because tumor cells may become resistant to chemotherapy over prolonged exposure [63] and because cumulative chemotherapy toxicity may be unwarranted, prolonged (44 cycles) courses of neoadjuvant chemotherapy are discouraged by all study groups. Early referral for complex surgical planning may be indicated for large invasive tumors potentially requiring transplantation. [12]

Two principle strategies exist. In the United States, tumor resection at diagnosis, whenever prudently possible, has been advocated with the argument that toxicity of chemotherapy can be reduced by avoidance of unnecessary neoadjuvant chemotherapy, that some tumors may become resistant to prolonged courses of chemotherapy [64] and the highest survival rates have historically been observed in patients with initially resected tumors—although these tumors also tend to be the smaller more favorable tumors. Proposed COG Surgical guidelines advocate definitive surgical resection at diagnosis for localized, unifocal PRETEXT I and II tumors followed by chemotherapy. When the tumor is large (PRETEXT III or IV), multicentric, shows radiographic evidence of portal or hepatic venous invasion, or pul-

monary metastatic lesions the chance of curative resection may be improved neoadjuvant chemotherapy and delayed primary resection. Alternatively, the SIOPEL study group discourages resection of hepatoblastoma at diagnosis favoring neoadjuvant chemotherapy in all patients with the argument that the chemotherapy renders most tumors smaller, better demarcated, and more likely to be completely resected, and that the toxicity of neoadjuvant chemotherapy is offset by the increased rates of surgical resectability. Both COG and SIOPEL have invested considerable effort in attempts to decrease the significant ototoxicity attendant to the use of cisplatin based chemotherapy in young infants and toddlers. [12]

In the Intergroup Hepatoblastoma/ Hepatocellular Carcinoma Study, 28% of HB tumors were completely resected at diagnosis (Stage I) and 4% (Stage II) were incompletely excised. These patients had a 91% and 100% 5-year survival, respectively. However, the surgical guidelines of the protocol lacked clear recommendations regarding which tumor should or should not be resected at diagnosis. The study compared the use of cisplatin and doxorubicin in one treatment arm to cisplatin, vincristine, and 5-fluorouracil (5-FU) in the other arm. The overall 3- year survival rates were 63% and 71%, respectively. [65] Although the difference between the groups was not significant, the cisplatin/ doxorubicin group had a higher toxicity rate. A significant response to preoperative chemotherapy was observed in Stage III patients allowing complete tumor resection in 70–80% of these cases. Pre-operative chemotherapy had no effect on operative mortality; however, increased transfusion requirement and a higher operative morbidity was observed in patients that received chemotherapy preoperatively. [55]

The studies coordinated by the SIOPEL group have concentrated on using preoperative chemotherapy. [56, 66] In SIOPEL-1, all patients were treated preoperatively with four courses of cisplatin and doxorubicin (PLADO); surgical resection was followed by two more courses of chemotherapy. If the tumor was judged unresectable by imaging after four courses of chemotherapy, attempting surgical resection was delayed until after the sixth course. If the tumor remained localized to the liver but was still unresectable, liver transplantation was recommended as the primary operative procedure if some response to chemotherapy had been obtained in the absence of extrahepatic tumor extent or metastatic disease. The SIOPEL-2 pilot study [67] was designed to test the efficacy and toxicity of two chemotherapy regimens, one for patients with HB confined to the liver and involving no more than three hepatic sections “standard-risk (SR) HB”, and one for instances of HB extending into all four sections and/or with lung metastases or intra-abdominal extrahepatic spread or tumor rupture at presentation or with serum AFP < 100 units at presentation “high-risk (HR) HB”. Those with SR-HB were treated with four courses of cisplatin monotherapy, delayed surgery, and then two more courses of cisplatin. Patients with HR-HB were given cisplatin alternating with carboplatin and doxorubicin, pre- and postoperatively. For SR-HB patients (n = 77), and HR-HB patients (n = 58), the 3-year progression-free survival rates were 89% and 48%, respectively. For SR-HB patients, the efficacy of cisplatin monotherapy and the cisplatin/doxorubicin combination are now being compared in a prospective randomized trial (SIOPEL-3 study). For HR-HB patients, intensified chemotherapy with cisplatin, doxorubicin, and carboplatin is being investigated in a SIOPEL-4 study. [55]

In unifocal HB, PRETEXT grouping based on imaging studies at diagnosis in some cases may lead to overstaging the tumor from PRETEXT III to PRETEXT IV when the anatomic border separating a lateral section from the sections of the liver harboring the bulging mass is simply displaced (due to compression) but not invaded. [56, 68] Indeed, repeat imaging studies after chemotherapy, when the tumor has shrunk, can demonstrate that the anatomic border is free from invasion and allow for correct staging and performance of a partial hepatectomy (right or left trisegmentectomy). In multifocal HB with lesions scattered in the different sections of the liver, clearance of one section, (e.g. the left lateral section) [69] can apparently be achieved by chemotherapy in some cases, tempting the surgeon to perform a partial rather than a total hepatectomy. However, this strategy is not recommended because of the high-risk of leaving viable malignant tumor cells in the remaining section. Therefore, in multifocal hepatoblastoma, liver transplantation is the best treatment option, whatever the apparent result of chemotherapy. Further intensification of chemotherapy when the response to completion of full courses of chemotherapy according to protocol is considered unsatisfactory, and hazardous attempts at partial liver resection in order to avoid liver transplantation “at any cost” are no longer justified since the efficacy of primary liver transplantation for unresectable HB has been validated during the last decade. [55]

Even patients presenting with metastatic disease are potentially curable with a combination of chemotherapy, complete tumor resection by partial hepatectomy or transplantation, and pulmonary metastasectomy. The role of pulmonary metastasectomy has yet to be clearly defined, although it appears that surgical resection of lung deposits may be more likely to cure patients with disease present at diagnosis but persistent after neoadjuvant therapy rather than patients with pulmonary relapse. [12] Data from the most recent COG study, 9645, show 3-year event-free survival of 90% for Stage I–II, 50% for Stage III, and only 20% for Stage IV (Malogolowkin et al., 2007). In the European SIOPEL II 3-year survival for standard risk tumors was 90% and for high-risk tumors was 50%. Cure from hepatoblastoma mandates a complete gross resection of the primary tumor at some point during the treatment regimen. [12]

3.4. Surgical resection

The objective of the surgical procedure is to obtain a complete resection of the tumor, both macro- and microscopically, which is paramount for cure of HB (and other liver cancers). The surgical strategy should be based on a sound knowledge of segmental liver anatomy as described by Couinaud, [70] vascular occlusion techniques and expertise in performing the different types of liver resections, including the most extensive procedures (left or right trisegmentectomies). Intraoperative ultrasound is useful in confirming the location of major vessels and other structures. Nonanatomical, atypical resections are best avoided, except in rare cases (i.e., pedunculated tumor), because of an increased risk of incomplete tumor removal and a higher incidence of postoperative complications. [58] Very extensive liver resections (up to 80% of the liver mass) can be tolerated by young children with HB and hepatic regeneration can be complete within 3 months, despite the administration of toxic agents since they usually have no underlying liver disease and excellent hepatic reserve. [71] Liver function rapidly returns to normal without long-term sequelae. Complete tumor resec-

tion can be easily achieved with a partial hepatectomy when the intrahepatic extent is limited to one or two sections (PRETEXT I and II). When the tumor involves three sections (PRETEXT III), preoperative neoadjuvant chemotherapy can make lesions initially considered “unresectable” become resectable with a trisegmentectomy. [55]

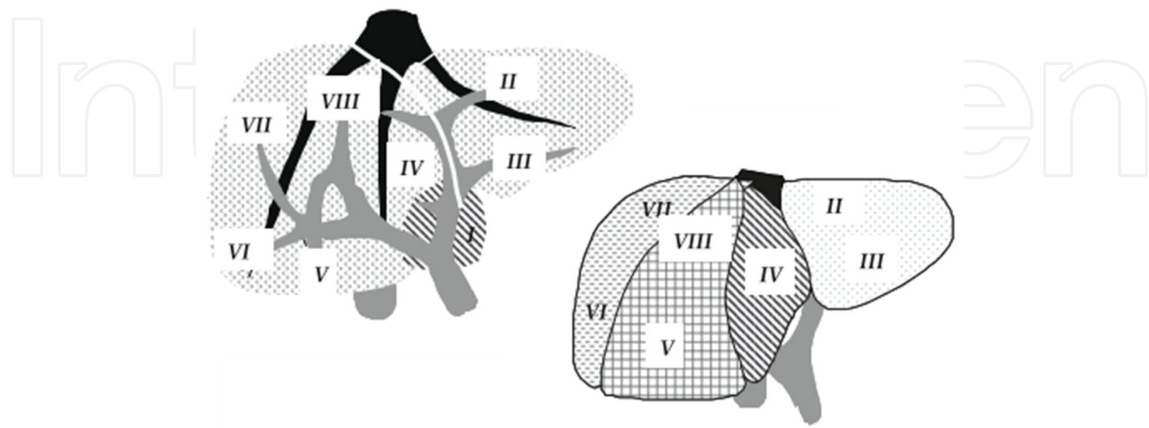


Figure 7. Couinaud's liver segmentation.

In centrally located HB, resection of Couinaud's segments 4, 5 and 8 (“central hepatectomy”) can occasionally be performed by expert hands. When an accessory right hepatic vein of appropriate size is present to drain remaining segments 5–7, subtotal hepatectomy removing segments 1–4 and 8 can be successfully performed. [55]

3.5. Liver transplantation

A growing experience with liver transplantation has shown that liver transplant is a good treatment option in children with unresectable primary tumors and without demonstrable metastatic disease after neoadjuvant chemotherapy and pulmonary metastasectomy if necessary. In large solitary, and especially multifocal, hepatoblastomas invading all four sectors of the liver, transplantation has resulted in long-term disease free survival in up to 80% of children. [73] While most agree that “extreme” resection of tumors without liver transplant will avoid the need for long-term immunosuppressive therapy, hazardous attempts at partial hepatectomy in children with major venous involvement or with extensive multifocal tumors should be discouraged. [56, 69, 74, 75, 76] Extensive hepatic surgery in children should be carried out in centers that have a facility for liver transplant, where surgical expertise, as well as willingness to embark on more radical surgery with a transplant “safety net” is likely to be greater. [76]

Previous studies have validated the concept of total hepatectomy and primary orthotopic liver transplantation (OLT) for unresectable HB. In SIOPEL-1, [77] 12 patients (8% of all patients enrolled from 1990 to 1994) underwent liver transplantation as the primary surgical option (after appropriate preoperative chemotherapy) in seven children, and as a rescue procedure in five children because of incomplete partial resection or tumor relapse after partial hepatectomy. The long-term, disease-free patient survival was 66% for the entire series

and 85% and 40% for primary transplants and rescue transplants, respectively. Current follow up is >10 years for all patients. All eight patients with PRETEXT IV tumors and all six patients with multifocal HB were cured of their disease. Of the seven patients with macroscopic extension into the portal vein and/or the hepatic veins/vena cava, 71% became long-term, disease-free survivors, as well as four of five (80%) children who had lung metastases at presentation with complete clearance of lung lesions after chemotherapy. [55]

An extensive review of the world experience collected 147 cases of liver transplantation for HB. [77] Data were contributed by 24 centers (12 in North America, 10 in Europe, 1 in Japan and Australia each). Twenty-eight (19% of the total) patients presented with macroscopic venous extension and 12 (8%) with lung metastases. A total of 106 patients (72%) underwent a primary transplant and 41 (28%) received a rescue transplant, either for incomplete resection with partial hepatectomy or for tumor relapse after previous partial hepatectomy. Twenty-eight (19%) received a live, donor-related liver transplant, and 119 (81%) received a deceased donor liver graft. Median follow up since diagnosis for surviving patients was 38 months (range 1– 121 months). Overall disease-free survival at 6 years post-transplant was 82% and 30% for primary transplants and for rescue transplants, respectively. Multivariate statistical analysis showed no difference in regard to gender, age, and lung metastases at presentation or type of transplant. For primary transplants, the only parameter significantly related to overall survival was macroscopic venous invasion ($P = 0.045$). Remarkably, the 6-year, disease-free survival (82%) for the 106 patients who received a primary transplant was similar to the 3-year, progression-free survival (89%) for the 77 HB patients with standard-risk hepatoblastoma confined to the liver and involving no more than 3 hepatic sections that were enrolled in the SIOPEL-2 study. [67] In a recent review of the UNOS database in the USA concerning liver transplantation in 135 children transplanted for unresectable or recurrent HB (1987–2004), the one, five, and 10-year survival was 79%, 69%, and 66% respectively. [78] The median age at transplantation was 2.9 ± 2.5 years. Sixteen percent received a graft from a live donor. Fifty-five percent of the deaths were due to metastases or recurrent disease. The latest ELTR report, including 129 patients transplanted for HB has shown a 1- and 5-year survival of 100% and 74%, respectively. [55, 79]

3.6. Timing of transplantation

Timing of liver transplantation should not be delayed in excess of a few weeks after the last course of chemotherapy (as per protocol). An expeditious access to organ donors is required to meet this requirement. If this is not possible with deceased donors (including split liver grafts), a live-related donor is a valuable option. [55]

According to the results of published studies, the following guidelines have been developed for early consultation with a transplant surgeon: [55]

1. Multifocal PRETEXT IV HB is a clear and undisputed indication for primary liver transplantation, whatever the result of chemotherapy. Apparent clearance of one liver lobe should not distract from this guideline because of the high probability of persistent microscopic viable neoplastic cells. Pediatric oncologists should resist the temptation to in-

tensify chemotherapy in a vain effort to avoid transplantation. These patients should be treated within the same protocol as patients with localized tumors amenable to partial hepatectomy, with as many cycles of chemotherapy before and after transplantation as patients submitted to partial hepatectomy for a localized HB.

2. Primary liver transplantation may be the best option for large, solitary PRETEXT IV HB, involving all four sections of the liver, unless tumor downstaging is clearly demonstrated after initial chemotherapy. If this is the case, a clear retraction of the tumor from the anatomic border of one lateral sector would allow performance of a radical trisegmentectomy.
3. Unifocal, centrally located PRETEXT II and III tumors involving main hilar structures or all three main hepatic veins should be considered for primary liver transplantation because these venous structures would presumably not become free of tumor after chemotherapy. Heroic attempts at partial hepatectomy would be best avoided because of the risk of incomplete resection of malignant tissue.

3.7. Contraindications

Persistence of viable extrahepatic tumor deposit after chemotherapy, not amenable to surgical resection, is the only absolute contraindication for liver transplantation. Macroscopic venous invasion (portal vein, hepatic veins, vena cava) is not a contraindication if complete resection of the invaded venous structures can be accomplished. When there is evidence or suspicion of invasion of the retrohepatic vena cava, it should be resected “en-bloc” and reconstructed. Review of the world experience showed that venous extent was associated with a significantly shorter survival ($P = 0.045$). [77] Of the nine TNM IV A/IVB patients (eight with major intrahepatic venous invasion) reported by Reyes and associates, seven were alive and disease-free 21–146 months after transplantation. [80]

Patients with lung metastases at presentation should not be excluded from liver transplantation if the metastases clear completely after chemotherapy and/or surgical resection. Long-term, disease-free survival was obtained in 80% of such patients in the SIOPEL-I study and 58% in the world experience. Complete eradication of metastatic lesions by chemotherapy and surgical resection of any suspicious remnant after chemotherapy is a paramount pre-requisite for transplantation. [81] When tumor resection by partial hepatectomy is incomplete or when intrahepatic relapse is observed after a previous partial hepatectomy, performing a rescue liver transplantation may be a relative contraindication because of the disappointing results observed in the SIOPEL-I study and in the reported world experience. [55]

3.8. Outcomes

In experienced surgical units, major intraoperative complications of liver resection for HB such as severe bleeding, air embolism, and unrecognized bile duct injury are infrequent and operative mortality is very low, even after extended hepatectomies, since children with HB have no underlying liver disease. As an example, summarizes the 25 years (1978–2003) of experience gained at Cliniques Saint-Luc, Brussels [82] with 53 children treated for HB.

There were 39 partial hepatectomies, including 23 right or left trisegmentectomies, and 13 primary liver transplants (two from deceased donors and 11 from living related donors). Only one child died from surgical complications (extensive portal vein thrombosis present at diagnosis). Postoperative bleeding requiring reoperation was encountered in 2 patients (3.5%). The incidence of biliary complications was 7.6% after partial hepatectomy and 23% following liver transplantation. Actuarial disease-free survival was 89% and 79% in transplant patients and in children treated with partial hepatectomy, respectively. [55]

Although individual centers treat relatively small numbers of patients with liver cancer, the best overall survival rates are obtained in experienced units that include liver transplantation in their surgical armamentarium. [55, 83, 84, 85]

The most recent report from King's college, London [86] confirms that the modern strategy of combining chemotherapy and radical tumor resection enables the majority of children with HB to be cured. From October 1993 to February 2007, 25 liver transplantations were performed for HB: 18 from deceased donors and 7 from living donors. Fifteen and ten patients were PRETEXT IV and III, respectively. All patients received preoperative chemotherapy following the successive SIOPEL protocols. Patient and graft survival after cadaveric transplantation was 91%, 77.6% and 77.6% after 1, 5 and 10 years, respectively, without retransplantation. Patient and graft survival after living related liver transplantation was 100%, 83.3% and 83.3%, respectively. All surviving children but one remain disease-free, with a median follow up of 6.8 years (range: 0.9–14.9). There were five deaths at a median of 13 months post-OLT, secondary to tumor recurrence in 4 and respiratory failure in one. [55]

A remote data entry system is accessible online, worldwide, and free of charge. Registration is open for patients transplanted since January 1st, 2006 (<http://www.pluto.cineca.org>). PLUTO stands for Pediatric Liver Unresectable Tumor Observatory and was developed by the SIOPEL strategy group. This will allow online registration of children undergoing liver transplantation for a malignant liver tumor. The aim is to establish an international multicenter database with prospective registration of children (<18 years) presenting with unresectable tumor (HB, HCC, epithelioid hemangioendothelioma and other rare malignant tumors) undergoing primary or rescue liver transplantation.

4. Hepatocellular carcinoma

Hepatocellular carcinoma (HCC) in childhood is rare and accounts for less than 0.5% of all pediatric malignancies, [87, 88] is the second most common malignant hepatic neoplasm in children. HCC presents at an older age than does hepatoblastoma, with most HCC cases diagnosed in children older than 5 years. [89] Its relative frequency is 0.5 to 1.0 cases per million children. It is more frequently encountered in older children and teenagers than in infants. [88,90] HCC is more often encountered in males and older children between age 10 and 14 yr and the median age of onset is 12 year. [88]

Previous reports from Southeast Asia cite an annual incidence of pediatric hepatic tumors that is roughly four times higher than western reports in children with less than 15 years of

age. [91] This finding is largely based on the high hepatitis carrier rate, with a Taiwanese report stating that 80% of primary liver tumors in children were hepatocellular carcinoma. With the introduction of hepatitis B vaccine in Southeast Asia, however, there has been a marked reduction in the incidence of hepatocellular carcinoma, although the impact of the hepatitis B vaccine has mainly reduced the incidence of liver tumors in males. [92] Occasionally, malignant tumors in children are seen with features of both hepatocellular carcinoma and hepatoblastoma. These tumors are more common in children with a diagnosis at later ages than that typical of hepatoblastoma.

There is an association with pediatric HCC and pre-existing liver cirrhosis, most often because of biliary atresia, Fanconi's syndrome, and hepatitis B. However, most pediatric HCC are de novo tumors and are not necessarily related to cirrhosis. [75] In certain metabolic diseases such as hereditary tyrosinemia and glycogen storage disease type IA, there is an increased incidence of HCC. Hereditary tyrosinemia, caused by a deficiency in fumarylacetoacetate hydroxylase, results in a greatly increased susceptibility to HCC. This is because of the accumulation of toxic metabolites in the liver, and the incidence of HCC is 50% by age two. Current medical therapies for tyrosinemia markedly reduce but do not eliminate the risk of development of HCC. Glycogen storage disease type IA is caused by a deficiency in glucose- 6-phosphatase. This results in the development of hepatic adenomas in 50% of patients, and about 11% of patients with adenomas because of glycogen storage disease type IA will undergo malignant transformation into HCC. [93] Other risk factors for HCC include previous treatment with androgenic steroids, oral contraceptives and methotrexate. [94] Unlike adult HCC, pediatric HCC often demonstrate reduced levels of cyclin D1 expression. [95] Whether this is involved in the pathogenesis of pediatric HCC is still unclear. [96]

HCC is a malignancy of hepatocyte origin. The tumor is noted to have a fibrous capsule and is also predisposed to vascular invasion. [97] There are two distinct groups of HCC patients in childhood: those developing HCC in the context of advanced chronic liver disease (CLD), and children who develop sporadic HCC without preceding liver disease. The latter group typically affects older children. Their clinical behavior and biologic behavior are similar to HCC in adults. Approximately 26% of cases are histologically of a fibrolamellar type, [98] which does not appear to make a prognostic difference. Sporadic HCC in children has a relatively poor outcome, [75] while the several small series that report on HCC developing in CLD do so in the context of liver transplantation (LT) [82, 99, 100, 101, 102] The fibrolamellar subtype of HCC (FLHCC) accounts for 3% of HCCs and is not associated with underlying liver disease. FLHCC lesions are solitary, encapsulated, and well defined. Up to 75% of patients will have elevated serum AFP levels. [89, 97].

As for the pathology, HCC macroscopically are usually multifocal and invasive, commonly involving both lobes and frequently associated with vascular invasion, extrahepatic extension, or both at the time of diagnosis. Areas of hemorrhage and necrosis are common, and the lesions themselves vary in consistency from soft to firm. This significantly reduces the resectability rate. Czauderna et al report only a 36% complete tumor resection rate in a series of 39 children recorded by the International Society of Pediatric Oncology over a 4-year time period. [75] The microscopic features distinguishing hepatocellular carcinoma from hepato-

blastoma are the presence of tumor cells larger than normal hepatocytes, broad cellular trabeculae, considerable nuclear pleomorphism, nucleolar predominance, frequent tumor giant cells, and absence of hemopoiesis. [33,94] The fibrolamellar variant of HCC is probably a separate clinical entity. Histologically, the tumor cells are plump, with deeply eosinophilic cytoplasm and a marked fibrous stroma separating epithelial cells into trabeculae. [103]

HCC often present as abdominal swelling associated with dull aching pain and discomfort. Other frequent complaints are of rapid weight loss and weakness. [75] The most common clinical sign is hepatomegaly. HCC frequently presents at the time of diagnosis with metastatic spread, most commonly to the regional lymph nodes, lungs and bones. [96]

4.1. Laboratory findings

Although most children with HB have an elevated serum AFP level, this marker is elevated in 50–70% of patients with HCC and less markedly than in HB. Approximately 60–80% of HCC present with significantly elevated AFP levels. [96] All children with HCC should be screened for exposure to viral hepatitis B and C. Similar to HB, some children with HCC may be anemic and others may demonstrate thrombocytosis. Children with cirrhosis-associated HCC may present with elevated serum liver enzyme levels (AST) and those with splenomegaly may show pancytopenia. Careful assessment of hepatic functional reserve in children with cirrhosis is important prior to embarking on major hepatic resection. However, no specific data are available for children regarding tests used in adults (Iodocyanine-green (ICG) dye clearance, galactose elimination capacity). Therefore, the evaluation of the hepatic functional reserve in children is based on standard liver tests including total bilirubin, prothrombine time and INR. [55]

4.2. Imaging

The diagnostic imaging in children with HCC is not different from HB. HCC is often multifocal and may present with a variable number and distribution of tumor nodules. While identifying larger nodules is not difficult, recognizing lesions less than 1.0 cm is still a challenge. Positron emission tomography (PET) using 18- fluorodeoxyglucose may be useful in identifying unsuspected extrahepatic disease. [104]

Three-dimensional CT image analysis techniques are now available to estimate tumor volume and provide detailed intrahepatic anatomy that resembles the actual intraoperative findings. CT volumetry may permit calculation of resected tumor volume and anticipated size of the remnant liver in planning resection. [105] Diagnostic laparoscopy is useful to determine if extra- hepatic disease is present and may avoid unnecessary attempts at resection. Plain radiograph and CT of the chest should be obtained to rule out lung metastases. Hepatic arteriography is currently limited to instances of HCC managed by hepatic artery infusion or transcatheter chemoembolization which can be performed in older children. [55]

On US imaging, HCC may appear as a solitary or multicentric mass most commonly involving the right lobe of the liver, or as a diffusely infiltrating lesion. At diagnosis, these masses appear solid, rarely contain calcification, and have variable echogenicity. Small lesions ap-

pear homogeneous and are most often hypoechoic. The capsule can be seen as a hypoechoic halo. Larger lesions become necrotic, and therefore demonstrate a more heterogeneous appearance. Doppler US may detect the high-velocity flow that is related to neovascularity, but Doppler US is most useful for identifying venous invasion. Portal venous invasion is identified in up to 60% of cases, [106] with hepatic venous invasion identified less commonly. Doppler US may differentiate neoplastic thrombus from bland (benign) thrombus by detecting internal neovascularity in the former. [97]

Potentially curative therapies can treat the very early and early stages of the disease. However, less than 30% of HCC patients are detected with the disease in those stages. [107] Another 20% of patients with terminal stage HCC receive recommendations for the best supportive treatment. Since HCC is unresectable in the majority of patients at the time of the first diagnosis, patients are often directed to nonsurgical treatments. Physicians have long overlooked radiotherapy (RT) for HCC as radiation might induce fatal hepatic toxicity at doses lower than the therapeutic doses. [108] However, such limitation has been overcome by recent developments in RT technology involving precise delivery of focused high-dose on partial volume of the liver. [109, 110, 111, 112, 113, 114] According to the Korean Liver Cancer Study Group (KLCSG) practice guidelines, RT is considered appropriate for unresectable, locally advanced HCC without extrahepatic metastasis, Child-Pugh class A or B, and tumors occupying less than two-thirds of the liver. [115]

4.3. Results of resection

Based on recent experience, the optimal treatment should have been total hepatectomy and liver transplantation. Katzenstein et al. reported on 46 children enrolled in the POG and CCG studies - 8 with stage I, 25 with stage III, 13 with stage IV. [49] The overall event-free survival at 5 years was 17%. The outcome was not more favorable in 10 children with FL-HCC. No difference in survival was observed whatever the chemotherapy regimen was given. 369 The German Cooperative Liver Study Group [116] reported the results of two prospective trials. The survival rate of HCC was 33% and 25% in HB-89 (12 patients – 1989–1993) and 25% in HB-94 (25 patients – 1994–1998), respectively. The SIOPEL-1 study (1990–1994) enrolled 39 patients with HCC who were treated with neoadjuvant chemotherapy (PLADO). Thirty-one percent had metastases, 39% had extrahepatic extension/vascular invasion, 56% had multifocal HCC while 31% had pre-existing liver disease. A partial response to PLADO was observed in 49%, a complete tumor resection was possible in 36% (2 with liver transplantation). The 5-year event-free survival was 17%. Adverse prognostic factors included multifocality, metastases and vascular invasion. In SIOPEL-2 pilot study (1994–1998), 21 patients were treated with “super-PLADO” (carboplatin, cisplatin and doxorubicine). Eighteen percent had metastases, 35% had extrahepatic extension/vascular invasion and 53% had multifocal HCC. Partial response to SUPER-PLADO was observed in 46%; complete tumor resection was performed in 47% (one with liver transplantation). The 3-year overall survival was 22%. In SIOPEL-3 (1999–2004), 65 patients were treated with SUPER-PLADO with a partial response in 40%. Thirteen underwent primary surgery. Forty-four percent were never resectable. The 3-year event-free survival was 10%. Currently, the new

SIOPEL-5 study is evaluating non-cirrhotic HCC patients staged according to the PRETEXT system and receiving neoadjuvant PLADO chemotherapy and thalidomide (an anti-angiogenic agent) followed by surgery and postoperative metronomic chemotherapy.

4.4. Liver transplantation for hepatocellular carcinoma

Experience with liver transplantation in children with unresectable HCC is somewhat limited but results have significantly improved over the recent years. Beaunoyer et al. reported on 10 children with underlying liver disease in 5 and cirrhosis in 5. Six had one nodule >5 cm and 7 had >3 nodules. The 5-year actuarial survival was 83%; two died, one of recurrence, while 2 with macrovascular invasion survived. Number and size of lesions or gross vascular invasion did not significantly impact survival. [82] Reyes et al. reported on 19 children with HCC who underwent total hepatectomy and liver transplantation in 1989–1998; two thirds had underlying liver disease. [80] The 5-year disease-free survival was 63% (3/6 died of recurrent HCC). In their experience, risk factors for recurrence were tumor size, vascular invasion and lymphnode involvement. [80] Austin et al. analyzed the aggregated outcome for OLT in HCC in 41 children <18 years (UNOS data). Patient survival was 63% at 5 year and 58% at 10 year. Recurrence was the primary cause of death in 86%. [78]

The most conventional criteria for transplantation are the so-called Milan criteria: [117] no more than three tumors, each not more than 3 cm in size, or a single tumor, not more than 5 cm in diameter, and no evidence of extrahepatic disease or vascular invasion. Recent studies suggest that, in an otherwise normal liver, the present cut-off for tumor size might be expanded to 6.5 cm or 7 cm. [118, 119] The evidence supports the moderate expansion of the Milan criteria although findings from different studies lack consistency and prospective validation by pretransplant imaging. [79] There are no hard data implying that Milan criteria can appropriately select children with a low risk of recurrence of HCC after transplantation. Indeed, Milan criteria are derived from experience in adults with cirrhosis, whereas the majority of children with HCC have no underlying cirrhosis. There is no prospective trial in children while the role of OLT in non-cirrhotic liver is unknown. Moreover, there are differences in biology [120] between adult and pediatric HCC with different molecular findings: mutation of c- met gene in children with HCC, not in adults, level of glycine D1 (regulatory protein of G1 phase cycle) expression is lower in children, loss of heterozygosity on chromosomal arm, 13q, higher in children. There is evidence that childhood HCC might be less chemoresistant than adult HCC; a partial response was observed in 49% enrolled in SIOPEL-1 study. [75] The SIOPEL group has launched in 2005 a new SIOPEL-5 trial directed to non-cirrhotic hepatocellular carcinoma in children and adolescents. It is based on the hypothesis that the addition of an antiangiogenic drug (Thalidomide) to PLADO will result in an improvement of survival with acceptable toxicity. Most likely, Sorafenib will be substituted for Thalidomide on the basis of data obtained in adults with advanced HCC. [121]

Patients with unresectable disease restricted to the liver will be submitted to liver transplantation. Since the majority of children with HCC in western countries have no underlying liver disease, recent data suggest that liver transplantation may be quite useful treatment in carefully selected unresectable cases. [78, 80, 82] Unlike the adult population, the frequency

of HCC in the pediatric population is low; therefore, the experience in the application of liver transplantation in the pediatric population for HCC is limited. [122, 123, 124, 125] In patients whose disease is confined to the liver, the use of liver transplantation is indicated. Because chemotherapy is not beneficial at present in this group, results in patients with more extensive disease are poor. [126]

5. Benign tumors

In general, benign tumors of the liver may arise from hepatocytes, bile duct epithelium, the supporting mesenchymal tissue, or a combination of two or more of these. In addition to true neoplastic conditions of the liver, a variety of nodular diseases may occur that resemble, and must therefore be differentiated from, tumours. Although most patients with benign hepatic tumors are asymptomatic, a minority may present with symptoms that may be local or systemic. In these patients, the relationship between the symptoms and the hepatic lesions may be difficult to correlate, and additional evaluation is necessary to rule out other causes for the patients complaints. In most cases patients with benign hepatic lesions have no preexisting liver disease, and the finding of a coexisting chronic liver disease such as cirrhosis, chronic hepatitis B or C, or hemochromatosis should raise a suspicion for a malignant tumor. A conclusive diagnosis of a focal hepatic lesion is essential because it may represent a primary or secondary malignancy, which may require immediate treatment. In addition, some benign lesions carry specific risks such as rupture, bleeding, malignant transformation, consumptive coagulopathy, and disseminated intravascular coagulation. [127]

Primary liver masses constitute the third most common group of solid abdominal tumors of childhood, [2, 128, 129] with an incidence of 0.4 to 1.9 per million children each year. [129, 130] Benign primary liver masses described in children include hemangioma/infantile hepatic hemangioendothelioma, focal nodular hyperplasia, simple hepatic cysts, mesenchymal hamartomas, adenomas, nodular regenerative hyperplasia, hematomas, arterial venous malformations, granulomas, and lymphangiomas. [2, 12, 128, 129, 130, 131, 132, 133]

Infantile hepatic hemangioendothelioma is a tumor derived from vascular endothelial cells, which is the most diagnosed benign hepatic tumor in children. Hence it accounts for approximately 12% of all childhood hepatic tumors, the most common benign vascular tumor of the liver in infancy, and the most common symptomatic liver tumor during the first 6 months of life. [134, 135, 136, 137]

While the majority of benign masses may be of little consequence, morbidity and mortality can occur from benign masses, mass effect from a tumor can cause pain, biliary obstruction and inferior vena cava obstruction, limit lung capacity, or cause feeding difficulty. [2, 12, 129, 138] Most of the recent radiology literature concerning the liver has focused on lesions detection or identification of specific features (enhancement patterns) that may help distinguish benign from malignant hepatic tumours. Except for hemangioma and focal nodular hyperplasia (FNH), little is know about imaging characteristics that can help identify and distinguish among the many less common bening liver masses. [139]

5.1. Infantile hepatic hemangioendothelioma

More than 90% are diagnosed before the age of 6 years. The typical presentation is of hepatomegaly, hemangiomas of the skin, and heart failure resulting from massive arteriovenous shunting. [127, 140] In addition to heart failure, this tumor may cause consumption coagulopathy (Kasabach–Merritt syndrome) and obstructive jaundice. [127, 141] Although well circumscribed, this tumor is not encapsulated and often has scattered calcifications. Microscopically, this tumor consists of multiple small vessels lined by plump endothelial cells and surrounded by fibrous stroma.

Ultrasonography usually shows hepatomegaly and solitary or multiple hepatic lesions, which may vary from anechoic to hyperechoic. The unenhanced CT scan demonstrates the lesion as a well-defined hypo-attenuating mass, occasionally with calcifications. After contrast injection, the lesion may show enhancement resembling hemangioma and may become isodense on delayed images. Angiography shows dilated, irregular vascular lakes that commonly persist beyond the venous phase. ^{99m}Tc-sulfur colloid scintigraphy shows the lesion as a cold spot because of a lack of Kupffer cells within the tumor. [127]

The prognosis of this lesion is dependent on its size and its effect on the heart function. Spontaneous regression is frequent but death may occur within the first 6 months of life because of cardiac failure or replacement of the normal hepatic parenchyma. [127, 142] The prognosis is usually good if heart failure is managed successfully.

Treatment is dictated by tumor-related symptoms produced by tumor size. Management of congestive heart failure may be sufficient in some cases. If symptoms are not relieved, treatment should be aimed at decreasing the tumor size. [127]

Other treatments include hepatic artery ligation, transcatheter endovascular embolization, and radiation therapy. [127, 143, 144] Liver transplant is increasingly recognized as a viable treatment modality for infantile hemangioendothelioma when other treatments fail. [127, 145]

5.2. Focal Nodular Hyperplasia (FNH)

FNH is very rare in pediatric population with an age prevalence in children 7-8 years old, although some cases are diagnosed in early childhood or even in the prenatal period. [146, 147] The female sex is predominant with a M/F ratio of less than 1/10 in one of the largest series. [147, 148]

The majority (70-90%) of FNH at presentation is asymptomatic and the most common way that the disease is discovered is when, during an occasional physical examination, hepatomegaly or a palpatory abdominal mass are detected. The lesion is more often unique, but about 8% of cases may show multiple nodules, up to 30. The diameter of lesions is extremely variable, from less than 1 cm to more than 15 cm but usually is less than 5 cm. [147]

The diagnosis in the majority of cases could be by Ultrasound, CT Scan and MRI. Needle biopsy or open air biopsy are necessary when the radiological investigations are doubtful, above all in case of absence of the central scar, and not rarely the differential diagnosis from

other nodular lesions of liver may be difficult. The differential diagnosis includes different nodular lesions of the liver. [147]

The natural evolution of FNH is unpredictable. In about 2/3 of cases, remain stable and in about 1/3-1/4 of cases show a gradual spontaneous improvement as far as a complete remission. In rare instances an increase in number as well as in size may occur [9]. The recent studies in molecular biology have confirmed that FNH is not a pre-neoplastic lesion: the tissue parenchymal organization is pretty the same of usual liver tissue and, moreover, even though in some cases a clonal origin of FNH nodules have been demonstrated, until now no somatic mutation in the β -catenin gene or in the other genes implicated in the hepatocellular adenoma (where a malignant transformation is possible) have been discovered. [147, 149, 150]

About the management the first step is, of course, the stop of oral contraceptive. Considering the body of evidence that FNH doesn't undergo malignant transformation and that there are only sporadic cases followed by spontaneous rupture and consequent abdominal bleeding, we agree with the opinion that in asymptomatic cases it is opportune a careful follow-up with an ultrasound scan every 6-12 months, and that elective surgery has probably to be limited to the patients suffering of abdominal pain or with a voluminous or growing mass. [147, 149]

5.3. Nodular regenerative Hyperplasia (NRH)

Nodular regenerative hyperplasia (NRH) is a disease characterized by multiple nodules composed by hepatocytes, without a fibrous tissue or central scar. The rare pediatric cases are mostly in association with the congenital absence of portal vein (sometimes complicated by heart disease or multi-cystic kidney dysplasia). Indeed, only about 200 cases have been reported. Symptoms, when present, are mainly associated with the complication of portal hypertension. [151, 152, 153, 154]

CT presentation is really different from FNH, as there are multiple hypodense lesions with poor or absent enhancement after contrast administration. [147, 155] The typical imaging showing anechoic and regular profile of the mass at ultrasound, easily recognize cystic lesions: however CT and MRI may be necessary in selected cases. [147]

5.4. Hamartomas

Mesenchymal hamartoma is a rare, benign, developmental tumor of the liver, with occasional risk of malignancy. Histologically, it appears as a disordered arrangement of the mesenchyme, bile ducts, and hepatic parenchyma. Cords of normal appearing hepatocytes are separated by zones of loose, poorly cellular mesenchyme. The porous nature of the mesenchyme permits accumulation of fluid. [156, 157] Grossly, it has stromal and cystic components with no capsules, and can grow to large sizes. [157, 158] The typical presentation is one of asymptomatic, rapid abdominal distention with a palpable mass on physical examination. The rapid expansion of the tumor is believed to be due to degeneration of the mesenchyme and fluid accumulation. Other uncommon associated symptoms are vomiting, fever, constipation, diarrhea, and weight loss. [156, 157] Laboratory investigations usually reveal normal liver function with elevated alpha-fetoprotein, which is believed to be secreted by

the proliferating hepatocytes within the tumor. [157, 159] The radiological appearance is one of a large, uni or multi-cystic, avascular mass occupying part of the liver. [157, 158] Surgical resection has been the standard treatment for this tumor.

6. Sarcoma

The third most common hepatic malignancy, after hepatoblastoma and hepatocellular carcinoma, is undifferentiated embryonal sarcoma. [8, 160, 161] It is believed to be a primitive mesenchymal neoplasm, which usually behaves in a highly malignant fashion. [162] It was first recognized as a clinicopathologic entity by Stocker and Ishak in 1978. [156] Before their report, this tumor had been described under different names such as embryonal sarcoma [163] mesenchymoma, [164] primary sarcoma [165] or fibromyxosarcoma. [166]

These tumors occur in children 5–10 years of age and are mesenchymal in appearance. [8, 167] Diagnosis of primary hepatic sarcoma is challenging due to the lack of specific presenting symptoms, lack of serological markers, non-specific findings on radiological imaging and the rarity of the disease. [86] However, leukocytosis and elevated aspartate aminotransferase and alkaline phosphatase are not uncommon laboratory findings. [156, 161, 162, 168, 169] The serum α -fetoprotein level is always normal. [156, 161, 162, 169] There is no correlation with hepatitis B or C virus infection. Most tumors have prominent areas of cystic degeneration. [161, 162] Multinucleated giant tumor cells with eosinophilic cytoplasm and frequent mitosis are usually present. (Stocker and Ishak, 1978 and [162] et al., 2001) PAS-positive, diastase-resistant hyaline globules, which are believed to be lysosomes or apoptotic bodies, are frequently seen within tumor cells as well as in extracellular stromata. [156, 162, 168, 170, 171]

Regarding the radiological imaging, undifferentiated embryonal sarcoma often show a misleading cystic appearance on CT and magnetic resonance imaging (MRI) in contrast to a predominantly solid appearance on ultrasound. [86, 172]

Undifferentiated embryonal sarcoma of the liver behaves in a highly malignant fashion, [162, 173] and the median survival has been less than a year. [156, 162] Complete surgical resection is the key to a favorable outcome. However, despite apparent complete resectability in some cases, local recurrence and distant metastases have been major impediments to achieving long-term disease-free survival. [162, 173] Multidisciplinary treatment (chemotherapy and radiotherapy) has been used to achieve superior and local control and disease-free survival in patients with Undifferentiated embryonal sarcoma of the liver. [160, 167, 173]

Author details

Julio C. Wiederkehr^{1,2*}, Izabel M. Coelho^{1,2}, Sylvio G. Avilla^{1,2}, Barbara A. Wiederkehr² and Henrique A. Wiederkehr²

*Address all correspondence to: julio.wieder@uol.com.br

1 Federal University of Paraná, Curitiba, Brazil

2 Hospital Pequeno Príncipe, Curitiba, Brazil

References

- [1] Kim, E. H., Koh, K. N, Park, M, Kim, B. E, Im, H. J, & Seo, J. J. (2011). Clinical features of infantile hepatic hemangioendothelioma. *Korean Journal of Pediatrics*, 54(6), 260, doi:10.3345/kjp.2011.54.6.260.
- [2] Luks, F. I., Yazbeck, S., Brandt, M. L., et al. (1991). Benign liver tumors in children: a 25- year experience. *J Pediatr Surg*, 26, 1326-30.
- [3] Reymond, D., Plaschkes, J., Luthy, A. R., et al. (1995). Focal nodular hyperplasia of the liver in children: review of follow-up and outcome. *J Pediatr Surg*, 30, 1590-3.
- [4] Ehren, H., Mahour, G. H., & Isaacs, H., Jr. (1983). Benign liver tumors in infancy and childhood. Report of 48 cases. *Am J Surg*, 145, 325-9.
- [5] Emre, S., & Mc Kenna, G. J. (2004). Liver tumors in children. *Pediatric transplantation*, 8(6), 632-8.
- [6] Weinberg, AG, & Finegold, MJ. (1983). Primary hepatic tumors of childhood. *Hum Pathology*, 14, 512-537.
- [7] Multerys, M., Goodman, M. T., Smith, MA, et al. (1999). Hepatic Tumors. In Ries LAG, SmithMA,GurneyJGet al. (eds). *Cancer Incidence, SurvivalamongChildren, Adolescents: United States SEER Program 1975-1995. SEER Program, NIH Pub.* [99-4649], Bethesda, MD, National Cancer Institute, 91-97.
- [8] Litten, J. B., & Tomlinson, G. E. (2008). Liver tumors in children. *The oncologist*, 13(7), 812-20.
- [9] Dimmick, J. E., Rogers, P. C. J., & Blair, G. (1994). Hepatic Tumors. In: *Pochedly C, ed. Neoplastic Siseases of Childhood*, Chur, Switzerland, Harwood Academic, 973-1010.
- [10] Kelly, D. (2008). *Diseases of the Liver and Biliary System in Children ed.*, Wiley-Blackwell, Oxford.
- [11] Kenney, LB, Miller, B. A., Ries, L. A., et al. (1998). Incidence of cancer in infants in the U.S.: 1980-1990. *Cancer*, 82, 1396-1400.
- [12] Meyers, R. L. (2007). Tumors of the liver in children. *Surgical oncology*, 16(3), 195-203.
- [13] Mann, J. R., Kasthuri, N., Raafat, F., et al. (1990). Malignant hepatic tumours in children: incidence, clinical features and aetiology. *Paediatr Perinat Epidemiol*, 4, 276-289.

- [14] Bulterys, M., Goodman, M. T., Smith, M. A., et al. (1999). Cancer Incidence and Survival Among Children and Adolescents: United States SEER Program 1975-1995. *National Cancer Institute SEER Program. NIH Publication* [99-4649], 91-97.
- [15] Owe, T., Kubota, A., Okuyama, H., et al. (2003). Hepatoblastoma in children of extremely low birth weight: a report from a single prenatal center. *Journal of Pediatric Surgery*, 38, 134-7.
- [16] Honda, S., Haruta, M., Sugawara, W., et al. (2008). The methylation status of RASSF1A promoter predicts responsiveness to chemotherapy and eventual cure in hepatoblastoma patients. *Int J Cancer*, 5, 1117-25.
- [17] Sakamoto, L. H., De Camargo, B., Cajaiba, M., et al. (2010). MT1G hypermethylation: a potential prognostic marker for hepatoblastoma. *Pediatr Res*, 67, 387-93.
- [18] Exelby, P. R., Filler, R. M., & Grosfeld, J. L. (1975). Liver tumors in children in the particular reference to hepatoblastoma and hepatocellular carcinoma: American Academy of pediatrics surgical section survey- 1974. *Journal of pediatric surgery*, Saunders, Retrieved from, <http://linkinghub.elsevier.com/retrieve/pii/0022346875900950?showall=true>.
- [19] DeBaun, M. R., & Tucker, M. A. (1998). Risk of cancer during the first four years of life in children from the Beckwith-Wiedemann Syndrome Registry. *J Pediatr*, 132, 398-400.
- [20] Steenman, M., Westerfeld, A., & Mannens, M. (2000). Genetics of Beckwith-Weidemann Syndrome associated tumours: common genetic pathways. *Genes Chromosomes Cancer*, 28, 1-13.
- [21] Giardello, F. M., Offerhaus, G. J., Krush, A. J., et al. (1991). Risk of hepatoblastoma in familial adenomatous polyposis. *J Pediatr*, 119, 766-768.
- [22] Aretz, S., Koch, A., Uhlhaas, S., et al. (2006). *Pediatric Blood Cancer*, 47, 811-8.
- [23] Hirschman, B. A., Pollock, B. H., & Tomlinson, G. E. (2005). The spectrum of APC mutations in children with hepatoblastoma from familial adenomatous polyposis kindreds. *Journal of Pediatrics*, 147, 263-6.
- [24] Wei, Y., Fabre, H., Branchereau, S., et al. (2000). Activation of B-catenin in epithelial and mesenchymal hepatoblastomas. *Oncogene*, 19, 498-506.
- [25] Jeng, Y. M., Wu, M. Z., Chang, M. H., et al. (2000). Somatic mutations of B-catenin play a crucial role in the tumorigenesis of sporadic hepatoblastoma. *Cancer*, 152, 45-5.
- [26] Udatsu, Y., Kusafuka, T., Kuroda, S., et al. (2001). High frequency of beta catenin mutations in hepatoblastoma. *Pediatr Surg Int*, 17, 508-512.
- [27] Tomlinson, G. E., Douglass, E. C., Pollock, B. H., et al. (2006). Cytogenetic analysis of a large series of hepatoblastoma: numerical aberrations with recurring translocations involving 1q12-21. *Genes Chromosomes Cancer*, 44, 177-84.

- [28] Ruck, P., Xiao, J. C., Pietsch, T., et al. (1997). Hepatic stem-like cells in hepatoblastoma: Expression of cytokeratin 7, albumin and oval cell associated antigens detected by OV-1 and OV-. *Histopathology*, 31, 324-329.
- [29] Ruck, P., & Xiao, J. C. (2002). Stem-like cells in hepatoblastoma. *Med Pediatr Oncol*, 39, 504-507.
- [30] Stocken, J. T. (1994). Hepatoblastoma. *Semin Diagn Pathol*, 11, 136-143.
- [31] Malogolowkin, M. H., Katzenstein, H. M., Krailo, M., et al. (2006). Intensified platinum therapy is an ineffective strategy for improving outcome in pediatric patients with advanced hepatoblastoma. *Journal of Clinical Oncology*, 24, 2879-84.
- [32] Haas, J. E., Feusner, J. H., & Finegold, M. J. (2001). Small cell undifferentiated histology in hepatoblastoma may be unfavorable. *Cancer*, 92, 3130-4.
- [33] Hass, J. E., Mczynski, K. A., Krailo, M., et al. (1989). Histopathology and prognosis in childhood hepatoblastoma and hepatocellular carcinoma. *Cancer*, 64, 1082-1095.
- [34] Perilongo, G., & Shafford, E. A. (1999). Liver tumours. *Eur J Cancer*, 19, 953-958.
- [35] Teng, C. T., Daeschner, C. W., Jr., Singleton, E. B., Rosenberg, H. S., Cole, V. W., Hill, L. L., & Brennan, J. C. (1961). Liver disease and osteoporosis in children. I. Clinical observations. *Journal of Pediatrics*, 59, 684-702.
- [36] Van Tornout, J. M., Buckley, J. D., Quinn, J. J., et al. (1997). Timing and magnitude of decline in alpha-fetoprotein levels in tested children with unresectable or metastatic hepatoblastoma are predictors of outcome: a report from the Children's Cancer Group. *J Clin Oncol*, 15, 1190-1197.
- [37] Hartley, A. L., Birch, J. M., Kelsey, A. M., et al. (1990). Epidemiological and familial aspects of hepatoblastoma. *Med Pediatr Oncol*, 18, 103-119.
- [38] Feusner, J. R., Krailo, M. A., Hass, J. E., et al. (1993). Treatment of pulmonary metastasis of initial stage I hepatoblastoma in childhood: report from the children's cancer group. *Cancer*, 71, 859-864.
- [39] Lack, E. E., Neave, C., & Vawter, G. F. (1982). Hepatoblastoma- A clinical and pathologic study of 54 cases. *Am J Surg Pathol*, 6, 693-705.
- [40] Nickerson, H. J., Silberman, T. L., & McDonald, T. P. (1980). Hepatoblastoma, thrombocytosis and increased thrombopoietin. *Cancer*, 315-7.
- [41] Meyers, R. L., Katzenstein, H. M., Rowland, J. H., et al. (2008). PRETEXT and other prognostic factors in hepatoblastoma. *Pediatric Blood Cancer*.
- [42] Perilongo, G. (2006). State of the art: Treatment of childhood liver tumors. Geneva, Switzerland. In: *38th annual meeting of SIOP*.
- [43] Roebuck, D. J., Olsen, O., & Pariente, D. (2006). Radiological staging in children with hepatoblastoma. *Pediatr Radiol*, 36, 176-82.

- [44] Roebuck, D. (2008). Focal liver lesion in children. *Pediatr Radiol*, 38(3), 518-22.
- [45] De Campo, M., & De Campo, J. F. (1988). Ultrasound of primary hepatic tumors in childhood. *Pediatric Radiol*, 19, 19-24.
- [46] Helmberger, J. R., Ros, P. R., Medgo, P. J., et al. (1999). Pediatric liver neoplasms: a radiology-pathological correlation. *Eur Radiol*, 9, 1339-1347.
- [47] Von Schweinitz, D., Burger, D., Weiner, P., et al. (1992). Therapy of malignant liver tumors in childhood. An intermittent report of the HB-89 multicenter. *Clin Pediatr*, 204, 214-220.
- [48] Katzenstein, H. M., Krailo, M., Malogolowkin, M. H., et al. (2007, February). Biology and treatment of children with all stages of hepatoblastoma: COG proposal AHEP-0731. *submitted to CTEP and NCI*.
- [49] Katzenstein, H. M., Krailo, M., Malogolowkin, M. H., et al. (2002). Hepatocellular carcinoma in children and adolescents: results from the Pediatric Oncology Group and the Children's Cancer Group intergroup study. *J Clin Oncol*, 20(12), 2789-97.
- [50] Aronson, D. C., Schnater, J. M., Staalman, C. R., et al. (2005). Predictive value of pre-treatment extent of disease system in hepatoblastoma: Results from the International Society of Pediatric Oncology Liver Tumor Study Group SIOPEL-1 study. *J Clin Oncol*, 23, 1245-1262.
- [51] Meyers, R. L., Rowland, J. R., Krailo, M., et al. (2009). Predictive power of pretreatment prognostic factors in children with hepatoblastoma: a report from the Children's Oncology Group. *Pediatr Blood Cancer*, 53(6), 1016-22.
- [52] Douglass, E. C., Reynolds, M., Finegold, M., et al. (1993). Cisplatin, vincristine, and fluorouracil therapy for hepatoblastoma: a Pediatric Oncology Group study. *J Clin Oncol*, 11(1), 96-9.
- [53] Brown, J., Perilongo, G., Shafford, E., et al. (2000). Pretreatment prognostic factors for children with hepatoblastoma-- results from the International Society of Paediatric Oncology (SIOP) study SIOPEL 1. *Eur J Cancer*, 36(11), 1418-25.
- [54] <http://www.cancer.gov/PublishedContent/MediaLinks/308970.html>.
- [55] Otte, J. B. (2010). Progress in the surgical treatment of malignant liver tumors in children. *Cancer treatment reviews*, 36(4), 360-71, Elsevier Ltd.
- [56] Czauderna, P., Otte, J. B., Aronson, D. C., et al. (2005). Guidelines for surgical treatment of hepatoblastoma in the modern era : recommendations from the childhood liver tumour strategy group of the international society of paediatric oncology (SIOPEL). *European Journal of Cancer*, 41, 1031-6.
- [57] Stringer, M. (2006). Liver tumors. *Semin Pediatr Surg*, 9, 196-208.
- [58] Fuchs, J., Rydzynski, J., Hecker, H., et al. (2002). The influence of preoperative chemotherapy and surgical technique in the treatment of hepatoblastoma-a report from

the German cooperative liver tumours studies HB-89 and HB-94. *Eur J Pediatr Surg*, 12, 255-61.

- [59] Von Schweinitz, D., Faundez, A., Teichmann, B., et al. (2000). Hepatocyte growth-factor- scatter-factor can stimulate postoperative tumor-cell proliferation in childhood hepatoblastoma. *Int J Cancer*, 85, 151-9.
- [60] Ortega, J. A., Douglass, E. C., Feusner, J. H., et al. (2000). Randomized comparison of cisplatin/vincristin/5-fluorouracil and cisplatin/doxorubicin for the treatment of pediatric hepatoblastoma (HB): a report from the Children's cancer group and the pediatric oncology group. *Journal of Clinical Oncology*, 18, 2665-75.
- [61] Schnater, J. M., Aronson, D. C., Plaschkes, J., et al. (2002). Surgical view of the treatment of patients with hepatoblastoma. *Cancer*, 94, 1111-20.
- [62] Malogolowkin, M. H., Katzenstein, H. M., Krailo, M., et al. Redefining the role of doxorubicin for the treatment of children with hepatoblastoma. *Journal of Clinical Oncology*.
- [63] Von Schweinitz, D., & Haberle, B. (2007, March). German liver tumor study: HB 99. Poland, Gdansk. In: *First international symposium childhood hepatoblastoma*.
- [64] Von Schweinitz, D., Hecker, H., Harms, D., et al. (1995). Complete resection before development of drug resistance is essential for survival from advanced hepatoblastoma-a report fro the German cooperative pediatric liver tumor study HB-89. *Journal of Pediatric Surgery*, 30, 845-52.
- [65] Ortega, J. A., Douglass, E., Feusner, J., et al. (1994). A randomized trial of cisplatin/vincristine/5-fluorouracil vs. CCP/doxorubicin continuous infusion for the treatment of hepatoblastoma: results from the pediatric inter-group hepatoma study (abstr). *Proc Am Soc Clin Oncol (ASCO)*, 13, 416.
- [66] Pritchard, J., Brown, J., Shafford, E., et al. (2000). Cisplatin, doxorubicin and delayed surgery for childhood hepatoblastoma: a successful approach-results of the first prospective study of the International Society of Pediatric Oncology. *J Clin Oncol*, 18, 3819-28.
- [67] Perilongo, G., Shafford, E., Maibach, R., et al. (2004). Risk-adapted treatment for childhood hepatoblastoma Final report of the second study of the International Society of Pediatric Oncology- SIOPEL 2. *Eur J Cancer*, 40, 411-21.
- [68] Meyers, R. L., Malogolowkin, M. H., Rowland, J. M., & Krailo, M. (2006, May 27). Predictive value of the PRETEXT staging system in children with hepatoblastoma. In: *Presented at the 37th annual meeting American Pediatric Surgical Association, Hilton Head, SC*.
- [69] Dall'Igna, P., Cecchetto, G., Toffolutti, T., et al. (2003). Multifocal hepatoblastoma is there a place for partial hepatectomy? *Med Pediatr Oncol*, 40, 113-6.
- [70] Couinaud, C. (1992). The anatomy of the liver. *Ann Ital Chir*, 63, 693-7.

- [71] Wheatley, J. M., Rosenfield, N. S., Berger, L., & La Quaglia, M. P. (1996). Liver regeneration in children after major hepatectomy for malignancy-evaluation using a computer-aided technique of volume measurement. *J Surg Res*, 61, 183-9.
- [72] Von Schweinitz, D. (2006). Management of liver tumors in childhood. *Semin Pediatr Surg*, 15, 17-24.
- [73] Otte, J. B., & De Ville de Goyet, J. (2005). The contribution of transplantation to the treatment of liver tumors in children. *Semin Pediatr Surg*, 14, 233-8.
- [74] Chardot, C., Sant Martin, C., Gilles, A., et al. (2002). Living related liver transplantation and vena cava reconstruction after total hepatectomy including the vena cava for hepatoblastoma. *Transplantation*, 73, 90-2.
- [75] Czauderna, P., Mac Kinley, G., Perilongo, G., et al. (2002). Hepatocellular carcinoma in children: results of the first prospective study of the international society of pediatric oncology group. *Journal of Clinical Oncology*, 20, 2798-804.
- [76] Millar, A. J. W., Hartley, P., Khan, D., et al. (2001). Extended hepatic resection with transplantation back-up for an unresectable tumor. *Pediatric Surgery International*, 17, 378-81.
- [77] Otte, J. B., Pritchard, J., Aronson, D. C., et al. (2004). Liver transplantation for hepatoblastoma: Results from the International Society of Pediatric Oncology (SIOP) study SIOPEL-1 and review of the world experience. *Pediatr Blood Cancer*, 42, 74-83.
- [78] Austin, M. T., Leys, C. M., Feurer, I. D., et al. (2006). Liver transplantation for childhood hepatic malignancy: a review of the United Network for Organ Sharing (UNOS) database. *J Pediatr Surg*, 41, 182-6.
- [79] Hoti, E., & Adam, R. (2008). Liver transplantation for primary and metastatic liver cancers. *Transplant Int*, 21, 1107-17.
- [80] Reyes, J. D., Carr, B., Dvorchik, I., et al. (2000). Liver transplantation and chemotherapy for hepatoblastoma and hepatocellular cancer in childhood and adolescence. *J Pediatr*, 136(6), 795-804.
- [81] Perilongo, G., Brown, J., Shafford, E., et al. (2000). Hepatoblastoma presenting with lung metastases: treatment results of the first cooperative, prospective study of the International Society of Pediatric Oncology on childhood liver tumors. *Cancer*, 89, 1845-53.
- [82] Beaunoyer, M., Vanatta, J. M., Ogihara, M., et al. (2007). Outcomes of transplantation in children with primary hepatic malignancy. *Pediatr Transplant*, 11(6), 655-60.
- [83] Pimpalwar, A. P., Sharif, K., Ramani, P., et al. (2002). Strategy for hepatoblastoma management: transplant versus nontransplant surgery. *J Pediatr Surg*, 37, 240-5.
- [84] Tiao, G. M., Bobey, N., Allen, S., et al. (2005). The current management of hepatoblastoma: a combination of chemotherapy, conventional resection, and liver transplantation. *J Pediatr*, 146, 204-11.

- [85] Molmenti, E. P., Wilkinson, K., Molmenti, H., et al. (2002). Treatment of unresectable hepatoblastoma with liver transplantation in the pediatric population. *Am J Transplant*, 6, 535-8.
- [86] Faraj, W., Mukherji, D., El Majzoub, N., Shamseddine, A., Shamseddine, A., & Khalife, M. (2010). Primary undifferentiated embryonal sarcoma of the liver mistaken for hydatid disease. *World journal of surgical oncology*, 8(58).
- [87] Moore, S. W., Hesselning, P. B., Wessels, G., et al. (1997). Hepatocellular carcinoma in children. *Pediatr Surg Int*, 12, 266-70 .
- [88] Bellani, F. F., & Massimino, M. (1993). Liver tumors in childhood: Epidemiology and clinics. *J Surg Oncol*, 3, 119-121.
- [89] Dubois, J., Garel, L., Russo, P., et al. (1993). Pediatric case of the day. *Radiographics*, 13, 691-2.
- [90] Parkin, D. M., Stiller, C. A., Draper, G. J., et al. (1988). The international incidence of childhood cancer. *Int J Cancer*, 42, 511-520.
- [91] Chen, J. C., Chang, M. L., Lin, J. N., et al. (2005). Comparison of childhood hepatic malignancies in a hepatitis B hyper-endemic area. *World J Gastroenterol*, 11, 5289-5294.
- [92] Chang, M. L., Chen, J. C., Lai, M. S., et al. (1997). Universal hepatitis B vaccination in Taiwan and the incidence of hepatocellular carcinoma in children. Taiwan Childhood Hepatoma Study Group. *N Engl J Med*, 336, 1855-1859.
- [93] Howell, R. R., Stevenson, R. E., Ben-Menachem, Y., et al. (1976). Hepatic adenoma in type I glycogen storage disease. *JAMA*, 236, 1481-1489.
- [94] Weinberg, A. G., & Finegold, M. J. (1983). Primary Hepatic Tumor of Childhood. *Hum Pathol*, 14, 512-537.
- [95] Kim, H., Lee, M. J., Kim, M. R., et al. (2000). Expression of cyclin D1, cyclin E, cdk4 and loss of heterozygosity of 8p13q 17p in hepatocellular carcinoma. *Comparison study of childhood and adult hepatocellular carcinoma. Liver*, 20, 173-178.
- [96] Emre, S., & McKenna, G. J. (2004). Liver tumors in children. *Pediatric transplantation*, 8(6), 632-8.
- [97] Varich, L. (2010). Ultrasound of Pediatric Liver Masses. *Ultrasound Clinics*, 5(1), 137-152, Elsevier Ltd.
- [98] Katzenstein, H. M., Krailo, M. D., Malogolowkin, M. H., et al. (2003). Fibrolamellar hepatocellular carcinoma in children and adolescents. *Cancer*.
- [99] Arikan, C., Kilic, M., Nart, D., et al. (2006). Hepatocellular carcinoma in children and effect of living-donor liver transplantation on outcome. *Pediatr Transplant*, 10, 42-7.
- [100] Sevmis, S., & Karakayali, H. (2008). Ovarian carcinoma in children. *Pediatr Transplant*, 12, 52-6.

- [101] Hadzic, N., Quaglia, A., Portmann, B., et al. (2011). Hepatocellular carcinoma in children with biliary atresia; King's College Hospital Experience. *J Pediatr*.
- [102] Hadzic, N., & Finegold, M. J. (2011). Liver neoplasia in children. *Clinics in liver disease*, 15(2), 443-62, vii-x., Elsevier Ltd.
- [103] Craig, J. R., Peters, R., Edmondson, H. A., & Omata, M. (1980). Fibrolamellar carcinoma of the liver: a tumor of adolescents and Young adults with distinctive clinicopathologic features. *Cancer*, 46, 372-9.
- [104] Hain, S. F., & Fogelman, I. (2004). Recent advances in imaging hepatocellular carcinoma: diagnosis, staging and response assessment functional imaging. *Cancer J*, 10, 121-7.
- [105] Shoup, M., Gonen, M., D'Angelica, M., et al. (2003). Volumetric analysis predicts hepatic dysfunction in patients undergoing major liver resection. *J Gastrointest Surg*, 7, 325-30.
- [106] Rumack, C. M., Wilson, S. R., & Charboneau, J. W. (2005). *Diagnostic ultrasound* (3rd edition), St Louis (MO), Mosby.
- [107] Bruix, J., & Sherman, M. (2005). Practice Guidelines Committee, American Association for the Study of Liver Diseases. Management of hepatocellular carcinoma. *Hepatology*, 42, 1208-1236.
- [108] Cochrane, A. M., Murray-Lyon, I. M., Brinkley, D. M., & Williams, R. (1977). Quadruple chemotherapy versus radiotherapy in treatment of primary hepatocellular carcinoma. *Cancer*, 40, 609-6.
- [109] Lawrence, T. S., Tesser, R. J., & ten Haken, R. K. (1990). An application of dose volume histograms to the treatment of intrahepatic malignancies with radiation therapy. *Int J Radiat Oncol Biol Phys*, 19, 1041-1047.
- [110] Lawrence, T. S., Ten Haken, R. K., Kessler, M. L., et al. (1992). The use of 3-D dose volume analysis to predict radiation hepatitis. *Int J Radiat Oncol Biol Phys*, 23, 781-788.
- [111] Robertson, J. M., Mc Ginn, C. J., Walker, S., et al. (1997). A phase I trial of hepatic arterial bromodeoxyuridine and conformal radiation therapy for patients with primary hepatobiliary cancers or colorectal liver metastases. *Int J Radiat Oncol Biol Phys*, 39, 1087-1092.
- [112] Seong, J., Keum, K. C., Han, K. H., et al. (1999). Combined transcatheter arterial chemoembolization and local radiotherapy of unresectable hepatocellular carcinoma. *Int J Radiat Oncol Biol Phys*, 43, 393-397.
- [113] Shim, S. J., Seong, J., Han, K. H., et al. (2005). Local radiotherapy as a complement to incomplete transcatheter arterial chemoembolization in locally advanced hepatocellular carcinoma. *Liver Int*, 25, 1189-1196.
- [114] Park, W., Lim, D. H., Paik, S. W., et al. (2005). Local radiotherapy for patients with unresectable hepatocellular carcinoma. *Int J Radiat Oncol Biol Phys*, 61, 1143-1150.

- [115] Park, JW. (2004). Korean Liver Cancer Study Group and National Cancer Center. Practice guideline for diagnosis and treatment of hepato- cellular carcinoma. *Korean J Hepatol*, 10, 88-98.
- [116] Von Schweinitz, D. (2004). Treatment of liver tumors in children. In: *Clavian PA, Fong Y, Lysterly H, et al. editors. Liver tumors: current and emerging therapies*, Boston, Jones and Bartlett.
- [117] Mazzaferro, V., Regalia, E., Doci, R., et al. (1996). Liver transplantation for the treatment of small hepatocellular carcinoma in patients with cirrhosis. *New Engl J Med*, 334, 693-9.
- [118] Yao, F. Y., Ferrell, L., Bass, N. M., et al. (2001). Liver transplantation for hepatocellular carcinoma: expansion of the tumor size limits does not adversely impact survival. *Hepatology*, 33, 1394-403.
- [119] Roayaie, S., Frischer, J. S., Emre, S. H., et al. (2002). Long-term results with multimodal adjuvant therapy and liver transplantation for the treatment of hepatocellular carcinoma larger than 5 centimetres. *Ann Surg*, 235, 533-9.
- [120] Terracciano, L., & Tornillo, L. (2003). Cytogenetic alteration in liver cell tumors as detected by comparative genomic hybridization. *Pathologica*, 95, 71-82.
- [121] Llovet, J. M., Ricci, S., Mazzaferro, V., et al. (2008). Sorafenib in advanced hepatocellular carcinoma. *New Engl J Med*, 359, 420-2.
- [122] Srinivasan, P., Mc Call, J., Pritchard, J., et al. (2002). Orthotopic liver transplantation for unresectable hepatoblastoma. *Transplantation*, 74, 652-5.
- [123] Tagge, E. P., Tagge, D. U., Reyes, J., et al. (1992). Resection, including transplantation, for hepatoblastoma and hepatocellular carcinoma: impact on survival. *J Pediatr Surg*, 27, 292-6, discussion 297.
- [124] Freeman, R. B., Jr., & Edwards, E. B. (2000). Liver transplant waiting time does not correlate with waiting list mortality: implications for liver allocation policy. *Liver Transplant*, 6, 543-52.
- [125] Organ Procurement and Transplantation Network-HRSA. (1998). Final rule with comment period. *Fed Regist*, 63, 16296-338.
- [126] Tiao, G. M., Alonso, M. H., & Ryckman, F. C. (2006). Pediatric liver transplantation. *Seminars in pediatric surgery*, 15(3), 218-27.
- [127] Schiff, E. R., Maddrey, W. C., & Sorrel, M. F. (2011). *Schiff's Disease of the Liver* (11th ed.), Wiley-Blackwell.
- [128] Ehren, H., Mahour, G. H., & Isaacs, H., Jr. (1983). Benign liver tumors in infancy and childhood. *Report of 48 cases*. *Am J Surg*, 145, 325-9.
- [129] Kochin, M. D., Tamir, A., Miloh, M. D., Ronen Arnon, M. D., Kishore, R., Iyer, M. D., Frederick, J., Suchy, M. D., Nanda Kerkar, M., Zenge, J. P., Fenton, L., Lovell, M. A.,

- Grover, T. R., et al. (2002). Case report: infantile hemangioendothelioma. *Curr Opin Pediatr*, 14, 99-102.
- [130] Reymond, D., Plaschkes, J., Luthy, A. R., et al. (1995). Focal nodular hyperplasia of the liver in children: review of follow-up and outcome. *J Pediatr Surg*, 30, 1590-3.
- [131] Bakshi, P., Srinivasan, R., Rao, K. L., et al. (2006). Fine needle aspiration biopsy in pediatric space- occupying lesions of liver: a retrospective study evaluating its role and diagnostic efficacy. *J Pediatr Surg*, 41, 1903-8.
- [132] Schwartz, M. E., Konstadoulakis, M. M., Roayaie, S., et al. (2008). The Mount Sinai experience with orthotopic liver transplantation for benign tumors: brief report and literature review: case reports. *Transplant Proc*, 40, 1759-62.
- [133] Finegold, M. J., Egler, R. A., Goss, J. A., et al. (2008). Liver tumors: pediatric population. *Liver Transpl*, 14, 1545-56.
- [134] Zenge, J. P., Fenton, L., Lovell, M. A., & Grover, T. R. (2002). Case report: infantile hemangioendothelioma. *Curr Opin Pediatr*, 14, 99-102.
- [135] Mortelé, K. J., Vanzieleghem, B., Mortelé, B., Benoit, Y., & Ros, P. R. (2002). Solitary hepatic infantile hemangioendothelioma: dynamic gadolinium-enhanced MR imaging findings. *Eur Radiol*, 12, 862-865.
- [136] Ingram, J. D., Yerushalmi, B., Connell, J., Karrer, F. M., Tyson, R. W., & Sokol, R. J. (2000). Hepatoblastoma in a neonate: a hypervascular presentation mimicking hemangioendothelioma. *Pediatr Radiol*, 30, 794-797.
- [137] Roos, J. E., Pfiffner, R., Stallmach, T., Stuckmann, G., Marincek, B., & Willi, U. (2003). Infantile hemangioendothelioma. *Radiographics: a review publication of the Radiological Society of North America*, 23(6), 1649-55.
- [138] Stringer, M. D., & Alizai, N. K. (2005). Mesenchymal hamartoma of the liver: a systematic review. *J Pediatr Surg*, 40, 1681-90.
- [139] Horton, K. M., Bluemke, D. A., Ralph, H., Soyer, P., & Fishman, E. K. (1999). *CT and MR Imaging of Benign Hepatic*, 431-451.
- [140] Zafrani, E. S. (1989). Update on vascular tumours of the liver. *J Hepatology*, 8(1), 125-30.
- [141] Linderkamp, O., Hopner, F., Klose, H., et al. (1976). Solitary hepatic hemangioma in a newborn infant complicated by cardiac failure, consumption coagulopathy, microangiopathic hemolytic anemia, and obstructive jaundice. Case report and review of the literature. *Eur J Pediatr*, 125(1), 239.
- [142] Hobbs, K. E. (1990). Hepatic hemangiomas. *World J Surg*, 14(4), 468-71.
- [143] DeLorimier, A. A., Simpson, E. B., Baum, R. S., et al. (1967). Hepatic-artery ligation for hepatic hemangiomatosis. *N Engl J Med*, 277(7), 333-7.

- [144] Warmann, S., Bertram, H., Kardorff, R., et al. (2003). Interventional treatment of infantile hepatic hemangioendothelioma. *J Pediatr Surg*, 38(8), 1177-81.
- [145] Walsh, R., Harrington, J., Beneck, D., et al. (2004). Congenital infantile hepatic hemangioendothelioma type II treated with orthotopic liver transplantation. *J Pediatr Hematol Oncol*, 26(2), 121-3.
- [146] Lack, E. E., & Ornvold, K. (1986). Focal nodular hyperplasia and hepatic adenoma: a review of eight cases in the pediatric age group. *J Surg Oncol*, 33, 129-35.
- [147] Farruggia, P., Alaggio, R., Cardella, F., Tropia, S., Trizzino, A., Ferrara, F., & D'Angelo, P. (2010). Focal nodular hyperplasia of the liver: an unusual association with diabetes mellitus in a child and review of literature. *Italian journal of pediatrics*, 36, 41, doi: 10.1186/1824-7288-36-41.
- [148] Luciani, A., Kobeiter, H., Maison, P., Cherqui, D., Zafrani, E. S., Dhumeaux, D., & Mathieu, D. (2002). Focal nodular hyperplasia of the liver in men: is presentation the same in men and women? *Gut*, 50, 877-80.
- [149] Rebouissou, S., Bioulac-Sage, P., & Zucman-Rossi, J. (2008). Molecular pathogenesis of focal nodular hyperplasia and hepatocellular adenoma. *J Hepatol*, 48, 163-170.
- [150] Raidl, M., Pirker, C., Schulte-Hermann, R., Aubele, M., Kandioler-Eckersberger, D., Wrba, F., Micksche, M., Berger, W., & Grasl-Kraupp, B. (2004). Multiple chromosomal abnormalities in human liver (pre)neoplasia. *J Hepatol*, 40, 660-668.
- [151] Vernier-Massouille, G., Cosnes, J., Lemann, M., Marteau, P., Reinisch, W., Laharie, D., & Cadiot, G. (2007). Nodular regenerative hyperplasia in patients with inflammatory bowel disease treated with azathioprine. *Gut*, 56(10), 1404-9.
- [152] Stromeyer, F. W., & Ishak, K. G. (1981). Nodular transformation (nodular "regenerative" hyperplasia) of the liver. A clinicopathologic study of 30 cases. *Hum Pathol*, 12, 60-71.
- [153] Wanless, I. R., Godwin, T. A., Allen, F., et al. (1980). Nodular regenerative hyperplasia of the liver in hematologic disorders: a possible response to obliterative portal venopathy. A morphometric study of nine cases with an hypothesis on the pathogenesis. *Medicine*, 59, 367-79.
- [154] Naber, A. H., Van Haelst, U., & Yap, S. H. (1991). Nodular regenerative hyperplasia of the liver: an important cause of portal hypertension in non-cirrhotic patients. *J Hepatol*, 12, 94-9.
- [155] Reshamwala, P. A., Kleiner, D. E., & Heller, T. (2006). Nodular regenerative hyperplasia: not all nodules are created equal. *Hepatology*, 44, 7-14.
- [156] Stocker, J. T., & Ishak, K. G. (1983). Mesenchymal hamartoma of the liver: Report of 30 cases and review of the literature. *Pediatr Pathol*, 1, 245-67.
- [157] Gupta, R., Parelkar, S. V., & Sanghvi, B. (2009). Mesenchymal hamartoma of the liver. *Indian J Med Paediatr Oncol*, 30, 141-143, doi:.

- [158] Kirks, D. R., & Griscom, N. T. (1990). Practical pediatric imaging. Lippincott Williams and Wilkins, 3rd ed, Boston, Little, Brown, *Diagnostic radiology of infants and children*, 808-815.
- [159] Ito, H., Kishikawa, T., Toda, T., Arai, M., & Muro, H. (1984). Hepatic mesenchymal hamartoma of an infant. *J Pediatr Surg*, 19, 315-7.
- [160] Bisogno, G., Pilz, T., Perilongo, G., et al. (2002). Undifferentiated sarcoma of the liver in childhood: A curable disease. *Cancer*, 94, 252-257.
- [161] Lack, E. E., Schloo, B. L., Azumi, Net, et al. (1991). Undifferentiated (embryonal) sarcoma of the liver. Clinical and pathological study of 16 cases with emphasis on immunohistochemical features. *Am J Surg Pathol*, 15, 1-16.
- [162] Chuang, W.-yu., Lin, J.-nan., Hung, I.-jih., & Hsueh, C. (2001). *Undifferentiated Sarcoma of the Liver*, 399-404.
- [163] Foster, J. H., & Berman, M. M. (1977). *Solid Liver Tumors*, Philadelphia, W. B. Saunders, 198-202.
- [164] Donovan, E. J., & Santulli, T. V. (1946). Resection of the left lobe of the liver for mesenchymoma- Report of case. *Ann Surg*, 124, 90-3.
- [165] Willeford, G., & Stenbridge, V. A. (1950). Primary sarcoma of liver- Report of a case. *Am J Dis Child*, 80, 404-7.
- [166] Dintzman, M., Reiss, R., & Haimoff, H. (1966). Right hepatectomy. *Isr J Med Sci*, 2, 743-9.
- [167] Noguchi, K., Yokoo, H., Nakanishi, K., Kakisaka, T., Tsuruga, Y., Kamachi, H., Matsushita, M., et al. (2012). A long-term survival case of adult undifferentiated embryonal sarcoma of liver. *World journal of surgical oncology*, 10(1), 65.
- [168] Walker, N. I., Horn, M. J., Strong, R. W., Lynch, S. V., Cohen, J., Ong, T. H., & Harris, O. D. (1992). Undifferentiated (embryonal) sarcoma of the liver: Pathologic findings and long-term survival after complete surgical resection. *Cancer*, 69(1), 52-59.
- [169] Aoyama, C., Hachitanda, Y., Sato, J. K., Said, J. W., & Shimada, H. (1991). Undifferentiated (embryonal) sarcoma of the liver. A tumor of uncertain histogenesis showing divergent differentiation. *Am J Surg Pathol*, 15, 615-24.
- [170] Chou, P., Mangkornkanok, M., & Gonzalez-Crussi, F. (1990). Undifferentiated (embryonal) sarcoma of the liver: ultrastructure, immunohistochemistry, and DNA ploidy analysis of two cases. *Pediatr Pathol*, 10, 549-62.
- [171] Keating, S., & Taylor, G. P. (1985). Undifferentiated (embryonal) sarcoma of the liver: ultrastructural and immunohistochemical similarities with malignant fibrous histiocytoma. *Hum Pathol*, 16, 693-9.

- [172] Buetow, P. C., Buck, J. L., Pantongrag-Brown, L., Marshall, W. H., Ros, P. R., Levine, M. S., & Goodman, Z. D. (1997). Undifferentiated embryonal sarcoma of the liver: pathological basis of imaging findings in 28 cases. *Radiology*, 203, 779-783.
- [173] Urban, C. E., Mache, C. J., Schwinger, W., Pakisch, B., Ranner, G., Riccabona, M., Schimpl, G., Brandesky, G., Messner, H., Pobegen, W., Becker, H., & Grienberger, H. (1993). Undifferentiated (embryonal) sarcoma of the liver in childhood. Successful combined-modality therapy in four patients. *Cancer*, 72, 2511-6.
- [174] Newman, K. D., Schisgall, R., Reaman, G., & Guzzetta, P. C. (1989). Malignant mesenchymoma of the liver in children. *J Pediatr Surg*, 24, 781-3.
- [175] Kirks, D. R., & Griscom, N. T. (1990). Practical pediatric imaging. editors. Lippincott Williams and Wilkins, 3rd ed., Boston, Little, Brown, *Diagnostic radiology of infants and children*, 808-815.

