

We are IntechOpen, the world's leading publisher of Open Access books Built by scientists, for scientists

6,900

Open access books available

185,000

International authors and editors

200M

Downloads

Our authors are among the

154

Countries delivered to

TOP 1%

most cited scientists

12.2%

Contributors from top 500 universities



WEB OF SCIENCE™

Selection of our books indexed in the Book Citation Index
in Web of Science™ Core Collection (BKCI)

Interested in publishing with us?
Contact book.department@intechopen.com

Numbers displayed above are based on latest data collected.
For more information visit www.intechopen.com



Optimization of Tuberosity Healing in Prosthetic Reconstruction of Proximal Humerus Fractures

Moby Parsons

Additional information is available at the end of the chapter

<http://dx.doi.org/10.5772/53727>

1. Introduction

Achieving successful clinical outcomes after hemiarthroplasty for 4-part proximal humerus fractures remains a sobering challenge for even the experienced shoulder reconstruction surgeon or traumatologist. Despite what appears to be secure tuberosity fixation at the time of wound closure, serial postoperative radiographs often reveal progressive displacement and/or resorption of the greater tuberosity.[1-3] This results in a situation akin to a posterior-superior rotator cuff tear, where most patients cannot generate sufficient cuff strength to stabilize the humeral head against the superior pull of the deltoid. Secondary mechanical consequences, including shoulder weakness, superior instability and trapezial substitution can compromise outcomes both in terms of shoulder function and pain in such circumstances.[4, 5] Stiffness and cuff dysfunction frequently render the functional results only fair and many patients must accept a limited goals end result.[6-8]

It is well established that restoration of shoulder function after hemiarthroplasty for fracture depends on successful tuberosity healing in combination with proper reconstruction of the head-tuberosity and head-shaft relationships.[1, 7-9] In the native proximal humerus, the edge of the articular cartilage of the superior head is directly adjacent to the cuff insertion and the two are nearly confluent. The dome of the head is about 5-8 mm above the supraspinatus footprint. Restoring this confluence between the cuff insertion and the prosthetic head while maintaining appropriate tuberosity offset relative to the center of rotation is essential for proper cuff mechanics. Restoring proper head height, medial offset, posterior offset and retrotorsion is also critical to achieving soft tissue balance that will provide both strength and stability.

Despite the introduction of fracture-specific prostheses, translating successful anatomical reconstruction into shoulder function is not guaranteed by the theoretical solutions these new-

er designs propose for complex fracture treatment. Realistically, outcomes after hemiarthroplasty for fracture are a blend of appropriate prosthesis selection and use, optimal management of tuberosity fixation, respect for the biology of fracture healing and application of an appropriate rehabilitation protocol that does not jeopardize these other aims. As follows is a discussion about principles for optimizing tuberosity reduction, fixation and healing using horizontal cable cerclage in combination with a press-fit, porous coated fracture-specific prosthesis. This technique can be applied in the setting of hemiarthroplasty or reverse shoulder arthroplasty for fracture.

2. Why does failure of tuberosity healing occur?

As with fractures in other bones, successful union of the tuberosities after humeral hemiarthroplasty requires an optimal biological and mechanical environment for bone healing. Failure occurs for several potential reasons alone or in combination. Firstly, aggressive mobilization techniques during exposure may devascularize and further destabilize the tuberosities by stripping periosteal attachments. These periosteal attachments are critical to the blood supply of the greater tuberosity when the posterior circumflex humeral artery has been severed by the fracture pattern. This is generally the case when fracture severity warrants prosthetic reconstruction. Secondly, violation of the rotator interval capsule during exposure and head retrieval disrupts the remaining bridge of tissue that links the tuberosities. This further destabilizes the tuberosities by dissociating the transverse force couple that counteracts their individual deforming forces.

Thirdly, thermal damage from cement may further damage the endosteal blood supply of the humerus, and cement blocks the marrow cavity and areas where the fracture fragments may interdigitate. Fourthly, conventional suture fixation constructs often fail to achieve sufficiently rigid fixation to permit healing. Poor bone quality and fracture comminution increase the likelihood of suture loosening, which occurs early in the postoperative period. Finally, prosthesis designs that do not provide an adequate template for recreation of the cortical shell of the proximal humerus and those that do not allow direct fixation of the tuberosities to the body of the prosthesis will invite a degree of micromotion that is not compatible with fracture union.

3. Features of the EPOCA prosthesis

For fracture hemiarthroplasty, the author prefers the EPOCA Shoulder System (Synthes, Westchester, PA). The EPOCA shoulder prosthesis has several features that make it an ideal choice for use in reconstructing proximal humerus fractures. The design of the humeral prosthesis is based on extensive anatomical studies with the goal of restoring the normal structural relationships between the head, tuberosities and shaft.[10] The rationale behind the design of the EPOCA system is that aspects of the proximal humeral anatomy that are

highly variable across the population should be adjustable while those aspects with minimal variation should be standardized. Features with a high variation include head radius, size of the humeral medullary canal, medial offset and tuberosity offset. Features with a low variation include neck-shaft angle and the ratio of head height to radius. To this end, the system offers 5 stem sizes (6 - 14mm in 2 mm increments) and 10 head diameters (40 – 58 mm in 2 mm increments). There are also standard (115 mm) and long (215 mm) stem lengths. Independent adjustment of medial and posterior offset can be achieved by a dual eccentricity (Eccenter) that allows the head to be placed in an infinite number of X-Y positions within a 6 mm orbit relative to the humeral component. This ensures precise reconstruction of the proximal humeral anatomy and center of rotation.

The EPOCA stem comes in both a press fit and cemented option (Figure 1). The former has porous coating on the proximal half, the roughness of which may help promote tuberosity adherence and security. The tapered wedge geometry has a prominent calcar design that helps the stem self-center, self-rotate and self-lock as it is inserted. Thus, even in a fracture situation, a press-fit stem can be used and achieve excellent stem stability without the need for cement fixation.

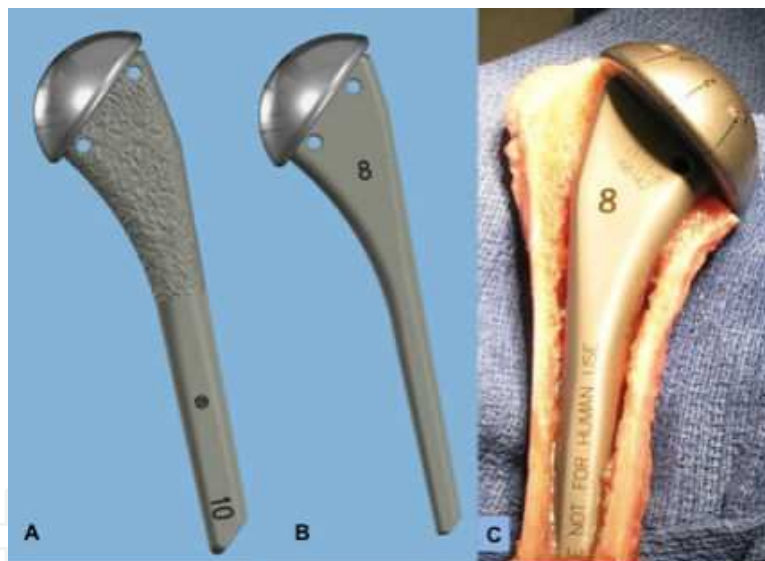


Figure 1. The EPOCA stem comes in press-fit, porous coated (A) and smooth, cemented (B) options. Both have a tapered wedge geometry with a prominent calcar design that promotes metaphyseal fill (C). Medial and lateral holes in the proximal stem allow cerclage directly through the prosthesis rather than around its medial calcar portion. These features permit use of the press-fit stem in the setting of fracture due to the rotational stability afforded by the stem geometry.

The proximal body of the stem has both a medial and lateral hole through which cables can be passed for tuberosity cerclage (Figure 1). This construct improves rotational stability of the cerclage fixation compared to cables or sutures passed around the calcar section of the prosthesis. In the latter case, the fixation is not directly linked to the stem so that the tuberosities can still move independently of the prosthesis when the arm is rotated about the axis of the humerus. By passing fixation through the stem of the prosthesis, the tuberosities are

compressed directly to the stem so that the construct rotates as a single unit during arm rotation. The improved stability of this fixation obviates the need for multiple other sutures, specifically vertical sutures between the shaft and bone-tendon junction that tend to result in the common mistake of tuberosity over-reduction.

4. Preoperative planning

When the decision to operate has been made, the surgeon needs to consider a variety of factors in deciding the best method of treatment for the given fracture pattern. Aspects of the patient’s medical and social history are important to consider. The following patients factors may bear on the decision to attempt fixation versus prosthetic replacement: age, hand-dominance, physical demands, expectations, compliance, smoking history, and medical comorbidity.

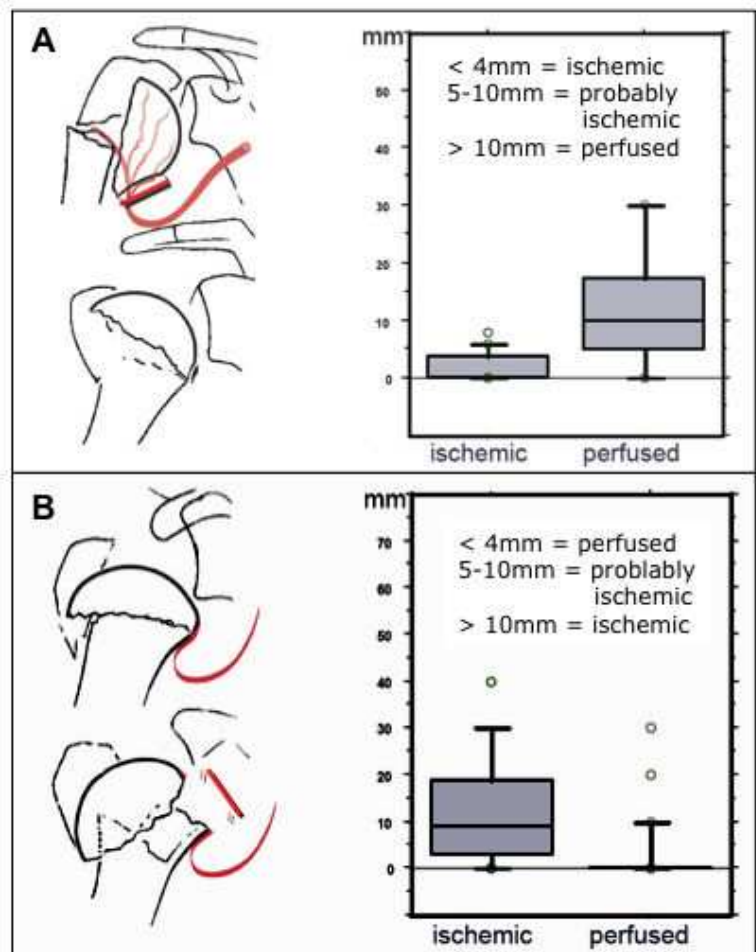


Figure 2. Head perfusion is best assessed by the length of the medial metaphyseal extension (A) and the displacement of the medial periosteal hinge (B). If the metaphyseal extension is less than 5mm and/or the displacement of the medial hinge is more than 5-10mm, the head is likely ischemic.

It is essential when assessing these fractures to have a thorough understanding of the fracture “personality” and this usually demands a CT scan with coronal and sagittal reconstructions that allow for 3-D rendering. Such imaging can be invaluable in determining the location and degree of comminution, the integrity of the articular surface, the exact relationship between the head, tuberosity and shaft, as well as prognostic indicators of head vascularity. In the latter case, the length of the medial metaphyseal extension and the displacement of the medial periosteal hinge are most predictive of head perfusion (Figure 2).

This collective information can help the surgeon determine if fixation is both warranted and feasible. Feasibility depends on factors such as bone quality and comminution, fracture complexity, availability of the necessary implants and surgeon skill. If stable, anatomical fixation is not possible, then prosthetic replacement is warranted. While reverse shoulder arthroplasty has become increasingly popular in this setting, there remains a role for hemiarthroplasty in younger and more physically demanding patients. Of note, the technique described herein can be used for secure tuberosity fixation during reverse arthroplasty for fracture where outcome can also be improved by successful tuberosity healing allowing restoration of active external rotation.

5. Surgical technique

The patient is positioned as for a shoulder arthroplasty such that the scapula is supported but the arm can be brought over the side of the bed to expose the humeral shaft. The fracture is exposed through a standard delto-pectoral approach taking the cephalic vein laterally with the deltoid. The anterior deltoid is elevated off the coracoacromial (CA) ligament and a sharp angled lever is placed behind the ligament. This helps “roll” the deltoid laterally to expose the proximal humerus.

The clavipectoral fascia is excised en bloc from the CA ligament proximally to the pectoralis major tendon distally and the conjoint tendon medially to the deltoid laterally. Once this layer has been removed, the humeroscapular motion interface is accessible and adhesions in this interval can be freed using blunt dissection. One must avoid overzealous dissection to prevent stripping of any residual periosteal attachment of the tuberosities to the shaft. A curved ring retractor can then be placed beneath the deltoid and a right-angle retractor beneath the conjoint tendon.

The biceps tendon is then identified and followed proximally. It should be sutured to the pectoralis major tendon to preserve native tension and then tenotomized at the superior aspect of the bicipital groove. Because the bicipital groove and a portion of the anterior greater tuberosity usually remain attached to the lesser tuberosity fragment, it is critical to preserve the rotator interval capsule (Figure 3A). Thus, it should not be routinely divided above the transverse humeral ligament as many conventional techniques recommend (Figure 3B). Preservation of the rotator interval will help stabilize the tuberosity repair by leaving a soft tissue bridge between the anterior and posterior fragments. This helps neutralize the individual deforming forces that lead to loosening and failure

of fixation. In a majority of cases there is a longitudinal split in the supraspinatus tendon where the anterior bundle remains attached to the lesser tuberosity fragment. Maintenance of this attachment is critical to maximize the potential for cuff function postoperatively. Exposure of the humeral head and glenoid can be achieved by extending the longitudinal cuff split medially. This can be repaired side-to-side at the conclusion of the case and does not jeopardize the cuff insertion to the bone.

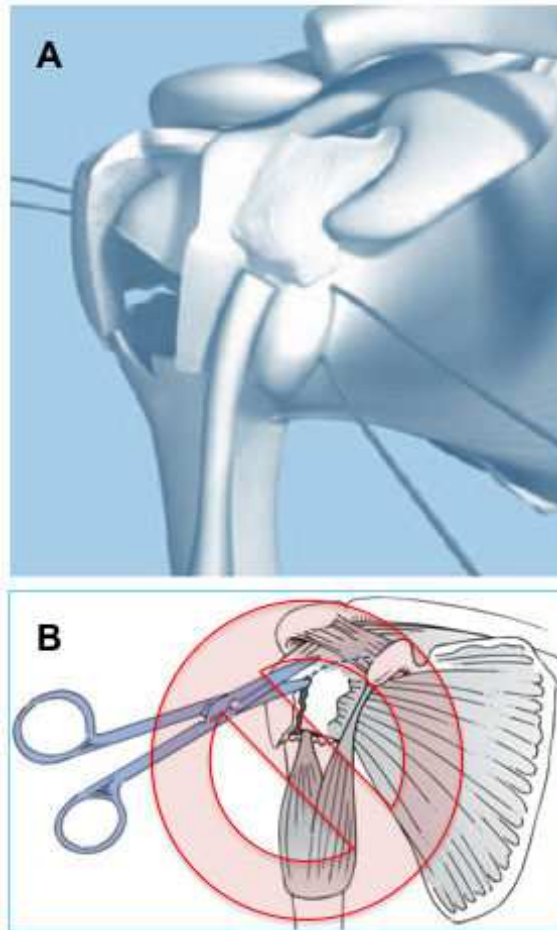


Figure 3. In a typical 4-part fracture, the bicipital groove and anterior most portion of the greater tuberosity remains attached to the anterior, lesser tuberosity fragment (A). The anterior bundle of the supraspinatus tendon remains attached to this anterior fragment, separated by a longitudinal split in the tendon at the level of the fracture plane. The rotator interval capsule remains intact and should not be violated as is current convention (B).

Heavy braided suture is placed through the bone tendon interface of each of the subscapularis (SC), supraspinatus (SS) and infraspinatus (IS) tendons. It is essential when placing the posterior sutures that excessive traction is not applied so that soft tissue attachments between the tuberosity and shaft are maintained. Overly aggressive tuberosity mobilization injures the periosteal blood supply and reduces the likelihood of eventual healing. As much as possible, the greater tuberosity should be left in-situ posteriorly.

The humeral head can then be retrieved from the joint through the split in the SS tendon. The head can then be “keyed in” to the shaft to determine the location of the medial metaphyseal extension. The length of this extension is then measured and this length represents the distance above the calcar that the prosthetic head should sit to restore proper head height (Figure 4). This is a simple, reliable and accurate method of determining head height that can be cross-referenced with other accepted methods per the surgeon’s discretion. The humeral head is then sized against the prosthetic head trials. One should typically downsize if the native head is in between trial head sizes so as not to overstuff the joint. Cancellous autograft is then harvested from the humeral head for supplemental bone grafting of the tuberosities to aid in restoration of tuberosity offset.

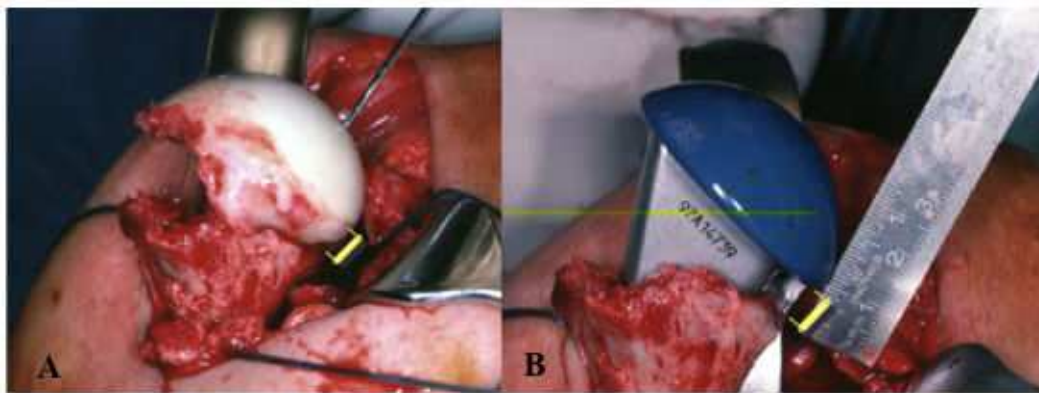


Figure 4. The length of the medial metaphyseal extension can be used as an accurate and reproducible method of determining the height at which the prosthesis should be seated to recreate proximal humeral anatomy. The native head can be keyed onto the shaft to determine this height (A). The prosthesis height and medial offset should be set to reproduce the native shoulder anatomy (B).

Prior to stem implantation, it is important to place the cerclage cables through the greater tuberosity in an inside-out fashion (Figure 5). At a level approximately 5 mm below the bone-tendon junction, a 2 mm drill bit is used to make the medial and lateral holes through the tuberosity bone. Again, care should be taken to leave the tuberosity in-situ when these holes are drilled to protect soft-tissue attachments. A Synthes 1 mm needled, beaded cable is then passed through each of the holes. The cable crimp must be taken off before the cable is placed and the crimp saved on the back table so that it is not inadvertently lost. The needle can be bounced off of the curved deltoid retractor and the cable retrieved on the dorsal tuberosity surface. The needle is removed and the cables are then tagged with a hemostat and parked posteriorly for later tuberosity repair.

A distally-angled Fukuda retractor is next placed behind the glenoid to inspect the joint. The root of the biceps should be excised and the glenoid articular surface checked for concomitant fracture. The labrum should be preserved to aid in stability and load distribution. Aggressive capsular releases are not necessary in fracture reconstruction as would be performed during shoulder arthroplasty for degenerative disease, and the temptation to perform a circumferential subscapularis release should be avoided. This will only jeopardize

the anterior circumflex humeral artery, which provides vascularity to the anterior tuberosity fragment, and disrupt the important rotator interval “bridge.”

The humeral shaft is then exposed by placing the arm in extension, adduction and external rotation. Two blunt Hohman retractors, posteriorly and medially, are used to lever the shaft anteriorly. If necessary, the medullary canal is opened with the cylindrical starter rasp. Further reaming is not necessary as the EPOCA system uses impaction broaches to prepare the canal. Starting with the smallest broach, proper stem rotation is determined by orienting the laser-etched center line of the broach with a point 8 mm posterior to the deepest point of the bicipital. This point has been shown to correspond to the equatorial plane of the humeral head (Figure 6A & B).[10] The broach is seated to the level that restores the head height according to the pre-determined metaphyseal extension length. Proper retrotorsion of the humeral stem can be confirmed by inserting the 6 mm rod into the broach and measuring roughly 25 degrees relative to the forearm axis with the goniometer.

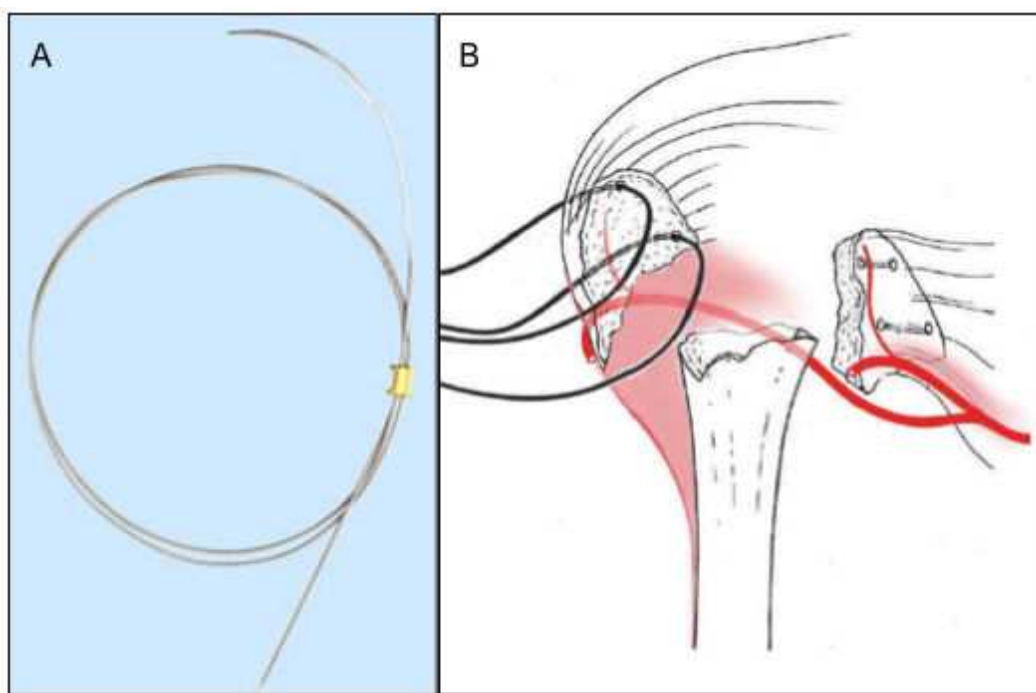


Figure 5. The Synthes beaded, needled cable should be used (A); cables should be placed prior to instrumentation of the humeral shaft with care taken not to disrupt periosteal attachments between the tuberosities and the humeral shaft (B).

Progressively larger broaches are introduced until distal (diaphyseal) canal fill is achieved. A curved curette can be used to remove cancellous bone along the medial humeral metaphyseal region to help fully seat the desired broach if necessary. The pronounced calcar design allows the broach to self-center, self-align and self-lock in the proper height and orientation, obviating the need for cumbersome jigs to position the trial stem. Once the stem size has been determined, the trial stem is impacted to the proper height using light progressive taps with the mallet to prevent fracture of the shaft by the wedge-shaped stem.

In a majority of cases, an optimal fit can be achieved allowing the use of a press-fit stem. In the occasional case, one stem size is over-recessed relative to the calcar and the next size too big for the diaphysis. In these cases, the surgeon has two choices. The first is to attempt impaction grafting the smaller stem to the proper height using autograft from the humeral head and the smaller impaction broach. With the diaphyseal portion of the broach inserted only slightly into the canal, small croutons of bone graft can be placed circumferentially around the canal opening and progressively impacted into the metaphysis. This process can be repeated until a snug fit is achieved with the broach. In patients with severely osteoporotic bone, a stable press-fit may not be possible without undue risk of humeral shaft fracture. The second option is to cement the final prosthesis in a conventional manner. In such a case, the final chosen stem will be one size smaller than the broach and trial stem to allow for a circumferential cement mantle.

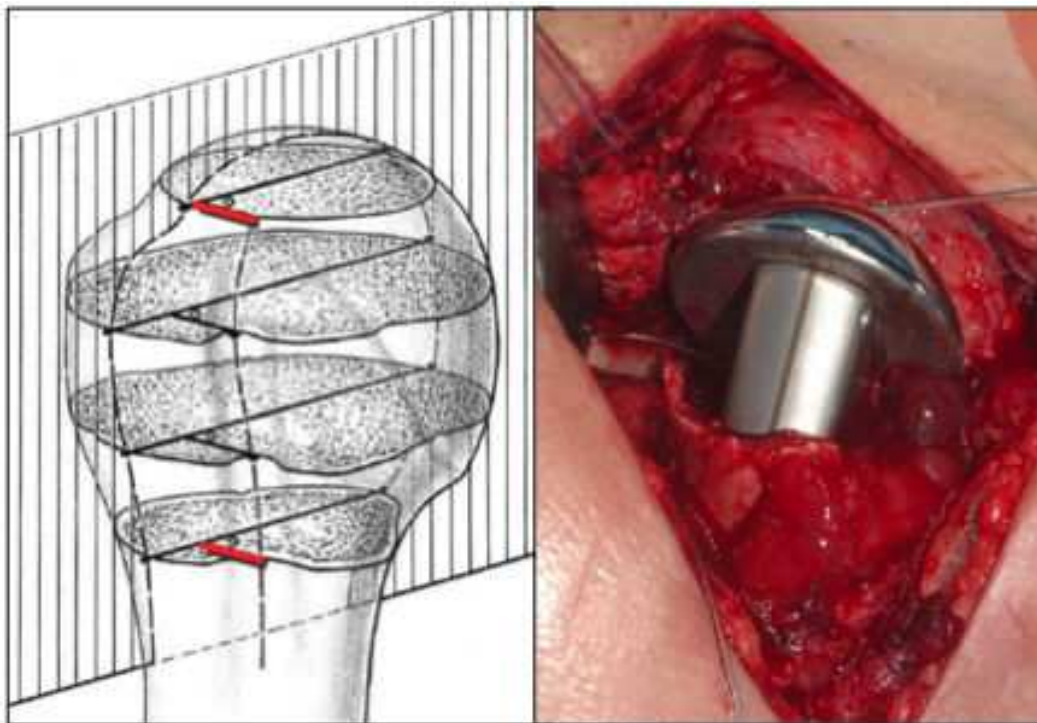


Figure 6. The equatorial plane of the humeral head bisects the edge of the articular cartilage adjacent the rotator cuff at a point approximately 8mm posterior to the deepest point of the bicipital groove (A); This is also true in the metaphyseal region and can be used to orient the trial stem into the proper retrotorsion. When the laser etch on the back of the stem is 8mm posterior to the bicipital groove on the proximal aspect of the humeral shaft, the retrotorsion should measure roughly 25-30 degrees relative to the forearm axis (B).

The Eccenter is then placed on the trial stem followed by the trial humeral head. The 2.5 mm hex driver is used to dial the Eccenter with respect to the stem while the head can be manually rotated on the Eccenter. The combined dual eccentricity of this design allows the head to be placed in an infinite number of antero-posterior (AP) and medio-lateral (ML) offset positions within a 6mm orbit (Figure 7A). More importantly it allows independent adjustment of the medial and posterior offset to more accurately restore the patient's native anatomy

and center of rotation. Optimal medial offset is achieved by recreating the medial calcar line without step off (Figure 7B). In the AP plane, slight posterior offset is desirable to accommodate the larger greater tuberosity and restore native posterior offset of the humeral head relative to the humeral medullary canal. Once the head position has been chosen, the head and Eccenter can be locked using the 2.0 mm hex driver. The trial prosthesis is then reduced into the joint to confirm a congruent stable fit with the glenoid. After the offset number of the head is recorded, the head is removed and the offset letter of the Eccenter is then recorded so that the construct can be replicated with the final components.

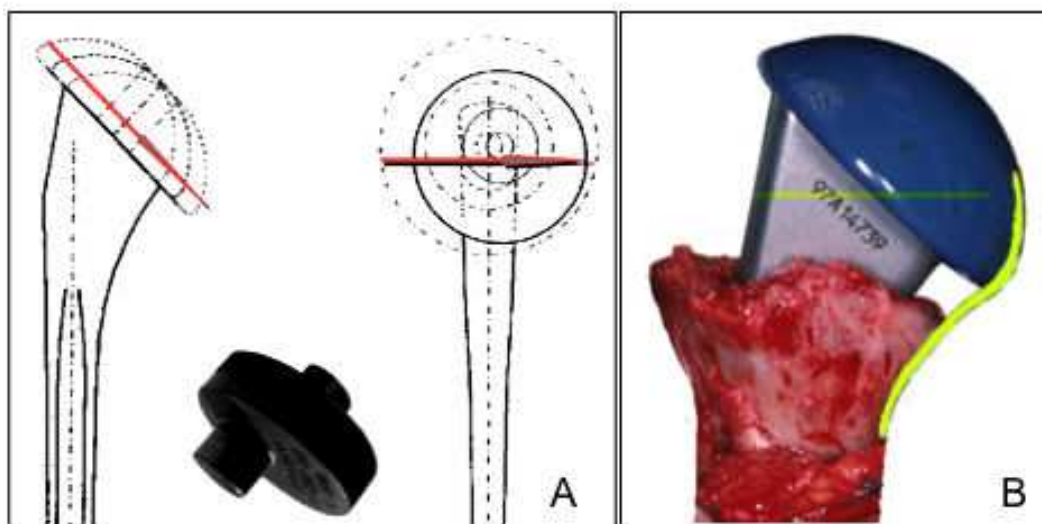


Figure 7. The Eccenter in combination with the humeral head provides a dual offset that allows independent adjustment of the medial and posterior offset for optimal head positioning (A); The medial offset should be adjusted to recreate the normal calcar line relative to the humeral shaft (B).

The final component is then assembled using the press and inserted as a monoblock. The diaphyseal portion of the stem is placed into the medullary canal. Prior to fully seating the component, the cables are passed through the medial and lateral holes from posterior to anterior (Figure 8A). The 3 mm retrotorsion bar is then used to cross-check proper rotation and the component is then fully press fit to the pre-determined height.

The prosthesis is then reduced into the glenoid. Two holes are then drilled into the lesser tuberosity fragment using the 2.0 mm drill. These holes should be placed slightly below the bone tendon junction and correspond to positions of the cables exiting the stem. A 14 gauge angiocath can then be inserted from outside to inside through these holes as a transit to shuttle the cables through the bone fragment. Prior to final tuberosity reduction, bone graft from the humeral head is packed around the stem to fill any voids and augment the often fragile cortical sleeve of the tuberosity fragments. A #2 non-absorbable suture is next used to reapproximate the longitudinal SS split. This aids in fine tuning the tuberosity reduction.

Care must be taken not to over-reduce the tuberosities especially distally. Rather than being pulled down and fixed to the humeral shaft with vertical sutures, the tuberosities should be pushed up to restore the native position of the superior rotator cuff insertion relative to the edge of the prosthetic head. Once this position has been optimized, the tuberosities can be securely fixed with horizontal cable cerclage (Figure 8B).

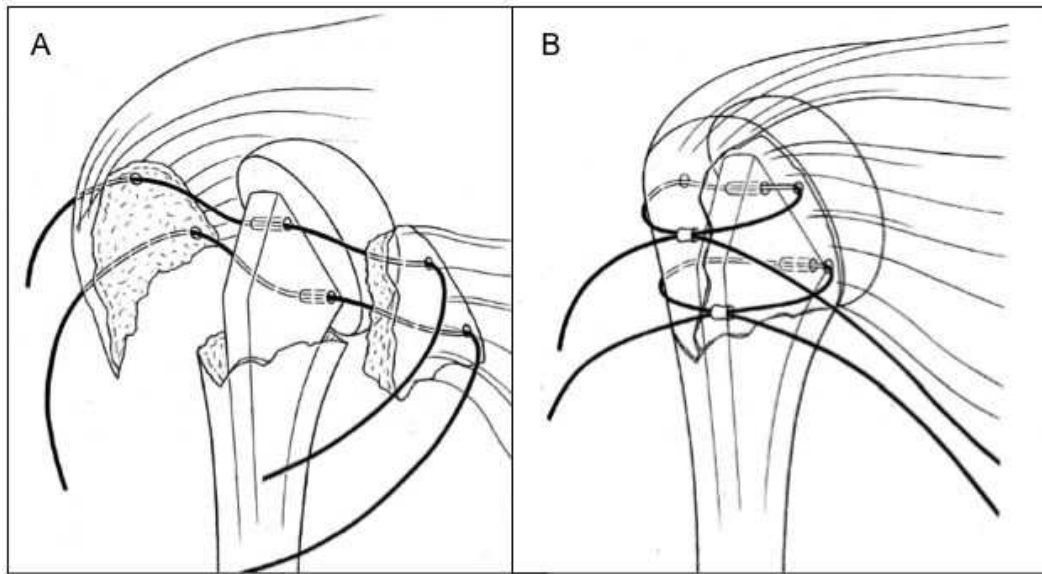


Figure 8. The cables should be passed through the prosthesis from back to front before final prosthesis seating. After holes are drilled into the lesser tuberosity fragment, these cables are then passed from inside to outside through the lesser fragment (A). Once the joint is reduced and the tuberosities situated to recreate the proper head-tuberosity relationship, the cables can be tightened and crimped to effect a horizontal cerclage directly to the prosthesis (B).

Both ends of each cable are threaded through their respective crimps, which are positioned over the bicipital groove. The cables are then spaced superiorly and inferiorly on the tuberosities. The superior cable must be placed below the bone tendon junction so that it does not subluxate over the humeral head. To tension the beadless cable, the crimp must be stabilized on one side by either a hemostat or by the accessory locking portion of the Synthes tensioner. The tensioner is then placed on the opposite side and tensioned until a firm embrace is achieved (roughly 20-30 kg). Overtensioning should be avoided so to prevent deforming or crushing the fragile bone and to avoid devascularization. After crimping and cutting the cables to length, the biceps tendon can be used to cover the crimps by a soft tissue tenodesis to the cuff.

Further tuberosity fixation is not necessary and usually only promotes overreduction and devascularization. A single vertical suture, however, can be passed from the shaft around

the superior cable to prevent it from slipping over the head. After copious irrigation, the wound is closed in layers over a drain, followed by a sterile compressive dressing and sling. Postoperative radiographs are obtained in the recovery room to confirm an optimal reconstruction (Figure 9).

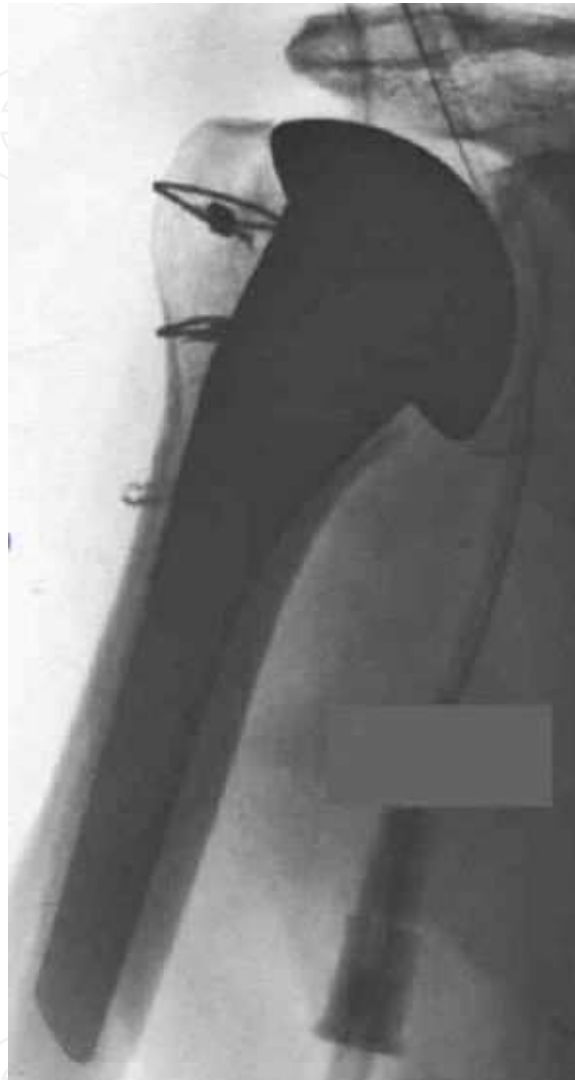

Figure 9. Postoperative AP film showing stable tuberosity reduction with anatomical reconstruction of the calcar line, head height and tuberosity height and offset.

6. Postoperative protocol

Active use of the arm is avoided for 6 weeks to allow tuberosity healing but passive motion exercises must be started early to maximize postoperative function. Although some advocate no passive motion for several weeks, stiffness remains a significant problem that limits the final outcome of these procedures. Because dense adhesions form in the subacromial

space and humeroscapular motion interface, nonoperative and operative treatment of post-surgical adhesive capsulitis in the presence of prosthesis is a substantial challenge that is often marginal in its success. Codman's exercises and positional exercises such as gentle table slides or resting the arm in an abducted position can be started as soon as patients are comfortable. Patients are instructed to steadily increase their passive range on a self-directed basis. Formal physical therapy is often avoided in the early stages to prevent overly aggressive applied stress that might jeopardize tuberosity fixation.

Serial x-rays and clinical status are checked at approximately 2, 4 and 8 weeks postoperatively. Active-assisted range of motion can be added around 6 weeks assuming stable tuberosity fixation. Progressive active range of motion and active use can be started at 8 weeks based on radiographic evidence of tuberosity healing and patient compliance.

7. Discussion

Prosthetic replacement for the fractured proximal humerus follows the same biological and mechanical principles that have evolved from experience in fracture fixation in other areas. Surgeons should approach this case with the same tenets and goals as any fracture case and not abandon these principles given the insertion of a prosthesis. Preservation of soft tissue and periosteal attachments is critical to maintaining blood supply to the fracture fragments. Preservation of the endosteal blood supply and avoidance of suture strangulation are also important. Finally, fixation must be sufficiently rigid to reduce micromotion to a level that permits fracture healing. The use of horizontal cable cerclage for tuberosity fixation using the above-described technique in combination with a press-fit, porous humeral stem addresses each of these critical elements to optimize the chance for successful healing in these difficult cases.

Nils et al performed a meta-analysis of fracture hemiarthroplasty outcomes. Although the quality of existing reports was deemed to be insufficient to make formal recommendations about the role of hemiarthroplasty in the fracture setting, the authors did note that "tuberosity healing has influenced functional outcome in all series mentioning this parameter." [7] Boileau et al followed 66 patients after hemiarthroplasty for fracture and found tuberosity malposition and migration in 50% of cases leading to unsatisfactory results including superior migration, stiffness, weakness and pain. [1] Greiner and associated found that tuberosity malposition correlates with the development of fatty infiltration of the cuff muscles and this occurrence was significantly associated with poorer clinical outcomes in patients after hemiarthroplasty for fracture. [11] Huffman and colleagues studied the biomechanics of tuberosity malposition in 4-part fractures and determined that inferior placement (tuberosity overreduction) has a significant negative impact on the mechanical advantage of the deltoid during shoulder abduction. [5]

Taken together, these reports demonstrate that complications related to failure of tuberosity reduction and fixation are frequent, have a negative impact on normal shoulder kinematics, and result in inferior outcomes for pain and function. This fact has remained true despite

advances in the development of fracture-specific prostheses, improved suture material and purportedly improved suture constructs. Borowsky and colleagues recently reported on failure modes of suture repair and found that tuberosity migration occurs early and in many cases was over 1 centimeter.[2] Given the frequency of clinical reports of tuberosity migration, it seems clear that currently accepted methods of suture repair fail to achieve a biological and mechanical environment that is suitable for bone healing, particularly in osteoporotic bone. Cable cerclage on the other hand has 4.8 times the circular embracing strength of conventional suture material and does not succumb to creep as suture material is proven to do.[12] Cables also have a prone track record in fracture fixation in long bones, such as periprosthetic fractures, and in fixation of trochanteric osteotomy in revision hip arthroplasty. Thus, their application to tuberosity fixation has a solid mechanical and clinical foundation.[13] Krause et al retrospectively compared cable fixation to nonabsorbable suture fixation and found that consistently better radiographic and functional results were achieved when cables were used with the Epoca stem. [12]

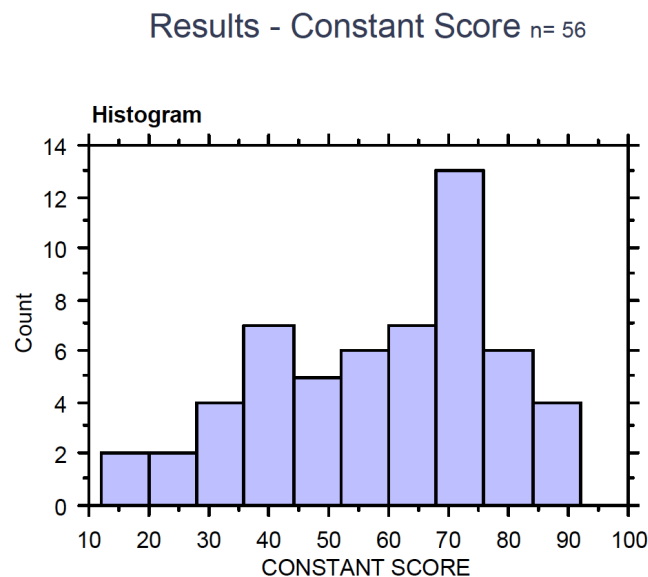


Figure 10. Histogram of Constant Scores in a consecutive series of 56 patients s/p fracture hemiarthroplasty with cable cerclage

The technique described above has been refined through Prof. Ralph Hertel’s extensive use of this prosthesis in the fracture setting. Between 1997 and 2002, 60 patients were followed prospectively following humeral hemiarthroplasty for fracture.(R Hertel, unpublished data) The mean age was 68 years (range 39 – 88 years) and there were 26 males and 34 females. Four patients were lost to follow-up leaving 56 patients available for review with an average follow-up interval of 40 months (range 12 – 92 months). Successful tuberosity healing was achieved in 49 patients with displacement or resorption in 7 patients. Five patients underwent an additional operation to refix the tuberosities. A total of 31 patients achieved active forward elevation above 120 degrees. The histogram in Figure 10 demonstrates the range of Constant Scores in this series of patients. These results, while not as favorable as those ach-

ieved in arthroplasty for degenerative joint disease, do demonstrate that relatively robust shoulder function can be restored by hemiarthroplasty given tuberosity healing and successful patient rehabilitation. Stiffness remains a problem with neither an optimal preventative strategy nor a reliably effective treatment.

8. Technique for the reverse prosthesis

There is growing interest in fracture reconstruction using a reverse prosthesis which may afford better active elevation in cases where tuberosity healing is unpredictable and will potentially be unsuccessful. Even in these cases, however, the surgeon should attempt to achieve stable tuberosity fixation to improve the possibility for rotational movement which aids in positioning the hand in space. Specifically, if active external rotation can be achieved through reattachment of the greater tuberosity, patients may achieve greatly improved the functional outcomes with a reverse arthroplasty.

Similar to primary shoulder arthroplasty, fracture specific systems are now available to address this reverse arthroplasty for fracture. As with primary systems, however, their design does not guarantee successful tuberosity fixation and the principles outlined above still apply to reconstruction with a reverse prosthesis. In addition to the importance of sound technique which preserves the optimal biological conditions for fracture healing, tuberosity fixation with horizontal cable cerclage can also be used to achieve a stable reconstruction with a reverse prosthesis. In such cases, the technical steps are essentially identical to those outlined for primary fracture hemiarthroplasty. Figure 11 demonstrates cable cerclage of the tuberosities in a fracture reconstruction using a reverse prosthesis.

As the indication of reverse shoulder arthroplasty for fracture and fracture sequel has gained more traction and as experience with this technique has grown, clinical studies are now available to report on the outcomes of this procedure including comparative studies with conventional hemiarthroplasty. Boyle and colleagues compared 313 fracture hemiarthroplasty patients to 55 fracture reverse patients and found that Oxford Shoulder Scores at 5 years postoperatively were superior in the reverse group.[14] Young et al, however, were unable to realize any gains in range of motion, American Shoulder and Elbow Surgeons Score or Oxford Shoulder Score in patient who underwent a reverse reconstruction compared to those who underwent hemiarthroplasty for fracture cases.[15] Cazeneuve et al reported on 35 patients who underwent reverse reconstruction for fracture or fracture dislocation.[16] Complications including neurological injury, infection, instability and progressive scapular notching led to a complication rate of 24% and stiffness was noted to be a functionally limiting problem. Bufquin et al also reported stiffness with mean active elevation of only 97 degrees and mean active external rotation of only 30 degrees.[17] Tuberosity migration also occurred in 53% of cases. Lenarz and colleagues reported on 30 patients status post reverse arthroplasty for fracture and mean achieved active elevation of 139 degrees and mean active external rotation of 27 degrees with a 10% complications rate.[18]

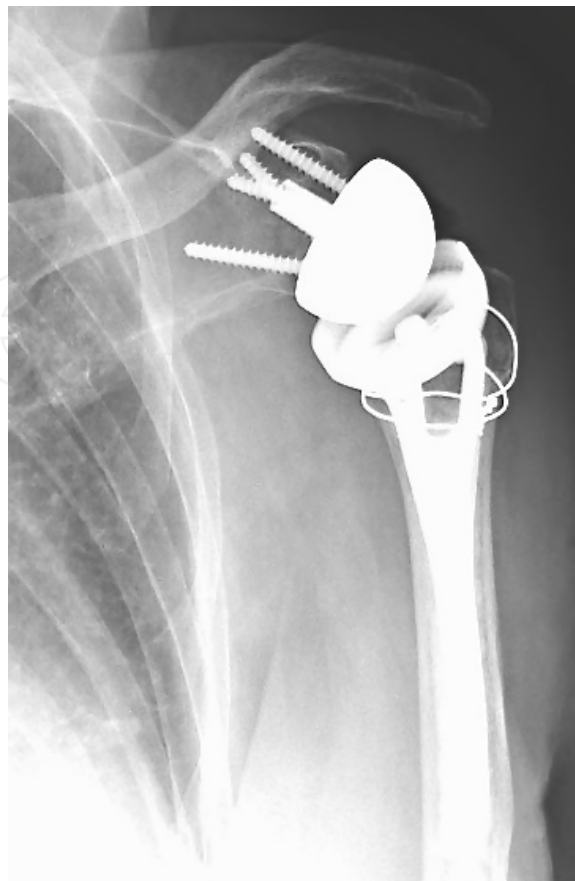

Figure 11. AP view showing horizontal cable cerclage tuberosity fixation in reverse arthroplasty for fracture.

Collectively these early outcomes are somewhat sobering relative to the anticipated advantages that reverse shoulder replacement might achieve in fracture cases. They prove the complexity of these cases and the challenges they present to the shoulder reconstruction surgeon. As design modifications continue to improve reverse systems and as experience with reverse arthroplasty in the fracture setting increases, surgeons can hopefully look forward to future advancements in our ability to provide improved function restoration in these difficult cases. Nevertheless, strict adherence to surgical techniques that preserve the biology of fracture healing, that maximize stability of fragment fixation and that permit early rehabilitation to encourage recovery of function are all critical regardless of the theoretical merits of any specific system in terms of biomechanics and design.

Acknowledgements

The concepts and techniques put forth in this manuscript represent the work of Professor Ralph Hertel, Department of Orthopaedics, Lindenhofspital, Berne Switzerland. He is the principle clinical design surgeon of the EPOCA prosthesis.

Author details

Moby Parsons

Address all correspondence to: impiv@comcast.net

Seacoast Orthopedics & Sports Medicine, Somersworth, NH, USA

References

- [1] Antuna, S. A., J. W. Sperling, and R. H. Cofield. 2008. Shoulder hemiarthroplasty for acute fractures of the proximal humerus: a minimum five-year follow-up. *J Shoulder Elbow Surg* 17:202-209.
- [2] Berend, K. R., A. V. J. Lombardi, T. H. Mallory, D. J. Chonko, K. L. Dodds, and J. B. Adams. 2004. Cerclage wires or cables for the management of intraoperative fracture associated with a cementless, tapered femoral prosthesis: results at 2 to 16 years. *J Arthroplasty* 19:17-21.
- [3] Boileau, P., S. G. Krishnan, L. Tinsi, G. Walch, J. S. Coste, and D. Mole. 2002. Tuberosity malposition and migration: reasons for poor outcomes after hemiarthroplasty for displaced fractures of the proximal humerus. *J Shoulder Elbow Surg* 11:401-412.
- [4] Borowsky, K., V. Raghuprasad, L. Wear, T. Stevenson, N. Marsden, N. Trent, and A. Bennett. 2010. Failure modes of suture repair of the tuberosities in hemiarthroplasty for four part fracture of the shoulder. 11th International Congress of Shoulder and Elbow Surgery 59.
- [5] Boyle, M. J., S. M. Youn, C. M. Frampton, and C. M. Ball. 2012. Functional outcomes of reverse shoulder arthroplasty compared with hemiarthroplasty for acute proximal humeral fractures. *J Shoulder Elbow Surg*
- [6] Bufquin, T., A. Hersan, L. Hubert, and P. Massin. 2007. Reverse shoulder arthroplasty for the treatment of three- and four-part fractures of the proximal humerus in the elderly: a prospective review of 43 cases with a short-term follow-up. *J Bone Joint Surg Br* 89:516-520.
- [7] Cazeneuve, J. F., and D. J. Cristofari. 2010. The reverse shoulder prosthesis in the treatment of fractures of the proximal humerus in the elderly. *J Bone Joint Surg Br* 92:535-539.
- [8] Cazeneuve, J. F., and D. J. Cristofari. 2011. Long term functional outcome following reverse shoulder arthroplasty in the elderly. *OrthopTraumatolSurg Res* 97:583-589.
- [9] Compito, C. A., E. B. Self, and L. U. Bigliani. 1994. Arthroplasty and acute shoulder trauma. Reasons for success and failure. *ClinOrthopRelat Res* 27-36.

- [10] Demirhan, M., O. Kilicoglu, L. Altinel, L. Eralp, and Y. Akalin. 2003. Prognostic factors in prosthetic replacement for acute proximal humerus fractures. *J Orthop Trauma* 17:181-8; discussion 188-9.
- [11] Dimakopoulos, P., N. Potamitis, and E. Lambiris. 1997. Hemiarthroplasty in the treatment of comminuted intraarticular fractures of the proximal humerus. *ClinOrthopRelat Res* 7-11.
- [12] Goldman, R. T., K. J. Koval, F. Cuomo, M. A. Gallagher, and J. D. Zuckerman. 1995. Functional outcome after humeral head replacement for acute three- and four-part proximal humeral fractures. *J Shoulder Elbow Surg* 4:81-86.
- [13] Greiner, S. H., G. Diederichs, I. Kroning, M. Scheibel, and C. Perka. 2009. Tuberosity position correlates with fatty infiltration of the rotator cuff after hemiarthroplasty for proximal humeral fractures. *J Shoulder Elbow Surg* 18:431-436.
- [14] Hawkins, R. J., and P. Switlyk. 1993. Acute prosthetic replacement for severe fractures of the proximal humerus. *ClinOrthopRelat Res* 156-160.
- [15] Hertel, R., U. Knothe, and F. T. Ballmer. 2002. Geometry of the proximal humerus and implications for prosthetic design. *J Shoulder Elbow Surg* 11:331-338.
- [16] Huffman, G. R., J. M. Itamura, M. H. McGarry, L. Duong, J. Gililland, J. E. Tibone, and T. Q. Lee. 2008. Neer Award 2006: Biomechanical assessment of inferior tuberosity placement during hemiarthroplasty for four-part proximal humeral fractures. *J Shoulder Elbow Surg* 17:189-196.
- [17] Krause, F. G., L. Huebschle, and R. Hertel. 2007. Reattachment of the tuberosities with cable wires and bone graft in hemiarthroplasties done for proximal humeral fractures with cable wire and bone graft: 58 patients with a 22-month minimum follow-up. *J Orthop Trauma* 21:682-686.
- [18] Lenarz, C., Y. Shishani, C. McCrum, R. J. Nowinski, T. B. Edwards, and R. Gobezie. 2011. Is reverse shoulder arthroplasty appropriate for the treatment of fractures in the older patient? Early observations. *ClinOrthopRelat Res* 469:3324-3331.
- [19] Lervick, G. N., R. M. Carroll, and W. N. Levine. 2003. Complications after hemiarthroplasty for fractures of the proximal humerus. *Instr Course Lect* 52:3-12.
- [20] Loebenberg, M. I., D. A. Jones, and J. D. Zuckerman. 2005. The effect of greater tuberosity placement on active range of motion after hemiarthroplasty for acute fractures of the proximal humerus. *Bull HospJt Dis* 62:90-93.
- [21] Mighell, M. A., G. P. Kolm, C. A. Collinge, and M. A. Frankle. 2003. Outcomes of hemiarthroplasty for fractures of the proximal humerus. *J Shoulder Elbow Surg* 12:569-577.
- [22] Nijs, S., and P. Broos. 2009. Outcome of shoulder hemiarthroplasty in acute proximal humeral fractures: a frustrating meta-analysis experience. *ActaOrthopBelg* 75:445-451.

- [23] Park, M. S., Y. K. Lee, K. H. Yang, and S. J. Shin. 2003. Management of periprosthetic femoral fractures. *J Arthroplasty* 18:903-906.
- [24] Plausinis, D., Y. W. Kwon, and J. D. Zuckerman. 2005. Complications of humeral head replacement for proximal humeral fractures. *Instr Course Lect* 54:371-380.
- [25] Reuther, F., B. Muhlhausler, D. Wahl, and S. Nijs. 2010. Functional outcome of shoulder hemiarthroplasty for fractures: A multicentre analysis. *Injury* 41:606-612.
- [26] Robinson, C. M., R. S. Page, R. M. Hill, D. L. Sanders, C. M. Court-Brown, and A. E. Wakefield. 2003. Primary hemiarthroplasty for treatment of proximal humeral fractures. *J Bone Joint Surg Am* 85-A:1215-1223.
- [27] Shah, N., H. J. Iqbal, S. Brookes-Fazakerley, and C. Sinopidis. 2010. Shoulder hemiarthroplasty for the treatment of three and four part fractures of the proximal humerus using Comprehensive(R) Fracture stem. *IntOrthop*
- [28] Smith, A. M., R. M. Mardones, J. W. Sperling, and R. H. Cofield. 2007. Early complications of operatively treated proximal humeral fractures. *J Shoulder Elbow Surg* 16:14-24.
- [29] Stiehl, J. B. 2006. Extended osteotomy for periprosthetic femoral fractures in total hip arthroplasty. *Am J Orthop (Belle Mead NJ)* 35:20-23.
- [30] Voos, J. E., J. S. Dines, and D. M. Dines. 2010. Arthroplasty for fractures of the proximal part of the humerus. *J Bone Joint Surg Am* 92:1560-1567.
- [31] Wretenberg, P., and A. Ekelund. 1997. Acute hemiarthroplasty after proximal humerus fracture in old patients. A retrospective evaluation of 18 patients followed for 2-7 years. *ActaOrthopScand* 68:121-123.
- [32] Young, S. W., B. S. Segal, P. C. Turner, and P. C. Poon. 2010. Comparison of functional outcomes of reverse shoulder arthroplasty versus hemiarthroplasty in the primary treatment of acute proximal humerus fracture. *ANZ J Surg* 80:789-793.
- [33] Zyto, K., M. Kronberg, and L. A. Brostrom. 1995. Shoulder function after displaced fractures of the proximal humerus. *J Shoulder Elbow Surg* 4:331-336.

