

We are IntechOpen, the world's leading publisher of Open Access books Built by scientists, for scientists

6,900

Open access books available

186,000

International authors and editors

200M

Downloads

Our authors are among the

154

Countries delivered to

TOP 1%

most cited scientists

12.2%

Contributors from top 500 universities



WEB OF SCIENCE™

Selection of our books indexed in the Book Citation Index
in Web of Science™ Core Collection (BKCI)

Interested in publishing with us?
Contact book.department@intechopen.com

Numbers displayed above are based on latest data collected.
For more information visit www.intechopen.com



“Neck-Sparing” Total Hip Arthroplasty

Lee E. Rubin, Scott A. Ritterman and
Timothy McTighe

Additional information is available at the end of the chapter

<http://dx.doi.org/10.5772/54830>

1. Introduction

Advanced arthritis of the hip joint can lead to profound changes in quality of life. Debilitating pain, stiffness, and altered gait biomechanics all affect the ability to stay mobile and maintain gainful employment; these concerns are magnified in younger patients with hip disease. While symptomatic hip arthritis typically affects older patients, there is a growing subset of active patients in their 30s, 40s, and 50s who are affected and were previously thought of as, “too young for a hip replacement.” Over the last several decades, advances in hip replacement surgery are allowing us to rethink that position.

A total hip replacement is one of the most reliably successful procedures in orthopaedics. Long term data has shown that with a well positioned modern prosthesis we can give our patients reliable pain relief that has a very high chance (>80% in most cases) of lasting over twenty years[1, 2]. While this may be very comforting to a 75 year old retired patient with relatively low functional demands, twenty year survival will not suffice for patient in their 30s with advanced arthritis. For this reason in the past, many surgeons were reluctant to perform joint replacement surgeries in young patients for fear of condemning them to multiple revisions over a lifetime of use.

Recent literature on the revision-free survival rates for modern hip implants have shown remarkable success, with 10-year survival rates of 100% for a variety of press-fit, uncemented femoral stem designs at a mean time of 8.2 years from surgery.[3] A 2012 award-winning study from the American Association of Hip and Knee Surgeons showed 100% survival for cross-linked polyethylene bearing surfaces at 10 year follow-up[4]. Another recent paper, looking at the 10-year analysis of various bearing couples, showed respective survival rates of 98.4%, 95.6%, and 87.9% for metal-on-polyethylene, ceramic-on-ceramic, and metal-on-metal groups.

[5] The outstanding results of modern implants and bearing surfaces have given surgeons new confidence when facing the challenging of hip arthroplasty in a young, active patient.

The ideal hip replacement prosthesis for a young patient has several important elements. It would be easily integrated, forming a long lasting bond with the host bone, yet be easily removed if needed. Another aspect of the modern hip prosthesis that has evolved is the actual design of the femoral implant itself. Several implant designs on the market are 'bone sparing,' meaning that less bone is taken off of the head/neck of the femur. Over the past decade, hip resurfacing was a popular procedure in this regard. In a resurfacing procedure, the femoral neck and much of the head are left in place. A metal cap is placed on the end of the femoral head and a metal cup is placed in the acetabulum. Resurfacing procedures have fallen out of favor recently for several reasons, including the difficulty of placing the prosthesis as well as concerns with metal-on-metal articulations.

2. Neck sparing arthroplasty

A "neck-sparing" or "bone-sparing" prosthesis is not a new concept but is one that has been gaining in popularity. This prosthesis is similar in design to other modern prosthesis but preserves more native bone in the femoral neck of the patient during femoral preparation. With a similar idea to the resurfacing, the hope is to allow placement of an implant while leaving a viable option for revision at a later date. These prostheses are proximally porous coated; after the femoral bone cut is made, more femoral neck bone is left in situ, and the proximally coated implant loads and helps maintain this "extra" bone over time. Any modern bearing surface can be utilized by the surgeon. This novel design saves a significant portion of native host bone and will lead to theoretically easier revision surgery when the time comes. A small saw can be slipped around the neck of the prosthesis and the "extra" bone is removed, allowing revision to a primary hip implant rather than the traditional, extensive revision implants currently in use today.

The level of the femoral bone resection varies based on the arthroplasty technique. (Figure 1) A native right proximal hip is visible in Figure 1.1. In hip resurfacing (1.2 A) and "mid-head" resurfacing (1.2 B) (available in Europe), most of the femoral bone is retained. With neck sparing arthroplasty (1.2 C) and conventional total hip arthroplasty (1.2 D), progressively more bone is resected during the operation. With hip revision surgery, native bone is often eroded, leading to an even lower bony resection level (1.2 E). "Neck-sparing" implants allow the surgeon to retain the native bone between cut levels C and D (Figure 1.3), with the concept of native neck bone stock preservation for future revision surgery in the young patient.

The idea of neck retention is not a new concept. Freeman, Townley, Whiteside and Pipino have all advocated saving the femoral neck since the 1980s. Freeman is credited with his classic article "Why Resect The Neck?" as the Godfather of neck retention[6]. His stem retained the femoral neck but was a conventional length straight stem that engaged both the metaphysis and diaphysis. The original stem was designed for cement fixation, with subsequent modifi-

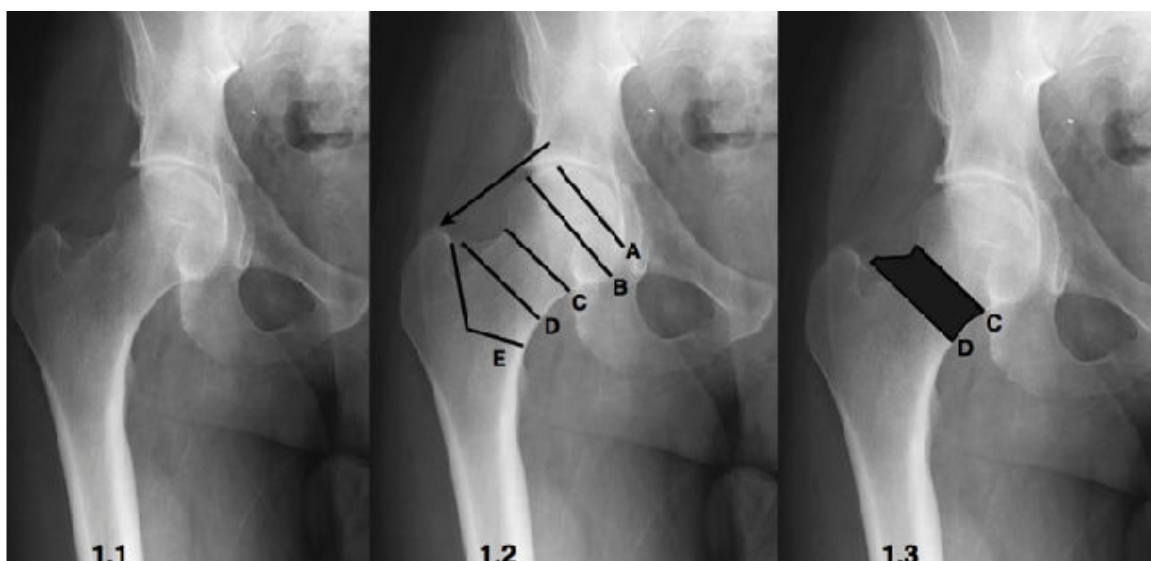


Figure 1. 1.1) Native right proximal hip. 1.2) Bone resection levels for hip resurfacing (A), mid-head resurfacing (B), neck-sparing arthroplasty (C), conventional total hip arthroplasty (D), and revision hip arthroplasty (E). 1.3) Illustration of native bone preserved during neck sparing arthroplasty compared to conventional total hip arthroplasty.

cation to introduce a cementless style stem that was of the same stem length and geometric shape with HA coating, as seen in Figure 2.

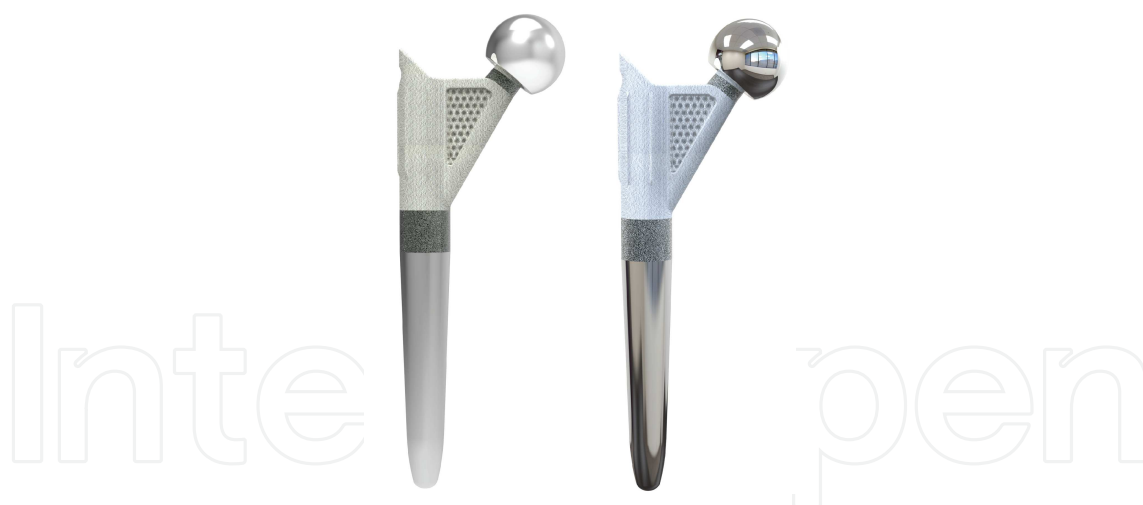

Figure 2. Freeman Femoral Stems. Left: Cemented Right: Cementless

Townley and Whiteside also designed conventional length straight stems that retained the femoral neck, but it was Professor Pipino who first advocated the short curved neck sparing stem to be stabilized by fit and fill of the femoral neck as a cementless press fit stem in 1979. He is also credited with term "tissue-sparing," referring to both saving hard and soft tissue as a surgical strategy. His Biodynamic hip prosthesis was implanted from 1983 to 1996 (Figure 3 Left), until it was replaced by the modified CFP hip stem (Figure 3 Right) Pipino reported

outstanding results of his stem design, with 97% satisfactory radiographic results and an implant survival rate of almost 100% at 25 years.[7]

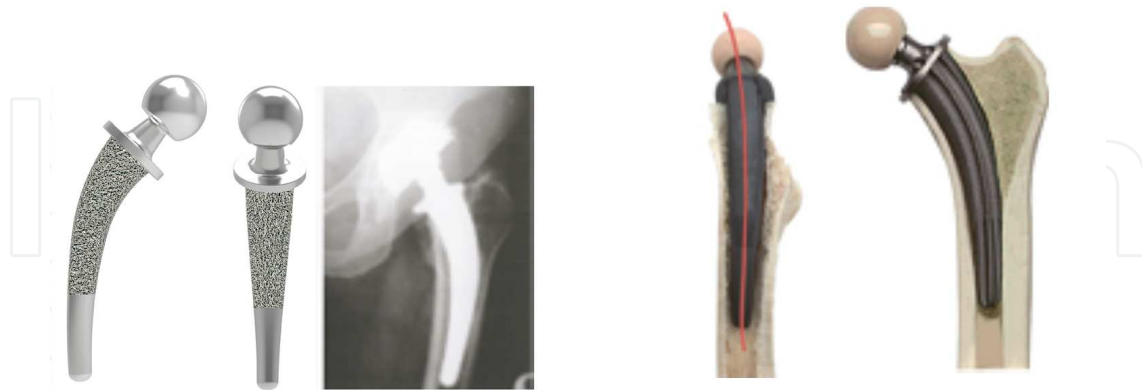


Figure 3. Left: Biodynamic c.c. stem by Howmedica, Right: CFP Stem by Link.

The CFP prosthesis stem is made of titanium alloy, a material better suited for cementless fixation than cobalt-chromium alloy. The left and right stem versions with built-in anatomical anteversion were adapted to the normal anatomy of the proximal femur. The left and right stems were available in six stem sizes along with two stem curvatures; the stem featured bilateral longitudinal ribs to increase surface contact and oppose torsional forces.

To promote osseointegration, the CFP stem has a 70 μm microporous surface with the exception of the short distal portion. In addition, the microporous surface is provided with a special 20 μm hydroxyapatite (calcium phosphate) coating which does not seal the surface but keeps the porous structure intact.

3. Biomechanics of neck sparing stem designs

The natural trabecular pattern of the bone and the trabecular orientation provide support against the natural functional loading, thus creating the necessary functional stability of the individual bone areas within the proximal femur. (Figure 4) The femoral neck and the adjoining medial aspect of the femur in the calcar region show the strongest bone structure with a high load capacity to support the stem. (Figure 5)

Femoral neck retention reduces both torsional and bending moments (forces) at the stem / bone interface. In accordance with Wolff's Law, the reduction of stresses relative to the natural situation would cause bone to adapt itself by reducing its mass, either by becoming more porous (internal remodeling) or by getting thinner (external remodeling).

In Figure 6, The neck on the left has been resected at the conventional level; in the one on the right the neck has been retained. Because the difference in the height of resection the length of the moment arms, the varus- turning moment increases by a factor of four when the neck is

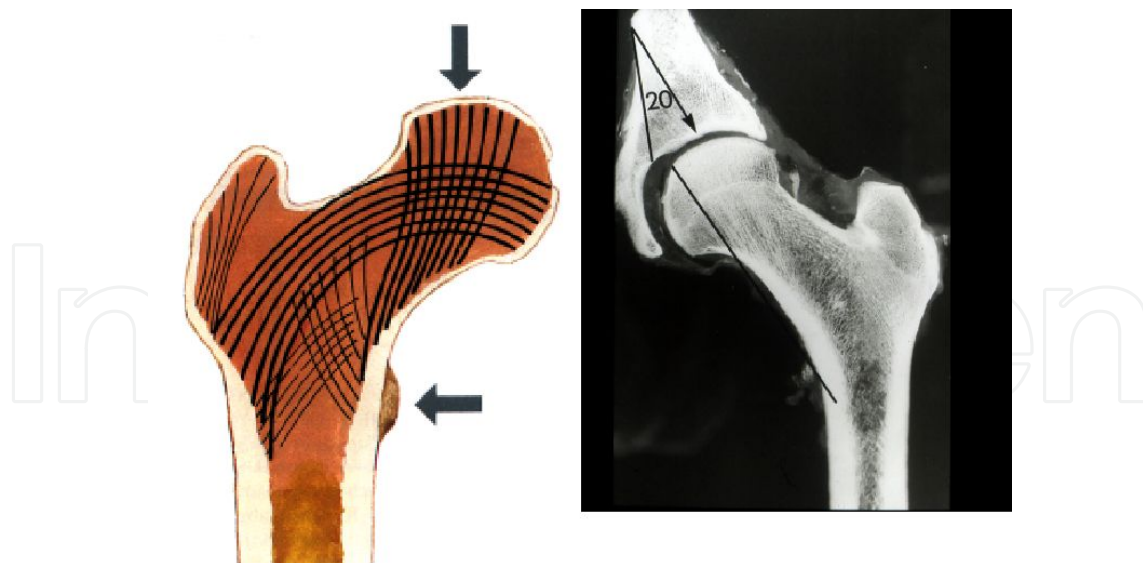


Figure 4. Trabecular bone patterns

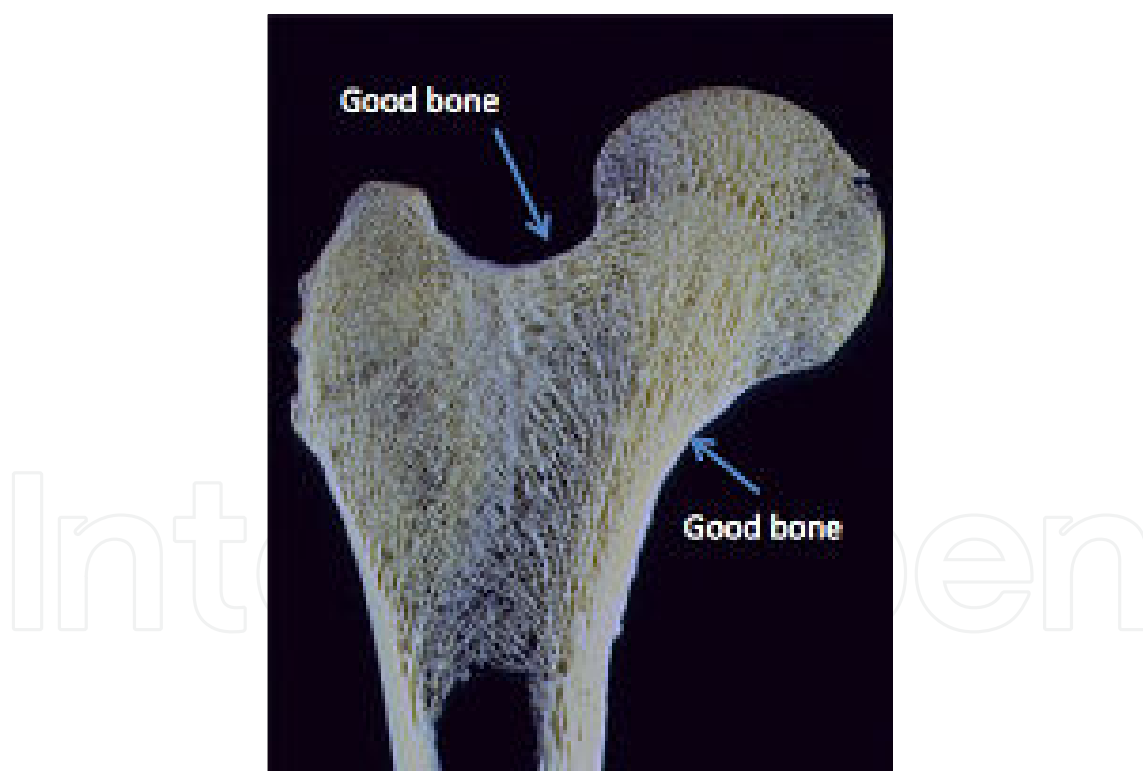


Figure 5. Cross section of the proximal femur

resected (Figure 7). At the same time the area of bone available for supporting the vertical component of the resultant of the forces acting on the implant is almost tripled

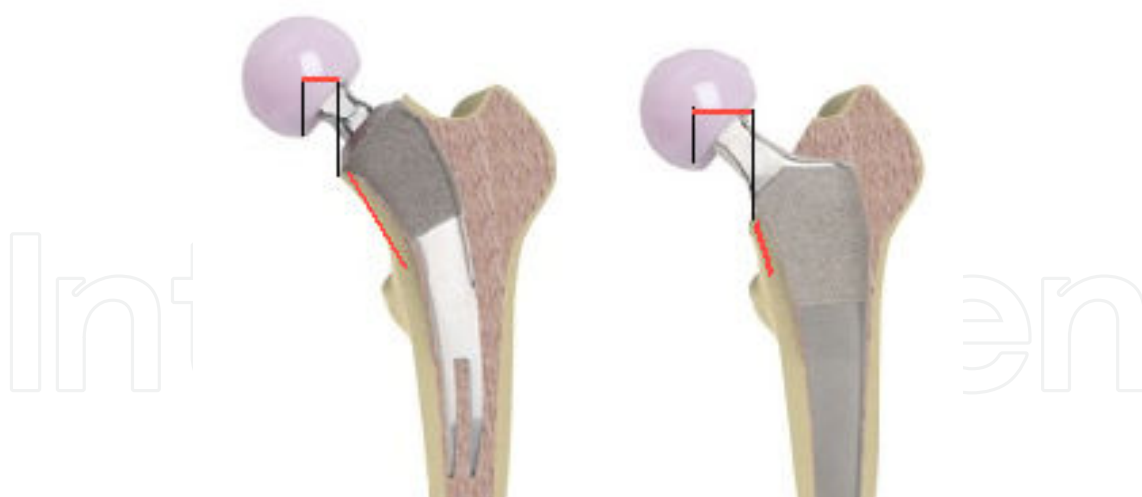


Figure 6. Illustrations comparing neck retention to conventional neck resection bending moment.

The anterior-posterior directed component of the resultant force is represented by an arrow. Neck resection generates a significant torsional moment.




Figure 7. Varus /Valgus turning moment in neck retention vs. conventional neck resection

It is important to remember that not all neck-sparing stems are not all short neck stabilized stems. Historically, neck sparing stems were not short curved neck stabilized by design (Figure 8).

To-date, most neck-sparing stems have been somewhat disappointing in their long-term ability to stimulate and maintain the medial calcar. For that reason, a new short stem neck stabilized design approach was undertaken to improve proximal load transfer and to create a bone or tissue sparing stem that would be simple in design, amenable to reproducible technique and provide for fine tuning joint mechanics while stimulating and maintaining ongoing, in-vivo compressive loads to preserve the medial calcar.



Figure 8. Left: Townley Platform Stem. Right: Whiteside Neck Sparing Stem.

4. "Short" hip arthroplasty stems

The use of short stems is growing. Initial short and mid-term follow up studies of a number of these stems suggest that stable, durable fixation and excellent clinical outcomes can be achieved. As a result, a very large number of short stem designs are available. Until recently, there was no classification system for uncemented short stem implants that would allow for comparisons of clinical and radiographic results.

A number of advantages have been argued to justify the design and clinical usage of short stems; Elimination of femoral proximal-distal mismatch, tissue preservation (hard & soft), facilitation of less invasive surgical exposures, less invasive surgical violation into the femoral canal, less violation into the trochanteric bed, improved proximal bone remodeling, less intraoperative blood loss, less postoperative rehabilitation, less instrumentation and less inventory cost.

All of these advantages are worthwhile if they can be proven to be significant benefits to the clinical outcome and increased survivorship of the device. The real question is can these shorter length devices obtain strong and long-lasting stability of the implant without diaphyseal anchoring?

The European experience with certain styles of conservative designs are years ahead of the U.S. experience. So it is reasonable to look towards Europe for both trends and early to mid-term clinical results. Some of these devices are not available in the U. S. and some are new to their clinical experience. As a result, the Joint Implant Surgery and Research Foundation

(JISRF) developed a short stem classification system based off stabilization contact for implant stability.[8]

JISRF developed this classification system to help identify, differentiate and catalog short stemmed total hip implants by primary stabilization contact points. Not all short stems generate the same radiographic findings and or clinical results. It is also important to appreciate the specific design and appropriate surgical technique for a given design. We believe this classification system helps to clarify some of the design principles and clinical findings. While there will be subcategories within the main categories, (Examples: Neck plugs versus short curved neck stems) but the primary stabilization point determines the same overall category.

5. JISRF classification system for short stems: Implant examples

1. Head Stabilized

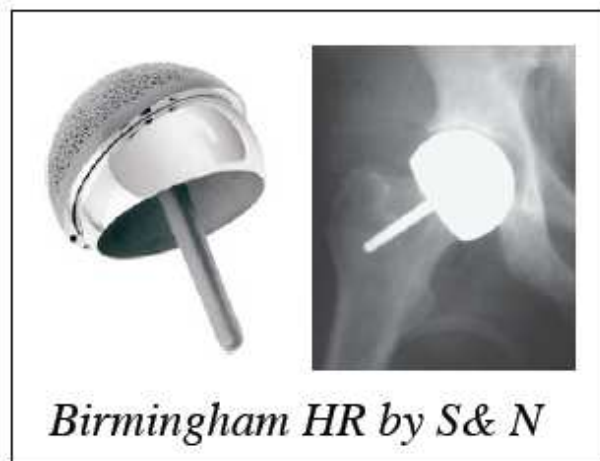

Figure 9. Hip Resurfacing Arthroplasty and “Mid-Head” Resurfacing Arthroplasty (Birmingham System, Smith and Nephew)

2. Neck Stabilized, Figure 11:

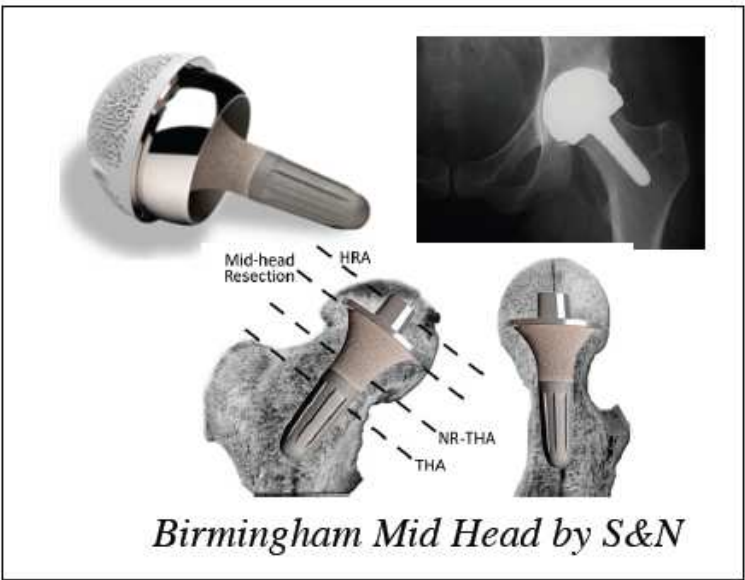

Figure 10. Hip Resurfacing Arthroplasty and "Mid-Head" Resurfacing Arthroplasty (Birmingham System, Smith and Nephew)

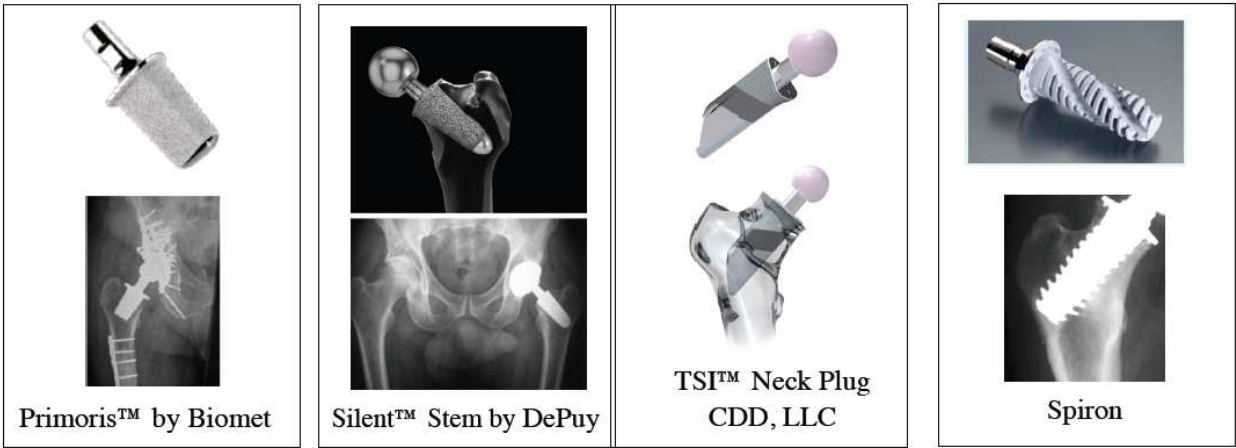


Figure 11. Metaphyseal Stabilized

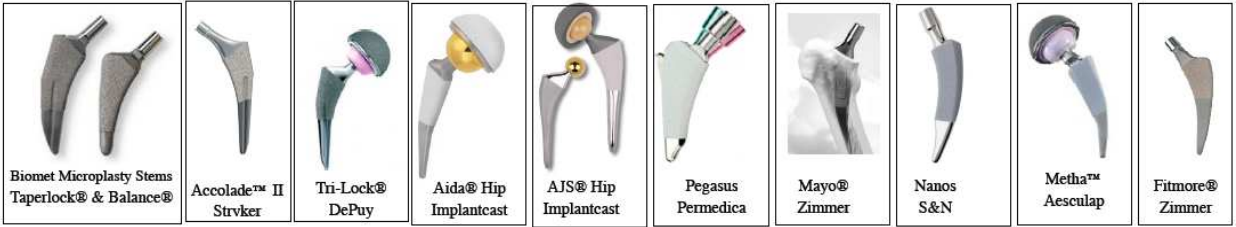


Figure 12. Conventional (Metaphyseal/Diaphyseal) Stabilized: Traditional Arthroplasty Stems

6. Current design rationale for a modular, short, curved neck stabilized stem

Stem Design:

The TSI™ Stem is a simple short curved trapezoidal neck sparing design that is tissue conservative (hard & soft) and features a number of unique and novel elements to improve upon short and long-term survivorship. This novel design has been licensed by Concept, Design and Development, LLC., in Chagrin Falls, Ohio to two commercial partners and has been introduced into the Australian market as the MSA™ Stem and the United States as the Apex ARC™ Stem. (Figure 13)



Figure 13. Left: The MSA™ Stem; Right: The Apex ARC™ Stem

The basic curvature of the stem comes from the historical work of Thompson and Müller. A side-by-side comparison of the Müller rasp and the ARC™ stem are seen in Figure 14. The medial curve and overall stem length are almost identical.

This simple, yet novel, stem design allows for considerable tissue conservation of both hard and soft tissue. Native bone is preserved in Gruen zones 7, 3,4,5 and zone 1, as seen in Figure 15.

The medial curve reduces the need to remove lateral bone, where one can risk damage to the musculature and increased bleeding by removal of cancellous bone in the greater trochanter (Figure 31). The stem shape is based on a curved trapezoidal design that is intrinsically stable within the cylindrical femur. The torsional stability is enhanced by a lateral “T-Flange” feature,

however, this has proven to be too aggressive in the small female profile and has been removed on the size 0 stem.

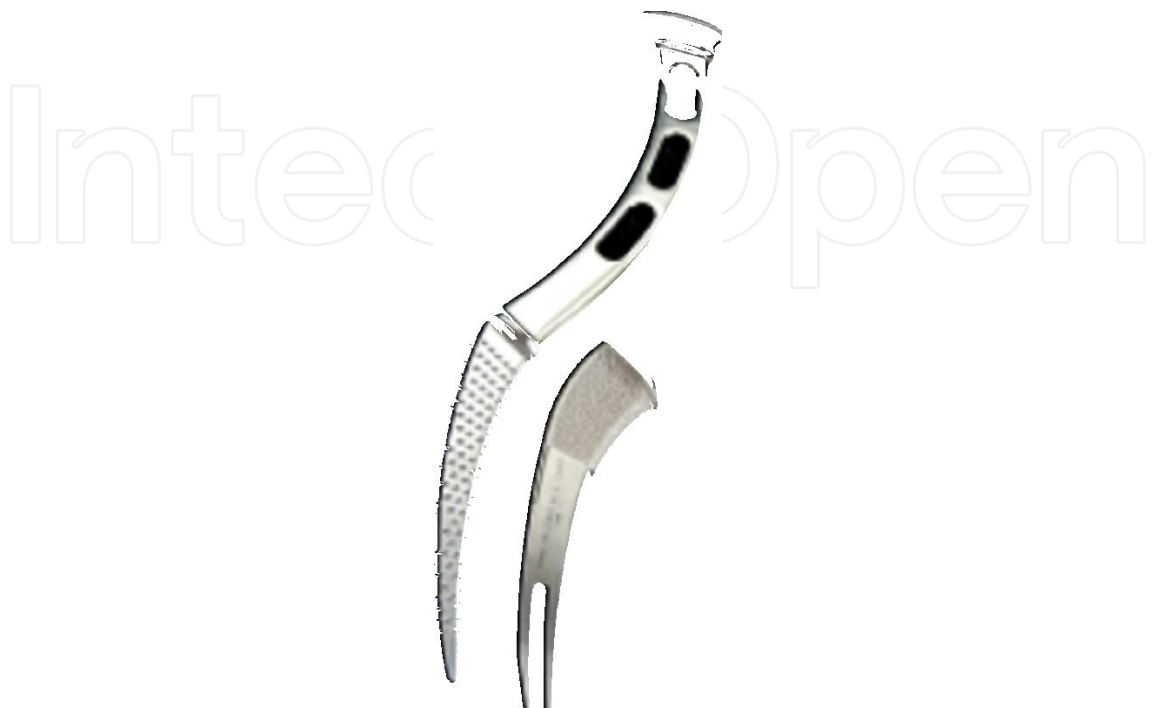

Figure 14. Image of historic Mueller proximal femoral rasp (left) placed adjacent to modern TSI neck-sparing arthroplasty implant (right).

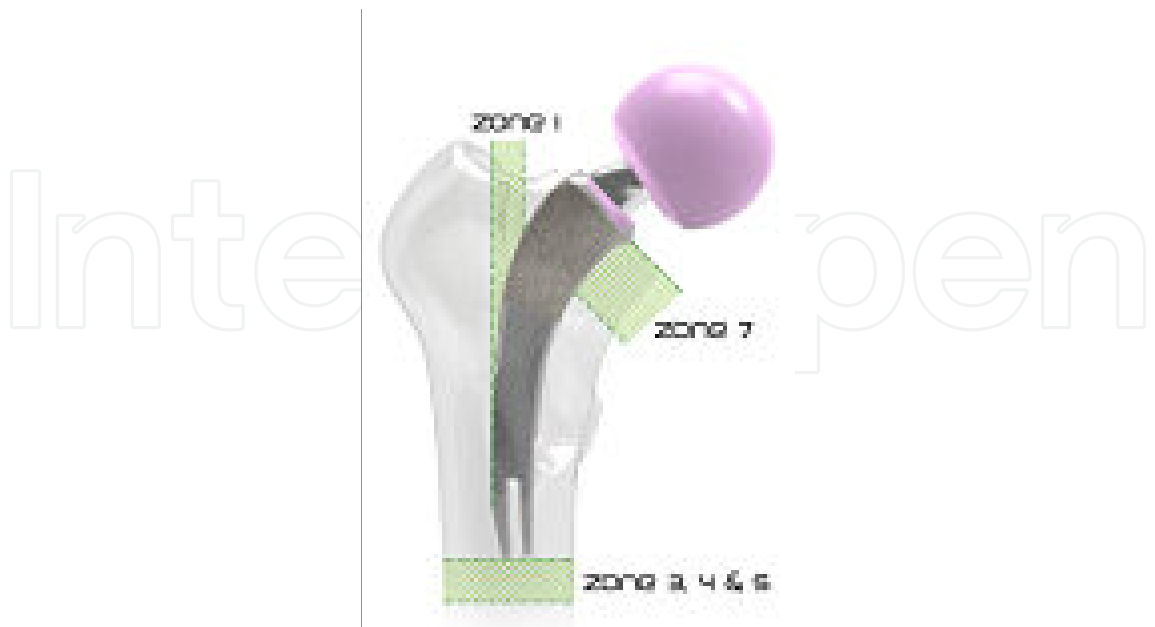

Figure 15. Image demonstrating areas of bone preservation maintained with neck-sparing arthroplasty, including Gruen Zones 1, 3, 4, 5, and 7.



Figure 16. Key Design Features of the ARC™ stem.

A porous titanium coating is applied circumferentially to the upper third of the stem and is a combination of commercially pure titanium applied first using a plasma spray process after which a thin layer of hydroxyapatite (HA) is also applied using a plasma spray process. The proximal portion of the stem also has a patent pending novel conical flair element that is design to off load compressive loads to the medial calcar. (Figure 17) This very unique feature has demonstrated positive stress transfer in both FEA modeling and now clinical observations.



Figure 17. Medial Flare seen on the lateral profile in 3-Dimensional stem rendering

A lateral distal relief of 11° reduces any distal tip contact with the lateral cortex if the stem is in a slight varus position. The sagittal slot reduces distal stiffness reducing the potential of distal load transfer and reduces hoop tension in type A bone by allowing stem to pinch in.

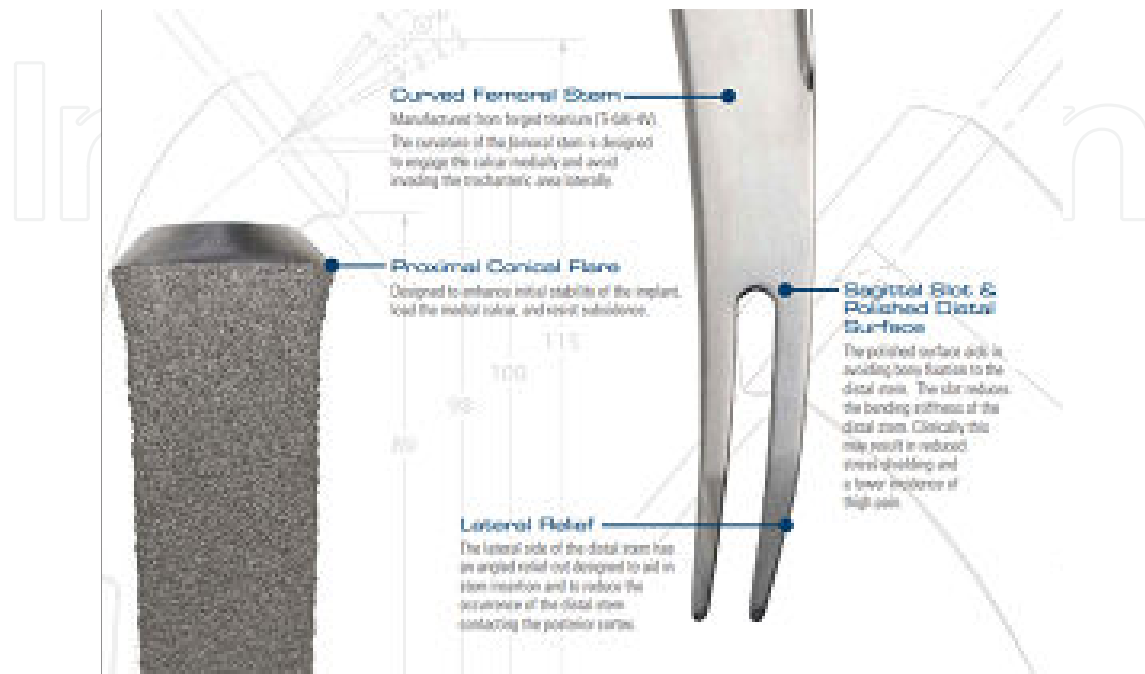


Figure 18. Additional Design Features of the ARC™ stem.

The TSI™ neck stabilized stem with a modular cobalt-chrome neck has demonstrated a reduction of maximum principal tensile stress in the neck stabilization stem was 35% less than that of a monoblock taper style design. (Figure 19) With regards to potential failure mode, the neck sparing feature with a short cobalt-chrome modular neck has basically eliminated potential fatigue failure of the neck, as opposed to other recent titanium modular neck designs that have demonstrated catastrophic fatigue fractures.[9]

7. Stress in the femoral component

The ring of cortical bone saved in the neck sparing stem has significant bio-mechanical advantage. Pipino refers to this as a "tension band." (Figure 20) The principal stress measured in the femoral component was lowest for model with cortical neck ring intact compared to the monoblock conventional cementless stem. (Figure 21)

The stress in the distal femur slightly reduces with the TSI neck sparing stem and reduces even more if the cortical rim remains intact. This data supports the concept that the medial conical flair does offload compression to the proximal femur especially if the cortical ring is intact.

The short TSI™ stem demonstrates better loading patterns as compared to Pipino's first stem (Biodynamic), (Figure 22) which was made of cobalt-chrome material. The x-ray on the right

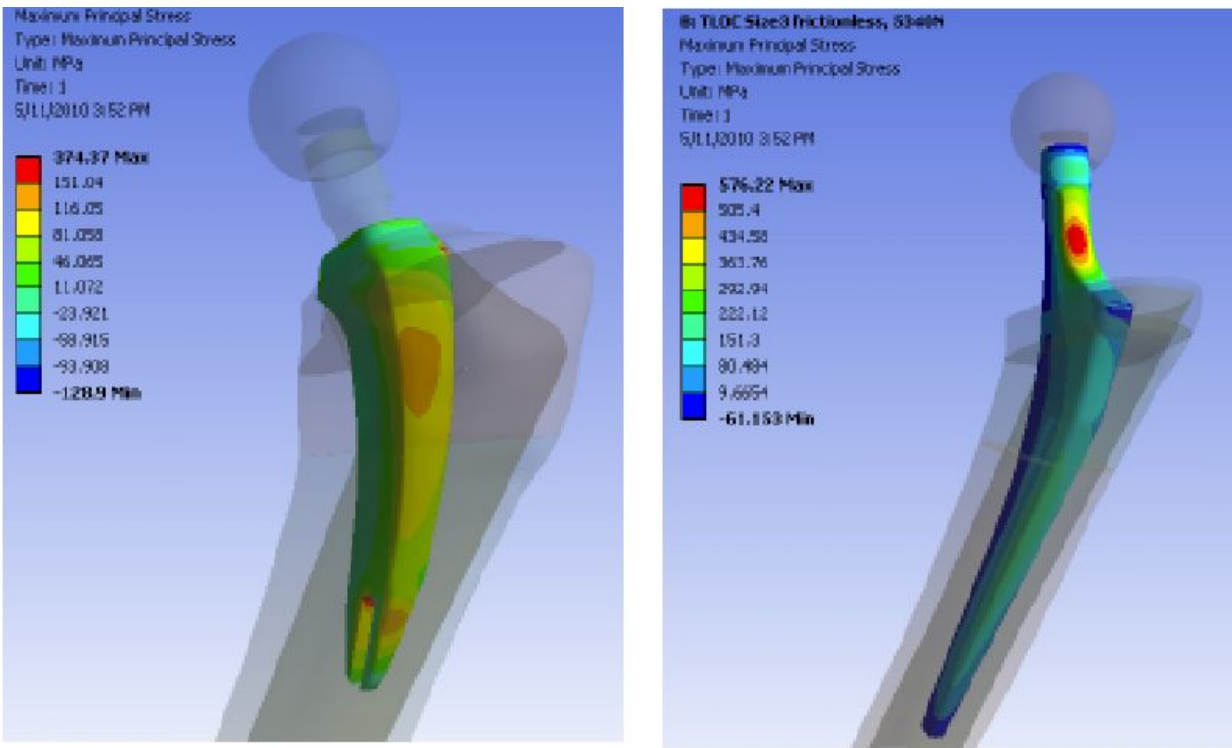


Figure 19. Finite Element Analysis of a short neck-sparing arthroplasty stem (left) compared to a monoblock stem (right). Increased areas of stress foci are highlighted in red.

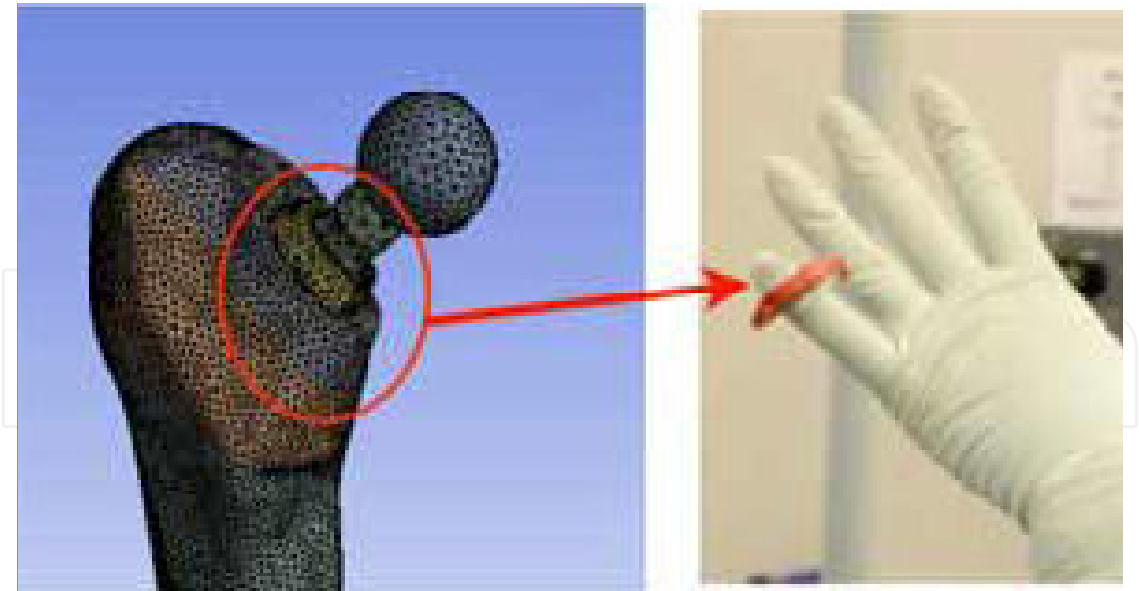


Figure 20. Ring of Proximal Femoral Bone

side of Figure 22 is his current stem CFP which still has had some medial calcar bone resorption issues.

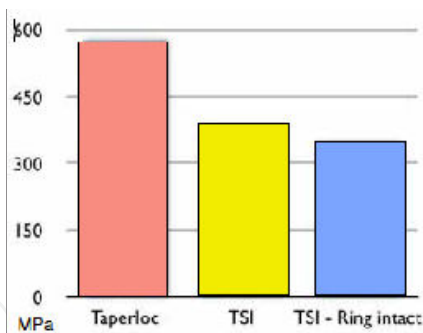


Figure 21. Assessment of proximal femoral stress with axial loading

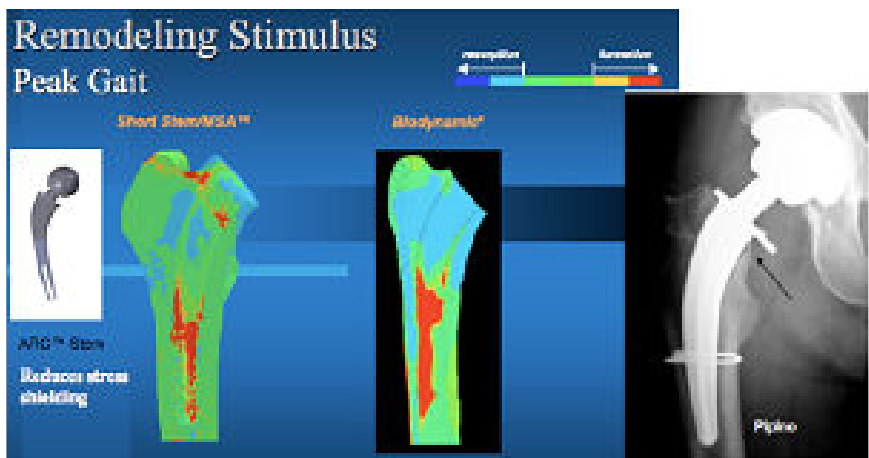


Figure 22. FEA Modeling of ARC™ (Left) compared with the Biodynamic stem (Right), showing normalized loading of the medial calcar on the left, and decreased loading on the right.

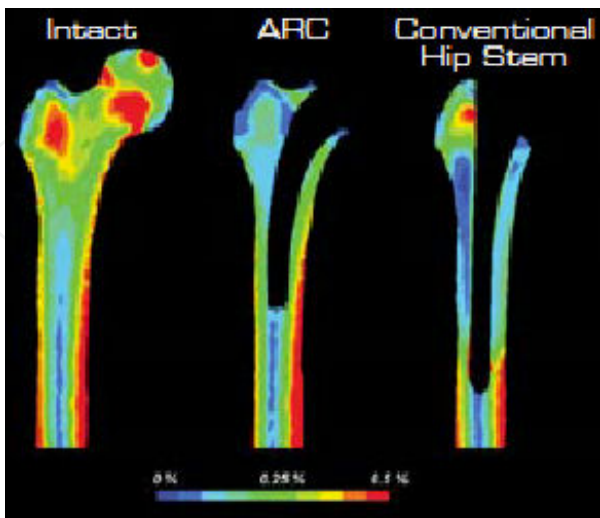
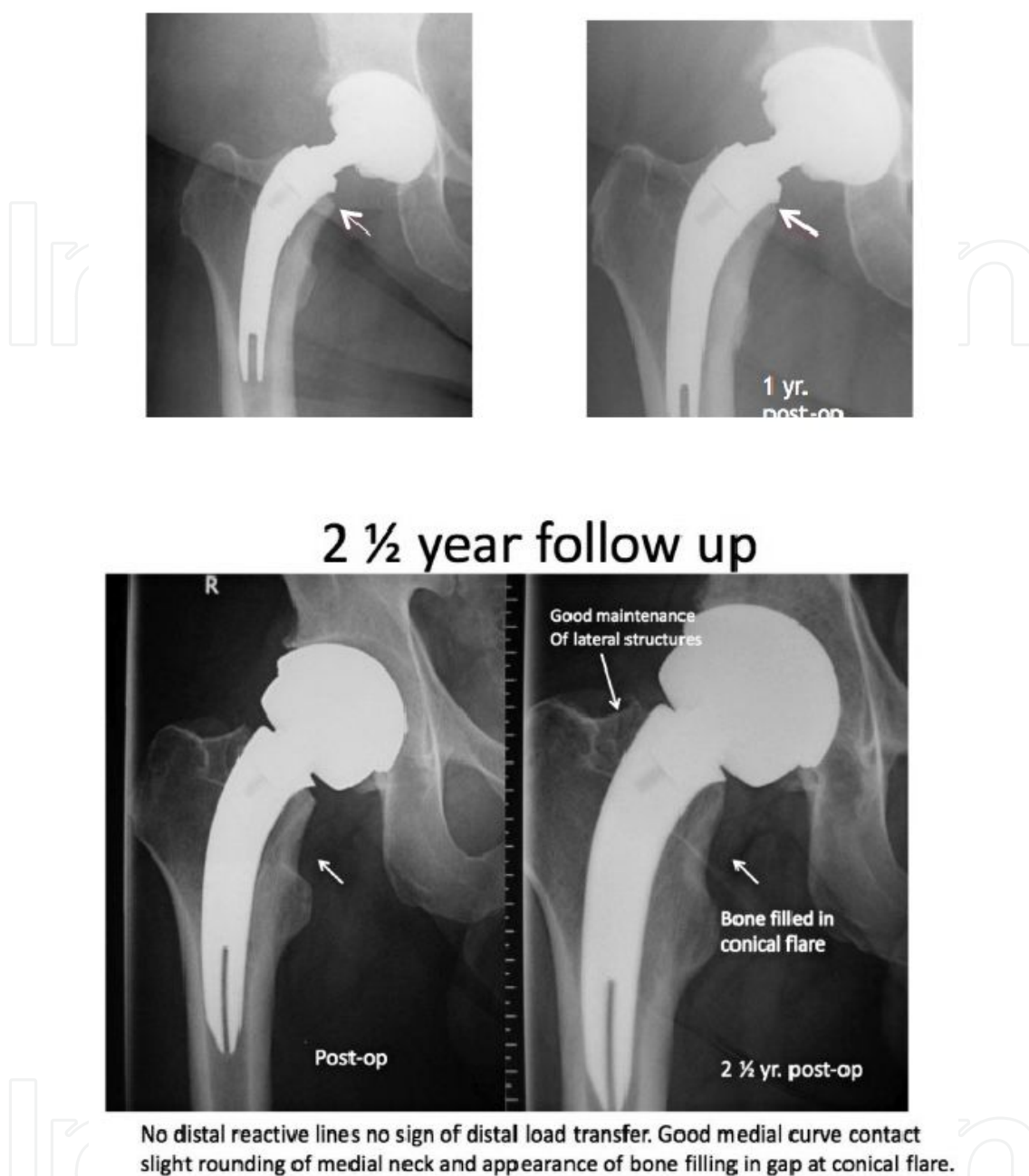


Figure 23. FEA Modeling of an intact femur (left), the ARC™ stem (Center) and a long, extensively coated press-fit stem (right), demonstrating improved proximal strain patterns compared to the AML style conventional cementless stem.



Prof. Ian Woodgate, Sydney, Australia

Figure 24. A and B: Clinical case examples of favorable bone remodeling from the ARC™ stem

8. Proximal neck modularity

Target Restoration of hip mechanics is aided by proximal neck modularity, especially focused on femoral offset, neck length, and combined version. Using monoblock femoral stem designs,

restoration of hip mechanics is difficult to address. Often, accomplishing intra-operative joint stability comes with an increased risk for over-lengthening..

Neck Modularity allows intraoperative fine tuning of joint mechanics, reducing risk of impingement and mitigating risk of accelerated wear and dislocation. This principle also aids in access in the event of acetabular revision. Monoblock hip stems are based on proportionality of design. As the stem gets bigger, the neck gets longer. Unfortunately, this scenario is not consistent with the variability seen with proximal femoral geometry, and is illustrated with the radiographs seen in Figure 25.

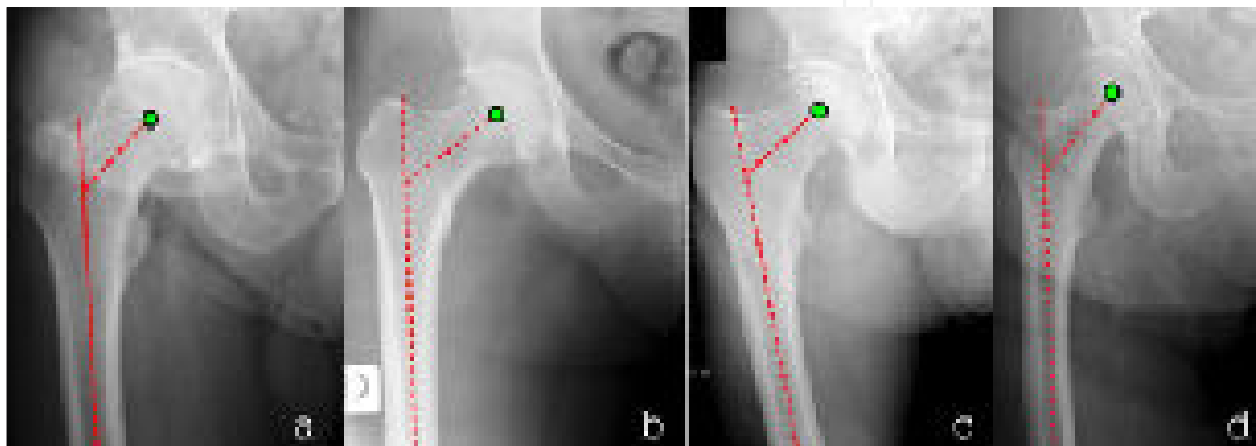


Figure 25. Anatomic variations commonly associated with primary osteo-arthritis patients using a monoblock stem: a: large canal, short neck, low offset, b: thin canal, long neck, high offset, c: large canal, short neck, high offset, d: thin canal, long neck, low offset

Femoral head center location data (Figure 26) shows that a wide variety of offsets and lengths are required to properly balance the soft tissues, but there is often little correlation between head center and stem size. A significant number of small stem diameters (10 or 11.5 mm) required large >45 mm femoral offsets.

One only has to review actual usage data on modular necks to validate the need of proximal modularity. A review of ARC™ Modular Neck Experience (Figure 27) on 1,640 stems implanted from April 2010 to August 2012 demonstrated that a significant variety of stems were selected by surgeons while using the device to fine-tune the biomechanics of the hip joint in vivo.

9. Clinical utilization and outcomes

Case One: A 29 year-old man presented with the acute-onset of debilitating pain in his left hip from osteonecrosis with collapse secondary to chronic steroid use for immunosuppression of severe lupus. (Figure 28). His symptoms developed over 4 weeks and were incapacitating, requiring the use of two crutches and high doses of long-acting narcotic for comfort.

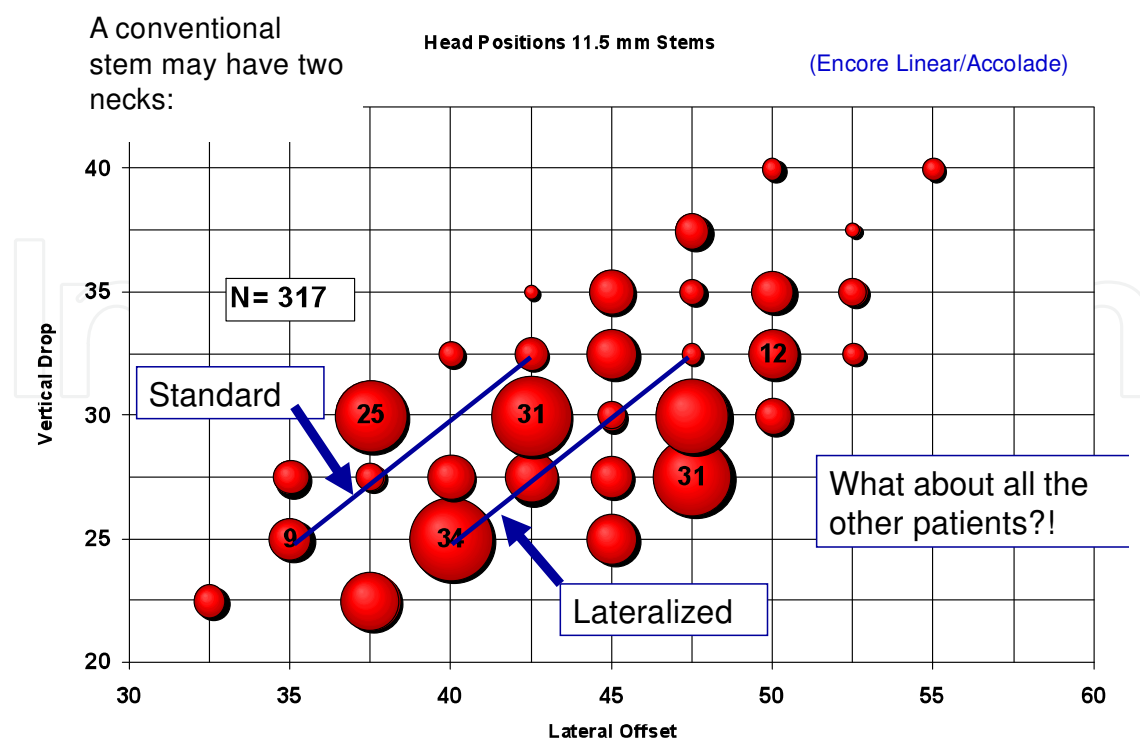


Figure 26. Femoral head location data, mapping a relationship of femoral implant sizing related to vertical drop (vertical axis) and lateral offset (horizontal axis). Most conventional femoral stems are available only in “standard” and “lateral” offsets, which do not match the variety of combined values seen in native anatomy.

Neutral Neck Standard = 33%
 Neutral Neck Long = 3% new size
Total Neutral Necks = 36%

8°Varus/Valgus = 19%
 8°Varus/Valgus Long = 3%
Total 8°Varus/Valgus = 22%

12°Varus Valgus = 17%
 12°Anteverted/Retroverted = 30% new size
Angled Necks Total = 47%

Figure 27. ARC™ modular neck utilization data, from April 2010 to August 2012.

He was treated with total hip arthroplasty using a neck sparing implant and a ceramic on cross-linked polyethylene bearing surface couple. The implants were inserted via the direct anterior approach with a “bone-sparing technique” allowing retention of 1.5 cm of his proximal femoral bone, with anatomic restoration of his hip center of rotation (Figures 29 and 30). His postoperative course showed complete resolution of his pain with elimination of narcotic use, dramatic improvement in his hip function, and he was able to begin returning to work as a professional chef after less than 8 weeks of recovery.

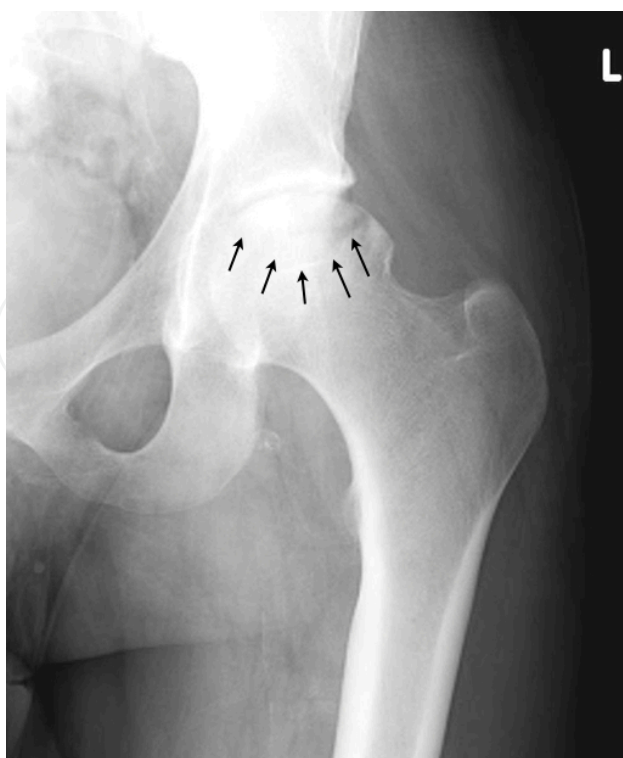

Figure 28. Left Hip Joint with AVN and acute collapse of the dome of the femoral head, indicated by arrows.

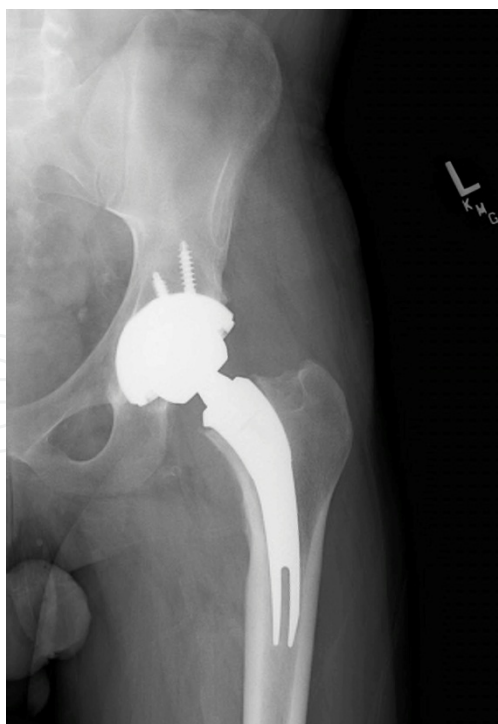


Figure 29. Postoperative AP Left Hip, Showing ARC™ "neck-sparing" arthroplasty in an anatomic position with restoration of hip alignment, offset, and position.

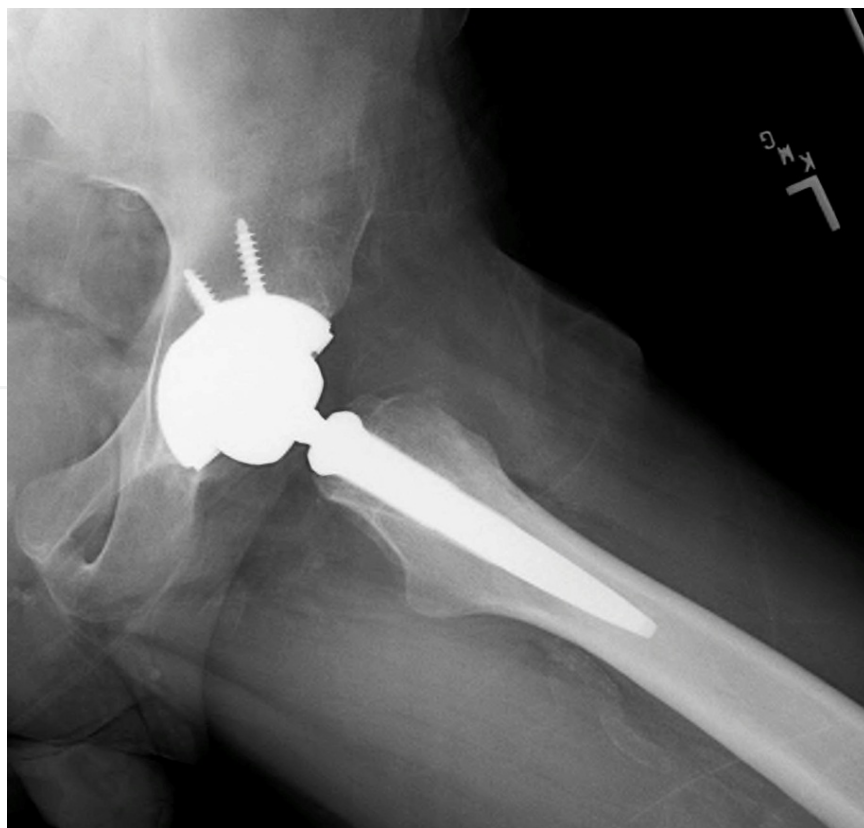

Figure 30. Postoperative Lateral Left Hip demonstrating anatomic prosthesis positioning.

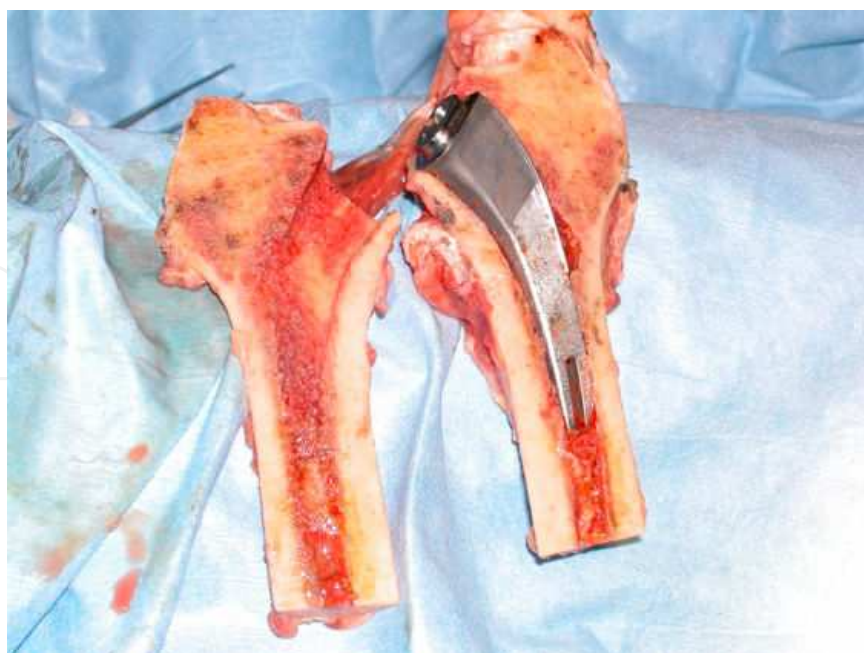

Figure 31. Coronal cross-section of cadaveric left proximal femur, demonstrating neck-sparing prosthesis position along medial calcar, with retained femoral neck and conservation of native trochanteric bone visible.

Case Two: A 32 year-old man presented for evaluation after having been previously diagnosed with advanced bilateral osteonecrosis of his proximal femoral heads. His management had already included a comprehensive medical and metabolic workup to assess for causes for the avascular necrosis, but none had been elucidated. He denied any known exposure to high dose corticosteroids and had no history of alcohol intake. He had previously undergone core decompression procedures at an outside institution on both the right hip (18 months prior) and the left hip (14 months prior) in the recent past, without any significant improvements in his clinical function or symptoms. He underwent simulateneous, bilateral neck-sparing THA, and is walking normally once again after a brief course of rehabilitation. The specific details of his case were described in detail elsewhere.[10]

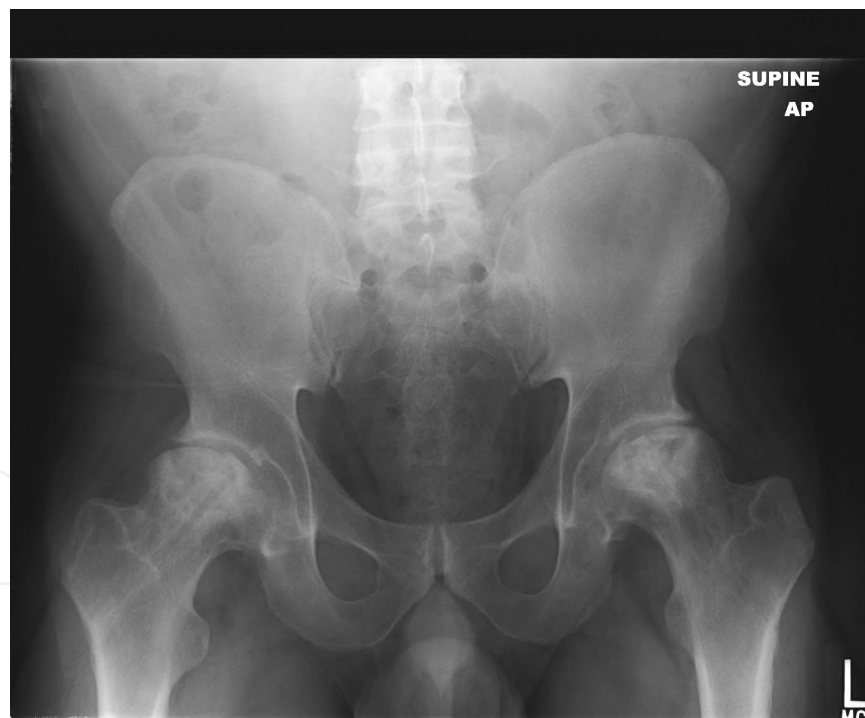


Figure 32. Preoperative AP Pelvis of a 32 year-old male with severe, bilateral, osteonecrosis with associated femoral head collapse and secondary arthrosis.

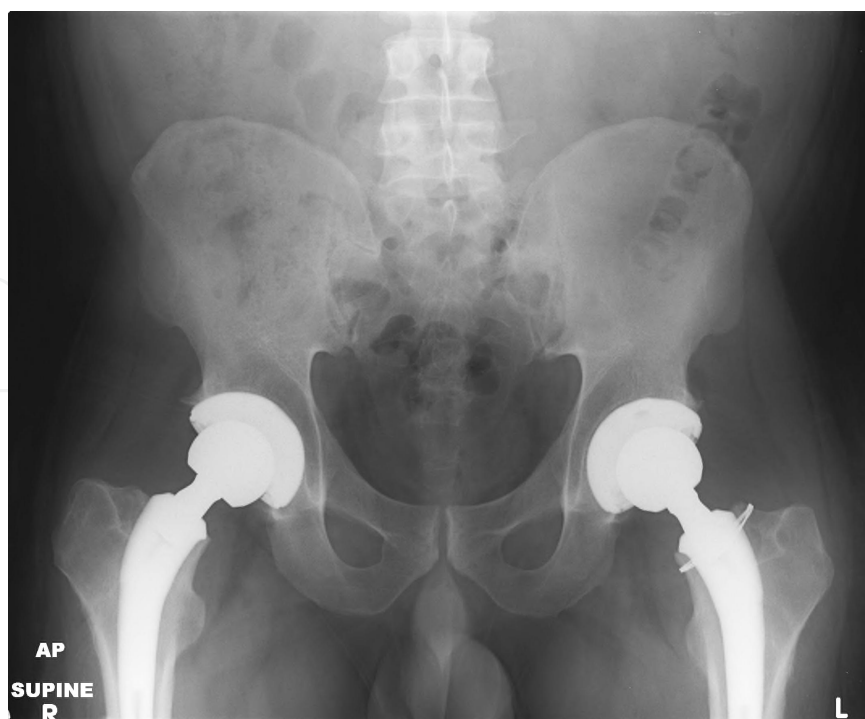


Figure 33. Postoperative AP Pelvis

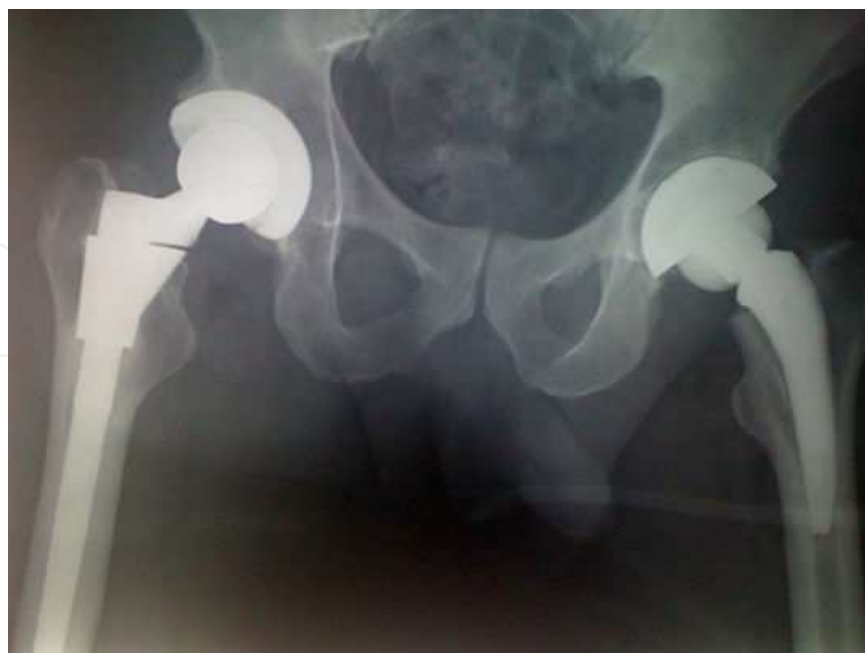

Figure 34. Comparison of historic versus modern femoral stem modularity. Right hip: S-ROM Prosthesis, 1984; Left Hip ARC™ Stem, 2012. (Image Courtesy Louis Keppler, MD and JISRF.)

10. Short-term results of TSI and ARC™ femoral stem

Since the introduction of these modular, short, neck-sparing femoral stem designs, the early results of implant utilization have been tracked by their manufacturers and JISRF.[11]

With 1,970 stems implanted worldwide, There have been only 8 stem explants, and an overall femoral stem survival of 99.5% at 29 months. There were 2 traumatic and 1 chronic dislocations, 2 cases of aseptic loosening, 2 infections, and 1 neck/stem disassociation. 10 cases had a leg length discrepancy greater than 7mm. 6 cases had an iatrogenic calcar fracture, and 3 required wiring. 6 patients had subsidence more than 5mm. There were 3 neck exchanges, with 2 performed for cup revisions. There were 3 intra-operative femoral perforations, and 5 cases that of intra-operative calcar fractures resulting in stem bail-out. There have been no known cases of pseudotumors, no elevated peripheral metal ion levels, and no known occurrence of modular neck fracture.

11. Conclusion

Over the next several decades we will continue to see improvements in implant fixation, bioengineering of bearing surface designs, and prosthesis design that will allow us to reliably replace hip joints in younger and more active adult patients. The design of the "neck-sparing" products and bearing surfaces mentioned herein have certainly played a large part in achieving this goal, but continued improvements and careful outcomes monitoring will be needed over the next few decades.

Acknowledgements

Rubin and Ritterman: Unrestricted educational grant from Joint Implant Surgery and Research Foundation. McTighe: Ownership interests, patents, and licensing fees related to Concept, Design, and Development (CDD) and TSI Stem designs.

Author details

Lee E. Rubin¹, Scott A. Ritterman² and Timothy McTighe³

*Address all correspondence to: lrubin@universityorthopedics.com

1 Division of Adult Reconstruction, Warren Alpert Medical School of Brown University, University Orthopedics, Inc. Providence, Rhode Island, USA

2 Brown University and Rhode Island Hospital, Providence, Rhode Island, USA

3 Joint Implant Surgery and Research Foundation (JISRF), Chagrin Falls, Ohio, USA

References

- [1] Moussa, H, Pierre, B, Jacques, D, et al. Alumina-on-Alumina Total Hip Arthroplasty A Minimum 18.5-Year Follow-up Study." J Bone Joint Surg Am (2002). , 84(1), 69-77.
- [2] Neumann, L, Freund, K. G, & Sorenson, K. H. Long-Term Results of Charnley Total Hip Replacement." J Bone Joint Surg Br (1994). B (2): 245-251., 76.
- [3] Polkowski et al Total Hip Arthroplasty in the very Young Patient." Journal of the American Academy of Orthopaedic Surgeons. (2012). , 20, 487-497.
- [4] Engh, C. A, & Hopper, R. H. Huynh C et. al. A prospective randomized study of cross-linked and non cross-linked polyethylene for total hip arthroplasty at year follow-up. Journal of Arthroplasty (2012). S): 2-7., 10.
- [5] Milosev, I, Kovac, S, & Trebse, R. et. al. Comparison of ten-year survivorship of hip prosthesis with use of conventional polyethylene, metal-on-metal, or ceramic-on-ceramic bearings. J Bone Joint Surg Am (2012). , 94(19), 1756-1763.
- [6] Freeman, M. A. Why resect the neck? J Bone Joint Surg Br (1986). , 68(3), 346-9.
- [7] Pipino, F, & Keller, A. Tissue-sparing surgery: 25 years' experience with femoral neck preserving hip arthroplasty. Journal of Orthopaedics and Traumatology. (2006). , 7(1), 36-41.
- [8] Stulberg, S. D, Keggi, J, & Keppler, L. et. al. A classification system for short stem uncemented total hip arthroplasty. Poster Presentation at the International Society for Technology in Arthroplasty. Sydney, Australia, October (2012). , 4-6.
- [9] Mctighe, T, & Brazil, D. Memorandum: Modular Necks. Reconstructive Review (2012). , 2(2), 98-101.
- [10] Rubin, L. E, Tuttle, J. R, & Rittman, S. A. Simultaneous bilateral direct anterior total hip arthroplasty utilizing a modular neck-sparing arthroplasty femoral stem. Reconstructive Review (2012). , 2(2), 68-71.
- [11] Mctighe, T, Keggi, J, & Keppler, L. et. al. The First 1,200 (1,790) U.S. Short Curved Neck Stabilized Stems. Poster Presentation at the International Society for Technology in Arthroplasty. Sydney, Australia, October (2012). , 4-6.