

# We are IntechOpen, the world's leading publisher of Open Access books Built by scientists, for scientists

6,900

Open access books available

185,000

International authors and editors

200M

Downloads

Our authors are among the

154

Countries delivered to

TOP 1%

most cited scientists

12.2%

Contributors from top 500 universities



WEB OF SCIENCE™

Selection of our books indexed in the Book Citation Index  
in Web of Science™ Core Collection (BKCI)

Interested in publishing with us?  
Contact [book.department@intechopen.com](mailto:book.department@intechopen.com)

Numbers displayed above are based on latest data collected.  
For more information visit [www.intechopen.com](http://www.intechopen.com)



# Dual OVD (Ophthalmic Viscosurgical Devices) Sealing Technique

Takao Tanaka<sup>1,\*</sup>, Maiko Hirose<sup>1</sup>, Shigemitu Ishii<sup>1</sup>,  
Satoshi Fujita<sup>1</sup> and Keisuke Kimura<sup>2</sup>

<sup>1</sup>Hachioji Medical Center, Tokyo Medical University Hospital, Hachioji Tokyo

<sup>2</sup>Department of Ophthalmology, Tokyo Medical University, Tokyo, Japan

## 1. Introduction

The soft shell technique (Arshinoff SA) is an excellent technique for protecting the corneal endothelium, particularly when performing microincision cataract surgery (MICS) (Tsuneoka H, et al.; Osher RH; and Agarwal A, et al.). We have observed that this technique is often associated with an increase in intraocular pressure (IOP) after surgery (Figure 1). Here we conducted a preliminary retrospective study to evaluate increases in IOP after surgery using the soft shell technique with different incision sizes. The incidence of an IOP of at least 22 mmHg at 1 day after surgery is increased when a narrow incision size is made during surgery. Therefore, the IOP spike may depend on the incision size.

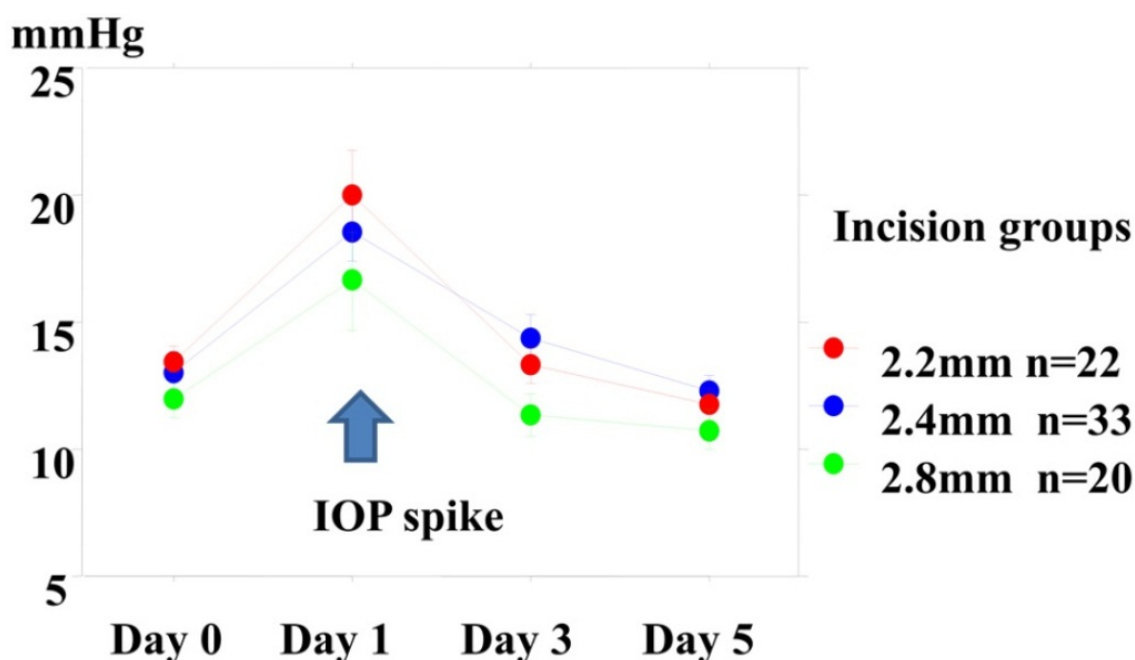


Fig. 1. IOP Values after Surgery Using the Soft Shell Technique

\* Corresponding Author

This was a preliminary retrospective study (n=75 cases). For cataract surgery, the soft shell technique is excellent for protecting the corneal endothelium. In our experience, however, the use of this technique during minimal incision cataract surgery (MICS) is often associated with an increase in postoperative intraocular pressure, especially 1 day after surgery in cases in which a 2.2-mm clear corneal incision was made.

Based on this impression, we designed a dual Ophthalmic Viscosurgical Device (OVD) sealing technique, anticipating that use of this sealing technique in combination with MICS would attenuate the IOP elevation and better protect the cornea as by contributing to maintain the appropriate anterior chamber depth during surgery.

The technique involves filling the anterior chamber with a low-molecular-weight ophthalmic viscosurgical device (LMW-OVD), using sodium hyaluronate (SH; Opegan®, Santen) for corneal protection (Nagahara M & Shimizu K). In addition, another OVD with a different surface tension, preferably one containing SH and chondroitin sulfate (SH/CS; Viscoat®, Alcon) is used to seal the wound to prevent marked leakage of the LMW-OVD from the anterior chamber. The purpose of this study was to evaluate the effect of this dual OVD sealing technique, combined with MICS, on the postoperative IOP and corneal protection.

## 2. Methods

*Technique:* After the initial paracentesis, a cannula was inserted into the anterior chamber and the LMW-OVD was injected. After filling 70% of the anterior chamber, the secondary SH/CH-OVD was injected around the wound. Injection of the LMW-OVD was resumed, penetrating the SH/CS-OVD mass and sealing the wound (Figure 2).

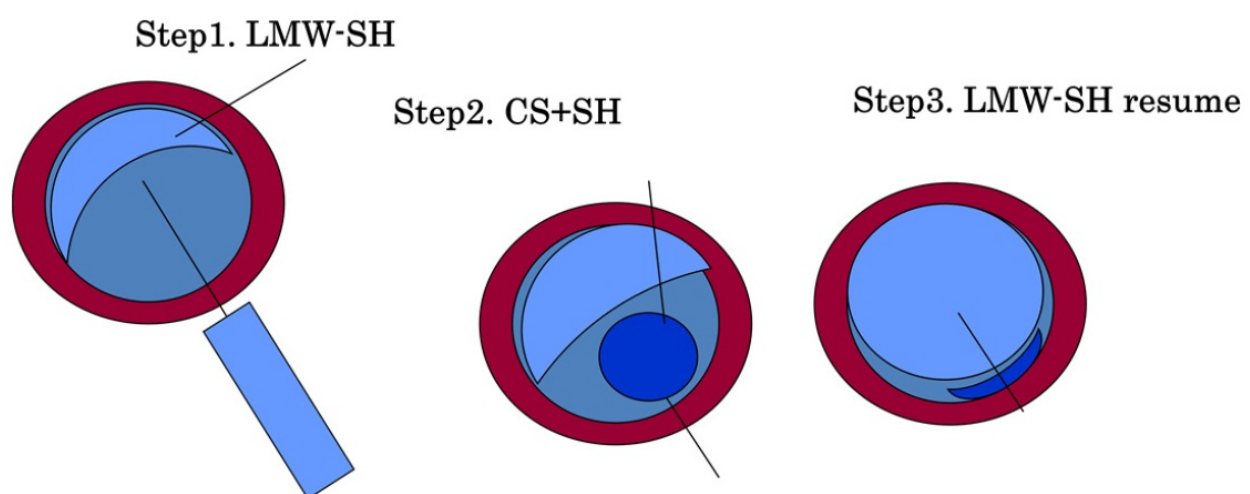


Fig. 2. The dual-OVD sealing technique

The anterior chamber is filled with LMW-OVD. The inside wound is sealed using a secondary OVD SH/CS-OVD with a different surface tension.

3. Clinical evaluation

The retrospective study involved a total of 165 eyes that underwent MICS by the same surgeon (T.T.). Subjects that underwent MICS with a 2.2-mm clear corneal incision and micro co-axial phaco were classified into five groups as follows: Group 1 (n=29), the soft shell technique (SH/CS-OVD and HMW-OVD, Healon ®, AMO); Group 2 (n= 29): a high molecular weight OVD (HMW-OVD1: Healon ®) was used; Group 3 (n=33) HMW-OVD2 (Opegan Hi ®, Santen); Group 4 (n=40): dual-OVD sealing technique (DOS) using a LMW-OVD and SH/CS-OVD; and Group 5 (n=34): LMW-OVD alone. Intraocular pressure and percent corneal endothelial cell loss were measured before surgery, and at 1, 3, and 5 days after surgery.

4. Results

At day 1 after surgery, IOP was increased in all cases (Figures 3 and 4) and did not significantly differ between groups. After day 1, however, IOP was significantly higher in Group 1, in which the soft shell technique was used, compared to Groups 2-5.

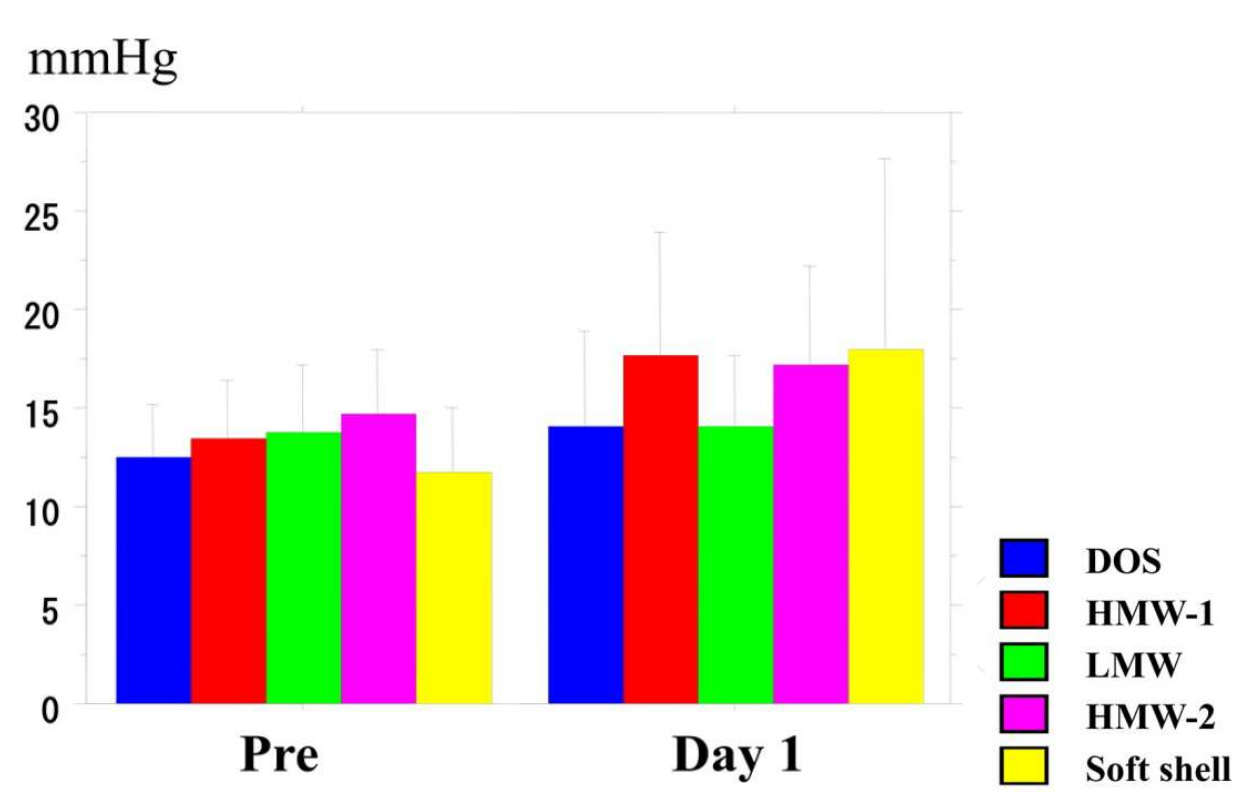


Fig. 3. Intraocular pressure

These findings suggest that the soft shell technique tends to induce an increase in the IOP compared with the non-soft shell techniques. The OVD used did not significantly affect corneal endothelial loss rate; mean cell area and the coefficient of variation did not differ significantly between groups (Figures 5,6, and 7).

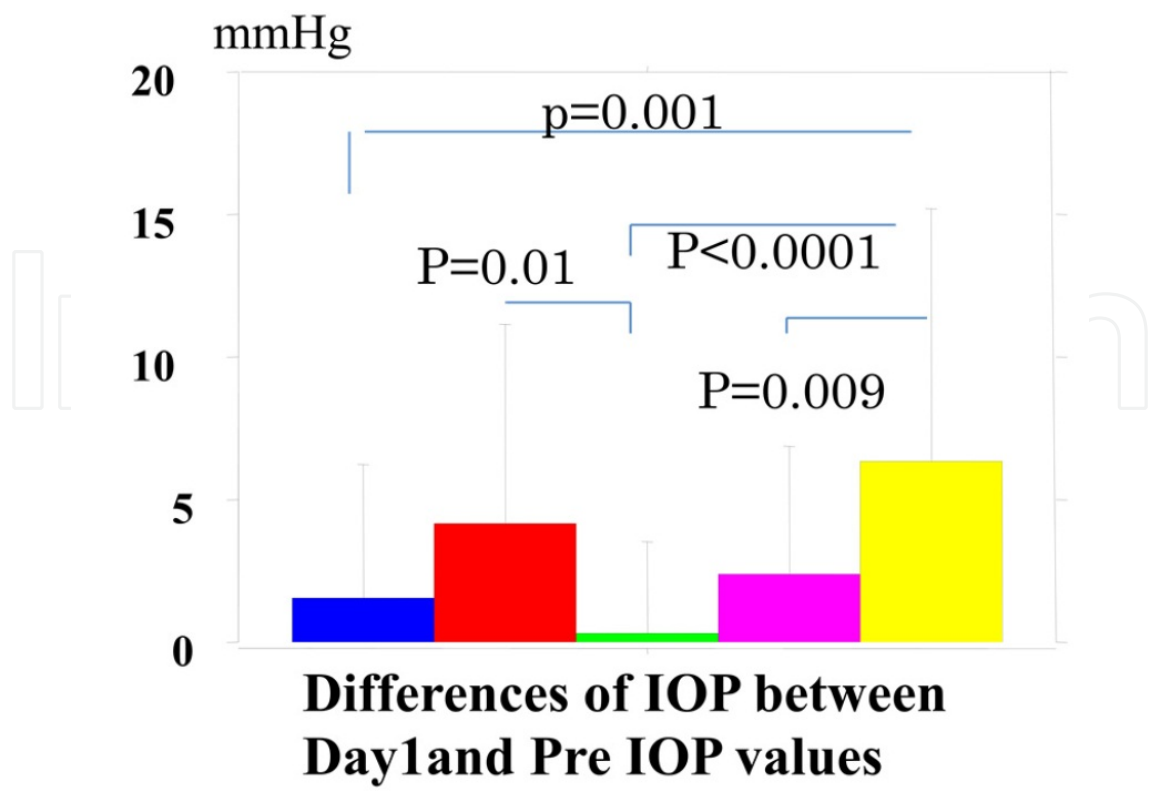


Fig. 4. Differences in the IOP elevation values

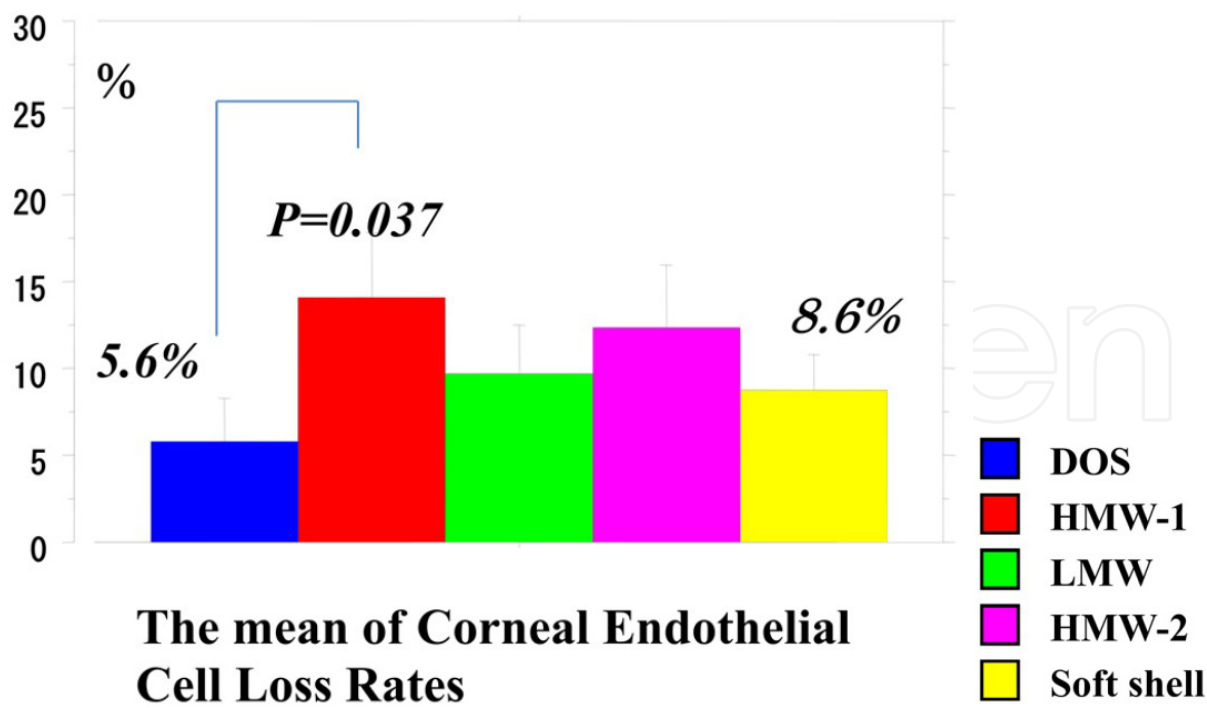


Fig. 5. Mean corneal endothelial cell loss rate

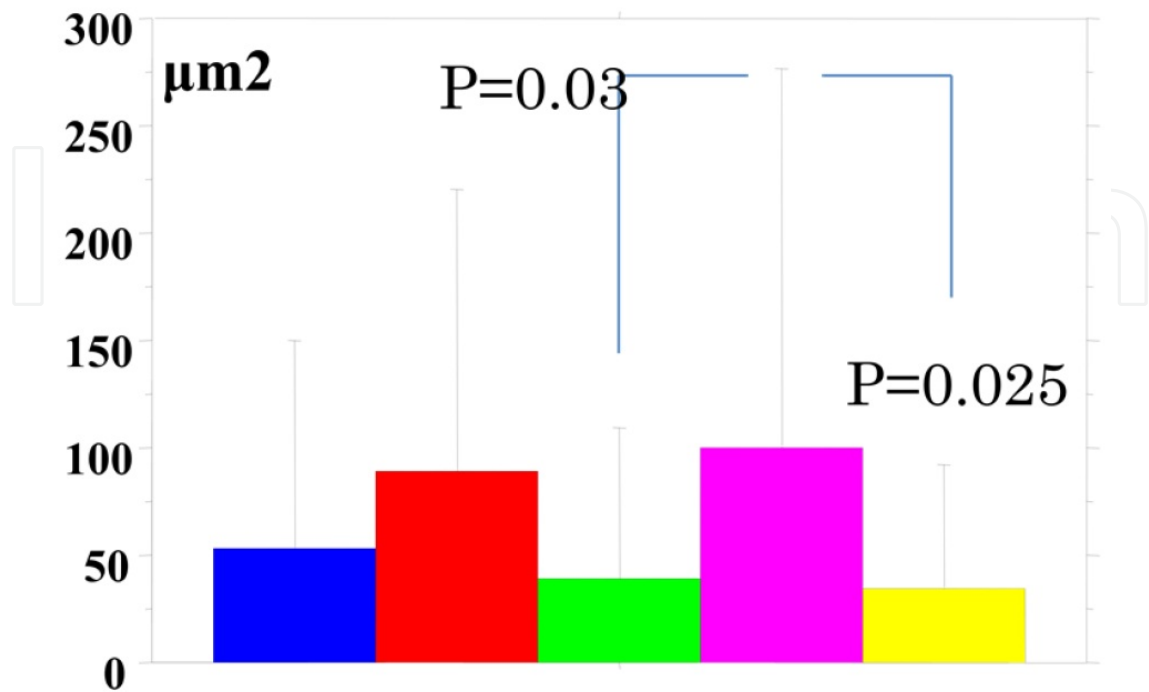


Fig. 6. Difference in mean cell area between before and after surgery

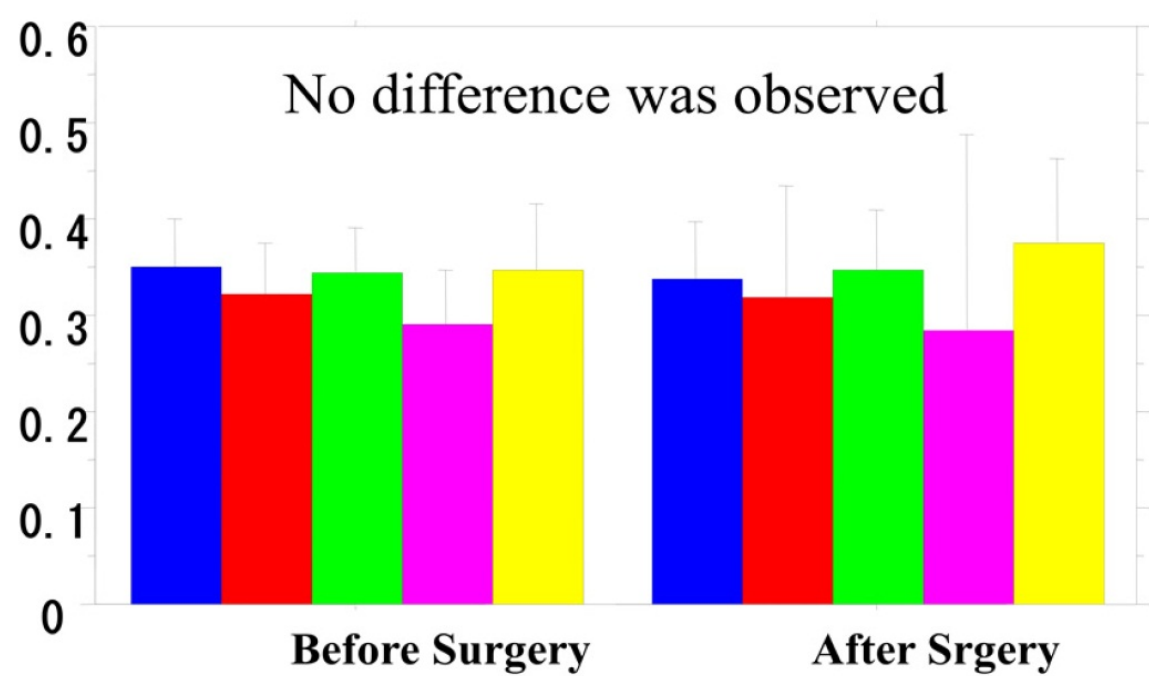


Fig. 7. Coefficient of variation

## 5. Discussion

Sodium hyaluronate demonstrates remarkable viscoadaptability and prolonged retention at the lower flow rate is associated with a high residual volume (Tanaka T, et al.). Leakage of the LMW-OVD is prevented when using the dual OVD sealing technique because the injection of a secondary OVD with a different surface tension facilitates maintenance of the anterior chamber depth.

Although the soft shell technique (Arshinoff SA) is useful for protecting the cornea, it is sometimes associated with an increased postoperative IOP when MICS is performed with a small incision. Thus, the IOP elevation may be due to residual OVD. Longer wash periods are therefore required to wash out the residual OVD or, when performing MICS, the irrigation volume must be very low. In such cases, the use of a LMW-OVD is expected to prevent the IOP elevation.

In our dual sealing procedure, a lower volume of the OVD is used than in the soft shell technique, allowing for the use of a LMW-OVD instead of a high molecular of OVD as the main filling in the anterior chamber. The SH/CS-OVD may prevent leakage and help to maintain an adequate anterior chamber depth. Thus, the dual OVD sealing technique appears to be more appropriate for small incision surgery.

The advantages of the dual sealing technique include: 1. Corneal protection by the LMW-OVD and 2. Low residual OVD, which helps prevent the elevation in IOP.

## 6. Financial disclosure

Takao Tanaka received partial support in the form of grants from Santen Pharmaceutical Company, Ltd., Osaka, Japan.

## 7. References

- Agarwal A, Agarwal A, Agarwal S, Narang P, Narang S. Phacoemulsification through a 0.9 mm corneal incision. *J Cataract Refract Surg* 2001; 27:1548-1552
- Arshinoff SA. Soft Shell technique, Dispersive-cohesive viscoelastic soft shell technique *J Cataract Refract Surg* 1999; 25:167-173
- Nagahara M, Shimizu K. Protecting the corneal endothelium with viscoelastic material during phacoemulsification. *Rinsho Ganka* (Written in Japanese) 1994; 48:900-901
- Osher RH. Micro coaxial phacoemulsification. Part 2: clinical study. *J Cataract Refract Surg* 2007; 33:408-412
- Tsuneoka H, Shiba T, Takahashi Y. Ultrasonic phacoemulsification using a 1.4 mm incision: clinical results. *J Cataract Refract Surg* 2002; 28:81-86
- Tanaka T, Kimura K, Usui M. Adhesive retention of sodium hyaluronate ophthalmic viscosurgical devices in an acrylic tube model and in porcine-eye corneal endothelium with different irrigation rates. *J Cataract Refract Surg* 2009 ; 35: 2008-2013