

# We are IntechOpen, the world's leading publisher of Open Access books Built by scientists, for scientists

6,900

Open access books available

185,000

International authors and editors

200M

Downloads

Our authors are among the

154

Countries delivered to

TOP 1%

most cited scientists

12.2%

Contributors from top 500 universities



WEB OF SCIENCE™

Selection of our books indexed in the Book Citation Index  
in Web of Science™ Core Collection (BKCI)

Interested in publishing with us?  
Contact [book.department@intechopen.com](mailto:book.department@intechopen.com)

Numbers displayed above are based on latest data collected.  
For more information visit [www.intechopen.com](http://www.intechopen.com)



# Complications Associated with Cataract Surgery

Rehab Ismail<sup>1</sup> and Ahmed Sallam<sup>2</sup>

<sup>1</sup>University of Aberdeen, Health Services Research Unit, Aberdeen

<sup>2</sup>Gloucestershire Hospitals NHS Foundation Trust, Gloucestershire  
UK

## 1. Introduction

This chapter reviews complications associated with cataract surgery and includes discussion of their risk factors, clinical presentation, prevention and management strategies. For the sake of discussion these complications are classified into intraoperative, early postoperative and late postoperative complications.

## 2. Anaesthesia-related complications

Ocular anaesthesia may be complicated by both ophthalmic and systemic factors. There have been reports of potentially life-threatening complications, including optic nerve damage, globe perforation as well as brainstem anaesthesia, dysrhythmias and cardiovascular depression. These complications are mainly seen with sharp needle techniques and are rarely encountered nowadays as cataract surgery is usually performed under topical or sub-Tenon's anaesthesia (1).

### 2.1 Optic nerve damage

If a sharp needle accidentally penetrates the dural sheath of the optic nerve (2), the anaesthetic can track back to the brainstem, causing unconsciousness and severe cardiorespiratory collapse/arrest with a potentially lethal outcome. This complication is rare, with some studies suggesting an incidence of between 0.09% and 0.79% for brainstem depression (3). Needle trauma to the optic nerve tissue can lead to significant loss of vision (4).

### 2.2 Globe perforation

Globe perforation is a rare complication of sharp needle anaesthesia and has been reported with both retrobulbar and peribulbar approaches with an incidence of 0.009% to 0.13% (3). This complication has potential for causing severe injury to the retina and is more frequently encountered in highly myopic eyes and eyes that underwent scleral buckling for retinal detachment (2).

Globe perforation should be suspected if hypotony is encountered after administering sharp needle anaesthesia. However, this could be absent if a large volume of anaesthetic has been injected intraocularly. Another sign is a dim red reflex and sometimes blood may be seen

behind the crystalline lens by the operating surgeon at the start of the operation. Management includes examination of the fundus to assess the extent of retinal damage and to apply argon laser photocoagulation or cryopexy to retinal breaks, if necessary(5). However, in most cases, examination of the fundus is usually difficult due to the presence of vitreous haemorrhage complicating the perforation. B scan ultrasonography is helpful in this context but vitrectomy surgery is usually indicated to remove the haemorrhage and deal with the retinal damage. Of note, in addition to the physical damage that could be caused by the needle injury to the globe, injection of the anaesthetic into the vitreous can also result in retinal toxicity and poor vision (6).

### **2.3 Retrobulbar haemorrhage**

Retrobulbar haemorrhage is an uncommon complication of ocular anaesthesia with an incidence of 0.032 to 3%. The condition is more common with sharp needle techniques (retrobulbar and peribulbar) compared to blunt needle anaesthesia (sub-Tenon's) (1) , and is more common in patients on antiplatelet medications and anticoagulants with elevated an International Normalised Ratio (INR) (5).

Retrobulbar haemorrhage is an emergency condition that needs to be promptly dealt with to save vision. It usually presents shortly after administration of the anaesthetic injection with increasing proptosis, tightness of the lids, subconjunctival haemorrhage and elevated intraocular pressure (IOP) that can lead to occlusion in the central retinal artery or short post ciliary arteries and blindness (5).

Initially mild intermittent compression on the globe can be helpful to stop further bleeding and limit progression of the haemorrhage. If this fails to resolve the condition, then pressure on the globe has to be relieved by performing a lateral canthotomy and cantholysis of the inferior crus of the lateral tarsal ligament. This is usually sufficient to decompress the orbit around the globe in most cases. IOP-lowering medications may be considered but these are usually not sufficient of their own to resolve pressure on the retinal circulation. Elective cataract surgery must be cancelled but may be rescheduled after at least a few weeks. While no immediate laboratory test is essential, patients must be re-assessed to exclude underlying blood dyscrasias. Subsequent cataract surgery is better performed under topical anaesthesia and attention should be given to normalizing the INR level if elevated and stopping antiplatelet medications in liaison with a physician.

## **3. Surgery-related complications**

### **3.1 Positive vitreous pressure**

Positive vitreous pressure can occur due to poor akinesia, inadvertent pressure on the globe from a tight lid speculum, proptosis, retrobulbar haemorrhage, eyelid abnormalities, as well as high hypermetropia. In this situation the iris-lens- diaphragm is pushed forward making surgery difficult and increasing the risk of more serious complications including iris damage, posterior capsule rupture and suprachoroidal haemorrhage (5).

Positive vitreous pressure is best dealt with by early recognition. In many cases a tight lid speculum is the culprit and minor adjustment of the speculum can correct the problem. Should this fail, attention needs to be directed to other causes including retrobulbar haemorrhage that usually manifests before the start of the surgery or aqueous misdirection and suprachoroidal haemorrhage that will present later on during the surgery. In the absence of retrobulbar

haemorrhage the surgeon can try to deepen the anterior chamber with a cohesive ophthalmic viscosurgical device but should the anterior chamber remain shallow with failure of pushing the iris-lens diagram backwards then the surgeon has to abandon the surgery and examine the fundus with an indirect ophthalmoscope for the presence of suprachoroidal haemorrhage. The absence of suprachoroidal haemorrhage makes the diagnosis of the aqueous misdirection most likely and in this scenario the condition usually resolves after a few hours and surgery can be reconsidered later on. Management of suprachoroidal haemorrhage will be discussed separately in the next section. Less commonly aqueous misdirection will not resolve conservatively and in this case, IOP-reducing agents will need to be given and possible interventions up to and including vitrectomy have to be considered.

### **3.2 Suprachoroidal haemorrhage**

The risk of suprachoroidal haemorrhage is much less common with phacoemulsification and small incision cataract surgery compared to large incision cataract surgery. Data from the most recent national UK-based cataract audit involving 55,567 operated eyes with phacoemulsification showed an incidence of 0.07% (7). Suprachoroidal haemorrhage results from rupture of the posterior ciliary arteries. The exact pathogenesis is unknown; however, hypertension, generalised arteriosclerosis, glaucoma and high myopia are possible precipitating factors.

Early recognition of suprachoroidal haemorrhage is crucial and cessation of surgery and immediate closure of the wound is necessary to prevent retinal extrusion (expulsive haemorrhage) and permanent loss of vision. This is unlikely to be seen with phacoemulsification surgery as the wound is usually self sealing but could be encountered with ECCE as wound closure is more time consuming but should be undertaken as fast as possible using the most readily available suture (preferably 8-0 but 6-0 sutures can be used). Drainage of the haemorrhage using sclerotomy guided by indirect ophthalmoscopy and / or B scan ultrasound can be considered.

Visual prognosis after suprachoroidal haemorrhage can vary depending on the extent of the haemorrhage. Usually the haemorrhage gradually resolves over a period of time and unless the macula has been affected, good visual recovery is usually achieved. Primary drainage of the suprachoroidal haemorrhage may not be felt to be necessary unless wound closure is not possible due to extreme positive pressure. Postoperatively, attention is given to control IOP and to treat inflammation with topical steroids and cycloplegics. Vitrectomy may be needed to drain a persistent large suprachoroidal haemorrhage but surgery is better to be deferred for 2 weeks to give time for clotted blood to liquefy.

### **3.3 Descemet's membrane detachment**

A small area of Descemet's membrane detachment at the area of the corneal section is not uncommon with phacoemulsification surgery and can be left alone. A wider Descemet's detachment along the section would need full-thickness suturing of the cornea including the Descemet's membrane (8). This is difficult to perform and another option is to inject air or a longer acting gas intracamerally to facilitate opposition of the Descemet's membrane to the stroma. The condition can be avoided by careful attention to wound construction and size as well as by avoiding the use of blunt blades. Extremely rarely the corneal endothelium may become detached during wound manipulations such as wound hydration.

### 3.4 Posterior capsule rupture and vitreous loss

Posterior capsule rupture is the most common major intraoperative complication observed during cataract surgery. There is wide agreement among ophthalmologists that its incidence can be used as a measure of surgical quality and is an indicator for measuring the quality of surgeons in training and for cataract surgeons' revalidation. The importance of this complication also stems from the fact that patients whose surgery has been complicated by posterior capsule rupture usually require more postoperative follow-up visits and have an increased risk of postoperative complications including endophthalmitis, cystoid macular oedema and retinal detachment.

Several factors could predispose to posterior capsule rupture and vitreous loss during cataract surgery only one of which is the surgeon's experience and skill. Posterior capsule rupture rates in the hands of residents have been reported to vary from 0.5% to 16%, varying according to experience (9). In the United Kingdom, there has been a trend for improvement from the mean benchmark rate of 4.4% defined in the 1997 National Survey to 2.68% in the first Pilot National Electronic Cataract Surgery Survey and 1.92% in a current survey of 55 567 cases (10). The lowest rate found in a major study has been 1.1% on certain supervised training lists in the UK (11). Inadequate mydriasis and a small pupil increase the risk of intraoperative posterior capsule rupture and visual loss because it restricts the surgeon's view during surgery. Pseudoexfoliation (PXF) is another significant risk factor associated with vitreous loss. The risk is increased by several mechanisms including zonular weakness and poor pupil dilatation. Intraoperative floppy iris syndrome (IFIS) in relation to systemic use of tamsulosin is also one of the important causes of a poorly dilated pupil during cataract surgery and could make surgery very difficult due to iris billowing and prolapse to the wound. High myopia is also a well known risk factor for vitreous loss (12). Diabetes mellitus may indirectly influence the rate of posterior capsular rupture through different mechanisms including a rigid pupil and the possibility of the patient having a history of pars plana vitrectomy.

While posterior capsule rupture can occur at any stage of cataract surgery, it commonly occurs in the hands of most surgeons towards the end of the surgery at the time of cortex removal or otherwise while removing the last quadrant of the nucleus mainly because the posterior capsule is more exposed at these stages of the operation. Another cause of posterior capsular tear is an extension of an anterior capsule tear that wraps around the equator - this could occur at the early stage of capsulorrhexis though extension can also occur later on during the surgery. In a large retrospective study of 2646 cases that were operated on by a single experienced surgeon, a tear in the anterior capsule rim was observed in 21 eyes (0.79 %) and extension of the tear into the posterior capsule occurred in almost half the eyes with an anterior capsule tear (13).

Appropriate risk assessment can significantly decrease the risk of intraoperative posterior capsule rupture and vitreous loss. Difficult cases with small pupil, PXF or anticipated IFIS should only be undertaken by senior surgeons or trainees that are at the end of their training programme. Risks inherent to small pupil size or iris billowing could be dealt with intraoperatively with the use of a super-cohesive ophthalmic viscosurgical device (OVD) such as Healon 5 or mechanical measures to dilate and restrain the iris movement such as iris hooks or pupil expansion rings. Posterior capsule rupture can also be avoided by taking extra caution during emulsifying the last nucleus quadrant to protect the posterior capsule through maintaining the anterior chamber depth. Bimanual irrigation aspiration may be safer than



coaxial irrigation aspiration as the aspiration port is always directed up and is therefore unlikely to snag the capsule. For anterior capsule tears, the surgeon should be aware of their risk of extension into the posterior capsule and redirection of the tear centrally to the desired circumferential path should be attempted unless the tear has extended into the zonules. This can be achieved with the capsulorrhexis tear-out rescue technique described by Little and associates (14). In this technique the authors recommend first filling the anterior chamber with a cohesive OVD and then folding the progressing anterior capsule flap back on the intact portion of the anterior capsule by forceps and then pulling it centrally to redirect the tear with the force applied in the plane of anterior capsule (14).

If posterior capsule rupture is suspected then the surgeon should stop aspiration and phacoemulsification but maintain irrigation and then inject a cohesive viscoelastic through the side port before withdrawing the handpiece from the eye. Maintaining the anterior chamber depth can prevent extension of the posterior capsule tear and avoid disruption of the anterior vitreous face and vitreous prolapse. Further management depends on the stage at which capsule rupture occurs and whether there is vitreous prolapse into the anterior chamber ('vitreous loss'). If the anterior hyaloid face is intact, removal of residual cortex can be performed using dry aspiration while the anterior chamber is maintained with a cohesive OVD. Another technique is bimanual irrigation aspiration with the irrigation and suction kept to a minimum and the irrigation flow directed away from the tear so as not to disrupt the anterior vitreous face. At all stages of the surgery, the anterior chamber depth should always be maintained.

Vitreous prolapse if it occurs has to be dealt with using anterior vitrectomy. Triamcinolone is increasingly used by surgeons to visualise vitreous. Bimanual vitrectomy through two side ports is the preferred technique as the anterior chamber depth is maintained with this approach limiting the amount of prolapsing vitreous. Triamcinolone serves as a good tool to visualize vitreous fibrils when injected in the anterior chamber and ensures complete anterior vitrectomy.

If there is a small central posterior capsule tear, an experienced surgeon can still implant the lens in the bag preferably after converting it to a posterior capsulorrhexis. In this case, a one-piece lens is much easier to implant. Should this not be feasible then the surgeon can place the intraocular lens in the ciliary sulcus provided that there is sufficient capsular support. Capturing the optic through an intact capsulorrhexis can also be performed to help better centralisation of the lens optic ('optic capture').

Any intraocular lens (IOL) placed in the ciliary sulcus should have sufficient posterior iris clearance and secure fixation. Therefore the choice is between a 3-piece foldable posterior chamber intraocular lens (PCIOL) and a polymethylmethacrylate (PMMA) IOL. A 3-piece foldable PCIOL has the advantage of thin, posteriorly angulated C-shaped haptics that do not contact the iris. Ideally, the anterior optic surface should be smooth and have rounded edges to minimize iris chafing and the overall IOL length should be at least 13.5 mm. It is important to reduce the risk of iris chafing that the IOL is inserted with the correct face forwards. Because of the risk of retinal detachment with posterior capsule rupture and vitreous loss, silicone intraocular lenses are better avoided as they may compromise the view should vitrectomy surgery become required. With optic capture, the same IOL power calculated for capsular bag fixation can generally be used. However, should optic capture not be feasible with sulcus IOL, the lens optic will have a more anterior location and the lens power should be reduced by 0.5 to 1.0 D (15). A large diameter (>13.5 mm) PMMA PC IOL

is another option but the incision will need to be enlarged to at least 6.5 mm which is not desirable (15). Single piece acrylic lenses are not recommended for ciliary sulcus placement. The haptics are thick and not posteriorly angulated and will therefore contact the posterior surface of the iris when implanted in the sulcus. Furthermore, the overall loop-to-loop dimension of these lenses is only 13.0 mm or less which is short for many eyes. The square edge optic design increases iris chaffing (15).

In eyes with insufficient capsule support, the surgeon has the choice between iris- or scleral-sutured PC IOLs and open loop AC IOLs. In our experience placing an AC IOL is a much easier technique than suturing a PC IOL during the primary surgery (Figure 1). The American Academy of Ophthalmology Technology Assessment study reviewed more than 40 papers that addressed the outcomes of IOLs implanted without adequate capsule support and carried evidence rating of level III or higher. The study was unable to find a significant difference in the safety or efficacy of these 3 methods and therefore use of any of these modalities is appropriate and is left to the discretion of the surgeon (16).

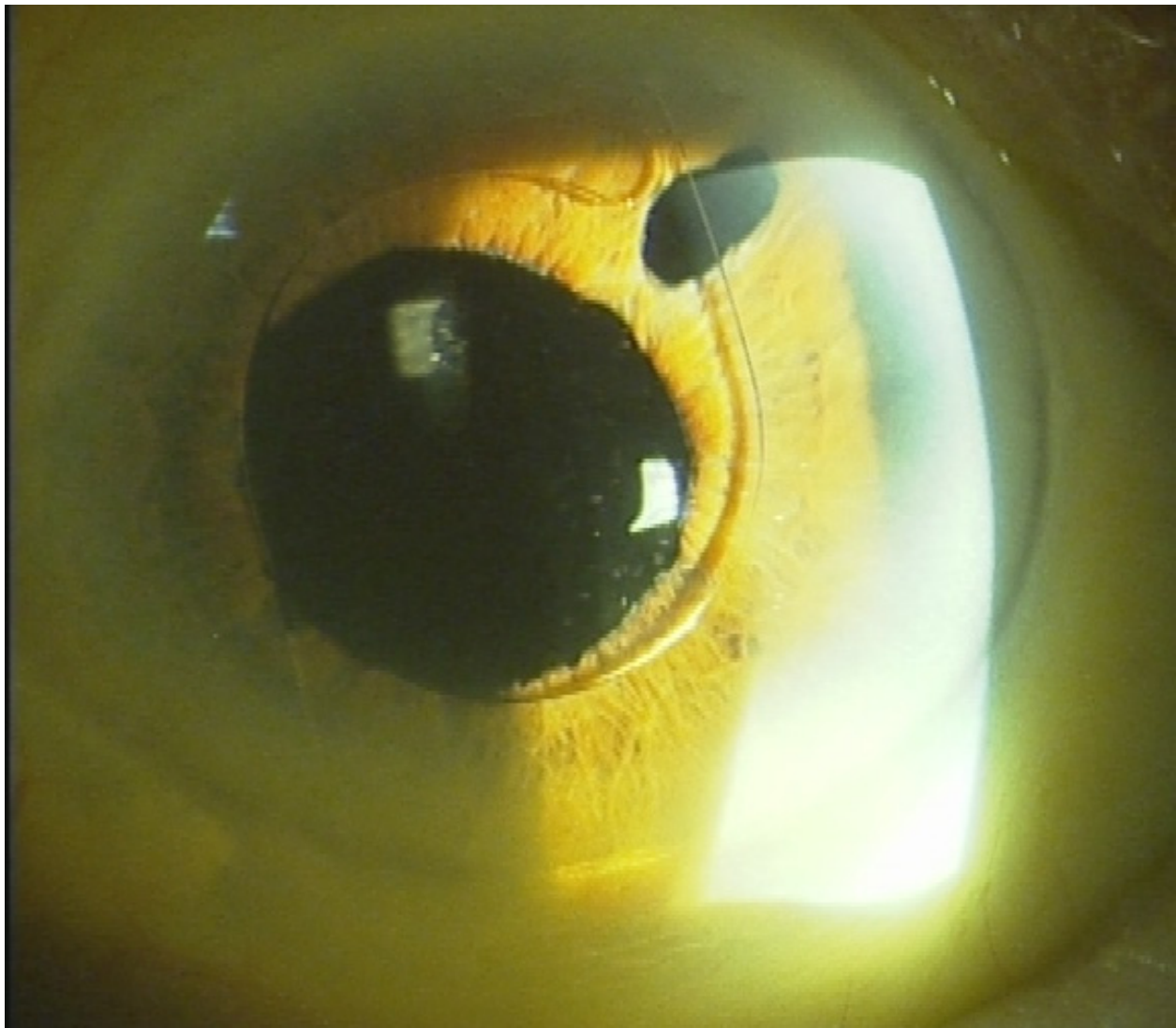


Fig. 1. Anterior chamber intraocular lens in a case of cataract surgery complicated by posterior capsule rupture. Note the presence of a peripheral iridectomy.

### 3.5 Zonular dialysis

A preoperative zonular dialysis may be the result of pre-existing conditions as traumatic cataract or in association with specific disorders as Marfan Syndrome and Weill-Marchesani Syndrome. Pseudoexfoliation and high myopia are other well recognized causes for zonular weakness and dialysis preoperatively. Signs that could alert the surgeon to the presence of zonular dialysis include phacodonesis, iridodonesis, presence of vitreous in the anterior chamber, or a visible zonular defect. Moreover, the nucleus may appear decentralised (off-centre) with a gap between the iris border and the lens.

Intraoperative zonular dialysis may result from vigorous manoeuvres that traumatise the zonules in one region. These include a traumatic capsulorrhexis, excessive manipulation of the nucleus, or inadvertent aspiration of the capsular bag or anterior capsule. Prompt recognition and early management can decrease the risk of intraoperative vitreous prolapse and postoperative lens decentration or posterior dislocation. Small areas of zonular dialysis (45 degrees or less) recognized at the time of surgery can be dealt with only by maintaining the anterior chamber depth at the time of surgery to limit further progression and prevent vitreous prolapse. A larger defect usually necessitates the use of a capsule tension ring (CTR) to preserve the integrity of the capsular bag and provide the necessary capsular support. It works by reducing asymmetric capsular forces, stabilizing the vitreous base. Moreover, it facilitates phacoemulsification and IOL implantation and decreases postoperative IOL decentration and capsular phimosis. Modified CTR designs are also available and can even be sutured to the sclera to provide additional support to the capsular bag in eyes with very loose zonules.

## 4. Early postoperative complications

### 4.1 Shallow anterior chamber (AC)

A shallow anterior chamber after cataract surgery may be associated with low or high IOP. Wound leak is the most common cause of shallow AC with low IOP and therefore, the initial work up aims to check for a wound integrity and perform a Seidel test. Other causes include choroidal effusion or severe uveitis with decreased aqueous formation. Management is directed towards treating the underlying problem in case of a wound leak and uveitis while choroidal effusion is usually self limiting.

Shallow anterior chamber with elevated IOP could be due to pupil block glaucoma, suprachoroidal haemorrhage or malignant glaucoma. Pupil block is an uncommonly encountered complication after cataract surgery where the aqueous humour accumulates under the iris causing the peripheral iris to balloon forward resulting in angle closure glaucoma. The pupillary aperture may be obstructed by complete adhesions between pupillary border of the iris (seclusio pupillae) and lens implant in eyes with severe postoperative uveitis. Other causes include pupil block caused by the anterior hyaloid or lens implant and for this reason it is essential to perform a peripheral iridectomy when implanting an anterior chamber IOL. Retained viscoelastic accumulating behind the lens implant can increase the pressure inside the capsular bag and induce pupil block i.e. capsular distension syndrome. These eyes will have an unexpected degree of myopia which is an important clue to the diagnosis.

Malignant glaucoma is a rare complication after cataract surgery. A blockage of the normal aqueous exchange between the posterior chamber and the anterior vitreous is believed to cause malignant glaucoma. Posterior misdirection of aqueous humor into the vitreous cavity



occurs producing a continuous expansion of the vitreous cavity with increased posterior segment pressure. This accumulation of aqueous in the vitreous cavity causes anterior displacement of the lens-iris diaphragm. The resulting shallow or flat AC is believed to exacerbate the condition because of the decreased access of aqueous to the trabecular meshwork. After excluding the presence of pupillary block initial management should be conservative with topical mydriatics and IOP lowering agents including systemic carbonic anhydrase inhibitors and osmotic agents as mannitol. Nd: YAG laser can be performed to disrupt the anterior vitreous face but surgical management in the form of vitrectomy should be performed if conservative treatment and laser fail to resolve the condition. Management of suprachoroidal haemorrhage has been discussed earlier in this chapter.

#### **4.2 Iris prolapse**

Iris prolapse can result from inadequate wound closure, accidental postoperative trauma, or raised intraocular pressure. Phacoemulsification wounds are usually self sealing but surgeons should confirm the absence of wound leak at the conclusion of the surgery and not hesitate to suture the wound if needed.

If iris prolapse is of less than 48 hours duration, the iris can be repositioned and the wound is closed. In cases where iris prolapsed has been present for a longer time, iris excision is usually needed to decrease risk of intraocular infection.

#### **4.3 Postoperative uveitis**

Mild anterior uveitis is not uncommon after uncomplicated phacoemulsification surgery and usually responds well to routine postoperative corticosteroid drops. Concerns are raised when a patient presents in the early postoperative period with more than a mild postoperative inflammation as this could be endophthalmitis even in the absence of pain and poor vision. As long as the vitreous remains quiet and the anterior chamber inflammation is not worsening, a sensible strategy is to increase the frequency of topical steroids and review the patient after several hours and then the next morning. However, diagnosis of endophthalmitis should be considered if symptoms worsen within 6 to 12 hours and emergency treatment should be commenced without delay.

#### **4.4 Infectious endophthalmitis**

Infectious endophthalmitis is the most serious postoperative complication of cataract surgery. Fortunately the incidence is very low and ranges from 1- 3 in 1000 or even less (17). Postoperative endophthalmitis can present as early as the first postoperative day and up to two weeks after surgery. However, most commonly it presents after 3-4 days. Presenting symptoms can include decreased vision and pain although pain is not a constant feature. The anterior chamber inflammation seen is usually significantly greater than that expected after surgery (Figure 2), with extension of inflammation to the vitreous cavity. Other classic signs of endophthalmitis are lid swelling, conjunctival injection, corneal oedema, vitreous abscess and retinitis but these could all be absent in early cases and are not essential for making the diagnosis. The Endophthalmitis Vitrectomy Study (EVS) found that at presentation, 86% of cases of acute postoperative endophthalmitis had hypopyon which can cause an increase in IOP. The majority of these patients complained of progressive pain and reduction in vision and 86% had acuity of 5/200 on initial presentation and 26% had light perception only (18).

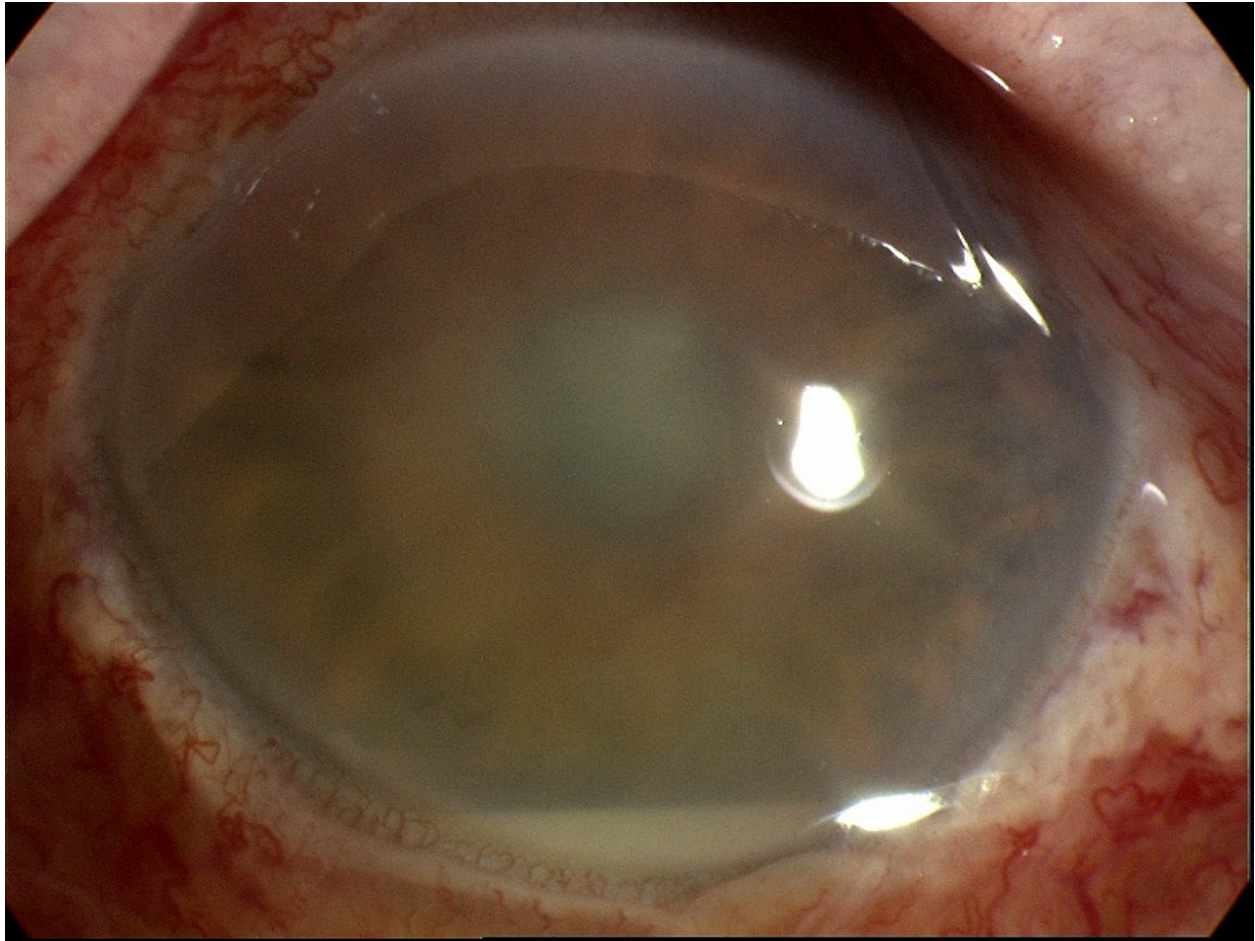


Fig. 2. Marked anterior chamber inflammation and hypopyon in a patient with infective endophthalmitis

The majority of cases of postoperative endophthalmitis result from intraocular microbial contamination from the patient's skin, preocular tear film or ocular adnexa. Posterior capsule rupture is a well known risk factor and it is therefore recommended that the cataract wound is sutured after complicated cases (19). Other risk factors include patient age, intraoperative surgical complications, and poor wound construction. In a case-control study of 10 patients, endophthalmitis after secondary IOL was associated with diabetes, trans-scleral suture fixation of posterior chamber IOLs, polypropylene haptics, and intraocular re-entry through the old wound (20).

The most common pathogens are gram-positive cocci, *Streptococcus epidermidis* and *Staphylococcus (Staph) aureus*. *Staph aureus* endophthalmitis often leads to a more virulent and destructive pattern of visual loss in comparison to that of *Staph epidermidis*. Gram-negative pathogens can also cause severe bacterial endophthalmitis with *Pseudomonas aeruginosa* being the most common casual agent. The normal flora colonising the eyelids and the lashes are the main source of bacteria in endophthalmitis post cataract surgery but other sources of infection include contaminated infusion solutions or instruments and aerosols in the operating theatre (21).

Several antibacterial protocols exist to prevent the occurrence of postoperative endophthalmitis, with topical, intracameral and subconjunctival delivery being the most common approaches. Worldwide, there seems to be significant variation in the methods of

delivery of prophylactic antibacterial regimens; for example, topical fluoroquinolones are commonly used in the United States, while intracameral cephalosporins are employed broadly in Europe. The optimal antibacterial strategy for the prevention of endophthalmitis should be the administration of safe, inexpensive antibiotics with a broad spectrum of activity and which also do not require patient compliance for effectiveness (22). In addition, detection and treatment of blepharitis preoperatively as well as preoperative administration of povidine iodine in the conjunctival sac reduces the incidence of postoperative endophthalmitis and are widely employed measures.

Intravitreal injection of antibiotics is the mainstay of treatment for postoperative endophthalmitis and needs to be commenced without delay once the diagnosis is made. Empirical antibiotics to cover gram positive and gram negative organisms are usually used after performing a vitreous tap for culture and sensitivity. With the rising incidence of resistant beta-lactam bacteria, intravitreal injection of vancomycin is the treatment of choice to cover gram-positive organisms. Vancomycin is a bactericidal agent that works by preventing the polymerisation of peptidoglycan in the cell wall and thus causes loss of cell wall integrity with cell lysis. The drug is used at a dose of 1.0-2.0mg/0.1ml and has been reported to have 100% efficacy against gram-positive bacteria but has no efficacy against gram-negative organisms (21). Cover for gram-negative organisms requires an agent with activity against *Pseudomonas aeruginosa*. Ceftazidime at a dose of 2.00-2.25 mg/0.1 ml or amikacin at a dose of 0.4 mg/0.1 ml may be used and have similar success rates close to 90%. Aminoglycosides are also synergistic with vancomycin against gram-positive organisms. However, both gentamicin and amikacin carry a small risk of retinal toxicity and macular infarction when injected intraocularly, but the risk is small and amikacin in particular is widely used (21). The toxic effect can even occur with smaller doses. A localised increase in the concentration may play a part in causing the toxicity. Also, ceftazidime 2.0 mg may be used instead of aminoglycosides in the treatment as well as prophylaxis of gram negative infection (23). Some centres also administer systemic antibiotics alongside intravitreal agents.

Pars plana vitrectomy (PPV) may be necessary for the management of acute endophthalmitis; however the need for vitrectomy in all cases of postoperative endophthalmitis remains questionable. While vitrectomy is expected to decrease the microbial load and increase intraocular diffusion of antibiotics, it carries the potential risk of causing retinal detachment and intraocular haemorrhage in cases of intraocular infection (24). As per the EVS recommendations, patients with only light perception or worse benefit from PPV with a significantly better outcome. However, different centres have different protocols and some centres treat all cases initially with intravitreal antibiotics irrespective of the level of vision and consider vitrectomy for cases that do not respond (24).

Visual prognosis is strongly associated with the type of microorganisms that are cultured. Gram positive coagulase negative cocci are associated with the best prognosis whilst *Streptococci* as well as *enterococci* seem to be associated with the worst visual outcome. Presenting visual acuity is a more powerful predictor of visual prognosis than the microbiological factors. Bacterial growths from vitrectomy cassette specimens have the same prognostic value as specimens taken from other intraocular sources (25).

The chronic form of postoperative endophthalmitis is more insidious and usually manifests after several weeks or even months after the surgery (figure 2). The ratio of acute to chronic cases ranges between 5:1 to 2:1 (17). The organisms responsible tend to be less virulent



bacteria or fungi. The inflammation may initially be controlled by postoperative topical steroids but rebound inflammation is common as the steroids are tapered. These cases may be treated with intravitreal antibiotics including vancomycin however in resistant cases treatment directed at surgical removal of the sequestered organisms through removing the intraocular lens and total removal of the capsular bag results in a lower recurrence rate (26).

#### **4.5 Toxic anterior segment syndrome (TASS)**

Over the last three decades several authors have reported a non-infectious condition mimicking endophthalmitis following cataract surgery (26). Initially it was termed "sterile postoperative endophthalmitis" however this was a misnomer, as unlike endophthalmitis, the inflammation is limited only to the anterior segment and does not extend to the vitreous cavity. It was later renamed 'toxic anterior segment syndrome' (TASS) (27).

TASS generally presents with severe inflammation that is restricted to the anterior chamber as mentioned before, often resulting in hypopyon. In severe cases of TASS, fibrin may be present in the anterior chamber, on the iris or on the IOL surface. Inflammatory membranes can develop, which result in iris damage and an irregular pupil with impaired pupil function. During the early stages of the condition the IOP is low but the inflammatory membrane can creep over the trabecular meshwork. These changes can result in ocular hypertension or the development of secondary glaucoma and the rise in IOP can be severe.

A number of possible causes have been identified as triggering factors. They include preservatives in drugs or the irrigating solution injected into the anterior chamber during surgery, traces of chemicals used in the sterilization process remaining on the surgical instruments or contamination of these instruments with bacterial endotoxins during sterilisation (28). Because TASS is a toxic insult, it almost always presents as an atypical and unusual form of inflammation one day after surgery.

Differentiation between TASS and infective endophthalmitis is very important but can sometimes be difficult. First, TASS is only an anterior segment inflammation whereas endophthalmitis involves both anterior and posterior segments with extension of the inflammation into the vitreous (29). Second, TASS occurs within the first 24 hours in the postoperative period, however, endophthalmitis is not uncommonly delayed for 4 -7 days and very rarely presents on the first day. Third, patients with infective endophthalmitis are usually more symptomatic than TASS patients who may only complain of mild discomfort. Fourth, limbus-to-limbus corneal oedema is an important differentiating finding strongly suggestive of TASS. If this sign is present on the first postoperative day, a diagnosis of TASS should be strongly considered. Nonetheless, endophthalmitis should never be eliminated as a diagnosis until the therapeutic response is measured and the inflammation remains confined to the anterior segment. Fifth, in an eye with TASS, a fixed dilated pupil, often with mottled or diffuse areas of iris atrophy, is not uncommon. However this is unlikely to be encountered in cases of infective endophthalmitis. Finally, a severe rise of IOP early in the postoperative period is an uncommon finding with endophthalmitis and is more suggestive of TASS (30).

Topical steroids comprise the first line of treatment of TASS. Patients should receive hourly topical steroids and remain in the clinic to be monitored during the day. Steroids can suppress inflammation from endophthalmitis for a short period of time and accordingly the diagnosis of endophthalmitis must be reconsidered if symptoms and signs are getting worse with the use of steroids. For mild or moderate cases of TASS most cases will respond well to

topical treatment and recover with time. Severe cases may require the use of oral steroids and visual outcome can be poor due to non resolving corneal oedema or refractory glaucoma.

#### **4.6 Retained Lens Material**

Inadequate aspiration of the cortex, especially of the subincisional cortex if the surgeon is using a coaxial irrigation aspiration, is the commonest cause of retained lens material after cataract surgery. This is usually in the form of soft lens matter.

Retained lens material excites an inflammatory reaction in the eye. In cases with minimal cortical matter, the anterior segment inflammation can be controlled medically with topical steroids and cycloplegics until the lens material is absorbed. In cases with significant cortical residue, surgical removal is essential as they can cause significant inflammation with raised IOP and can also move centrally to obstruct the visual axis. There should be a low threshold for intervening quickly with surgery to remove the retained lens matter if intraocular pressure and /or intraocular inflammation is proving difficult to control.

### **5. Late postoperative complications**

#### **5.1 Change in refraction / astigmatism**

Corneal topography has been used to evaluate postoperative astigmatism. Topographic analysis has shown a mean flattening of 0.4 to 1.0 dioptre in the temporal region after a sutureless 3 mm temporal corneal incision with no significant vertical steeping or nasal flattening in the majority of patients (31).

In patients with a pre-existing small degree of corneal astigmatism (up to 0.75D), this can be tailored for a favourable outcome by manipulating the incision parameters (size, location and shape). On-axis incisions are the most widely used of these approaches. However cases with more significant amount of astigmatism are unlikely to benefit from incision site modification but could benefit from combined cataract surgery and limbal relaxing incisions or toric intraocular lens implantation.

#### **5.2 Refractive surprises after cataract surgery**

Refractive surprises following cataract surgery can be due to inaccurate biometry, insertion of the wrong IOL (either due to manufacturer-associated or surgeon-associated errors) or previous corneal refractive procedures. The best markers of the quality of a biometry service are the percentage of eyes achieving a postoperative spherical equivalent refraction within 0.5 and 1.0D of the target refraction and the total range of refractive error (32). The Royal College of Ophthalmologists (RCOphth) 2004 cataract surgery guidelines state that both optical (partial coherence interferometry (PCI)) and acoustic (ultrasound) methods of axial length measurement can be routinely used (33), although it has been shown that PCI reduces the prediction error of postoperative refractive outcome. The RCOphth guidelines state that each ophthalmology department, if not each surgeon, should personalise the A constant on the basis of continuous audit of the comparison of the predicted and actual spherical equivalent of the postoperative subjective refraction (34).

IOL power calculations in cataract patients who have formerly undergone keratorefractive surgery are often less precise than they are for patients who have not had refractive procedures. This is mainly due to errors in determination of corneal refractive powers and



using wrong keratometry values and is more common in patients who have undergone myopic keratorefractive surgery. As their corneal refractive power may be overestimated, this may lead to a hyperopic postoperative refractive outcome. Several options are available for subsequent correction of refractive surprises, including prescription of spectacles or contact lenses, IOL exchange, keratorefractive surgery, or implantation of a supplementary IOL (i.e., polypseudophakia) (35).

Spectacles may not be ideal for some young self-conscious patients. Likewise contact lenses may not be suitable for older patients. Keratorefractive procedures may not be the best solution due to the inherent risks associated with further corneal surgery. IOL exchange and supplementary IOLs, implanted in the ciliary sulcus anterior to the primary implant, can be an option, especially when capsular changes have firmly fixed the primary implant within the capsular bag making IOL exchange surgically challenging with very significant risks of posterior capsule and zonular rupture (35).

### **5.3 Posterior capsule opacification (PCO)**

A thickened posterior capsule is the most common postoperative cause of decreased vision following cataract surgery with a prevalence of over 40% in many studies within five years of surgery. It is a multi-factorial problem related to patient factors such as age, surgical factors and also factors in the IOL design.

PCO is caused by residual lens epithelial cells, which are left behind after cataract surgery. These residual lens epithelial cells have been shown to produce interleukins (36-38), fibroblast growth factor and transforming growth factor beta in inoculation media. Cytokines may also play a role in the proliferation and development of lens epithelial cells; therefore inhibition of cytokines may lead to prevention of PCO (39). There is also some evidence that the proliferation of lens epithelial cells (Elschnig's pearls) may be linked to the severity and duration of intraoperative or postoperative inflammation.

The IOL implant itself creates a physical barrier between the anterior and posterior lens capsule and IOL designs with square edged optics provide a more effective barrier than round edges thus minimising the risk of PCO. This is usually more effective when the anterior capsulorrhexis is continuous, well centred and overlaps the implant edge by 1-2 mm. Intraocular lens designs have also been improved to reduce trauma and thus decrease the likelihood of epithelial cell proliferation. Together with appropriate aspiration of cortical lens matter and improved surgical experience, these techniques have reduced the prevalence of PCO (40).

PCO is treated with Neodymium:Yttrium Aluminium Garnet (Nd:YAG) laser capsulotomy, preferably six months after surgery after stabilisation of the blood-ocular barrier (Figure 3). Nd:YAG laser capsulotomy should begin with minimal power and an adequate opening should be created, at least encompassing the pupillary area in the undilated position. For patients who require regular fundus examination such as patients with diabetic retinopathy a wider capsulotomy opening is more preferable.

Although Nd: YAG laser capsulotomy is a straightforward procedure, it is not entirely without risk. Iatrogenic complications of Nd:YAG laser capsulotomy include corneal endothelial loss, increase in IOP, uveitis, and retinal detachment. Accidental lens pitting can occur in up to 30% of patients and laser burns on silicone IOLs can resemble pigment deposition (41).

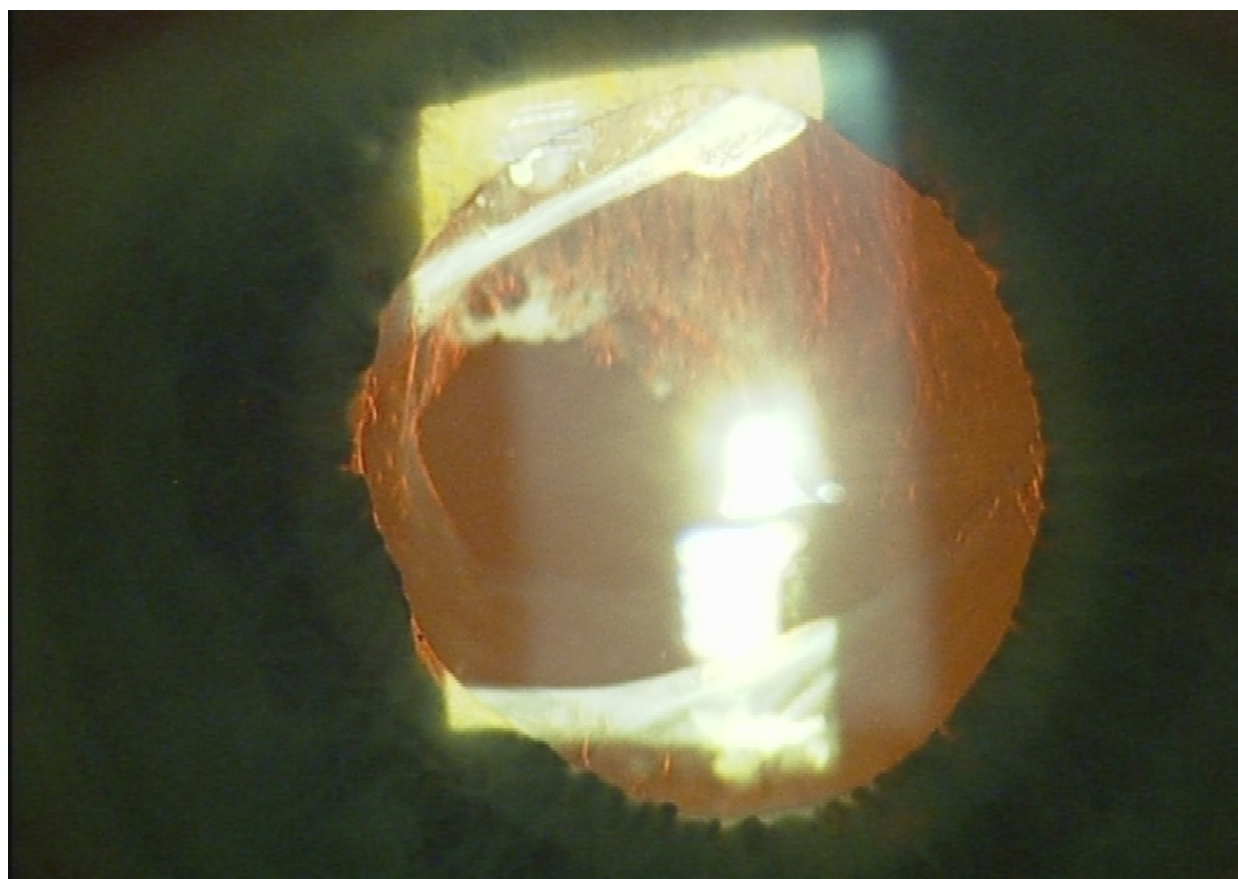


Fig. 3. Nd: YAG posterior capsulotomy laser for posterior capsule opacification

## 6. Cystoid macular oedema (CMO)

Advances in cataract surgery techniques and increasing awareness of the importance of minimizing vitreous loss have resulted in a marked reduction in the incidence of cystoid macular oedema (CMO) compared with the era of intracapsular cataract surgery (42,43).

Cystoid macular oedema is now considered an infrequent complication and the literature suggests that the incidence of pseudophakic CMO following uncomplicated phacoemulsification of the lens and implantation of an in-the-bag intraocular lens is 0.6–6% (43). The incidence of CMO is higher if the surgery is complicated (e.g., posterior capsule rupture with or without vitreous loss, iris damage and vitreous incarceration through the wound) (44). It is also more common in diabetic eyes and in patients with pre-existing uveitis (45,46).

CMO following cataract surgery results from the maldistribution of intravascular fluid within the macula. Leakage of intravascular contents from the dilated perifoveal capillaries initially causes thickening of the macula, which may progress to cystoid expansions within the outer plexiform (Henle's) layer and inner nuclear layer of the retina (47). Most investigators agree that inflammation is the major aetiological factor with prostaglandin release being implicated as the possible mediator of inflammation (48).

Pseudophakic CMO is characterized by poor postoperative visual acuity. CMO has a peak incidence of 4–6 weeks following cataract surgery (49) but can occur earlier in complicated cases. Diagnosis is made after slit lamp biomicroscopy but subtle cases can be diagnosed

with optical coherence tomography examination (OCT) (Figure 4). Fundus fluorescein angiography could also be helpful in diagnosis of CMO and usually shows perifoveal petaloid staining pattern and late leakage of the optic disc but is not needed in all cases and has been superseded by OCT.

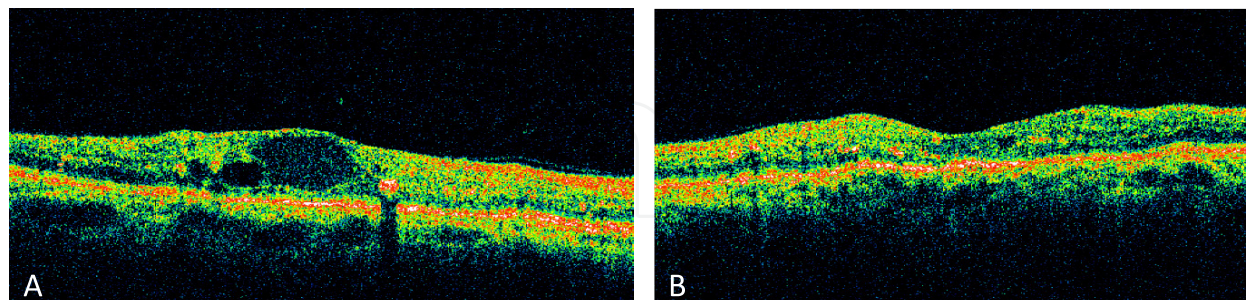


Fig. 4. Optical coherence tomography photographs of chronic cystoid macular oedema before (a) and after (b) treatment with intravitreal triamcinolone.

Most CMO cases (>80%) will resolve spontaneously within weeks to months. The presence of chronic CMO however occurs in a small proportion of patients (1%) leading to chronic or permanent vision loss and hence the argument for early diagnosis and treatment of CMO. Several studies have considered the effect of pharmacologic and surgical treatments for pseudophakic CMO. Most clinicians use a combination of topical corticosteroids and non steroidal anti-inflammatory drugs (NSAIDs) as a first-line treatment in most instances (50). Corticosteroids inhibit several parts of inflammation including prostaglandin synthesis by inhibiting the enzyme phospholipase A2, while NSAIDs interrupt prostaglandin synthesis by inhibiting the enzyme cyclo-oxygenase. A course of 6 weeks treatment is usually tried before a second line treatment is considered. For cases that do not respond, treatment options include periocular or intravitreal steroids and oral acetazolamide. Periocular steroids (sub-Tenon or peribulbar) have the advantageous of being able to reach the posterior segment of the eye in a higher concentration compared to topical application and have less ocular side effects compared to the intravitreal route. Side effects include raised intraocular pressure, cataract, orbital fat prolapse and ptosis but these are less likely to occur after a single injection. Intravitreal triamcinolone injection is an effective treatment option for resistant postoperative CMO, although there are no randomized prospective trials to date. Intravitreal triamcinolone results in a rapid improvement in visual acuity that may be sustained for more than 6 months (51-52). However it is associated with significant ocular morbidity including a high risk of cataract, ocular hypertension and a small risk of infectious or sterile endophthalmitis (Figure 5).

Carbonic anhydrase inhibitors (CAIs), such as acetazolamide, have been used in cases resistant to standard topical treatment with some success (53, 54). They enhance the pumping action of retinal pigment epithelial cells, facilitating the transport of fluid across the retina. However, there are no controlled studies that demonstrated a positive effect of acetazolamide on pseudophakic macular oedema.

Bevacizumab (Avastin) is a monoclonal antibody able to inactivate the effects of vascular endothelial growth factors (VEGF). The role of VEGF in pseudophakic CMO is not clear, yet several authors have reported resolution of CMO after administration of bevacizumab (55) retrospectively. This class of drugs could be of benefit in patients with chronic CMO that have exhibited a steroid hypertensive response to topical or periocular steroids. However, a report by Spitzer et al did not find any beneficial effects with this treatment (56).



When vitreous is incarcerated in the corneal wound following complicated cataract surgery, Nd:YAG laser lysis of vitreous strands has been shown to have a positive effect on restoring the retinal vascular stability and reduction of macular oedema (57). Finally, pars plana vitrectomy (PPV) could be employed in the management of chronic postoperative CMO (58). This helps to remove vitreous strands tracking to the surgical wound after complicated ocular surgery as well as peeling of epiretinal membranes from the surface of the macula when associated with CMO. It also works by removal of inflammatory mediators from the vitreous or retained nuclear lens fragments and possibly by increasing oxygen diffusion to the macula.

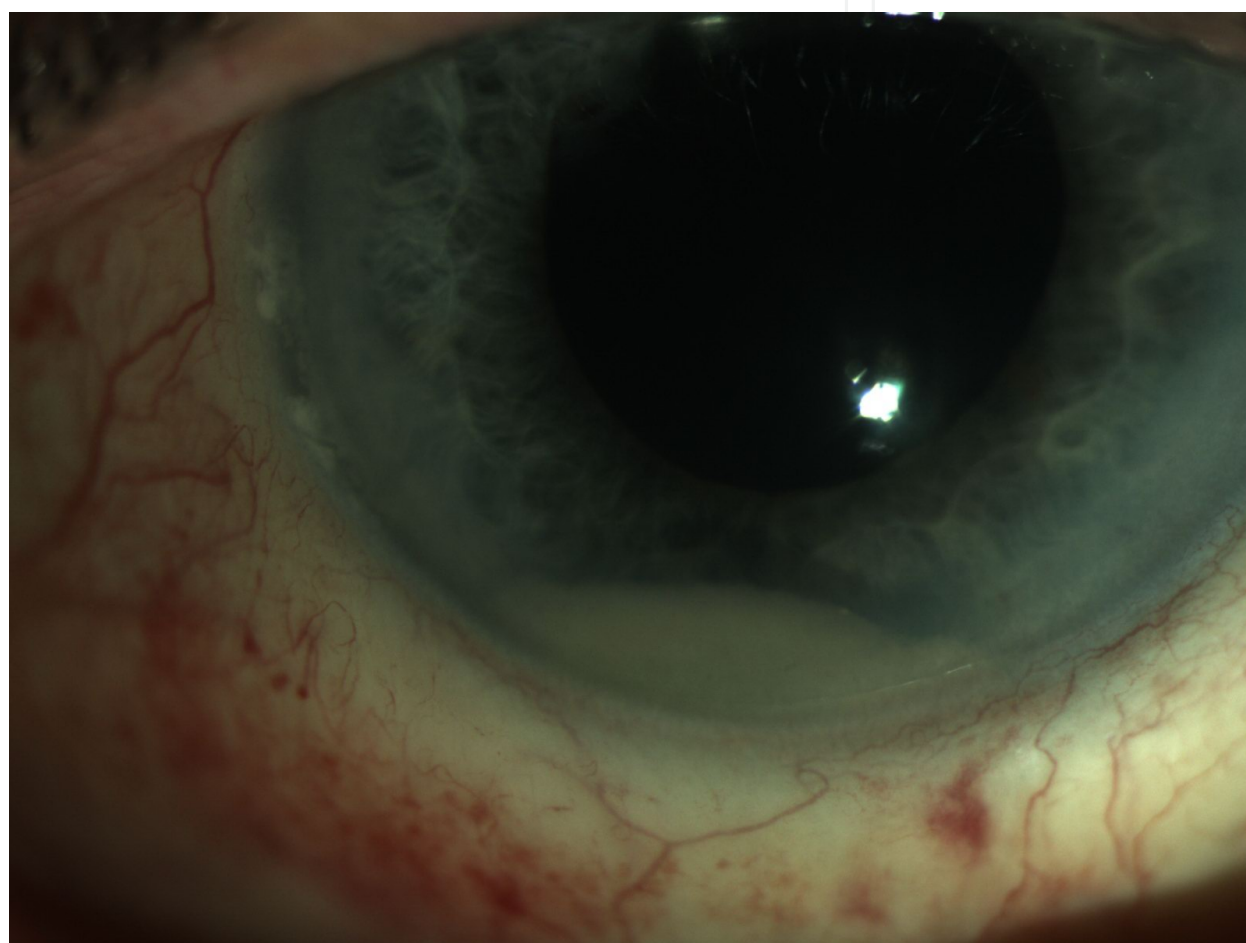


Fig. 5. Sterile endophthalmitis with a pseudohypopyon due to deposition of triamcinolone crystals in the anterior segment after intravitreal triamcinolone treatment.

There is debate whether routine prophylactic treatment of CMO is needed as the cost:benefit ratio of treatment and long term visual benefit are not clear. Unless a patient presented with risk factors for developing CMO—diabetes, previous vein occlusions, uveitis or epiretinal membrane, prophylactic intervention prior to cataract is usually not employed by most clinicians. When indicated, topical NSAIDs are the most widely used class of drugs in the prophylaxis of pseudophakic CMO and several studies have reported that they are effective in this context (59).

### 6.1 Posterior vitreous detachment and rhegmatogenous retinal detachment

Posterior vitreous detachment (PVD) is considered to be common following cataract surgery and can occur at any time. A published study found a prevalence of PVD in 50.8% of eyes that had undergone cataract surgery compared to 20.8% in the fellow unoperated eye (60). The removal of the crystalline lens and its replacement with a thinner IOL implant leaves more space inside the globe for the vitreous to move forward which may induce a detachment from the posterior pole. The study also found that eyes with an axial length of more than 25mm were at increased risk of developing PVD (60).

Rhegmatogenous retinal detachment (RRD) is rare but is a serious potential complication of cataract surgery. The prevalence is much lower with phacoemulsification and small incision surgery than that found after intra-capsular cataract extraction (ICCE). It is this increased incidence of PVD after cataract surgery that is the main precipitating factor in the development of retinal breaks and subsequent pseudophakic RRD. 75% of retinal detachments occur in the first year while the other quarter may develop within 4 years of surgery (61). The risk of RRD appears to be increased in male patients, myopes and very significantly in those patients who have vitreous loss at the time of cataract surgery. It was also found that scleral-sutured posterior chamber intraocular lenses (PCIOLs) may be associated with a high risk of RD due to pre-existing conditions (myopia, aphakia and vitreous loss) and vitreous disturbances as well as pars plana entry sites during IOL fixation. In addition, retinal breaks may result from traumatic incarceration of the IOL and pre-retinal manipulation of dislocated IOLs (62). Nd:YAG laser posterior capsulotomy may increase the risk of retinal detachment after cataract surgery. The hazard ratio of RD after Nd:YAG laser posterior capsulotomy was 4.9, however, this risk is changed by a factor of 1.3 with an increase of axial length of 1 mm and by a factor of 0.94 for each added year of the patient's age (63).

Pseudophakic retinal detachment can be treated with a number of different approaches including pneumatic retinopexy, scleral buckling and primary pars plana vitrectomy. While choice of surgery remains a matter of personal choice for the surgeon, there is growing popularity in use of pars plana vitrectomy for treatment of retinal detachment particularly because retinal tears in pseudophakic eyes could be multiple and thus difficult to treat successfully with pneumatic retinopexy or a localized buckle. One recent prospective randomized trial that compared primary vitrectomy and scleral buckling in rhegmatogenous retinal detachment showed superiority of the former over the latter in pseudophakic eyes (64).

### 6.2 Lens dislocation

This is a rare complication with the patient complaining of blurred vision, glare and possibly monocular diplopia. The visual symptoms can be potentially disabling for the patient and requires repositioning of the lens, or IOL exchange. The IOL implant can be displaced by asymmetrical thickening or fibrosis of the lens capsule particularly in cases complicated by zonular dehiscence or patients with pre-existing weakness of the zonules as in pseudoexfoliation syndrome. Lens dislocation can also result from ocular trauma or previous pars plana vitrectomy.

A major problem associated with posteriorly dislocated IOL is retinal damage during the intraocular manipulations. Removal of a posteriorly located IOL through the corneal wound is hazardous and should not be attempted. Pars plana vitrectomy surgery is needed for



retrieval of the lens from the vitreous followed by IOL exchange or repositioning in the ciliary sulcus with or without suturing to the sclera (65). However, some patients may be treated conservatively and their aphakia corrected with a contact lens or secondary lens implant.

### **6.3 Capsular block syndrome**

Also known as capsular bag distension, this occurs after cataract removal and placement of a posterior chamber IOL. Typically the patient reports blurring of vision postoperatively, which is usually found to be due to an induced myopic shift, although a hyperopic shift or no refractive change have also been reported (66-68).

The pathogenesis of this condition may be due to a fibrotic reaction with a larger lens optic in the capsular bag allowing enhanced adhesion between the lens and the capsule resulting in sealing of the capsulorrhexis (2). It is postulated that this syndrome may result from osmotic movement of fluid due to various types of collagen and substances produced by the proliferating lens epithelial cells and is associated with lens capsule thickening (69, 70). Nd:YAG posterior capsulotomy laser is usually performed to release the fluid into the vitreous cavity and in most cases this is sufficient to improve the vision. Retained viscoelastic behind the lens can also cause this condition and may have to be removed surgically.

### **6.4 Ptosis and diplopia**

This is an unusual complication of cataract surgery and usually occurs several months later. It is important to take a thorough ocular history, as it is possible that the ptosis may have been present prior to cataract surgery but went unnoticed.

This form of ptosis is often transient and does not require intervention, although persistent ptosis may require surgical intervention. Causes of persistent ptosis usually involve damage to the levator muscle due to the toxic effects of anaesthesia, prolonged oedema, and trauma from direct injection into the muscle, or from the lid speculum during cataract surgery.

Persistent diplopia is an uncommon complication after cataract surgery. Some cases are due to vertical or less commonly horizontal muscle imbalance which is thought to be due to direct surgical trauma or due to an anaesthetic myotoxic effect (71). Patients with pre-operative diplopia should also be counselled about this risk as the deviation may be unstable in a quite large proportion of these patients and some cases may need surgical treatment to correct their diplopia (72). Another cause of postoperative diplopia is aniseikonia due to surgically induced anisometropia.

### **6.5 Corneal oedema and pseudophakic bullous keratopathy (PBK)**

Postoperative corneal oedema is not a rare complication of phacoemulsification. Epithelial oedema (that is not associated with stromal oedema) is usually due to increased IOP and is reversible when the cause is treated. Presence of corneal stromal oedema postoperatively is a sign of endothelial damage. This may result from pre-existing endothelial pathology as in Fuch's Endothelial Dystrophy or intraoperative endothelial trauma particularly after phacoemulsification of dense nuclei and in complicated cases with posterior capsular rupture and vitreous loss. Postoperative uveitis can also lead to endothelial cell loss and corneal oedema as in TASS.

Postoperatively, corneal stromal oedema can be localized or diffuse and is usually associated with underlying Descemet's membrane folds, hence the name striate keratopathy. Clinically, this could also be associated with epithelial oedema and in severe cases epithelial bullae may be seen. Vision is usually significantly affected in patients with striate keratopathy although mild cases can manifest with blurred vision early in the morning which improves later in the day. Chronic unresolved corneal oedema (decompensated corneal oedema) can lead to progressive scarring with severe decline in visual acuity.

Mild stromal oedema secondary to intraoperative trauma usually settles with time. While topical steroids can help decrease associated intraocular inflammation and limit further insult to the endothelium from inflammation, steroids have no direct effect on the corneal endothelium. Reduction of raised IOP can also help the cornea to recover by decreasing further damage to the endothelium and while most IOP-lowering drops may be used it is better to avoid topical CAIs as they can adversely affect recovery of corneal endothelium. Hypertonic saline drops can help improve the symptoms until the cornea recovers but does not change the outcome. Bandage contact lenses can also be helpful in decreasing pain from ruptured epithelial bullae and recurrent corneal erosions in eyes with advanced corneal oedema. Penetrating keratoplasty (PKP) would be the definitive treatment for eyes with decompensated corneal oedema to improve the vision. More recently, Descemet's stripping endothelial keratoplasty (DSEK) is becoming more popular and has the advantage of more rapid visual recovery and less corneal astigmatism.

For hard nuclei or in cases with borderline corneal endothelial function, a dispersive ophthalmic viscosurgical device (OVD) is of benefit to protect the cornea and decrease the severity of postoperative corneal oedema. The best dispersive OVD in our experience is Viscoat (40 mg sodium chondroitin sulphate and 30 mg sodium hyaluronate). In this context the authors inject the dispersive OVD first and then place the cohesive OVD underneath it to form a soft shell as described by Arshinoff (73). Healon5 is a viscoadaptive OVD that combines cohesive with dispersive properties and therefore can be used in both routine and complex cataract surgery and provides corneal protection (74). However, caution is needed when using Healon5 as overfilling the anterior chamber can result in difficult manipulation of the anterior capsule and can also predispose to phaco burn (74). Creating a fluid space around the phaco tip before phacoemulsification should circumvent these problems. This can be performed by partially filling the anterior chamber with the OVD and injecting balanced salt solution (BSS) underneath, as described by Arshinoff in his ultimate soft-shell technique (74, 75).

## 7. Conclusion

Cataract surgery is the commonest surgical operation performed in the world. Perioperative complications can be reduced by training and reflective surgical practice. Adequate preventive measures, timely diagnosis and early recognition as well as appropriate management of complications can decrease ocular morbidity. Posterior capsule rupture and vitreous loss is the most common intraoperative complication and is regarded as the benchmark of the quality of a surgeons' training and experience. Anticipation of the likelihood of complications before, during and after surgery is the most important way to reduce complications.

## 8. References

- [1] El-Hindy N, Johnston RL, Jaycock P, Eke T, Braga AJ, Tole DM, et al. The Cataract National Dataset Electronic Multi-centre Audit of 55,567 operations: anaesthetic techniques and complications. *Eye (Lond)* 2009 Jan; 23(1):50-55.
- [2] Karampatakis V, Natsis K, Gigis P, Stangos NT. The risk of optic nerve injury in retrobulbar anesthesia: a comparative study of 35 and 40 mm retrobulbar needles in 12 cadavers. *Eur J Ophthalmol* 1998 Jul-Sep; 8(3):184-187.
- [3] Eke T, Thompson JR. Serious complications of local anaesthesia for cataract surgery: a 1 year national survey in the United Kingdom. *Br J Ophthalmol* 2007 Apr; 91(4):470-475.
- [4] Rodriguez-Coleman H, Spaide R. Ocular complications of needle perforations during retrobulbar and peribulbar injections. *Ophthalmol Clin North Am* 2001 Dec; 14(4):573-579.
- [5] Reddy MK. Complications of cataract surgery. *Indian J Ophthalmol* 1995 Dec; 43(4):201-209.
- [6] Wadood AC, Dhillon B, Singh J. Inadvertent ocular perforation and intravitreal injection of an anesthetic agent during retrobulbar injection. *J Cataract Refract Surg* 2002 Mar; 28(3):562-565.
- [7] Jaycock P, Johnston RL, Taylor H, Adams M, Tole DM, Galloway P, et al. The Cataract National Dataset electronic multi-centre audit of 55,567 operations: updating benchmark standards of care in the United Kingdom and internationally. *Eye (Lond)* 2009 Jan; 23(1):38-49.
- [8] Stainer L. Cataract surgery complications1. Intraoperative complications. Continuing education & training. On line publication; course code C-11440. 2009:23-29.
- [9] Zare M, Javadi M-A, Einollahi B, Baradaran-Rafii A-R, Feizi S, Kiavash V. Risk factors for posterior capsule rupture and vitreous loss during phacoemulsification. *J Ophthalmic Vis Res.* 2009; 4(4):208-212.
- [10] Johnston RL, Taylor H, Smith R, Sparrow JM. The Cataract National Dataset electronic multi-centre audit of 55,567 operations: variation in posterior capsule rupture rates between surgeons. *Eye (Lond)* 2010 May; 24(5):888-893.
- [11] Zaidi FH, Corbett MC, Burton BJ, Bloom PA. Raising the benchmark for the 21st century--the 1000 cataract operations audit and survey: outcomes, consultant-supervised training and sourcing NHS choice. *Br J Ophthalmol* 2007 Jun; 91(6):731-736.
- [12] Kuchle M, Schonherr U, Dieckmann U. Risk factors for capsular rupture and vitreous loss in extracapsular cataract extraction. The Erlangen Ophthalmology Group. *Fortschr Ophthalmol* 1989; 86(5):417-421.
- [13] Marques FF, Marques DM, Osher RH, Osher JM. Fate of anterior capsule tears during cataract surgery. *J Cataract Refract Surg* 2006 Oct; 32(10):1638-1642.
- [14] Little BC, Smith JH, Packer M. Little capsulorhexis tear-out rescue. *J Cataract Refract Surg* 2006 Sep; 32(9):1420-1422.
- [15] Chang DF, Masket S, Miller KM, Braga-Mele R, Little BC, Mamalis N, et al. Complications of sulcus placement of single-piece acrylic intraocular lenses: recommendations for backup IOL implantation following posterior capsule rupture. *J Cataract Refract Surg* 2009 Aug; 35(8):1445-1458.
- [16] Wagoner MD, Cox TA, Ariyasu RG, Jacobs DS, Karp CL, American Academy of Ophthalmology. Intraocular lens implantation in the absence of capsular support: a

- report by the American Academy of Ophthalmology. *Ophthalmology* 2003 Apr; 110(4):840-859.
- [17] Rogers NK, Fox PD, Noble BA, Kerr K, Inglis T. Aggressive management of an epidemic of chronic pseudophakic endophthalmitis: results and literature survey. *Br J Ophthalmol* 1994 Feb; 78(2):115-119.
- [18] Han DP, Wisniewski SR, Wilson LA, Barza M, Vine AK, Doft BH, et al. Spectrum and susceptibilities of microbiologic isolates in the Endophthalmitis Vitrectomy Study. *Am J Ophthalmol* 1996 Jul; 122(1):1-17.
- [19] Oxford KW, Abbott RL, Fung WE, Ellis DS. Aspergillus endophthalmitis after sutureless cataract surgery. *Am J Ophthalmol* 1995 Oct; 120(4):534-535.
- [20] Scott IU, Flynn HW, Jr, Feuer W. Endophthalmitis after secondary intraocular lens implantation. A case-report study. *Ophthalmology* 1995 Dec; 102(12):1925-1931.
- [21] Sallam A, Jayakumar S, Lightman S. Intraocular delivery of anti-infective drugs-bacterial, viral, fungal and parasitic. *Recent Pat Antiinfect Drug Discov* 2008 Jan; 3(1):53-63.
- [22] Fintelmann RE, Naseri A. Prophylaxis of postoperative endophthalmitis following cataract surgery: current status and future directions. *Drugs* 2010 Jul 30; 70(11):1395-1409.
- [23] Campochiaro PA, Lim JL. Aminoglycoside toxicity in the treatment of endophthalmitis. The Aminoglycoside Toxicity Study Group. *Arch Ophthalmol* 1994 Jan; 112(1):48-53.
- [24] Theelen T TM. Treatment of acute bacterial endophthalmitis after cataract surgery without vitrectomy. In: Kirchhof B, Wong D. *Vitreo-retinal Surgery (Essentials in Ophthalmology)* 1<sup>st</sup> ed. Springer Press, 2007:70-81. *Vitreo-retinal Surgery*. 1<sup>st</sup> ed. ed.: Springer Press; 2007. p. 70-81.
- [25] Durand M. Microbiologic factors and visual outcome in the Endophthalmitis Vitrectomy Study. *Am J Ophthalmol* 1997 Jul; 124(1):127-130.
- [26] Winward KE, Pflugfelder SC, Flynn HW, Jr, Roussel TJ, Davis JL. Postoperative Propionibacterium endophthalmitis. Treatment strategies and long-term results. *Ophthalmology* 1993 Apr; 100(4):447-451.
- [27] Monson MC, Mamalis N, Olson RJ. Toxic anterior segment inflammation following cataract surgery. *J Cataract Refract Surg* 1992 Mar; 18(2):184-189.
- [28] Choi JS, Shyn KH. Development of toxic anterior segment syndrome immediately after uneventful phaco surgery. *Korean J Ophthalmol* 2008 Dec; 22(4):220-227.
- [29] Holland SP, Morck DW, Lee TL. Update on toxic anterior segment syndrome. *Curr Opin Ophthalmol* 2007 Feb; 18(1):4-8.
- [30] Olson RJ. TASS versus endophthalmitis. *Cataract and Refractive Surgery Today Journal*. 2006:51-52.
- [31] Vass C, Menapace R. Computerized statistical analysis of corneal topography for the evaluation of changes in corneal shape after surgery. *Am J Ophthalmol* 1994 Aug 15; 118(2):177-184.
- [32] Gayton JL, Sanders VN. Implanting two posterior chamber intraocular lenses in a case of microphthalmos. *J Cataract Refract Surg* 1993 Nov; 19(6):776-777.
- [33] Gills JP, Gayton JL, Raanan M. Multiple intraocular lens implantation. In: Gills JP, Fenzel R, Martin RG, eds. *Cataract Surgery: The State of the Art*. Slack; Thorofare, NJ. ; 1998. p. 183-195.



- [34] Gale RP, Saldana M, Johnston RL, Zuberbuhler B, McKibbin M. Benchmark standards for refractive outcomes after NHS cataract surgery. *Eye (Lond)* 2009 Jan; 23(1):149-152.
- [35] Fenzl RE, Gills JP, 3rd, Gills JP. Piggyback intraocular lens implantation. *Curr Opin Ophthalmol* 2000 Feb; 11(1):73-76.
- [36] Sundelin K, Sjostrand J. Posterior capsule opacification 5 years after extracapsular cataract extraction. *J Cataract Refract Surg* 1999 Feb; 25(2):246-250.
- [37] Garston MJ. Three cases of late Cataract Surgery Complications. *Rev of Optom.* 2008; 145(04):85.
- [38] Neuhann IM, Neuhann TF, Heimann H, Schmickler S, Gerl RH, Foerster MH. Retinal detachment after phacoemulsification in high myopia: analysis of 2356 cases. *J Cataract Refract Surg* 2008 Oct; 34(10):1644-1657.
- [39] Duncan G. Lens cell growth and posterior capsule opacification: in vivo and in vitro observations. *Br J Ophthalmol* 1998 Oct; 82(10):1102-1103.
- [40] Schmidbauer JM, Escobar-Gomez M, Apple DJ, Peng Q, Arthur SN, Vargas LG. Effect of haptic angulation on posterior capsule opacification in modern foldable lenses with a square, truncated optic edge. *J Cataract Refract Surg* 2002 Jul; 28(7):1251-1255.
- [41] Auffarth GU, Newland TJ, Wesendahl TA, Apple DJ. Nd:YAG laser damage to silicone intraocular lenses confused with pigment deposits on clinical examination. *Am J Ophthalmol* 1994 Oct 15; 118(4):526-528.
- [42] Gass JDM. *Stereoscopic Atlas of Macular Diseases Diagnosis and Treatment*, 4th edition. St. Louis: MO: MosbyYearbook. ; 1997. p. 478-81.
- [43] Flach AJ. The incidence, pathogenesis and treatment of cystoid macular edema following cataract surgery. *Trans Am Ophthalmol Soc* 1998; 96:557-634.
- [44] Frost NA, Sparrow JM, Strong NP, Rosenthal AR. Vitreous loss in planned extracapsular cataract extraction does lead to a poorer visual outcome. *Eye (Lond)* 1995; 9 ( Pt 4)(Pt 4):446-451.
- [45] Bonnet S. Repercussions of cataract surgery on the development of cystoid macular edema in the diabetic patient. *Bull Soc Belge Ophtalmol* 1995;256:127-129.
- [46] Foster RE, Lowder CY, Meisler DM, Zakov ZN. Extracapsular cataract extraction and posterior chamber intraocular lens implantation in uveitis patients. *Ophthalmology* 1992 Aug; 99(8):1234-1241.
- [47] Ray S, D'Amico DJ. Pseudophakic cystoid macular edema. *Semin Ophthalmol* 2002 Sep-Dec; 17(3-4):167-180.
- [48] Hee MR, Puliafito CA, Wong C, Duker JS, Reichel E, Rutledge B, et al. Quantitative assessment of macular edema with optical coherence tomography. *Arch Ophthalmol* 1995 Aug; 113(8):1019-1029.
- [49] Jaffe NS, Luscombe SM, Clayman HM, Gass JD. A fluorescein angiographic study of cystoid macular edema. *Am J Ophthalmol* 1981 Dec; 92(6):775-777.
- [50] Heier JS, Topping TM, Baumann W, Dirks MS, Chern S. Ketorolac versus prednisolone versus combination therapy in the treatment of acute pseudophakic cystoid macular edema. *Ophthalmology* 2000 Nov; 107(11):2034-8; discussion 2039.
- [51] Conway MD, Canakis C, Livir-Rallatos C, Peyman GA. Intravitreal triamcinolone acetonide for refractory chronic pseudophakic cystoid macular edema. *J Cataract Refract Surg* 2003 Jan; 29(1):27-33.
- [52] Koutsandrea C, Moschos MM, Brouzas D, Loukianou E, Apostolopoulos M, Moschos M. Intraocular triamcinolone acetonide for pseudophakic cystoid macular edema:



- optical coherence tomography and multifocal electroretinography study. *Retina* 2007 Feb; 27(2):159-164.
- [53] Cox SN, Hay E, Bird AC. Treatment of chronic macular edema with acetazolamide. *Arch Ophthalmol* 1988 Sep; 106(9):1190-1195.
- [54] Marmor MF, Maack T. Enhancement of retinal adhesion and subretinal fluid resorption by acetazolamide. *Invest Ophthalmol Vis Sci* 1982 Jul; 23(1):121-124.
- [55] Rotsos TG, Moschos MM. Cystoid macular edema. *Clin Ophthalmol* 2008 Dec; 2(4):919-930.
- [56] Spitzer MS, Ziemssen F, Yoeruek E, Petermeier K, Aisenbrey S, Szurman P. Efficacy of intravitreal bevacizumab in treating postoperative pseudophakic cystoid macular edema. *J Cataract Refract Surg* 2008 Jan; 34(1):70-75.
- [57] Steinert RF, Wasson PJ. Neodymium: YAG laser anterior vitreolysis for Irvine-Gass cystoid macular edema. *J Cataract Refract Surg* 1989 May; 15(3):304-307.
- [58] Fung WE. Vitrectomy for chronic aphakic cystoid macular edema. Results of a national, collaborative, prospective, randomized investigation. *Ophthalmology* 1985 Aug; 92(8):1102-1111.
- [59] Rossetti L, Chaudhuri J, Dickersin K. Medical prophylaxis and treatment of cystoid macular edema after cataract surgery. The results of a meta-analysis. *Ophthalmology* 1998 Mar; 105(3):397-405.
- [60] Hilford D, Hilford M, Mathew A, Polkinghorne PJ. Posterior vitreous detachment following cataract surgery. *Eye (Lond)* 2009 Jun; 23(6):1388-1392.
- [61] Tielsch JM, Legro MW, Cassard SD, Schein OD, Javitt JC, Singer AE, et al. Risk factors for retinal detachment after cataract surgery. A population-based case-control study. *Ophthalmology* 1996 Oct; 103(10):1537-1545.
- [62] Shakin EP, Carty JB, Jr. Clinical management of posterior chamber intraocular lens implants dislocated in the vitreous cavity. *Ophthalmic Surg Lasers* 1995 Nov-Dec; 26(6):529-534.
- [63] Ninn-Pedersen K, Bauer B. Cataract patients in a defined Swedish population, 1986 to 1990. V. Postoperative retinal detachments. *Arch Ophthalmol* 1996 Apr; 114(4):382-386.
- [64] Heimann H, Bartz-Schmidt KU, Bornfeld N, Weiss C, Hilgers RD, Foerster MH, et al. Scleral buckling versus primary vitrectomy in rhegmatogenous retinal detachment: a prospective randomized multicenter clinical study. *Ophthalmology* 2007 Dec; 114(12):2142-2154.
- [65] Lewis H, Sanchez G. The use of perfluorocarbon liquids in the repositioning of posteriorly dislocated intraocular lenses. *Ophthalmology* 1993 Jul; 100(7):1055-1059.
- [66] Chee SP, Jap A, Theng JT. Induced myopia associated with capsular bag distension syndrome. *Ophthalmology* 2001 Sep; 108(9):1517.
- [67] Theng JT, Jap A, Chee SP. Capsular block syndrome: A case series. *J Cataract Refract Surg* 2000 Mar; 26(3):462-467.
- [68] Wendrix G, Zeyen T. Late-onset capsular bag distention syndrome after cataract surgery: 2 case-reports. *Bull Soc Belge Ophtalmol* 2006;(301) (301):67-69.
- [69] Sugiura T, Miyauchi S, Eguchi S, Obata H, Nanba H, Fujino Y, et al. Analysis of liquid accumulated in the distended capsular bag in early postoperative capsular block syndrome. *J Cataract Refract Surg* 2000 Mar; 26(3):420-425.

- [70] Cheung D, James N. Late-onset capsular block syndrome: an occult cause of decreased vision in a 63-year-old pseudophakic Asian woman. *Eye (Lond)* 2001 Feb; 15(Pt 1):107-108.
- [71] Capo H, Guyton DL. Ipsilateral hypertropia after cataract surgery. *Ophthalmology* 1996 May; 103(5):721-730.
- [72] Wylie J, Henderson M, Doyle M, Hickey-Dwyer M. Persistent binocular diplopia following cataract surgery: aetiology and management. *Eye (Lond)* 1994; 8 (Pt 5) (Pt 5):543-546.
- [73] Arshinoff SA. Dispersive-cohesive viscoelastic soft shell technique. *J Cataract Refract Surg* 1999 Feb; 25(2):167-173.
- [74] Arshinoff SA. Using BSS with viscoadaptives in the ultimate soft-shell technique. *J Cataract Refract Surg* 2002 Sep; 28(9):1509-1514.
- [75] Sallam A, Kashani S, Sherfat H. Healon5 and corneal wound burn during phacoemulsification. *J Cataract Refract Surg* 2007 May; 33(5):754; author reply 754-5.