

We are IntechOpen, the world's leading publisher of Open Access books Built by scientists, for scientists

6,900

Open access books available

186,000

International authors and editors

200M

Downloads

Our authors are among the

154

Countries delivered to

TOP 1%

most cited scientists

12.2%

Contributors from top 500 universities



WEB OF SCIENCE™

Selection of our books indexed in the Book Citation Index
in Web of Science™ Core Collection (BKCI)

Interested in publishing with us?
Contact book.department@intechopen.com

Numbers displayed above are based on latest data collected.
For more information visit www.intechopen.com



Penetrating Aortic Ulcers

Arman Kilic and Ahmet Kilic

Additional information is available at the end of the chapter

<http://dx.doi.org/10.5772/54107>

1. Introduction

Penetrating aortic ulcers were initially described by Shennan in 1934 [1]. Shumacker and King reported the first operative repair of a ruptured descending aorta secondary to a penetrating aortic ulcer in 1959 [2]. The clinical and pathologic entity of penetrating aortic ulcers was not established, however, until 1986 by Stanson [3]. Since that time, the body of literature on this disease has increased significantly. This chapter provides a broad overview of penetrating aortic ulcers.

2. Pathophysiology

Acute aortic syndromes are a group of disease entities that include penetrating aortic ulcers in addition to aortic dissections and intramural hematomas. Aortic dissections are defined by a tear of the intima that results in passage of blood and separation of the intimal and medial or adventitial layers of the vessel wall (Figure 1) [4]. This typically occurs in patients with cystic medial necrosis or medial degeneration. This creates a false lumen, and propagation of the tear either antegrade or retrograde can result in aortic valve insufficiency, cardiac tamponade, and/or organ malperfusion [5]. Intramural hematomas are caused by rupture of the vasa vasorum. This leads to hemorrhage within the aortic media, and can subsequently lead to rupture of the aortic wall or inward disruption of the intima with resultant secondary aortic dissection [6,7].

As the name suggests, penetrating aortic ulcers arise from atheromatous plaques that ulcerate, causing disruption of the internal elastic lamina [6]. Erosion into the medial layer can lead to development of an intramural hematoma or dissection, complications that can eventually lead to pseudoaneurysm formation or aortic rupture. Penetrating aortic ulcers tend to occur in patients with advanced atherosclerosis. Furthermore, they can occur in isolation or in multiples

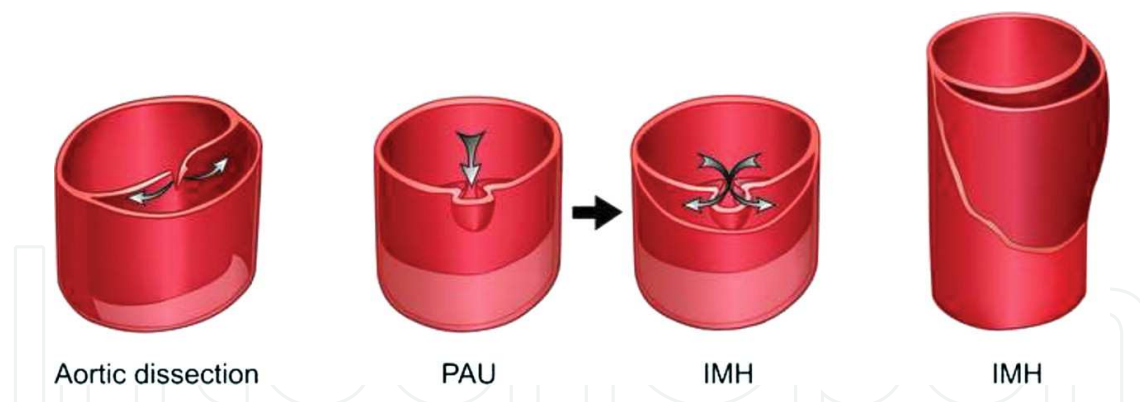


Figure 1. Acute aortic syndromes include aortic dissections, penetrating aortic ulcers (PAU), and intramural hematomas (IMH), each with different pathophysiologies. Aortic dissections are defined by a tear in the intima and separation of the intimal and medial or adventitial layers. Penetrating aortic ulcers result from lesions that ulcerate and disrupt the internal elastic lamina. Intramural hematomas can arise from penetrating aortic ulcers, or can occur in isolation after disruption of the vaso vasorum (from Reference 4 – permission granted).

[8]. Most commonly, penetrating aortic ulcers affect the descending thoracic aorta and less commonly the aortic arch, abdominal aorta, or ascending aorta [9].

3. Epidemiology

Penetrating aortic ulcers comprise 2% to 11% of acute aortic syndromes [10]. In a classic autopsy study, only 4.6% of aortic dissections were found to originate from penetrating aortic ulcers [11]. In one study of incidental findings during cardiac computed tomography for acute chest pain in an emergency department setting, only 1 (0.3%) of 395 consecutive patients was found to have a penetrating aortic ulcer [12]. Another study of incidental findings during cardiac computed tomography similarly found a low prevalence of penetrating aortic ulcers, with only 2 (0.2%) detected in a sample of 966 patients [13].

4. Clinical presentation

The risk factors and clinical presentation of penetrating aortic ulcers are similar yet different in some ways from intramural hematomas and aortic dissections. Similar to patients with intramural hematomas, patients with penetrating aortic ulcers tend to be elderly and are typically older than patients with aortic dissection. As with the other acute aortic syndromes, symptoms include severe chest pain or midscapular pain. An important difference between penetrating aortic ulcers and aortic dissections is that the former tends to be focal disease with absent signs of malperfusion or branch vessel occlusion, whereas the latter can be extensive and present with aortic insufficiency or organ malperfusion. The atherosclerotic burden also tends to be the greatest in patients with penetrating aortic ulcers as compared to those with intramural hematomas or aortic dissections in whom the degree of atherosclerosis is variable.

In a study of 19 patients with penetrating aortic ulcers, common comorbidities included hypertension (95%), chronic obstructive pulmonary disease (63%), cardiac disease (42%), chronic renal insufficiency (26%), and diabetes mellitus (16%) [14]. This comorbidity profile was similar to that seen in patients with intramural hematomas. Patients with penetrating aortic ulcers were found to have the highest rate of concomitant abdominal aortic aneurysms (42%).

A large series of 105 patients with penetrating aortic ulcers demonstrated similar results [15]. Moreover, patients tended to be elderly with an average age of 72 years, and most patients were males (70%) and symptomatic (75%). Common comorbidities included hypertension (92%), smoking (77%), coronary artery disease (46%), chronic obstructive pulmonary disease (24%), and chronic renal insufficiency (21%). Concomitant abdominal aortic aneurysms were found in 61% of patients, and 30% had a pleural effusion on presentation.

5. Diagnosis

5.1. History and physical examination

The diagnosis of penetrating aortic ulcers relies first upon a thorough history and physical examination. The typical patient is elderly with a history of hypertension. As mentioned previously, these patients can also have a history of coronary artery disease, chronic obstructive pulmonary disease, renal disease, and tobacco use. They typically present with anterior chest or midscapular pain. Similar to aortic dissections, those with anterior chest pain usually have ascending aortic involvement and those with back pain typically have descending aortic involvement. The differential diagnosis with this typical presentation includes acute coronary syndrome, aortic aneurysm, aortic dissection, intramural hematoma, and pulmonary embolism.

Physical examination should initially include a review of airway, breathing, and circulation to ensure that the patient is stable. Murmurs indicative of aortic insufficiency typically reflect aortic dissection as opposed to isolated penetrating ulcers, which are focal in nature. Similarly, signs of malperfusion such as neurologic deficits, acute renal insufficiency, visceral vessel compromise, or limb pain with pulse deficit usually occur with dissection as opposed to isolated penetrating aortic ulcers. It is important to note, however, that penetrating aortic ulcers and aortic dissections can occur concomitantly, and therefore, the presence of these signs on physical examination does not exclude a diagnosis of penetrating aortic ulcer. Penetrating aortic ulcers may also be discovered incidentally in asymptomatic patients with imaging performed for other indications.

5.2. Diagnostic modalities

Radiological imaging is essential to the diagnosis of penetrating aortic ulcers given its similarities to other acute aortic syndromes with respect to clinical presentation. A plain chest roentgenogram is frequently obtained in patients presenting with these symptoms and may

demonstrate findings that support a diagnosis of penetrating aortic ulcer, although these findings are often nonspecific. Such findings including enlargement of the thoracic aorta, pleural effusion, widened mediastinum, and deviated trachea.

Although once considered the gold standard in diagnosis, angiography has fallen out of favor as the preferred diagnostic modality for acute aortic syndromes. Indeed, contrast-enhanced computed tomography and magnetic resonance imaging are currently the modalities most frequently employed for diagnosis of penetrating aortic ulcers. The typical radiological features of penetrating aortic ulcers appreciated by these modalities includes severe aortic atherosclerosis, aortic calcification, thickening or enhancement of the aortic wall, and a crater-like focal outpouching of the aortic wall (Figure 2) [16]. If associated with an intramural hematoma, inward displacement of the intima may be appreciated. Transesophageal echocardiography can also be used for diagnosis with a reported high sensitivity and specificity, although its invasive nature and need for a skilled operator are relative disadvantages.

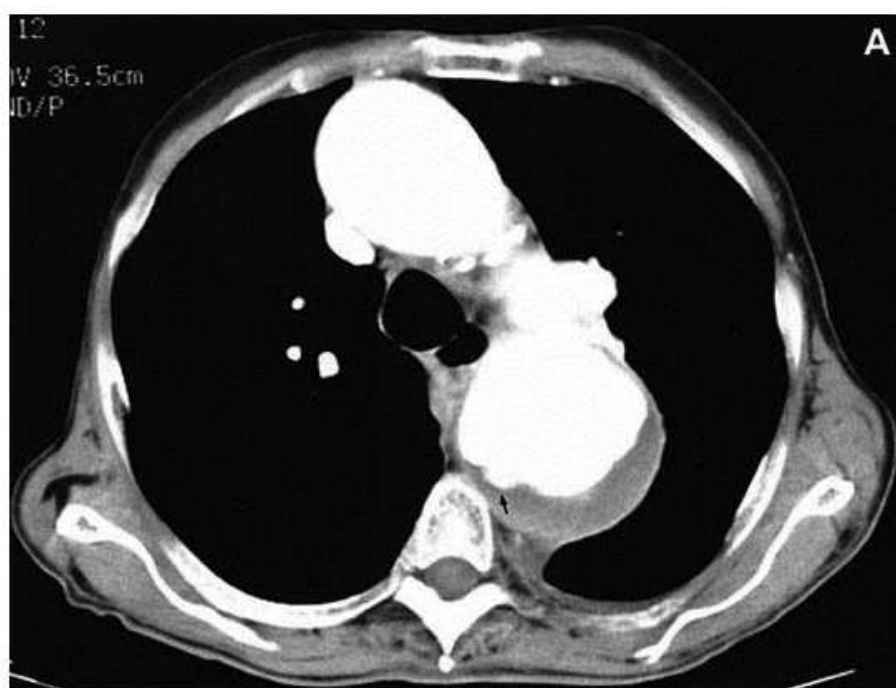

Figure 2. Computed tomography demonstrating a penetrating aortic ulcer as indicated by the black arrow (from Reference 18 – permission granted).

6. Treatment

6.1. Medical management

Patients diagnosed with a penetrating aortic ulcer without rupture or impending rupture, and without involvement of the ascending aorta, can initially be treated medically. Medical

management includes afterload reduction and beta-blockade to reduce shear stress on the aortic wall. Intravenous analgesia should also be used to control pain in symptomatic patients. In symptomatic patients whose pain resolves and no evidence of hemodynamic instability, recurrent symptoms, expanding hematoma, or pseudoaneurysm formation occurs, transitioning to oral antihypertensives and re-imaging in 6 to 12 weeks is a reasonable approach. Asymptomatic patients should also be monitored for disease progression and be placed on an antihypertensive regimen.

6.2. Indications for operative repair

Although there is general agreement to treat ulcers with involvement of the ascending aorta surgically, indications for operative management of penetrating aortic ulcers particularly in the descending aorta remain controversial. A single institution series spanning 25 years and including 105 patients with penetrating aortic ulcers employed nonoperative management in the majority of cases (n=76) [14]. In this nonoperative cohort, 89% of those with an associated intramural hematoma had a decrease in the mean thickness of the hematoma at 1-month, and 85% had a completely resolved hematoma at 1-year. The 30-day mortality rate was significantly lower in the nonoperative (4%) versus operative (21%) group. The only predictors of nonoperative management failure were aortic rupture and earlier era (prior to 1990).

Another study provided a longitudinal analysis of computed tomography scans in patients with aortic ulcers [17]. Of 33 lesions with available follow-up scans, 21 (64%) were found to be stable at a mean follow-up of 18.4 months. In 10 (30%) cases, there was progression of the lesion at a mean follow-up of 19.8 months, with the most common changes consisting of an increase in aortic diameter along with increase in size of lesion (n=7), increase in aortic diameter with incorporation of the ulcer into the aortic wall contour (n=2), and increase in aortic diameter without changes in the ulcer itself (n=1). In the remaining 2 (6%) patients, an associated intramural hematoma decreased in thickness over 1 to 2 months with no changes in the ulcer itself.

Based on these reports, many groups have recommended a conservative approach to penetrating aortic ulcers, with surgical repair indicated only in cases of rupture, impending rupture, persistent pain, or enlarging ulcer or aortic diameter. Other reports, however, have indicated that penetrating aortic ulcers should be treated more aggressively. In a single institution series, the risk of aortic rupture with penetrating aortic ulcers was found to be significantly greater than with type A or type B aortic dissection (40% versus 7% versus 4%; $p<0.0001$) [18]. An updated series by the same group similarly advocated operative management in all patients with penetrating aortic ulcers as long as comorbidities do not preclude surgery given the high early rupture rate, risk of late rupture, and frequency of radiographic progression [19]. Another group advocated aggressive management in patients with penetrating aortic ulcers associated with intramural hematoma given a 48% rate of disease progression [20]. Predictors of disease progression in this latter series included increasing pleural effusion, increasing ulcer diameter, increasing ulcer depth, and persistent or recurrent pain.

6.3. Operative approach

Open repair of the descending thoracic aorta in patients with penetrating aortic ulcers is a significant operation with mortality rates as high as 15-20% [20, 21]. This is in part a reflection of the advanced age and comorbidity burden of the typical patient with this disease. Given the frequently segmental nature of aortic ulcers and the higher risk patient profile, an endovascular approach to treatment appears particularly well suited. However, it is important to mention that patients with penetrating ulcers typically have extensive atherosclerotic disease, and therefore, access for endovascular delivery of grafts is challenging if not unfeasible in many patients.

A single-center experience with endovascular treatment of penetrating aortic ulcers in 21 patients demonstrated successful deployment in all patients, with no endoleaks or mortalities at 30-days (Table 1) [22]. Another single institution study compared open repair in 37 patients with endovascular repair in 58 patients [23]. The endovascular cohort was significantly older and had a higher frequency of prior cerebrovascular disease. As expected, the open group involved repair of the aortic arch more frequently. The operative mortality rate was 5.1% in the endovascular group, which was one-third of that observed in the open cohort (16.2%; $p=0.07$). Furthermore, rates of perioperative stroke and prolonged ventilation were higher in those treated with an open approach.

In a European study of 72 patients undergoing endovascular repair of penetrating aortic ulcers, there was an in-hospital mortality rate of 4%, with an early endoleak rate of 7% and late endoleak rate of 4% [24]. Long-term survival was also favorable, with 1-, 5-, and 10-year survival being 93%, 72%, and 60%. Age greater than 75 years was an independent predictor of survival in their analysis. Another European study of 22 patients undergoing endovascular treatment of aortic ulcers similarly demonstrated excellent outcomes, with no in-hospital mortalities and no complications aside from stroke in 1 (5%) patient [25].

Although outcomes of an endovascular approach to penetrating aortic ulcers appear favorable, it is unclear if lower volume institutions or surgeons can attain comparable results to those reported in the literature. Referral to centers with significant experience in endovascular surgery is therefore advisable. Furthermore, open surgical repair will always remain an important component of the treatment armamentarium, as certain ulcers are not anatomically amenable to an endovascular approach due to their location, due to unfavorable aortic dimensions or anatomy, or due to an inability to gain access given the frequently extensive atherosclerotic burden of these patients.

7. Conclusions

Understanding the defining characteristics of the various acute aortic syndromes is essential as their pathophysiology and potential therapeutic implications are different. Penetrating aortic ulcers are defined by their focal nature and a patient population that tends to be elderly with significant comorbidities. Given these characteristics, endovascular approaches to

Study	No. of Patients	Patient Characteristics	In-hospital or 30-day Mortality	Complications
Brinster et al [22]	21	Mean age = 73 years 33% male 76% acute symptoms 76% smoking history 73% hypertension 18% COPD 18% diabetes mellitus 18% coronary artery disease 9% renal failure	0%	Reoperation 5% Endoleak 0% Stroke 0% PE 0% Wound infection 0%
Patel et al [23]	58	Mean age = 73 years 47% male 43% aortic rupture 50% smoking history 81% hypertension 89% COPD 12% diabetes mellitus 52% coronary artery disease Mean creatinine = 1.4 mg/dL	5.1%	Stroke 3.4% Dialysis 3.4% Prolonged ventilation 1.7% Endoleak 13.8%
Czerny et al [24]	72	Median age = 67 years 70% male 58% emergency cases 36% aortic rupture 93% hypertension 27% COPD 12% diabetes mellitus 32% coronary artery disease 14% renal insufficiency 8% cerebrovascular accident	4%	Overall complications 29% Early endoleak 7% Late endoleak 4% Open conversion 1% Secondary intervention 21%
Eggebrecht et al [25]	22	Mean age = 69 years 73% male 64% acute presentation 14% aortic rupture 100% hypertension 5% COPD 55% coronary artery disease 41% renal insufficiency	0%	Early endoleak 5% Open conversion 0% Paraplegia 0% Stroke 5%

Table 1. Operative Outcomes following Endovascular Repair of Penetrating Aortic Ulcers.

treatment in those with suitable anatomy appear particularly attractive, and indeed, initial reports from experienced centers have demonstrated favorable outcomes. A growing cumulative experience with penetrating aortic ulcers will hopefully be met with continuing advances and improvements in therapy. This will be particularly important as the population ages and imaging techniques improve, changes that will likely result in increases in the prevalence of this disease.

Author details

Arman Kilic^{1*} and Ahmet Kilic^{2*}

*Address all correspondence to: akilic1@jhmi.edu

*Address all correspondence to: Ahmet.Kilic@osumc.edu

1 Department of Surgery, Johns Hopkins Hospital, Baltimore, MD, USA

2 Division of Cardiac Surgery, The Ohio State University College of Medicine, Columbus, OH, USA

References

- [1] Shennan T. Dissecting aneurysms. Medical Research Council, Special Report Series, No 193. 1934.
- [2] Shumacker Jr HB, King H. Surgical management of rapidly expanding intrathoracic pulsating hematomas. *SurgGynecolObstet* 1959; 109:155-164.
- [3] Stanson AW, Kazmier FJ, Hollier LH, Edwards WD, Pairolero PC, Sheedy PF, Joyce JW, Johnson MC. Penetrating atherosclerotic ulcers of the thoracic aorta: natural history and clinicopathologic correlations. *Ann VascSurg* 1986; 1:15-23.
- [4] Nienaber CA, Powell JT. Management of acute aortic syndromes. *Eur Heart J* 2012; 33: 26-35b.
- [5] Meszaros I, Morocz J, Szilavi J, Schmidt J, Tornoci L, Nagy L, Szepl L. Epidemiology and clinicopathology of aortic dissection. *Chest* 2000; 117:1271–1278.
- [6] Vilacosta I, San Roman JA. Acute aortic syndrome. *Heart* 2001; 85:365 –368.
- [7] Choi SH, Choi SJ, Kim JH, Bae SJ, Lee JS, Song KS, Lim TH. Useful CT findings for predicting the progression of aortic intramural hematoma to overt aortic dissection. *J Comput Assist Tomogr* 2001; 25:295 –299.

- [8] Botta L, Buttazzi K, Russo V, Parlapiano M, Gostoli V, Di Bartolomeo R, Fattori R. Endovascular repair for penetrating atherosclerotic ulcers of the descending thoracic aorta: early and mid-term results. *Ann ThoracSurg* 2008; 85: 987-992.
- [9] Gottardi R, Zimpfer D, Funovics M, Schoder M, Lammer J, Wolner E, Czerny M, Grimm M. Mid-term results after endovascular stent-graft placement due to penetrating atherosclerotic ulcers of the thoracic aorta. *Eur J CardiothoracSurg* 2008; 33: 1019-1024.
- [10] Brinster DR. Endovascular repair of the descending thoracic aorta for penetrating atherosclerotic ulcer disease. *J Card Surg* 2009; 24: 203-208.
- [11] Hirst AE Jr, Barbour BH. Dissecting aneurysm with hemopericardium: report of a case with healing. *N Engl J Med* 1958; 258: 116-20.
- [12] Lehman SJ, Abbata S, Cury RC, Nagurney JT, Hsu J, Goela A, Schlett CL, Dodd JD, Brady TJ, Bamberg F, Hoffmann U. Significance of cardiac computed tomography incidental findings in acute chest pain. *Am J Med* 2009; 122:543-549.
- [13] Machaalany J, Yam Y, Ruddy TD, Abraham A, Chen L, Beanlands RS, Chow BJ. Potential clinical and economic consequences of noncardiac incidental findings on cardiac computed tomography. *J Am CollCardiol* 2009; 54: 1533-1541.
- [14] Coady MA, Rizzo JA, Elefteriades JA. Pathologic variants of thoracic aortic dissections: penetrating atherosclerotic ulcers and intramural hematomas. *CardiolClin* 1999; 17:637-657.
- [15] Cho KR, Stanson AW, Potter DD, Cherry KJ, Schaff HV, Sundt TM 3rd. Penetrating atherosclerotic ulcer of the descending thoracic aorta and arch. *J ThoracCardiovasc-Surg* 2004; 127:1393-1399.
- [16] Hayashi H, Matsuoka Y, Sakamoto I, Sueyoshi E, Okimoto T, Hayashi K, Matsunaga N. Penetrating atherosclerotic ulcer of the aorta: imaging features and disease concept. *Radiographics* 2000; 20:995-1005.
- [17] Quint LE, Williams DM, Francis IR, Monaghan HM, Sonnad SS, Patel S, Deeb GM. Ulcerlike lesions of the aorta: imaging features and natural history. *Radiology* 2001; 218:719-723.
- [18] Coady MA, Rizzo JA, Hammond GL, Pierce JG, Kopf GS, Elefteriades JA. Penetrating ulcer of the thoracic aorta: what is it? How do we recognize it? How do we manage it? *J VascSurg* 1998; 27:1006-1015.
- [19] Tittle SL, Lynch RJ, Cole PE, Singh HS, Rizzo JA, Kopf GS, Elefteriades JA. Midterm follow-up of penetrating ulcer and intramural hematoma of the aorta. *J ThoracCardiovascSurg* 2002; 123:1051-1059.

- [20] Ganaha F, Miller DC, Sugimoto K, Do YS, Minamiguchi H, Saito H, Mitchell RS, Dake MD. Prognosis of aortic intramural hematoma with and without penetrating atherosclerotic ulcer: a clinical and radiological analysis. *Circulation* 2002; 106:342-8.
- [21] Tittle SL, Lynch RJ, Cole PE, Singh HS, Rizzo JA, Kopf GS, Elefteriades JA. Midterm follow-up of penetrating ulcer and intramural hematoma of the aorta *J Thorac Cardiovasc Surg* 2002; 123:1051-1059.
- [22] Brinster DR, Wheatley GH 3rd, Williams J, Ramaiah VG, Diethrich EB, Rodriguez-Lopez JA. Are penetrating aortic ulcers best treated using an endovascular approach? *Ann Thorac Surg* 2006; 82:1688-1691.
- [23] Patel HJ, Sood V, Williams DM, Dasika NL, Diener AC, Deeb GM. Late outcomes with repair of penetrating thoracic aortic ulcers: the merits of an endovascular approach. *Ann Thorac Surg* 2012; 94:516-522.
- [24] Czerny M, Funovics M, Sodeck G, Dumfarth J, Schoder M, Juraszek A, Dziodzio T, Loewe C, Reineke D, Krähenbühl E, Grimm M, Ehrlich M. Results after thoracic endovascular aortic repair in penetrating atherosclerotic ulcers. *Ann Thorac Surg* 2011; 92:562-566.
- [25] Eggebrecht H, Herold U, Schmermund A, Lind AY, Kuhnt O, Martini S, Kühl H, Kienbaum P, Peters J, Jakob H, Erbel R, Baumgart D. Endovascular stent-graft treatment of penetrating aortic ulcer: results over a median follow-up of 27 months. *Am Heart J* 2006; 151:530-536.