

We are IntechOpen, the world's leading publisher of Open Access books Built by scientists, for scientists

6,900

Open access books available

186,000

International authors and editors

200M

Downloads

Our authors are among the

154

Countries delivered to

TOP 1%

most cited scientists

12.2%

Contributors from top 500 universities



WEB OF SCIENCE™

Selection of our books indexed in the Book Citation Index
in Web of Science™ Core Collection (BKCI)

Interested in publishing with us?
Contact book.department@intechopen.com

Numbers displayed above are based on latest data collected.
For more information visit www.intechopen.com



Hereditary Palmoplantar Keratosis

Tamihiro Kawakami

Additional information is available at the end of the chapter

<http://dx.doi.org/10.5772/53572>

1. Introduction

Palmoplantar keratosis or palmoplantar keratoderma (PPK) constitutes a heterogeneous group of disorders characterized by excessive epidermal thickening of the palms and soles of affected individuals [1]. PPK can be characterized as either inherited or acquired. Transgredient PPK extends beyond palmoplantar skin, contiguously or as callosities on pressure points on the fingers or knuckles, or elsewhere. Typical pathohistological findings of PPK are orthokeratotic hyperkeratosis, hyper- or hypogranulosis and acanthosis. These changes are non-specific and found in many types of PPK.

PPK is classified clinically as diffuse, focal, striate, or punctuate and develops either in isolation or in association with other cutaneous or extracutaneous manifestations. The diffuse type consists of uniform involvement of the palmoplantar surface. The focal type consists of localized areas of hyperkeratosis located mainly on pressure points and sites of recurrent friction. The striate type presents with linear hyperkeratosis on the palms and soles. The punctate type features multiple small, hyperkeratotic papules, spicules, or nodules on the palms and soles. These tiny keratoses may involve the entire palmoplantar surface or may be restricted to certain locations.

2. Diffuse PPK

2.1. Unna-Thost PPK

Unna-Thost PPK is inherited in an autosomally dominant manner without associated organ involvement. The condition may manifest in the first few months of life but is usually well developed by age 3-4 years. The disease develops in early childhood and persists throughout life. Clinically, there is hyperkeratosis on the palms and soles. Unna-Thost PPK is characterized by a well-demarcated, symmetric, often "waxy" hyperkeratosis involving the whole of the palms and soles. It is usually nontransgredient, with a sharp demarcation of the lesions at the wrists. Aberrant keratotic lesions may appear in the dorsum of the

hands, feet, knees, and elbows. The dorsa of the fingers may be involved with a scleroderma-like thickening of the distal digit. A cobblestone hyperkeratosis of the knuckles may be seen. Nails may be thickened.

Histological findings include orthokeratotic hyperkeratosis associated with hypergranulosis or hypogranulosis and moderate acanthosis. Molecular biology features include linkage to type II keratin locus on band 12q11-13, corresponding to a keratin 1 gene mutation. Treatment includes salicylic acid, 50% propylene glycol in water under plastic occlusion several nights per week, and lactic acid- and urea-containing creams and lotions; all have been shown to be helpful. Mechanical debridement with a blade may also be useful. Oral retinoid therapy has had variable effects.

2.2. Vörner PPK

This type is inherited in an autosomal dominant fashion. It has an estimated prevalence of at least 4.4 cases per 100,000 population in Northern Ireland. Onset occurs in the first few months of life, but the disease is usually well developed by age 3-4 years. A well-demarcated, symmetric thick, yellow hyperkeratosis is present over the palms and soles, often with a "dirty" snakeskin appearance due to underlying epidermolysis [2]. An erythematous band is frequently present at the periphery of the keratosis. The surface is often uneven and verrucous. Finally, it is usually nontransgradient, with a sharp demarcation of the lesions at the wrists.

Histologically, keratinocytes show epidermolysis, hyperkeratosis, acanthosis, and papillomatosis. Perinuclear vacuolization and large keratohyalin granules are seen. Cellular breakdown in the spinous and granular cell layers sometimes leads to blister formation. Keratin 1 and keratin 9 mutations have also been reported. Treatment includes salicylic acid, 50% propylene glycol in water under plastic occlusion several nights per week, and lactic acid- and urea-containing creams and lotions; all have been shown to be helpful. Mechanical debridement with a blade also may be useful. Oral retinoid therapy has had variable effects and may not benefit patients with certain genotype profiles, such as K1 mutations.

Clinical features of Vörner PPK are very similar to Unna-Thost PPK. Unna-Thost PPK may have a waxy appearance, compared with the dirty appearance of Vörner PPK. Hyperhidrosis and pitted keratolysis may be present with Unna-Thost PPK. Differentiation from Unna-Thost PPK can be made histopathologically, with the finding of epidermolysis. There is no epidermolysis or vacuolar changes in Unna-Thost PPK.

2.3. Mal de Meleda

Mal de Meleda is characterized by a diffuse, thick hyperkeratosis with a prominent erythematous border. This disease is characterized by early infancy onset and follows a progressive course with extension to the dorsal surfaces of the hands and feet. This condition is inherited in an autosomal recessive fashion. The prevalence is 1 case per 100,000 population. The disease has its onset in early infancy and follows a progressive course. It was first described in inhabitants of the Adriatic Island of Meleda.

Mal de Meleda frequently presents with constrictive bands, perioral erythema, nail changes, and occasional brachydactyly, with a progressive clinical course throughout the patients' lives. The main clinical characteristics are transgressive PPK, hyperhidrosis, and perioral erythema. Clinical dermatological features include diffuse, thick keratoderma with a prominent erythematous border. Lesions spread onto the dorsa of the hands and the feet (transgredient). Constricting bands are present around the digits and can result in spontaneous amputation. Well-circumscribed psoriasis-like plaques or lichenoid patches may be present on the knees and the elbows. Patients may have severe hyperhidrosis, possibly accompanied by malodor. Secondary bacterial and fungal infections are common. Other clinical features include: lingua plicata, syndactyly, hair on the palms and the soles, high-arched palate, and left-handedness.

Histologic findings include orthokeratosis and normogranulosis without epidermolysis. Mutations in the gene SLURP1 located on chromosome 8q24.3 were identified as the cause of Mal de Meleda. Molecular biology features include mutations in the gene encoding SLURP1 found on band 8q24.3.

2.4. Nagashima-type PPK

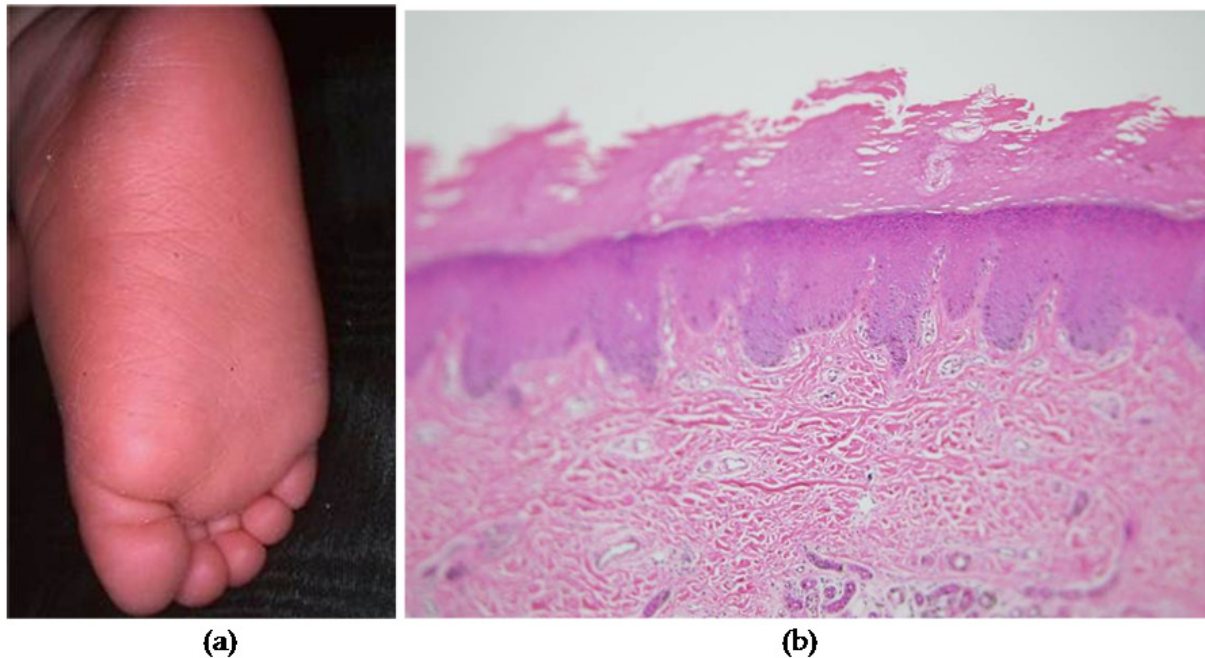
Nagashima-type PPK is included in the diffuse autosomal recessive type of hereditary PPKs without associated features [3]. Nagashima-type PPK was first described in a report from Japan in 1977. Since then, more than 20 cases have been reported in Japan. Nagashima-type cases have been reported only in the Japanese literature; this type of PPK is not well known in Western countries, even though the existence of this disease is recognized. Therefore, the definition and characterization of this disease have not been well recognized globally.

Onset of disease occurs between birth and age 3 years (Figures 1, 2). Because its clinical manifestations are similar to but milder than those of mal de Meleda, it was originally described as a mild form of Mal de Meleda. Mal de Meleda is much more severe than Nagashima-type. It usually involves perioral erythema and occasionally exhibits brachydactyly, nail abnormalities, and lichenoid plaques. Unlike Mal de Meleda, spontaneous amputation has never been observed in Nagashima type PPK. Furthermore, there is no evidence of a SLURP1 mutation in patients with Nagashima-type PPK. The results of genetic study suggested that Nagashima-type PPK is distinct from Mal de Meleda.

2.5. Vohwinkel syndrome

Vohwinkel syndrome (mutilating and diffuse PPK) is associated with various extracutaneous features, including ichthyosis and deafness. Onset occurs in infancy. Clinically, this condition manifests in infants as a honeycomblike keratosis of the palms and the soles. It becomes transgredient during childhood. Later-forming, constricting, fibrous bands appear on the digits and can lead to progressive strangulation and autoamputation. Starfish-shaped keratosis may occur on the knuckles of the fingers and toes, which is a characteristic feature of this disorder. Alopecia, hearing loss, spastic paraplegia, myopathy, ichthyosiform dermatosis, and nail abnormalities are other associated manifestations. Other

reported findings are deaf-mutism, congenital alopecia universalis, pseudopelade type alopecia, acanthosis nigricans, spastic paraplegia, myopathy, nail changes, mental retardation, bullous lesions on the soles, and seizures [4].



A 10-month-old Japanese girl presented with bilateral reddish, palmoplantar hyperkeratotic lesions on her palms and soles. The patient was otherwise healthy.

(A) Right sole

(B) Histopathological findings reveal orthokeratotic hyperkeratosis, hypergranulosis, acanthosis, and a mild lymphocytic infiltrate in the upper dermis of the palm.

Figure 1. Nagashima-type PPK

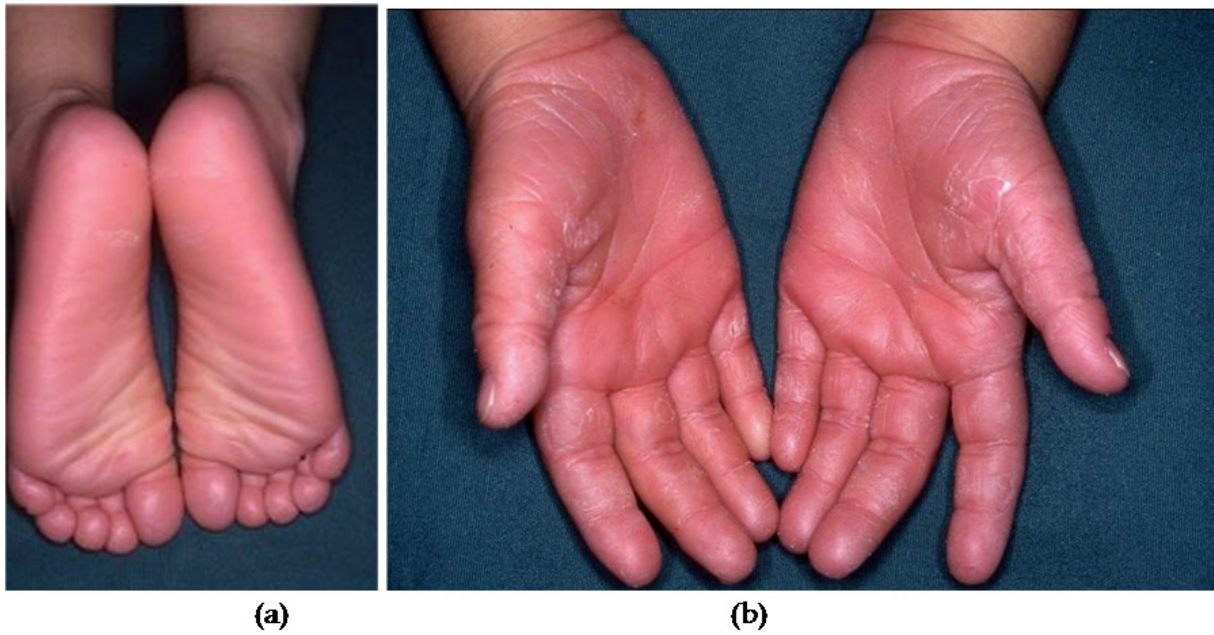
Histological findings include hyperkeratosis, acanthosis, and a thickened granular cell layer with retained nuclei in the stratum corneum. Molecular biology studies have confirmed that the most common mutation is found in the gene encoding connexin 26. This subtype is associated with hearing loss. In contrast, a mutation in the gene for loricrin is associated with mutilating keratoderma and ichthyosis but not deafness. The mode of inheritance for mutation in the loricrin and connexin 26 genes is autosomal dominant. Treatment includes oral retinoids.

2.6. Bart-Pumphrey syndrome

Bart-Pumphrey syndrome is an autosomal-dominant disorder characterized by knuckle pads, leukonychia, PPK and hearing loss. Onset occurs in infancy. PPK may be diffuse and striate, with accentuation of crease patterns and with a grainy surface [5]. Clinically, all neonates are hearing impaired from birth and develop diffuse PPK in childhood. Leukonychia and hyperkeratoses over the joints of the hand may also appear.

Knuckle pads are circumscribed, with hyperkeratotic or fibrous growths over the dorsal aspects of the small joints of the hands or feet. Leukonychia that may be seen in Bart-

Pumphrey syndrome is defined as whiteness of nails that can occur either in patches or involving the total nail. Large keratohyaline granules are found in the keratinocytes, and the keratohyaline-containing cells reflected light, resulting in a white nail appearance. Molecular biology studies reveal a new mutation in the gene that encodes connexin 26, which explains the clinical overlap with Vohwinkel syndrome.



The patient's sister, a 3-year-old girl, had bilateral reddish palmoplantar hyperkeratotic lesions on the (A) soles and (B) palms. This family had no other significant medical history.

Figure 2. Nagashima-type PPK

2.7. Loricrin keratoderma

The term “loricrin keratoderma” has been suggested to group patients with dominantly inherited PPK that has a different clinical presentation characterized by non-bullous congenital ichthyosiform erythroderma, progressive symmetric erythrokeratoderma, and the patients with Vohwinkel syndrome, carrying mutations in loricrin gene [6, 7]. In all loricrin keratoderma patients, the common signs are the palmoplantar honeycomb hyperkeratosis and ichthyosis. Collodion baby was sometimes reported independently from the clinical evolution of the patients. The originally described Vohwinkel syndrome, because of mutations in connexin 26 gene, shows: palmoplantar honeycomb hyperkeratosis; constricting fibrous bands encircling fingers or toes, characterized as pseudoainhum, leading to autoamputation of the fifth finger due to circulatory impairment; starfish-shaped hyperkeratotic lesions on the extensor surfaces; and high-tone deafness. By contrast, in loricrin keratoderma, the hearing impairment and starfish-shaped hyperkeratosis are absent and a generalized non-erythrodermic ichthyosis is described.

2.8. Clouston syndrome (Hidrotic ectodermal dysplasia)

Clouston syndrome (hidrotic ectodermal dysplasia) is an autosomal dominant ectodermal dysplasia characterized by hypotrichosis, severe nail dystrophy, and PPK as well as hyperpigmentation of the skin over the large joints. Clinical features include diffuse papillomatous PPK (especially over pressure points of the palms and soles), dystrophic nails, and hypotrichosis. Thickened, hyperpigmented skin may also appear over the small and large joints, including the knuckles, elbows, and knees. Thickened, severely dystrophic nails develop, but they may be normal at birth. Universal sparsity of hair involves the scalp, eyebrows, eyelashes, and axillary and genital regions. Sensorineural deafness, polydactyly, syndactyly, clubbing of the fingers, mental retardation, dwarfism, photophobia, and strabismus are associated manifestations.

Clouston syndrome reveals orthohyperkeratosis with a normal granular layer based on histopathological analysis of PPK. Ultrastructural studies of the hair of these patients demonstrate disorganization of hair fibrils with loss of the cuticular cortex. Positional cloning identifies GJB6 on chromosome 13q12 as the causative gene for Clouston syndrome [8]. GJB6 encodes connexin 30 (Cx30), which belongs to a family of cell membrane proteins, the connexins, which form gap junctions between neighbouring cells.

2.9. Olmsted syndrome

Olmsted syndrome is an uncommon genetic disorder with symmetrical, diffuse, transgredient, mutilating PPK and periorificial hyperkeratosis [9]. Most cases of this condition are sporadic, with the exception of one report of an autosomal dominant pattern of inheritance. Onset occurs in the first year of life. Clinically, PPK begins focally in infancy and then becomes diffuse and severe. Later findings include flexion deformities and constriction of the digits, sometimes leading to spontaneous amputation. Progressive, well-defined perioral, perianal, and perineal hyperkeratotic plaques are present, as is onychodystrophy. Alopecia, deafness, nail dystrophy, and dental loss may be associated. Squamous cell carcinoma and malignant melanoma are also known to develop in the affected areas. Rare findings include large joint laxity, ichthyotic lesions, absent premolar teeth, hearing loss for high frequencies, and sclerosing cholangitis.

Histological findings include hyperkeratosis without parakeratosis and mild acanthosis. Abnormal expression of keratin 5 and 14 has been reported. Treatment includes oral and topical retinoids. Full-thickness excision and skin grafting has also been reported to result in clinical improvement.

2.10. Huriez syndrome

Huriez syndrome is an autosomal dominant genodermatosis, characterized by the triad of congenital scleroatrophy of the distal extremities, PPK, and hypoplastic nail changes. The soles are not commonly involved. It was first described in two large pedigrees from northern France [10]. In addition to its occurrence in French patients, it has also been

reported in Tunisia, Germany and Italy [11]. Onset occurs in infancy. Clinical features include red, atrophic skin on the dorsal hands and feet at birth. Diffuse, mild keratoderma is more marked on the palms than the soles. Other clinical features are sclerodactyly and nail abnormalities (hypoplasia, fissuring, ridging, koilonychia). The age at the onset of skin cancer is much lower than in the general population, and tumors arise in the areas of the affected skin. Affected individuals carry a more than 100-fold higher risk for the development of aggressive squamous cell carcinoma of the skin.

Histological findings include acanthosis, accentuation of the granular layer, and orthokeratosis. Langerhans cells are almost completely absent in the affected skin. Electron microscopy reveals normal dermoepidermal junctions and desmosomes; however, dense bundles of tonofilaments are seen in the epidermal layer. The granular layer shows large, coarse, clumped keratohyalin. Molecular biology findings include a mutation in the gene mapped to 4q23.

2.11. Papillon-Lefèvre syndrome

Papillon-Lefèvre syndrome is a rare disease characterized by skin lesions, which include PPK and hyperhidrosis with severe periodontal destruction involving both the primary and the permanent dentitions [12]. It is transmitted as an autosomal-recessive condition, and consanguinity of parents is evident in about one-third of the cases. This disease usually has its onset between the ages of 1 to 4 years. The male to female ratio is roughly equal. Its prevalence is estimated to be 1 to 4 per million in the general population with a carrier rate of 2 to 4 per 1000.

Clinically, diffuse transgredient PPK may be observed, typically developing within the first 3 years of life. Punctiform accentuation, particularly along the palmoplantar creases, may be seen. Unless treated, periodontitis results in severe gingivitis and loss of teeth by age 5 years. No significant correlation has been demonstrated between the level of periodontal infection and the severity of skin affections, which supports the concept that these major components of this syndrome are unrelated to each other. Patients exhibit increased susceptibility to cutaneous and systemic infections. Scaly, psoriasiform lesions are often observed over the knees, elbows, and interphalangeal joints. Finally, patients may have malodorous hyperhidrosis.

Histological findings include hyperkeratosis with irregular parakeratosis and moderate perivascular infiltration. Electron microscopic features include lipid-like vacuoles in corneocytes and granulocytes, a reduction in tonofilaments, and irregular keratohyalin granules. Molecular biology findings include mutations in the gene for cathepsin C, mapping to 11q14-q21, which are responsible for this syndrome. Cathepsin C is a lysosomal protease known to activate enzymes that are vital to the body's defenses. The susceptibility factor may involve defective immune function or pleiotropic effect of the single mutant Cathepsin C gene [13].

Treatment includes oral retinoids for the PPK. Elective extraction of involved teeth may prevent excess bone resorption. Appropriate antibiotic therapy may be required for

periodontitis and recurrent cutaneous and systemic infections. Treatment with acitretin starting at an early age shows promise in allowing patients to have normal adult dentition. Early treatment and compliance with the prevention program are the major determinants for preserving permanent teeth in young patients. By extracting all primary teeth and eradicating periodontal pathogens, the patient's adult teeth can erupt into a safe environment. Treatment may be more beneficial if it is started during the eruption and maintained during the development of the permanent teeth. Recommended therapy includes aggressive local measures to control plaque including rigorous oral hygiene, chlorhexidine mouth rinses, frequent professional prophylaxis, and periodic appropriate antibiotic therapy needed for long-term maintenance.

2.12. Naxos disease

Naxos disease is a rare autosomal recessive inherited association of right ventricular dysplasia/dilated cardiomyopathy with woolly hair and PPK [14]. The disease has an adverse prognosis, especially in young patients. In a long-term study of an unselected population of patients with Naxos disease it was shown that risk factors for sudden death include history of syncope, the appearance of symptoms, severely progressive disease of the right ventricle before the age of 35 years, and the involvement of the left ventricle [15]. Symptoms of right heart failure appear during the end stages of the disease. One-third of patients become symptomatic before the 30th year of life. In some cases, a few clinical findings of early heart disease can be detected during childhood.

Clinically, a diffuse, nontransgradient keratoderma with an erythematous border appears during the first year of life. Woolly (dense, rough, and bristly) scalp hair is present at birth. Cardiac disease, manifested by arrhythmias, heart failure, or sudden death, becomes evident during and after late puberty. Other cutaneous manifestations include acanthosis nigricans, xerosis, follicular hyperkeratosis over the zygoma, and hyperhidrosis. In addition to the woolly hair at birth, PPK develops during the first year of life and cardiomyopathy is clinically manifested by adolescence with 100% penetrance. Patients present with syncope, sustained ventricular tachycardia or sudden death.

Histological findings include hyperkeratosis, hypergranulosis, and acanthosis. Molecular biology findings include a mutation in the plakoglobin gene, mapping to 17q21, which is responsible for Naxos disease. Plakoglobin is an important component of cell-to-cell and cell-to-matrix adhesion complexes of many tissues, including the skin and cardiac junctions. It also plays a role in signaling in the formation of desmosomal junctions. Mutations in the plakoglobin gene may lead to detachment of the cardiac myocytes, resulting in myocyte death. Plakoglobin mutations may also lead to desmosomal junction fragility in hair shafts, explaining the clinical phenotype of woolly hair.

The primary goal of treatment is the prevention of sudden cardiac death. Implantation of an automatic cardioverter defibrillator is indicated in patients who develop symptoms and/or structural progression, particularly before the age of 35 years. Antiarrhythmic drugs are indicated for preventing recurrence of episodes of sustained ventricular tachycardia. In an

attempt to control Naxos disease, systematic genetic screening of the populations at risk has been initiated and is starting to identify the heterozygous carriers of the plakoglobin gene mutation.

3. Focal type

The focal type is subclassified into focal PPK, focal palmoplantar and gingival keratosis, focal keratoderma with oral leukokeratosis, pachyonychia congenita type 1 (Jadassohn–Lawandowsky type) and type 2 (Jackson–Lawler type), and focal PPK associated with esophageal carcinoma. Focal palmoplantar and gingival keratosis is characterized clinically by focal PPK with leukoplakic appearance on the labial surface of the attached gingival lesion, and histologically by focal epidermolytic PPK [16].

4. Striate type

4.1. Striate PPK (Brunauer-Fohs-Siemens syndrome)

Striate PPK (Brunauer-Fohs-Siemens syndrome) presents with linear hyperkeratosis on the palms and fingers and focal plaques on the plantar aspects of the feet. Onset occurs in infancy or the first few years of life. Striate PPK, woolly hair, and left ventricular dilated cardiomyopathy has been described in both autosomal dominant and autosomal recessive forms, but only the recessive forms have a clear association with dilated cardiomyopathy.

Histopathological features include hyperkeratosis, hypergranulosis, and acanthosis with no epidermolysis. Electron microscopic examination shows diminished desmosomes, clumped keratin filaments, and enlarged keratohyalin granules. The syndrome has been linked to mutations in desmoglein 1, desmoplakin, and keratin 1. Treatment may include keratolytics, oral retinoids, and surgical debridement. Striate PPK is known to be caused by heterozygous mutations in either the desmoglein 1 (type I striate PPK), desmoplakin (type II striate PPK) or keratin 1 (type III striate PPK) gene [17-20].

5. Punctate type

5.1. Buschke-Fischer syndrome

Buschke-Fischer syndrome is an autosomal dominant disorder characterized by multiple punctate keratoses over the entire palmoplantar surfaces [21]. Punctate PPK presents as asymptomatic, tiny, hyperkeratotic punctate papules on the palmoplantar surface. Many tiny "raindrop" keratoses involve the palmoplantar surface; skin lesions may involve the whole palmoplantar surface, or may be more restricted in their distribution. The prevalence is 1.17 cases per 100,000 population. The age of onset ranges between 12 and 30 years.

This condition is usually manifested bilaterally as asymptomatic, tiny, hyperkeratotic punctate papules/plaque on the palmoplantar surface. The exact etiology of this disorder is not known, but a dual influence of genetic and environmental factors may trigger the disease. Nail abnormalities in the form of longitudinal ridging, onychorrhexis,

onychoschizia, trachyonychia, and notching can be seen. Clinically, asymptomatic, tiny, hyperkeratotic papules are present on the palmoplantar surface. Lesions are uncommon in childhood and usually manifest after age 20 years. This condition is not associated with hyperhidrosis. Patients commonly report pruritus. Most individuals lack associated features; however, spastic paralysis, ankylosing spondylitis, and facial sebaceous hyperplasia have been reported. An association with gastrointestinal and pulmonary malignancy is possible.

Histological findings include substantial compact hyperkeratosis over a distinct area of epidermis, hypergranulosis, the presence of a cornoid lamella, and the absence of epidermal dyskeratosis or hydropic change, which help differentiate this condition from porokeratosis. Two punctate PPK loci have been found to map to 15q22-15q24 and to 8q24.13-8q24.21 [22, 23]. Treatment includes keratolytics, topical salicylic acid, mechanical debridement, excision, and topical and systemic retinoids.

6. Remarks

Hereditary PPK constitutes a heterogeneous group of disorders characterized by thickening of the palms and the soles of individuals who are affected. The diagnosis and classification are difficult due to inter-individual and intra-individual variations and differences in nomenclature. Dermatologists must be alert during the evaluation of these findings to ensure proper diagnosis, and must perform complete dermatological examination including nails, hair, and mucosa. In addition, future studies should include either a whole genome mapping plan or focus directly on candidate genes, such as SLURP1 gene for differential diagnosis between Mal de Meleda and Nagashima-type PPK. More reports and concise clinical observations with genetic approach may reveal the pathomechanism underlying PPK.

Author details

Tamihiro Kawakami

Department of Dermatology, St. Marianna University School of Medicine, Japan

7. References

- [1] Luckner GP, Van de Kerkhof PC, Steijlen PM. The hereditary palmoplantar keratoses: an updated review and classification. *British Journal of Dermatology* 1994;131(1):1-14.
- [2] Hamm H, Happle R, Butterfass T, Traupe H. Epidermolytic palmoplantar keratoderma of Vörner: is it the most frequent type of hereditary palmoplantar keratoderma? *Dermatologica* 1988;177(3):138-145.
- [3] Kabashima K, Sakabe J, Yamada Y, Tokura Y. 'Nagashima-type' keratosis as a novel entity in the palmoplantar keratoderma category. *Archives of Dermatology* 2008;144(3):375-379.

- [4] Castro PJS, Fernandez CN, Subirana PQ, Ortiz MP. Vohwinkel Syndrome secondary to missense mutation D66H in GJB2 gene (connexin 26) can include epileptic manifestations. *Seizure* 2010;19(2):129-131.
- [5] Ramer JC, Vasily DB, Ladda RL. Familial leukonychia, knuckle pads, hearing loss, and palmoplantar hyperkeratosis: An additional family with Bart-Pumphrey syndrome. *Journal of Medical Genetics* 1994;31(1):68-71.
- [6] Ishida-Yamamoto A, McGrath JA, Lam H, Iizuka H, Friedman RA, Christiano AM. The molecular pathology of progressive symmetric erythrokeratoderma: a frameshift mutation in the loricrin gene and perturbations in the cornified cell envelope. *American Journal of Human Genetics* 1997;61(3):581-589.
- [7] Ishida-Yamamoto A. Loricrin keratoderma: a novel disease entity characterized by nuclear accumulation of mutant loricrin. *Journal of Dermatological Science* 2003;31(1):3-8.
- [8] Lamartine J, Munhoz Essenfelder G, Kibar Z, Lanneluc I, Callouet E, Laoudj D, Lemaître G, Hand C, Hayflick SJ, Zonana J, Antonarakis S, Radhakrishna U, Kelsell DP, Christianson AL, Pitaval A, Der Kaloustian V, Fraser C, Blanchet-Bardon C, Rouleau GA, Waksman G. Mutations in GJB6 cause hidrotic ectodermal dysplasia. *Nature Genetics* 2000;26(2):142-144.
- [9] Bergonse FN, Rabello SM, Barreto RL, Romiti R, Nico MM, Aoki V, Reis VM, Rivitti EA. Olmsted syndrome: The clinical spectrum of mutilating palmoplantar keratoderma. *Pediatric Dermatology* 2003;20(4):323-326.
- [10] Huriez C, Deminatti M, Agache P, Mennequier M. A gene dysplasia not previously known: frequently degenerative sclero-atrophying and keratodermic genodermatosis of the extremities. *Sem Hop journal* 1968;44(8):481-488.
- [11] Watanabe E, Takai T, Ichihashi M, Ueda M. A Non familial Japanese case of Huriez syndrome: p 53 expression in squamous cell carcinoma. *Dermatology* 2003;207(1):82-84.
- [12] Angel TA, Hsu S, Kornbleuth SI, Kornbleuth J, Kramer EM. Papillon-Lefèvre syndrome: A case report of four affected siblings. *Journal of the American Academy of Dermatology* 2002;46(2 Suppl):S8-S10.
- [13] Hart TC, Hart PS, Michalec MD, Zhang Y, Marazita ML, Cooper M, Yassin OM, Nusier M, Walker S. Localization of a gene for prepubertal periodontitis to chromosome 11q14 and identification of a cathepsin C gene mutation. *Journal of Medical Genetics* 2000;37(2):95-101.
- [14] Protonotarios N, Tsatsopoulou A, Patsourakos P, Alexopoulos D, Gezerlis P, Simitsis S, Scampardonis G. Cardiac abnormalities in familial palmoplantar keratosis. *British Heart Journal* 1986;56(4):321-326.
- [15] Protonotarios N, Tsatsopoulou A, Anastasakis A, Sevdalis E, McKoy G, Stratos K, Gatzoulis K, Tentolouris K, Spiliopoulou C, Panagiotakos D, McKenna W, Toutouzas P. Genotype-phenotype assessment in autosomal recessive arrhythmogenic right ventricular cardiomyopathy (Naxos disease) caused by a deletion in plakoglobin. *Journal of the American College of Cardiology* 2001;38(5):1477-1484.
- [16] Kolde G, Hennies HC, Bethke G, Reichart PA. Focal palmoplantar and gingival keratosis: a distinct palmoplantar ectodermal dysplasia with epidermolytic alternations

- but lack of mutations in known keratins. *Journal of the American Academy of Dermatology* 2005;52(3 Pt 1):403-409.
- [17] Armstrong DK, McKenna KE, Purkis PE, Green KJ, Eady RA, Leigh IM, Hughes AE. Haploinsufficiency of desmoplakin causes a striate subtype of palmoplantar keratoderma. *Human Molecular Genetics* 1988;8(1):143-148.
 - [18] Whittock NV, Ashton GH, Dopping-Hepenstal PJ, Gratian MJ, Keane FM, Eady RA, McGrath JA. Striate palmoplantar keratoderma resulting from desmoplakin haploinsufficiency. *Journal of Investigative Dermatology* 1999;113(6):940-946.
 - [19] Hunt DM, Rickman L, Whittock NV, Eady RA, Simrak D, Dopping-Hepenstal PJ, Stevens HP, Armstrong DK, Hennies HC, Küster W, Hughes AE, Arnemann J, Leigh IM, McGrath JA, Kelsell DP, Buxton RS. Spectrum of dominant mutations in the desmosomal cadherin desmoglein 1, causing the skin disease striate palmoplantar keratoderma. *European Journal of Human Genetics* 2001;9(3):197-203.
 - [20] Whittock NV, Smith FJ, Wan H, Mallipeddi R, Griffiths WA, Dopping-Hepenstal P, Ashton GH, Eady RA, McLean WH, McGrath JA. Frameshift mutation in the V2 domain of human keratin 1 results in striate palmoplantar keratoderma. *Journal of Investigative Dermatology* 2002;118(5):838-844.
 - [21] Oztas P, Alli N, Polat M, Dagdelen S, Ustün H, Artüz F, Erdemli E. Punctate palmoplantar keratoderma (Brauer-Buschke-Fischer syndrome). *American Journal of Clinical Dermatology* 2007;8(2):113-116.
 - [22] Martinez-Mir A, Zlotogorski A, Londono D, Gordon D, Grunn A, Uribe E, Horev L, Ruiz IM, Davalos NO, Alayan O, Liu J, Gilliam TC, Salas-Alanis JC, Christiano AM. Identification of a locus for type I punctate palmoplantar keratoderma on chromosome 15q22-q24. *Journal of Medical Genetics* 2003;40(12):872-878.
 - [23] Zhang XJ, Li M, Gao TW, He PP, Wei SC, Liu JB, Li CR, Cui Y, Yang S, Yuan WT, Li CY, Liu YF, Xu SJ, Huang W. Identification of a locus for punctate palmoplantar keratodermas at chromosome 8q24.13-8q24.21. *Journal of Investigative Dermatology* 2004;122(5):1121-1125.