

# We are IntechOpen, the world's leading publisher of Open Access books Built by scientists, for scientists

6,900

Open access books available

186,000

International authors and editors

200M

Downloads

Our authors are among the

154

Countries delivered to

TOP 1%

most cited scientists

12.2%

Contributors from top 500 universities



WEB OF SCIENCE™

Selection of our books indexed in the Book Citation Index  
in Web of Science™ Core Collection (BKCI)

Interested in publishing with us?  
Contact [book.department@intechopen.com](mailto:book.department@intechopen.com)

Numbers displayed above are based on latest data collected.  
For more information visit [www.intechopen.com](http://www.intechopen.com)



---

# Erythropoietic Protoporphyria

---

Akira Kawada, Shigeru Kawara and Hajime Nakano

Additional information is available at the end of the chapter

<http://dx.doi.org/10.5772/54132>

---

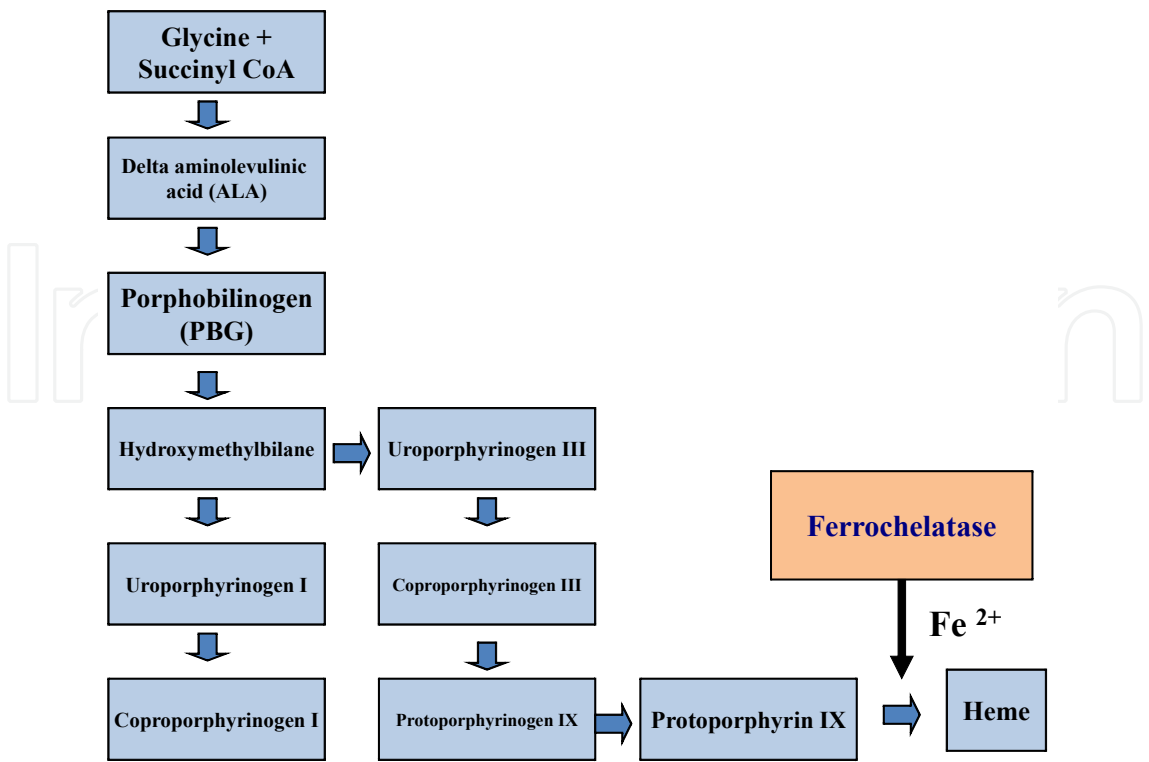
## 1. Introduction

The porphyrias are metabolism diseases caused by the deficiency of a specific enzyme in the heme biosynthetic pathway. Porphyrias have been classified into bone marrow and liver types on the basis of the predominant site of porphyrin production site. Recent classification of porphyrias shows acute porphyria and cutaneous porphyria according to the condition of signs (Table 1). Erythropoietic protoporphyria (EPP; OMIM 177000) is an autosomal dominant disease of porphyrin metabolism caused by decreased activity of the ferrochelatase (FECH; E.C. 4.99.1.1) that is the terminal enzyme in the heme biosynthetic pathway (Fig. 1). This type of porphyria was first described in 1953 by Kosenow and Treibs and this description was completed in 1961 by Magnus et al.<sup>1</sup> Decrease in FECH activity causes excess protoporphyrin induction, leading to photosensitivity of the skin and liver dysfunction. Photosensitivity starting from childhood makes quality of life low and liver dysfunction may lead to hepatic failure and death. In this session, we describe (1) clinical features of EPP, (2) genetic characteristics of EPP, and (3) mice models of EPP.

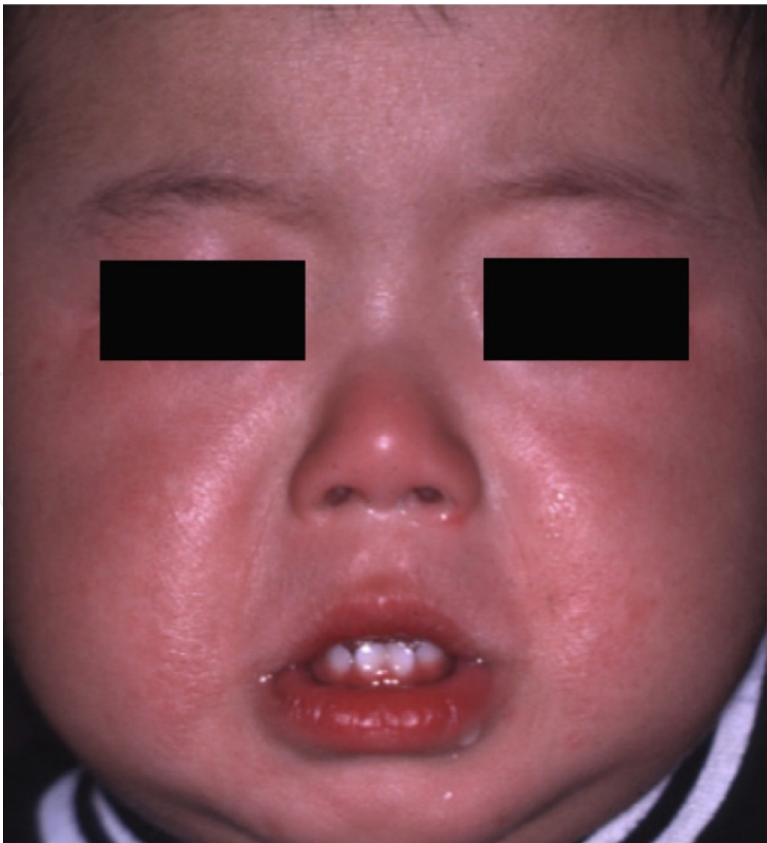## 2. The clinical features of EPP

### 2.1. Skin

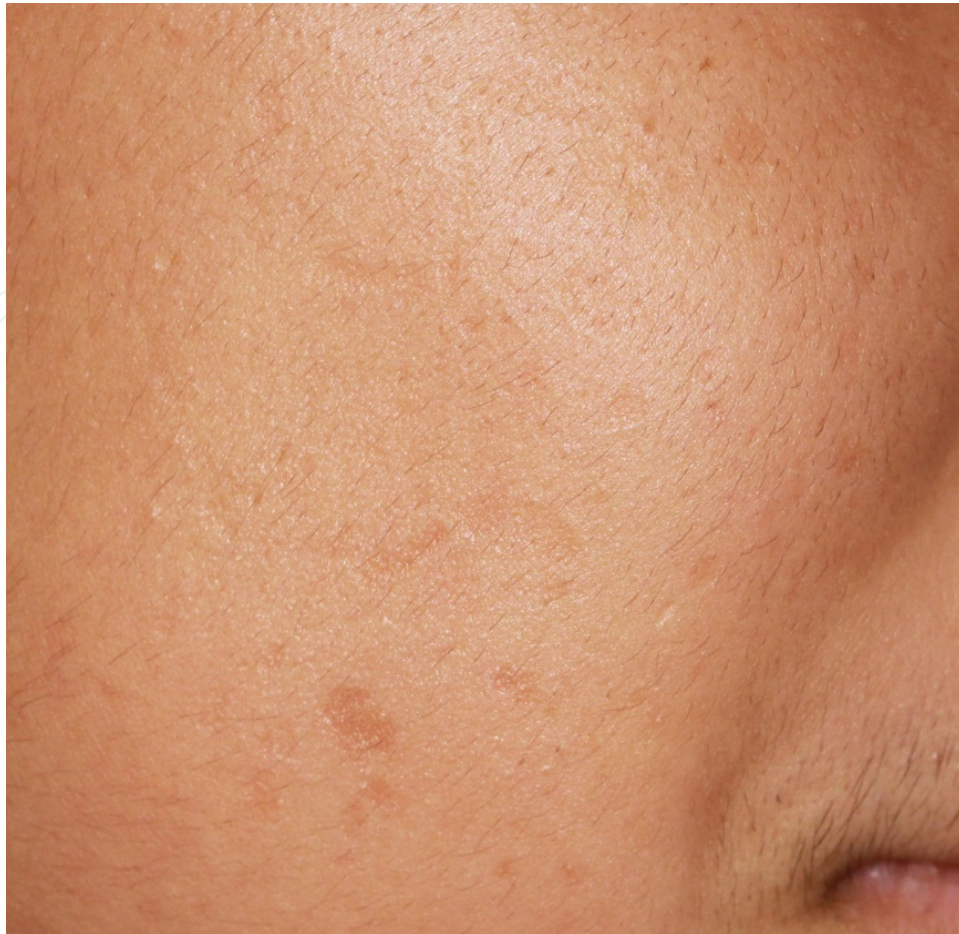Suspicion of EPP should be raised by the history of screaming or skin pain in a child on going outdoors.<sup>2</sup> However, it is very difficult to suspect EPP if clinical manifestation are minimum. The characteristics of photosensitivity in EPP are first a burning, stinging sensation appearing immediately at sun exposure followed by erythema, edema and purpura.<sup>1</sup> We reported a 1-year-old male infant with EPP who showed only erythema after sun exposure (Fig. 2).<sup>3</sup> Infant patients are unable to complain the abnormal sensations and pain. Cutaneous signs are characterized with erythema, swelling, papules, vesicles, small blood blisters, crusts, and scars. Scar, the most distinct skin lesion, is small, polygonal or linear, depressed or slightly elevated (Figs. 3 and 4). With the progression of the disease and



**Figure 1.** Heme biosynthetic pathway.



**Figure 2.** Clinical picture of a 1-year-old male baby with erythropoietic protoporphyria. Redness and swelling were seen on the face.

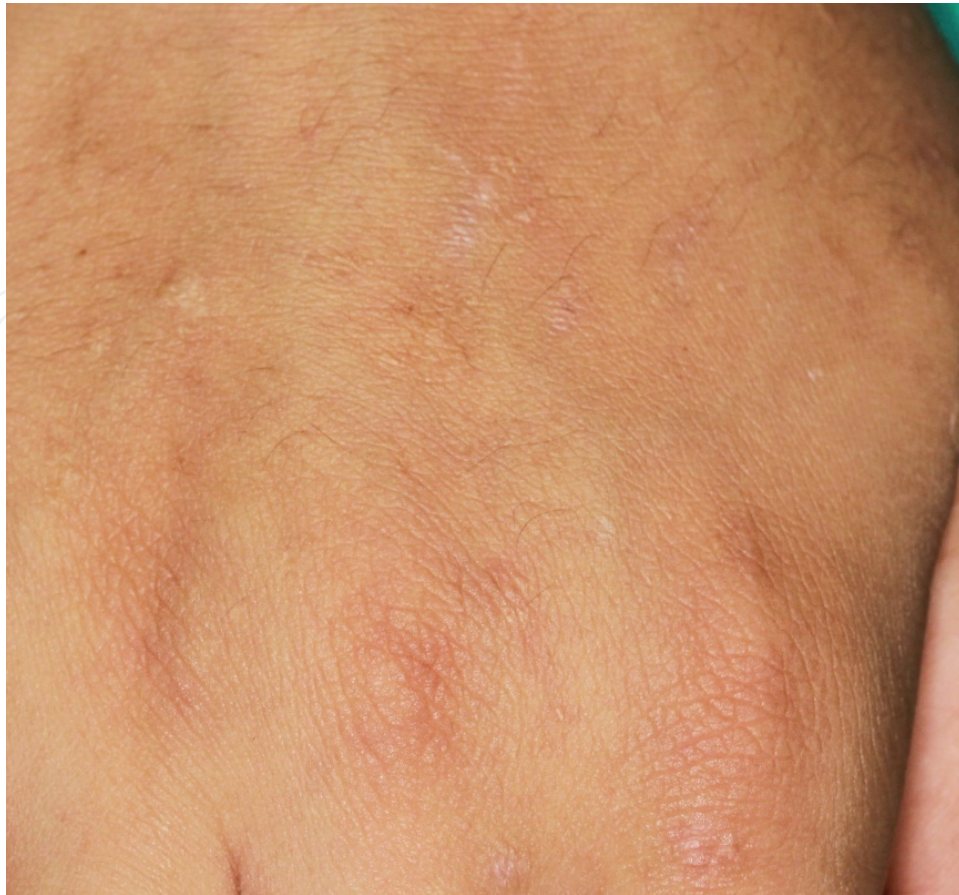

**Figure 3.** Clinical picture of a 14-year-old boy with erythropoietic protoporphyria. Depressed scars were seen on the face.

if sun exposure is not avoided, chronic lesions develop progressively with skin thickening (waxy lichenification on the dorsa of the hands) and scarring (pseudorhagades formation in the lips).<sup>1</sup>

Minder performed a systematic review of treatment options for dermal photosensitivity in EPP.<sup>4</sup> Sixteen of 25 relevant studies dealt with  $\beta$ -carotene. However, the results from  $\beta$ -carotene were strongly contradictory and efficacy was inversely correlated with study quality.<sup>4</sup> Afamelanotide, an  $\alpha$ -melanocyte-stimulating hormone analogue, was reported to be effective for EPP.<sup>5</sup> Afamelanotide, making melanin density of the skin increase, was effective for photosensitivity from artificial light and sunlight in 5 EPP patients.<sup>5</sup> Moreover, Petersen reported that oral treatment with a high daily dosage of zinc sulphate during the spring and summer reduced light sensitivity and pain in 71% of 14 EPP patients.<sup>6</sup> They speculated that zinc treatment in EPP patients may have provided antioxidant protection of cellular membranes against the deleterious photodynamic effects of protoporphyrin IX (PPIX) accumulation.<sup>6</sup> Photoprotection against visible light that absorbs PPIX is still a mainstream in the care of EPP patients, although these novel approaches were reported. However, some reports raised awareness about vitamin D deficiency due to sun avoidance in EPP. Spelt reported that 46% of 48 Dutch EPP patients showed decreased level of serum





**Figure 4.** Clinical picture of a 14-year-old boy with erythropoietic protoporphyria. Whitish swelling scars were seen on the back of the hand.

25-hydroxyvitamin D.<sup>7</sup> Vitamin D deficiency was high in male patients and correlated with the severity of EPP.<sup>7</sup> Holme also reported that 17% was deficient and 63% was insufficient in serum 25-hydroxyvitamin D levels of 201 United Kingdom (UK) patients with EPP.<sup>8</sup> Then, we should care for vitamin D deficiency in EPP patients performing strict photoprotection.

## 2.2. Liver

Mild abnormalities of liver function may be detected in about 10% of patients of EPP and liver failure affects about 5-20%.<sup>2,9</sup> Excess PP with any origin is excreted by the liver into bile and enters an enterohepatic circulation.<sup>10</sup> Excess PP becomes insoluble in bile and exerts cholestatic effects, structural changes from mild inflammation to fibrosis and cirrhosis.<sup>10</sup> Liver diseases include cholelithiasis, gallstones, biochemical abnormalities (aspartate amino transferase (AST), alanine amino transferase (ALT), gamma-glutamyl transpeptidase (gamma-GTP), alkaline phosphatase (ALP)), cirrhosis, and terminal liver failure. PP deposition in hepatocytes is invariable, whereas histological evidence of damage is less common; electron microscopy shows ultrastructural damage in most patients with EPP.<sup>10</sup>

Liver transplantation for liver failure in EPP patients started in 1980. Dowman investigated 5 UK cases receiving liver transplant for EPP-related liver diseases.<sup>11</sup> Two patients died at 44

and 95 months from causes unrelated to liver disease, while 3 patients were alive at 22.4 years, 61 months and 55 months after liver plant.<sup>11</sup> In spite of a good long-term survival, a high rate of postoperative biliary stricturing requiring multiple biliary interventions was seen.<sup>11</sup> Wahlin also investigated that 35 liver transplants for protoporphyric liver disease in 31 European patients between 1983 and 2008.<sup>12</sup> The overall rate of disease recurrence in the graft was high (69%), although they showed good survival rates, 77% at 1 year and 66% at 5 and 10 years.<sup>12</sup>

As liver transplant does not correct the constitutional deficiency of FECH, there is a risk of recurrence of liver disease even after liver transplant due to continuing overproduction of protoporphyrin.<sup>9</sup> Then, bone marrow transplantation may be considered in liver allograft recipients in the future.

### 2.3. Biochemistry and blood test

Increase of PP in the blood and stool is the most specific in EPP. However, urinary porphyrins (uroporphyrin, coproporphyrin, porphobilinogen,  $\delta$ -aminolevulinic acid) remain at normal levels. Many patients with EPP have an apparent mild anemia with a microcytic hypochromic blood film.<sup>2</sup> However, administration of iron is not recommended since iron sometimes exacerbate the porphyria.

## 3. Genetic characteristics of EPP

EPP is a disease caused by decreased activity of the ferrochelatase (FECH; E.C. 4.99.1.1) that is the final enzyme in the heme biosynthetic pathway. The *FECH* gene contains 11 exons and spans about 45 kb of genomic DNA on chromosome 18q21.3, and its cDNA sequence encodes for 423 amino acids (GenBank no. D00726). The mode of inheritance is primarily autosomal dominant, and the clinical penetrance is low. In the dominant type of EPP, different degrees of enzyme deficiency are seen between patients and asymptomatic gene carriers, *i.e.*, symptomatic patients usually have less than 50% of the normal activity, whereas the asymptomatic ones show approximately 50% of the normal activity.<sup>13</sup>

Gouya reported that (1) coinheritance of a *FECH* gene defect and a wild-type low-expressed allele is generally involved in the clinical expression of EPP; (2) the low-expressed allelic variant was associated with a partial 5' haplotype [-251G IVS1-23T IVS2 $\mu$ satA9] that may be ancestral and was present in an estimated 10% of a control group of Caucasian origin; and (3) haplotyping allows the absolute risk of developing the disease to be predicted for those inheriting *FECH* EPP mutations.<sup>13</sup> Mutations of *FECH* gene in EPP are highly heterogeneous and specific for each family members. Minder studied the association between "null allele" mutation and liver complication in 1112 EPP patients.<sup>14</sup> All 18 EPP patients who had severe liver complication showed a "null allele" mutation, whereas 20 patients with a missense mutation did not have liver complication till the time of study.<sup>14</sup> This study indicates that a significant genotype-phenotype correlation between "null allele" mutation and liver disorder in EPP.

Genetic variants in the *FECH* gene include more than 175 mutations and 538 single-nucleotide polymorphisms (SNPs).<sup>15</sup> The functionality of these SNPs may reduce the level of transcription of the *FECH* gene contributing to the triggering of EPP.<sup>15</sup> A common low expression allele, IVS3-48T>C, is seen in 10% of European Caucasians. Most EPP patients (~90%) have a *FECH* loss-of-function mutation *in cis* and the common low expression allele *in trans*, resulting in 15-25% of normal *FECH* activity.<sup>16</sup> As described above, mutations of *FECH* gene in EPP are highly family-specific. There have been many variations of *FECH* gene mutations reported in various countries.

Nakano firstly identified two novel mutations in two Japanese families using direct sequence analysis of the entire coding region of the *FECH* gene.<sup>17</sup> The proband in the first family was heterozygous for a 3-bp deletion from nucleotide positions 853 to 855 in exon 8, designated delCAA<sup>853</sup>.<sup>17</sup> Pedigree analysis of the other family members showed that the mother and two sisters, all asymptomatic, were heterozygous for this mutation.<sup>17</sup> Restriction fragment polymorphism analysis indicated that the proband was homozygous for the IVS3-48C polymorphism, while other family members, asymptomatic carriers, had a wild-type T at position IVS3-48 *in trans* to the mutated allele.<sup>17</sup> They concluded that the IVS3-48C polymorphism in one allele and a deleterious mutation (delCAA<sup>853</sup>) in the other allele caused a phenotype of EPP. In the second family, all three members having symptoms of EPP showed the C<sup>683</sup>→T mutation in combination with the trans IVS3-48C polymorphism.<sup>17</sup> These results from the analysis of two Japanese families indicated that the intronic IVS3-48C polymorphism in the non-mutated allele is a distinct determinant of the EPP phenotype. Their further investigation of the frequency of IVS-48C polymorphism in 104 Japanese controls revealed that the genotypic frequency of IVS3-48C/C was 0.192, that was over 10 times those of European countries (0-0.017).<sup>17</sup> These differences may affect the prevalence and penetrance of EPP in Japan.

In UK, Whatley identified large deletions of the *FECH* gene in 19 (58%) of 33 unrelated UK patients with EPP using gene dosage analysis by quantitative PCR; (1) six deletions (c.1-7887-IVS1+ 2425insTTCA; c.1-9629-IVS1+ 2437; IVS2-1987-IVS4+352del; c.768-IVS7+ 244del; IVS7+2784-IVS9+108del; IVS6+2350-TGA+95del), (2) five breakpoints in intronic repeat sequences (AluSc, AluSq, AluSx, L1MC4), and (3) large insertion-deletion (Del Ex3-4).<sup>18</sup> Berroeta reported a UK case with late onset of EPP and identified a mutation (1001C→T; P334L).<sup>19</sup>

In Canada, Pierro identified a 10,376 bp deletion (c.1-7887\_67+2422del) including a portion of the upstream intergenic region, the promoter, the exon 1 and a portion of intron 1 in a Canadian EPP patient of Italian origin.<sup>20</sup> Li also reported that a Canadian EPP patient had a novel large deletion [c.1-9628\_67+2871del12566 bp] and three polymorphisms [c.1-251A>G, c.68-23C>T and c.315-48T>C] *in trans* to the deletion in *FECH* gene.<sup>21</sup>

In China, Zhou identified a novel IVS1+1G→C mutation of the *FECH* gene in a Chinese EPP family.<sup>22</sup> Fong identified a recurrent splice site mutation, c.67+1G>C, and a novel nonsense mutation, p.Y191X, in 2 unrelated Chinese families.<sup>23</sup> Their investigation revealed that the allele frequency of IVS3-48C in Hong Kong population (28%) was lower than that of

Japanese population but higher than that of European populations.<sup>23</sup> Ma identified a novel splicing *FECH* mutation, IVS3+1G→A, and IVS3-48C polymorphism in a Chinese EPP family.<sup>24</sup>

In Argentina, Parera detected three novel and two previously described mutations in five Argentinean EPP families; (1) a deletion (451delT) producing a stop codon located 18 codons downstream from the mutation, (2) IVS1-2A>G leading to exon 2 skipping, (3) IVS4-2A>G, which causes the loss of the first 48 bp of exon 5, (4) C343T, and (5) 400delA.<sup>25</sup> Colombo's study of 19 Argentina EPP patients identified three novel (p.S222N; p.R298X and p.R367X) and seven already known (g.12490\_18067del; p.R115X; p.I186T; c.580\_584delTACAG; c.598+1G>T; p.Y209X and p.W310X) and indicated the possibility of c.315-48C variant in *trans* to the mutated allele as a sufficient trigger of EPP.<sup>15</sup>

In Spain, Herrero reported that three novel mutations (IVS4+1delG, 347-351delC, and 130\_147dupl 18) and IVS3-48C low-expression allele in ten of 11 EPP patients.<sup>26</sup> They also estimated the frequency of the IVS3-48C allele among 180 nonporphyric Spanish individuals as 5.2%.<sup>26</sup> In South Africa, Parker identified ten sequence variations; IVS3-48T / C polymorphism, five further polymorphisms, a 5-bp deletion in exon 7 (757\_761delAGAAG), two previously described splice-site mutations (IVS3+2T>G and IVS7+1G>A), and a novel 7-bp deletion in exon 4 (356\_362delTTCAAGA).<sup>27</sup> In Portugal, Morais identified heterozygosity for a novel mutation (c.1052delA) in *FECH* gene of two children, and heterozygosity for the hypomorphic allele IVS3-48T>C in two children and asymptomatic mother.<sup>28</sup>

Recently, an association of EPP and palmar keratoderma has been reported. Méndez detected a homozygous inheritance of a novel missense mutation Q285R, a homozygous A-to-G transition, c.854A>G, in the *FECH* gene in a Caucasian family of EPP associated with palmar keratoderma.<sup>29</sup> Minder also reported a case of an association of EPP and palmar keratoderma who had a novel homoallelic missense mutation (p.Ser318Tyr) in the *FECH* gene.<sup>30</sup> Their Palestinian (Jordanian) parents were heterozygous for the S318Y mutation.<sup>30</sup>

#### 4. Mice models of EPP

Mice models of EPP are useful to investigate the effects of *FECH* on iron metabolism in EPP. Lyoumi investigated hematologic and iron status in *FECH*-deficient *Fechm1Pas* mutant mice.<sup>31</sup> Their mice had microcytic hypochromic anemia without ringed sideroblasts, little or no hemolysis, and no erythroid hyperplasia, whereas the mice showed no tissue iron deficiency but did a redistribution of iron stores from peripheral tissues to the spleen, with a 2- to 3-fold increase in transferrin expression of mRNA and protein levels.<sup>31</sup> Using *Fechm1Pas* mutant mice with the BALB/c and C57BL/6 backgrounds, Lyoumi demonstrated that BALB/c backgrounded *Fechm1Pas* mice had more severe cholestasis, fibrosis with portoportal bridging, bile acid regurgitation, sclerosing cholangitis, and hepatolithiasis as compared with the mice with C57BL/6 background.<sup>32</sup>



## 5. Conclusion

EPP is an autosomal dominant disease of porphyrin metabolism that is characterized with photosensitivity and liver disease. We have reviewed recent advances of clinical features of EPP, genetic characteristics of EPP, and mice models of EPP. Further studies of genetic analysis and FECH-deficient mice will provide us the new strategy for the treatment of EPP.

## Author details

Akira Kawada

*Department of Dermatology, Kinki University Faculty of Medicine, Osaka-Sayama, Osaka, Japan*

Shigeru Kawara

*Department of Dermatology, Kanazawa Red Cross Hospital, Kanazawa, Japan*

Hajime Nakano

*Department of Dermatology, Hirosaki University School of Medicine, Hirosaki, Aomori, Japan*

## 6. References

- [1] Lecha M. Erythropoietic protoporphyria. *Photodermatol Photomed Photoimmunol* 2003; 19: 142-6.
- [2] Murphy GM. Diagnosis and management of the erythropoietic protoporphyria. *Dermatol Ther* 2003; 16: 57-64.
- [3] Kawada A, Gomi H, Shiraishi H, Hatanaka K, Matsuo I, Inafuku K, Takamori K, Tezuka T. An infantile case of erythropoietic protoporphyria with a decreased mRNA level of ferrochelatase. *Hifu* 2001; 43: 111-5.
- [4] Minder EI, Schneider-Yin X, Steurer J, Bachmann LM. A systematic review of treatment options for dermal photosensitivity in erythropoietic protoporphyria. *Cell Mol Biol* 2009; 55: 84-97.
- [5] Harms J, Lautenschlager S, Minder CE, Minder EI. An  $\alpha$ -melanocyte-stimulating hormone analogue in erythropoietic protoporphyria. *N Eng J Med* 2009; 360: 306-7.
- [6] Petersen AB, Philipsen PA, Wulf HC. Zinc sulphate: a new concept of treatment of erythropoietic protoporphyria. *Br J Dermatol* 2012; 166: 1129-31.
- [7] Spelt JMC, Rooij FWM, Wilson JHP, Zandbergen AAM. Vitamin D deficiency in patients with erythropoietic protoporphyria. *J Inherit Metab Dis* 2009 doi: 10.1007/s10545-008-1037-0.
- [8] Holme SA, Anstey AV, Badminton MN, Elder GH. Serum 25-hydroxyvitamin D in erythropoietic protoporphyria. *Br J Dermatol* 2008; 159: 211-3.
- [9] Casanova-González MJ, Trapero-Marugán M, Jones EA, Moreno-Otero R. Liver disease and erythropoietic protoporphyria: a concise review. *World J Gastroenterol*. 2010; 16: 4526-31.
- [10] Anstey AV, Hift RJ. Liver disease in erythropoietic protoporphyria: insights and implications for management. *Gut* 2007; 56: 1009-18.

- [11] Dowman JK, Gunson BK, Mirza DF, Badminton MN, Newsome PN. UK experience of liver transplantation for erythropoietic protoporphyria. *J Inherit Metab Dis* 2011; 34: 539-45.
- [12] Wahlin S, Stal P, Adam R, Karam V, Porte R, Seehofer D, Gunson BK, Hillingsø J, Klempnauer JL, Schmidt J, Alexander G, O'Grady J, Clavien PA, Salizzoni M, Paul A, Rolles K, Ericzon BG, Harper P. Liver transplantation for erythropoietic protoporphyria in Europe. *Liver Transpl* 2011; 17: 1021-6.
- [13] Gouya L, Puy H, Lamoril J, Silva VD, Grandchamp B, Nordmann Y, Deybach J-C. Inheritance in erythropoietic protoporphyria: a common wild-type ferrochelatase allelic variant with low expression accounts for clinical manifestation. *Blood* 1999; 93: 2105-10.
- [14] Minder EI, Gouya L, Schneider-Yin X, Deybach JC. A genotype-phenotype correlation between null-allele mutations in the ferrochelatase gene and liver complication in patients with erythropoietic protoporphyria. *Cell Mol Biol* 2002; 48: 91-6.
- [15] Colombo FP, Rossetti MV, Méndez M, Martínez JE, Enríquez de Salamanca R, Batlle AMC, Parera VE. Functional associations of genetic variants involved in the clinical manifestation of erythropoietic protoporphyria in the argentinean population. *J Eur Acad Dermatol Venereol* 2012 doi: 10.1111/j.1468-3083.2012.04566.x.
- [16] Balwani M, Desnick RJ. The porphyrias: advances in diagnosis and treatment. *Blood* 2012 doi:10.1182/blood-2012-05-423186
- [17] Nakano H, Nakano A, Toyomaki Y, Ohashi S, Harada K, Moritsugu R, Takeda H, Kawada A, Mitsuhashi Y, Hanada K. Novel Ferrochelatase Mutations in Japanese Patients with erythropoietic protoporphyria: high frequency of the splice site modulator IVS3-48C polymorphism in the Japanese population. *J Invest Dermatol* 2006; 126: 2717-9.
- [18] Whatley SD, Mason NG, Holme SA, Anstey AV, Elder GH, Badminton MN. Gene dosage analysis identifies large deletions of the *FECH* gene in 10% of families with erythropoietic protoporphyria. *J Invest Dermatol* 2007; 127: 2790-4.
- [19] Berroeta L, Man I, Goudie DR, Whatley SD, Elder GH, Ibbotson SH. Late presentation of erythropoietic protoporphyria: case report and genetic analysis of family members. *Br J Dermatol* 2007; 157: 1030-1.
- [20] Di Pierro E, Brancaleoni V, Besana V, Ausenda S, Drury S, Cappellini MD. A 10376 bp deletion of *FECH* gene responsible for erythropoietic protoporphyria. *Blood Cells Mol Dis* 2008; 40: 233-6.
- [21] Li C, Di Pierro E, Brancaleoni V, Cappellini MD, Steensma DP. A novel large deletion and three polymorphism in the *FECH* gene associated with erythropoietic protoporphyria. *Clin Chem lab Med* 2009; 47: 44-6.
- [22] Zhou SN, Xiao SX, Peng ZH, Li BX, Li XL, Li Y, Luo SJ. A novel mutation of the *FECH* gene in a Chinese family with erythropoietic protoporphyria. *J Dermatol Sci* 2007; 48: 145-7.
- [23] Lau KC, Lam CW. DNA-based diagnosis of erythropoietic protoporphyria in two families and the frequency of a low-expression *FECH* allele in a Chinese population. *Clin Chim Acta* 2009; 400: 132-4.

- [24] Ma J, Xiao S, An J, Wang X, Xu Q, Dong Y, Feng Y, Wang J. A novel splicing mutation and haplotype analysis of the *FECH* gene in a Chinese family with erythropoietic protoporphyria. *J Eur Acad Dermatol Venereol* 2010; 24: 726-9.
- [25] Parera VE, Koole RH, Minderman G, Edixhoven A, Rossetti MV, Batlle A, De Rooij FWM. Novel null-allele mutations and genotype-phenotype correlation in Argentinean patients with erythropoietic protoporphyria. *Mol Med* 2009; 15: 425-31.
- [26] Herrero C, To-Figueras J, Badenas C, Méndez M, Serrano P, Enríquez-Salamanca R, Lecha M. Clinical, biochemical, and genetic study of 11 patients with erythropoietic protoporphyria including one with homozygous disease. *Arch Dermatol* 2007; 143: 1125-9.
- [27] Parker M, Corrigall AV, Hift RJ, Meissner PN. Molecular characterization of erythropoietic protoporphyria in South Africa. *Br J Dermatol* 2008; 159: 182-91.
- [28] Morais P, Mota A, Baudrier T, Trigo F, Oliveira JP, Cerqueira R, Palmeiro A, Tavares P, Azevedo F. Erythropoietic protoporphyria: a family study and report of a novel mutation in the *FECH* gene. *Eur J Dermatol* 2011; 21: 479-83.
- [29] Méndez M, Poblete-Gutiérrez P, Morán-Jiménez MJ, Rodríguez ME, Garrido-Astray MC, Fontanellas A, Frank J, de Salamanca RE. A homozygous mutation in the ferrochelatase gene underlies erythropoietic protoporphyria associated with palmar keratoderma. *Br J Dermatol* 2009; 160: 1330-4.
- [30] Minder EI, Schneider-Yin X, Mamet R, Horev L, Neuenschwander S, Baumer A, Austerlitz F, Puy H, Schoenfeld N. A homoallelic *FECH* mutation in a patient with both erythropoietic protoporphyria and palmar keratoderma. *J Eur Acad Dermatol Venereol* 2010; 24: 1349-53.
- [31] Lyoumi S, Abitbol M, Andrieu V, Henin D, Robert E, Schmitt C, Gouya L, de Verneuil H, Deybach JC, Montagutelli X, Beaumont C, Puy H. Increased plasma transferrin, altered body iron distribution, and microcytic hypochromic anemia in ferrochelatase-deficient mice. *Blood* 2007; 109: 811-8.
- [32] Lyoumi S, Abitbol M, Rainteau D, Karim Z, Bernex F, Oustric V, Millot S, Letteron P, Heming N, Guilmot L, Montagutelli X, Berdeaux G, Gouya L, Poupon R, Deybach JC, Beaumont C, Puy H. Protoporphyrin retention in hepatocytes and Kupffer cells prevents sclerosing cholangitis in erythropoietic protoporphyria mouse model. *Gastroenterology* 2011; 141: 1509-19.