

We are IntechOpen, the world's leading publisher of Open Access books Built by scientists, for scientists

6,900

Open access books available

185,000

International authors and editors

200M

Downloads

Our authors are among the

154

Countries delivered to

TOP 1%

most cited scientists

12.2%

Contributors from top 500 universities



WEB OF SCIENCE™

Selection of our books indexed in the Book Citation Index
in Web of Science™ Core Collection (BKCI)

Interested in publishing with us?
Contact book.department@intechopen.com

Numbers displayed above are based on latest data collected.
For more information visit www.intechopen.com



Essential Functional Hepatic and Biliary Anatomy for the Surgeon

Ronald S. Chamberlain

Additional information is available at the end of the chapter

<http://dx.doi.org/10.5772/53849>

1. Introduction

That every surgeon will experience complications is a certainty. Indeed, it has been said that if one has no complications, one does not do enough surgery. Yet, major surgical complications are often avoidable and frequently the result of three tragic surgical errors. These errors are: 1) a failure to possess sufficient knowledge of normal anatomy and function, 2) a failure to recognize anatomic variants when they present, and 3) a failure to ask for help when uncertain or unsure. All but the last of these errors are remediable with study and effort. In regard to the last error, most surgeons learn humility through their failures and at the expense of their patients, while some never learn.

The importance of a precise knowledge of parenchymal structure, blood supply, lymphatic drainage, and variant anatomy on outcome is perhaps nowhere more apparent than in hepatobiliary surgery. Though the liver was historically an area where few brave men dared to tread, and even less returned a second time, recent advances in anesthetic technique and perioperative care now permit hepatic surgery to be performed with low morbidity and mortality in both academic and community hospitals. That said, surgeons are duly cautioned to inventory their own skills and knowledge before venturing forward into the right upper quadrant. This chapter will review functional biliary and hepatic anatomy necessary for the conduct of safe and successful hepatic operations.

2. The liver

2.1. Surface anatomy

The liver is situated primarily in the right upper quadrant, and usually benefits from complete protection by the lower ribs. Most of the liver substance resides on the right side, although it

is not uncommon for the left lateral segment to arch over the spleen. The superior surface of the liver is molded to, and abuts the undersurface of the diaphragm on both the right and left side. During normal inspiration, the liver may rise as high as the 4th or 5th intercostal space on the right.

The liver itself is completely invested with a peritoneal layer except on the posterior surface where it reflects onto the undersurface of the diaphragm to form the right and left triangular ligaments. The liver is attached to the diaphragm and anterior abdominal wall by three separate ligamentous attachments, namely the falciform, round, and right and left triangular ligaments. (Figure 1) The falciform ligament, which is situated on the anterior surface of the liver, arises from the anterior leaflets of the right and left triangular ligaments and terminates inferiorly where the ligamentum teres enters the umbilical fissure. The gallbladder is normally attached to the undersurface of the right lobe and directed towards the umbilical fissure. At the base of the gallbladder fossa, is the hilar transverse fissure through which the main portal structures to the right lobe course. Additional important landmarks on the posterior liver surface include a deep vertical groove in which the inferior vena cava is situated, and a large bare area (i.e. no peritoneal coating) that is normally in contact with the right hemidiaphragm and right adrenal gland. The left lateral segment of the liver arches over the caudate lobe that is situated to the left of the vena cava. The caudate lobe is demarcated on the left by a fissure containing the ligamentum venosum (a remnant of the umbilical vein). Additional left-sided important surface features include the gastrohepatic omentum that is located between the left lateral segment and the stomach. The gastrohepatic omentum may contain replaced or accessory hepatic arteries. Finally, there is usually a thick fibrous band that envelops the vena cava high on the right side and runs posteriorly towards the lumbar vertebrae. This band, which is sometimes referred to as the vena caval ligament, must be divided to allow proper visualization of the suprahepatic cava and right hepatic veins.

2.2. Parenchyma (the liver substance)

The liver is comprised of two main lobes, a large right lobe, and a smaller left lobe. Although the falciform ligament is often thought to divide the liver into a right and left lobe, the true “anatomic” or “surgical” right and left lobes of the liver are defined by the course of the middle hepatic vein that runs through the main scissura of the liver. Although various descriptions of the internal anatomy of the liver have been proffered over the last century, Couinaud’s (1957) segmental anatomy of the liver is the most useful for the surgeon.

Couinaud’s classification system divides the liver into four unique sectors based upon the course of the three major hepatic veins. Each sector receives its blood supply from a separate portal pedicle. Within the *main scissura* lies the middle hepatic vein that courses from the left side of the suprahepatic vena cava to the middle of the gallbladder fossa. Functionally, the main scissura divides the liver into separate right and left lobes which have independent portal inflow, and biliary architecture. (Figures 2 and 3) An artificial line that divides the liver into right and left hemilivers is known as Cantlie’s line. The right hepatic veins runs within the right segmental scissura and divides the right lobe into a right posterior and anterior sector,

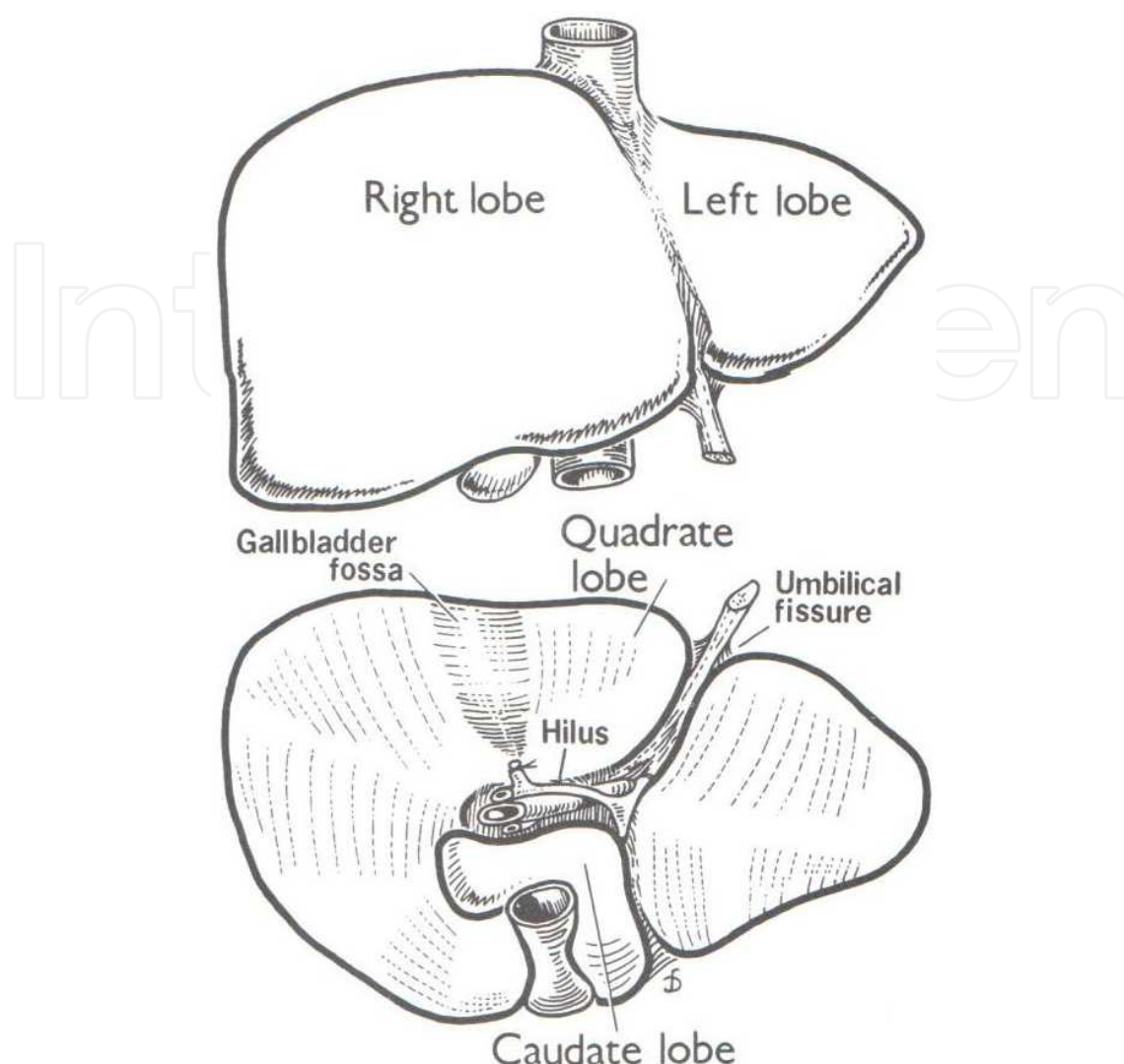


Figure 1. Surface anatomy of the liver. (A) Anterior surface, (B) Inferior surface of the liver. Reprinted with permission from Hahn and Blumgarty, Functional Hepatic and Radiologic Anatomy in Surgery of the Liver and Biliary Tract (3rd Edition), Blumgarty LH, Fong Y and WH Jarnigan (Eds.) Lippincott Williams, London, UK (2000).

while the left hepatic veins follows the path of the falciform ligament and divides the left lobe into a medial and lateral segment.

The right and left lobes of the liver are further divided into 8 segments based upon the distribution of the *portal scissurae*. At the hilus, the right portal vein pursues a very short course (1 – 1.5 cm) before entering the liver. Once entering the hepatic parenchyma, the portal vein divides into a right anterior sectoral branch that arches vertical in the frontal plane of the liver, and a posterior sectoral branch that follows a more posterolateral course. The right portal vein supplies the anterior (or anteriomedial) and posterior (or posterolateral) sectors of the right lobe. The branching pattern of these sectoral portal veins subdivides the right liver into 4 segments -- segments V (anterior and inferior) and VIII (anterior and superior) form the anterior sector, and segments VI (posterior and inferior) and VII (posterior and superior) form the posterior sector.

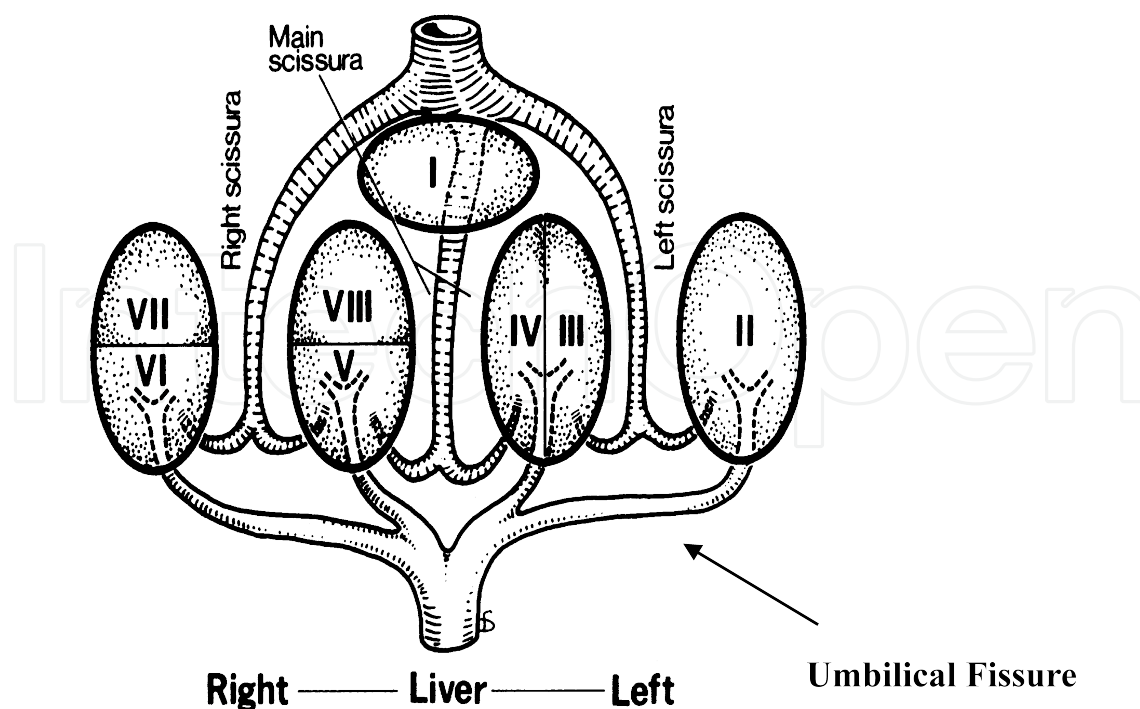


Figure 2. Segmental and sectoral anatomy of the liver. The liver is divided into three main scissura by the right, middle, and left hepatic vein branches. The middle hepatic courses through the main scissura (or Cantlie's line) and divides the liver into right and left lobes. The right hepatic vein divides the right liver into anterior (segments V and VIII) and posterior (segment VI and VII) sectors, while the left hepatic vein divides the left lobe into medial (segments IV A and B) and lateral segments (segments II and III). The intrahepatic branching of the right and left hepatic ducts, arteries and portal veins (shown) in the horizontal plane of the liver divides the liver into eight separate segments. The caudate lobe (segment I) is neither part of left lobe. Rather the caudate lobe receives venous and arterial branches from both the right and left side of the liver, and drains directly into the inferior vena cava.

In contrast to the right portal vein, the left portal vein has a long extrahepatic length (3 – 4 cm) coursing beneath the inferior portion of the quadrate lobe (segment 4B) enveloped in a peritoneal sheath (the hilar plate.) Upon reaching the umbilical fissure, the left portal vein runs anteriorly and superiorly within the liver substances, and gives off horizontal branches to the quadrate lobe medially (segments IV A (superior) and B (inferior)) and to the left lateral segment (segments III (inferior) and II (superior)) (Figure 3).

The caudate lobe (segment I) is neither part of the left nor right lobes, though it lies mostly on the left side (Figure 4). More precisely, it is the most dorsal portion of the liver situated behind the left lobe and embracing the retrohepatic vena cava from the hilum to the diaphragm. The portion of the caudate lobe that is within the right liver is usually quite small, and lies posterior to segment 4B. Figure 3 illustrates the location of the caudate lobe which lies between the left portal vein and vena cava on the far left, and the middle hepatic vein and vena cava within the right liver. The caudate lobe receives blood vessels and biliary tributaries from both the right and left hemilivers. The right side of the caudate lobe, and the caudate process, receives its blood supply from branches of the right or main portal vein, while the left side of the caudate receives a separate vessel from the left portal vein.

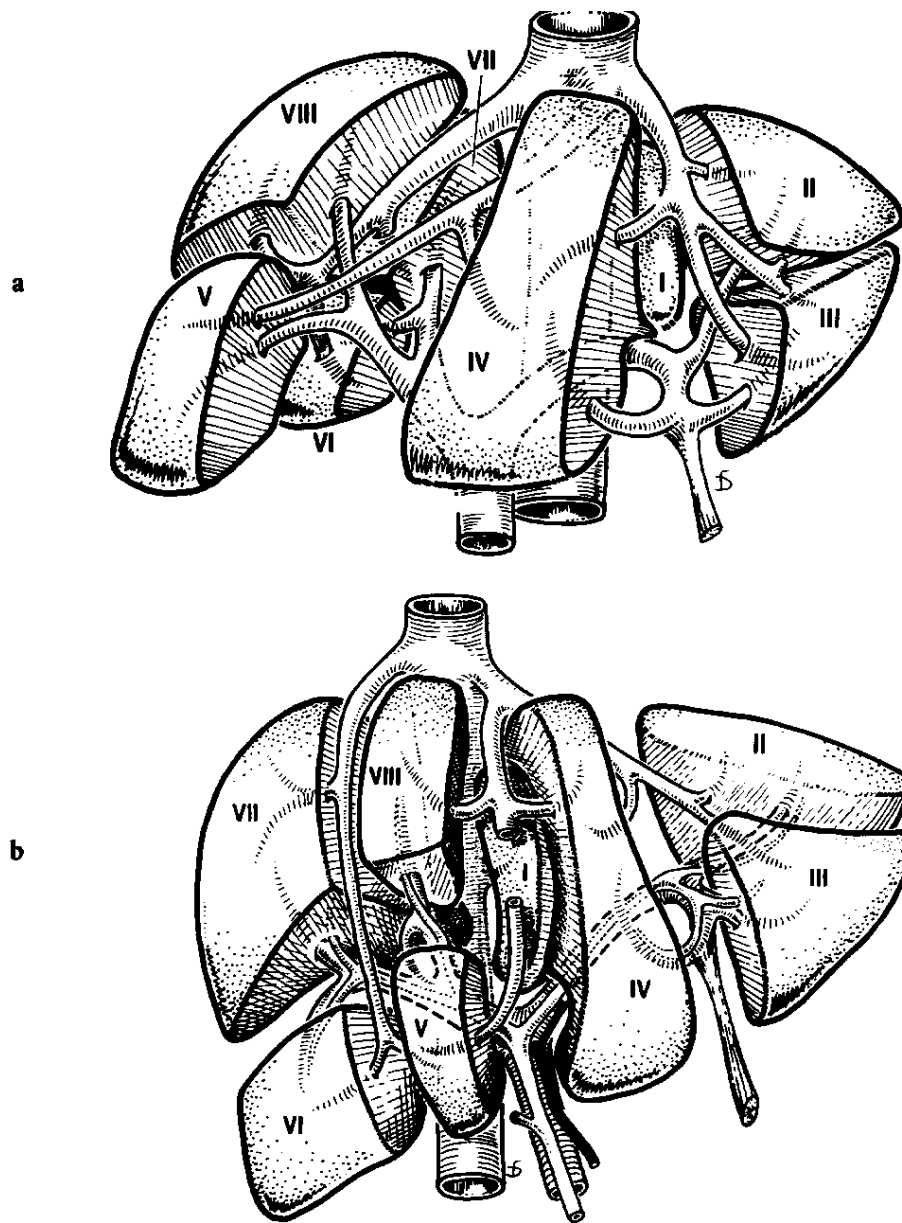


Figure 3. Couinaud's segmental anatomy of the liver. (a) *in vivo* appearance; (b) *ex vivo* appearance.

Aberrant segmental anatomy of the liver is uncommon. The presence of a diminutive left lobe is the most common anomaly reported, and is important only because it may serve as a limitation to the performance of extended right hepatectomies. Although reports of “accessory” hepatic lobes are not uncommon, these do not represent separate segments with independent intrahepatic vascular supply, but rather elongated tongues of normal liver tissue. Riedel's lobe is the most common of these “accessory” lobes, and is reality, an extended piece of liver tissue hanging inferiorly off segments 5 and 6.

3. Hepatic veins (Outflow)

The three major hepatic veins (the right, middle and left) comprise the main outflow tract for the liver, although additional veins (5 – 20) of varying size are always present as direct communications between the vena cava and the posterior surface of the right lobe. Uniquely, the caudate lobe (segment I) drains principally through direct communications with the retrohepatic cava.

The hepatic veins lie within the three major scissura of the liver dividing the parenchyma into the right anterior and posterior sectors, and the right and left lobes. (Fig 2 and 3) The right hepatic vein lies within the right scissura (or segmental fissure) and divides the right lobe into a posterior (segments VI and VII) and anterior (segments V and VIII) sector. The middle hepatic vein lies within the main hepatic scissura (or main lobar fissure) separating the right anterior sector (segments V and VIII) from the quadrate lobe (segment IV). Anatomically, the main scissura separates the liver into right and left lobes. The left hepatic vein lies within the left scissura (or the left segmental fissure) in line with or just to the right of the falciform ligament. The right hepatic vein drains directly into the suprahepatic cava, while the middle and left hepatic vein coalesce to form a short common trunk prior to entry. The umbilical vein represents an additional alternative site of venous efflux. It is located beneath the falciform ligament and eventually terminates in the left hepatic vein, or less commonly in the confluence of the middle and left hepatic veins.

4. Hepatic venous anomalies

Although the outline above should suffice as cursory knowledge of hepatic venous anatomy, it is far from exhaustive. For example, large accessory right hepatic veins are commonly found, and an appreciation of these structures on axial imaging can be important to operative planning. If a large accessory right hepatic vein is present, it may be possible to divide all three major hepatic veins in the performance of an extended left hepatectomy. Most importantly, the surgeon embarking on hepatic resection should have a thorough knowledge of the internal course of the hepatic veins, as the danger posed by hepatic venous bleeding cannot be overestimated.

5. Hepatic arteries (Inflow)

5.1. Extrahepatic arterial anatomy

“Normal” hepatic arterial anatomy is anything but normal. Indeed standard celiac arterial anatomy as described in most major anatomic treatise is found in only 60% of cases. An *accessory* hepatic artery refers to a vessel that supplies a segment of liver that also receives blood supply from a normal hepatic artery. An aberrant hepatic artery is called a *replaced*

hepatic artery as it represents the only blood supply to a specific hepatic segment. Precise knowledge of normal hepatic arterial anatomy is necessary to appreciate abnormal anatomy and will be the focus of this section.

The celiac artery arises from the aorta shortly after it emerges through the diaphragmatic hiatus. The celiac trunk itself is typically very short and divides into the left gastric, splenic, and common hepatic artery shortly after its origin. (Figure 5). The common hepatic artery typically passes forward for a short distance in the retroperitoneum where it then emerges at the superior border of the pancreas and left side of the common hepatic duct. The common hepatic artery supplies 25% of the liver's blood supply, with the portal vein supplying the remaining 75%.

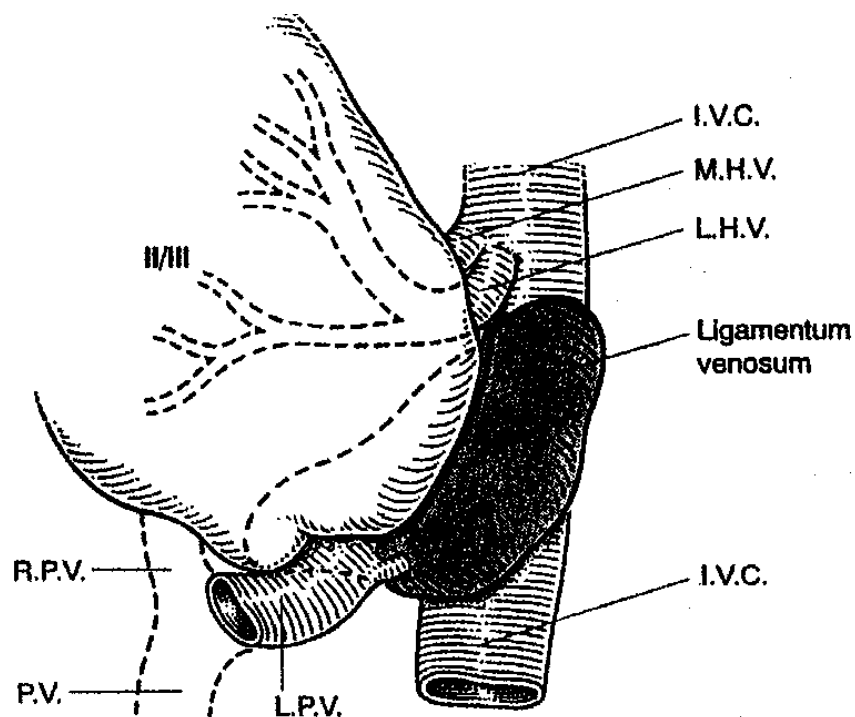


Figure 4. Caudate lobe anatomy. The caudate lobe is situated to the left of the inferior vena cava (I.V.C.). Superiorly the caudate lobe is covered by segments II and III which are reflected laterally in this diagram. The ligamentum venosum, a remnant of the fetal umbilical vein, courses across the anterior surface of the caudate lobe to enter the left hepatic vein. The caudate lobe runs along the retrohepatic vena cava from the common trunk of the middle and left hepatic veins (M.H.V., L.H.V.) to the portal vein (P.V.) inferiorly. (Left (L.P.V.) and right portal vein (R.P.V.)). Small venous tributaries drain the caudate lobe directly into to the I.V.C. On its medial surface, the caudate lobe is attached to the right liver by the caudate process.

After arising from the celiac axis, the common hepatic artery turns upward and runs lateral and adjacent to the common bile duct. The gastroduodenal artery that supplies the proximal duodenum and pancreas is typically the first branch of the common hepatic artery. The right gastric artery takes off shortly thereafter and continues within the lesser omentum along the lesser curve of the stomach. At this point the common hepatic artery is referred to as the proper hepatic artery. The proper hepatic artery courses towards the hilum, and soon divides into the right and left hepatic arteries. Prior to the bifurcation, a small cystic artery branches off to

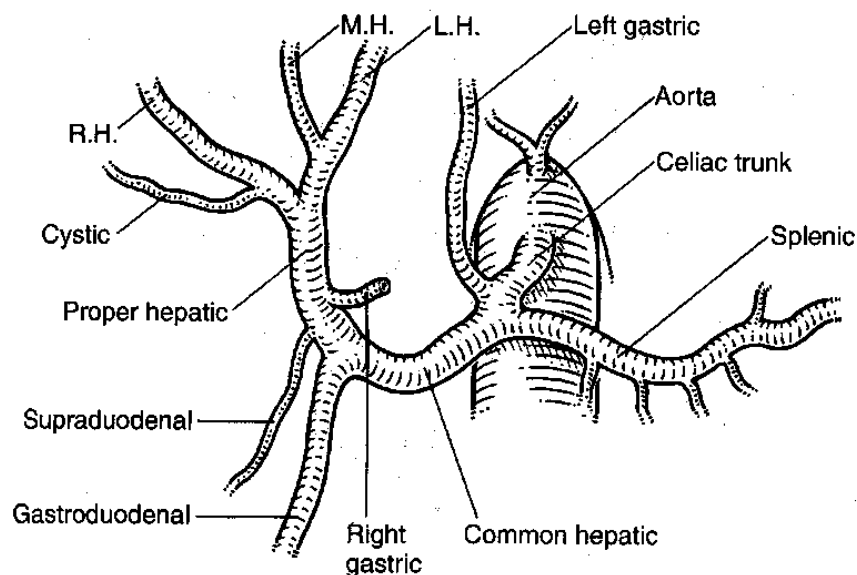


Figure 5. Normal celiac axis anatomy. The presence of the right hepatic (R.H.), middle hepatic (M.H.) to segment IV, and left hepatic (L.H.) artery are demonstrated.

provide blood supply to the gallbladder. While coursing through the hepatoduodenal ligament, the proper hepatic artery, common bile duct, and portal vein are enveloped in a peritoneal sheath within the hepatoduodenal ligament. The proper hepatic artery bifurcates earlier than the common bile duct and portal vein. In 80% of cases the right hepatic artery courses posterior to the common hepatic duct before entering the hepatic parenchyma. In 20% of cases, the right hepatic artery may lie anterior to the common hepatic duct. Upon reaching the hepatic parenchyma, the right hepatic artery branches into right anterior (Segments V and VIII), and right posterior sectoral branches (Segments VI and VII). The posterior sectoral branch initially runs horizontally through the hilar transverse fissure (of Gunz), normally present at the base of Segment V and adjacent to the caudate process. The left hepatic artery runs vertically towards the umbilical fissure where it gives off a small branch (often called the middle hepatic artery) to segment IV, before continuing on to supply Segments II and III. Additional small branches of the left hepatic artery supply the caudate lobe (segment I), although caudate arterial branches may also arise from the right hepatic artery. The sectoral and segmental bile ducts and portal veins follow the course of the hepatic artery branches. Intrahepatic branching of these structures will be discussed in more detail below.

The blood supply to the common bile duct is varied and multiple. Branches of the common hepatic, gastroduodenal, and pancreaticoduodenal arteries have all been shown to provide arterial supply at various levels.

5.2. Hepatic arterial anomalies

Variations in the arterial blood supply to the liver are common. Although the hepatic artery typically arises from the celiac axis, complete replacement of the main hepatic artery or its'

branches occur with variable frequency. Similarly, duplication or accessory hepatic arterial branches, particularly an accessory left hepatic artery, may be more the norm than an anomaly. The most common hepatic arterial anomaly involving a replaced vessel is a replaced right hepatic artery (25%). In this situation, the replaced right hepatic artery usually arises from the superior mesenteric artery and runs lateral and posterior to the portal vein within the hepatoduodenal ligament. (Figure 6). In rare instances, the entire common hepatic artery, or its' individual branches may arise directly off the celiac trunk or aorta.

6. Portal venous anatomy

The portal vein is formed by a union of the superior mesenteric vein (SMV) and splenic vein behind the neck and body of the pancreas. In up to one third of all individuals, the inferior mesenteric vein may also join this confluence. Venous tributaries from the pancreas may also drain directly into the portal vein, and generally correspond to the arterial supply. More precisely, there are anterior, posterior, superior and inferior pancreatic vessels. In addition, the left gastric vein and inferior mesenteric vein typically drain into the splenic vein, but in rare instances these vessels may enter the portal vein directly. Surgical dogma states that there are no venous branches on the anterior surface of the portal vein and, for the most part this is true – most veins enter the portal vein tangentially from the side. However, having paid homage to surgical dogma, the reality is that small anterior venous branches may exist, and any manipulation posterior to the pancreatic neck and anterior to the portal vein should be performed with maximum operative exposure and care.

Access to the portal vein is typically obtained by identifying the superior mesenteric vein on the inferior surface of the pancreas. In some circumstances it is necessary to first locate the middle colic vein within the transverse mesocolon and follow it inferiorly to the SMV. The length of the SMV is highly variable, and may range from only a few millimeters up to 4 cm. In many circumstances the SMV is made up of 2 to 4 venous branches that coalesce shortly before joining the portal vein rather than a single dominant vein. The inferior pancreaticoduodenal vein, which can be quite prominent, is the only vein that normally enters the SMV directly. Proper identification of this vein is necessary to avoid injury (and often substantial blood loss). All other pancreatic venous tributaries enter the portal vein, rather than the SMV.

In the performance of a pancreaticoduodenal resection, early division of the common bile duct (CBD) provides great exposure to the right lateral side of the portal vein, and facilitates the creation of a “tunnel” above the portal vein, and beneath the pancreas. Once a determination has been made regarding the resectability of the pancreatic lesion, we favor early transection of the common bile duct. If the tumor later proves unresectable, a palliative end to side bilioenteric bypass can be performed.

In addition to those variants described above, there are additional (but rare) congenital anomalies of the portal vein with which the surgeon should be aware. The two most common are an anterior portal vein that lies above the pancreas and duodenum, and a direct entry of the portal vein into the inferior vena cava-- a congenital “portocaval” shunt. The importance

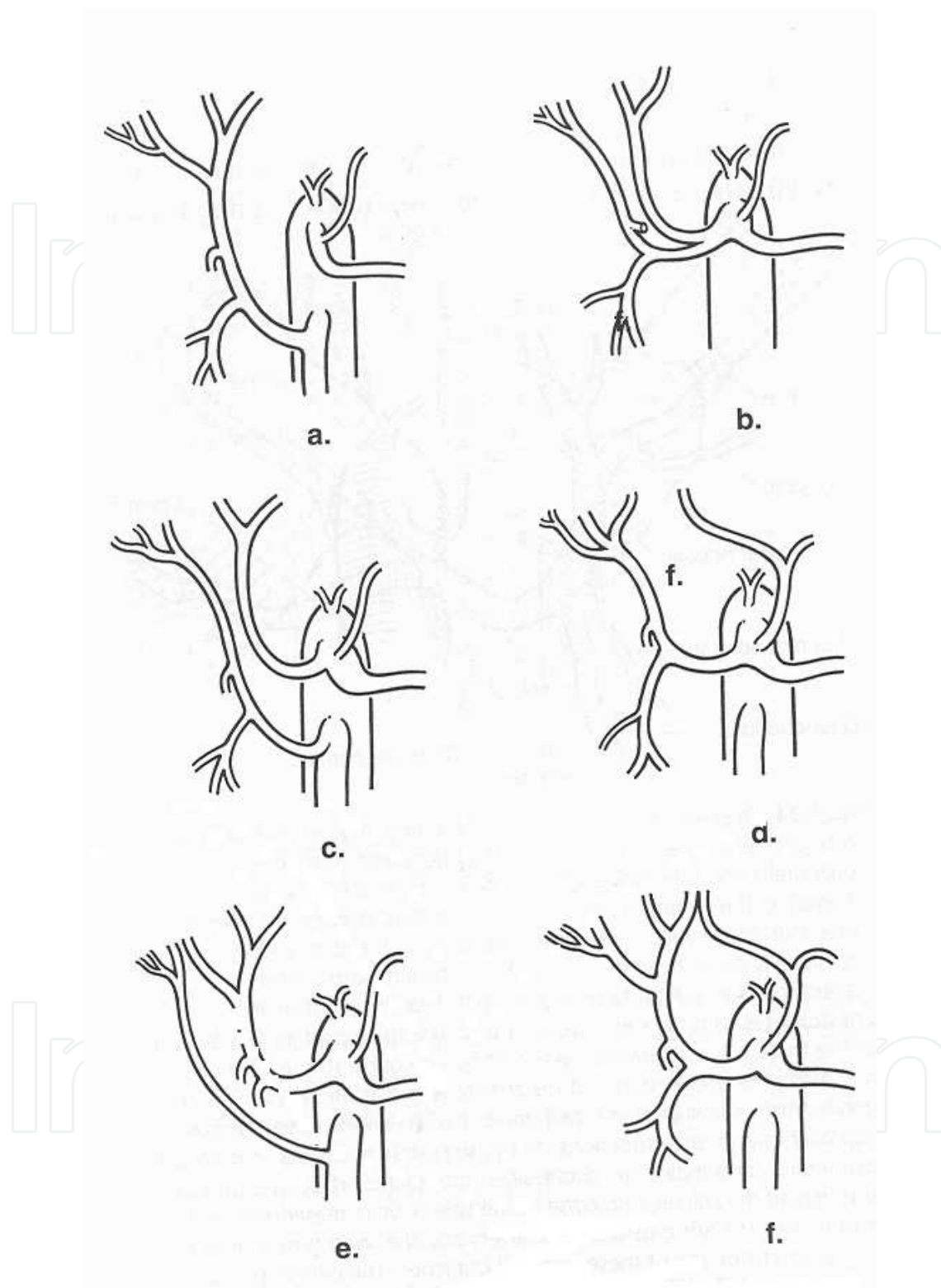


Figure 6. Hepatic arterial anomalies. (a) Replaced main hepatic artery arising from the superior mesenteric artery (SMA), (b) Independent origin of the right and left hepatic artery from the celiac axis, (c) Replaced right hepatic artery arising from the SMA, (d) Replaced left hepatic artery arising from the left gastric artery (LGA), (e) Accessory right hepatic artery arising from the SMA, (f) Accessory left hepatic artery arising from the LGA.

of careful dissection around the portal vein cannot be overemphasized. Inadvertent injury or transection of the portal vein or a main tributary is difficult to correct, and remains among the most lethal of surgical errors.

7. Intrahepatic arterial and portal venous anatomy

Throughout the course of the liver, the sectoral and segmental bile ducts, hepatic arteries and portal venous branches run together. (Figure 7) Whereas knowledge of precise intrahepatic biliary anatomy is of most practical value to the operating surgeon, further detail about intrahepatic anatomy will be discussed in that section below.

8. The biliary tract

Extrahepatic hepatic biliary anatomy

The extrahepatic biliary system consists of the extrahepatic portions of the right and left bile ducts that join to form a single biliary channel coursing through the posterior head of the pancreas to enter the medial wall of the second portion of the duodenum. The gallbladder and cystic duct form an additional portion of this extrahepatic biliary system that typically joins with the terminal portion of the common hepatic duct to form the common bile duct. In most instances, the confluence of the right and left bile ducts lies to the right of the umbilical fissure and anterior to the right branch of the portal vein. The right hepatic duct is typically short (< 1cm) and branches into a right posterior sectoral duct (segments VI/VII) and a right anterior sectoral duct (segments V/VIII) shortly after entering the hepatic parenchyma. In contrast, the left hepatic duct has a relatively long extrahepatic course (2- 3 cm) along the base of the quadrate lobe (segment IV) and enters the hepatic parenchyma at the umbilical fissure. Lowering the hilar plate (i.e., connective tissue enclosing the left hepatic elements and Glisson's capsule) at the base of the quadrate lobe provides great exposure to both the biliary hilum and the extrahepatic portion of the left hepatic duct. (Figure 8)

9. The common bile duct

By convention, the entry point of the cystic duct divides the main extrahepatic biliary channel into the common hepatic duct (above) and the common bile duct (below). The common bile duct continues inferiorly positioned anterior to the portal vein, and lateral to the common hepatic artery. If the hepatic artery bifurcates early, the right hepatic artery may be seen coursing below (80% of the time) the common bile duct (see details above). At the junction of the 1st and 2nd portion of the duodenum, the common bile duct ducks behind the duodenum posterior to the pancreatic head, in order to enter the medial wall of the duodenum (2nd portion) at the sphincter of Oddi.

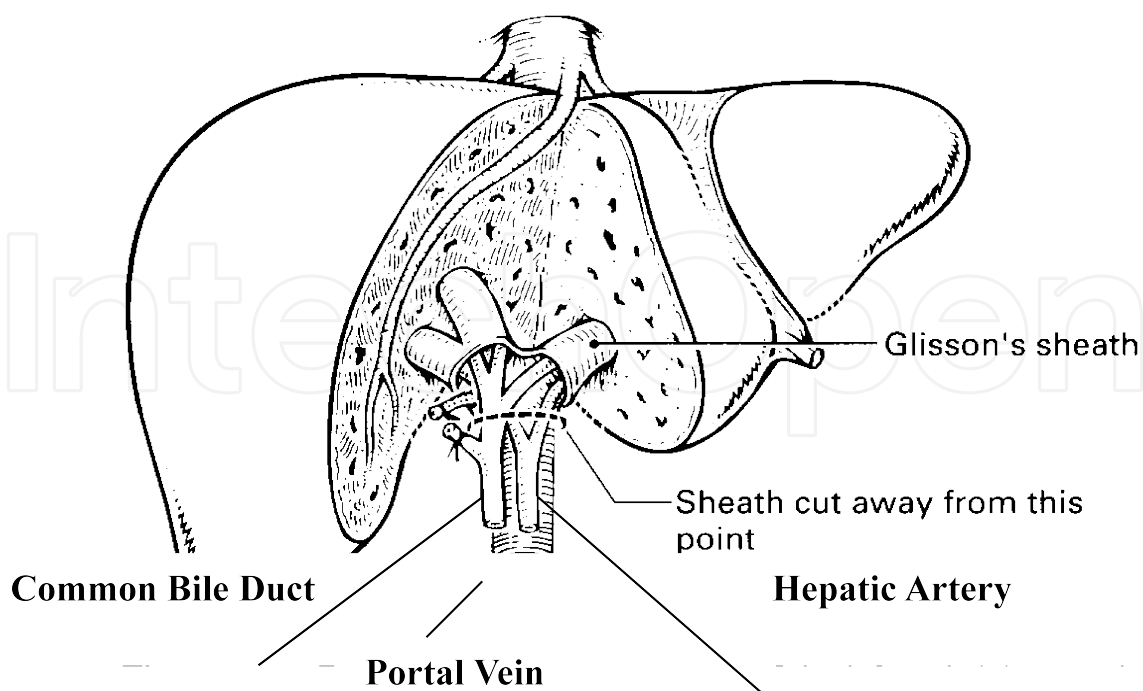


Figure 7. Portal pedicles. This cutaway view of the right and left portal pedicles demonstrate the course of the right and left portal veins, hepatic ducts, and hepatic arteries as they enter the hepatic parenchyma

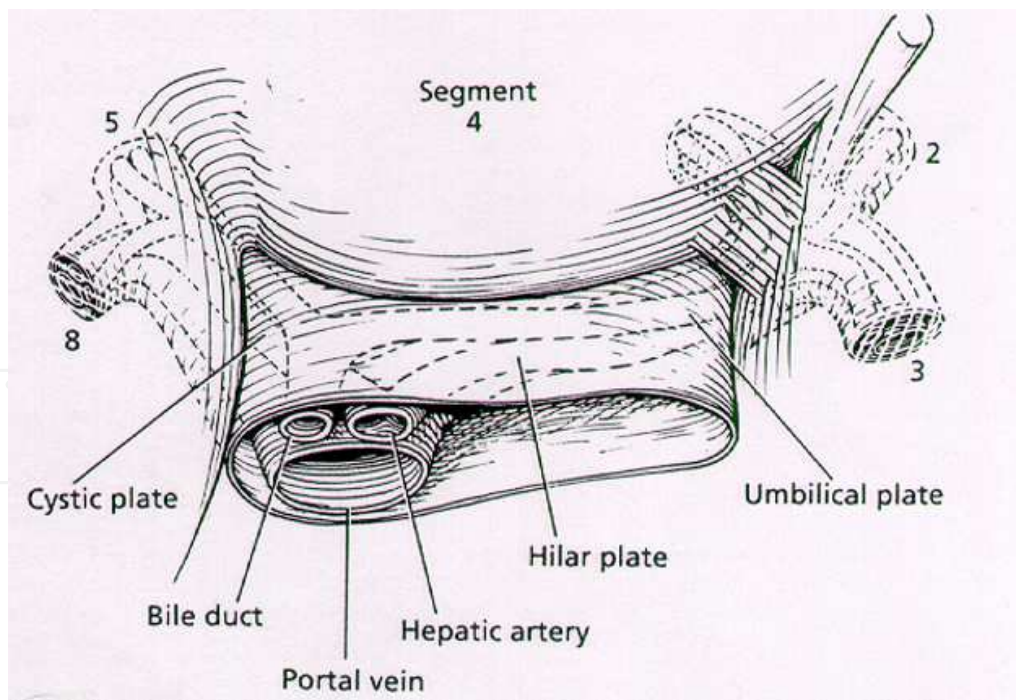


Figure 8. Lowering of the hilar plate and exposure of the left hepatic duct. The left hepatic duct runs at the base of the quadrate lobe (segment 4) and is covered by the hilar plate (a layer of connective tissue running between the hepatoduodenal ligament and the Glissonian capsule of the liver). Dividing this layer demonstrates the extrahepatic portion of the left hepatic duct arising from the umbilical fissure. (Numbers 2,3,4 and refer to segmental liver anatomy).

10. Gallbladder and cystic duct

The gallbladder is situated on the undersurface of the anterior inferior sector (segment V) of the right lobe of the liver. Though often densely adherent, it is separated from the liver parenchyma by the cystic plate, a layer of connective tissue arising from Glisson's capsule and in continuity with the hilar plate at the base of segment IV. In rare instances, the gallbladder is only loosely attached to the undersurface of the liver by a thinly veiled mesentery and may be prone to volvulus. Variations in gallbladder anatomy are rare. These variations include (a) bilobed or double gallbladders, (b) septated gallbladders, or (c) gallbladder diverticula.

The cystic duct arises from the infundibulum of the gallbladder and runs medial and inferior to join the common hepatic duct. The cystic duct is typically 1-3 mm in diameter, and can range from 1 mm to 6 cm in length depending upon its union with the common hepatic duct. Spiral mucosal folds, referred to as valves of Heister, are present in the mucosa of the cystic duct. Cystic duct abnormalities are uncommon and include (a) double cystic ducts (very rare), (b) aberrant cystic duct entry sites, and (c) aberrant cystic duct union with the common hepatic duct. Aberrant entry points for the cystic duct include a low entry into the common hepatic duct retroduodenal or retropancreatic, and anomalous entry into the main right hepatic duct or sectoral duct. Aberrant union of the cystic duct and common hepatic duct can take multiple forms including (a) absence of a cystic duct (< 1%), (b) parallel course of the cystic duct and common hepatic artery with a shared septum (20%), and (c) an anomalous passage of the cystic duct posterior to the common hepatic duct with entry on the medial wall (5%). (Figure 9)

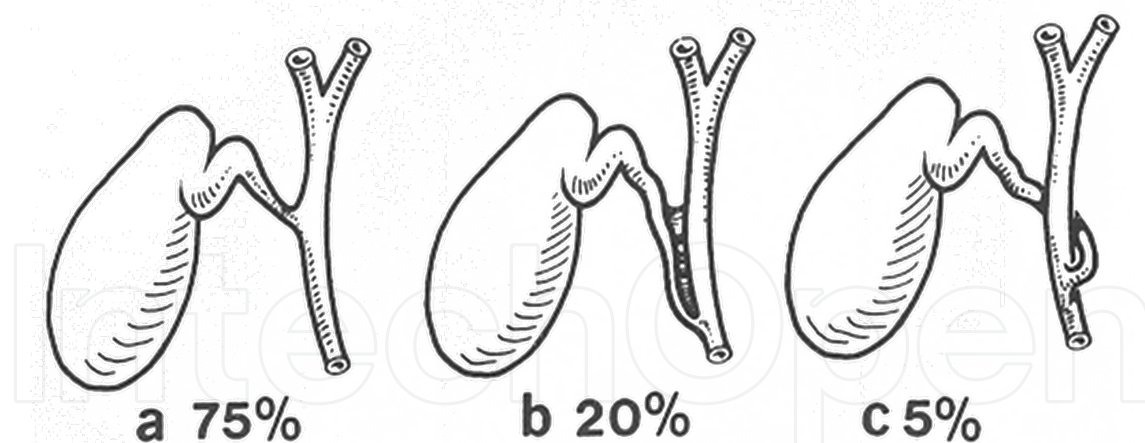


Figure 9. Variations in cystic ductal anatomy.

Typically, the cystic artery is a single vessel that courses lateral and posterior to the cystic duct. However, variations in the anatomy of the cystic artery are common. (Figure 10) Multiple cystic arteries, origin of the cystic artery from a segmental or lobar hepatic artery, aberrant course of the cystic artery over the cystic duct, and various other anomalies have been reported. A careful intra-operative determination of cystic artery anatomy is important to prevent unnecessary hemorrhage during cholecystectomy.

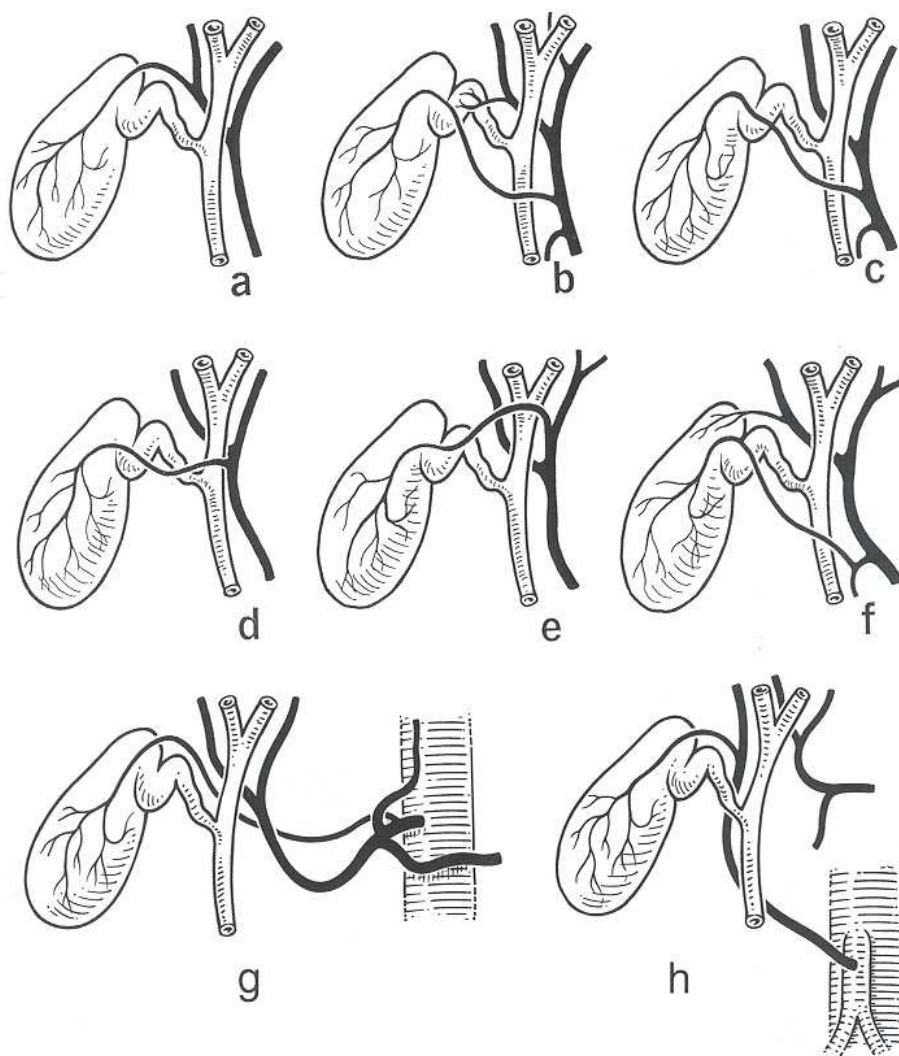


Figure 10. Cystic artery anomalies. (A) Typical course, (B) Double cystic artery, (C) cystic artery crossing anterior to the main bile duct, (D) cystic artery originating from the right branch of the hepatic artery and crossing the common hepatic duct anteriorly, (E) cystic artery originating from the left branch of the hepatic artery, (F) cystic artery originating from the gastroduodenal artery, (G) the cystic artery may arise from the celiac axis, (H) cystic artery originating from a replaced right hepatic artery.

10. Intrahepatic bile duct anatomy

An understanding of intrahepatic ductal anatomy is obviously important and vital to the performance of a high biliary anastomoses for cholangiocarcinoma (Klatskin tumors), an intrahepatic bilioenteric bypass, and complex hepatic resections such as caudate lobectomy, and left and right trisegmentectomy. The right and left lobes of the liver are drained separately by the right and left hepatic ducts. In contrast, 1 – 4 smaller ducts from either the right or left hepatic ducts drain the caudate lobe. Within the liver parenchyma, the intrahepatic biliary radicals parallel the major portal triad tributaries directed toward each hepatic segment of the

liver. More specifically, bile ducts are usually situated superior to its complementary portal vein branch, while the hepatic artery lies inferiorly.

The left hepatic duct drains all 3 segments of the left liver. (Segment II, III, and IV). In some textbooks, segment IV, the quadrate lobe, is further sub-divided into sub-segments (4A, superior, and 4B, inferior). So conceptually, both the right and left hepatic ducts each drains 4 segments. Although the left hepatic duct originates within the liver and terminates in the common hepatic duct, it is easier to describe its' path in reverse since the extrahepatic areas are readily visible to the operating surgeon. After the bifurcation into the right and left hepatic ducts, the left duct courses towards the umbilical fissure along the under surface of segment IVB above and behind the left branch of the portal vein. Access to this area can be gained by lowering the hilar plate (described above). Several small branches from the quadrate lobe (Segment 4) and the caudate lobe (Segment 1) may enter the left duct at this location. The left hepatic duct is formed within the umbilical fissure by the segment III (lateral), and segment IVB (medial) ducts. Following the course of the umbilical fissure vertically towards the falciform ligament, the segment II (lateral), and segment IVA (medial) branches are formed. Although a careful and tedious dissection is required to access the segmental biliary ducts for anastomoses, (e.g., a segment III bypass), control of the segmental portal triads to all areas of left lobe is readily achievable within the umbilical fissure. (see Figure 11)

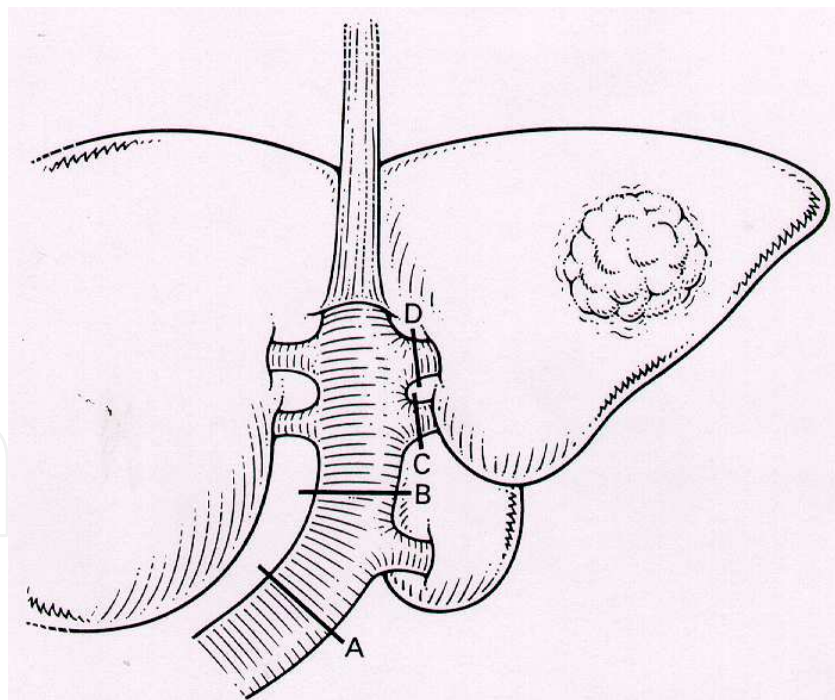


Figure 11. Left portal vein pedicle. The union of the segment IV, II, and III portal veins within the umbilical fissure forms the left portal vein. A separate segment I portal vein also enters the left portal vein before it coalesces with the right portal vein at the hilus. Lines A, B, C, D demonstrate various lines of portal vein transection which are required to complete various hepatic resections. Line A is the line of transection for completion of a left hepatectomy and caudate lobectomy. Line B is the line of transection for completion of a left hepatectomy. Line C is the line of transection for a segment II resection. Line D is the line of transection for a segment III resection.

The right hepatic duct emerges from the liver at the base of segment V just to right of the caudate process. This duct drains segments V, VI, VII, and VIII and originates at the junction of the right posterior (segments VI and VII), and anterior (segments V and VIII) sectoral ducts. The right posterior sectoral duct follows an almost horizontal course at the base of segments V and VI that can often be seen lying within a transverse fissure on the superficial surface of the liver. Segmental biliary branches from segments VI (inferior) and VII (superior) converge to form the main right posterior sectoral duct. Segmental branches from segments V and VIII form the right anterior sectoral duct. While the right posterior sectoral duct follows a horizontal course, the right anterior sectoral duct runs almost vertical within segment V, and receives branches from both segment V (inferior) and VIII (superior).

Biliary drainage of the caudate lobe is less predictable. Conceptually, the caudate lobe has three distinct areas -- a right part, a left part, and the caudate process. In some instances three separate bile ducts may be present. The caudate process represents a narrow bridge of tissue that connects the caudate to the right lobe (segment V). In more than 75% of cases the caudate drains into both the right and left hepatic ductal system, but isolated drainage into the right (< 10%), or left hepatic duct (~15%) can occur.

11. Anomalous biliary drainage

Normal intra- and extrahepatic biliary anatomy is present in approximately 75 percent of cases. (Figure 12) Every effort should be made to define existing intrahepatic anatomy based on pre-operative imaging, since failure to do so may result in devastating complications. Anomalies in both sectoral and segmental anatomy may exist together or separately. The more common type of each of the anomalies will be described in more detail below.

Anomalous sectoral biliary anatomy

Although the union of the right and left hepatic duct typically occurs at the hilum, a triple confluence of the right posterior and anterior sectoral ducts with the left hepatic duct may, exist in up to ~15% of cases. (Figure 12) In 20% of cases, one of the right sectoral ducts, more commonly the anterior sectoral duct, may enter the common hepatic duct distal to the confluence. If this situation is not recognized it can be very dangerous, and represents a common cause of injury during laparoscopic cholecystectomy. Less commonly (~5%), the right posterior sectoral duct (and rarely the right anterior sectoral duct) may cross to enter the intrahepatic portion of the left hepatic duct. Failure to appreciate this anomaly prior to right or left hepatectomy, can lead to significant post-operative problems. Note some authorities believe that this anomaly represents the most common intrahepatic biliary variations.

Anomalous segmental biliary anatomy

A large number of segmental biliary anomalies have been reported. Most are unimportant to the surgeon and of anatomical interest only. Figure 13 illustrates the more common anomalies that have been reported within the right lobe and the medial segment of the left lobe.

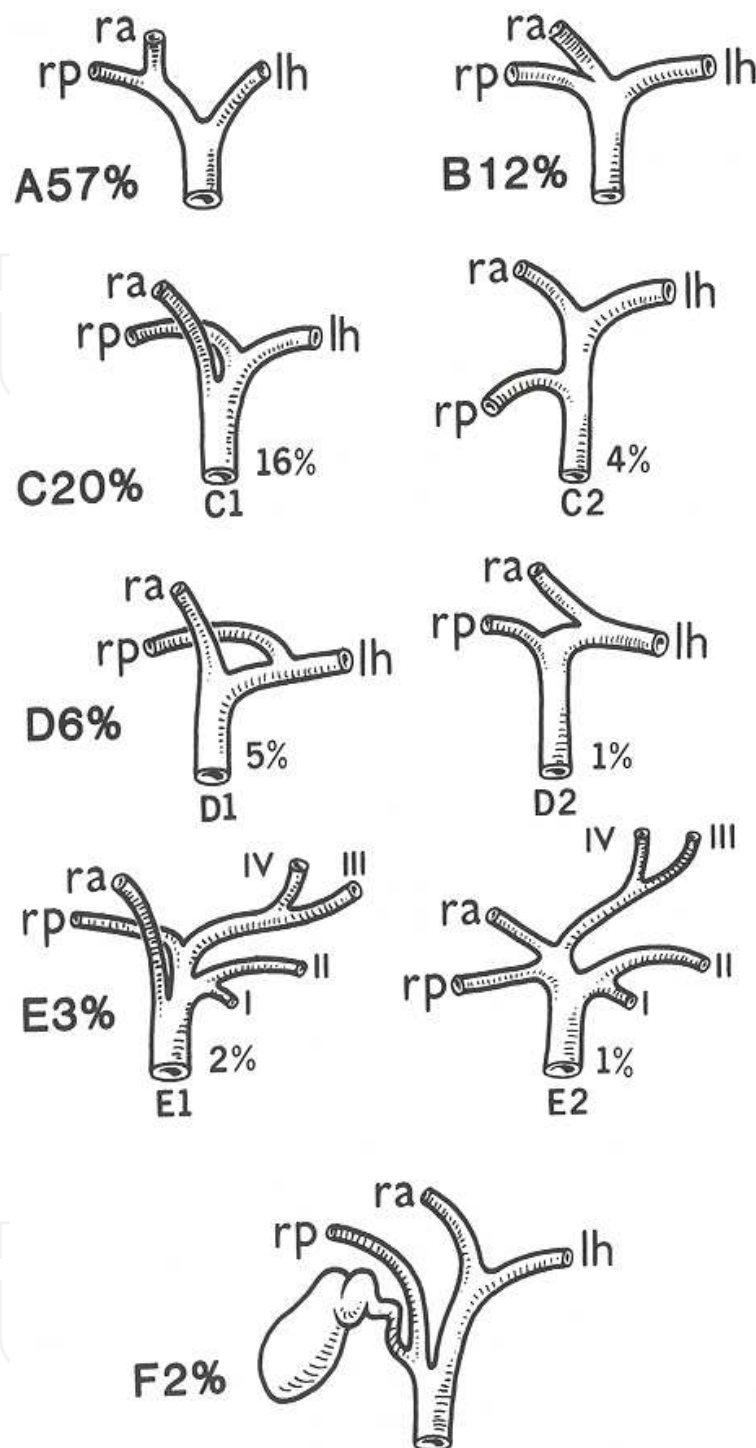


Figure 12. Normal and aberrant sectoral ductal anatomy. (A) Typical ductal anatomy, (B) triple confluence, (C) Ectopic drainage of a right sectoral duct into the common hepatic duct (C1, right anterior duct draining into the common hepatic duct; C2, right posterior duct draining into the common hepatic duct), (D) ectopic drainage of a right sectoral duct into the left hepatic ductal system (D1, right posterior sectoral duct draining into the left hepatic ductal system; D2, right anterior sectoral duct draining into the left hepatic ductal system), (E) absence of the hepatic duct confluence, (F) absence of right hepatic duct and ectopic drainage of the right posterior duct into the cystic duct.

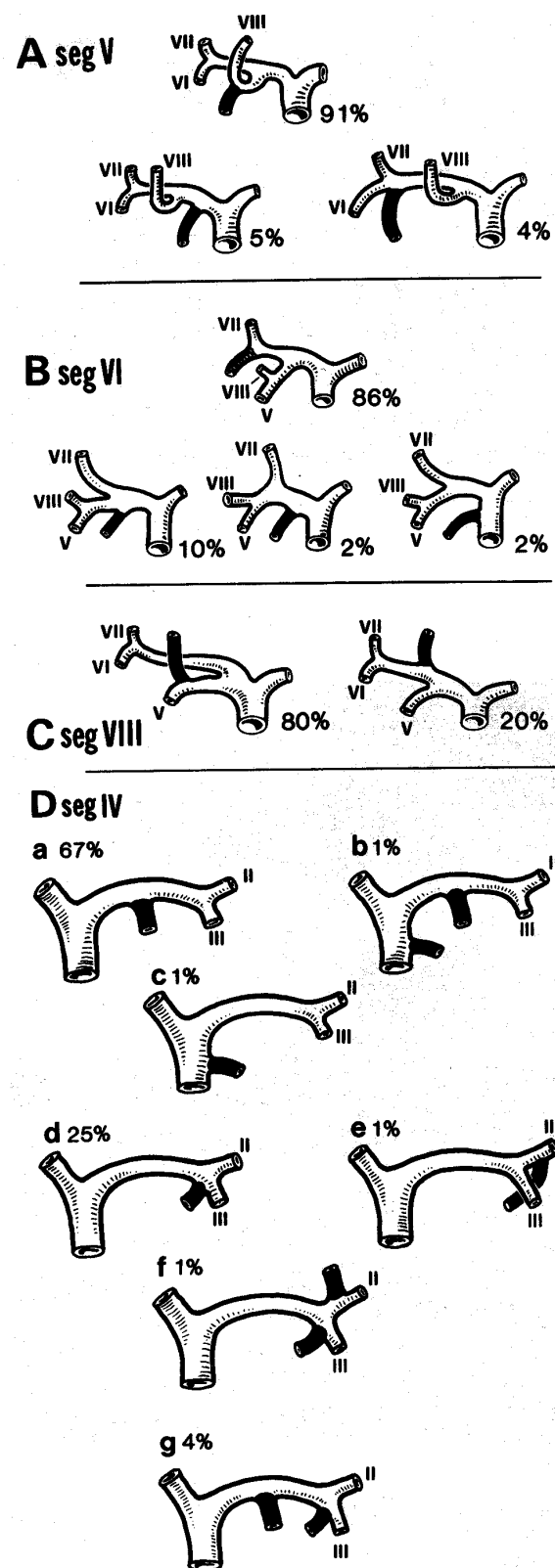


Figure 13. Normal and aberrant segmental ductal anatomy. (A), variations of segment V, (B) variations of segment VI, (C) variations of segment VIII, (D) variations of segment IV. Note there is no variation of drainage of segments II, III, and VII.

12. Summary

A comprehensive understanding of normal and aberrant anatomy is the cornerstone of surgery. The truth of this statement is nowhere more apparent than in the performance of complex hepatobiliary surgery. Mastery of the segmental anatomy of the liver, as well as a comprehensive understanding of both normal and anomalous arterial, venous and biliary anatomy, are the *sine qua non* for performing safe hepatic resections. Recent advances in peri-operative management of patients with hepatobiliary diseases (detailed elsewhere in this book), permit the surgeon to perform increasingly radical hepatic procedures (upon sicker patients.) Although the expertise offered by our radiology and anesthesiology colleagues is important, it is incumbent upon every surgeon who performs liver resection to be well prepared. An age-old surgical axiom states “98% of the surgical outcome is determined in the operating room.” A good outcome in the performance of hepatic resections requires one to become a student of the game.

Author details

Ronald S. Chamberlain^{1,2,3}

1 Department of Surgery, Saint Barnabas Medical Center, Livingston, NJ, USA

2 Department of Surgery, University of Medicine and Dentistry of New Jersey, Newark, NJ, USA

3 Saint George's University School of Medicine, Grenada, West Indies

References

- [1] Abdalla, E. K, Vauthey, J. N, & Couinaud, C. The caudate lobe of the liver: implications of embryology and anatomy for surgery. *Surg Oncol Clin N Am* (2002). , 11, 835-48.
- [2] Bismuth, H. Surgical anatomy and anatomical surgery of the liver. *World J Surg* (1982). , 6, 3-9.
- [3] Bismuth, H. Surgical anatomy and anatomical surgery of the liver. In: Blumgart LH, editor. *Surgery of the liver and biliary tract*. Edinburgh (UK): Churchill Livingstone; (1988). , 3-10.
- [4] Couinaud, C. Lobes et segments hépatiques: note sur l'architecture anatomique et chirurgicale du foie. *Presse Med* (1954).
- [5] Ger, R. Surgical anatomy of the liver. *Surg Clin N Am* (1989). , 69, 179-93.

- [6] Goldsmith, N. A, & Woodburne, R. T. Surgical anatomy pertaining to liver resection. *Surg Gynecol Obstet* (1957).
- [7] Healey JE JrSchroy PC. Anatomy of the biliary ducts within the human liver: analysis of the prevailing pattern of branchings and the major variations of the biliary ducts. *Arch Surg* (1953).
- [8] Healey JE JrVascular anatomy of the liver. *Ann N Y Acad Sci* (1970).
- [9] Healey JE JrClinical anatomic aspects of radical hepatic surgery. *J Int Coll Surg* (1954).
- [10] Hjortsjo, C. H. The topography of the intrahepatic duct system. *Acta Anat* (1951). , 11, 599-615.
- [11] Longmire, W. P. Historic landmarks in biliary surgery. *South Med J* (1982). , 75, 1548-50.
- [12] Meyers, W. C, Ricciardi, R, & Chiari, R. S. Liver. Anatomy and development. In: Townsend CM, editor. *Sabiston textbook of surgery*. 16th edition. Philadelphia: WB Saunders; (2001). , 997-1034.
- [13] Mizumoto, R, & Suzuki, H. Surgical anatomy of the hepatic hilum with special reference to the caudate lobes. *World J Surg* (1988). , 12, 2-10.
- [14] Nakamura, S, & Tsuzuki, T. Surgical anatomy of the hepatic veins and the inferior vena cava. *Surg Gynecol Obstet* (1981). , 152, 43-50.
- [15] Skandalakis, L. J, Colborn, G. L, Gray, S. W, et al. Surgical anatomy of the liver and extrahepatic biliary tract. In: Nyhus LM, Baker RJ, editors. *Mastery of surgery*. 2nd edition. Boston: Little, Brown and Co; (1992). , 775-805.
- [16] Skandalaki, J. E, Skandalakis, L. J, Skandalakis, P. N, & Mirilas, P. Hepatic Anatomy. *Surg Clin N Am* 84 ((2004).
- [17] Smith, R. In: Suzuki T, Nakayusu A, Kauabe K, et al, editors. Surgical significance of anatomic variations of the hepatic artery. *Am J Surg* (1971). , 122, 505-12.