

# We are IntechOpen, the world's leading publisher of Open Access books Built by scientists, for scientists

6,900

Open access books available

185,000

International authors and editors

200M

Downloads

Our authors are among the

154

Countries delivered to

TOP 1%

most cited scientists

12.2%

Contributors from top 500 universities



WEB OF SCIENCE™

Selection of our books indexed in the Book Citation Index  
in Web of Science™ Core Collection (BKCI)

Interested in publishing with us?  
Contact [book.department@intechopen.com](mailto:book.department@intechopen.com)

Numbers displayed above are based on latest data collected.  
For more information visit [www.intechopen.com](http://www.intechopen.com)



---

# **Management of In-Transit Malignant Melanoma**

---

Paul J. Speicher, Douglas S. Tyler and Paul J. Mosca

Additional information is available at the end of the chapter

<http://dx.doi.org/10.5772/53618>

---

## **1. Introduction**

In-transit melanoma is a unique pattern of recurrence that occurs in up to ten percent of patients with melanoma. In-transit disease denotes multifocal tumor deposits occurring between the site of the primary lesion and its regional draining lymph node basin [1, 2]. It is an independent adverse prognostic factor and is frequently associated with distant metastasis. This pattern of recurrence represents a challenging management problem, but provides unique treatment modalities as well. In addition, studying in-transit melanoma has the potential to shed additional light on melanoma biology. The goal of this chapter is to discuss the presentation, underlying disease biology, and various current treatment strategies for this unique pattern of recurrence in melanoma.

## **2. Background**

### **2.1. Nomenclature and staging**

The nomenclature used for in-transit melanoma can be confusing, in part because a number of different terms have traditionally been used in the literature to describe what is most likely the same oncologic process. Historically, terms such as locoregional recurrence, satellitosis, and in-transit disease have all been used with varying definitions and intentions. Historically, satellitosis has been defined as locoregional recurrence, not lying within the regional nodal basin, that is located within either 5cm of the initial lesion or 2cm of the excision scar, whereas the term in-transit disease has been defined as such a recurrence occurring at greater distances from the initial lesion or scar, respectively. In either case, such lesions likely represent tumor deposits growing along routes of lymphatic drainage. More recently, it has become apparent that for locoregional recurrence, distance from the primary

lesion to the site of recurrence does not carry significant prognostic value [3-6]. Accordingly, the most recent AJCC staging system for melanoma does not differentiate between in-transit lesions and satellitosis in the assignment of stage, both being designated as N2 or N3 disease, depending on regional node status [7]. Thus, in an effort to address the ambiguity arising from nomenclature, many authors have advocated for eliminating the term satellitosis, instead referring to all regional non-nodal metastatic disease as in-transit disease.

Stage	T	N	M
IIIA	Any depth, Without ulceration	1-3 nodes (not clinically detectable)	No distant disease
IIIB	Any depth, With ulceration	1-3 nodes (not clinically detectable)	No distant disease
	Any depth, Without ulceration	1-3 nodes (clinically detectable), OR in-transit lesions	No distant disease
IIIC	Any depth, With ulceration	1-3 nodes (clinically detectable), OR in-transit lesions, OR any combination of positive nodes and in-transit disease, OR greater than 4 positive nodes	No distant disease

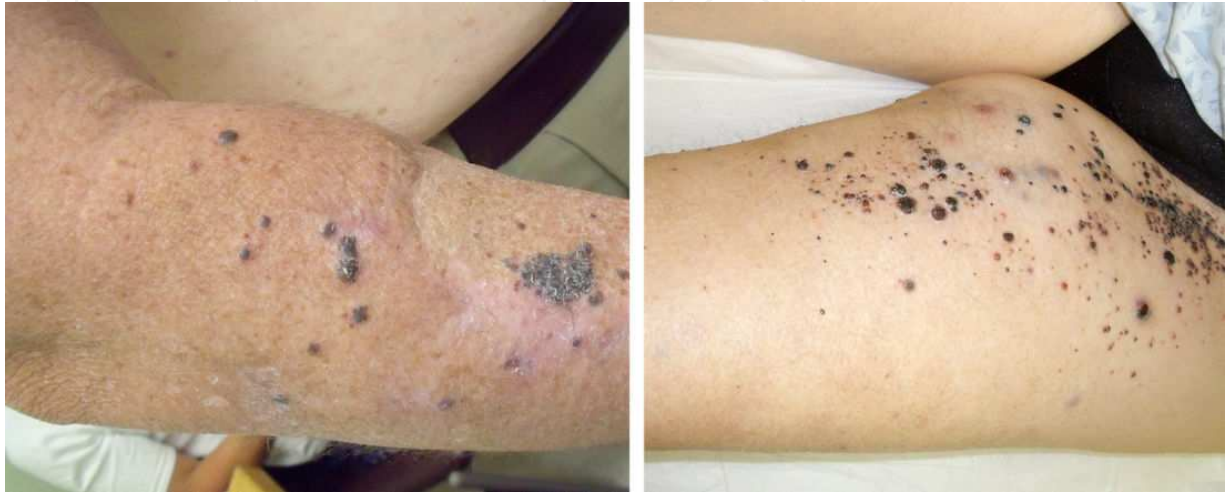**Table 1.** Breakdown of AJCC staging for stage III melanoma [7].

An additional and equally important point of clarification is the distinction between actual local recurrence and in-transit disease. True local recurrence is defined as a primary tumor that recurs as a result of incomplete primary excision, and is confined to or contiguous with an excision scar and bearing an in situ component [8]. As this carries a much better prognosis, it must be distinguished from potentially similar appearing in-transit disease found in close proximity to a prior excisional scar.

**2.2. Presentation**

By definition, in-transit melanoma represents advanced stage disease, and such recurrences are typically discovered months after the initial management of a primary lesion. In most series, this disease-free interval to recurrence as in-transit disease ranges from 12-16 months [9, 10]. The clinical presentation can be quite variable, but usually involves anywhere from one to upwards of one-hundred small cutaneous or subcutaneous nodules. The lesions themselves can differ significantly in size, ranging from sub-millimeter diameter to well over one centimeter. They may take the form of superficial cutaneous (also called epidermotropic) or deeper subcutaneous tumors. For extremity-based disease, the lesions may be clustered near the primary lesion, or may involve the entire extremity extending between

the primary tumor and its lymphatic drainage basin. For non-extremity disease, the distribution can be even more variable, with widespread tumor burden on the head, neck or trunk, depending on the location of the primary melanoma.



**Figure 1.** Examples of in-transit melanoma of the arm (left) and leg (right). Note the distribution and extent of disease, making these presentations very poor candidates for surgical excision. On the left, there is evidence of in-transit metastases both within the area of previous skin flap, as well as extending more proximally along its course of lymphatic drainage. On the right, there is extensive disease extending up to the inguinal crease.

### 2.3. Incidence

In-transit melanoma is a relatively uncommon phenomenon, with fewer than 10% of melanomas recurring as in-transit disease [1, 11]. This accounts for approximately 12-22% of all recurrences, although this number is difficult to determine with accuracy due to ambiguity regarding terminology used to describe local recurrence versus regional in-transit disease [12-14]. Stage of disease appears to be the most important factor that predicts the development of in-transit metastasis. The presence of associated nodal disease significantly increases risk of in-transit recurrence, with one study reporting incidence as high as 31% when three or more positive nodes were present [12]. Location itself also appears to be a factor, with a higher incidence of in-transit disease in the lower extremities compared to the upper extremities [15]. Of note, some earlier authors observed that surgical lymph node dissection may lead to increased risk of recurrence as in-transit disease, an area of some debate. This is postulated to be a result of lymphatic trapping, whereby dissection of the draining lymph node basin removes the potential outflow of lymphatic tumor deposits, possibly leading to increased likelihood of in-transit disease. In larger, more recent studies, however, neither sentinel lymph node biopsy nor lymphadenectomy were found to have any effect on the incidence of in-transit metastases [16-19].

## 2.4. Outcomes

The presence of in-transit metastases indicates either N2 or N3 status under the current AJCC TNM system, and is classified as stage IIIB or C disease, respectively. In-transit melanoma carries a poor prognosis, with 5-year survival rates ranging from 25% to 30% in most reports [12, 20, 21]. Additionally, the presence or absence of regional lymph node disease is of significant prognostic value; the combination of nodal metastasis and in-transit melanoma comprise stage IIIC disease, which is associated with a poorer outcome than stage IIIB (40% vs. 59% five-year survival, respectively) [7]. There is a high incidence of occult distant metastasis in the presence of in-transit melanoma, but this is not universally the case. Studies examining the outcomes of major amputation for the treatment of this pattern of recurrence have identified a number of patients who experience a complete and durable response and have demonstrated five-year survival rates ranging from 21-32% [22-26]. This indicates that a significant minority of patients with in-transit metastases have disease that is truly limited to the extremity at the time of detection. Nonetheless, it is essential that distant metastases be ruled out when staging patients with in-transit melanoma, since treatment options and prognosis may differ substantially when measurable distant disease is present.

## 3. Biology of in-transit disease

The underlying biology of in-transit melanoma is believed to be related to lymphatic dissemination of small tumor emboli along the lymphatic drainage from the primary tumor. It is generally accepted that these migrating tumor cells become trapped in the dermal and subdermal lymphatics, typically, though not always, somewhere between the primary lesion and the draining regional lymph nodes. These cells are thought to remain static along this route, eventually progressing to a clinically detectable lesion. Consistent with this theory, in-transit melanoma is often described as an ongoing process, with increasing disease burden over time. Although the lymphatic route is the most likely biological explanation, some authors have suggested other mechanisms. One alternate explanation describes in-transit disease as a manifestation of systemic disease resulting from hematogenous spread, similar to distant metastases [27, 28]. Proponents of this argue that in the lymphatic theory, wider margins of primary excision would be expected to include more static occult cells, with subsequent improved clinical outcomes, yet this has not been shown to be the case. It is difficult to reconcile this theory, however, with the significant differences in survival observed in stage III versus stage IV melanoma.

## 4. Therapy for in-transit disease

Treatment of locoregionally recurrent melanoma depends on a number of important factors, including tumor size, multiplicity, and anatomic location. Although in-transit melanoma is often followed by metastatic disease, it is important that the surgeon choose an appropriate therapy based on clinical presentation, history, technical experience, and patient preference.

#### 4.1. Local management

Distinguishing in-transit disease from true local recurrence is of great importance, as the management and prognosis differ substantially. Local recurrence, or tumor confined to or contiguous with an excision scar and bearing an in situ component, should be managed similarly to the primary lesion with wide local excision. For in-transit disease, however, it is generally accepted that the wide local excision margin guidelines applicable to primary melanomas need not be applied. In-transit metastases are generally very clearly demarcated histologically from surrounding tissue, and complete macroscopic excision with negative surgical margins is usually all that is required.

In addition to wide local excision, there has been significant interest in other forms of local therapy for melanoma lesions, including laser ablation, external beam radiation, and intralesional injections. Irrespective of modality, these should all be thought of as equivalents to local surgical excision regarding indications and prognosis.

Laser therapy was first described in 1973, and has gained favor in the local treatment of in-transit disease that is not amenable to surgical excision, such as when the disease is too extensive [29]. It is most useful in patients with a large number of small in-transit lesions, but its advantages and utility decrease as lesions increase in size [30]. For tumors smaller than approximately 3mm, the entire lesion can be ablated using a carbon dioxide laser, though larger lesions must be circumscribed using the laser and subsequently excised with forceps.

Intralesional injections have also been used in the treatment of in-transit melanoma with some success. The most commonly used therapies include bacillus Calmette-Guérin (BCG), dinitrochlorobenzene (DNCB), and interferon-alpha (INF- $\alpha$ ), and IL-2. Small studies have demonstrated complete response rates of 31-63% (overall response 45-91%), although long-term survival, when reported, remained unfortunately low [31-33]. This suggests that if surgical excision is not a viable option, intralesional injection is a reasonable alternative. More recently, electrochemotherapy (ECT) has gained popularity as local alternative to radiotherapy and laser ablation. This technique relies on using high intensity electric pulses to allow intracellular delivery of cytotoxic drugs, such as cisplatin and bleomycin, via intralesional injection [34]. Complete response rates have been reported as 53-89% (overall response 84-99%), with minimal systemic toxicity [35-37]. Unfortunately, regardless of which method is employed, local management of in-transit melanoma remains suboptimal in many situations.

#### 4.2. Radiation therapy

Early in-vitro and clinical studies suggested that melanoma tumors exhibited significant intrinsic resistance to ionizing radiation, and as such, radiotherapy has not traditionally been considered to have a major role in the treatment of in-transit melanoma [38, 39]. More recent studies, however, have suggested radiotherapy may be of value in certain subsets of individuals, particularly those with one or few metastatic lesions that are not amenable to surgical excision [40]. As a primary treatment, radiotherapy is largely reserved for palliation of patients with incurable symptomatic lesions, particularly in cases that are not amenable to



surgical excision. Generally speaking, when unresectable in-transit melanoma is amenable to regional chemotherapy, this should be considered prior to employing radiotherapy.

While some studies have demonstrated potential benefit of adjuvant radiation therapy in patients with nodal melanoma metastases, there are very little data regarding the use of adjuvant radiation therapy in the setting of in-transit disease [41, 42]. Treatment depends on area and location of involvement. While not routine practice, adjuvant radiotherapy should be considered in patients with head and neck disease, and in those with positive margins that are not amenable to re-excision [43-45].

4.3. Regional therapy

Given the high rate of local treatment failure and frequently increased burden of in-transit disease, regionally focused modalities offer potential strategies to obtain more durable treatment responses. Regional chemotherapy is a promising therapeutic option for suitable patients with extremity in-transit melanoma and is currently the focus of exciting research. This modality involves vascular isolation of the affected area, after which chemotherapy is then delivered at doses 10-20 times higher than doses that can be achieved and tolerated systemically, with dosing based on affected limb volume. As regional therapy requires complete vascular isolation of the affected body area, obvious anatomic limitations are involved. The inflow and outflow vessels to the area of interest must be selectively cannulated, and the treatment region must then be isolated from the systemic circulation, usually by means of a tourniquet.

There remains significant debate as to whether regional chemotherapy produces an overall survival benefit over other therapeutic modalities, but studies have demonstrated a survival benefit in patients who exhibited a clinical response [46-48]. Originally described in the 1950s, two primary forms of regional chemotherapy have evolved: hyperthermic isolated limb perfusion (HILP) and isolated limb infusion (ILI).

	HILP	ILI
Drug delivery	Cardiopulmonary bypass	Manual pump with three-way stopcock
Circuit pressure	High; with significant risk for systemic leak	Low; significantly reduced risk of systemic leak
Vessel access	Open surgical exposure; large diameter cannulas	Percutaneous access under fluoroscopic guidance, smaller diameter cannulas
Limb pH	Physiologic	Acidotic
Limb oxygenation	Active membrane oxygenation	No external oxygenation; profound hypoxia
Temperature	39-40°C	37.8-38.5°C
Duration of treatment	60 minutes	30 minutes
Technical demand	Technically complex, difficult re-operation	Technically simpler, re-do operation without difficulty

**Table 2.** Comparison of technique and parameters between hyperthermic isolated limb perfusion (HILP) and isolated limb infusion (ILI).

#### 4.4. Regional chemotherapy agents

Melphalan is typically the drug of choice for regional chemotherapy. It is an alkylating agent derived from phenylalanine, an amino acid preferentially taken up by melanocytes due to its key role in melanin synthesis. Theoretically, melphalan should produce selective toxicity in melanocytes and melanin-containing melanoma cells. As a systemic agent, however, melphalan is ineffective despite its theoretical benefits, as its allowable dose is significantly less than its effective dose. For regional therapy, in contrast, this much higher effective dose is achieved without systemic toxicity.

Other agents have been employed either alone or in combination with melphalan in the treatment of in-transit melanoma. An essential quality of any agent considered for regional therapy is the constraint that it must not require metabolic transformation to take on a biologically active form. Cisplatin is another alkylating agent that held significant promise in preclinical studies of regional chemotherapy. Early clinical reports were favorable regarding response rates, but were plagued by concerns over toxicity [49-51]. Subsequent studies confirmed significant limb-threatening toxicity with the use of cisplatin, and as such most authors recommend against its routine use in regional therapy [52, 53]. Similarly, TNF $\alpha$  has exhibited some potential, particularly when combined with interferon-gamma, but widespread use of TNF $\alpha$ -based regimens have been tempered by significant concerns regarding toxicity [54]. The 2006 ACOSOG Z0020 trial comparing melphalan with melphalan plus TNF $\alpha$  was terminated early after interim analysis demonstrated a significant increase in toxicity with the addition of TNF $\alpha$  and yet a similar clinical response rate compared to melphalan alone [55]. Temozolomide is a newer alkylating agent that could have potential application in regional chemotherapy, as it also does not require hepatic conversion to become active. Early results in animal models reported superior tumor growth delay compared to regional melphalan, and a phase 1 clinical trial is currently underway, enrolling patients at Duke University Medical Center [56].

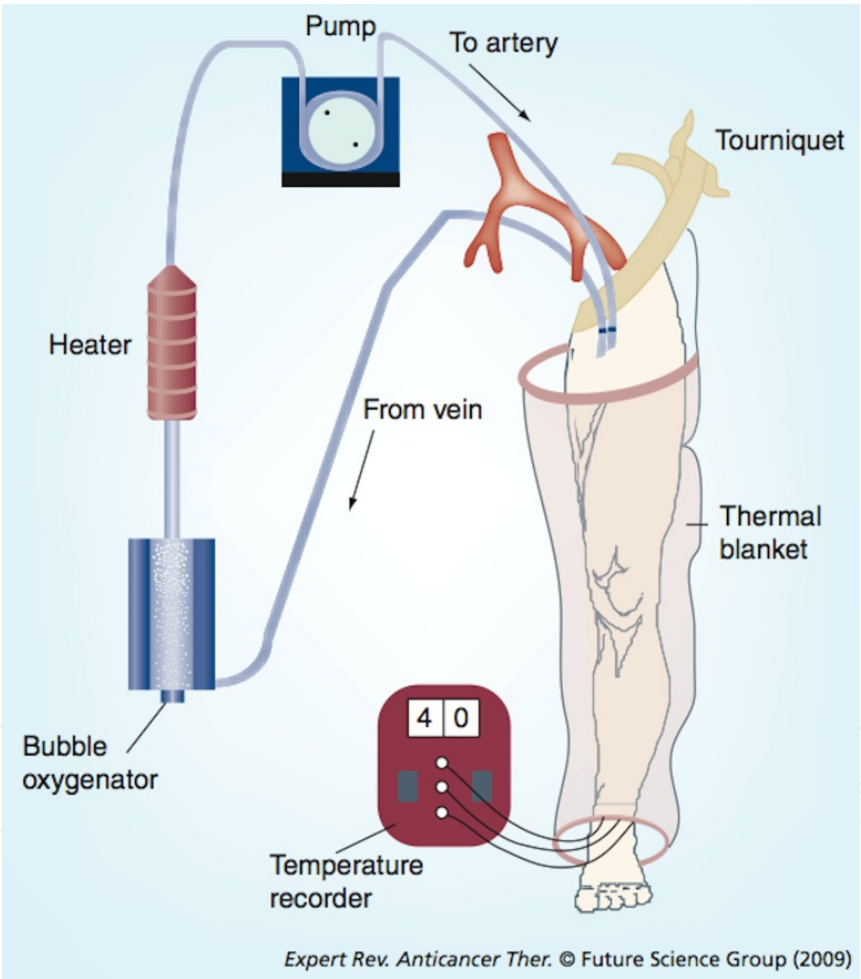
#### 4.5. Isolated limb perfusion

Isolated limb perfusion (ILP) was first described in Creech and colleagues in 1958, basing their technique on advances in cardiopulmonary bypass developed for cardiac surgery in the 1950s [57]. They utilized an extracorporeal oxygenator as part of the isolated limb circuit to deliver high dose chemotherapy while maintaining normal oxygen tension and pH of the treated limb. Ten years later, Stehlin and coworkers added the effects of hyperthermia to the treatment protocol, now called hyperthermic isolated limb perfusion (HILP), enhancing the cytotoxicity of the chemotherapy and increasing efficacy [58]. The technical aspects of HILP vary somewhat among surgeons and institutions, but the basic technique is similar.

The procedure is performed under general anesthesia, and the vasculature supplying the affected limb is exposed and cannulated. During this exposure, one typically performs a regional lymphadenectomy, which aids vascular exposure (particularly in the case of the iliac vessels) and is often indicated from an oncologic standpoint. The target limb is isolated from the systemic circulation using a proximal tourniquet. Perfusion is then initiated via the cannulated vessels, utilizing a membrane oxygenator and cardiopulmonary bypass apparatus



to maintain limb oxygen tension and pH at physiologic levels. The perfusion treatment is generally continued for 60 to 90 minutes, depending on the protocol. External warming blankets and heated melphalan perfusate are used to achieve hyperthermia. During HILP, it is important to monitor for leakage of the perfusate into the systemic circulation, particularly when high dose TNF-alpha is employed, as systemic leakage can lead to significant morbidity or mortality. Traditionally this monitoring was performed using intravenous fluorescein and watching for staining proximal to the tourniquet. A more precise method involves the administration of radiolabeled tracer into the HILP circuit, followed by continuously monitored systemic radiation exposure using a gamma probe placed over the chest. After completion of chemotherapy perfusion, a 30-minute washout period with crystalloids follows to remove the active agents.



**Figure 2.** Hyperthermic isolated limb perfusion. Surgical exposure of the proximal vasculature is followed by cannulation and circulation of chemotherapy perfusate. Acid-base status and oxygenation is maintained throughout the procedure. Reproduced with permission.

Results of HILP vary widely, perhaps depending on the patient population and adjunctive agents employed. In single-center studies, overall response rates of 81-100% and complete

response rates of 39-82% [46, 48, 59-62] have been reported. However, the previously mentioned multi-center ACOSOG Z0020 study demonstrated complete response rates of only 25%, significantly lower than what had been previously reported [55]. Overall, recurrence rates are 50-60% within one year, and overall 5-year survival rates remain in the 30-40% range [63]. As such, while HILP may be the best treatment option for suitable patients with in-transit extremity melanoma, there remains significant room for therapeutic improvement.

Study (year) [ref]	Patients (n)	CR (%)	PR (%)	OR (%)
Minor (1985) [60]	18	82	18	100
Storm (1985) [62]	26	50	31	81
Di Filippo (1989) [59]	69	39	43	82
Cornett (2006) [55]	58	25	39	64
Sanki (2007) [48]	120	69	15	84
Raymond (2011) [61]	62	55	26	81

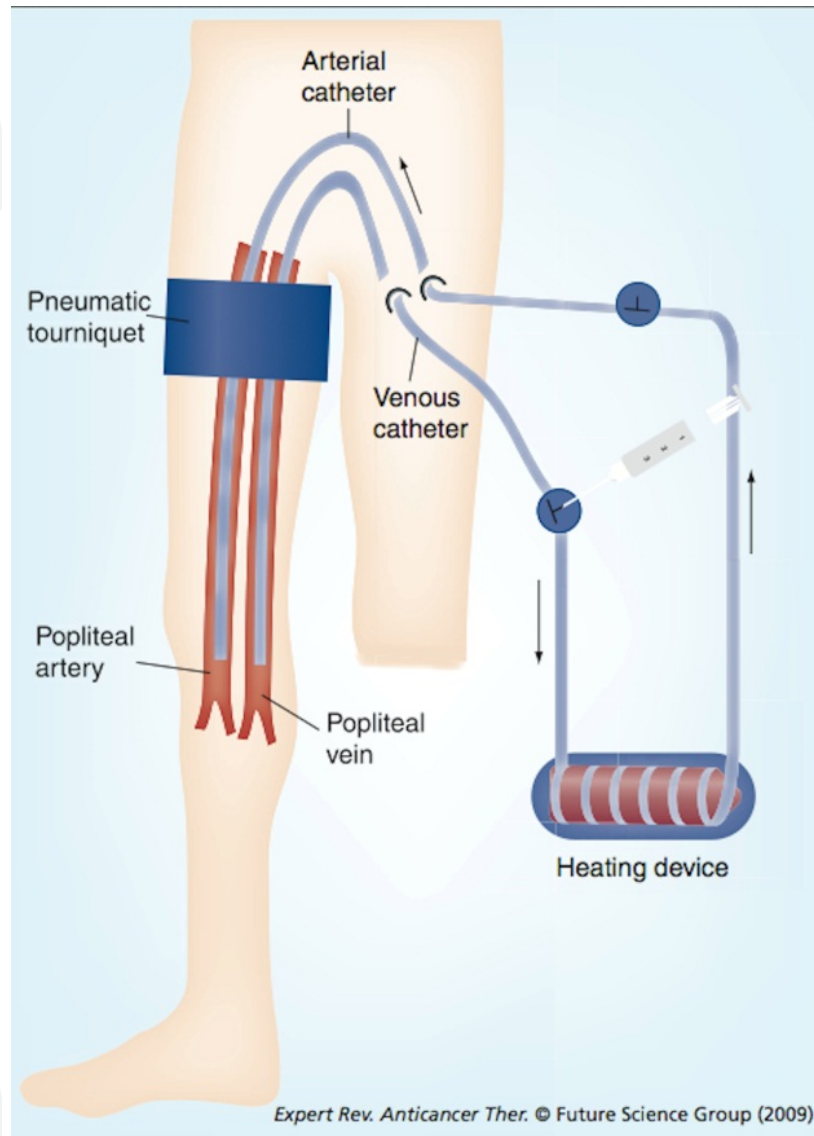
**Table 3.** Response rates following HILP in patients with in-transit melanoma. Adapted with permission from Coleman et al., Expert Rev. Anticancer Ther. 2009;9(11):1599-1602. CR: Complete response; PR: Partial response; OR: Overall response.

#### 4.6. Isolated limb infusion

Isolated limb infusion (ILI) was developed by Thompson and coworkers at the Sydney Melanoma Unit as a less invasive alternative to HILP. This technique employs percutaneous catheters inserted under fluoroscopic guidance as a means to cannulate the target limb vessels. An external tourniquet is used to isolate the limb, which is then wrapped in heating blankets. The key difference with ILI as compared to HILP is the lack of a perfusion pump and membrane oxygenator. The melphalan solution is instead manually circulated via the arterial catheter using a syringe and three-way stopcock. Consequently, during ILI the limb is not maintained at normal pH and oxygen tension, and becomes markedly hypoxic and acidotic during the course of the procedure. Some authors propose that the acidosis and hypoxia may serve to augment melphalan action [64]. In addition, while external and internal warming are performed in ILI, limb temperatures achieved with ILI are lower than those in HILP and generally do not exceed 38.5 degrees centigrade [65, 66].

From a technical standpoint, ILI is appreciably simpler and easier to perform and learn. The infusion treatment is continued for about 30 minutes, followed by a similar washout period with crystalloid. Lower doses of melphalan are typically used, often in combination with dactinomycin, and regional morbidity is reduced, particularly with respect to incidence of severe toxicity. In light of these factors, ILI is generally well tolerated, and is often offered to frail patients with multiple comorbidities who would not tolerate the longer and more invasive groin exposure required for HILP. Along similar lines, due to its simplicity and lower morbidity, ILI can be safely offered as a repeat procedure. Although theoretically attractive as a means of obtaining fractionated regional chemotherapy, elec-

tive repeat ILI has not been shown to improve survival compared to single ILI [67]. However, repeat ILI can be very valuable in the management of recurrent or progressive in-transit disease after primary regional therapy.



**Figure 3.** Isolated limb infusion. Catheters are placed percutaneously, and chemotherapy is circulated by hand without active oxygenation, leading to profound hypoxia and acidosis.

Outcomes after ILI are generally inferior to HILP, with complete response ranging from 23-44% and overall response ranging from 43-100% [47, 61, 65, 66, 68-70]. In one of the largest studies explicitly comparing patterns of recurrence, ILI was found to have both significantly higher probability of recurrence (85% vs. 65%) and shorter time to first recurrence (8 months vs. 23 months) as compared to HILP [71]. Notably, there was no statistically significant difference in overall survival between the two groups, although there was a trend in favor of HILP.

Study (year) [ref]	Patients (n)	CR (%)	PR (%)	OR (%)
Mian (2001) [70]	9	44	56	100
Lindner (2002) [66]	128	41	44	85
Brady (2006) [69]	22	23	27	50
Kroon (2008) [47]	185	38	46	84
Beasley (2009) [68]	128	31	33	64
Raymond (2011) [61]	126	30	13	43

**Table 4.** Response rates following ILI in patients with in-transit melanoma. Adapted with permission from Coleman et al., *Expert Rev. Anticancer Ther.* 2009;9(11):1599-1602. CR: Complete response; PR: Partial response; OR: Overall response.

#### 4.7. Post-treatment complications

As a result of the high concentration of chemotherapies administered in regional therapy, some degree of tissue toxicity is often seen. Multiple grading systems have been developed to score regional toxicity after treatment, with one of the most prominent being that developed by Wieberdink and colleagues. In this system scores range from Grade I, or no evidence of significant reaction, to Grade V, representing reaction severe enough to warrant possible amputation [72]. Up to 85% of patients will exhibit Grade I or II level of toxicity, but as a result of careful drug dosing based on limb volume rather than total body weight, fortunately overall less than 1% of patients develop Grade V toxicity [73]. While the spectrum of toxicity is similar between patients undergoing ILI and HILP, the risk of significant toxicity is greater among those undergoing HILP. Furthermore, HILP carries a higher risk of limb loss from amputation as compared to ILI. Regardless of modality, most adverse reactions are transient, with almost all patients demonstrating some skin erythema and edema that peaks in the first month post-operatively. Rare but more serious complications include severe muscle toxicity and the development of compartment syndrome, necessitating fasciotomy.

#### 4.8. Amputation

Amputation is almost never indicated in the standard treatment of in-transit melanoma. As mentioned previously, historical treatment of in-transit disease by means of limb amputation has led to long-term survival rates of 20-30 percent, which would suggest that a significant minority of patients with locoregional disease have recurrence that is in fact confined entirely to the affected extremity. Recent advancements in aggressive local management, regional therapy and systemic treatment have rendered extremity amputation obsolete except for the most intractable disease, particularly in light of comparable five-year survival rates among patients undergoing these therapies. Thus, amputation should generally only be offered with palliative intent or in patients who refuse or are not candidates for regional chemotherapy or other less morbid therapies [22, 26].

#### 4.9. Systemic treatment

While a comprehensive discussion regarding systemic therapy for the treatment of melanoma is beyond the scope of this chapter, when appropriate this modality should be considered in the management of in-transit disease. Systemic therapy is typically applied in cases of in-transit disease in the presence of distant metastases – that is, stage IV disease [74]. Similarly, patients with non-extremity in-transit metastases – such as in-transit disease involving the head and neck, truncal or genitalia – present a difficult management problem and are often palliated best with systemic treatment options. Systemic therapy should also be considered for in-transit metastases in patients with recurrent or progressive disease who are not candidates for repeat local or regional therapy. Unfortunately, systemic therapy for the treatment of patients with advanced melanoma has historically been quite poor. A large meta-analysis of 42 trials of systemic treatments demonstrating a median progression free survival of 1.7 months with only 14.5% of patients being progression-free at 6 months [75]. Despite this poor track record, newer approaches to systemic treatment of regional disease may hold promise, including vascular regulating agents, signal targeting therapies and immune modulation therapy.

Current strategies have focused on attempting to increase tumor sensitivity to chemotherapeutics, improve local drug delivery, or target apoptotic pathways in an attempt to augment response to regional therapy. The BRAF enzyme inhibitor vemurafenib, as well as the immune modulating anti-CTLA-4 antibody ipilimumab, have recently shown promise in phase III trials, although neither is likely to provide durable disease-free survival [76, 77]. Another newer agent is bevacizumab, a monoclonal antibody to vascular endothelial growth factor (VEGF), which is believed to normalize immature and shunt-dominated tumor vasculature, leading to improved delivery of chemotherapeutics to tumor cells. A recent preclinical animal study demonstrated that systemic treatment with bevacizumab prior to regional therapy increased delivery of melphalan to the tumors of interest [78]. Another vascular targeting agent of recent interest is ADH-1, a pentapeptide that targets and disrupts N-cadherin adhesion complexes, which are predominantly expressed by melanocytes after malignant transition into melanoma [79, 80]. ADH-1 is believed to increase blood vessel permeability, increasing chemotherapy drug delivery [81]. A recent phase II clinical trial studying pre-treatment systemic ADH-1 administration prior to ILI with melphalan demonstrated a reassuring complete response rate of 38% and an overall response rate of 60%, although no significant progression free survival was appreciated [82]. The role of all of these agents as systemic adjuncts to regional chemotherapy remains to be seen, and is being defined in ongoing trials.

### 5. Conclusions

In-transit melanoma is a distinctive form of tumor recurrence, and is an indicator of late-stage disease. It is very distressing to patients, often requiring multiple treatments, proce-



dures and hospitalizations. As such, management of this disease can be challenging and frustrating to clinicians as well. Similar to systemic melanoma, in-transit disease is notoriously resistant to chemotherapy, and treatment outcomes remain unsatisfactorily poor. Local therapies often tout impressive initial response rates, but are plagued by recurrence. Over the past half-century, advances have been made in regional approaches to chemotherapy, including isolated limb perfusion and isolated limb infusion. While some of these methods have demonstrated limited success, significant improvements in patient outcomes will require further advances in both regional and systemic treatment of melanoma.

## Author details

Paul J. Speicher, Douglas S. Tyler and Paul J. Mosca

Division of Surgical Oncology, Department of Surgery, Duke University Medical Center, Durham, USA

## References

- [1] Pawlik TM, Ross MI, Johnson MM, Schacherer CW, McClain DM, Mansfield PF, et al. Predictors and natural history of in-transit melanoma after sentinel lymphadenectomy. *Annals of surgical oncology*. 2005;12(8):587-96. Epub 2005/07/16.
- [2] Meier F, Will S, Ellwanger U, Schlagenhauff B, Schitteck B, Rassner G, et al. Metastatic pathways and time courses in the orderly progression of cutaneous melanoma. *The British journal of dermatology*. 2002;147(1):62-70. Epub 2002/07/09.
- [3] Singletary SE, Tucker SL, Boddie AW, Jr. Multivariate analysis of prognostic factors in regional cutaneous metastases of extremity melanoma. *Cancer*. 1988;61(7):1437-40. Epub 1988/04/01.
- [4] Karakousis CP, Temple DF, Moore R, Ambrus JL. Prognostic parameters in recurrent malignant melanoma. *Cancer*. 1983;52(3):575-9. Epub 1983/08/01.
- [5] Roses DF, Karp NS, Oratz R, Dubin N, Harris MN, Speyer J, et al. Survival with regional and distant metastases from cutaneous malignant melanoma. *Surgery, gynecology & obstetrics*. 1991;172(4):262-8. Epub 1991/04/01.
- [6] Haffner AC, Garbe C, Burg G, Buttner P, Orfanos CE, Rassner G. The prognosis of primary and metastasising melanoma. An evaluation of the TNM classification in 2,495 patients. *British journal of cancer*. 1992;66(5):856-61. Epub 1992/11/01.
- [7] Balch CM, Gershenwald JE, Soong SJ, Thompson JF, Atkins MB, Byrd DR, et al. Final version of 2009 AJCC melanoma staging and classification. *Journal of clinical oncology*.

- gy : official journal of the American Society of Clinical Oncology. 2009;27(36):6199-206. Epub 2009/11/18.
- [8] Brown CD, Zitelli JA. The prognosis and treatment of true local cutaneous recurrent malignant melanoma. *Dermatologic surgery : official publication for American Society for Dermatologic Surgery [et al]*. 1995;21(4):285-90. Epub 1995/04/01.
  - [9] Lee YT. Loco-regional recurrent melanoma: I natural history. *Cancer treatment reviews*. 1980;7(2):59-72. Epub 1980/06/01.
  - [10] Wong JH, Cagle LA, Kopald KH, Swisher SG, Morton DL. Natural history and selective management of in transit melanoma. *Journal of surgical oncology*. 1990;44(3):146-50. Epub 1990/07/01.
  - [11] Roses DF, Harris MN, Rigel D, Carrey Z, Friedman R, Kopf AW. Local and in-transit metastases following definitive excision for primary cutaneous malignant melanoma. *Annals of surgery*. 1983;198(1):65-9. Epub 1983/07/01.
  - [12] Cascinelli N, Bufalino R, Marolda R, Belli F, Nava M, Galluzzo D, et al. Regional non-nodal metastases of cutaneous melanoma. *European journal of surgical oncology : the journal of the European Society of Surgical Oncology and the British Association of Surgical Oncology*. 1986;12(2):175-80. Epub 1986/06/01.
  - [13] McCarthy WH, Shaw HM, Thompson JF, Milton GW. Time and frequency of recurrence of cutaneous stage I malignant melanoma with guidelines for follow-up study. *Surgery, gynecology & obstetrics*. 1988;166(6):497-502. Epub 1988/06/01.
  - [14] Soong SJ, Harrison RA, McCarthy WH, Urist MM, Balch CM. Factors affecting survival following local, regional, or distant recurrence from localized melanoma. *Journal of surgical oncology*. 1998;67(4):228-33. Epub 1998/05/14.
  - [15] Karakousis CP, Balch CM, Urist MM, Ross MM, Smith TJ, Bartolucci AA. Local recurrence in malignant melanoma: long-term results of the multiinstitutional randomized surgical trial. *Annals of surgical oncology*. 1996;3(5):446-52. Epub 1996/09/01.
  - [16] Kang JC, Wanek LA, Essner R, Faries MB, Foshag LJ, Morton DL. Sentinel lymphadenectomy does not increase the incidence of in-transit metastases in primary melanoma. *Journal of clinical oncology : official journal of the American Society of Clinical Oncology*. 2005;23(21):4764-70. Epub 2005/07/22.
  - [17] Morton DL, Thompson JF, Cochran AJ, Mozzillo N, Elashoff R, Essner R, et al. Sentinel-node biopsy or nodal observation in melanoma. *The New England journal of medicine*. 2006;355(13):1307-17. Epub 2006/09/29.
  - [18] Pawlik TM, Ross MI, Thompson JF, Eggermont AM, Gershenwald JE. The risk of in-transit melanoma metastasis depends on tumor biology and not the surgical approach to regional lymph nodes. *Journal of clinical oncology : official journal of the American Society of Clinical Oncology*. 2005;23(21):4588-90. Epub 2005/07/22.
  - [19] van Poll D, Thompson JF, Colman MH, McKinnon JG, Saw RP, Stretch JR, et al. A sentinel node biopsy does not increase the incidence of in-transit metastasis in pa-

tients with primary cutaneous melanoma. *Annals of surgical oncology*. 2005;12(8): 597-608. Epub 2005/07/16.

- [20] Calabro A, Singletary SE, Balch CM. Patterns of relapse in 1001 consecutive patients with melanoma nodal metastases. *Archives of surgery (Chicago, Ill : 1960)*. 1989;124(9):1051-5. Epub 1989/09/01.
- [21] Zogakis TG, Bartlett DL, Libutti SK, Liewehr DJ, Steinberg SM, Fraker DL, et al. Factors affecting survival after complete response to isolated limb perfusion in patients with in-transit melanoma. *Annals of surgical oncology*. 2001;8(10):771-8. Epub 2002/01/05.
- [22] Jaques DP, Coit DG, Brennan MF. Major amputation for advanced malignant melanoma. *Surgery, gynecology & obstetrics*. 1989;169(1):1-6. Epub 1989/07/01.
- [23] Karakousis CP, Choe KJ, Holyoke ED. Biologic behavior and treatment of intransit metastasis of melanoma. *Surgery, gynecology & obstetrics*. 1980;150(1):29-32. Epub 1980/01/01.
- [24] McPeak CJ, McNeer GP, Whiteley HW, Booher RJ. Amputation for Melanoma of the Extremity. *Surgery*. 1963;54:426-31. Epub 1963/09/01.
- [25] Pack GT, Gerber DM, Scharnagel IM. End results in the treatment of malignant melanoma; a report of 1190 cases. *Annals of surgery*. 1952;136(6):905-11. Epub 1952/12/01.
- [26] Turnbull A, Shah J, Fortner J. Recurrent melanoma of an extremity treated by major amputation. *Archives of surgery (Chicago, Ill : 1960)*. 1973;106(4):496-8. Epub 1973/04/01.
- [27] Griffiths RW, Briggs JC. Incidence of locally metastatic ('recurrent') cutaneous malignant melanoma following conventional wide margin excisional surgery for invasive clinical stage I tumours: importance of maximal primary tumour thickness. *The British journal of surgery*. 1986;73(5):349-53. Epub 1986/05/01.
- [28] Heenan PJ, Ghaznawie M. The pathogenesis of local recurrence of melanoma at the primary excision site. *British journal of plastic surgery*. 1999;52(3):209-13. Epub 1999/09/04.
- [29] Kaplan I, Ger R, Sharon U. The carbon dioxide laser in plastic surgery. *British journal of plastic surgery*. 1973;26(4):359-62. Epub 1973/10/01.
- [30] Strobbe LJ, Nieweg OE, Kroon BB. Carbon dioxide laser for cutaneous melanoma metastases: indications and limitations. *European journal of surgical oncology : the journal of the European Society of Surgical Oncology and the British Association of Surgical Oncology*. 1997;23(5):435-8. Epub 1997/12/11.
- [31] Green DS, Bodman-Smith MD, Dalglish AG, Fischer MD. Phase I/II study of topical imiquimod and intralesional interleukin-2 in the treatment of accessible metastases in malignant melanoma. *The British journal of dermatology*. 2007;156(2):337-45. Epub 2007/01/17.

- [32] Radny P, Caroli UM, Bauer J, Paul T, Schlegel C, Eigentler TK, et al. Phase II trial of intralesional therapy with interleukin-2 in soft-tissue melanoma metastases. *British journal of cancer*. 2003;89(9):1620-6. Epub 2003/10/30.
- [33] von Wussow P, Block B, Hartmann F, Deicher H. Intralesional interferon-alpha therapy in advanced malignant melanoma. *Cancer*. 1988;61(6):1071-4. Epub 1988/03/15.
- [34] Testori A, Faries MB, Thompson JF, Pennacchioli E, Deroose JP, van Geel AN, et al. Local and intralesional therapy of in-transit melanoma metastases. *Journal of surgical oncology*. 2011;104(4):391-6. Epub 2011/08/23.
- [35] Glass LF, Pepine ML, Fenske NA, Jaroszeski M, Reintgen DS, Heller R. Bleomycin-mediated electrochemotherapy of metastatic melanoma. *Archives of dermatology*. 1996;132(11):1353-7. Epub 1996/11/01.
- [36] Heller R, Jaroszeski MJ, Reintgen DS, Puleo CA, DeConti RC, Gilbert RA, et al. Treatment of cutaneous and subcutaneous tumors with electrochemotherapy using intralesional bleomycin. *Cancer*. 1998;83(1):148-57. Epub 1998/07/09.
- [37] Mir LM, Glass LF, Sersa G, Teissie J, Domenge C, Miklavcic D, et al. Effective treatment of cutaneous and subcutaneous malignant tumours by electrochemotherapy. *British journal of cancer*. 1998;77(12):2336-42. Epub 1998/07/02.
- [38] Adair FE. Treatment of melanoma: report of four hundred cases. *Surgery, gynecology & obstetrics*. 1936;62:406-8.
- [39] Barranco SC, Romsdahl MM, Humphrey RM. The radiation response of human malignant melanoma cells grown in vitro. *Cancer research*. 1971;31(6):830-3. Epub 1971/06/01.
- [40] Overgaard J, Gonzalez Gonzalez D, Hulshof MC, Arcangeli G, Dahl O, Mella O, et al. Hyperthermia as an adjuvant to radiation therapy of recurrent or metastatic malignant melanoma. A multicentre randomized trial by the European Society for Hyperthermic Oncology. *International journal of hyperthermia : the official journal of European Society for Hyperthermic Oncology, North American Hyperthermia Group*. 1996;12(1):3-20. Epub 1996/01/01.
- [41] Burmeister BH, Henderson MA, Ainslie J, Fisher R, Di Iulio J, Smithers BM, et al. Adjuvant radiotherapy versus observation alone for patients at risk of lymph-node field relapse after therapeutic lymphadenectomy for melanoma: a randomised trial. *The lancet oncology*. 2012;13(6):589-97. Epub 2012/05/12.
- [42] Corry J, Smith JG, Bishop M, Ainslie J. Nodal radiation therapy for metastatic melanoma. *International journal of radiation oncology, biology, physics*. 1999;44(5):1065-9. Epub 1999/07/27.
- [43] Ballo MT, Bonnen MD, Garden AS, Myers JN, Gershenwald JE, Zagars GK, et al. Adjuvant irradiation for cervical lymph node metastases from melanoma. *Cancer*. 2003;97(7):1789-96. Epub 2003/03/26.

- [44] O'Brien CJ, Petersen-Schaefer K, Stevens GN, Bass PC, Tew P, Gebiski VJ, et al. Adjuvant radiotherapy following neck dissection and parotidectomy for metastatic malignant melanoma. *Head & neck*. 1997;19(7):589-94. Epub 1997/10/10.
- [45] Stevens G, Thompson JF, Firth I, O'Brien CJ, McCarthy WH, Quinn MJ. Locally advanced melanoma: results of postoperative hypofractionated radiation therapy. *Cancer*. 2000;88(1):88-94. Epub 2000/01/05.
- [46] Aloia TA, Grubbs E, Onaitis M, Mosca PJ, Cheng TY, Seigler H, et al. Predictors of outcome after hyperthermic isolated limb perfusion: role of tumor response. *Archives of surgery (Chicago, Ill : 1960)*. 2005;140(11):1115-20. Epub 2005/11/23.
- [47] Kroon HM, Moncrieff M, Kam PC, Thompson JF. Outcomes following isolated limb infusion for melanoma. A 14-year experience. *Annals of surgical oncology*. 2008;15(11):3003-13. Epub 2008/05/30.
- [48] Sanki A, Kam PC, Thompson JF. Long-term results of hyperthermic, isolated limb perfusion for melanoma: a reflection of tumor biology. *Annals of surgery*. 2007;245(4):591-6. Epub 2007/04/07.
- [49] Wile AG, Guilmette E, Friedberg H, Mason GR. A model of experimental isolation perfusion using cis-platinum. *Journal of surgical oncology*. 1982;21(1):37-41. Epub 1982/09/01.
- [50] Aigner K, Hild P, Henneking K, Paul E, Hundeiker M. Regional perfusion with cis-platinum and dacarbazine. Recent results in cancer research *Fortschritte der Krebsforschung Progres dans les recherches sur le cancer*. 1983;86:239-45. Epub 1983/01/01.
- [51] Roseman JM. Effective management of extremity cancers using cisplatin and etoposide in isolated limb perfusions. *Journal of surgical oncology*. 1987;35(3):170-2. Epub 1987/07/01.
- [52] Santinami M, Belli F, Cascinelli N, Rovini D, Vaglini M. Seven years experience with hyperthermic perfusions in extracorporeal circulation for melanoma of the extremities. *Journal of surgical oncology*. 1989;42(3):201-8. Epub 1989/11/01.
- [53] Thompson JF, Gianoutsos MP. Isolated limb perfusion for melanoma: effectiveness and toxicity of cisplatin compared with that of melphalan and other drugs. *World journal of surgery*. 1992;16(2):227-33. Epub 1992/03/01.
- [54] Fraker DL, Alexander HR, Andrich M, Rosenberg SA. Treatment of patients with melanoma of the extremity using hyperthermic isolated limb perfusion with melphalan, tumor necrosis factor, and interferon gamma: results of a tumor necrosis factor dose-escalation study. *Journal of clinical oncology : official journal of the American Society of Clinical Oncology*. 1996;14(2):479-89. Epub 1996/02/01.
- [55] Cornett WR, McCall LM, Petersen RP, Ross MI, Briele HA, Noyes RD, et al. Randomized multicenter trial of hyperthermic isolated limb perfusion with melphalan alone compared with melphalan plus tumor necrosis factor: American College of Surgeons



- Oncology Group Trial Z0020. *Journal of clinical oncology* : official journal of the American Society of Clinical Oncology. 2006;24(25):4196-201. Epub 2006/09/01.
- [56] Ueno T, Ko SH, Grubbs E, Yoshimoto Y, Augustine C, Abdel-Wahab Z, et al. Modulation of chemotherapy resistance in regional therapy: a novel therapeutic approach to advanced extremity melanoma using intra-arterial temozolomide in combination with systemic O6-benzylguanine. *Molecular cancer therapeutics*. 2006;5(3):732-8. Epub 2006/03/21.
  - [57] Creech O, Jr., Krementz ET, Ryan RF, Winblad JN. Chemotherapy of cancer: regional perfusion utilizing an extracorporeal circuit. *Annals of surgery*. 1958;148(4):616-32. Epub 1958/10/01.
  - [58] Stehlin JS, Jr. Hyperthermic perfusion with chemotherapy for cancers of the extremities. *Surgery, gynecology & obstetrics*. 1969;129(2):305-8. Epub 1969/08/01.
  - [59] Di Filippo F, Calabro A, Giannarelli D, Carlini S, Cavaliere F, Moscarelli F, et al. Prognostic variables in recurrent limb melanoma treated with hyperthermic antitlastic perfusion. *Cancer*. 1989;63(12):2551-61. Epub 1989/06/15.
  - [60] Minor DR, Allen RE, Alberts D, Peng YM, Tardelli G, Hutchinson J. A clinical and pharmacokinetic study of isolated limb perfusion with heat and melphalan for melanoma. *Cancer*. 1985;55(11):2638-44. Epub 1985/06/01.
  - [61] Raymond AK, Beasley GM, Broadwater G, Augustine CK, Padussis JC, Turley R, et al. Current trends in regional therapy for melanoma: lessons learned from 225 regional chemotherapy treatments between 1995 and 2010 at a single institution. *Journal of the American College of Surgeons*. 2011;213(2):306-16. Epub 2011/04/16.
  - [62] Storm FK, Morton DL. Value of therapeutic hyperthermic limb perfusion in advanced recurrent melanoma of the lower extremity. *American journal of surgery*. 1985;150(1):32-5. Epub 1985/07/01.
  - [63] Grunhagen DJ, Brunstein F, Graveland WJ, van Geel AN, de Wilt JH, Eggermont AM. One hundred consecutive isolated limb perfusions with TNF-alpha and melphalan in melanoma patients with multiple in-transit metastases. *Annals of surgery*. 2004;240(6):939-47; discussion 47-8. Epub 2004/12/01.
  - [64] Siemann DW, Chapman M, Beikirch A. Effects of oxygenation and pH on tumor cell response to alkylating chemotherapy. *International journal of radiation oncology, biology, physics*. 1991;20(2):287-9. Epub 1991/02/01.
  - [65] Beasley GM, Petersen RP, Yoo J, McMahon N, Aloia T, Petros W, et al. Isolated limb infusion for in-transit malignant melanoma of the extremity: a well-tolerated but less effective alternative to hyperthermic isolated limb perfusion. *Annals of surgical oncology*. 2008;15(8):2195-205. Epub 2008/06/06.
  - [66] Lindner P, Doubrovsky A, Kam PC, Thompson JF. Prognostic factors after isolated limb infusion with cytotoxic agents for melanoma. *Annals of surgical oncology*. 2002;9(2):127-36. Epub 2002/03/13.

- [67] Lindner P, Thompson JF, De Wilt JH, Colman M, Kam PC. Double isolated limb infusion with cytotoxic agents for recurrent and metastatic limb melanoma. *European journal of surgical oncology : the journal of the European Society of Surgical Oncology and the British Association of Surgical Oncology*. 2004;30(4):433-9. Epub 2004/04/06.
- [68] Beasley GM, Caudle A, Petersen RP, McMahon NS, Padussis J, Mosca PJ, et al. A multi-institutional experience of isolated limb infusion: defining response and toxicity in the US. *Journal of the American College of Surgeons*. 2009;208(5):706-15; discussion 15-7. Epub 2009/05/30.
- [69] Brady MS, Brown K, Patel A, Fisher C, Marx W. A phase II trial of isolated limb infusion with melphalan and dactinomycin for regional melanoma and soft tissue sarcoma of the extremity. *Annals of surgical oncology*. 2006;13(8):1123-9. Epub 2006/06/23.
- [70] Mian R, Henderson MA, Speakman D, Finkelde D, Ainslie J, McKenzie A. Isolated limb infusion for melanoma: a simple alternative to isolated limb perfusion. *Can J Surg*. 2001;44(3):189-92. Epub 2001/06/16.
- [71] Sharma K, Beasley G, Turley R, Raymond AK, Broadwater G, Peterson B, et al. Patterns of Recurrence Following Complete Response to Regional Chemotherapy for In-Transit Melanoma. *Annals of surgical oncology*. 2012. Epub 2012/04/06.
- [72] Wieberdink J, Benckhuysen C, Braat RP, van Slooten EA, Olthuis GA. Dosimetry in isolation perfusion of the limbs by assessment of perfused tissue volume and grading of toxic tissue reactions. *European journal of cancer & clinical oncology*. 1982;18(10):905-10. Epub 1982/10/01.
- [73] Klaase JM, Kroon BB, van Geel BN, Eggermont AM, Franklin HR, Hart GA. Patient- and treatment-related factors associated with acute regional toxicity after isolated perfusion for melanoma of the extremities. *American journal of surgery*. 1994;167(6):618-20. Epub 1994/06/01.
- [74] Li Y, McClay EF. Systemic chemotherapy for the treatment of metastatic melanoma. *Seminars in oncology*. 2002;29(5):413-26. Epub 2002/10/31.
- [75] Korn EL, Liu PY, Lee SJ, Chapman JA, Niedzwiecki D, Suman VJ, et al. Meta-analysis of phase II cooperative group trials in metastatic stage IV melanoma to determine progression-free and overall survival benchmarks for future phase II trials. *Journal of clinical oncology : official journal of the American Society of Clinical Oncology*. 2008;26(4):527-34. Epub 2008/02/01.
- [76] Hodi FS, O'Day SJ, McDermott DF, Weber RW, Sosman JA, Haanen JB, et al. Improved survival with ipilimumab in patients with metastatic melanoma. *The New England journal of medicine*. 2010;363(8):711-23. Epub 2010/06/08.
- [77] Sosman JA, Kim KB, Schuchter L, Gonzalez R, Pavlick AC, Weber JS, et al. Survival in BRAF V600-mutant advanced melanoma treated with vemurafenib. *The New England journal of medicine*. 2012;366(8):707-14. Epub 2012/02/24.

- [78] Turley RS, Fontanella AN, Padussis JC, Toshimitsu H, Tokuhisa Y, Cho EH, et al. Bevacizumab-induced alterations in vascular permeability and drug delivery: a novel approach to augment regional chemotherapy for in-transit melanoma. *Clinical cancer research : an official journal of the American Association for Cancer Research*. 2012;18(12):3328-39. Epub 2012/04/13.
- [79] Qi J, Chen N, Wang J, Siu CH. Transendothelial migration of melanoma cells involves N-cadherin-mediated adhesion and activation of the beta-catenin signaling pathway. *Molecular biology of the cell*. 2005;16(9):4386-97. Epub 2005/07/01.
- [80] Hsu MY, Meier FE, Nesbit M, Hsu JY, Van Belle P, Elder DE, et al. E-cadherin expression in melanoma cells restores keratinocyte-mediated growth control and down-regulates expression of invasion-related adhesion receptors. *The American journal of pathology*. 2000;156(5):1515-25. Epub 2000/05/04.
- [81] Augustine CK, Yoshimoto Y, Gupta M, Zipfel PA, Selim MA, Febbo P, et al. Targeting N-cadherin enhances antitumor activity of cytotoxic therapies in melanoma treatment. *Cancer research*. 2008;68(10):3777-84. Epub 2008/05/17.
- [82] Beasley GM, Riboh JC, Augustine CK, Zager JS, Hochwald SN, Grobmyer SR, et al. Prospective multicenter phase II trial of systemic ADH-1 in combination with melphalan via isolated limb infusion in patients with advanced extremity melanoma. *Journal of clinical oncology : official journal of the American Society of Clinical Oncology*. 2011;29(9):1210-5. Epub 2011/02/24.