We are IntechOpen, the world's leading publisher of Open Access books Built by scientists, for scientists

6,900
Open access books available

185,000
International authors and editors

200M
Downloads

Our authors are among the

154
Countries delivered to

TOP 1%
most cited scientists

12.2%
Contributors from top 500 universities

WEB OF SCIENCE™

Selection of our books indexed in the Book Citation Index in Web of Science™ Core Collection (BKCI)

Interested in publishing with us?
Contact book.department@intechopen.com

Numbers displayed above are based on latest data collected.
For more information visit www.intechopen.com

Chapter 4

Placenta in Preterm Birth

Erdener Ozer

Additional information is available at the end of the chapter

http://dx.doi.org/10.5772/54887

1. Introduction

This chapter provides an understanding of specific patterns of placental pathology and their associations with the various phenotypes and underlying mechanisms of preterm birth.

To the perinatal pathologists, preterm births are those occurring at less than 37 weeks of gestation. In almost all countries with reliable data, preterm birth rates have increased worldwide. The complications of preterm birth due to prematurity are often serious community health problems and account for 75% of perinatal mortalities and more than 50% of long-term infant morbidities [1]. Globally, prematurity is the leading cause of newborn deaths and now the second leading cause of death after pneumonia in children under the age of five [2]. The complications of prematurity include adverse cognitive, organ functional and motor outcomes. Moreover, preterm infants have increased rates chronic lung disease, necrotizing enterocolitis and neurological sequels including periventricular leukomalacia. Later in childhood, they have reduced motor, intellectual and behavioral skills compared to children born at term.

Clinical managements to reduce the incidence of preterm birth have not been yet very successful. They have largely been targeting treatments for individual risk factors and focused on answering clinical questions rather than pathogenic mechanisms such as placental ones. The above facts regarding the clinical importance of preterm birth reveal that the pathologist is and will be increasingly asked to examine placentas from preterm births in order to help explaining the pathogenesis of preterm birth. In addition, the placental examinations from these cases may provide valuable clues for predicting which infants and why some infants may be at relatively greater risk for developing long term complications of preterm births.

The aim of this chapter is to present sufficient pathogenic background concerning what is currently appreciated about the placental pathology in preterm birth in order that the prac-

INTECH
open science | open minds

© 2013 Ozer; licensee InTech. This is an open access article distributed under the terms of the Creative Commons Attribution License (http://creativecommons.org/licenses/by/3.0), which permits unrestricted use, distribution, and reproduction in any medium, provided the original work is properly cited.

ticing perinatologists will be aware of the fact that any infant requiring the care of a neonatologist should have a placental examination.

2. Clinicopathological scenarios

The causes of singleton preterm birth are incompletely understood, and a full discussion of the current clinical literature on this subject is beyond the scope of this chapter. Supporting the fetus through the preceding gestation, the placenta is a very critical organ in explaining the pathogenesis of preterm birth. From this point of view, the placental pathology will be emphasized in two clinical categories of preterm birth: spontaneous preterm birth (SPB) and indicated preterm birth (IPB).

SPB can be classified into two separate clinical scenarios: (i) premature onset of labor (POL) defined as regular contractions with accompanying cervical change and with intact membranes, and accounting for 40–45% of cases of preterm births or (ii) preterm premature rupture of membranes (PPROM) defined as spontaneous rupture of membranes at less than 37 weeks of gestation and at least one hour before the onset of contractions, and seen in 25–30% of preterm births) [1].

IPB is defined when the labor is induced or caesarean section is performed for maternal or fetal reasons. It has a high frequency of associated maternal vascular changes in the placenta, similar to those described for hypertension or diabetes, as well as placental abruptions.

3. Placental pathology in spontaneous preterm birth

The various pathologic reaction patterns in SPB can be grouped in etiological context by determining whether the etiological process is infectious or non-microbial (Table 1). There is a large body of evidence that a cascade of activations of cellular components and mediators of inflammatory pathways result in onset of labor and membrane rupture [3, 4]. POL and PPROM are likely to be the pathological results of abnormal microbial and non-microbial activation of imbalances among these normally orchestrated components and mediators.

POL may result from (i) acute chorioamnionitis, (ii) uteroplacental underperfusion, (iii) uterine fundal and cervical abnormalities or fetal anomalies. However, non-microbial etiologies appear more prevalent. Acute uteroplacental underperfusion may be due to a retroplacental hemorrhage (placental abruption). Chronic uteroplacental underperfusion is seen in maternal chronic hypertension or diabetes.

The placenta in PPROM often shows evidence of ascending infection (amniotic fluid infection sequence) or vasculopathic problems (hemorrhage or thrombi). Amniotic fluid infection has clinical significance for the neonate beyond just causing preterm birth. The fetus may reveal an inflammatory response associated with cytokine release that can cause damage to the

http://dx.doi.org/10.5772/54887

Infectious etiology	Acute inflammatory pathology	1. Acute chorioamnionitis
		- Subacute chorioamnionitis
		2. Acute villitis
	Chronic inflammatory pathology	1. Chronic villitis
		- CMV placentitis
		- Syphilis placentitis
		- HSV placentitis
		2. Idiopathic chronic deciduitis
Non-microbial etiology	1. Retromembranous hemorrhage	
	2. Retroplacental hematoma	
	3. Marginal hematoma	
	4. Uteroplacental underperfusion	

Table 1. Etiopathogenetic correlation of placental pathology in spontaneous preterm birth

developing brain and lungs. This inflammatory response is evident microscopically by neutrophils migrating from the fetal vasculature of the umbilical cord or chorionic plate towards the infected amnionic fluid.

4. Placental pathology of intrauterine infections and inflammatory processes in SPB

Intrauterine infection is clinically a common etiology of SPB following POL and PPROM. It is most prevalent and severe in early preterm infant. Bacterial infection is very common and predisposes to preterm delivery. The most common pathogens include the genital mycoplasmas (especially *Ureaplasma urealyticum*) and *Streptococcus agalactiae*, *Escherichia coli*, *Fusobacterium*, and *Gardnerella vaginalis* [4]. Group B streptococcus, *Staphylococcus*, *Propionibacterium*, *Peptostreptococcus*, *Pseudomonas*, *Proteus* and *Klebsiella* species have also been commonly detected [5]. Although *Candida albicans* is an uncommon pathogen, it has been associated with high rates of morbidity and mortality in earlier cases of preterm birth.

Microbiological studies of amniotic fluid have shown that overall rates of infection in SPB are 25–40%. Approximately 32.5% of women with POL and over 75% with PPROM have positive amniotic fluid cultures. Studies have additionally shown that infection can be confined to the decidua and the rate of chorioamnion colonization is twice that of the amniotic fluid [1]. Although bacterial infection is very common and predisposes to preterm delivery, not all women with positive evidence of bacteria in the chorioamnion have POL or PPROM. In addition, up to 70% of women undergoing elective caesarean section at term have evidence of bacterial invasion and even inflammation [6].

The relative numbers and pathogenicity of the organisms gaining access to the uterine or amniotic fluid cavities, together with the degree of underlying maternal inflammatory response and predisposing genetic, cervical/structural risk factors and/or fetal factors may trigger inflammatory mechanisms involved in normal parturition towards SPB. Based on the observation that 10–15% of placentas at term have histological acute chorioamnionitis, some investigators suggest that chorioamnionitis may develop as a consequence of POL rather than representing a cause of preterm birth [7].

There is a poor correlation between clinically diagnosed chorioamnionitis and the pathological diagnosis of histological acute chorioamnionitis. It can be partly explained by the fact that the clinical definition of chorioamnionitis is non-uniform, and that most cases of histopathological chorioamnionitis represent subclinical infection. Further studies focused on the pathogenetic mechanisms involved in SPB may yield clinicopathological explanations and improved correlations [8].

4.1. Acute chorioamnionitis

Gross examination of the placenta the evidence of chorioamnionitis reveals membranous edema, clouding, or yellowish-green discoloration and congestive placentomegaly. The cord may show punctate yellowish lesions characteristic of candidiasis, although minute whitish lesions may rarely be seen in severe bacterial infections.

The inflammatory response to ascending infection consists of an acute inflammatory neutrophilic infiltrate composed of maternal neutrophils from the intervillous circulation and small venules in the membranous decidua. In many cases this maternal response is supplemented by a fetal response composed of neutrophils emanating from large vessels of the umbilical cord and chorionic plate. Therefore, acute chorioamnionitis should be separated into two components, the maternal and fetal inflammatory responses. Each of these in turn should be characterized in terms of its spatiotemporal progression (stage) and severity (grade) [9].

Maternal inflammatory response begins in the decidua of the external membranes as patchy deciduitis and progresses to margination of neutrophils along the deciduochorionic junction, and additionally infiltration of the subchorionic maternal space. Therefore, the stages of maternal response are;

Stage 1 (early chorioamnionitis or acute subchorionitis): Neutrophils are restricted to subchorionic fibrin and the membranous decidual-chorionic interface.

Stage 2 (acute chorioamnionitis): Neutrophils are located at in chorion and amnion.

Stage 3 (necrotizing chorioamnionitis): There are signs of amnion necrosis including karyorhexis of neutrophils, desquamation of amnionic epithelial cells, and bandlike eosinophilia of the amnionic basement membrane (Figure 1).

Severe maternal inflammatory response responses are characterized by large accumulations of neutrophils (microabcesses) under the chorion. Stage 1 response is generally clinically silent. Stages 2 and 3 are associated with increased risk of neonatal morbidity and mortality. Stage 2 is most common in preterm births, but especially in the earliest periods of gestation [10].

http://dx.doi.org/10.5772/54887

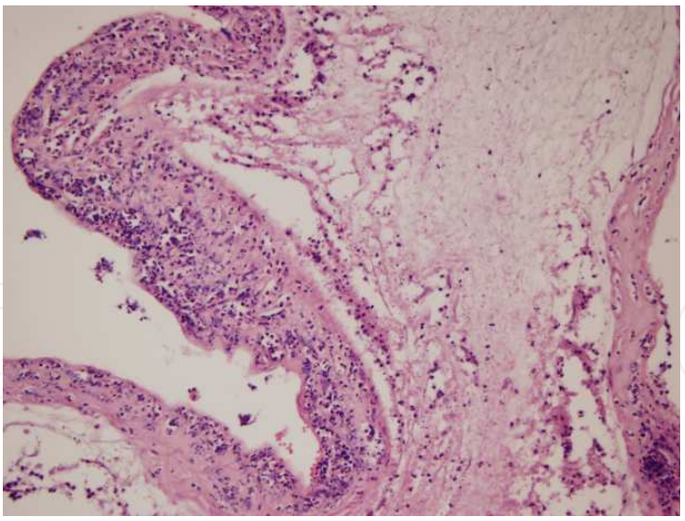

Figure 1. Stage 3 (advanced, late) histological acute chorioamnionitis.

Maternal grade (intensity and distribution of inflammation) 2 of subchorionic neutrophilic aggregation is associated with increased risk of neonatal infection [11].

The fetal inflammatory response to infection is manifested by migration of neutrophils from chorionic plate vessels and from the umbilical cord vessels. Severe fetal responses are characterized by near confluent neutrophilic infiltrates in the amnionic side of chorionic vessels with attenuation and degenerative changes of the vessel wall (Figure 2). The staging of fetal response is;

Stage 1: Neutrophils are located at in chorionic vessels (chorionic vasculitis) and/or umbilical vein (umbilical phlebitis).

Stage 2: There is umbilical arterial infiltration of neutrophils (umbilical arteritis) or trivasculitis (Figure 3).

Stage 3: There are neutrophils and neutrophilic debris forming arcs around umbilical vessels in the Wharton's jelly (necrotizing funisitis).

There are numerous important pathological outcomes associated with fetal inflammatory response stages 2 and 3, and fetal grade 2 (severe), particularly for extremely preterm infants. Fetal grade 2 inflammatory response is characterized by severe inflammation of the cord or chorionic plate vessels and may be accompanied by acute mural non-occlusive thrombosis. Severe fetal response associated with prolonged intrauterine infection may be manifested by necrotizing funisitis revealing mineralization of the inflammatory and debris laden arcs. Fetal stages 2 and 3 generally indicate increasing duration and/or severity of the infection. Fetal grade 2, in particular, is strongly correlated with the presence of high fetal levels of circulating proinflammatory cytokines and inflammatory mediators, such as interleukin-6. This condition is referred to as the fetal inflammatory response syndrome (FIRS). It is currently believed that various aspects of this response including circulating cytokines, bacterial toxins, and activation of the coagulation cascade predispose to cerebral palsy and other forms of adverse neurological

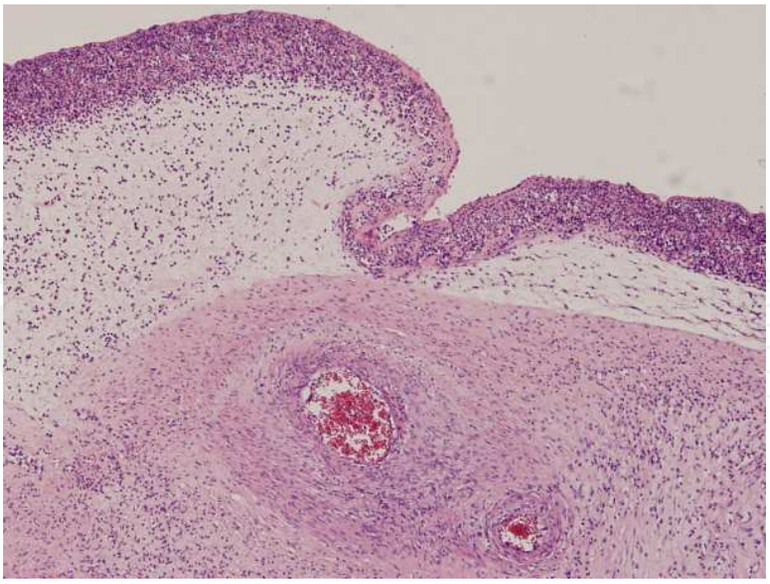

Figure 2. Severe fetal inflammatory response characterized by intense chorionic vasculitis.

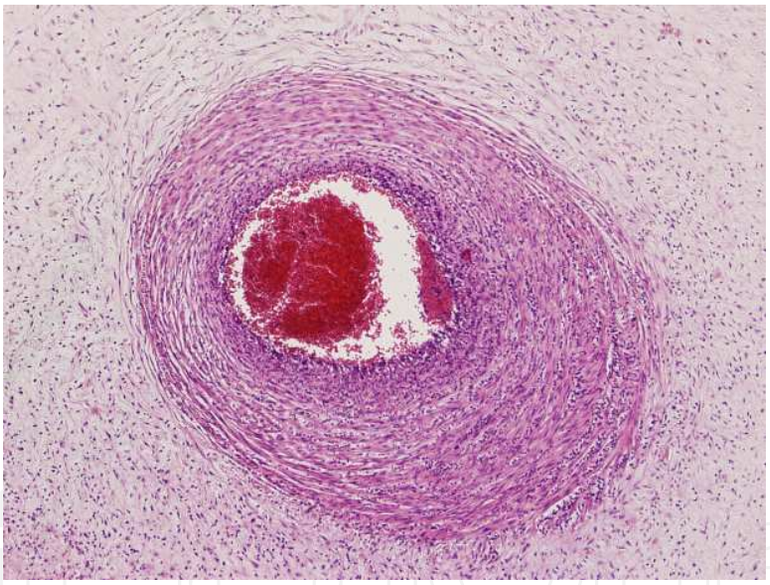

Figure 3. The fetal inflammatory response (stage 2) characterized by funisitis with arteritis.

outcomes, such as periventricular leukomalacia and cerebral palsy. A role for fetal inflammatory response syndrome in the development of chronic lung disease has also been proposed with conflicting evidence.

Chorionic villous edema may also be prominent with fetal grade 2 histopathology. In addition, it has been linked to increased risk in extremely preterm infants, even without intense chorionic vasculitis. The risk is evidenced for cerebral palsy and impaired neurological function when these children reach school age [12]. Thus chorionic villous edemas are potentially an inde-

http://dx.doi.org/10.5772/54887

pendent histopathological feature associated with increased risk for morbidity and mortality in preterm infants.

Certain organisms have been more strongly associated with both intense chorionic plate inflammation and fetal vasculitis including *Actinomyces* species, *Corynebacterium* species, *Mycoplasma* species, *Escherichia coli*, *Ureaplasma urealyticum* and group B, group D, alpha-hemolytic, and anaerobic streptococci. However, it should be remembered that group B streptococcal infection is not consistently accompanied by significant inflammation. Spread of organisms from the infected placenta to the fetus (so-called early onset sepsis) is rare and chorioamnionitis is rarely a direct cause of intrauterine fetal death. One exception is untreated group B streptococcal infection.

Subacute necrotizing funisitis is a subset of acute chorioamnionitis characterized by peripheral microabscesses of the umbilical cord. The classic gross finding is the presence of pinpoint yellow-white nodules on the umbilical cord that track the coils of the underlying vessels. They are best viewed with tangential light and/or use of a hand-held magnifying lens. These foci correspond to histological subamniotic microabscesses and include mineralization of the arcs of inflammatory detritus. Subacute necrotizing funisitis may also be seen in infections of longer duration and cord vessel thrombosis in more chronic cases. The vast majority of these cases are due to *Candida albicans* but *C parasilopsis* and other species have been identified. Co-infection with bacteria and genital mycoplasmas may also occur.

Intrauterine infection by *Candida*, although a less common cause of acute chorioamnionitis is more prevalent in preterm deliveries and is associated with significant mortality rates in the extreme and severely preterm infant [13]. Gross detection of these lesions at the macroscopy room should need rapid alarming of the neonatologist in charge so that the administration of antifungal therapy can be started, if necessary. In addition, special fungal stains of the lesions should be done. Rarely, the cord lesions represent foci of infections of *Corynebacterium*, *Haemophilus* or *Listeria monocytogenes*.

Subacute chorioamnionitis is another acute inflammatory placental pathology of infectious etiology in SPB. This is a histopathological diagnosis characterized by a chorionic mononuclear (histiocytic) infiltrate admixed with degenerating neutrophils and karyorrhectic debris that is most prominent in the upper zone of the chorionic plate and indicates a more prolonged duration of intrauterine infection. It may represent infection by organisms of low pathogenicity or recurrent mild infection. Clinically it is seen in gestations complicated by repeated second and/or third trimester episodes of bleeding [11].

In a study, it was concluded that subacute chorioamnionitis was strongly associated with the development of chronic lung disease of infancy and that very low birth weight and amniotic necrosis were the strongest predictors of this pulmonary outcome [14]. However, the relative significance of this histopathology needs further investigation. The differential diagnosis includes *chronic, predominantly lymphocytic, chorionitis* which is generally focal and associated with villitis of unknown etiology (Figure 4, 5).

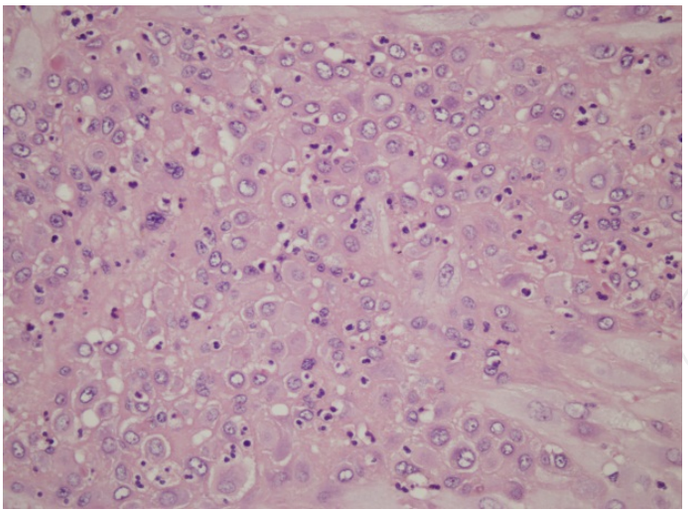

Figure 4. Predominantly lymphocytic focal infiltrate of chronic chorionitis.

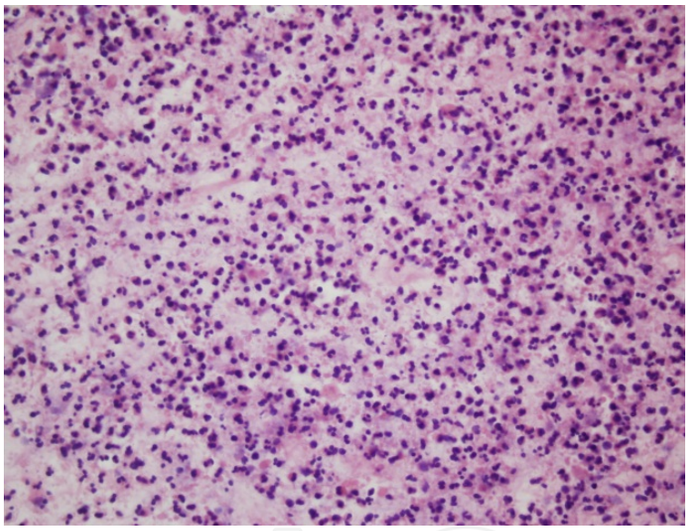

Figure 5. Acute chorionitis characterized by diffuse neutrophilic infiltration

4.2. Acute villitis / intervillositis

This acute inflammatory response is characteristic of hematogenous (transplacental) spread of infection from the mother to the fetus. The organisms spreading by transplacental route gain access to the maternal bloodstream in early infection. The intervillous space contains aggregates of (maternal) neutrophils admixed with fibrin in contrast to chronic villitis (Figure 6, 7). Acute villitis with marked microabscess formation and necrosis follows, since the trophoblast has receptors for the bacterial surface antigen internalin A, and cell-to-cell translocation of the bacteria across the placental barrier into the villous endothelial cells and fetal circulation occurs. Foci of acute intervillositis / villitis may coalesce to form punctate or confluent regions of abscess and necrosis that are grossly seen on placental sections.

http://dx.doi.org/10.5772/54887

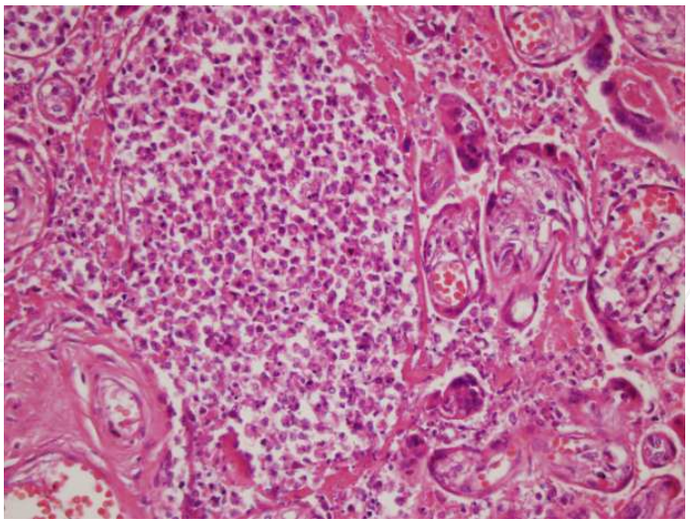

Figure 6. Acute villitis characterized by aggregates of neutrophils in the intervillous space admixed with fibrin.

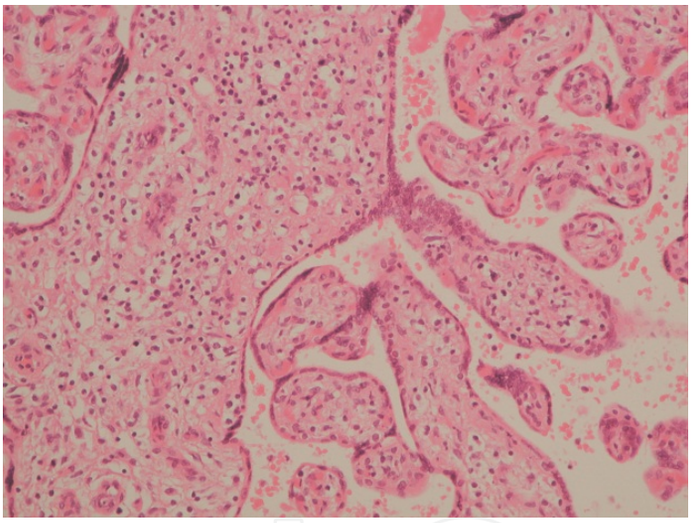

Figure 7. Acute villitis characterized by aggregates of neutrophils in the intervillous space admixed with fibrin.

Detection of acute villitis should prompt immediate notification of the perinatologists, since *Listeria monocytogenes* is a common cause and associated with rapid and disseminated fetal infection and high perinatal mortality in preterm births. This microorganism is a facultative anaerobe that can survive and replicate within a broad thermal range. Maternal infection is generally acquired through ingestion of contaminated food products (i.e. vegetables, packaged or refrigerated meats, dairy products). Tissue gram stains will show numerous, short gram positive rods. In addition, the placental lesions should be cultured, since investigations of perinatal death and epidemics may require detailed documentation through specific typing of the organism.

Other rare causes of acute villitis / intervillositis reflect maternal exposure to the pathogens. Acute fibrinopurulent inflammation due to *Chlamydia psittaci* will show organisms within

syncytiotrophoblast. Maternal tularemia following tick bite, inhalation of airborne bacteria, or contact with infected rodents or rabbits can lead to a severe villitis and fetal infection. *Coccioides immitis* spherules produce an intense villitis / intervillositis but rarely transplacental infection of the fetus. Fetal sepsis due to *Escherichia coli* and group B and other streptococci can be evidenced by neutrophilia within the fetal chorionic villous capillaries that may infiltrate into the stroma forming aggregates in the subtrophoblastic space. In contrast to *L monocytogenes*, there is mild intervillositis or necrosis.

4.3. Chronic villitis

Chronic infections that may result in SPB are largely those caused by the TORCH (Toxoplasmosis, Others, Rubella virus, Cytomegalovirus, and Herpes simplex virus) infections. All of these infectious disease result in fetal onset of growth restriction, hepatosplenomegaly, cytopenias, coagulopathies, and often fetal hydrops and high infant morbidity and mortality. Parasitic pathogens are uncommon but may complicate gestations of women who have infected cats and are exposed early in their gestation to endemic pathogens. *Toxoplasma gondii* is the most important parasitic placental infection in Western countries [15].

The overwhelming majority (approximately 90%) of infectious chronic villitis is due to cytomegalovirus (CMV) and *Troponema pallidum* [16]. CMV infection usually results in a pale, hydropic-appearing placenta and preterm delivery frequently complicated by placental abruption. In these instances, dysmature villi are seen on light microscopy. More chronic infection generally results in a normal weight to shrunken, firm, pale, fibrotic placenta and fetal intrauterine growth restriction (IUGR). In these cases, CMV infection is characterized by lymphohistiocytic and especially, lymphoplasmacytic villitis. Plasma cell infiltrate, while not specific for CMV, is highly suggestive, especially if plasma cells are seen in terminal villi that are not in contiguity with the basal plate. Intranuclear or cytoplasmic trophoblastic epithelial, Hofbauer cellular, and endothelial inclusions are easily seen on hematoxylen eosin stains (Figure 8). However, immunoperoxidase stains for CMV are particularly useful in cases of longstanding intrauterine infection where the inclusions are sparse. Even if viral inclusions are unapparent; presence of stromal hemosiderin deposition due to capillary damage, dystrophic mineralization due to villous damage), and sclerosis are virtually pathognomonic of CMV. Lymphoplasmacytic deciduitis in the capsularis and basalis is generally present. Use of PCR for CMV early and late gene antigen gp 64 has also been reported [17].

Detection of acute villitis should prompt immediate notification of the perinatologists, since *Listeria monocytogenes* is a common cause and associated with rapid and disseminated fetal infection and high perinatal mortality in preterm births. This microorganism is a facultative anaerobe that can survive and replicate within a broad thermal range. Maternal infection is generally acquired through ingestion of contaminated food products (i.e. vegetables, packaged or refrigerated meats, dairy products). Tissue gram stains will show numerous, short gram positive rods.

Of special importance, prior maternal infection with CMV does not provide overall absolute immunity and therefore, most cases of congenital CMV are due to recurrent maternal infection that is asymptomatic in both the mother and the newborn. Since recurrent CMV is more

http://dx.doi.org/10.5772/54887

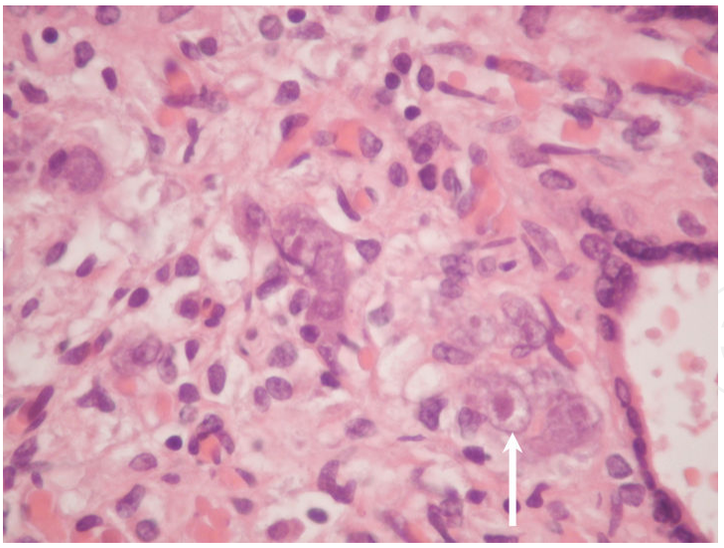

Figure 8. Intracytoplasmic inclusions (arrow) in a CMV villitis.

common than primary CMV infection during gestation, placental examination in SPB emerges as a critical means of detection of congenital CMV infection.

Syphilis placentitis is another cause of chronic villitis. The histopathology of *T pallidum* infection is T-lymphocytic and sometimes lymphoplasmacytic chronic villitis which are typically associated with sclerosis and circumferential vascular thickening of stem villous vessels and thrombosis. Sometimes, histopathology may be limited to villous edema and hypercellularity. Thrombi are also seen in umbilical cord and chorionic plate vessels, and confirmatory Warthin–Starry or Steiner silver stains are best performed on the umbilical cord because of its relative hypocellularity.

Herpes simplex virus (HSV) infection is characterized by lymphohistiocytic inflammation but marked necrosis and intervillositis with trophoblastic multinucleation and viral cytopathy. The villitis / intervillositis is similar to that seen in *L monocytogenes* except that the inflammation is more often chronic and trophoblastic glassy inclusions are present. Intranuclear inclusions can be confirmed by immunohistochemical stains. About 95% of intrauterine HSV infections are due to acute ascending infections from the maternal genital tract, and most occur with intact membranes. Therefore, amniotic multinucleation and necrosis is present, and frequently, lymphoplasmacytic chorioamnionitis. In more chronic cases these multinucleated residual cells may be incorporated into the superficial chorion. Chronic lymphoplasmacytic villitis is often accompanied by chronic deciduitis.

4.4. Idiopathic chronic deciduitis

Chronic deciduitis limited to the decidua basalis, and defined as diffuse lymphocytic infiltrate of the basal plate or any infiltrate in the decidua basalis that includes plasma cells is abnormal (Figure 9). It is suggested to represent maternal response to chronic intrauterine colonization or infection by organisms of low pathogenicity and may predispose to preterm birth. Poten-

tially, infection may develop early in gestation, before membrane fusion of the chorioamnion of the gestational sac to the opposite uterine wall at 19–20 weeks, and then later after fusion, transmitted to the conceptus. Alternatively, the inflammation may represent recurrent / persistent low-grade infection that occurs between pregnancies as chronic endometritis. Therefore, it is a risk factor for recurrent pregnancy loss. In a study, it was found that 40% of preterm placentas from cases of idiopathic preterm labor and 15% of their control cases had chronic deciduitis [18]. Further clinicopathological studies may improve our understanding of the implications of this entity.

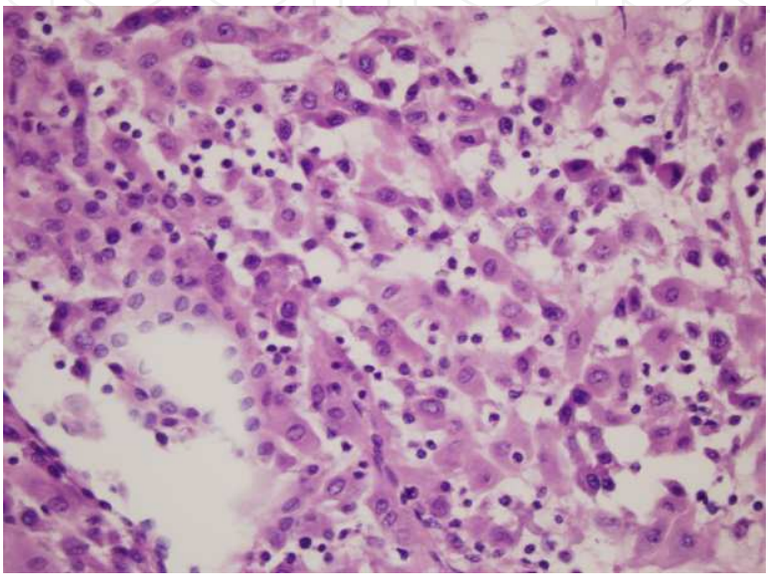

Figure 9. Chronic desiduitis including plasma cells in the decidua basalis.

5. Placental pathology of non-inflammatory processes in SPB

The pathogenesis of SPB in the absence of infection may also involve activation of pathways responsible for normal onset of labor via components of the maternal and fetal hypothalamic–pituitary–adrenal axis. These include loss of the normally coordinated interactions and changes in systemic and local uterine balances of oxytocin levels, fetal cortisol levels, and decreasing estrogen to progesterone ratios. Other non-infectious triggers of SPB are uteroplacental ischemia and / or oxidative stress, excessive uterine stretching, immunologically-mediated processes and uterine anomalies.

Finally, an important pathway also appears to involve non-infectious, pathological activation of decidual inflammation by decidual bleeding, because extravasated blood is a biochemical irritant and acts as a trigger of inflammation. Clinical findings suggest that pathological findings including chronic retromembraneous hemorrhage, marginal and retroplacental hematoma may have causal implications in SPB.

http://dx.doi.org/10.5772/54887

5.1. Chronic retromembranous hemorrhage

Gross examination of retromembraneous hemorrhage reveals marked discoloration characterized by red-brown thickenings and yellow areas behind the membranes, and opacity of the fetal surface (Figure 10). This lesion is most likely to be from old bleeding and ascending infection which are common together in extremely premature deliveries. The underlying cause of retromembranous hemorrhage may involve ischemia and / or endothelial damage. Decidua capsularis ischemia should be especially suspected if there is laminar necrosis or leukocytoclastic necrosis. In a recent study, immunohistochemical staining for some markers of oxidative stress including complement component 9 and nitrotyrosine residues were prominent in membrane rolls with laminar necrosis [19].

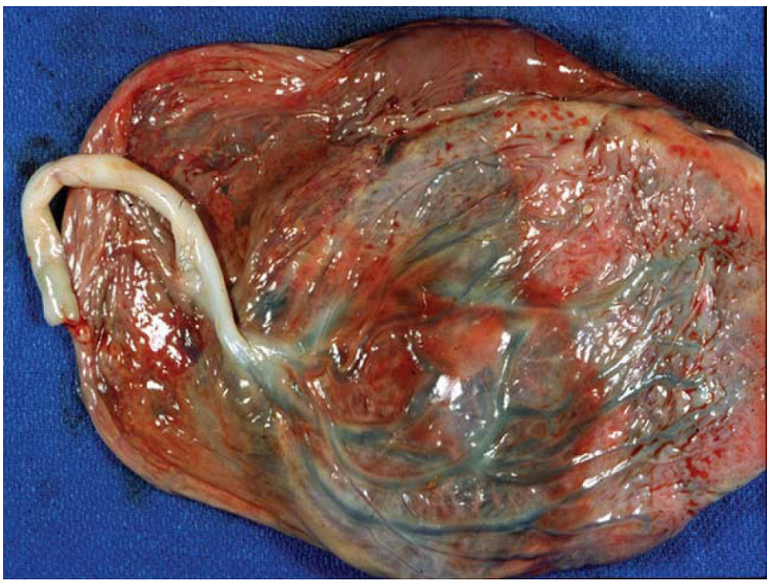

Figure 10. Retromembranous hemorrhages showing brown or yellow discolorations on the membranes.

In addition, tumor necrosis factor α (TNFα) production is a potential focus of ongoing researches on this topic, because TNFα in cervical secretions is of one of many potential cytokines that has been identified as a marker of preterm labor in women without risk factors of hypertension. It causes many effects and plays many roles on biological phenomena. TNFα production is a common outcome of activation of monocytes and histiocytes in tissue damage resulted from ischemia and bacteria, immune complexes, toxins and other cytokines TNFα causes the release of proteolytic enzymes from mesenchymal cells, in addition to resulting in aggregation and activation neutrophils. TNFα has also recently been shown to raise apoptosis of cultured villous trophoblasts [20]. Alternatively, it has a biological effect on inducing decidual vascular smooth muscle apoptosis and elastin degradation. TNFα also increases production of other inflammatory cytokines, matrix metalloproteinases involved in amnion degradation, and mediators of increased uterine tonicity (i.e., prostaglandin production by amnion, decidua and myometrium). Besides TNFα, other cytokines and chemokines such as IL-1β, IL-4, IL-6, IL-8 and factor Va are being investigated in preterm birth and seem

to exhibit racial differences and polymorphisms, but their precise roles and points of entry in the cascade of preterm labor are unclear.

5.2. Retroplacental hematoma (Abruptio placenta)

Abruptio placenta is defined as the sudden separation of a significant portion of the placenta from its underlying maternal blood supply prior to delivery and is one important cause of acute hypoxic injury. It is associated with a number of adverse outcomes including preterm delivery, fetal growth restriction, stillbirth, and hypoxic ischemic encephalopathy. Patients with evidence of early pregnancy bleeding are also at risk for later acute abruption.

It is often stated that the correlation between pathological and clinical abruption is poor. Likewise, clinical signs and symptoms of abruption may also prove unreliable [21]. The gold standard for diagnosis of abruptio placenta is macroscopical appearance of retroplacental hemorrhage at the time of C-section. The best pathologic evidence is the gross finding of a retroplacental hematoma with either placental indentation or intraplacental extension (Figure 11). In the absence of these findings, microscopic evidence of interstitial hemorrhage in the basal plate or diffuse retromembranous hemorrhage is helpful to think about abruption. Ischemic changes in the overlying placenta such as recent villous infarction or villous stromal hemorrhage are also very suggestive of abruption. Finally, lesions associated with chronic maternal underperfusion are very commonly associated with abruption and can help strengthen a strong clinical suspicion of the diagnosis. Figure 12 illustrates morphological types of hemorrhagic and ischemic lesions of placental disk.

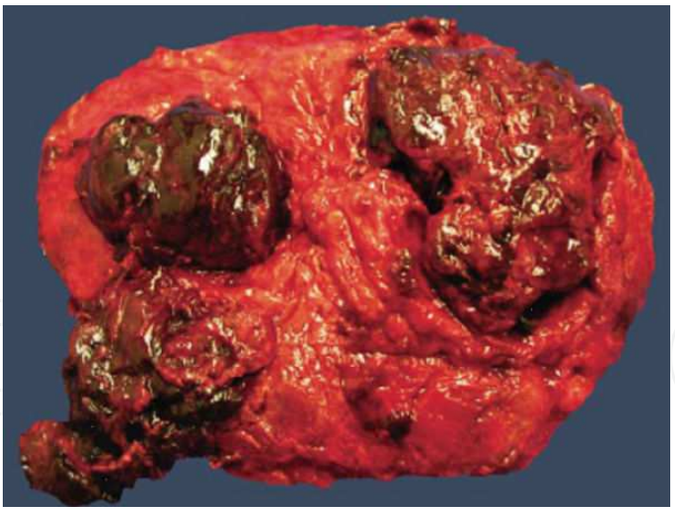

Figure 11. Gross appearance of the lesions of hematoma in the retroplacental area.

5.3. Marginal hematoma

Chronic marginal hematoma (chronic abruption) is an important cause of preterm delivery and may be associated with an atypical form of neonatal lung disease. It is also a significant risk factor for cerebral palsy and other forms of worse neurological outcome in term infants.

http://dx.doi.org/10.5772/54887

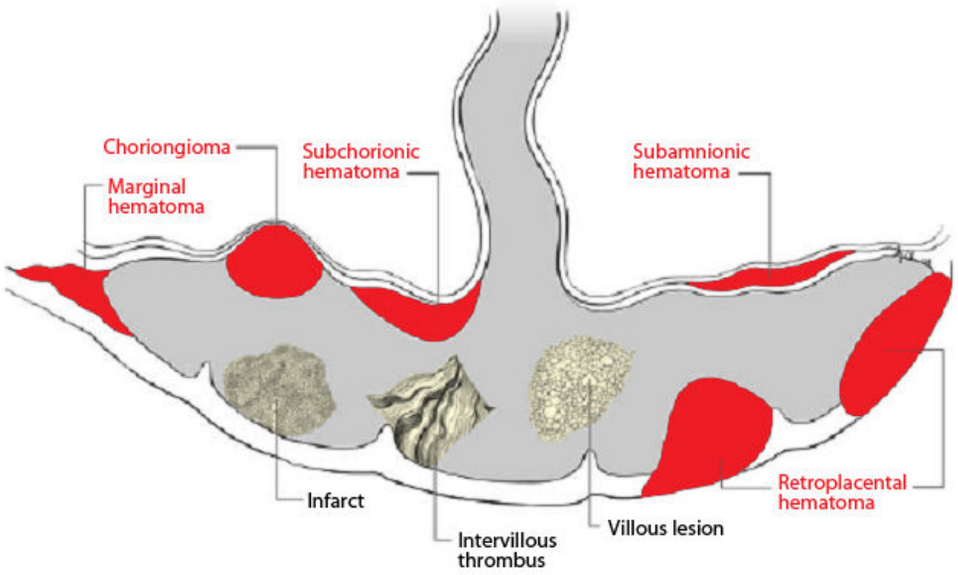

Figure 12. Morphological illustration of placental hemorrhagic and ischemic lesions.

Factors that have been associated with chronic abruption include multiparity, smoking, oligohydramnios, and excessively deep uterine implantation.

Unlike arterial rupture resulting in abruptio placenta, venous hemorrhage tends to occur at the placental margins and to escape at lower pressure in chronic abruption. Therefore, in contrast to retroplacental hematoma, hemorrhage of lower pressure accumulation plays a role in the process of preterm labor. The pathogenetic explanation is that lateral growth of the placenta involves remodeling of large uterine veins and these large obliquely oriented structures may rupture prematurely if poorly supported by the surrounding endometrium or subjected to elevated intramural pressure due to obstruction of larger upstream veins such as the vena cava. For these reasons, marginal abruptions may not result in immediate delivery, instead acute form presents as threatened abortion in early pregnancy or chronic abruption occurs in later pregnancy causing bleeding with preterm birth or spontaneous abortion, if it shows rapidly enlarging of great enough volume or recurs. Additionally, chronic abruption is often associated with oligohydramnios in a syndrome known as the chronic abruption-oligohydramnios sequence.

Clinically, marginal hematoma may be seen on prenatal ultrasonogram and is referred to as subchorionic hemorrhage or periplacental hemorrhage. They may be detected early in gestation and resolve later and lead to circumvallation. It is important to note that the clinically

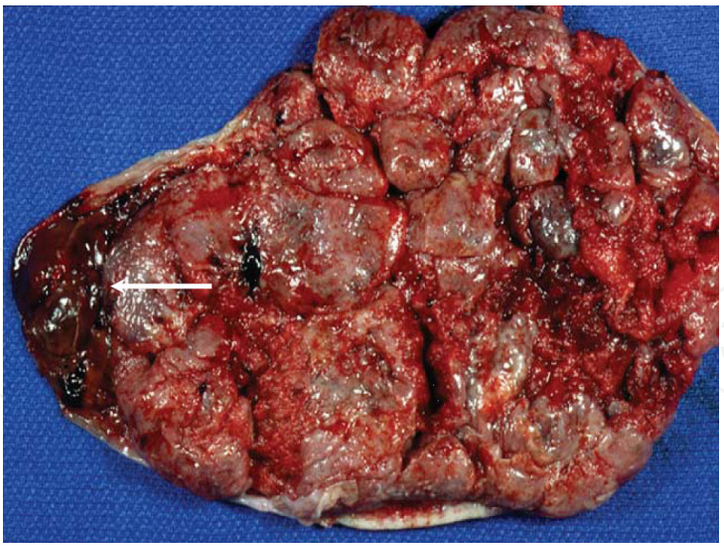

Figure 13. Marginal hematoma extending onto the membranes (white arrow). The brown color of the blood indicates its chronicity.

used term "subchorionic hemorrhage" is different from "subchorionic thrombohematoma", also called Breus mole, which refers to a central, nodular protuberance on the fetal surface of the placenta, and from thrombohematoma formation in the maternal space.

Examination of suspected marginal hematoma should include recording of its dimensions and percentage of marginal involvement, type of adherence and appearance, features of chronicity, extent of dissection of adjacent parenchyma on section, and type of associated, overlying membranous insertion, along with histological evaluation of the junctional region and membranes. They are crescent-shaped and have a cut surface with a triangular configuration at the lateral angle of the placenta (Figure 13). There is associated dissection into the lateral chorionic villous parenchyma. Chronic form may produce a depression in adjacent marginal chorionic villous tissue. On section, it has a laminated, friable, yellowish-brown and / or calcified thrombohematoma with dissection of the lateral placental border. A superimposed acute component may be also present.

Chronic abruption, like chronic maternal underperfusion, is associated with a cluster of placental findings. These include old marginal blood clot, circumvallate membrane insertion, chorioamnionic hemosiderin deposition, and green (biliverdin) staining of the fetal surface *Circumvallation* may develop as a consequence of blood accumulating in the space between the decidua and chorion leading to folding of the marginal chorionic plate. When circumvallation is attributable to chronic marginal separation, old blood clot and local *hemosiderin deposition* are seen on histological sections. Hemosiderin stains blue by iron stain, but other hemoglobin related pigments do not. Any pigment seen in a premature placenta favors chronic abruption rather than meconium release which is extremely uncommon before 37 weeks. Additionally, the finding of hemosiderosis in the decidua basalis should always be documented, but when seen in cases of SPB in the absence of a clinical history of maternal hypertension, it may have different implications and reflect a genetic or ethnic risk factor.

http://dx.doi.org/10.5772/54887

To be noted, marginal hematomas are often acute and affect less than a quadrant of the placental perimeter. They are reportedly seen in 0.7–1.9% of placentas [22]. This percentage may relatively increase in the academic tertiary units where large numbers of patients are admitted for complicated gestations and SPB. In a study, therefore, incidence of chronic marginal hematoma was found in 7–10% of placentas [7].

Incidental marginal hematoma or passive, intrapartum accumulation of blood in the marginal anatomic fissure, with no grossly detectable loss of the distinct border between the lateral placental margin and the borders of the hematoma, may accompany oxytocin induction, such as seen in IPB.

6. Placental pathology in induced preterm birth

Induction of labor with or without artificial rupture of membranes, and caesarean section delivery in cases of IPB is largely performed for maternal hypertensive disorders of pregnancy, non-reassuring fetal heart rate and IUGR.

The pathology of the spectrum of pregnancy induced hypertensive conditions as they relate to IUGR and the placental pathology associated with IUGR may be seen in preterm and term placentas [23]. The other disorders that predispose to maternal indications for IPB are also largely related to those that result in chronic uteroplacental underperfusion and risk of IUGR, such as vasculopathy and thrombosis associated with maternal primary hypertension or diabetes mellitus (maternal vascular obstructive lesions). Thus, there is some overlap between maternal and fetal indications for indicated preterm delivery. However, there are some placental pathologies that may not be associated with IUGR but with fetal distress in the preterm birth, and some that have been found to be causally linked to IUGR, non-reassuring fetal heart rate, and / or absent umbilical arterial end diastolic blood flow. The following entities are more likely seen in placentas from induced or caesarean section deliveries performed for fetal indications, and that might be expected to be identified in different frequencies in late versus early preterm placentas.

7. Chronic uteroplacental underperfussion

Chronically underperfused placentas are associated with fetal growth restriction, preterm birth due to either premature labor or premature rupture of membranes, premature placental separation (abruptio placenta), and carry an increased risk for the development of preeclampsia. Clinical conditions predisposing to maternal underperfusion include type I diabetes mellitus, connective tissue disease, chronic renal insufficiency, essential hypertension, and underlying maternal coagulopathies including thrombophilic mutations and antiphospholipid syndrome. Familial aggregation of preeclampsia and underlying maternal vascular disease may at least in part be due inheritance of the so-called metabolic syndrome characterized by

abnormal serum lipid levels, enhanced production of acute phase inflammatory mediators, and a predisposition to vascular damage related to reactive oxygen intermediates.

Chronic maternal underperfusion of the intervillous space can result from a variety of causes including underlying cardiac insufficiency, failure to expand intravascular volume during pregnancy, or structural abnormalities in arteries supplying the uterus. It is currently believed that the major process leading to underperfusion is failure of trophoblast to appropriately invade and remodel the uterine spiral arteries. While the exact mechanisms of events leading to this outcome have not yet been explained, but a number of contributing factors have been identified. These include initial exposure to fetoplacental antigens in the first pregnancies, inherited polymorphisms in genes of the renin-angiotensin system, circulating anti-endothelial cell antibodies, and underlying uterine small vessel disease. The common activator for all of these factors seems to be decreased oxygen delivery to the implantation site resulting in impaired trophoblast differentiation and inadequate placentation. In the absence of arterial remodeling, the placenta is chronically underperfused leading to decreased fetoplacental growth and, in some cases, release of vasoactive mediators in late pregnancy leading to the clinical syndrome of preeclampsia.

Placentas affected by maternal underperfusion generally show multiple pathological findings that together allow a specific diagnosis to be rendered. One important, often overlooked, feature is decreased body weight for gestational age and decreased placental weight relative to that of the infant, which suggests increased fetoplacental weight ratio. In severe cases, this correlates with late impairment of placental growth (distal villous hypoplasia) as the fetus sacrifices placental perfusion in order to supply critical vascular beds such as the central nervous and cardiovascular systems. Also common in severe cases are villous infarcts caused by thrombosis of abnormal maternal arteries and a thin umbilical cord resulting from extracellular volume depletion and decreased hydration of Wharton's jelly. Lesser degrees or durations of underperfusion and hypoxia can lead to stasis with intervillous fibrin deposition, accelerated syncytiotrophoblast turnover with increased syncytial knots, and ischemia leading to foci of villous agglutination (Figure 14). Finally, there are other findings directly reflecting inadequate placentation. These include muscularization of basal plate arteries, aggregates of immature or prematurely differentiated cells such as placental site giant cells or epithelioid (chorion laeve type) trophoblasts in the basal plate, and medial hypertrophy or fibrinoid necrosis (acute atherosis) of maternal arterioles in the membranous decidua (Figure 15).

8. Chronic villitis of unknown etiology

Villitis of unknown etiology (VUE) represents a subcategory of chronic villitis and has not been proven clinically or identified histopathologically to result from an infection in the placenta, mother or infant [24]. VUE is a common lymphohistiocytic villitis affecting terminal villi with vasculosyncytial membrane formation which is a characteristic morphological feature of 32 or more weeks of gestational development. Therefore, the diagnosis should be restricted to the cases of 32–36 weeks.

http://dx.doi.org/10.5772/54887

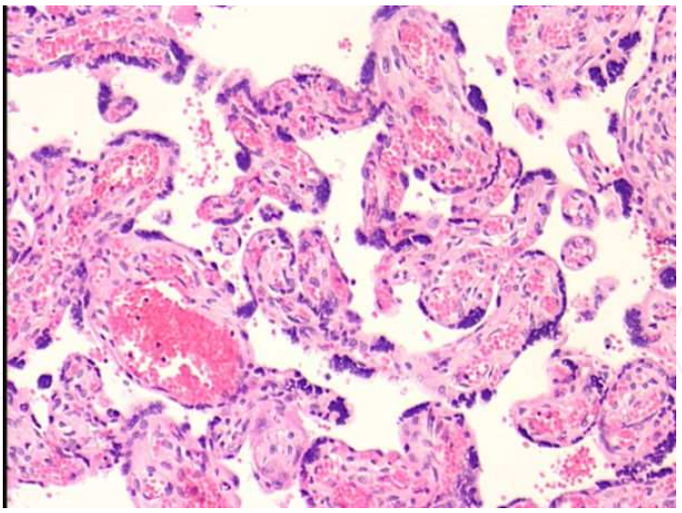

Figure 14. Histopathological features in placentas affected by maternal underperfusion including increased syncytial knots due to increased apoptosis and accelerated syncytiotrophoblast turnover.

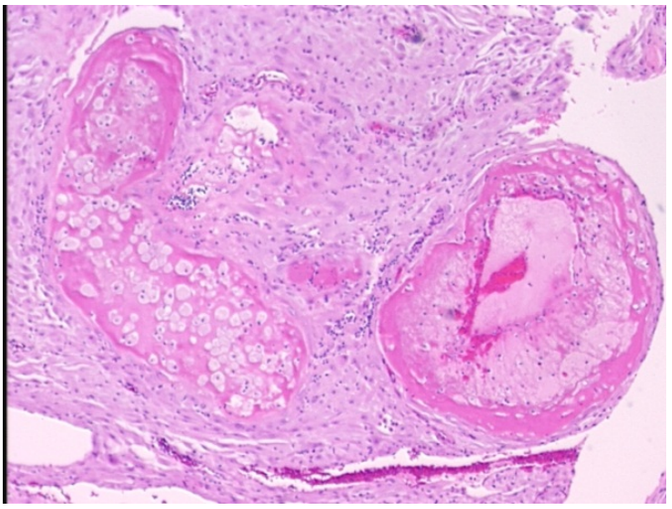

Figure 15. Endothelial damage in maternal underperfusion characterized by medial hypertrophy or fibrinoid necrosis (acute atherosis).

VUE does not have consistent gross pathological features. Because of its irregular distribution, the histological detection of VUE is sample-dependent. It is best detected at low power magnification (20×), typically in the subchorionic and especially basal villi. Higher power view generally reveals lymphohistiocytic villitis affecting less than five villi (Figure 16). Plasma cells are rarely seen, but depending on the stage, the villitis may be accompanied by villous destruction, sclerosis, and the very rarely giant cell reaction. Lymphoplasmacytic deciduitis of the basal plate and chronic chorioamnionitis characterized by foci of small lymphocytic infiltrates in the lower chorion may be also seen. If the villous inflammation is patchy and involves more than 5% of chorionic villi, it is termed "diffuse VUE". In diffuse form the

midzonal parenchyma is generally not spared, perivillous fibrin deposition is seen, and villous destruction is more prominent.

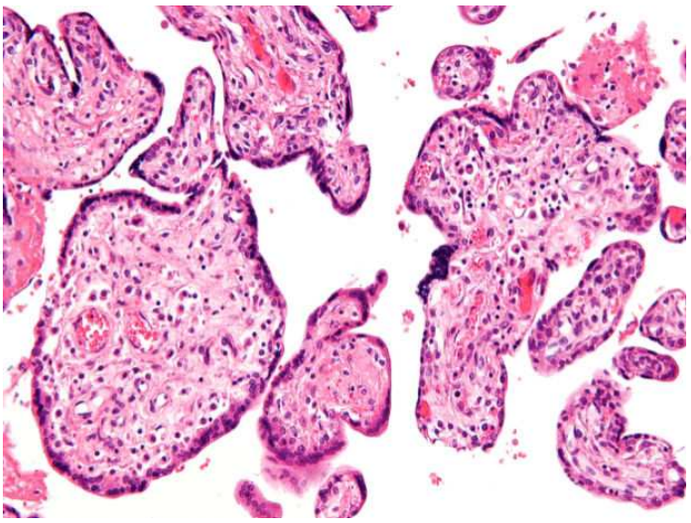

Figure 16. Lymphohistiocytic villitis in a case of preterm birth with VUE.

Most cases of VUE do not result in perinatal morbidity and mortality. However, there is a strong risk correlation between VUE and idiopathic IUGR. The frequency of IUGR directly correlates with the diffuse form. VUE has also been shown to be linked to non-infectious spontaneous preterm birth and perinatal asphyxia [25]. The presence of VUE may contribute to placental insufficiency and to the oligohydramnios without a maternal hypertensive disorder or other risk factor. Diffuse VUE with an inflammatory involvement of larger stem villi and villous vessels, termed "chronic villitis with obliterative vasculopathy", is also more strongly associated with severe IUGR and perinatal morbidity, including neurological sequelae.

The most important pathogenetic characteristic of VUE is that it appears to represent a localized, alloimmune process of host versus graft response in the chorionic villous tree from a breakdown in maternal–fetal tolerance. The lymphohistiocytic villous infiltrates have been shown to be composed almost exclusively of maternal CD8-positive T cells and Hofbauer cells of fetal origin. Activation of fetal Hofbauer cells and focal syncytiotrophoblast destruction at sites of villitis, together with the absence of eosinophils and presence of histiocytic giant cells are compatible with a delayed hypersensitivity response or a T-helper 1 type of response. The hypothesis that VUE is an alloimmune-mediated process is supported by its high risk of recurrence (10–25%) and 60% rate of pregnancy loss in instances of recurrence.

Massive chronic intervillositis (MCI) is also an alloimmune phenomenon, but it is unclear if it is a variant of VUE. MCI is most frequently seen in first trimester abortion, and therefore might be expected to be more prevalent in placentas from extremely and severely preterm birth It is also a potential cause of IUGR in the preterm infant in IPB or non-infectious SPB. (Figure 17)

http://dx.doi.org/10.5772/54887

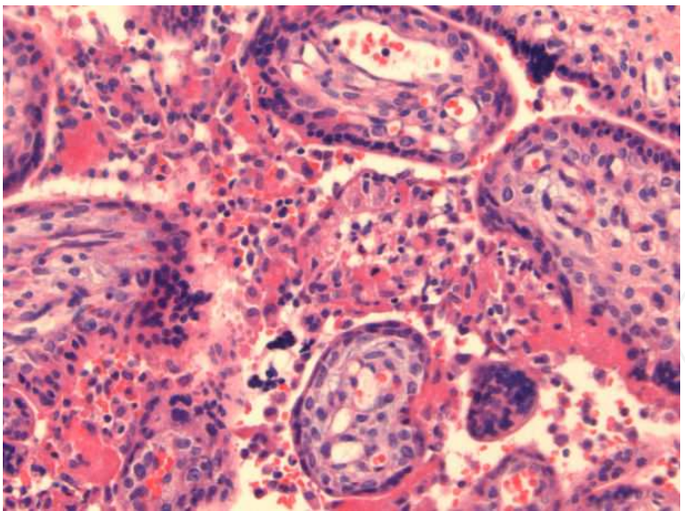

Figure 17. Histiocytic intervillitis in an extremely preterm birth complicated by mortality.

9. Fetal thrombotic vasculopathy

Fetal thrombotic vasculopathy (FTV) is explained by the biological fact that vessels of the chorionic villous tree are in continuity with those in the fetus. The presence of chorionic villous thrombi leads to fetal thromboembolic phenomena and increased placental vascular resistance, and may lead to loss of end-diastolic blood flow, which may exacerbate any underlying cord or fetal factors that predispose to thrombosis.

Thromboocclusive lesions of large fetal vessels in the placenta and umbilical cord occur in the context of one or more of the classic triad of risk factors; vascular stasis, loss of surface resistance to coagulation, and circulatory hypercoagulability. Possible causes of fetal vascular stasis include prolonged umbilical cord obstruction, increased central venous pressure, and elevated hematocrit. Loss of surface resistance to coagulation may occur with severe fetal inflammation, antiphospholipid syndrome, and other forms of vessel wall damage. Circulatory hypercoagulability may be present with platelet disorders, maternal diabetes, or thrombophilic mutations involving protein C, protein S, antithrombin II, factor V, prothrombin 2010, and methyl tetrahydrofolate reductase. It is likely that most cases of fetal thromboocclusive disease involve more than one risk factor.

Sustained proximal vascular occlusion leads to degenerative changes in the distal villous tree. Longstanding occlusion of large arteries leads to distal hyalinized avascular villi. The early stages of proximal venous occlusion cause circulatory stasis with villous stromal-vascular karyorrhexis which is degeneration of red blood cells, endothelial cells, and villous stromal fibroblasts. This pattern of change occurs diffusely in the placentas of stillbirths. When seen in a focal distribution in either live births or stillborns it has been termed hemorrhagic endovasculitis. With longstanding venous obstruction, upstream villi become hyalinized and avascular as with arterial obstruction. These villous changes can affect large or small groups

of villi and can be localized or widely distributed throughout the placental parenchyma. When the number of affected villi exceeds an average of ≥ 15 villi/ slide the process has been termed fetal thrombotic vasculopathy (Figure 18). Large vessel thrombi are identified in approximately one third of such cases. Other lesions associated with fetal thrombo-occlusive disease include intimal fibrin cushions and fibromuscular sclerosis of stem arteries (Figure 19). Intimal fibrin cushions are intramural aggregates of fibrin in proximal fetal veins that are usually attributed to increased intramural pressure. Fibromuscular sclerosis represents concentric narrowing of the vascular lumen by proliferating smooth muscle cells and subendothelial fibroblasts, typically occurring in placental vessels lying between the point of occlusion and the affected villi secondary to lack of flow.

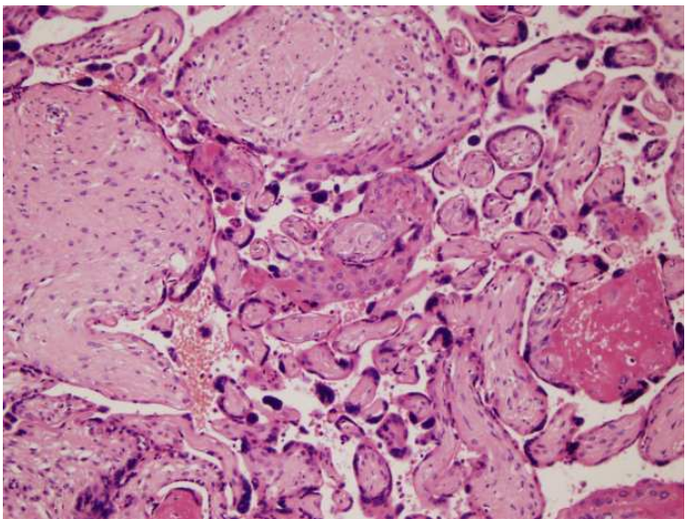

Figure 18. Avascular villi associated with fetal thrombo-occlusive disease.

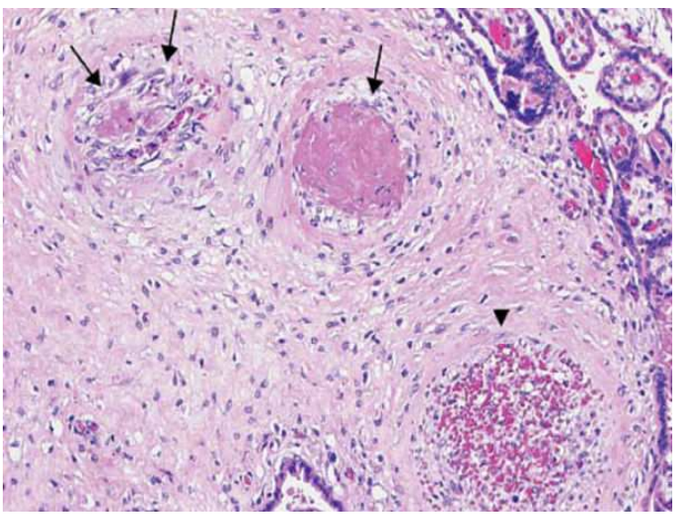

Figure 19. Intimal fibrin cushions and fibromuscular sclerosis of stem arteries, a suggestive histological finding for fetal thrombo-occlusive disease.

http://dx.doi.org/10.5772/54887

FTV is a significant risk factor for thromboembolic neurological sequelae such as a stroke. Other thromboembolic sequelae include limb reduction anomalies, systemic visceral thromboemboli in the gastrointestinal tract, kidneys, and liver. Hepatic thrombosis may lead to Budd–Chiari syndrome and perinatal liver disease. IUGR with FTV is likely related to loss of functional placental parenchyma. Avascular villi are also associated with IUGR, chronic monitoring abnormalities, and discordant growth in twin gestations. Nonocclusive thrombi in severely inflamed chorionic vessels are occasionally seen with severe acute chorioamnionitis in very low birth weight infants and represent a risk factor for neurologic impairment in this subgroup.

10. Maternal floor infarction

Maternal floor infarction (MFI) is also associated with high rates of preterm birth (26–60%) and unexplained IUGR (24–100%) [26]. When it shows an early onset, there is an associated increased risk of recurrence and severity in subsequent pregnancies. The dense perivillous fibrinoid deposition impairs villous exchange resulting in villous atrophy. The etiopathogenesis of the perivillous accumulation of fibrinoid in MFI is likely complex, but there is good evidence that it may be immune mediated.

11. Conclusion

Preterm birth is common and is associated with high rates of perinatal morbidity and mortality. Pathological examination of the preterm placenta can provide valuable information concerning the immediate and chronic risks for the infant and risks of chronic diseases in childhood.

The gross and microscopic examination of the placenta from preterm birth, whenever possible, should be approached with the clinical perspective of whether the specimen is from an SPB or IPB. Placentas from SPB more commonly show acute chorioamnionitis with funisitis and intense vasculitis, marginal hematoma, chronic decidual hemorrhage, and acute and chronic infectious villitis. SPB due to POL and / or PPROM likely results from abnormal activation a cascade of cellular components and mediators of an inflammatory pathway are responsible for the process of normal, term parturition. Placentas from IPB more commonly show fetal thrombotic vasculopathy. Diffuse VUE and chronic villitis with obliterative vasculopathy are very common in late IPB, whereas those from early IPB show chronic intervillositis more frequently. All of these diagnoses have implications for the neonate and/or the mother.

Further studies may reveal that maternal chorionic villous inflammatory cells, as seen in syphilis and toxoplasmosis, play a role in many other infectious villitides and that the effects of these cells contribute to the severity of the morbidity or mortality that has been largely attributed to the infectious organisms. Research may also reveal that the maternal lymphocytes in VUE and even infections may gain access to fetal circulation. The prolonged period that a mother's lymphocytes may be in her child's circulation may have implications for the etiologies

of other pediatric immune-mediated disorders. FTV may also predispose the infant to short or long term persistence of increased vascular tone or vascular disease, in addition to functional deficiencies of major organs such as the liver or kidneys.

Thus, the placenta in preterm birth is not only a record of adverse conditions during intrauterine life that led to SPB or necessitated an IPB, it also likely holds clues to predicting which individuals will be at heightened risks for developing chronic diseases in childhood. Low birth weight infants are at risk for developing chronic diseases in adulthood. Pathological examination of the preterm placenta may provide important insights into future investigations to determine which infants will be at risk for development of cardiovascular disease, hypertension and diabetes mellitus, later in life. Risks of neurological sequelae in the infant have been linked to specific histopathological features in the placenta. The placental pathology report should include notation of these features.

In conclusion, placental pathologists are in a unique position to provide valuable observations in preterm birth. Their service in the perinatal medicine;

- may provide an immediate impact on the care of the premature newborn,
- may help to explain the poorly understood pathogenetic mechanisms responsible for preterm birth,
- and may potentially aid in the process of linking currently unexplained roles of alloimmune-mediated processes and intrauterine stress to the development of chronic human diseases.

Author details

Erdener Ozer

Address all correspondence to: erdener.ozer@deu.edu.tr

Department of Pathology, Dokuz Eylul University School of Medicine, Izmir, Turkey

References

[1] Goldenberg RL, Culhane JF, Iams JD, et al. Epidemiology and causes of preterm birth. Lancet 2008;371:75–84.

[2] World Health Organization. Media Center: Preterm Birth, Fact Sheet. http://www.who.int/mediacentre/factsheets/fs363/en/index.html (accessed 1 October 2012).

[3] Alexander JM, Gilstrap LC, Cox SM, et al. Clinical chorioamnionitis and the prognosis for very low birth weight infants. Obstetrics and Gynecology 1998;91:725–729.

[4] Romero R, Espinoza J, Goncalves LF, et al. The role of inflammation and infection in preterm birth. Seminars in Reproductive Medicine 2007;25:21–39.

[5] Goldenberg RL, Andrews WW, Goepfert AR, et al. The Alabama Preterm Birth Study: umbilical cord blood Ureaplasma urealyticum and Mycoplasma hominis cultures in very preterm newborn infants. American Journal of Obstetrics and Gynecology 2008;198:e41–45.

[6] Steel JH, Malatos S, Kennea N, et al. Bacteria and inflammatory cells in fetal membranes do not always cause preterm labor. Pediatrics Research 2005;57:404–411.

[7] Redline RW. Placental pathology: a systematic approach with clinical correlations. Placenta 2008;29(suppl A):S86–91.

[8] Arias F, Victoria A, Cho K, Kraus F. Placental histology and clinical characteristics of patients with preterm premature rupture of membranes. Obstetrics and Gynecology 1997;89:265-271.

[9] Redline R, Faye-Petersen O, Heller D, et al. Amniotic infection syndrome: nosology and reproducibility of placental reaction patterns. Pediatric and Developmental Pathology 2003; 6: 435-48

[10] Benirschke KKP, Baergen RN. Pathology of the human placenta. New York: Springer; 2006.

[11] 47 Kraus FT, Redline RW, Gersell DJ, et al. Placental Pathology. In: Atlas of Nontumor Pathology. Washington, DC: Armed Forces Institute of Pathology, American Registry of Pathology; 2004:p75–115.

[12] Redline RW. Inflammatory responses in the placenta and umbilical cord. Seminars in Fetal and Neonatal Medicine 2006;11:296–301.

[13] Qureshi F, Jacques SM, Bendon RW, et al. Candida funisitis: a clinicopathologic study of 32 cases. Pediatric and Developmental Pathology 1998;1:118–124.

[14] Ohyama M, Itani Y, Yamanaka M, et al. Re-evaluation of chorioamnionitis and funisitis with a special reference to subacute chorioamnionitis. Human Pathology 2002;33:183–190.

[15] Fowler KB, Stagno S, Pass RF, et al. The outcome of congenital cytomegalovirus infection in relation to maternal antibody status. New England Journal of Medicine 1992;326:663–667.

[16] Redline RW. Villitis of unknown etiology: noninfectious chronic villitis in the placenta. Human Pathology 2007;38:1439–1446.

[17] Nakamura Y, Sakuma S, Ohta Y, et al. Detection of the human cytomegalovirus gene in placental chronic villitis by polymerase chain reaction. Human Pathology 1994;25:815–818.

[18] Edmondson N, Bocking A, Machin G, et al. The prevalence of chronic deciduitis in cases of preterm labour without clinical chorioamnionitis. Pediatric and Developmental Pathology 2009;12:16-21.

[19] Stanek J, Al-Ahmadie HA. Laminar necrosis of placental membranes: a histologic sign of uteroplacental hypoxia. Pediatric and Developmental Pathology 2005;8:34–42.

[20] Menon R, Camargo MC, Thorsen P, et al. Amniotic fluid interleukin-6 increase is an indicator of spontaneous preterm birth in white but not black Americans. American Journal of Obstetrics and Gynecology 2008;198:e71–77.

[21] Ananth CV, Wilcox AJ. Placental abruption and perinatal mortality in the United States. American Journal of Epidemiology 2001;153:332-337.

[22] Fox HSN, Sebire NJ. Pathology of the Placenta. In: Major Problems in Pathology. Philadelphia: Saunders Elsevier; 2007:p123–337.

[23] Salafia CM, Charles AK, Maas EM. Placenta and fetal growth restriction. Clinics in Obstetrics and Gynecology 2006;49:236-256.

[24] Jacques SM, Qureshi F. Chronic villitis of unknown etiology in twin gestations. Pediatric Pathology 1994;14:575-584.

[25] Bjoro K Jr, Myhre E. The role of chronic non-specific inflammatory lesions of the placenta in intra-uterine growth retardation. Acta Pathologica Microbiologica et Immunologica Scandinavica 1984;92:133–137.

[26] Faye-Petersen OM, Heller DS, Joshi VV. Handbook of Placental Pathology. Oxford: Taylor and Francis; 2006.

IntechOpen