

We are IntechOpen, the world's leading publisher of Open Access books Built by scientists, for scientists

6,900

Open access books available

186,000

International authors and editors

200M

Downloads

Our authors are among the

154

Countries delivered to

TOP 1%

most cited scientists

12.2%

Contributors from top 500 universities



WEB OF SCIENCE™

Selection of our books indexed in the Book Citation Index
in Web of Science™ Core Collection (BKCI)

Interested in publishing with us?
Contact book.department@intechopen.com

Numbers displayed above are based on latest data collected.
For more information visit www.intechopen.com



Hydrosurgery-System® in Burn Surgery – Indications and Applications

Thomas Rapp

Additional information is available at the end of the chapter

<http://dx.doi.org/10.5772/51851>

1. Introduction

- Apart from the extent and depth of burns, inflammatory reactions and infections (caused by impurities, cell detritus, bacterial degradation etc.) impair the healing of burn wounds. Bacterial colonization and invasion significantly influence wound healing (epithelialisation and contraction of the wound) [1]. Early debridement and depth-specific early coverage are currently the standard in the surgical treatment of burns [2,3,8,10]. Basic prerequisites are exact determination of the depth and accurate debridement. Particularly in cases of large burn wounds it is essential to preserve and protect vital tissue. In cases of wide, generous removal of tissue by the use of the Dermatom, Guilon or Humbey knife, one frequently removes more than the actual burned tissue and unnecessarily damages vital tissue. On the other hand, one may remove too little necrotic tissue. The depth of the burn may be difficult to difficult to assess so that the surgeon waits too long, causing valuable time to lapse during which he may well have performed surgical repair. Accurate ablation of the damaged layers of skin and identification of petechial bleeding help to assess the vitality of tissue. This permits exact determination of depth (whether the subpapillary, cutaneous or subdermal plexus are preserved) [9,16] and depth-specific coverage.
- Versajet® is a hydrosurgical system employing a jet of water by which tissue is simultaneously cut, ablated, and suctioned. The wound is rinsed without significant aerosolisation. This system has been approved by the US Food and Drug Administration (FDA) for debridement of wounds and soft tissue as well as CE-certified for ablation of tissue and other substances in various surgical procedures including wound debridement [7]. The system is based on the Venturi principle: a thin high-velocity jet of water consisting of sterile saline is discharged from a 0.12-mm nozzle into a suction tube (see Table 1). The

consistency of the working tip and the velocity of the water jet create a vacuum below the incision window. This aspirates, cuts and suctions the tissue. As the handpiece is held parallel to the wound the high-pressure water jet acts as a scalpel. When the working tip is tilted slightly the scalpel effect of the water jet is reduced while the rinsing and suction effect is enhanced. Furthermore, the quantity of ablated tissue is determined by the pressure settings at the console (1-10), the pressure exerted by the surgeon, and the speed at which the handpiece is moved on tissue. The console is operated by a foot pedal. Hydro-surgical systems have been in use for a large variety of indications [14]. However, they have not entered burn surgery thus far. Further development of the concept led to a more modern system, namely the Versajet® system, which works precisely and simply. A number of handpieces are currently available for various purposes. They differ in terms of the size of the surgical window and the angle of the working tip: 8 mm surgical window, 45° angle, 14 mm surgical window, 15° or 45° angle of the working tip. Furthermore, the different holders are also available in a Versajet plus® variation which enables the surgeon to forcefully ablate tough tissue. The basic principles underlying this concept were derived from histological investigations. The exact layer-wise removal of tissue components achieved by this procedure is of the same quality as that achieved by laser ablation. The Versajet system® was also successfully used for the treatment and the removal of dirt-tattoos/pigment deposits.

Pressure levels	Flow rate of the jet	Velocity of water pressure
1	90 ml/min	103 bar 426 km/h
3	125 ml/min	265 bar 591 km/h
7	188 ml/min	587 bar 885 km/h
10	230 ml/min	827 bar 1078 km/h

Table 1. Physical data

2. Case 1

Figures 1 to 5 show a 6-year old boy with partial to full thickness scalds in the neck. Large portions of the chest were also affected. Necrosectomy with Versajet® (at levels 5–7) and subsequent coverage with unmeshed split-thickness skin graft were performed on the 4th day after the accident. Fat gauze was placed on the grafts. A collar was provided to protect the grafts and immobilize the neck postoperatively. On the 6th postoperative day the split-thickness skin grafts had healed in a stable manner. Bacterial investigations performed before and after the treatment showed no microbial growth. The functional outcome after six months was favourable.

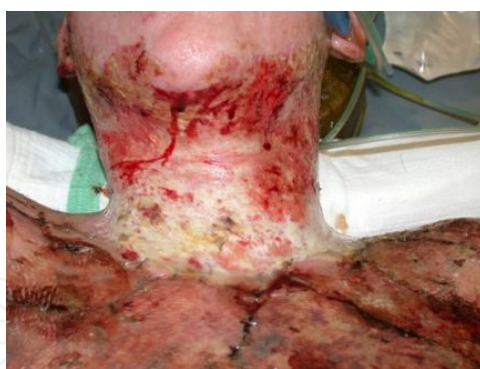

Figure 1. 6-year-old boy, grade partial to full thickness scalds in the chest and neck, 11% of body surface.

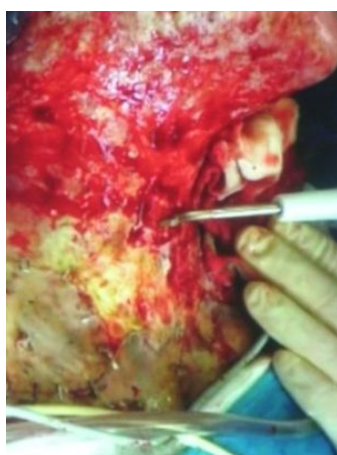

Figure 2. Necrosectomy with Versajet®.

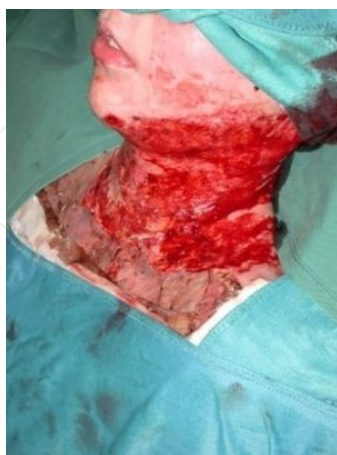

Figure 3. After necrosectomy.

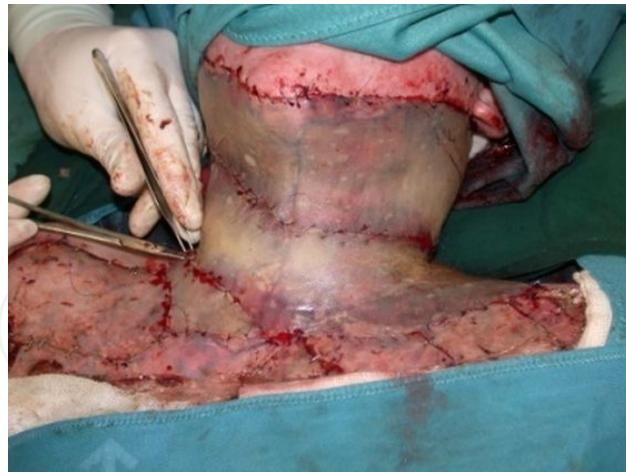

Figure 4. Split-thickness skin graft, unmeshed

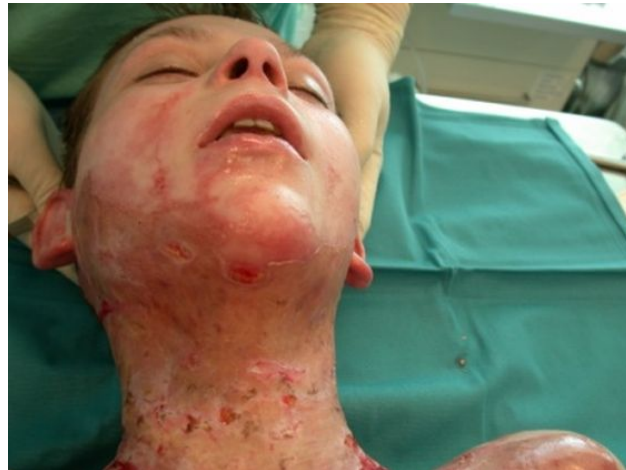

Figure 5. 10 days postoperatively

3. Case 2

Fig. 6 to 10 show a 45-year-old man who developed partial to full thickness-burns in both hands and partial thickness burns in the forearm and face during a car accident. Necrosectomy with Versajet® (at levels 3–5) and split-thickness skin grafting on the dorsum of the left hand were performed on the 2nd day after the accident. The hand covered with a split-thickness skin graft was covered with fat gauze and immobilized with a splint for 6 days. The remaining burned areas were superficially cleaned with Versajet® (at level 3) and treated with Acticoat because the smears showed colonization of germs in the wounds. On the 6th postoperative day the split-thickness skin grafts had healed in a stable manner. The smears showed no microbial growth. Function and aesthetics were satisfactory after six months.

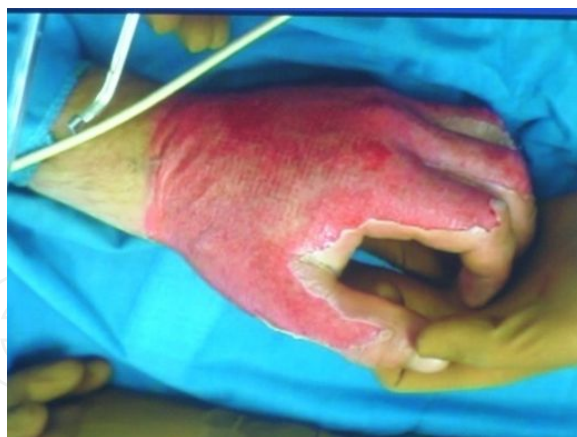

Figure 6. 45-year-old man, grade partial thickness burns on both hands

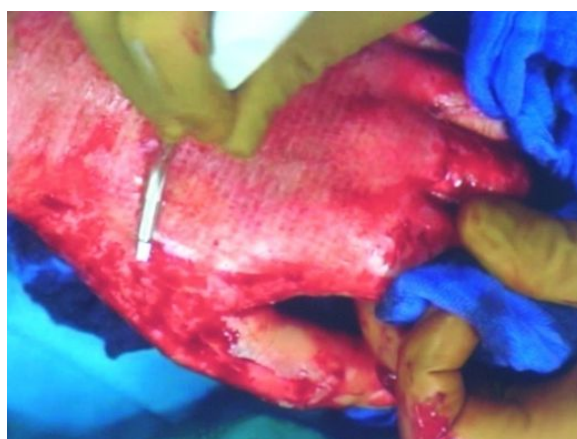

Figure 7. 45-year-old man, grade partial thickness burns on both hands

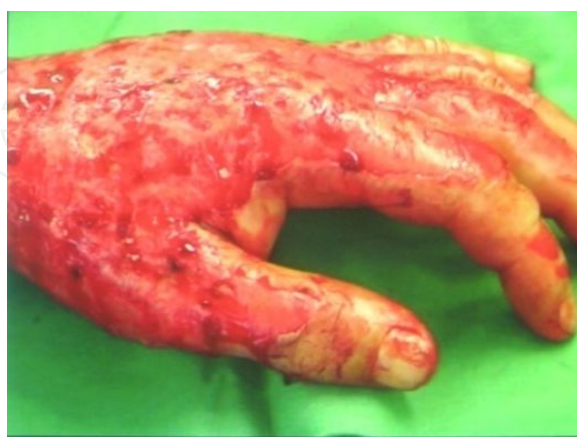

Figure 8. Post debridement

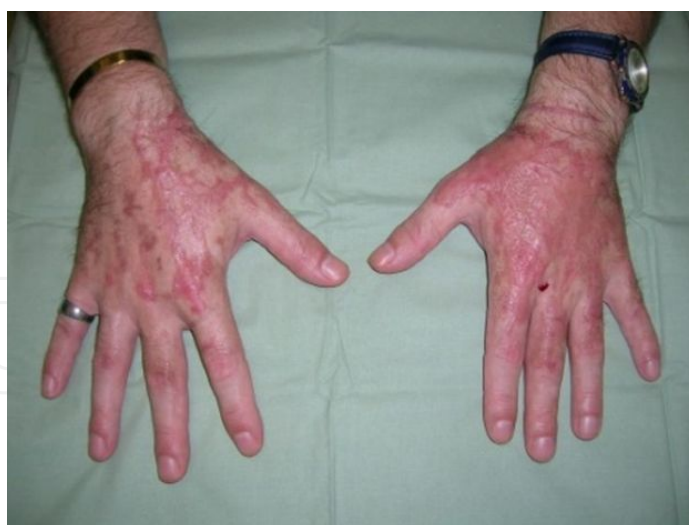

Figure 9. 6 months postoperatively, the left hand is covered with a split-skin graft while the right hand was treated by conservative means

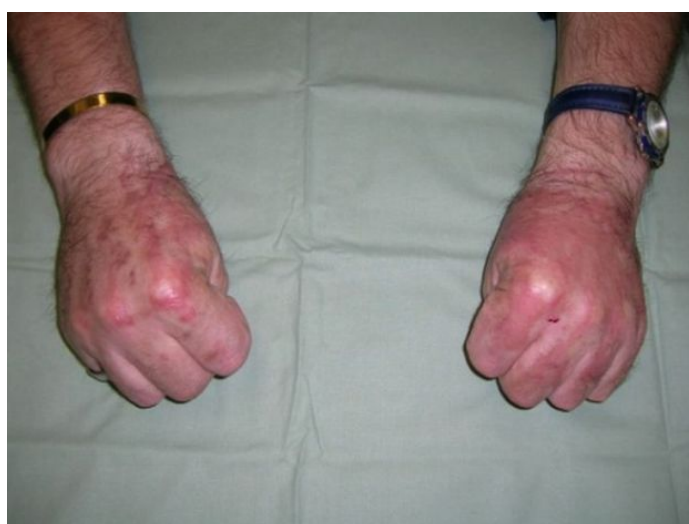

Figure 10. 6 months postoperatively, the left hand is covered with a split-skin graft while the right hand was treated by conservative means

4. Case 3

Fig. 11 to 12 show a 40-year-old man who partial thickness burns in the face covered with pigment deposits after an explosion. Dirt tattoos has been removed by using the hydro surgery system at level 3 with a very superficial removal of the pigment deposits. Uneventful healing shows a clean skin after 2 weeks without scarring.

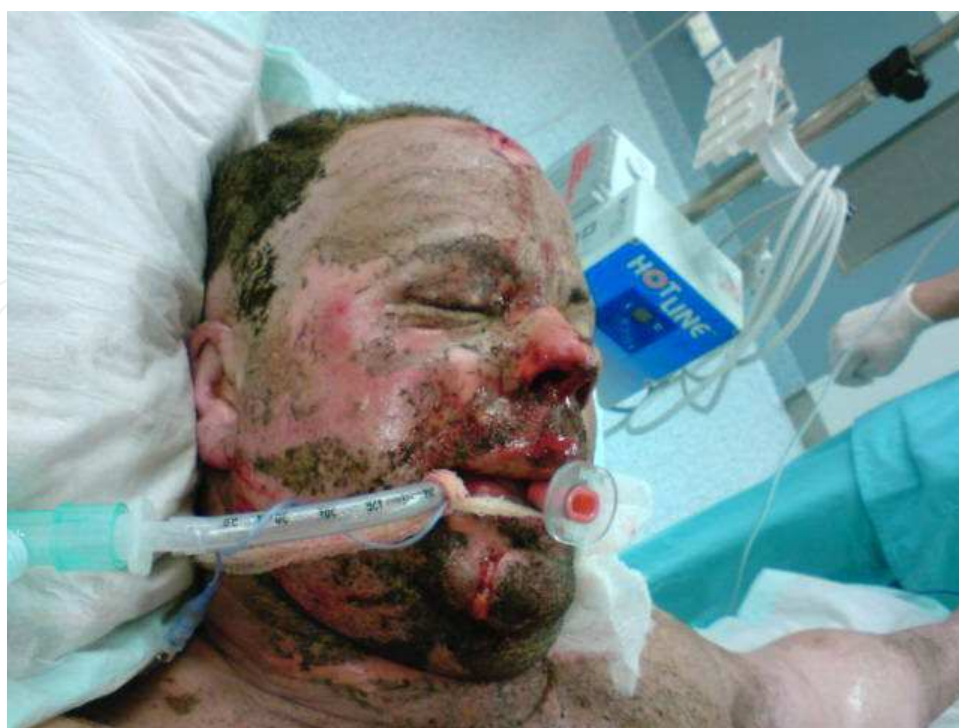

Figure 11.

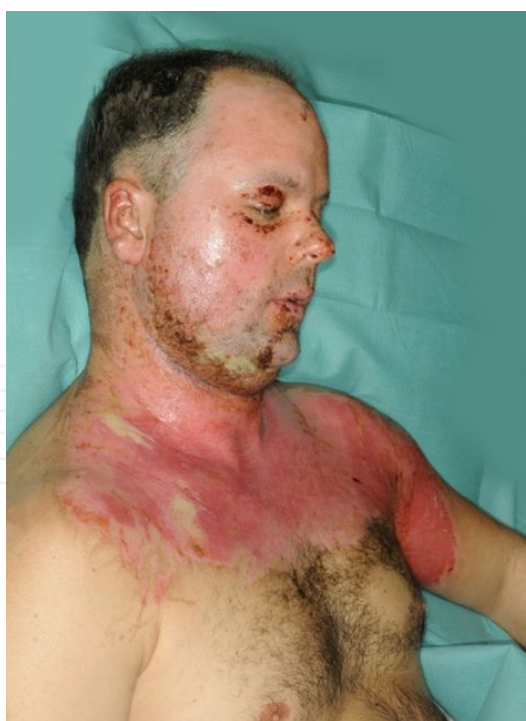

Figure 12.

5. Results

The experience shows that in cases of full thickness burns a necrosectomy with the Dermatom, Humbey knife or the scalpel could be performed rapidly and efficiently. In these cases Versajet® was of use only in marginal zones or to provide the wound with the necessary finishing touches. Tissue damaged in a leathery fashion could not be ablated rapidly or satisfactorily even by the use of Versajet plus®. In contrast, the advantages of Versajet in the treatment of partial thickness burn wounds are worthy of mention. In particular, burns in complex, inaccessible areas are an indication for the use of this hydrosurgical system. In the region of the face (the lips, eyelids, etc.) debridements can be performed with a degree of precision that is hardly achievable by the use of conventional methods. Furthermore, necrosectomy in the region of the hand (fingers, interdigital spaces, etc.) can be significantly improved by the use of Versajet®. In burn surgery convex surfaces could be ablated uniformly and concavities curetted with precision. Pigment deposits could be completely removed. Histological investigations prove and confirm the precision of ablation by the use of Versajet®.

Fig. 13: This technique permits ablation of clearly defined anatomical structures. Removal of the most superficial layers of skin, dermal papillae/papillary dermis (Fig. 13a). Layer of the superficial reticular dermis, removal of the epidermis, the papillary dermis, and superficial portions of the reticular dermis (Fig. 13b). Layer of the mid reticular dermis (Fig. 13c).

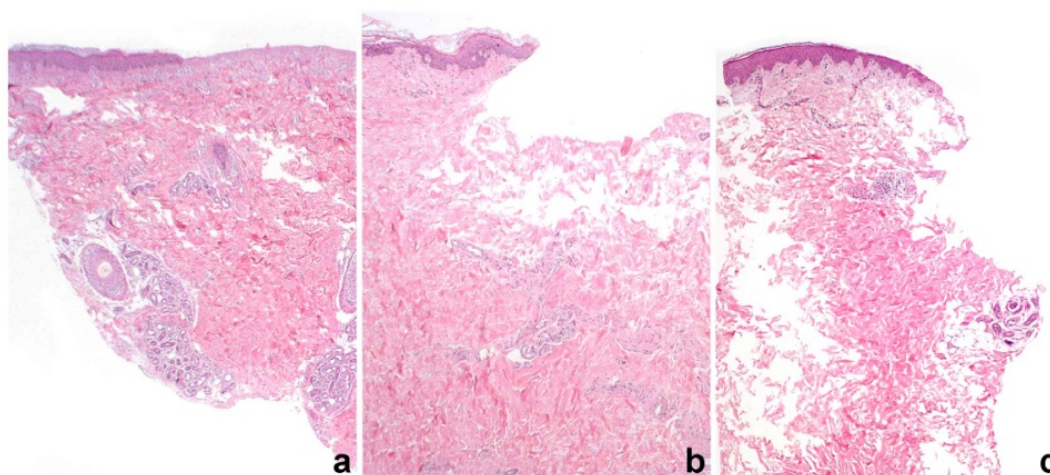


Figure 13. a to c, Layer-wise ablation with Versajet®, a. papillary layer, b reticular layer in the middle, c Reticular layer, deep

In cases of large partial thickness burns this method was very helpful to achieve effective wound debridement. At level 2-3, impurities, coatings and cell detritus could be removed in a simple, rapid and gentle manner and microbial growth could thus be reduced. Smears and

biopsies taken before and after the treatment showed marked reduction of microbial growth in all cases. In superficial wounds that could be treated with Versajet® we observed more rapid re-epithelialisation compared to conservative treatment on the side with the same depth of burns treated with fat gauze. In no case did we encounter side effects or undesired events. Steps, unevenness or ridges in tissue were caused by lack of practice, but could be corrected during the procedure. Postoperative wound dressing was performed according to the general guidelines of burn treatment.

6. Discussion

Surgical debridement as the most common technique for necrosectomy is done using scalpels, forceps, scissors, and other instruments. It is used if your wound is large, has deep tissue damage. It may also be done if debriding the wound is urgent. The skin surrounding the wound is cleaned and disinfected and the damaged tissue is cut away. The wound will be washed out to remove any free tissue. In large damaged areas of full thickness burns, cutting away the entire contaminated wound may be the most rapid and the most effective treatment.

Using *Chemical /enzymatic debridement* a debriding medicine will be applied onto the wound. The wound is then covered with a dressing. The enzymes in the medicine dissolve the dead tissue in the wound. Chemical enzymes are fast acting products that produce slough of necrotic tissue. Some enzymatic debriders are selective, while some are not. Best results are shown on any wound with a large amount of necrotic debris. The main disadvantages of the enzymatic debridement are: costs, a specific secondary dressing may be necessary and sometimes inflammation or discomfort may occur.

Mechanical debridement can involve a variety of methods to remove dead or infected tissue. Allowing a dressing to proceed from moist to wet, then manually removing the dressing causes a form of non-selective debridement. Wet to dry dressing starts by applying a wet dressing to the wound. As this dressing dries, it absorbs wound material. The dressing is then remoistened and removed. Some of the tissue comes with it. This method is useful for wounds with moderate amounts of necrotic debris. This treatment is non-selective and may traumatize healthy or healing tissue, is time consuming and can be painful to patient. Hydrotherapy can cause tissue maceration. Also, waterborne pathogens may cause contamination or infection. Disinfecting additives may be cytotoxic. There are nearly no indications in burn-surgery for this kind of debridement.

Autolytic Debridement uses dressings that retain wound fluids that assist your body's natural abilities to clean the wound. This type of dressing is more often used to treat pressure sores than burns. This process takes more time than other methods. It will not be used for wounds that are infected or if quick treatment is needed. It is a good treatment if the body cannot tolerate more forceful treatments, it's a selective, effective, easy and safe process with no damage to surrounding skin, using the body's own defence mechanisms to clean the wound of necrotic debris, with little to no pain for the patient. But it's not as rapid as surgical debridement, the wound must be monitored closely for signs of infection. Promote anaerobic

growth may occur, if an occlusive hydrocolloid is used. Because of the time consuming process we won't recommend this treatment for debridement of burned tissue.

Hydrosurgery permits accurate intraoperative diagnosis of the depth of burns. The petechial bleeding that occurs during necrosectomy shows that the subpapillary plexus is preserved and the burn may be treated by conservative means. Nevertheless, one should not hesitate to perform skin transplantation if necessary because the risk of hypertrophic scar formation is very high when necrosectomy is insufficient and no coverage provided [3]. With regard to superficial wound debridement the hydrosurgical system is superior to other procedures (such as jet lavage) because it simultaneously cleans the wound and carries away the ablated particles without significant aerosolisation. Several methods are available for debridement and conditioning of the wound bed [5, 6]. Sharp physical debridement is of undisputed value for the treatment of full thickness burns. In cases of 28 burns the advantages of Versajet® in respect of handling and precision have been mentioned earlier. Versajet and laser ablation were found to be of equal quality with regard to the depth of layers and accuracy. A major advantage of Versajet® is the duration of the treatment. More than one treatment session is rarely necessary. The achievable outcome is identical on histology as well as gross investigation. In the hands of an experienced user Versajet® has no disadvantages or side effects compared to other methods. In order to achieve the best possible outcome in complex concave or convex regions, a certain amount of experience in using the device is required. Particularly in the eyelids, the surgeon must have sufficient experience in handling the apparatus. The learning curve is quite steep. After a few treatments the operator will be confident enough to treat complex sites at no risk. However, it should be ensured that the settings at the console are initially low (level 3-5) because a higher intensity causes more aggressive ablation, which may be associated with disadvantages such as irregularities and step formation in tissue. In most cases the moderate setting (setting 5-8) is used and has proved to be adequate. As the handpiece is a disposable system, the question of cost-effectiveness arises. However, by using Versajet® early the surgeon is able to rapidly establish the indication for reconstruction. The additional cost is balanced by the fact that the duration of the hospital stay is shortened [7].

7. Conclusion

As rapid debridement and immediate deep coverage should be performed for the reasons mentioned at the beginning of this report as well as to avoid the risk of hypertrophic scar formation [12], Versajet® fulfils standards of precision, rapid intervention and simple handling. The special domain of Versajet® is partial thickness burns, particularly in poorly accessible anatomical regions [4,13]. These regions can be treated and debrided more effectively by the use of hydrosurgical systems than with conventional methods. By means of layer-wise ablation the surgeon is able to identify healthy tissue immediately and protect it in the best possible manner. Intraoperative diagnosis of the depth of burns is also achieved by this procedure. Owing to these advantages the Versajet® system has become a standard procedure in burn surgery.

Author details

Thomas Rappl

Department of Plastic, Aesthetic & Reconstructive Surgery, Medical University Graz, Austria

References

- [1] Bojrab MJ: A Handbook on Veterinary Wound Management. Ashland, OH: KenVet Professional Veterinary Company, 1994
- [2] Breie Z, Zdrovic F: Lessons learned from 2409 burn patients operated by early excision. *Scand J Plast Surg* 1979; 13: 107–118
- [3] Burke JF, Quimby WC, Bondoc CC: Primary excision and prompt grafting as routine therapy for the treatment of thermal burns in children. *Surg Clin N Am* 1976; 56: 477–494
- [4] Cubison TC, Pape SA, Jeffery SL: Dermal preservation using the Versajet® hydro-surgery system for debridement of paediatric burns. *Burns* 2006; 32: 714–720
- [5] Eldad A, Weinberg A, Breiterman S, Chaouat M, Palanker D, Ben-Bassat H: Early nonsurgical removal of chemically injured tissue enhances wound healing in partial thickness burns. *Burns* 1998; 24: 166–172
- [6] Falabella AF: Debridement and wound bed preparation. *Dermatologic Therapy* 2006; 19: 317–325
- [7] Granick MS, Possnett JW, Jackoby M, Noruthum S, Ganchi P, Daliashvili R: Efficacy and cost-effectiveness of the high powered parallel water jet for wound debridement. Poster, EWMA, Stuttgart, 2005
- [8] Herndon DN, Gore D, Cole M et al.: Determinants of mortality in pediatric patients with greater than 70% full thickness total body surface area thermal injury treated by early total excision and grafting. *J Trauma* 1987; 27: 208–212
- [9] Jackson DM: The diagnosis of the depth of burning. *Br J Surg* 1953; 40: 588–596
- [10] Janzekovic Z: A new concept in the early excision and immediate grafting of burns. *J Trauma* 1970; 10: 1103–1108
- [11] Kamolz LP, Andel H, Haslik W, Winter W, Meissl G, Frey M: Use of subatmospheric pressure therapy to prevent burn wound progression in human: first experiences. *Burns* 2004; 30: 253–258
- [12] McDonald WS, Deitch EA: Hypertrophic skin grafts in burned patients: a prospective analysis of variables. *J Trauma* 1987; 27: 147–150

- [13] Rennekampff H-O, Schaller HE, Wisser D, Tenenhaus M: Debridement of burn wounds with a water jet surgical tool. *Burns* 2006; 32: 64–69
- [14] Shekarriz B, Shekarriz H, Upadhyay J, Wood DP, Bruch HP: Hydro-jet dissection for laparoscopic nephrectomy: a new technique. *Urology* 1999; 54: 964–967
- [15] Sheridan RL, Lydon MM, Petras LM, Schomacker KT, Tompkins RG, Glatter RD, Parrish JA: Laser ablation of burns: initial clinical trial. *Surgery* 1999; 125: 92–95
- [16] Womack BS: Wound management: healing & assessment. *Veterinary Technician* 2001; 22: 588–594