

We are IntechOpen, the world's leading publisher of Open Access books Built by scientists, for scientists

6,900

Open access books available

185,000

International authors and editors

200M

Downloads

Our authors are among the

154

Countries delivered to

TOP 1%

most cited scientists

12.2%

Contributors from top 500 universities



WEB OF SCIENCE™

Selection of our books indexed in the Book Citation Index
in Web of Science™ Core Collection (BKCI)

Interested in publishing with us?
Contact book.department@intechopen.com

Numbers displayed above are based on latest data collected.
For more information visit www.intechopen.com



Vascular Access for Hemodialysis - Overview and Emphasis on Complications

Octavio J. Salgado

Additional information is available at the end of the chapter

<http://dx.doi.org/10.5772/53220>

1. Introduction

A functioning vascular access (VA) represents a key issue in the management of patients needing acute or chronic hemodialysis (HD). However, VA surgeons, interventionists and all involved in VA creation and preservation are facing an everyday challenge, a huge one: How to meet their HD patients' VA needs. Most centers over the world are currently taking care of a steadily increasing and aging HD population, with more and more comorbidities, particularly diabetes mellitus, as well as of a growing proportion of prevalent patients with history of multiple access failures. With help of both autogenic and graft materials it has been possible to develop up to the present a wide armamentarium of VA options. However, all access alternatives are plagued with the same problems as in the past decades: thrombosis, infection, steal, etc, all of which limit their time span. In addition, anatomic sites for access creation are limited and may become exhausted. Every VA that fails brings the patient one step closer to a terminal access problem, a point where all roads seem closed. To avoid reaching this point, every VA team should be able, through careful planning and systematic application of adequate techniques for VA creation and preservation, to reduce VA-related complications to a minimum. In this chapter, a general overview of the field of VA for chronic hemodialysis in adult patients is offered where the most relevant topics are mentioned and briefly discussed. It is by no means an exhaustive review but we hope this way to convey an idea of the magnitude and complexity of the VA-related problematic and their possible solutions. We have dispensed with including details of VA history since a lot of well documented work on this issue is available in the literature.

2. Temporary blood accesses for HD

Temporary access in current nephrological praxis is synonymous with double lumen catheters whose main goal is to serve as interim VA. Emergent HD in a patient with chronic kidney disease (CKD) is the commonest indication for HD catheter insertion. It is a known fact that in most countries over the world a significant proportion, if not the majority of CKD patients starting HD do not have a functioning PVA [1]. Some of the reasons for this trend are:

- a. many patients seek specialized medical care for the first time when frank uremic symptoms are present,
- b. late referral to either a nephrologist or
- c. to the access surgeon, etc, which do not allow for a permanent VA to be timely created.

Two types of double-lumen catheters are used for emergent acute or chronic HD:

- a. non-tunneled, uncuffed (NTC) also called acute or temporary catheters, and
- b. Tunneled, cuffed catheters (TC, called “permanent” catheters).

2.1. Non-tunneled catheters (NTC).

NTC are still the most commonly used catheter type for emergent HD and can be readily inserted, exchanged and withdrawn either at bedside or in a procedure at any center or outpatient dialysis facility. Although NTC are deemed to be used for a short dwell times (< 3 weeks), in some centers they are used for extended periods. Eventually, they are even exchanged for up to 2 times in case of malfunction [2].

2.1.1. Insertion technique

Typical NTC insertion method is the Seldinger technique, which consists in placing a catheter percutaneously through a guidewire [3]. Once inserted, the NTC should be firmly fixed to the skin by means of a monofilament nonabsorbable synthetic suture (polypropylene or nylon). Multifilament, also called “braided” sutures like silk, should not be used because bacteria may hide within the interstices of the braids and this way the catheter entry site may become secondarily infected. A loose fixation of the catheter to skin causes a constant in- and outward movement of the catheter through entry site which favors bacterial colonization and infection. Dehiscent sutures lead to partial or total catheter extrusion. In case of partial extrusion, no attempt should be done to reintroduce the catheter but rather, if deemed safe, it may be exchanged over a guidewire.

2.1.2. Insertion sites

The preferred insertion site is the right internal jugular vein (IJV) mainly because in a great majority of cases it does not interfere with ulterior AV access creation on the ipsilateral upper extremity [4]. On the contrary, catheterization of the left IJV is not equally safe as the right one and is associated with left innominate vein stenosis or thrombosis [2,5]. Femoral veins are safer

vein accesses in emergency settings particularly in patients with high risk of bleeding [6]. However, when left in place for extended periods, femoral catheters may lead to stenosis and thrombosis of the external and/or common iliac veins causing significant impairment of venous drainage of the lower limbs with mild to severe, painful edema. In transplantation candidates, external iliac vein thrombosis, which can extend up to common iliac vein may preclude ulterior renal graft placement on the affected side. With respect to subclavian vein approach, the KDOQI guidelines [7] strongly recommend its avoidance unless:

- a. permanent access creation on the ipsilateral extremity is not possible because of severe arterial occlusive disease,
- b. all potential access sites on the side are exhausted, or
- c. when there is no other option.

Subclavian vein stenosis or thrombosis are a sequelae of 20 to 50% of subclavian vein catheters, which usually preclude ulterior use of ipsilateral arm for PVA creation [4]. Endovascular procedures like balloon angioplasty or stenting have proved useful in restoring central vein patency [8].

2.1.3. Ultrasound guidance

Real-time ultrasound guidance decreases significantly the rate of puncture-related complications in the case of IJV cannulation [9]. Landmark-guided puncture may be an acceptable alternative in experienced hands. Regardless of the employed insertion technique, in patients with history of previous IJV catheterization, checking sonographically for IJV patency (Figure 1) before making any catheter insertion attempt is strongly advised.

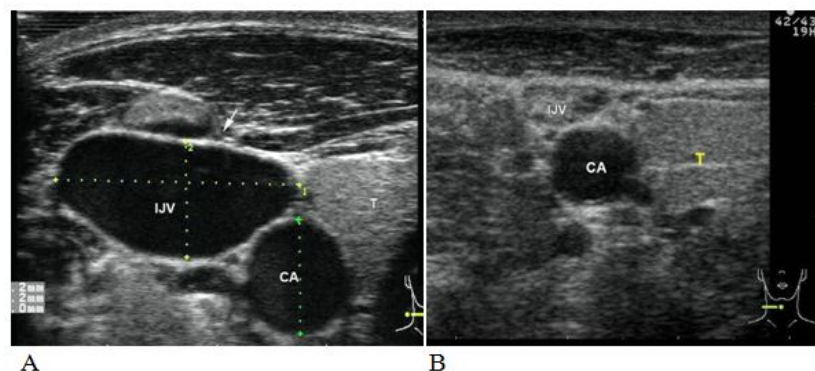


Figure 1. A) Normal ultrasound appearance of the right internal jugular vein (RIJV). (B) RIJV damage after catheterization.

2.1.4. Control chest radiographs

(for superior vena cava catheters) or an abdominal plain film (for femoral catheters) should be done to verify catheter tip position. Ideally, both posteroanterior and lateral thorax views

may be needed to better assess catheter location. Normally, catheter tip should lie at the junction of the vena cava with the right atrium so that the catheter side openings are located into the caval lumen (Figure 2). Catheter malposition (Figure 3) and puncture-related complications can also be readily diagnosed with chest radiographs in two views.

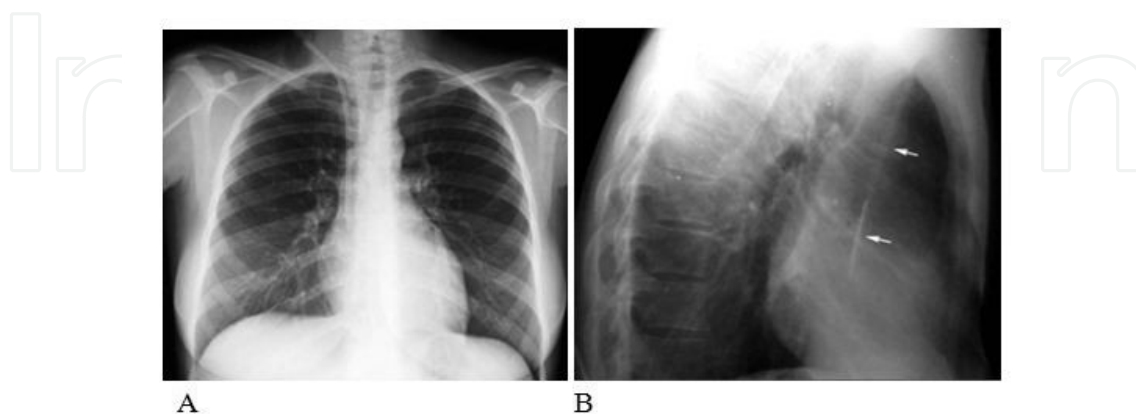


Figure 2. A) Posteroanterior chest X-ray showing normally located right-sided internal jugular vein catheter. (B) Normal lateral view of the catheter (arrows).

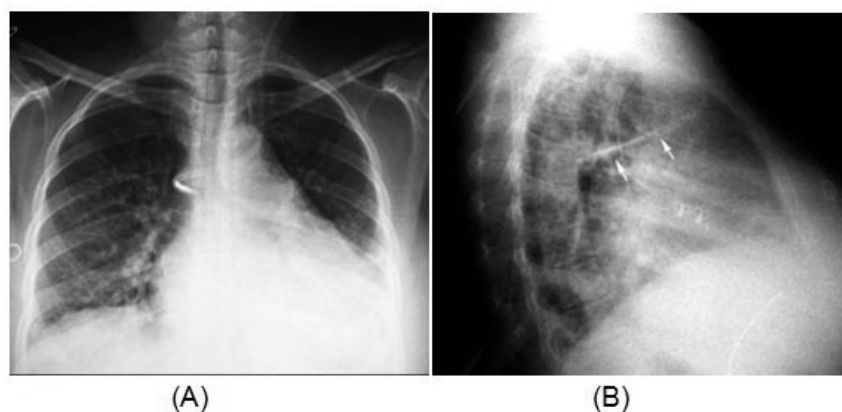


Figure 3. A) Abnormal location of a left-sided internal jugular vein catheter. Lateral thorax view (B) shows catheter tip (arrow) and side openings into the azygos vein.

2.1.5. Catheter length

The distance from insertion site to venoatrial junction may vary according to patients anatomy (height, obesity), thorax length and shape, central vein configuration and insertion route. However, as a rule of thumb, a catheter of 15-16 cm in length catheters may be adequate when placing right-sided internal jugular veins in adults. A 17.5-20 cm long catheters is required for either left internal jugular or left subclavian vein approach [10]. Femoral catheters should be 20-25 cm in length depending on insertion point and patient's physiognomy (i.e. obesity).

2.1.6. Catheter dysfunction

NTC malfunction may be due to non-thrombotic causes like catheter misplacement, kinking, use of inappropriate catheter length and formation of pericatheter fibrin sleeve [11]. Thrombotic catheter occlusion is usually due to either intraluminal and/or mural thrombus formation. Malfunctioning catheters, except those having a fibrin sheath, mural thrombus or some evidence of infection can be exchanged over a guidewire. Biofilm formation begins immediately after catheter insertion by bacteria that has been carried by the catheter surface from skin entry site. With time, biofilm turns into a fibrin sheath or sleeve that covers side openings and adheres to the entire external surface of most catheters [12]. In advanced stage, a total extraluminal encasement of the catheter occurs causing backflow of blood which goes out through the catheter insertion orifice when dialysis pump is started. Thus, bleeding through catheter entry site only during HD indicates the presence of a fibrin sleeve and, the catheter should be removed. However, much of the fibrin sleeve may remain adhered to the vein wall after catheter removal [13] (Figure 4).

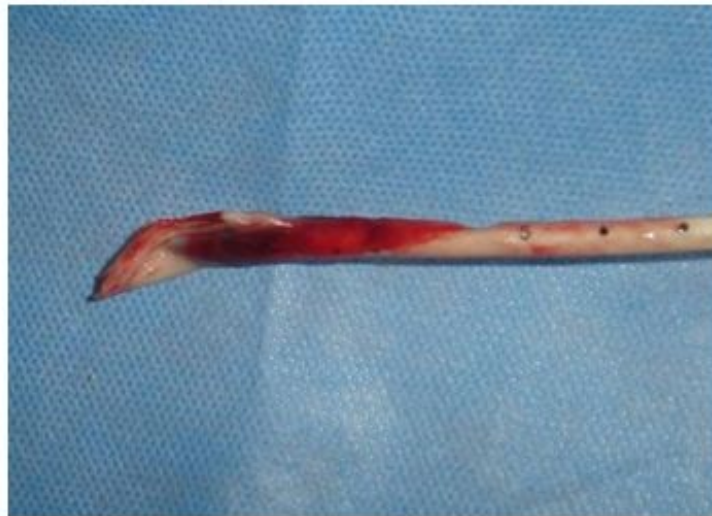

Figure 4. Catheter tip with adhered fibrin sheath.

Catheter exchange after balloon disruption of the sleeve has been reported to be a successful procedure in such cases [12]. Too short left-sided IJV or subclavian catheters may cause catheter malfunctioning as tip and side openings will lie within the lumen of the left innominate vein whose caliber and flow are lower than that of the vena cava [8].

2.1.7. Arterial Puncture

Central vein catheterization in patients with ESRD bears a higher risk of bleeding because of disturbances in platelet adhesion and aggregation. Carotid artery puncture can lead, if unadvertent, to formation of a big hematoma which can further extend in the neck and upper mediastinum causing external airway compression [14]. Mediastinal hematoma is a

rare but feared complication after inadvertent arterial puncture. Pneumothorax, hemothorax and chylothorax are complications more related to subclavian than to IJV cannulation. Femoral artery puncture can also lead to formation of huge hematomas at the groin. Retroperitoneal hematoma is also an extremely rare complication and results from inadequate puncture technique.

2.1.8. Bleeding at entry site

Bleeding around catheter entry site is most commonly due to a wide skin opening. Applying compression at entry site with sterile dressing may suffice to stop bleeding. Otherwise, the orifice can be reduced by stitching with 6x0 nylon suture which is usually effective to achieve local hemostasis. To prevent this complication, the size of the skin incision must be tailored as small as possible so that the catheter, once in place, fits tightly in the orifice. Persisting bleeding with bulging at puncture site points at a more serious cause of the bleeding and the patient should be immediately evaluated by a vascular surgeon. As mentioned before, bleeding only during HD is highly suggestive of encasement of the catheter by a fibrin sheath.

2.1.9. Catheter infection

Early infection of a new inserted catheter indicates poor aseptic conditions at the time of placement or inadequate catheter handling during HD or at home. Infected catheters may be the starting point of bacteremia and sepsis and there is an increased risk of metastatic complications, including endocarditis, septic arthritis, and epidural abscess. The relative risk of bacteremia is 7-fold higher in CKD patients with catheters than in those with an autogenous PVA [15]. Staph aureus and other grampositive bacteria like coagulase-negative staphylococcus and enterococcus are the most commonly isolated agents in infected catheters [16]. Cultures of blood, entry site exudate and catheter tip play a key role in identifying the causative agent. Sensitivity tests to different antimicrobials with determination of minimal inhibitory concentration (MIC) are the basis for an effective antibiotic treatment.

2.1.10. Central vein stenosis and thrombosis

Despite improved catheter technology and better biomaterials, central vein stenosis continues to be the most serious middle- and long-term complication of HD catheters. Central vein stenosis may preclude permanent VA creation on the ipsilateral upper or lower extremity. Clinically, the development of superficial vein collaterals on the affected side or the development of limb swelling after ipsilateral arteriovenous access creation should raise the suspicion of central vein occlusion. This diagnosis can be confirmed by imaging procedures like angiotomography or MRI. In the past decades, endovascular procedures like percutaneous transluminal angioplasty (PTA) or percutaneous transluminal stenting (PTS) has proven useful and safe to recanalize occluded central veins with low rates of technical failure. However, multiple additional interventions are the rule with both treatment modalities since neither of them offer truly durable outcomes nor add to the longevity of the ipsilateral access [17]. Superior vena cava syndrome is an extreme manifestation of central vein stenosis and

results from multiple catheter insertions [18]. Femoral vein catheters may cause stenosis and thrombosis in the femoro-iliac axis precluding kidney graft placement on the affected side.

2.1.11. Postcatheterization arterial pseudoaneurysms and arteriovenous fistulas

are usually of iatrogenic origin. Some of them can close spontaneously. US guided compression has proven effective some cases. If ineffective, a more invasive treatment should be attempted. The standard approach has been surgical but currently, percutaneous endovascular implantation of covered stents has been reported to yield similar results while being less invasive [19].

2.2. Tunneled catheters (TC)

TC are made either of polyurethane, carbothane (polycarbonate-based polyurethane) or silicone. They are available in many shapes (straight or pre-curved), sizes (12-16 Fr), lengths (16-50 cm from tip to cuff) and tip forms (rounded, stepped or splitted). In addition, they may consist of either two single lumen catheters as the original Tesio catheter, which has 2 independent 10F catheters [20], or a double lumen device. All are provided with a polyester cuff favoring tissue in-growth for fixation of the catheter into the subcutaneous tunnel. TC can be either placed de novo or in exchange for a nontunneled catheter using the same insertion site without increased risk of infection [21,22].

2.2.1. Catheter insertion technique

A detailed description of all technical aspects of TC implantation are beyond the scope of this chapter. In principle, TC implantation technique is similar to that of NTC but a subcutaneous tunnel is additionally created to lodge the external segment or extension of the catheter. Catheter placement can also be done at a procedure room within the HD unit. TC offer some advantages over NTC. Tunneling from the neck to an exit site at the right or left upper chest quadrant below the clavicle brings greater comfort to patients, catheter extensions can easily be covered by dressings, concealed by clothing and, in addition, TC are suitable for outpatient management and care [23]. However, their disadvantages are many and far outweigh their advantages [24]. In this regard, it should be underscored that tunneling does neither prevent nor make less severe central vein occlusion, which is the most feared middle- and long-term complication of all HD catheters.

2.2.2. TC infection

TC have been found to reduce the incidence of catheter-related bloodstream infection particularly when antibiotic lock is additionally used [25]. However, contrary to NTC, TC are not routinely withdrawn as first move in case of infection. Removal is only done in case of persistent infection or infection recurrence nonresponsive to antimicrobial therapy. Therefore, a major concern in such cases is the emergence of multidrug-resistant bacteria. Long-term indwelling TC are associated with five- to ten-fold increased risk of bacteremia and sepsis, significantly higher mortality risk, decreased likelihood of adequate dialysis, more frequent

hospital admissions and more frequent need for access surgeries [26,27]. It is essential to have cultures with blood drawn from catheter lumen as well as from a peripheral vein. Catheter infection can be confirmed by isolation of the same agent in both samples, particularly if the UFC count is 4-fold higher in the luminal sample than in the peripheral blood sample. Initial empirical administration of broad spectrum antibiotics should be followed by specific antibiotics when sensibility tests with minimum inhibitory concentration (MIC) data are available.

2.2.3. TC occlusion

Dysfunctional TC due to thrombotic occlusion requires administration of thrombolytic therapy to restore flow, decrease venous dialysis pressure and increase dialysis delivery. Tissue-type plasminogen activator (tPA, alteplase), is currently the only recommended antithrombotic agent for failing TC [28]. Single intraluminal instillation (in 30- 60 minutes) of low-dose (1 mg/ml) alteplase has been shown to increase catheter flow with significantly more patients achieving $Q_b=300$ ml/min than with urokinase (5000 U/ml) (70% *versus* 35%; $P<0.013$) and completing an HD session (93% *versus* 70%; $P=0.023$) [28]. TC are used as definite access in patients who have exhausted all options for PVA creation, cardiac failure, severe occlusive peripheral disease or those with limited life span. Exceptionally, TC may be placed in unusual locations, like inferior vena cava (Figure 5) or left atrium.

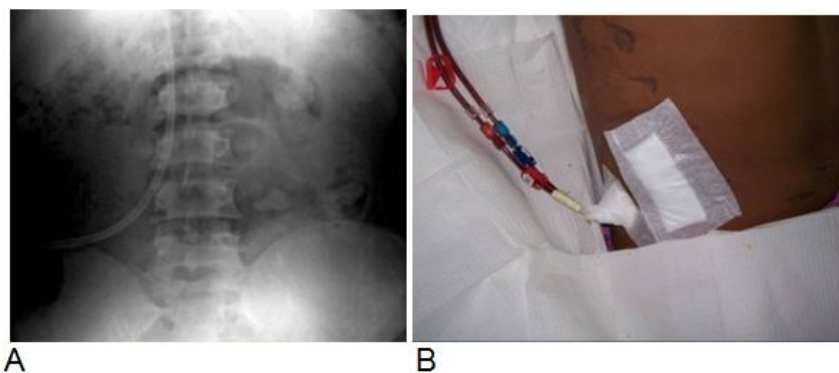


Figure 5. A) Tunneled catheter placed into the inferior vena cava. (B) Catheter being used for HD.

3. Permanent vascular HD accesses (PVA)

3.1. Measures to increase autogenic VA creation

3.1.1. Preservation of usual vascular sites for PVA creation

Preserving peripheral veins at both upper extremities (not only at the non-dominant side) as well as both subclavian veins is the mainstay for an ulterior successful PVA creation. The

major veins of the upper extremity like the cephalic and basilic, eventually also the cephalic accessory, are the only appropriate vessels for creation of a fistula or graft and should not be routinely used for administration of fluid or medication, especially when irritating, because they may cause irreversible endothelial injury. Indiscriminate peripheral venipuncture is the first cause of loss of adequate veins for VA creation. Nursing personnel should be advised to use alternative veins like hand dorsum veins (Figure 6), the median or intermediate antebrachial vein and other minor forearm veins for intravenous fluids and medications. If there is some compelling need to use any of the major arm veins, cannulation should be done only for short periods of time, using small gauge needles, and rotating puncture sites to prevent phlebitis and thrombosis. Patients should ideally receive education about the importance of vein preservation.

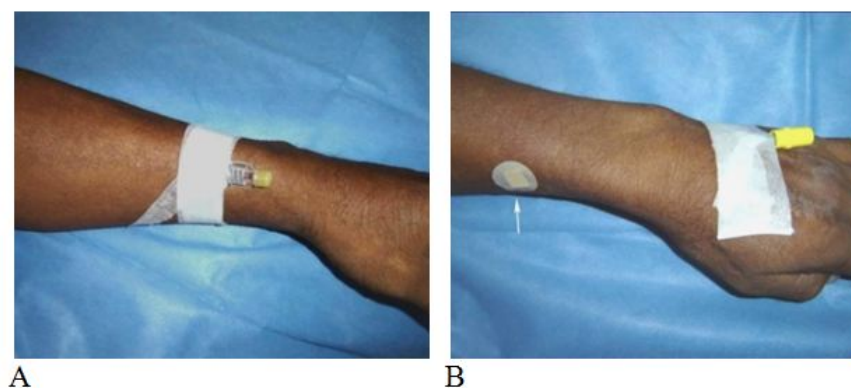


Figure 6. Preventing damage of peripheral veins. Venous cannula in the cephalic vein of a CKD patient (A) is removed and placed in a hand dorsum vein (B).

3.1.2. Optimal timing for access creation

The exact timing of placement of VA should be determined in each particular case by the rate of decline of renal function, presence of co-morbidities (i.e. diabetes, obesity), estimated time from referral to surgeon until access creation and degree of difficulty for VA creation. Avorn et al [29] found that patients referred to a nephrologist 90 days before the initiation of dialysis were approximately 40% more likely to undergo catheter placement compared with those who were seen 90 days before the initiation of dialysis.

3.1.3. Clinical evaluation of arm veins

The initial evaluation of peripheral veins is done on clinical grounds. Past access failure should be analyzed and a careful history of previous catheterizations, particularly of central outflow veins, like subclavian and innominate veins. Previous right IJV cannulation in most cases do not preclude ipsilateral access creation, except in patients developing arm edema during catheter dwell time or when enlarged superficial vein collaterals are observed on the chest wall or the neck, which is highly suspicious for significant central vein stenosis or oc-

clusion. Evaluation of the arm veins should be done by palpation with a proximal tourniquet or inflatable pressure cuff in place. This way, stenotic or thrombotic segments can be easily detected. The explored outflow vein walls should be distensible all along its course with uninterrupted lumen. Collecting past history of venipuncture, presence of edema, especially if unilateral, is extremely important. Palpation of the arteries should include assessment of pulse amplitude and rhythm, as well as texture of the arterial wall all along its course. Evaluation should detect wall hardening, plaques or absence of pulse. Allen's test should be routinely done in all cases.

3.1.4. Ultrasound mapping of the vessels

Color Doppler ultrasound (CDU) is usually a complementary diagnostic tool in the setting of VA planning. It should be used to further assess pathologic findings obtained at clinical evaluation. CDU can corroborate or exclude underlying vein stenosis and thrombosis, arterial plaques, etc. Hemodynamic parameters like vessel diameter, arterial flow pattern and flow measurement can also be readily assessed. Minimum artery diameter for successful autogenous AV access creation at forearm ranges from 1.5 mm and 2.0 mm although 2.0 mm seems to be a more acceptable limit in adults [30,31]. In addition to measuring arterial diameter, it is of utmost importance to exclude calcification of the media, which precludes surgical opening of the artery, or the presence of proximal atheromas which would reduce inflow. Typical arterial flow pattern is shown in Figure 7.

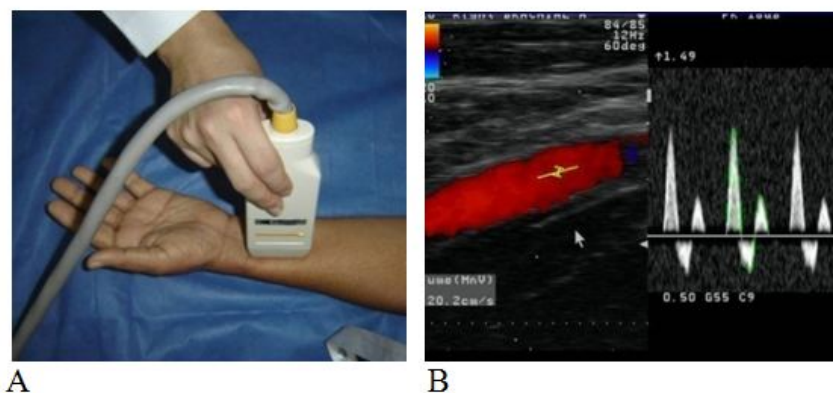


Figure 7. Doppler ultrasound of the radial artery (A) showing normal triphasic flow pattern (B).

Venous system can be evaluated sonographically for continuity and absence of strictures. To this end, CDU scans should be done with a distal tourniquet in place to distend the outflow vein. Evaluation of the basilic vein at upper arm is only possible with CDU since this vein is located below the brachial fascia in most of its upper arm course. Arm diameter in obese patients may limit access site selection. CDU may also dictate the need for primary or staged vein elevation in case of too deep lying outflow veins.

3.1.5. Additional imaging studies

A central vein imaging procedure is necessary to exclude subclavian or innominate vein stenosis or thrombosis in patients with history of subclavian or left internal jugular vein cannulation, especially if catheter infection occurred or when vein collaterals are visible on skin over the chest. To circumvent the need for central imaging procedure, it is advisable to select in first instance the contralateral upper extremity for access creation, if the vessels are appropriate, in those patients with history of subclavian vein cannulation only on one side. Likewise, former left IJV cannulation requires that innominate vein stenosis or occlusion be excluded before ipsilateral VA creation.

3.1.6. Order of preference for VA creation

The sequence of VA creation should, ideally, be individually tailored with clear preference for native vessels, exhausting first more distal VA options bilaterally before considering creating a proximal one. The sequence of preference is:

1. radiocephalic fistula (RCF),
2. ulnarbasilic fistula (UBF),
3. brachiocephalic fistula (BCF)
4. brachiobasilic (BBF) or brachio brachial fistula and
5. brachioaxillary straight graft (BASG).

Eventually, placement of a forearm graft, in preference in straight configuration, may be evaluated before moving to an autogenous upper arm access [32]. If graft placement is decided, the graft/vein anastomosis should be performed below the elbow crease in order that both cephalic and basilic vein at upper arm remain intact for ulterior access procedures.

3.1.7. Preoperative clinical protocol

Some basic clinical, hemodynamic and laboratory parameters should be systematically evaluated in patients scheduled for VA surgery [32]. Patients should be in their dry weight, afebrile without evidence of catheter infection or elsewhere, no signs of cardiac insufficiency nor pericardial effusion, normal range heart rate and rhythm, minimal BP 110/70 without orthostatic hypotension. Regarding laboratory data, normal WBC and platelet count with Hb levels above 8 g/dl are essential. Too high hematocrit levels can make the patient more prone to access thrombosis. In such cases, transient epoetin reduction should be considered. Coagulation tests like bleeding time, TP and TPT should be within normal range. Serum albumin should be 3.0 mg/dl or higher. Prothrombotic medication (methilprednisolone) should be tapered to 10-15 mg daily before performing access surgery. It is very important that antithrombotic agents (ASA, clopidogrel, davigatran), anticoagulants (low-weight heparin, warfarin) are stopped at least 5 to 8 days before surgery.

3.1.8. Operative technique

A detailed operative technique for each access type would be beyond the scope of this chapter. However, It can be never stressed enough that, for successful VA creation, surgical procedures should be done under stringent aseptic conditions, using appropriate surgical instruments, sutures and a meticulous technique. AVF not requiring general anesthesia, like forearm fistulas and BCF, may be performed on an outpatient basis in a procedure room located within a renal unit, Access procedures requiring axillary nerve block or general anesthesia should be performed in a conventional operating room keeping the patient hospitalized for a short observation period. Vein collaterals should be ligated to allow for better maturation. Ligation of tributary veins like hand dorsum veins in case of RCF and cephalic accessory vein in case of BCF may prevent retrograde flow once the runoff vein has enlarged and increased its flow. The recommended anastomosis technique for arm fistulas is side-to-end. However, for forearm fistulas, side-to-side anastomosis, turned into a functional side-to-end anastomosis by juxta-anastomotic ligation of the distal venous limb (Figure 8), may be an equivalent alternative which has an additional advantage: the anastomosis size can be tailored regardless of the diameter of the vessels.

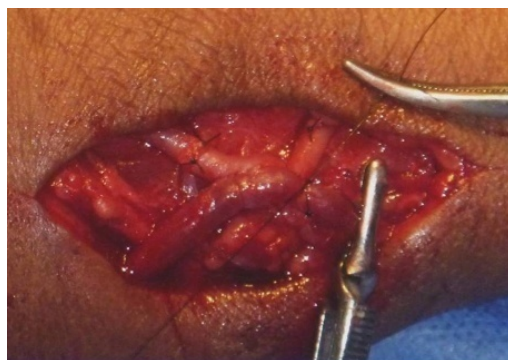

Figure 8. Side-to-side anastomosis turned into a functional side-to-end by juxta-anastomotic ligation of the distal venous limb.

In case of BBF creation, subcutaneous transposition of the arterialized basilic vein is mandatory since it runs in most of its upper arm course beneath the deep fascia and would otherwise not be amenable to safe cannulation except in its short distal postanastomotic segment [33]. In addition, the basilic vein is crossed in part of its upper arm course by branches and filaments of the medial antebrachial cutaneous nerve. Aneurysmatic dilation of the postanastomotic segment of BBF is commonly observed when superficialization is not performed owing to the fact that the arterialized vein is being “clamped” proximally by the deep fascia. Superficialization of the vein usually requires either a long incision or multiple short incisions in the medial aspect of the upper arm. However, a new endoscopically performed superficialization technique has been described recently [34]. Some authors recommend doing superficialization as a two-stage procedure [35].

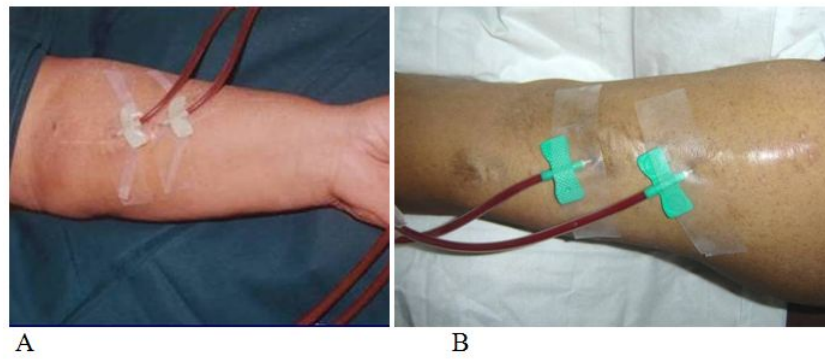


Figure 9. RCF (A) and BCF (B) with staged superficialization of the cephalic vein.

3.2. Basic types of PVA at upper extremities

3.2.1. Autogenic

RCF, also called Cimino or Brescia-Cimino fistula, is by far the best type of HD access. It offers the longest and easiest to puncture vein segment, lowest venous dialysis pressures, higher primary function rates, as well as better long-term survival. Snuff box fistula, a distal variant of RCF which may be created at the basis of the thumb, can be performed if the caliber of the vessels at this location is appropriate. UBF, another autogenic VA type in the forearm, was first described by Hanson et al as early as 1967 [36]. UBF is an optimal VA alternative with good survival rates [37] which has not yet been included in the KDOQI recommendations probably under the argument that the posteromedial course of the basilic vein along the forearm is inconvenient for cannulation. However, in our experience, UBF does not need transposition to be successfully cannulated (Figure 10).

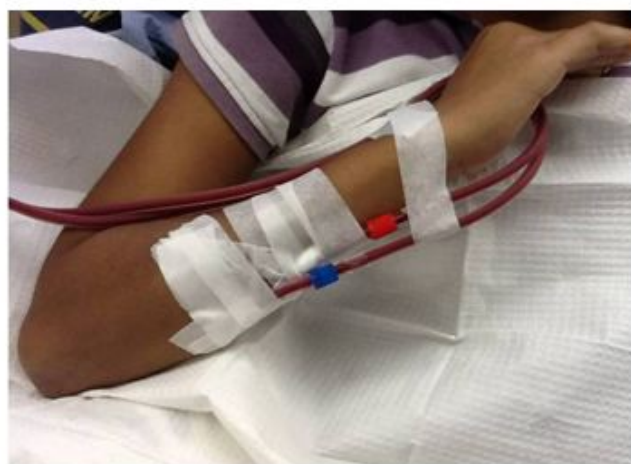

Figure 10. Ulnarbasilic fistula being used for HD. Note that transposition of the arterialized basilic vein is not necessary for safe cannulation.

BCF and BBF with vein superficialization are the the two basic autogenic fistula variants at upper arm. If the basilic vein is found to be inadequate, one of the brachial veins may be used instead [34]. Other access options like Gracz fistula, or bidirectional (reverse) fistulas offer no additional advantages over other conventional fistulas [38].

3.2.2. *Prosthetic grafts*

In the forearm, arteriovenous grafts (AVG) are placed in either straight or loop configuration [39]. Inflow artery of straight grafts may be either the radial or the ulnar artery. Inflow artery of forearm loop grafts is the brachial artery. Outflow veins are usually antecubital veins. As stated earlier, the graft/vein anastomosis should be located in preference below the elbow crease. At upper arm, the most common AVG variant is the brachioaxillary graft. Since adhesion between the graft and subcutaneous tissue may last up to 3 weeks, it is advisable waiting until after that time has elapsed to start cannulation. The shorter waiting time for starting cannulation is one of the advantages of AVG over AVF. The expanded PTFE (ePTFE) remains still the most commonly used graft material. Biological prostheses are of limited availability, usually more expensive and of variable size and quantity [39].

3.3. Basic types of PVA in the thigh

They should be attempted only when all options in the upper extremity are exhausted.

3.3.1. *Femoral vein transposition*

It is an autogenous AV access in the thigh which is created between the femoral artery and the transposed common femoral vein. It has good patency rates but a higher risk of distal ischemia [40].

3.3.2. *Sapheno femoral arteriovenous fistula*

It is created by anastomosis of the distal femoral artery and the great saphenous vein (Figure 11) which is subcutaneously transposed to allow cannulation. Access survival is acceptable [41].

3.3.3. *Saphenous Loop*

It is also an autogenous alternative whose inflow is provided by the proximal femoral artery at groin level. It requires frequent endovascular procedures owing to vein stenosis. Only 70% of all new created saphenous loop are functional with a 16-months survival rate [42].

3.3.4. *Femorofemoral ePTFE loop graft*

This AVG type is created at the groin using the common femoral artery as inflow, or at mid-thigh level using the superficial femoral artery instead [39,43]. Infection rate of thigh graft is higher than that of upper arm accesses.

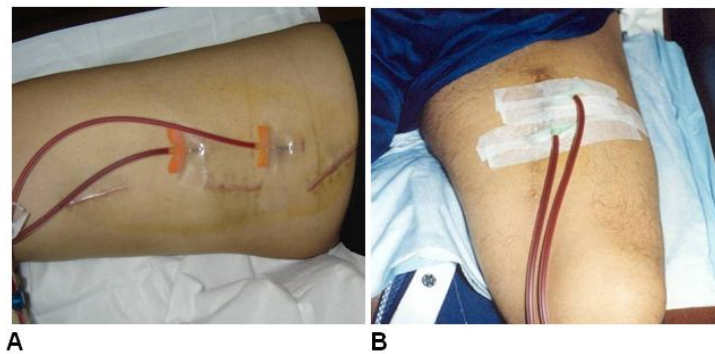


Figure 11. A) Saphenofemoral arteriovenous fistula. (B) Arterioarterial HD through a superficialized femoral artery.

3.4. Timing of first puncture

Ideally, mature AVF should have the following characteristics to be safely punctured: discernible vein margins, flow greater than 600 mL/min, vein diameter at least 0.6 cm and should be located no more than 0.6 cm deep [8]. Too deep lying arterialized cephalic veins, particularly in obese patients, can be superficialized either along its forearm course in case of RCF or along its upper arm course as in the case of BCF. (Figure 9). Since superficialization is an extensive, surgically complex and time-consuming procedure, we recommend to perform it as staged procedure on a case-by-case basis once the impossibility to cannulate the new access has been established. Superficialization of the vein can be done by surgical transposition [44], by single lipectomy [45] (or suction-assisted lipectomy [46]). Maturation time of BBF is about 8 weeks. Adequate puncture technique and care is the clue to prolonged VA survival. Cannulations can help to widen the caliber of the arterialized vein on condition that puncture sites are rotated. Lack of needle rotation may favor the development of aneurysms at needling sites. However, some authors recommend the buttonhole cannulation and report less complications and interventions using this technique [47].

4. PVA complications

4.1. Immediate and early postoperative period

Complications in the immediate and early postoperative access complication are bleeding, thrombosis and infection. CKD patients are more prone to bleeding, but this complication is totally preventable with careful surgical technique. Significant bleeding associated with skin bulging at the operative site always requires surgical revision.

4.1.1. Thrombosis

is the commonest complication of PVA in the immediate and early postoperative period. Even using an impeccable surgical technique and in the presence of both adequate vessel

anatomy and optimal hemodynamic parameters, the risk of thrombosis remains high in the first minutes or hours after access surgery. Arterial wall incision done for anastomosis is in principle an arterial injury causing exposure of subendothelial elements as collagen and laminin which initiates a cascade of cytochemical and cellular events leading to platelet recruiting, adhesion and activation at the anastomosis site. Platelet activation together with thrombin generation results in thrombus formation [48]. In addition, chronic renal failure per se is a procoagulant state with multiple concurrent hemostatic abnormalities [49]. Some comorbidities like old age, obesity, diabetes, atrial fibrillation and hypertension could also contribute to enhance prothrombotic conditions. Therefore, close surveillance of fistula function, particularly in high risk patients, should begin just after unclamping of the vessels and continue after wound closure during the immediate and early postoperative period. Initially, a discontinuous sometimes high-pitched bruit may be heard over the anastomosis but in the following minutes or within the first hour it should turn into a continuous bruit which is the normal auscultatory finding in a well functioning fistula. In addition, fistula bruit must increase in intensity to a maximum in the first hours, remaining then stable. Decreasing fistula bruit, particularly during the first minutes or the first hour may herald impending thrombosis. Careful intravenous fluid and heparin administration may avert definite fistula thrombosis in a great majority of cases. In the event of complete bruit disappearance, a gentle massage can be done over the anastomosis area until the fistula bruit reappears. This massage can be repeated more than once if necessary [32]. Persistent discontinuous flow associated with pulsations instead of thrill over the outflow vein may point at an underlying outflow impairment.

4.1.2. Postoperative infection

in a new created VA needs aggressive therapy particularly because the anastomosis site is almost always involved and may rupture leading to acute, eventually life-threatening bleeding requiring urgent VA ligation. Infection is more common in AVG than in AVF [50]. Factors favoring infection are intraoperative contamination, poor wound care, diabetes, steroids, etc. Similarly as in NTC and TC, most episodes of infection are due to gram positive bacteria in particular, *S. aureus*. Infection at the anastomosis site may lead to fistula ligation or graft excision.

4.2. Late postoperative/precannulation period

Thrombosis in this period is most commonly due to hypotension after HD. The nursing staff should be strongly advised to always measure standing blood pressure (BP) before allowing a patient going back home after finishing HD session. If BP is found to be less than 110/70, the patient should be placed immediately in recumbent position until BP improvement. Tight circular bandages or dressings should be avoided. Since a new created AVF or AVG may cause a variable decrease in peripheral vascular resistance, antihypertensive drug dosing may eventually need to be adjusted. A bit higher median arterial pressure than usual (100-110 mmHg) should be tolerated in the first 10 days after surgery. Patients should be advised to keep their arm elevated to reduce local edema and decreased wound suture tension.

Mild to moderate edema is not uncommon but it normally subsides within the first 3 weeks after surgery. In case of persistent or worsening edema, venous hypertension syndrome owing to an underlying central or peripheral vein occlusion should be suspected. Arterial steal is another complication that may also become clinically apparent during this period. Both the latter complications will be addressed in detail later in this chapter.

4.3. Lack of maturation

As mentioned earlier a mature autogenous access requires

1. an adequate diameter (> 6 mm),
2. discernible margins,
3. adequate access flow rate (>500 ml/min) and
4. it must be sufficiently superficial (<0.6 cm deep) to permit accurate, safe cannulation.

Blood access flow increases dramatically within 24 hours of autogenous access placement and reaches most of its maximum flow within 3 to 6 weeks [51,52]. Average flow rates vary according to access site and type. Mean forearm fistula flow is 784 ± 623 ml/min, upper arm fistula 1400 ± 850 and prosthetic graft 1270 ± 604 [53]. Similarly, most of the increase in access diameter is achieved within 4 to 8 weeks of autogenous access placement [54]. It has been estimated that about one quarter to one third of AVF fail to mature [55]. Causes of lack of maturation are poor arterial inflow (inadequate vessel diameter, proximal atheroma, juxta-anastomotic occlusion of the proximal arterial limb, anastomosis of small size, chronic hypotension), juxta-anastomotic vein stenosis (probably resulting from intraoperative prolonged venous clamping), lack of ligation of tributary and collateral veins, venous intimal or media fibrosis not allowing vein diameter to enlarge. The usefulness of endovascular or surgical procedures to improve flow and promote AVF maturation should be evaluated in each particular case.

4.4. Postcannulation complications

4.4.1. Hematoma or infiltration

Infiltration are common complications. They may be confined to subcutaneous tissue looking like ecchymotic lesions or be the result of subaponeurotic bleeding, when the needle crosses the vein lumen leaving an orifice in the posterior vein wall [56]. In the latter case, skin bulging is seen without significant ecchymosis. Hematomas may eventually either become secondarily infected, cause significant stenosis or turn into pseudoaneurisms.

4.4.2. Pseudoaneurysm (PA)

PA are typical puncture-related complications of both AVF and AVG. The trigger event is usually a wall laceration due to a traumatic cannulation with subsequent hematoma formation around the vessel or a leak at the anastomosis site leading to hematoma formation [57].

The size of the hematoma may vary widely and is one of the determinants of final PA size. Inadequate compression at puncture site favors further hematoma growth. PA may be located either subcutaneously or subfascially depending on where the hematoma was located. Once hematoma is formed around the fistula vein or graft, it will be progressively eroded in the course of few days by the pressure of a blood jet going out through the wall defect, which will later become the PA neck. Finally, a cavity or sac can be observed within the hematoma, connected to the fistula vein or graft lumen by the PA neck (Figure 12). PA can develop in both AVG and AVF. US guided compression of the PA for 30 minutes [58], or US guided direct thrombin injection into the PA sac have been used as primary options [59]. However, in case the latter measures fail or when PA is rapidly enlarging, revision is required. Surgical revision has been the standard approach to treat PA. However, endovascular treatment using covered stents insertion to exclude PA has been successfully used to treat such complications [57,60]. This method has proven safe and effective and the results have been encouraging, however it requires a specialized institution and the procedure-related costs are high. Surgery should be used in preference in case of wide-neck PA or when a significant skin bulge or mass is observed. Infection is a contraindication for endovascular procedures. In case of secondarily infected PA, the best way of action is to ligate the access in a definite manner.

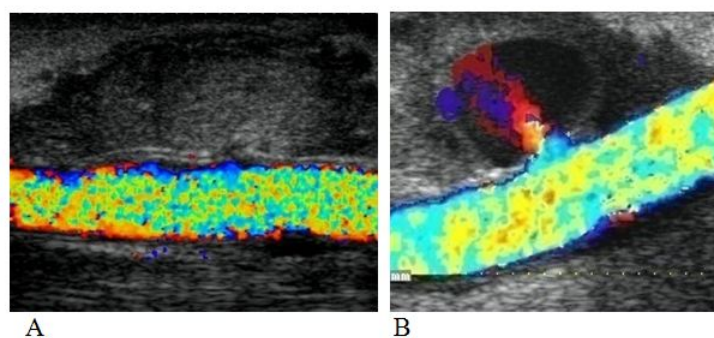


Figure 12. A) Perigraft hematoma. (B) Doppler ultrasound show formation of pseudoaneurysm following hematoma cavitation.

4.4.3. Aneurysms

Different than pseudoaneurysms, aneurysms are widened or enlarged segments of the arterialized vein that may develop at puncture site or at the anastomosis. Aneurysms may reach significant sizes and exhibit small saccular areas with thin wall which may cause, if ruptured, serious bleeding. Aneurysms usually limit puncture sites and can be the starting point of infections and thrombus formation. In selected cases, surgical plication may be attempted to reduce aneurysm size on condition that a proximal stenosis of the vein is excluded [61]. Otherwise, ligation of the access is the only option.

4.4.4. Puncture site Infection

Infection can develop at puncture sites, poor asepsia, hematoma formation or infiltrations being predisponent factors. Most commonly isolated agents are grampositive bacteria, particularly *S. aureus* and coagulase-negative staphylococci [62]. AVF or AVG infection should be always viewed as an emergency condition that require hospitalization since it may ultimately lead to access rupture with bleeding, sepsis, endocarditis and other metastatic infections. Aggressive empirical antibiotic therapy should be started until culture results are available. Strict adherence to aseptic and antiseptic protocols by the nursing staff and patient's education are instrumental in preventing access-related infections.

4.4.5. Stenosis

Luminal stenosis may range from mild to severe and can develop at any site along the AVF or graft (anastomotic stenosis, peri or postanastomotic stenosis, puncture-related stenosis, stenosis at the site of former venipunctures and venous outflow stenosis). While anastomotic or puncture-related stenosis point at surgical failure or inadequate puncture technique, perianastomotic stenosis in AVF and venous outflow stenosis at the graft-vein anastomosis are due primarily to neointimal hyperplasia [63]. Other possible causes of postanastomotic stenosis might be venous wall damage induced by clamping and excessive denudation of the vein. The diagnosis of luminal vein stenosis can be accurately done in a great majority of arteriovenous fistulas by physical examination alone [64]. CDU or other vascular imaging techniques should be used to confirm the clinical diagnosis of stenosis. Treatment of stenosis is either surgical or endovascular (balloon dilatation or stent placement) and the results depend largely on the size and type of the stenosis. The KDOQI Guidelines [7] recommend that stenoses in prosthetic or autogenous accesses should be treated prophylactically with percutaneous transluminal angioplasty or surgical revision if the stenosis is 50% of the lumen diameter and is associated with clinical abnormalities. Early detection of fistula vein stenosis can be achieved by applying the KDOQI static intra-access pressure surveillance protocol which consists of serial calculations of the normalized arterial and venous segment static intra-access pressure ratios or indexes. Arterial index values > 0.43 in AVF or > 0.75 in AVG are suggestive of significant stenosis [65]. Index calculations and normal range values are described in detail in the respective KDOQI recommendation [7].

4.4.6. Neointimal hyperplasia

of the runoff vein is a special type of stenosis which has been subject of extensive research. Cumulative patency of AVG largely depends on the development of neointimal hyperplasia at the graft/venous anastomosis. Therefore, prevention of this complication would contribute to prolong AVG survival [63]. Research has been focused on how to eliminate or inhibit the two main pathogenetic factors involved in the development of this complication: Shear stress and the subsequent endothelial cell proliferation. Shear stress has long been pointed as the main cause of neointimal proliferation as proved in experimental flow models. Some modifications in graft configuration have been shown to reduce shear stress, particularly on the bed of graft-vein junction, like helical ePTFE grafts which swirl blood flow across the graft-

venous anastomosis reducing endothelial stress [66]. Another way to limit neointimal hyperplasia is reducing venous outflow turbulence either by modifying the graft-vein anastomotic angle inserting grafts with angled venous end [67] or with the so called Y-Split AVG (Prolong™) that bifurcates shortly after arterial end and reunite just before the runoff vein anastomosis [68]. *Inhibition of endothelial cell proliferation* has been achieved on the one side by embedding allogeneic aortic endothelial cells in a gelatin matrix (Vascugel™), which is placed around the vessel at the time of AV access creation. Preliminary studies have been promising but further research is needed [69]. On the other side, it has been long known that increased nitric oxide levels inhibit the intimal hyperplasia of grafts [70]. In this regard, worth-mentioning is the interesting work by Luo et al [71] who evaluated the efficacy and safety of an adenoviral vector encoding the carboxyl terminus of beta-adrenergic receptor kinase in a pig model of arteriovenous PTFE graft failure. The authors found that locally applied gene therapy reduced significantly neointimal hyperplasia in the graft/vein anastomosis.

4.4.7. Access recirculation

Access recirculation occurs when dialized blood having already passed through the dialyzer, instead of returning to circulation via the proximal “venous” needle, is redirected toward the distally placed arterial needle and reenters the extracorporeal circuit. The explanation is that flow of the extracorporeal circuit exceeds that of the VA whose minimal range should be between 300 to 450 mL/min [72]. Recirculation results in dialysis delivery being less than that prescribed. The most common cause is stenosis of the outflow vein which can ultimately lead to access thrombosis owing to significant intraaccess flow reduction. Other causes to be excluded are poor arterial inflow, close proximity of the needles and inverted lines. Complementary imaging methods like Doppler ultrasound, venography, angioresonance, etc, can locate site and determine degree and extension of the stenotic segment, measuring access recirculation is a valuable tool to estimate the percentage of recirculation and help to establish the indication for surgical or endovascular interventions. Recirculation may be measured either by urea-based or non-urea based methods like ultrasound dilution, potassium dilution, ionic dialysance, glucose infusion and thermal dilution [73]. Percentage recirculation can be calculated by the traditional urea-based method according to the following equation: $\frac{\text{Systemic BUN}-\text{arterial blood line BUN}}{\text{Systemic BUN}-\text{venous blood line BUN}} \times 100$. Consistency of the urea-based methods is poor for surveillance for access stenosis, in part because of arteriovenous (cardiopulmonary recirculation) and venovenous disequilibrium [74,75] but if the percentage recirculation is >10% stenosis should be suspected. Other methods which eliminate the effect of disequilibrium have different thresholds, such as > 5% for ultrasound dilution [76].

4.4.8. Arterial steal syndrome (ASS)

Also referred to as HD access-induced distal ischaemia (HAIDI), ASS is a rather uncommon complication and occurs in 2.7–4.3% of AVG and 1% of AVF [77,78]. It may appear early after surgery or in the postcannulation period. Symptoms range from only pain and coldness during dialysis to digital necrosis. It may develop shortly after surgery or years afterwards.

Patients at risk are diabetic and those with severe peripheral occlusive disease. ASS may be classified in 4 stages [79]:

Stage 1: Retrograde diastolic flow without complaints; steal phenomenon;

Stage 2: Pain on exertion and/or during HD;

Stage 3: Rest pain and

Stage 4: Ulceration/necrosis/gangrene.

The diagnosis of steal syndrome is made clinically, color Doppler US and complementary imaging procedures. Measuring finger pressure before and after fistula vein or graft compression is a very helpful diagnostic manoeuvre in patients with steal syndrome. Using the digital brachial index (DBI), Goff et al [80] identified patients with a DBI of <0.45 as having a significant risk for ASS. Treatment of ASS is surgical and has two main objectives: increasing or restoring distal limb flow and maintaining access patent. Surgical interventions to obtain symptoms relief in SS are of two kinds:

- a. Revascularization and
- b. Banding.

The more severe forms require excision or removal of the affected tissue.

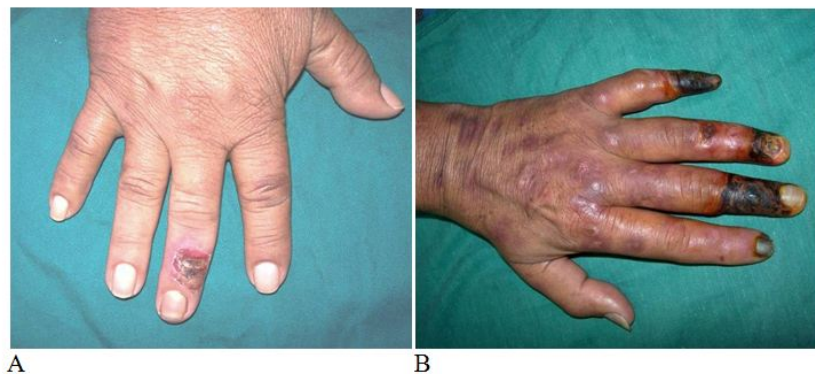

Figure 13. A) Steal syndrome with painful necrotic ulceration of the middle finger. (B) Stage 4 steal syndrome.

4.4.8.1. Revascularization techniques

- a. Distal revascularization with interval ligation (DRIL) was first described by Shanzer et al [81] as early as 1988 and consists in placing an arterioarterial bridge that bypasses the anastomosis site. In addition, a juxta anastomotic ligation of the distal limb of the artery is done. It has been long viewed as the gold standard procedure.
- b. Proximalization of the arterial inflow: First, the distal original arteriovenous anastomosis is closed and the artery repaired using an interposition graft. Secondly, the outflow vein is anastomosed to a bridge graft (autologous or else) which is in turn anasto-

mosed to a more proximal site of the artery. This procedure is useful in cases with low fistula flow [82].

- c. Revision Using Distal Inflow (RUDI). In this technique the original anastomosis at the brachial artery is ligated and the outflow vein is anastomosed more distally to either the radial or ulnar artery just below the bifurcation using a bridge graft (autologous or ePTFE). The basic principle is that the distal artery has both lower diameter and flow [83].

4.4.8.2. Banding

The main objective of banding is to increase postanastomotic outflow resistance by narrowing the lumen of the outflow vein or graft so as to reduce outflow and increase distal arterial flow. Banding may be achieved either by placing a *narrowing suture* near the anastomosis site [84], by *plication* of a short postanastomotic stretch [85] or by tapering [86]. Flow reduction in either technique is measured by means of intraoperative pulse volume recording or by measuring access flow with a flow meter [87]. Among the banding techniques, the minimally invasive limited ligation endoluminal-assisted revision (MILLER) for treatment of dialysis access-associated ASS is one of the most simplest to perform and offers excellent results [88]. In this technique one or two sutures are placed 1-3 cm after the anastomosis using an inflated endoluminal angioplasty balloon, which is retrogradely inserted more proximally, to size the final luminal diameter of the outflow vein.

4.4.9. High-output heart failure

It is a rather uncommon complication which can easily be overseen [89]. Excessive shunting of the access, anemia and underlying heart disease are triggering factors. Surgical banding [90] may relieve symptoms, but in case of persistent manifestations, definite ligation is the only remaining option.

4.4.10. Venous hypertension syndrome (VHS)

VHS is a relatively common complication of AV accesses, particularly AVF and consists of a painful edema, redness and warmth of the affected skin area that appear after VA creation that may affect, depending on the site of the outflow stenosis or occlusion, either the entire upper extremity or may be circumscribed to forearm, hand, or skin segments overlying the fistula. The stenotic site represents a formidable barrier against arteriovenous flow originating a steady rise of the intraluminal pressure distally to the stenosis. The increased intraluminal pressure is in turn transmitted backward to the superficial or subcutaneous vein system producing the typical symptoms of VHS (Figure 14). In patients with longstanding VHS skin pigmentation occurs as well as other manifestations observed in chronic venous insufficiency like vein collaterals, small varicosities and even ulcerative lesions. The mechanism of hyperpigmentation is possibly similar to that of chronic venous insufficiency where both a moderate hypermelanosis and dermal hemosiderin deposits can be seen microscopically, derived from the breakdown of red blood cells that have extravasated through damaged capillaries and smaller vessels are [91]. Diagnosis of VHS is made clinically and should

be complemented by imaging procedures like ultrasound, flebography, angiotomography or angioresonance. The main advantage of the two latter procedures is that small doses of contrast media are used. Treatment options are: Ligation of retrograde veins, endovascular or surgical procedures or definite access ligation.

5. Last resort PVA (complex VA options)

5.1. Subcutaneous transposition of peripheral arteries

The purpose is to perform an arterioarterial hemodialysis. The arteries reported to be used this way are: the superficial femoral [91], the brachial [92] and radial artery [93].

5.2. Arterioarterial grafts

Desperate case access option that has been performed as axillary-axillary chest loop (preferred type) or femorofemoral loop. Reported primary and secondary patency at 3 years were 54% and 87%, respectively [94].

5.3. Anterior chest wall (body wall) prosthetic accesses

These are a particular type of VA. The axillary artery is anastomosed by means of an ePTFE graft to either the ipsilateral axillary vein, internal jugular or femoral vein. Loop configuration of the graft at the upper chest is the typical configuration when either the axillary or the ipsilateral internal jugular vein is used [95]. If the contralateral axillary vein is used as outflow, ePTFE configuration in the form of a collar or necklace is placed. Mickley et al [96] described a novel AVG using the axillary artery as inflow and the right atrium as outflow in cases with superior vena cava occlusion.

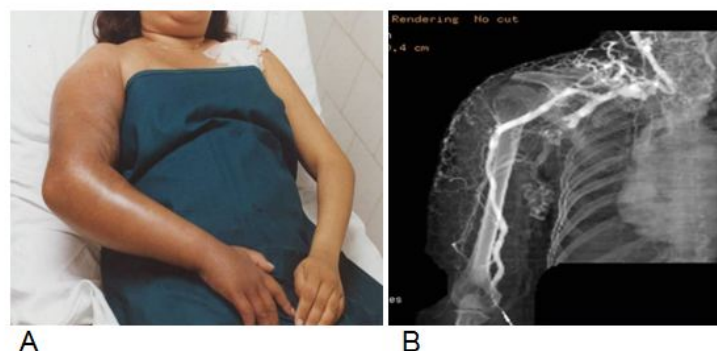


Figure 14. A) Venous hypertension syndrome developing after a brachiocephalic fistula creation (B) Angiotomography showing right innominate vein occlusion.

6. Alternatives to PTFE graft material and new trends in the field of PVA creation

6.1. Xenografts

Xenografts are more expensive than PTFE grafts, a fact which limits their use in spite of their proven better patency rates and lesser frequency of complications compared to PTFE graft [97-99]. Two types xenografts are commercially available:

- a. The bioengineered bovine carotid artery (Artegraft™) which has been in use since 1970 and
- b. the bioengineered bovine mesenteric vein (Procol™).

6.2. Hybrid prosthetic devices

The Hemoaccess Reliable Outflow (HeRO™) Vascular Access Device (Hemosphere, Inc., Minneapolis, MN) has emerged as a valuable, innovative alternative to tunneled catheters (TC). Early results suggests that bacteremia was significantly less frequent for the HeRO device than for TC being its secondary patency (> 72.2%) quite close to that of PTFE grafts [100-102]. According to the description by Katzman et al [102], this device consists of a 6-mm straight ePTFE upper arm graft serving as cannulation segment, whose distal end is anastomosed to the brachial artery and the proximal one is attached by means of a titanium-made crimp ring to an also subcutaneously placed, 5 mm inner diameter, silicon catheter ("outflow component"). The catheter may be introduced endovascularly or inserted into the internal jugular or subclavian vein utilizing the Seldinger technique The catheter tip should lie at the cavoatrial junction.

6.3. Early stick grafts (ESG)

Their main advantage is that they can be used 24 hours after placement and would avoid using NTC and TC preventing catheter-related morbidity and costs. Some of the ESG have resulted from modifications introduced to the original ePTFE like the *Trilaminare composite construction ePTFE* (Flixene™) which would have reduced hole bleeding, being ideal for early use [103] or the gelatin-coated ePTFE (Vascutek™). The gelatin would make subcutaneous graft placement smoothly preventing tissue trauma and thus allowing early graft cannulation. However, with the latter a high incidence of perigraft hygroma has recently been reported [104]. Other ESG are made of polyurethane urea (Vectra™) which is an antithrombogenic material with an impermeable middle layer. The graft would seal rapidly after decannulation being thus ideal for early use [105,106]. A really innovative development as graft material in the future is the endothelialized polyurethane grafts (NanoVasc™) which has a biomimetic scaffold allowing for endothelial cell ingrowth. The results of animal studies are encouraging [107].

6.4. Tissue engineered vascular grafts (TEVG)

The creation of AVG using TEVG technology is really very promising. Some are created by seeding autologous bone marrow-derived mononuclear cells onto biodegradable tubular scaffolds constructed mainly from derivatives of the extracellular matrix or using allogeneic or canine smooth muscle cells grown on a tubular polyglycolic acid [108]. Other TEVG grafts are created from autologous fibroblasts and endothelial cells obtained from small skin and vein biopsies. The grafts are implanted without synthetic scaffolding [108].

7. Comorbidities and vascular access creation

As stated in the introduction paragraph, during the past two decades, HD population has become increasingly composed of patients of advanced age and/or suffering from comorbidities like diabetes, hypertension, chronic hypotension, dyslipidemias, occlusive artery peripheral disease, malnutrition, etc. In this population the risk of VA loss or malfunction is extremely high, particularly when two or more comorbid conditions coexist.

7.1. Diabetics

are prone to complications like occlusive arterial disease which limits their access options and, in a significant proportion of them, the primary access has to be created at upper arm due to severe atheromatous changes of distal arteries. The risk for development of arterial steal syndrome in patients of this group is elevated. In addition, a subset of diabetic patients suffer from chronic hypotension, orthostatic hypotension, etc., owing to autonomic neuropathy or cardiac failure. Access thrombosis is very common among those patients and, in many of them, a TC for chronic HD or CAPD are often the only remaining option.

7.2. Chronic hypotension

defined as interdialytic systolic pressure of less than 100 mmHg without cardiac function impairment, affects 5 to 10% of HD population. Its pathophysiology is not well understood but the mechanism of hypotension seems to be a reduction of the peripheral resistances with poor response to midodrine and other vassopresor agents [109]. In these patients frequent VA thrombosis are observed. The creation of upper arm fistulas has been recommend as primary access choice in such cases [110].

7.3. Elevated lipoprotein and hypoalbuminemia

have been associated with AV access thrombosis [111]. In addition, serum albumin is a known marker of nutritional status in HD patients. Hypoalbuminemia is associated with malnutrition and the latter, in turn, may lead to poor wound healing, infection and subsequent VA loss [112]. Hyperhomocysteinemia has also been found by some authors to be a risk factor for VA thrombosis and suggest decreasing levels before performing any VA [113]. Others, on the contrary, found no association between risk for thrombosis and hyper-

homocysteinemia [114]. Further studies are necessary to clarify whether lowering plasma homocysteine concentrations may prevent VA failure in HD patients.

7.4. Patients with systemic lupus erithematosus (SLE)

Patients with SLE on HD are at increased risk of vascular access thrombosis as compared to non-SLE patients because of the high prevalence of the so called, antiphospholipid antibodies, namely, anticardiolipin antibodies and lupus anticoagulant among SLE patients. [115 - 117]. Lupus anticoagulant is actually a prothrombotic agent which precipitates the formation of thrombi in vivo. In addition, SLE patients on chronic HD receiving high doses of oral steroids, may have an elevated risk of VA thrombosis and infection and, for this reason, steroid doses should be reduced before performing VA surgery.

8. Conclusion

The ideal AVG, which can be created with graft materials similar to the patient's own vessels is yet to be invented. However, a lot of progress has been done. The best example is TEVG technology which are showing us a complete new world in the realm of HD accesses in the future. Likewise, early stick grafts are undoubtedly invaluable developments which have raised special attention because they could obviate the need for a bridging NTC or TC. However, before resorting to all that panoply of innovative developments whose extensive use would otherwise represent a serious financial burden for any health care system, there is a lot that can still be done. Catheters have been a necessary evil but one step in the right direction is avoiding or minimizing their use in the years to come. To reach this goal, increasing pre-dialysis construction of autogenous fistulas is the only way out of the current trend. Applying autogenic-oriented VA plans is another crucial step that could help to substantially decrease the use of grafts. Additionally, but equally essential measures are complications prevention through patients' education, continuous staff training and timely-performed VA preserving interventions. Certainly, we will continue finding patients with very difficult access who will benefit from all those innovative AV types described in this chapter. Yet, it would not be far from the truth to state that the VA needs of the overwhelming majority of our patients could be met with a simple autogenous fistula if timely done, adequately punctured and optimally cared.

Acknowledgements

The author thanks NOVARTIS-NOVACID, Caracas, Venezuela, for their invaluable bibliographic support.

Author details

Octavio J. Salgado*

Address all correspondence to: ojsalg@hotmail.com

University of Zulia, Maracaibo, Venezuela

References

- [1] Beathard, G.A. (2000). Strategy for maximizing the use of arteriovenous fistulae. *Semin Dial*, 13, 291-296.
- [2] Salgado, O. J., Urdaneta, B., Colmenares, B., García, R., & Flores, C. (2004). Right versus left internal jugular vein catheterization for hemodialysis: Complications and impact on ipsilateral access creation. *Artif Organs*, 28(8), 720-725.
- [3] Seldinger, S. I. (1953). Catheter replacement of the needle in percutaneous arteriography; a new technique. *Acta radiologica*, 39(5), 368-376.
- [4] Schillinger, F., Schillinger, D., Montagnac, R., & Milcent, T. (1991). Post catheterisation vein stenosis in haemodialysis: comparative angiographic study of 50 subclavian and 50 internal jugular accesses. *Nephrol Dial Transplant*, 6(10), 722-724.
- [5] Salgado, O. J., Chacón, R. E., Mora, E., & Mora La Cruz, E. (2007). Angiotomographically-proven left innominate vein occlusion in dialysis patients with prior left internal jugular vein catheterization presenting with arm swelling after ipsilateral access creation: report of four cases. *Ther Apher Dial*, 11(5), 396-401.
- [6] Frampton, A. E., Kessaris, N., Hossain, M., Morsy, M., & Chemla, E. S. (2009). Use of the femoral artery route for placement of temporary catheters for emergency haemodialysis when all usual central venous access sites are exhausted. *Nephrol Dial Transpl*, 24(3), 913-918.
- [7] National Kidney Foundation. (2006). Updates. Clinical Practice Guidelines and Recommendations. http://www.kidney.org/professionals/kdoqi/pdf/12-50-0210_JAG_DCP_Guidelines-VA_Oct06_SectionC_ofC.pdf, accessed 22 August 2012).
- [8] Kim, Y. C., Won, J. Y., Choi, S. Y., Ko, H. K., Lee, K. H., do Lee, Y., Kang, B. C., & Kim, S. J. (2009). Percutaneous treatment of central venous stenosis in hemodialysis patients: long-term outcomes. *Cardiovasc Intervent Radiol*, 32(2), 271-278.
- [9] Lin, B. S., Huang, T. P., Tang, G. J., Tarng, D. C., & Kong, C. W. (1998). Ultrasound-guided cannulation of the internal jugular vein for dialysis vascular access in uremic patients. *Nephron*, 78(4), 423-428.

- [10] Andrews, R. T., Bova, D. A., & Venbrux, A. C. (2000). How much guidewire is too much? Direct measurement of the distance from subclavian and internal jugular vein access sites to the superior vena cava-atrial junction during central venous catheter placement. *Crit Care Med*, 28, 138-142.
- [11] Faintuch, S., & Salazar, G. M. (2008). Malfunction of dialysis catheters: management of fibrin sheath and related problems. *Tech Vasc Interv Radiol Sep*; , 11(3), 195-200.
- [12] Alomari, A. I., & Falk, A. (2007). The natural history of tunneled hemodialysis catheters removed or exchanged: a single-institution experience. *J Vasc Interv Radiol*, 18(2), 227-235.
- [13] Peters, P. J., Sohn, J., Butler, M., Okorie, N., Moss, E. G., & Corbett, B. (2009). Retained fibrin sleeve: transesophageal echocardiographic observations. *J Am Soc Echocardiogr*, 22(1), 105.e1-2.
- [14] Silva, F. S. (2003). Neck haematoma and airway obstruction in a patient with goitre: complication of internal jugular vein cannulation. *Acta Anaesthesiol Scand*, 47(5), 626-629.
- [15] Hoen, B., Paul-Dauphin, A., Hestin, D., & Kessler, M. (1998). EPIBACDIAL: a multi-center prospective study of risk factors for bacteremia in chronic hemodialysis patients. *J Am Soc Nephrol*, 9(5), 869-876.
- [16] Nielsen, J., Ladefoged, S. D., & Kolmos, H. J. (1998). Dialysis catheter-related septicemia-focus on *Staphylococcus aureus* septicemia. *Nephrol Dial Transplant*, 13(11), 2847-2852.
- [17] Bakken, A. M., Protack, C. D., Saad, W. E., Lee, D. E., Waldman, D. L., & Davies, M. G. (2007). Long-term outcomes of primary angioplasty and primary stenting of central venous stenosis in hemodialysis patients. *J Vasc Surg*, 45(4), 776-783.
- [18] Akoglu, H., Yilmaz, R., Peynircioglu, B., Arici, M., Kirkpantur, A., Cil, B., Altun, B., & Turgan, C. (2007). A rare complication of hemodialysis catheters: superior vena cava syndrome. *Hemodial Int*, 11(4), 385-391.
- [19] Defillo, A., Zelensky, A., Pulivarthi, S., Lowary, J. L., Nussbaum, E. S., Lassig, J. P., & Madison, M. T. (2012). Non-infected carotid artery pseudoaneurysm 29 years after endarterectomy, endovascular management with covered stent. *J Neurosurg Sci*, 56(2), 145-149.
- [20] Power, A., Singh, S. K., Ashby, D., Cairns, T., Taube, D., & Duncan, N. (2011). Long-term Tesio catheter access for hemodialysis can deliver high dialysis adequacy with low complication rates. *J Vasc Interv Radiol*, 22(5), 631-637.
- [21] Van Ha, T. G., Fimmen, D., Han, L., Funaki, BS, Santeler, S., & Lorenz, J. (2007). Conversion of non-tunneled to tunneled hemodialysis catheters. *Cardiovasc Intervent Radiol*, 30(2), 222-225.

- [22] Falk, A. (2005). Parthasarathy S Conversion of temporary hemodialysis catheters to tunneled hemodialysis catheters. *Clin Nephrol*, 63(3), 209-214.
- [23] Ashby, D. R., Power, A., Singh, S., Choi, P., Taube, D. H., Duncan, N. D., & Cairns, T. D. (2009). Bacteremia associated with tunneled hemodialysis catheters: outcome after attempted salvage. *Clin J Am Soc Nephrol*, 4(10), 1601-1605.
- [24] Vats, H. S. (2012). Complications of catheters: tunneled and nontunneled. *Adv Chronic Kidney Dis*, 19(3), 188-194.
- [25] Zhang, P., Yuan, J., Tan, H., Lv, R., & Chen, J. (2009). Successful prevention of cuffed hemodialysis catheter-related infection using an antibiotic lock technique by strictly catheter-restricted antibiotic lock solution method. *Blood Purif*, 27(2), 206-211.
- [26] Thompson, P. C., Stirling, C. M., Geddes, C. C., et al. (2007). Vascular access in hemodialysis patients: a modifiable risk factor for bacteremia and death. *Quart J Med*, 100(7), 415-422.
- [27] Rehman, R., Schmidt, R. J., & Moss, A. H. (2009). Ethical and legal obligation to avoid long-term tunneled catheter access. *Clin J Am Soc Nephrol*, 4(2), 456-460.
- [28] Eyrich, H., Walton, T., Macon, E. J., & Howe, A. (2002). Alteplase versus urokinase in restoring blood flow in hemodialysis catheter thrombosis. *Am J Health Syst Pharm*, 59, 1437-1440.
- [29] Avorn, J., Winkelmayer, W. C., Bohn, R. L., Levin, R., Glynn, R. J., Levy, E., & Owen, W. Jr. (2002). Delayed nephrologist referral and inadequate vascular access in patients with advanced chronic kidney failure. *J Clin Epidemiol*, 55(7), 711-716.
- [30] Malovrh, M. (2003). Approach to patients with end-stage renal disease who need an arteriovenous fistula. *Nephrol Dial Transplant*, 18, 50-52.
- [31] Silva, M. B., Hobson, R. W., Pappas, P. J., Jamil, Z., Araki, C. T., & Goldberg, M. C. (1998). A strategy for increasing use of autogenous hemodialysis access procedures: impact of preoperative noninvasive evaluation. *J Vasc Surg*, 27, 302-308.
- [32] Salgado, O. (2003). Basic steps for increasing the rate of autogenic vascular accesses for hemodialysis. *Ther Apher Dial*, 7(2), 238-243.
- [33] Salgado, O. J., Terán, N., García, R., Henriquez, C., Herrera, J., & Rodríguez-Iturbe, B. (1998). Subcutaneous transposition of arterialized upper arm veins for hemodialysis access: optimal alternative to grafts. *Vasc Endovasc Surg*, 32(1), 81-85, 10.1177/153857449803200111.
- [34] Paul, E. M., Sideman, M. J., Rhoden, D. H., & Jennings, W. C. (2010). Endoscopic basilic vein transposition for hemodialysis access. *J Vasc Surg*, 51(6), 1451-1456.
- [35] Francis, D. M., Lu, Y., Robertson, A. J., Millar, R. J., & Amy, J. (2007). Two-stage brachio-basilic arteriovenous fistula for chronic haemodialysis access. *ANZ J Surg*, 77(3), 150-155.

- [36] Hanson, J. S., Carmody, M., Keogh, B., & O'Dwyer, W. F. (1967). Access to circulation by permanent arteriovenous fistula in regular dialysis treatment. *Br Med J*, 4, 586-589.
- [37] Salgado, O. J., Chacón, R. E., & Henríquez, C. (2004). Ulnar-basilic fistula: indications, surgical aspects, puncture technique and results. *Artificial Organs*, 28(7), 638-634.
- [38] Bender, M. H., Bruyninckx, C. M., & Gerlag, P. G. (1995). The Gracz arteriovenous fistula evaluated. Results of the brachiocephalic elbow fistula in haemodialysis angio-access. *Eur J Vasc Endovasc Surg*, 10(3), 294-297.
- [39] Akoh, J. A. (2009). Prosthetic arteriovenous grafts for hemodialysis. *The Journal of Vascular Access*, 10, 137-147.
- [40] Gradman, W. S., Laub, J., & Cohen, W. (2005). Femoral vein transposition for arteriovenous hemodialysis access: improved patient selection and intraoperative measures reduce postoperative ischemia. *J Vasc Surg*, 41(2), 279-284.
- [41] Correa, J. A., Abreu, L. C., Pires, A. C., Breda, J. R., Yamazaki, Y. R., Fioretti, A. C., Valenti, V. E., Vanderlei, L. C. M., Macedo, H., Jr Colombani, E., & Miranda, Fausto. (2010). Saphenofemoral arteriovenous fistula as hemodialysis access. *BMC Surg*, 10, 28.
- [42] Pierre-Paul, D., Williams, S., Lee, T., & Gahtan, V. (2004). Saphenous vein loop to femoral artery arteriovenous fistula: a practical alternative. *Ann Vasc Surg*, 18(2), 223-227.
- [43] Scott, J. D., Cull, D. L., Kalbaugh, C. A., Carsten, C. G., Blackhurst, D., Taylor, S. M., Snyder, B. A., York, J. W., & Langan, E. M. (2006). The mid-thigh loop arteriovenous graft: patient selection, technique, and results. *Am Surg*, 72(9), 825-828.
- [44] Tordoir, J. H., van Loon, M. M., Peppelenbosch, N., Bode, A. S., Poeze, M., & van der Sande, F. M. (2010). Surgical techniques to improve cannulation of hemodialysis vascular access. *Eur J Vasc Endovasc Surg*, 39(3), 333-339.
- [45] Bourquelot, P., Tawakol, J. B., Gaudric, J., Natário, A., Franco, G., Turmel-Rodrigues, L., Van Laere, O., & Raynaud, A. (2009). Lipectomy as a new approach to secondary procedure superficialization of direct autogenous forearm radial-cephalic arteriovenous accesses for hemodialysis. *J Vasc Surg*, 50(2), 369-374.
- [46] Krochmal, D. J., Rebecca, A. M., Kalkbrenner, K. A., Casey, W. J., Fowl, R. J., Stone, W. M., Chapital, A. B., & Smith, A. A. (2010). Superficialization of deep arteriovenous access procedures in obese patients using suction-assisted lipectomy: A novel approach. *Can J Plast Surg*, 18(1), 25-27.
- [47] Van Loon, MM, Goovaerts, T., Kessels, A. G., van der Sande, F. M., & Tordoir, J. H. (2010). Buttonhole needling of haemodialysis arteriovenous fistulae results in less complications and interventions compared to the rope-ladder technique. *Nephrol Dial Transplant*, 25(1), 225-230.

- [48] Nuytens, B. P., Thijs, T., Deckmyn, H., & Broos, K. (2011). Platelet adhesion to collagen. *Thrombosis Research*, (2), S26-S29.
- [49] Marinigh, R., Lane, D. A., & Lip, G. Y. H. (2011). Severe Renal Impairment and Stroke Prevention in Atrial Fibrillation. Implications for Thromboprophylaxis and Bleeding Risk. *J Am Coll Cardiol*, 57(12), 1339-1348, 10.1016/j.jacc.2010.12.013.
- [50] Schild, A. F., Perez, E., Gillaspie, E., Seaver, C., Livingstone, J., & Thibonnier, A. (2008). Arteriovenous fistulae vs. arteriovenous grafts: a retrospective review of 1,700 consecutive vascular access cases. *J Vasc Access*, 9(4), 231-235.
- [51] Malovrh, M. (1998). Non-invasive evaluation of vessels by duplex sonography prior to construction of arteriovenous fistulas for hemodialysis. *Nephrol Dial Transpl*, 13, 125-129.
- [52] Yerdel, MA, Kesenci, M., Yazicioglu, K. M., Doseyen, Z., Turkcapar, A. G., & Anadol, E. (1997). Effect of haemodynamic variables on surgically created arteriovenous fistula flow. *Nephrol Dial Transplant*, 12, 1684-1688.
- [53] Back, M. R., Maynard, M., Winkler, A., & Bandyk, D. F. (2008). Expected flow parameters within hemodialysis access and selection for remedial intervention of nonmaturing conduits. *Vasc Endovascular Surg*, 42(2), 150-158.
- [54] Robbin, M. L., Chamberlain, N. E., Lockhart, M. E., Gallichio, M. H., Young, C. J., Deierhoi, M. H., et al. (2002). Hemodialysis arteriovenous fistula maturity: US evaluation. *Radiology*, 225, 59-64.
- [55] Zangan, MS, & Falk, A. (2009). Optimizing arteriovenous fistula maturation. *Semin Intervent Radiol*, 26(2), 144-150.
- [56] Salgado, O. J., Chacón, R. E., Alcalá, A., & Alvarez, G. (2005). Vein wall dissection: a rare puncture-related complication of brachiocephalic fistula. Gray-scale and color Doppler sonographic findings. *J Clin Ultrasound*, 33(9), 464-467.
- [57] Najibi, S., Bush, R. L., Terramani, T. T., Chaikof, E. L., Gunnoud, A. B., Lumsden, A. B., & Weiss, V. J. (2002). Covered stent exclusion of dialysis access pseudoaneurysms. *J Surg Res*, 106(1), 15-19.
- [58] Witz, M., Werner, M., Bernheim, J., Shnaker, A., Lehmann, J., & Korzets, Z. (2000). Ultrasound-guided compression repair of pseudoaneurysms complicating a forearm dialysis arteriovenous fistula. *Nephrol Dial Transplant*, 15(9), 1453-1454.
- [59] Clark, T. W., & Abraham, R. J. (2000). Thrombin injection for treatment of brachial artery pseudoaneurysm at the site of a hemodialysis fistula: report of two patients. *Cardiovasc Intervent Radiol*, 23(5), 396-400.
- [60] Keeling, A. N., Naughton, P. A., Mc Grath, F. P., Conlon, P. J., & Lee, M. J. (2008). Successful endovascular treatment of a hemodialysis graft pseudoaneurysm by covered stent and direct percutaneous thrombin injection. *Semin Dial*, 21(6), 553-556.

- [61] Lo, H. Y., & Tan, S. G. (2007). Arteriovenous fistula aneurysm--plicate, not ligate. *Ann Acad Med Singapore*, 36(10), 851-853.
- [62] Krzanowski, M., Janda, K., Chowaniec, E., & Sułowicz, W. (2011). Hemodialysis vascular access infection and mortality in maintenance hemodialysis patients. *Przegl Lek*, 68(12), 1157-1161.
- [63] Lee, T., & Roy-Chaudhury, P. (2009). Advances and New Frontiers in the Pathophysiology of Venous Neointimal Hyperplasia and Dialysis Access Stenosis. *Adv Chronic Kidney Dis*, 16(5), 329-338.
- [64] Asif, A., Leon, C., Orozco-Vargas, L. C., Krishnamurthy, G., Choi, K. L., Mercado, C., Merrill, D., Thomas, I., Salman, L., Artikov, S., & Bourgoignie, J. J. (2007). Accuracy of physical examination in the detection of arteriovenous fistula stenosis. *Clin J Am Soc Nephrol*, 2(6), 1191-1194.
- [65] Dinwiddie, L. C., Frauman, A. C., Jaques, P. F., Mauro, M. A., Hogan, S. L., & Falk, R. J. (1996). Comparison of measures for prospective identification of venous stenoses. *ANNA J*, 23(6), 593-600.
- [66] Huijbregts, H. J., Blankestijn, P. J., Caro, C. G., Cheshire, N. J., Hoedt, M. T., Tutein, Nolthenius, R. P., & Moll, F. L. (2007). A helical PTFE arteriovenous access graft to swirl flow across the distal anastomosis: results of a preliminary clinical study. *Eur J Vasc Endovasc Surg*, 33(4), 472-475.
- [67] Gage-C, S. M. P. A., & Lawson, J. H. (2010). New Developments in Hemodialysis Grafts. *Endovascular Today*. June. <http://bmctoday.net/evtoday/2010/06/article.asp?f=new-developments-in-hemodialysis-grafts> accessed 22 august 2012).
- [68] Centre for Applied Biomedical Engineering Research. (2012). University of Limerick, Ireland. *Haemodynamic Influences on Cellular Behaviour in Vascular Access Junctions- A Computational and Experimental Study.*, <http://www3.ul.ie/caber/index.php/research/haemodynamic-influences-on-cellular-behaviour-in-vascular-access-junctions/>, Accessed 18 July).
- [69] Conte, M. S., Nugent, H. M., Gaccione, M. A., et al. (2009). Multicenter phase I/II trial of the safety of allogeneic endothelial cell implants after the creation of arteriovenous access for hemodialysis use: the V-HEALTH study. *J Vasc Surg*, 50, 1359-1368.
- [70] Cable, D. G., Caccitolo, J. A., Caplice, N., O'Brien, T., Simari, R. D., Daly, R. C., Dearani, J. A., Mullany, C. J., Orszulak, T. A., & Schaff, H. V. (1999). The role of gene therapy for intimal hyperplasia of bypass grafts. *Circulation*, 100(19), 392-396.
- [71] Luo, Z., Akita, G. Y., Date, T., Treleaven, C., Vincent, K. A., Woodcock, D., Cheng, S. H., Gregory, R. J., & Jiang, C. (2005). Adenovirus-mediated expression of beta-adrenergic receptor kinase C-terminus reduces intimal hyperplasia and luminal stenosis of arteriovenous polytetrafluoroethylene grafts in pigs. *Circulation*, 111(13), 1679-1684.

- [72] Lindsay, R. M. (1997). Assessment of access recirculation during haemodialysis. *Curr Opin Nephrol Hypertens*, 6(6), 570-574.
- [73] Basile, C., Ruggieri, G., Vernaglione, L., Montanaro, A., & Giordano, R. (2003). A comparison of methods for the measurement of hemodialysis access recirculation. *J Nephrol*, 16(6), 908-913.
- [74] Schneditz, D. (1998). Theoretical and practical issues in recirculation; assessment of vascular access. *EDTNA ERCA J*, 24(2), 3-6.
- [75] Sherman, R. A., & Kapoian, T. (1997). Recirculation, urea disequilibrium, and dialysis efficiency: peripheral arteriovenous versus central venovenous vascular access. *Am J Kidney Dis*, 29(4), 479-489.
- [76] Whittier, W. L. (2009). Surveillance of hemodialysis vascular access. *Semin Intervent Radiol*, 26(2), 130-138.
- [77] Morsy, A. H., Kulbaski, M., Chen, C., Isiklar, H., & Lumsden, A. B. Res. (1998). Incidence and characteristics of patients with hand ischemia after a hemodialysis access procedure. *J Surg*, 74(1), 8-10.
- [78] Tordoir, J. H., Dammers, R., & van der Sande, F. M. (2004). Upper extremity ischemia and hemodialysis vascular access. *Eur J Vasc Endovasc Surg*, 27, 1-5.
- [79] Mickley, V. (2008). Steal syndrome--strategies to preserve vascular access and extremity. *Nephrol Dial Transplant*, 23(1), 19-24.
- [80] Goff, C. D., Sato, D. T., Bloch, P. H., et al. (2000). Steal syndrome complicating hemodialysis access procedures: can it be predicted? *Ann Vasc Surg*, 14, 138-144.
- [81] Schanzer, H., Schwartz, M., Harrington, E., & Haimov, M. (1988). Treatment of ischemia due to "steal" by arteriovenous fistula with distal artery ligation and revascularization. *J Vasc Surg*, 7(6), 770-773.
- [82] Zanow, J., Petzold, K., Petzold, M., Krueger, U., & Scholz, H. (2006). Flow reduction in high-flow arteriovenous access using intraoperative flow monitoring. *J Vasc Surg*, 44(6), 1273-1278.
- [83] Minion, D. J., Moore, E., & Endean, E. (2005). Revision using distal inflow: a novel approach to dialysis-associated steal syndrome. *Ann Vasc Surg*, 19(5), 625-628.
- [84] West, J. C., Bertsch, D. J., Peterson, S. L., Gannon, M. P., Norkus, G., Latsha, R. P., & Kelley, S. E. Arterial insufficiency in hemodialysis access procedures: correction by "banding".
- [85] Rivers, S. P., Scher, L. A., & Veith, F. J. (1992). Correction of steal syndrome secondary to hemodialysis access fistulas: a simplified quantitative technique. *Surgery*, 112(3), 593-597.
- [86] Kirkman, R. L. (1991). Technique for flow reduction in dialysis access fistulas. *Surg Gyn Obstet*, 172(3), 231-233.

- [87] Zanow, J., Kruger, U., & Scholz, H. (2006). Proximalization of the arterial inflow: a new technique to treat access-related ischemia. *J Vasc Surg*, 43(6), 1216-1221.
- [88] Goel, N., Miller, G. A., Jotwani, M. C., Licht, J., Schur, I., & Arnold, W. P. (2006). Minimally Invasive Limited Ligation Endoluminal-assisted Revision (MILLER) for treatment of dialysis access-associated steal syndrome. *Kidney Int*, 70(4), 765-770.
- [89] Engelberts, I., Tordoir, J. H., Boon, E. S., & Schreij, G. (1995). High-output cardiac failure due to excessive shunting in a hemodialysis access fistula: an easily overlooked diagnosis. *Am J Nephrol*, 15.
- [90] Anderson, C. B., & Groce, M. A. (1975). Banding of arteriovenous dialysis fistulas to correct high-output cardiac failure. *Surgery*, 78(5), 552-554.
- [91] Parsi, K. (2007). Dermatological manifestations of venous disease. *Part I. Australian & New Zealand J Phlebol*, 10(1), 7-15, http://www.sydneyskinandvein.com.au/PDF_Uploads/39_DermManPart1.pdf, Accessed 23 August 2012).
- [92] Salgado, O. J., Terán, N. A., Rosales, B., & Garcia, R. A. (2008). Subcutaneous transposition of the superficial femoral artery for arterioarterial hemodialysis: technique and results. *Artif Organs*, 32(12), 969-973.
- [93] Yasunaga, C., Nakamoto, M., Fukuda, K., & Goya, T. (1995). Superficial repositioning of the artery for chronic hemodialysis: indications and prognosis. *Am J Kidney Dis*, 26, 602-606.
- [94] Weyde, W., Kuształ, M., Golebiowski, T., Letachowicz, K., Letachowicz, W., Wator-ek, E., Madziarska, K., Krajewska, M., Szyber, P., Janczak, D., & Klinger, M. (2012). Superficialization of the radial artery- an alternative secondary vascular access. *J Vasc Access*, 10.5301/jva.5000079.
- [95] Zanow, J., Kruger, U., Petzold, M., Petzold, K., Miller, H., & Scholz, H. (2005). Arterioarterial prosthetic loop: a new approach for hemodialysis access. *J Vasc Surg*, 41, 1007-1012.
- [96] Gray, R. J. (2002). *Dialysis Access: A multidisciplinary approach* Ambler: Lippincott Williams & Wilkins.
- [97] Mickley, V. (1996). Subclavian artery to right atrium haemodialysis bridge graft for superior vena caval occlusion. *Nephrol Dial Transplant*, 11(7), 1361-1362.
- [98] Kennealey, P. T., Elias, N., Hertl, M., Ko, D. S., Saidi, R. F., Markmann, J. F., Smoot, E. E., Schoenfeld, D. A., & Kawai, T. (2011). A prospective, randomized comparison of bovine carotid artery and expanded polytetrafluoroethylene for permanent hemodialysis vascular access. *J Vasc Surg*, 53(6), 1640-1648.
- [99] Tahami, V. B., Hakki, H., Reber, P. U., Widmer, M. K., & Kniemeyer, H. W. (2007). Polytetrafluoroethylene and bovine mesenteric vein grafts for hemodialysis access: a comparative study. *J Vasc Access*, 8(1), 17-20.

- [100] Katzman, H. E., Glickman, M. H., Schild, A. F., Fujitani, R. M., & Lawson, J. H. (2005). Multicenter evaluation of the bovine mesenteric vein bioprostheses for hemodialysis access in patients with an earlier failed prosthetic graft. *J Am Coll Surg*, 201(2), 223-230.
- [101] Glickman, M. H. (2011). HeRO Vascular Access Device. *Semin Vasc Surg*, 24(2), 108-112.
- [102] Katzman, H. E., Mc Lafferty, R. B., Ross, J. R., Glickman, M. H., Peden, E. K., & Lawson, J. H. (2009). Initial experience and outcome of a new hemodialysis access device for catheter-dependent patients. *J Vasc Surg*, 50(3), 600-7, e1.
- [103] Gage, S. M., Katzman, H. E., Ross, J. R., Hohmann, S. E., Sharpe, C. A., Butterly, D. W., & Lawson, J. H. (2012). Multi-center experience of 164 consecutive Hemodialysis Reliable Outflow [HeRO] graft implants for hemodialysis treatment. *Eur J Vasc Endovasc Surg*, 44(1), 93-99.
- [104] Chemla, E. S., Nelson, S., & Morsy, M. (2011). Early cannulation grafts in straight axillo-axillary angioaccesses avoid central catheter insertions. *Semin Dial*, 24(4), 456-459.
- [105] Ladenheim, E. D., Lum, C., Chadwick, N., & Agrawal, S. (2012). High Incidence of Perigraft Seroma Formation with Gelatin-Coated Polytetrafluoroethylene Grafts. *Semin Dial*, 10.1111/j.1525-139X.2012.01085.x.
- [106] Schild, A. F., Perez, E. A., Gillaspie, E., Patel, A. R., Noicely, K., & Baltodano, N. (2007). Use of the Vectra polyetherurethaneurea graft for dialysis access in HIV-positive patients with end-stage renal disease. *Vasc Endovasc Surg*, 41(6), 506-508.
- [107] Jefic, D., Reddy, P. P., Flynn, L. M., et al. (2005). A single center experience in the use of polyurethaneurea arteriovenous grafts. *Nephrol News*, 19(19), 44-47.
- [108] Hashi, C. K., & Glickman, M. H. (2011). Preclinical results of a prosthetic, early-stick graft with functional endothelium. *J Vasc Access*, 12(3), 231-218.
- [109] Naito, Y., Shinoka, T., Duncan, D., Hibino, N., Solomon, D., Cleary, M., Rathore, A., Fein, C., Church, S., & Breuer, C. (2011). Vascular tissue engineering: towards the next generation vascular grafts. *Adv Drug Deliv Rev*, 63(4-5), 312-323.
- [110] Wystrychowski, W., Cierpka, L., Zagalski, K., Garrido, S., Dusserre, N., Radochonski, S., Mc Allister, T. N., & L'heureux, N. (2011). Case study: first implantation of a frozen, devitalized tissue-engineered vascular graft for urgent hemodialysis access. *J Vasc Access*, 12(1), 67-70.
- [111] Windus, D. W. (1994). The effect of comorbid conditions on hemodialysis access patency. *Adv Ren Replace Ther*, 1(2), 148-154.
- [112] Cases, A., & Coll, E. (2002). Chronic hypotension in the dialysis patient. *J Nephrol*, 15(4), 331-335.

- [113] Tsai, Y. T., Lin, S. H., Lee, G. C., Huen, G. G., Lin, Y. F., & Tsai, C. S. (2002). Arteriovenous fistula using transposed basilic vein in chronic hypotensive hemodialysis patients. *Clin Nephrol*, 57(5), 376-380.
- [114] Gagliardi, G. M., Rossi, S., Condino, F., Mancuso, D., Greco, F., Tenuta, R., Savino, O., Bonofiglio, R., Domma, F., & Latorre, G. (2011). Malnutrition, infection and arteriovenous fistula failure: is there a link? *Vasc Access*, 12(1), 57-62.
- [115] Mallamaci, F., Bonanno, G., Seminara, G., Rapisarda, F., Fatuzzo, P., Candela, V., Scudo, P., Spoto, B., Testa, A., Tripepi, G., Tech, S., & Zoccali, C. (2005). Hyperhomocysteinemia and arteriovenous fistula thrombosis in hemodialysis patients. *Am J Kidney Dis*, 45(4), 702-707.
- [116] Manns, B. J., Burgess, E. D., Parsons, H. G., Schaefer, J. P., Hyndman, M. E., & Scott-Douglas, N. W. (1999). Hyperhomocysteinemia, anticardiolipin antibody status, and risk for vascular access thrombosis in hemodialysis patients. *Kidney Int*, 55(1), 315-320.
- [117] Shafi, S. T., & Gupta, M. (2007). Risk of vascular access thrombosis in patients with systemic lupus erythematosus on hemodialysis. *J Vasc Access*, 8(2), 103-108.