

# We are IntechOpen, the world's leading publisher of Open Access books Built by scientists, for scientists

6,900

Open access books available

186,000

International authors and editors

200M

Downloads

Our authors are among the

154

Countries delivered to

TOP 1%

most cited scientists

12.2%

Contributors from top 500 universities



WEB OF SCIENCE™

Selection of our books indexed in the Book Citation Index  
in Web of Science™ Core Collection (BKCI)

Interested in publishing with us?  
Contact [book.department@intechopen.com](mailto:book.department@intechopen.com)

Numbers displayed above are based on latest data collected.  
For more information visit [www.intechopen.com](http://www.intechopen.com)



---

# Management of Hepatobiliary Trauma

---

Rajan Jagad, Ashok Thorat and Wei-Chen Lee

Additional information is available at the end of the chapter

<http://dx.doi.org/10.5772/52107>

---

## 1. Introduction:

The liver is the most commonly injured solid abdominal organ, despite its relative protected location [1, 2]. Treatment of traumatic liver injuries is based on patient physiology, mechanism and degree of injury, associated abdominal and extra-abdominal injuries and local expertise. Non-operative management has evolved into the treatment of choice for most patients with blunt liver injuries who are hemodynamically stable and success rates for non-operative management commonly are greater than 95%. With the sweeping shift towards the non-operative management, most hepatic injuries can be treated conservatively [3, 4, 5].

More recently several authors have highlighted an excessive use of non-operative management (NOM), which for some high grade liver injuries is pushed far beyond the reasonable limits, carrying increased morbidity at short and long term, such as bilomas, biliary fistula, early or late haemorrhage, false aneurysm, arterio-venous fistulae, haemobilia, liver abscess, and liver necrosis [5]. Incidence of complications attributed to NOM increases in concert with the grade of injury. In a series of 337 patients with liver injury grades III-V treated non-operatively, those with grade III had a complication rate of 1%, grade IV 21%, and grade V 63% [6].

## 2. Mechanism of injury and anatomic consideration:

Road traffic accident, antisocial violent behaviours, industrial and farming accidents are the commonest mode of injury to the liver. Though the liver is protected by the rib cage, as the largest solid organ in the abdomen, the liver is particularly vulnerable to the ability of compressive abdominal blows to rupture its relatively thin capsule. The vasculature consists of wide-bore, thin-walled vessels with a high blood flow, and injury is usually associated with significant blood loss. Blunt trauma in a road traffic accident, or fall from a height, may result in a deceleration injury as the liver continues to move on impact. This leads to tears at

sites of fixation to the diaphragm and abdominal wall. A well-recognised deceleration injury involves a fracture between the posterior sector (segments VI and VII) and the anterior sector (segments V and VIII) of the right lobe. This type of injury can lead to rupture of right hepatic vein and significant bleeding. In contrast, direct blow on right upper abdomen during vehicular accident or direct blow by a weapon or fist can lead to stellate type of injury to the central liver (segment IV, V and VIII). This type of injury can lead to massive bleeding from portal vein or hepatic vein and can also lead to bile duct injury.

Penetrating injuries may be associated with a significant vascular injury. For example, a stab injury may cause major bleeding from one of the three hepatic veins or the vena cava and also from the portal vein or hepatic artery if it involves the hilum. Gunshots may similarly disrupt these major vessels; this disruption may be much more marked than with stab wounds due to the cavitation effect, particularly with bullets from high-velocity weapons.

The connection between the thin-walled hepatic veins and the inferior vena cava (IVC), at the site where the ligamentous mechanism anchors the liver to the diaphragm and posterior abdominal wall, represents a vulnerable area, particularly to shearing forces during blunt injury. Disruption here leads to the “juxtahepatic” venous injuries, which are usually associated with major blood loss and present a particularly challenging management problem.

3. Grade of liver injury:

The severity of liver injuries ranges from the relatively inconsequential minor capsular tear to extensive disruption of both lobes with associated hepatic vein, portal vein, or vena caval injury. Several classifications have been advised to grade the liver injury and management accordingly. Following table shows the grade of liver injury. Grade I & II are successfully managed non-operatively in most cases. Grade IV and onward injuries will eventually require emergency exploration. Grade III injuries require observation and if such patients are hemodynamically stable will recover with conservative treatment. Such patients should be closely followed in ICU with serial monitoring of hemoglobin and hematocrit level along with cardio-respiratory monitoring. Any fall in hematocrit or hemodynamic instability not responding to fluid resuscitation warrants urgent exploration.

Liver organ injury scale		
Grade		description
I	Hematoma	Subcapsular, <10% surface area
	Laceration	Capsular tear, < 1 cm parenchymal depth
II	Hematoma	Subcapsular, <10%-50% surface area; intraparenchymal, <10 cm in diameter
	Laceration	1-3 cm parenchymal depth, <10 in Length

Liver organ injury scale		
III	Hematoma	Subcapsular, >50% surface area or expanding; ruptured subcapsular or parenchymal hematoma
	Laceration	>3cm parenchymal depth
IV	Hematoma	Parenchymal disruption involving 25%-75% of hepatic lobe or 1-3 Couinaud segments within a single lobe
V	Laceration	Parenchymal disruption involving >75% of hepatic lobe >3 Couinaud segments within a single lobe
	Vascular	Juxtahepatic venous injuries; ie, retrohepatic vena cava/central major hepatic vein
VI	Hepatic avulsion	

**Table 1.** Liver Organ Injury Scale.

**4. Early Measures:**

**4.1. Resuscitation and treatment of Hemodynamic instability:**

It is generally accepted that initial resuscitation and management is the same as for any patient with major trauma and should follow the Advanced Trauma Life Support (ATLS) principles of aggressive fluid resuscitation, guided by monitoring of central venous pressure and urinary output [7]. Management should also be directed toward avoidance of any of the sinister triad of hypothermia, coagulopathy, and acidosis, which are associated with significantly increased mortality. Mechanisms to avoid hypothermia are standard now in major centres and include the use of rewarming blankets and heat exchanger pumps for rapid infusion of resuscitation fluids and blood [8].

The next management phase depends largely on the response to resuscitation and the stability of the patient. Liver injury should be suspected in all patients with blunt or penetrating thoracoabdominal trauma but particularly in shocked patients with blunt or penetrating trauma to the right side. There are two major determinants to consider when making decisions in suspected liver trauma: hemodynamic stability and mechanism of injury. In general, hemodynamic instability or peritonism makes decision-making in trauma more straightforward, although ultimately, the surgical procedure required may be complex. Management decisions are more challenging when patients are hemodynamically stable as the array of potential therapeutic modalities are substantial and the patient’s future clinical course is unknown [9].

**4.2. Advanced Trauma Life Support:**

The appropriate evaluation and management of liver injuries results from an organized approach to abdominal trauma. Experience and technical developments over the past several decades make the current approach both logical and effective. It is generally accepted that ini-

tial resuscitation and management is the same as for any patient with major trauma and should follow the Advanced Trauma Life Support (ATLS) principles of aggressive fluid resuscitation, guided by monitoring of central venous pressure and urinary output [7]. Management should also be directed toward avoidance of any of the sinister triad of hypothermia, coagulopathy, and acidosis, which are associated with significantly increased mortality.

#### **4.3. Focused assessment by ultrasound for trauma (FAST):**

Ultrasonography (USG) is the most important and readily available investigation for any patient with blunt or sharp abdominal injury. It is particularly useful for detecting injury to parenchymal organs and the presence of free intraperitoneal fluid or blood. USG is a quick, non-invasive, inexpensive, and transportable tool, used with increasing frequency in the initial workup of patients with abdominal trauma [10].

The particular relevance to major liver injury is the focused assessment by ultrasound for trauma (FAST), often performed in the emergency department, which involves a rapid examination of several areas, namely, the pericardial region, right upper quadrant (including Morrison's pouch), left upper quadrant, and the pelvis, specifically looking for free fluid. One of the main limitations of USG is that parenchymal injuries, sometimes relevant and requiring surgical or embolization therapy, may be present without combined peritoneal fluid [11,12].

On the basis of detection of free fluid or parenchymal injury, the sensitivity of USG has been found to be 72% to 95% for abdominal organ injuries, 51% to 92% for liver lesions, and 98% for grade III or higher liver injuries [13]. Richards et al reported 56% and 68% sensitivity of FAST and complete USG, respectively, in detecting childhood abdominal trauma [11].

Detection of peritoneal fluid is the first step in FAST. Fluid in the right upper quadrant or in the right upper quadrant and pelvic recess suggests hepatic injury, as opposed to splenic, renal, or enteric injury [14]. Fluid limited to the left upper quadrant or to both upper quadrants is not seen in patients with isolated liver trauma [14]. Hemoperitoneum recognition must prompt further imaging, but its absence does not definitely exclude parenchymal injury. Clinical assessment and observation are also relevant in combination with USG. With special reference to liver trauma, it has been noted that patients with negative USG results but with an aspartate aminotransferase level of greater than 360 IU/L should undergo CT imaging because of potentially overlooked hepatic injury, whereas patients with normal levels can be effectively discharged [15].

Although FAST provides a rapid assessment of liver disruption and intraperitoneal bleeding, it is a limited scan that is highly operator dependent. It is very important to note that a negative FAST scan does not safely rule out injury [12, 16]. Due to the operator dependence of the modality, different end points, and inconsistent comparative gold standards in the studies, the reported specificities, sensitivities, and overall accuracies are variable [17]. It has been demonstrated that up to a quarter of hepatic and splenic injuries, as well as renal, bladder, pancreatic, mesenteric, and gut injuries, can be missed if ultrasound is used as the primary investigative modality in the stable patient. However, while the possibility of false

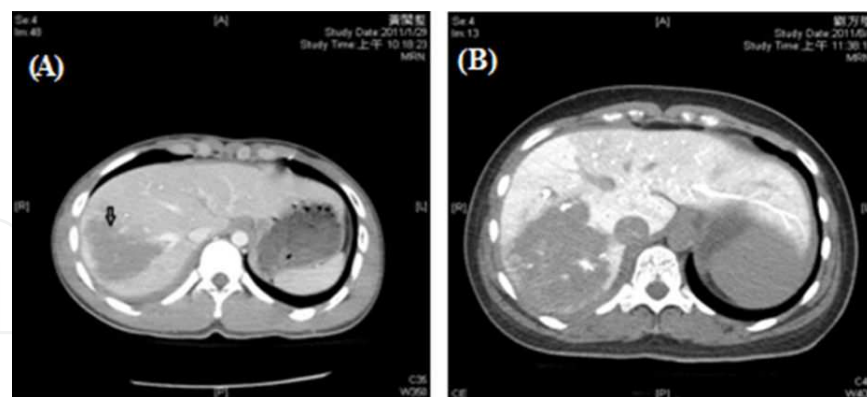
negatives is ever present, the combination of a negative ultrasound scan and normal clinical examination and observations almost excludes liver injury in the event of significant blunt trauma [12, 18].

#### 4.4. Computed Tomography:

The wide availability of high-resolution CT has changed the manner in which blunt abdominal trauma is diagnosed and managed (figure 1). Currently, multi-detector computed tomography (MDCT) scanning with intravenous contrast is the gold standard diagnostic modality in hemodynamically stable patients with intra-abdominal fluid detected with FAST.

CT has a sensitivity of 92% to 97% and a specificity of 98.7% for detection of liver injury. The type and grade of liver injury, the volume of hemoperitoneum, and differentiation between clotted blood and active bleeding can be identified. In addition to increasing the rate of detection of liver lesions following trauma, CT has also helped to improve the understanding of the course of liver injuries [19]. CT scan also allows diagnosis of associated intraperitoneal and retroperitoneal injuries, including splenic, renal, bowel, and chest trauma, and pelvic fractures.

Even though NOM has proven to be of tremendous benefit, a couple of controversies regarding the current management of trauma patients should be discussed. Advances in CT technology have improved the practitioner's ability to determine the degree of injury and to identify patients who are more likely to fail NOM. However, until now, MDCT scanning has not been able to differentiate, in a precise manner, among which patients should be treated conservatively, which would benefit from angio-embolization and which would respond best to a surgical response.



**Figure 1.** CT scan images of blunt abdominal trauma patients. (A) CT scan of liver showing intraparenchymal hematoma in segment VI. (B) CT scan of liver showing intraparenchymal hematoma in segment VI and extending to segment VII and V.

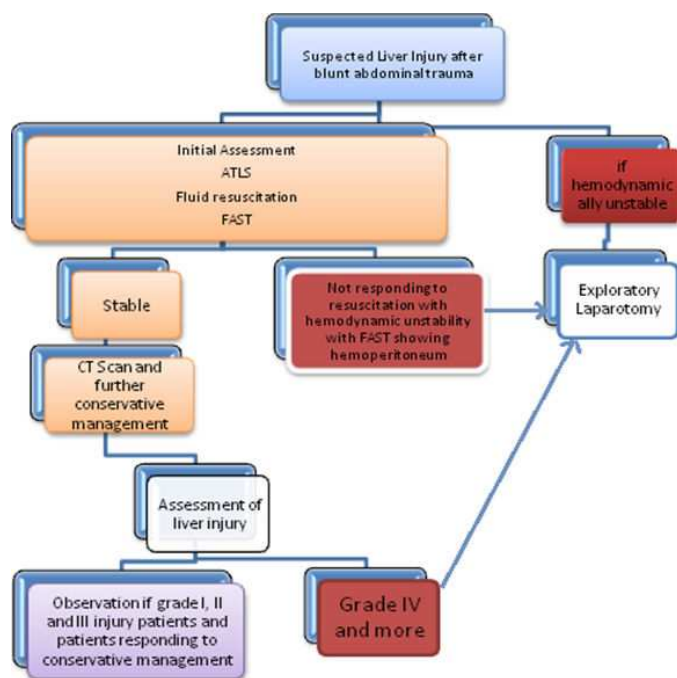
Although CT is the investigative gold standard, it is important to remember that it involves exposure to high levels of ionising radiation and the use of intravenous contrast may compromise renal function. In the majority of hospitals the use of CT requires movement of the patient away from adequate resuscitation facilities to the X-ray department, highlighting the



importance of hemodynamic stability in patients with abdominal trauma being considered for CT examination [16].

4.5. Diagnostic laparoscopy:

The use of laparoscopy for trauma patients has been slower to evolve partly due to factors inherent in the trauma population and some limitations of the laparoscopic technique. Initially, the evaluation of peritoneal violation in hemodynamically stable patients was seen as the greatest benefit of laparoscopy for trauma [20]. Improvements in laparoscopic training and technology have enabled an increase in the use of diagnostic and therapeutic procedures in trauma patients.



**Figure 2.** Algorithm - Advanced trauma life support, FAST- focused assessment by ultrasound for trauma. ATLS for managing liver trauma patients.

There are a number of series describing the successful haemostasis of minor liver injuries, in both the civilian [21] and military setting [22], although it is likely that these were self-limiting injuries anyway.

5. Management of hepatic Trauma:

There are two major determinants to consider when making decisions in suspected liver trauma: hemodynamic stability and mechanism of injury. In general, hemodynamic instability or peritonism makes decision-making in trauma more straightforward, although ultimately, the surgical procedure required may be complex (figure 2). Management decisions

are more challenging when patients are hemodynamically stable as the array of potential therapeutic modalities are substantial and the patient's future clinical course is unknown [9].

### 5.1. Non operative management:

Hogarth Pringle, in 1908, provided the first description of operative management of liver trauma. Unfortunately, all eight patients died and Pringle recommended conservative non-operative management of these patients. In the modern surgical literature, non-operative management was first reported in 1972 and has been one of the most significant changes in the treatment of liver injuries over the last two decades [23, 24].

Initiated in pediatric trauma patients [25], nonsurgical management of blunt liver trauma has become recognized as an appropriate treatment option for hemodynamically stable adult patients with blunt hepatic injury [26, 27].

With the wide availability and improved quality of CT scanning, and the more modern, less invasive intervention options, such as angio-embolization, NOM has evolved into the treatment of choice for hemodynamically stable patients. Although angio-embolization has been defined the logical augmentation of damage control techniques for controlling hemorrhage, the overall liver-related complication rate can be as high as 60.6% with 42.2% incidence of major hepatic necrosis [28]. Non-operative management (NOM) consists of close observation of the patient completed with angio-embolization, if necessary. Observational management involves admission to a unit and the monitoring of vital signs, with strict bed rest, frequent monitoring of hemoglobin concentration and serial abdominal examinations [29].

Following factors contribute to conservative management of liver trauma:

- i. Realization that more than 50% of liver injuries stop bleeding spontaneously at the time of exploration
- ii. Availability of CT scan imaging for better assessment of grade of liver injury and associated injuries
- iii. The success of non-operative management in paediatric patients
- iv. Knowledge that the liver has tremendous capacity of healing after injury,
- v. Improved critical care management in specialized unit
- vi. The introduction of angio-embolization which allows patients with specific CT findings to potentially be treated in a minimally invasive manner.

Given the availability of angio-embolization, trauma surgeons are more likely to initiate non-operative treatment, even in higher grade injuries, because, in the event of failure, intervention in the form of angio-embolization is possible and, in the event of angio-embolization failure, surgical intervention is possible. Criteria for non-operative management include foremost, hemodynamic stability, absence of other abdominal injuries that require laparotomy, immediate availability of resources including a fully staffed operating room, and a vigilant surgeon. While non-operative management was initially introduced for minor injuries,



it was soon in vogue for more severe injuries (grades III–V) [6, 30]. Close observation and repeated scans are usually recommended to document non-expansion of hematoma and healing of the injuries over time. The shift towards non-operative management of liver injuries has resulted in a lower mortality rate, but still a significant percentage of complications [31]. The current reported success rate of non-operative management of hepatic trauma ranges from 82% to 100%. Twenty-five percent of patients with blunt hepatic injury managed non-operatively, 92% of whom have grade IV or V injury will require an intervention for complications [5].

Despite the reduction of mortality that has been achieved using angio-embolization, some studies describe a rise in severe but treatable complications such as hepatic necrosis, abscesses or bile leakage [6, 28]. Gallbladder ischemia, hepatic parenchymal necrosis and biloma may also occur, and in patients with a high grade liver injury (grade 4 and 5) the incidence of complications can be high [32].

A determinant of the success of NOM is the level of cooperation between different specialists in the hospital. Good teamwork among the trauma surgeon, the anaesthesiologist and the interventional radiologist leads to a quicker understanding of the underlying injuries and thus shortens the time between entering the hospital and the initiation of therapeutic interventions. This seems obvious in level 1 trauma centers, but can be a matter of concern, especially in level II or III trauma centers.

While there has been considerable debate about the grade of liver injury and the acceptable volume of hemoperitoneum, it is now generally accepted that the ultimate decisive factor in favour of non-operative management is the hemodynamic stability of the patient, irrespective of the grade of injury or the volume of hemoperitoneum. It is also essential that appropriate clinical and radiological follow-up is arranged [33].

The rate of liver-related complications is low, and generally ranges from 0% to 7% [31]. Liver-related complication rates in high-grade liver injury patients are 11–13% and can be predicted by the grade of liver injury and the volume of packed red blood cells transfused at 24 hours post-injury [6, 34]. Incidence of complications attributed to NOM increases in concert with the grade of injury. In a series of 337 patients with liver injury grades III–V treated non-operatively, those with grade III had a complication rate of 1%, grade IV 21%, and grade V 63% [6]. Patients with grades IV and V injuries are more likely to require operation, and to have complications of non-operative treatment. Therefore, although it is not essential to perform liver resection at the first laparotomy, if bleeding has been effectively controlled, increasing evidence suggests that liver resection should be considered as a surgical option in patients with complex liver injury, as an initial or delayed strategy, which can be accomplished with low mortality and liver related morbidity in experienced hands [3].

Some of the complications related to conservative management of liver injuries are bile leaks, liver abscess, delayed haemorrhage, false aneurysm, arterio-venous fistulae, haemobilia, liver and gall bladder necrosis. Carrillo described complications in up to 85% of patients with a high ( $\geq 4$ ) Abbreviated Injury Score (AIS) in a series of 32 patients who were treated non-operatively [27].

High grade liver injury (>3) treated with NOM and angio-embolization may be associated with severe complications like liver necrosis, bile leaks and severe sepsis. Mortality has been noted in up to 11% of patients in high grade liver injury treated conservatively [35]. Although angio-embolization has been defined the logical augmentation of damage control techniques for controlling hemorrhage, the overall liver-related complication rate can be as high as 60.6% with 42.2% incidence of major hepatic necrosis [28]. Early liver lobectomy in such cases required lesser number of procedures and achieved lower complication rate and lower mortality compared to less aggressive approaches such as serial operative debridements and/or percutaneous drainage [36].

## 5.2. Transarterial Embolization (TAE):

TAE of blunt hepatic injury was first recognized as a safe and effective treatment for the control of recurrent postoperative hemorrhage, hemobilia and hepatic artery-portal vein fistulas in the late 1970s [37]. Hashimoto et al. [38] also showed the efficacy of emergency TAE in four patients with severe complex hepatic injury and suggested that this method may be useful in nonsurgical management of unstable patients with severe hepatic injury. This multidisciplinary approach to the management of complex hepatic injuries is becoming much more important as the role of interventional radiology expands. Denton et al. [39] reported successful use of a combination of arterial embolization and transhepatic venous stenting in the management of a grade V injury involving the retrohepatic vena cava in a patient whose injury had been temporarily controlled by perihepatic packing. Recent more extensive series of angiography for control of hepatic haemorrhage have reported increasing success, with identification and control of bleeding rates ranging from 68 to 87%. [40] Angiography and embolization or stenting is a very useful adjunctive technique in the stable patient who is being managed non-operatively or in the patient who either has been stabilised by perihepatic packing or has re-bled after a period of initial stability.

The recent literature reveals that the increased use of angio-embolization and decreased mortality rates result in increased frequencies of severe complications, such as liver necrosis, bile leakage and intra-abdominal abscesses [28, 32, 41]. Indications of angiography in hemodynamically stable patients are high grade liver injury in CT scan, evidence of arterial vascular injury, and the presence of hepatic venous injury [41]. Angio-embolization can be used immediately after a damage control laparotomy as part of the primary haemorrhage control strategy [42]. Alternatively, angio-embolization can be used in post-operative patients to manage ongoing bleeding not associated with hemodynamic compromise [32]. This can involve not only angio-embolization, but also the placement of stents to reconstruct vasculature [39].

## 5.3. Complications of non-operative management:

### 5.3.1. Biliary complications:

Bile leaks are a frequent complication in the non-operative management of liver injuries, occurring in 6% to 20% of cases. Bile leaks present either as trauma, drainage of bile through

surgically placed drain, or percutaneously placed catheter to drain biloma. The time of presentation of biliary leaks is variable. Ultrasound and CT scan are used to diagnose a biloma, whereas a hepatobiliary iminodiacetic acid scan is used to show an active bile leak.

Majority of bile leaks can be treated by ultrasound or CT-guided percutaneous drainage or ERCP and stenting.

#### 5.3.2. *Delayed haemorrhage:*

The prevalence of delayed haemorrhage following non-operative management of blunt liver injury ranges from 1.7 to 5.9% [27, 43]. The mechanism of delayed hemorrhage may be related to an expanding injury or to a pseudoaneurysm induced by a biloma which eventually causes an expanding hematoma and free rupture into the peritoneal cavity. Early bleeding episodes are attributed directly to the traumatic insult, while late hemorrhage is probably related to infectious hepatic complications. Angio-embolization may prove an useful technique to deal with such complications.

### 5.4. Operative management:

Patients with associated liver and spleen injuries are twice as likely to fail non-operative therapy as those with only a single organ injured [44]. Missing associated intra-abdominal injury and delayed treatment, significantly affects the outcome. This occurs more often in conjunction with liver than with splenic injury, especially pancreas and bowel injury are significantly associated with liver injury in blunt trauma.

Patients with high grade liver injury who are hemodynamically unstable require surgical management. Failure of NOM also requires urgent exploration and appropriate surgical management.

Anesthesia must ensure that blood products are already in the room. The massive transfusion protocol should be activated so that the blood bank is always ahead of the patient's needs for packed red blood cells, fresh frozen plasma, platelets, and cryoprecipitate. Adequate vascular access and arterial blood pressure monitoring are essential. It is important to preferentially have venous access above the diaphragm. Resuscitation fluids infused under pressure through femoral access will exacerbate hepatic venous bleeding, at times dramatically so. Massive transfusion protocols should be activated early to prevent any delay in resuscitation with blood products.

The most widely adopted incision for the patient with liver trauma is a long midline laparotomy, which can be extended to the right chest if a posterior right lobe injury, major hepatic venous injury, or vena caval injury is encountered. An effective alternative, which gives good exposure and avoids a thoracotomy, is a right subcostal extension. A bilateral subcostal incision is sometimes favoured by hepatobiliary surgeons if there is an obvious penetrating through-and-through liver injury. This allows excellent exposure of the right lobe of the liver, the hepatic veins, and vena cava without having to open the chest or diaphragm; however, it does compromise access to the lower abdomen.

If a major liver injury is encountered, immediate control of bleeding is an absolute priority because the greatest threat to the patient's life at this juncture is exsanguination. Liver should immediately be manually closed and compressed. Patients with massive hemoperitoneum are at risk of coagulopathy, hypothermia and acidosis. Measures should be taken to prevent and treat all these consequences of massive bleeding. If this still does not control the bleeding, pedicle occlusion (Pringle manoeuvre) should be applied using an atraumatic vascular clamp or non-crushing bowel clamp. If bleeding stops after Pringle manoeuvre, the bleeding is from branches of portal vein or hepatic artery. If bleeding continuous after this manoeuvre, the bleeding is likely to be from hepatic vein or IVC. The time of Pringle manoeuvre is controversial, but it can be applied up to 1 hour without compromising the blood supply to the liver.

#### *5.4.1. Damage control surgery:*

The concept of damage control was introduced by Stone et al [45] in the 1980s and promulgated by the group at Ben Taub in 1992 [46]. This came after the report by Denver General in patients sustaining fatal hepatic hemorrhage.

After trauma, hemostasis was not possible as patients were hypothermic, acidotic, and receiving large volumes of packed red cells before blood component or fresh blood [47]. This led to the concept of the "bloody vicious cycle." The term "damage control" was popularized by the group at the University of Pennsylvania in the 1993 [48]. They described initial control of haemorrhage and contamination followed by packing and temporary abdominal closure, ICU restoration of normal physiology, and delayed definitive repair of intra-abdominal injuries. The decision for damage control should be made very early in the operation before the onset of severe coagulopathy, acidosis, and hypothermia. Early institution of packing as a damage control technique has been shown to lessen mortality [49].

The damage control concept is very appropriate for the management of major liver injuries. The three key factors that interact to produce a deteriorating metabolic situation are hypothermia, coagulopathy, and acidosis. Patients in this condition are at the limit of their physiological reserve and persistence with prolonged and complex surgical repair attempts will cause exceptionally high mortality [50]. Early recognition of hypothermia, coagulopathy, and acidosis is the key to the damage control approach. It is recommended that definitive surgery should cease and a damage control approach be adopted when hypothermia is deteriorating or a temperature of 34°C is reached, when coagulopathy has developed (nonsurgical oozing or prothrombin time greater than 50% above normal), or when acidosis exists (pH<7.2 despite adequate volume resuscitation).

Once the patient is stabilized, patient is returned to the operation theatre and definitive surgery is undertaken if needed.

#### *5.4.2. Perihepatic packing:*

Tamponade which is achieved by manual compression that can then be maintained by packs, which can also be manually compressed if bleeding continues. Packs placed in an an-



terio-posterior axis will often distract the injured liver further and worsen the bleeding. The lobes of the liver must be compressed back to normal position, essentially back toward mid-line. Simultaneously, the liver is pushed toward the diaphragm. Maintenance of this anatomic compression by the first or second assistant is critical to reduce bleeding as the surgeon assesses the liver injury or mobilizes the liver. Perihepatic packing can help to maintain this tamponade. Most minor venous bleeding and small lacerations to the parenchyma can be temporized by this manoeuvre. Haemostatic agents such as surgicell, thrombin-soaked gel foam, or fibrin glue are useful adjuncts.

Packing is not as effective for the injuries to the left hemiliver, because with the abdomen open, there is insufficient abdominal and thoracic wall anterior to the left hemiliver to provide adequate compression. Fortunately, haemorrhage from the left hemiliver can be controlled by dividing the left triangular and left coronary ligaments and compressing the left hemiliver between the hands.

Packs must be placed around the liver to reconstitute its anatomical shape. Packs should never be inserted into the hepatic wound, as it will tear the vessels and will increase the bleeding. It is also important to avoid excessive packing, as compression of IVC can lead to resultant decreased venous return, and reduces left ventricular filling. Excessive packing can also lead to compartment syndrome and multi-organ failure [51]. Conversely under-packing is associated with increased transfusion requirements and unplanned re-look laparotomies [52]. To reduce the risk of abdominal compartment syndrome, some advocate closing the upper part of the wound to enhance the tamponade effect but leaving the lower two-thirds open and temporarily covered with a silastic sheet sutured to the skin edges [53, 54].

Perihepatic packing will control profuse haemorrhage in up to 80% of patients undergoing laparotomy and will allow intraoperative resuscitation (resuscitative packing) [50, 55]. In the management of severe injuries of the liver, packing has emerged as the key to effective damage control [56]. However, more definitive “therapeutic” packing is also a very effective technique, particularly when used judiciously to prevent the cascade of hypothermia, coagulopathy, and acidosis [57].

Once the patient is stabilized, temporary closure of the abdomen is done and patient is shifted to the ICU. Packs can be removed after 36-48 hours. Broad spectrum antibiotics should be started to prevent sepsis. The exact timing of the removal of packs is controversial, but they should not be removed before 24 hours as this is related to re-bleeding and leaving them in place for 24 hours or more does improve outcome [58]. Even delayed removal (up to 1 week) has been reported without increasing the morbidity [59]. During removal, the packs should gently be removed after soaking with saline. Liver should be checked for re-bleeding and if adequate hemostasis is achieved, closure of the abdomen can be done after putting a drain.

#### 5.4.3. Hepatorrhaphy:

This is an older technique which involves passing deep parenchymal sutures to bring disrupted tissue together compressing bleeding vessels and reducing dead space. The major

drawback of this procedure is ischemic necrosis and infection of the liver parenchyma. However, some advocate hepatorrhaphy for “hard-to-reach” areas such as the dome and posterior portion of the right lobe.

#### *5.4.3.1. Mesh Wrapping:*

Mesh-wrapping is a quick and technically feasible method to achieve definitive hemostasis in severe liver trauma. It can be combined ideally with conventional procedures. Mesh-wrapping technique provides a highly selective, tight compression confined to the liver and does not produce an increased intra-abdominal pressure. Emphasis should be given in two important technical aspects while mesh wrapping. First, the traumatized liver has to be slung with the mesh under enough tension to create a tamponade effect. In addition the mesh should be attached into two anchoring stable points. The diaphragmatic crus and the falciform ligament provide the best options to stabilize the mesh. The mesh is resorbable and therefore reoperation for removal is not necessary. Furthermore, the resulting product of mesh hydrolysis has a bacteriostatic effect, minimizing the risk of infection [60].

#### *5.4.4. Hepatotomy and selective vascular ligation:*

Combined hepatotomy and selective vascular ligation has emerged as the preferred method of management for major hepatic venous, portal venous, and arterial injuries in many centres [61]. For control of major vascular injuries, Pachter et al. recommend a rapid and extensive finger fracture, often through normal parenchyma, to reach the site of injury. However, it is important to emphasise that with a major hepatic venous injury, significant haemorrhage may occur while attempting to extend a deep liver laceration and that this bleeding will not be controlled by a Pringle clamp and increased morbidity may be incurred. Hepatotomy is done under Pringle manoeuvre and finger fracture method is used to divide the parenchyma to ligate the bleeding vessels. Pringle clamp is released intermittently to identify bleeding vessels.

#### *5.4.5. Non-anatomical resection of liver:*

This refers to removal of devitalised parenchyma using the line of injury as the boundary of the resection rather than standard anatomical planes [62]. Resectional debridement is indicated for peripheral portion of nonviable hepatic parenchyma. Debridement is rarely a technique practised in isolation and is frequently used in conjunction with inflow control and hepatotomy. This allows for haemorrhage control prior to resection of all devitalised tissue while usually involves crossing traditional anatomical boundaries hence the term “non-anatomical resection”. All devitalized tissues should be removed without making any attempt to resect normal parenchyma. Operative time should be as short as possible.

Except in rare circumstances, the amount of tissue removed should not be more than 25% of the liver. In some cases simple completion of an extensive parenchymal avulsion may suffice, e.g., when there has been an avulsion of the posterior sector of the right lobe (segments VI and VII). This type of injury is often associated with a right hepatic vein laceration and



completion of the “resection” will allow control and suture of this. In such situations, vascular stapling devices are extremely useful for rapid and secure division of major veins.

#### 5.4.6. *Anatomical resection of liver:*

The final alternative for patients with extensive injury to one hemiliver is anatomic hepatic resection. In elective circumstances, anatomic hemi-hepatectomies can be performed with excellent results; however, in the setting of trauma, the mortality associated with this procedure exceeds 50% in most series [63, 64]. This, plus the fact that the time and magnitude of the surgery goes against the later principles of conservative surgery and damage control, has resulted in anatomical resection being practised rarely and it is now performed in only approximately 2–4% major liver trauma cases [51].

Hepatic resection for an injured segment of the liver definitively controls bleeding, potential bile leak, and removes devitalized tissue. However, the role of hepatic resection in the management of liver injury remains controversial. The traditional poor results and lack of enthusiasm for this technique have been contradicted by the results of some recent series particularly that from Strong et al. who achieved excellent results in a series of 37 patients, 11 of whom (33%) had grade V juxtahepatic venous injuries [61]. These results probably reflect the fact that this procedure was performed in a specialist liver resection and transplantation unit, and while the majority of liver injuries continue to be managed initially in trauma centres or district hospitals, it is likely that more conservative and damage control procedures will remain the most widely practised techniques.

#### 5.4.7. *Intrahepatic balloon tamponade:*

Intrahepatic balloon tamponade is useful for transhepatic penetrating injury. A device can either be fashioned from a Foley catheter and Penrose drain [65] or a Sengstaken-Blakemore tube. The device is gently delivered into the length of the tract and then inflated, often with a radio-opaque contrast fluid so integrity and position can be later confirmed radiologically if required. Once the patient is stabilized and coagulation and acidosis is corrected, the balloon can be deflated and removed during re-laparotomy.

#### 5.4.8. *Total vascular exclusion:*

Total vascular exclusion of liver is sometimes used for extensive retrohepatic venous injuries. The technique involves clamping of the portal triad and infra- and supra-hepatic IVC and therefore requires experience with mobilisation of the liver as done in liver resection and transplantation. Excellent results were reported for this technique by Khaneja et al. [66] who used it to manage grade V penetrating injuries with 90% of patients surviving the operation and an overall survival rate of 70%.

The major drawback of this technique is decreased venous return due to clamping of IVC. This will lead to further hypotension in patient who is already in hypothermia and hypotension. This procedure can only be feasible in experienced hand in high volume centres.

#### 5.4.9. Liver transplantation:

This remains a therapy of last resort limited to specialist centres with the literature limited to occasional case reports and series [67]. While liver transplantation may be life-saving for major liver trauma, the logistical problems will mean that it remains a limited option, available only in specialist centres.

## 6. Postoperative complications and mortality:

Overall mortality for patients with hepatic injuries is approximately 10%. The most common cause of death is exsanguination, followed by MODS and intracranial haemorrhage. Liver trauma is a morbid injury with complication rates from recent series ranges from between 8.1% to 30% [68].

### 6.1. Postoperative haemorrhage:

Primary exsanguinating haemorrhage is a major source of mortality, but most studies report secondary haemorrhage occurring in 3- 6% of survivors with no significant difference between blunt and penetrating mechanisms [69]. Surgical haemorrhage (ie discrete bleeding) and disseminated intravascular coagulation account for the majority of causes in even proportions. In patients managed by peri-hepatic packing, patients who had packs removed at <36hrs had more episodes of haemorrhage requiring re-packing than those with removal between 36 hours and 72 hours.

In most instances of persistent postoperative haemorrhage, the patient is best served by being returned to the operation room. Angiography with embolization may be considered in selected patients. If the reason for haemorrhage is coagulopathy, it should be corrected first and then patients should be reassessed.

### 6.2. Sepsis and abscess:

Post-operative sepsis occurs in 12-32% of patients. Minor morbidity occurs with urinary tract, surgical wound and respiratory tract sepsis. More serious are intra-abdominal abscesses which occur in up 24% of patients and are associated with concomitant bowel injury, higher grades of liver injury (IV and V) and massive transfusion [70].

An abdominal CT with intravenous and oral contrast should be performed to diagnose the cause of sepsis. Majority of the abscesses can be drained percutaneously under USG or CT-guidance; however, infected hematoma and infected necrotic liver tissue cannot be expected to respond to percutaneous drainage. Operative drainage may be a better option in such type of patients.

### 6.3. Biloma:

Bilomas are loculated collection of bile, which is with or without infection. CT-guided percutaneous drainage is the best option for infected bilomas. If the biloma is sterile, it will

eventually be resorbed. Biliary ascites is caused by disruption of major bile duct. Reoperation after the establishment of appropriate drainage is the prudent course.

Biliary fistulas occur in approximately 3% of the patients with major liver injury [71]. They are usually of little consequences and generally close without specific treatment.

## 7. Injuries to the Bile ducts and gall bladder:

Extrahepatic bile ducts are rarely injured during blunt or penetrating abdominal injuries [72, 73]. Diagnosis is usually made during surgery or sometimes postoperatively. Management of bile duct injury detected postoperatively has already been described. If laparotomy is performed for patient with trauma, collection of bile in to the right upper quadrant suggest major bile duct injury. Sometimes it is very difficult to detect the site of bile duct injury, as associated disruption of liver parenchyma and haemorrhage makes detection a challenging task.

Management of bile duct injury is further complicated by small calibre and thin wall of the bile duct. Bile duct injury ranges from small laceration to tissue loss or complete disruption. Primary repair may be attempted when there is small laceration and no tissue loss. When there is a tissue loss or the laceration is larger than 25% to 50% of the diameter of the duct, the treatment option is a Roux-en-Y choledocho-jejunostomy [74, 75]. Isolated injury to left or right hepatic duct is even more challenging and should only be managed by experienced hepatobiliary surgeon. If expertise is not available, large bore tube should be kept and patient should be transferred to higher centre. If both the ducts are injured, both the ducts should be intubated by separate tubes and brought out. Elective repair should be undertaken once the patient is stable and after adequate assessment of injury by cholangiogram.

Injury to the gall bladder is treated either by repair or cholecystectomy.

## 8. Summary:

The management of injuries of the liver has evolved significantly throughout the last two decades. Non-operative techniques for the management of grade IV–V injuries in stable patients have been established, although there is a higher failure rate for these injuries compared with grade I–III injuries. Because of the progress that has been made in the quality and wide availability of the MDCT scan combined with minimally invasive intervention options like angio-embolization, NOM has evolved to be the treatment of choice for hemodynamically stable patients. In terms of surgical management there has been a definite move away from major, time-consuming procedures toward conservative surgery and damage control. The preferred surgical technique for inaccessible bleeding within a laceration is rapid finger fracture hepatotomy, Kelly –crush hepatic transection and direct suture or ligation. Prolonged attempts at surgical control and repair should be avoided, and definitive perihaptic packing should be employed at an early stage in the persistently unstable patient or at

the first signs of coagulopathy. Formal anatomical resection carries a high morbidity when used for haemorrhage control, although in an experienced centre this may be appropriate. Hepatorrhaphy has become discouraged due to complications of sepsis and bleeding, but may be a useful technique in penetrating trauma where the liver is difficult to access.

## Author details

Rajan Jagad\*, Ashok Thorat and Wei-Chen Lee

\*Address all correspondence to:

Division of Liver and Transplantation Surgery, Department of General Surgery, Chang-Gung Memorial Hospital at Linkou, Chang-Gung University College of Medicine, Taiwan

## References

- [1] Miller, P. R., Croce, M. A., Bee, T. K., et al. (2002). Associated injuries in blunt solid organ trauma: the implications for missed injury in non-operative management. *J Trauma*, 53, 238-242.
- [2] Shanmuganathan, K., Mirvis, S. E., & Chiu, W. C. (2004). Penetrating torso trauma: triple-contrast helical CT in peritoneal violation and organ injury. *A prospective study in 200 patients. Radiology*, 231, 775-784.
- [3] Polanco, P., Leon, S., Pineda, J., et al. (2008). Hepatic resection in the management of complex injury to the liver. *J Trauma*, 65(6), 1264-9, 1269-70.
- [4] Badger, S. A., Barclay, R., Diamond, T., et al. (2009). Management of liver trauma. *World J Surg*, 33, 2522-37.
- [5] Trunkey, D.D. (2004). Hepatic trauma: contemporary management. *Surg Clin North Am*, 84, 437-50.
- [6] Kozar, R. A., Moore, J. B., Niles, S. E., et al. (1999). Complications of non-operative management of high-grade blunt hepatic injuries. *J Trauma* 2005 59:1066-1071.
- [7] American College of Surgeons. (1997). Advanced Trauma Life Support manual. *American College of Surgeons*, Chicago, IL.
- [8] Peng, R. Y., & Bongard, F. S. (1999). Hypothermia in trauma patients. *J Am Coll Surg*, 188, 688-696.
- [9] Mac, Kenzie. S., Kortbeek, J. B., Mulloy, R., & Hameed, S. M. (2004). Recent experiences with a multidisciplinary approach to complex hepatic trauma. *Injury*, 35, 869-77.

- [10] Dolich, M. O., Mc Kenney, M. G., Varela, J. E., Compton, R. P., Mc Kenney, K. L., & Cohn, S. M. (2001). ultrasounds for blunt abdominal trauma. *J Trauma*, 50, 108-112.
- [11] Richards, J. R., Knopf, N. A., Wang, L., & Mc Gahan, J. P. (2002). Blunt abdominal trauma in children: evaluation with emergency US. *Radiology*, 222, 749-754.
- [12] Sirlin, C. B., Brown, M. A., Andrade-Barreto, O. A., et al. (2004). Blunt abdominal trauma: clinical value of negative screening US scans. *Radiology*, 230, 661-668.
- [13] Poletti, P. A., Kinkel, K., Vermeulen, B., Irmay, F., Unger, P. F., & Terrier, F. (2003). Blunt abdominal trauma: should US be used to detect both free fluid and organ injuries? *Radiology*, 227, 95-103.
- [14] Sirlin, C. B., Casola, G., Brown, M. A., Patel, N., Bendavid, E. J., & Hoyt, D. B. (2001). Patterns of fluid accumulation on screening ultrasonography for blunt abdominal trauma: comparison with site of injury. *J Ultrasound Med*, 20, 351-357.
- [15] Stassen, N. A., Lukan, J. K., Carrillo, E. H., et al. (2002). Examination of the role of abdominal computed tomography in the evaluation of victims of trauma with increased aspartate aminotransferase in the era of focused abdominal sonography for trauma. *Surgery*, 132, 642-646.
- [16] Jansen, J. O., Yule, S. R., & Loudon, M. A. (2008). Investigation of blunt abdominal trauma. *BMJ*, 336, 938-942.
- [17] Rozycki, G. S., Ballard, R. B., Feliciano, D. V., et al. (1998). Surgeonperformed ultrasound for the assessment of truncal injuries: lessons learned from 1540 patients. *Ann Surg*, 228, 557-567.
- [18] Stengel, D., Bauwens, K., Sehouli, J., et al. (2005). Emergency ultrasound based algorithms for diagnosing blunt abdominal trauma. *Cochrane Database Syst Rev* (2):CD004446.
- [19] Taourel, P., Vernhet, H., Suaud, A., et al. (2007). Vascular emergencies in liver trauma. *Eur J Radiol*, 64, 73-82.
- [20] Smith, R.S. (2001). Cavitary endoscopy in trauma. *Scand J Surg*, 91, 67-71.
- [21] Kawahara, N. T., Alster, C., Fujimura, I., Poggetti, R. S., & Birolini, D. (2009). Standard examination system for laparoscopy in penetrating abdominal trauma. *J Trauma*, 67:589.
- [22] Israelit, S. H., & Krausz, M. M. (2006). Laparoscopic management of a combat military injury during the Lebanon War in August., *J Trauma*, 108-10.
- [23] Haan, J. M., Bocchicchio, G. V., Kramer, N., et al. (2005). Nonoperative management of blunt splenic injury: a 5-year experience. *J Trauma*, 58, 492-498.
- [24] Stein, D. M., & Scalea, T. M. (2006). Nonoperative management of spleen and liver injuries. *J Intensive Care Med*, 21, 296-304.



- [25] Cywes, B. S., Rode, H., & Millar, A. J. (1985). Blunt liver trauma in children: nonoperative management. *J Pediatr Surg*, 20, 14-18.
- [26] Sherman, H. F., Savage, B. A., Jones, L. M., et al. (1994). Nonoperative management of blunt hepatic injuries: safe at any grade? *J Trauma*, 37, 616-621.
- [27] Carrillo, E. H., Spain, D. A., Wohltmann, C. D., et al. (1999). Interventional techniques are useful adjuncts in nonoperative management of hepatic injuries. *J Trauma*, 46, 619-624.
- [28] Dabbs, D. N., Stein, D. M., & Scalea, T. M. (2009). Major hepatic necrosis: a common complication after angioembolization for treatment of high-grade liver injuries. *J Trauma*, 66(3), 621-7.
- [29] Pachter, H. L., Guth, A. A., Hofstetter, S. R., & Spencer, F. C. (1998). Changing patterns in the management of splenic trauma: the impact of nonoperative management. *Ann Surg*, 227, 708-717.
- [30] Meyer, A. A., Crass, R. A., Lim, R. C., et al. (1985). Selective nonoperative management of blunt liver injury using computed tomography. *Arch Surg*, 120, 550-554.
- [31] Velamhaos, G. C., Konstantinos, T., Radan, R., Chan, L., Rhee, P., Tillou, A., & Deme- triades, D. (2003). High success with nonoperative management of blunt hepatic trauma. *Arch Surg*, 138, 475-81.
- [32] Misselbeck, T. S., Teicher, E. J., Cipolle, M. D., Pasquale, M. D., Shah, K. T., Dangle- ben, D. A., & Badellino, M. M. (2009). Hepatic angioembolization in trauma patients: indications and complications. *J Trauma*, 67, 769-773.
- [33] Yaman, I., Nazli, O., Tugrul, T., et al. (2007). Surgical treatment of hepatic injury: morbidity and mortality analysis of 109 cases. *Hepatogastroenterology*, 54, 1507-1511.
- [34] Kozar, R. A., Moore, F. A., Cothren, C. C., Moore, E. E., Sena, M., Bulger, E. M., Mill- er, C. C., Eastridge, B., Acheson, E., Brundage, S. I., Tataria, M., Mc Carthy, M., & Holcomb, J. B. (2006). Risk factors for hepatic morbidity following nonoperative management: multicenter study. *Arch Surg*, 141, 451-8.
- [35] Goldman, R., Zilkoski, M., Mullins, R., Mayberry, J., Deveney, C., & Trunkey, D. (2003). Delayed celiotomy for the treatment of bile leak, compartment syndrome, and other hazards of nonoperative management of blunt liver injury. *Am J Surg*, 185(5), 492-7.
- [36] Dabbs, D. N., Stein, D. M., Philosophe, B., & Scalea, T. M. (2010). Treatment of major hepatic necrosis: lobectomy versus serial debridement. *J Trauma*, 69(3), 562-7.
- [37] Hashimoto, 5., Hiramatsu, K., Ido, K., Yosii, H., et al. (1990). Expanding role of emer- gency embolization in the management of severe blunt hepatic trauma. *Cardiovasc In- tervent Radiol*, 1, 193-199.



- [38] Denton, J. R., Moore, E. E., & Coldwell, D. M. (1997). Multimodality treatment for grade 5 hepatic injuries: 'perihepatic packing', arterial embolisation and venous stenting. *J Trauma*, 42, 964-968.
- [39] Asensio, J. A., Demetriades, D., Chahwan, S., et al. (2000). Approach to the management of complex hepatic injuries. *J Trauma*, 48, 66-72.
- [40] Gaarder, C., Naess, P. A., Eken, T., Skaga, N. O., Pillgram-Larsen, J., Klow, N. E., et al. (2007). Liver injuries- improved results with a formal protocol including angiography. *Injury*, 38, 1075-1083.
- [41] Lin, B. C., Wong, Y. C., Lim, K. E., et al. (2010). Management of ongoing arterial haemorrhage after damage control laparotomy: optimal timing and efficacy of transarterial embolisation. *Injury*, 41, 44-9.
- [42] Griffen, M., Ochoa, J., & Boulanger, B. R. (2000). A minimally invasive approach to bile peritonitis after blunt liver injury. *Am Surg*, 66, 309-12.
- [43] Malhotra, A. K., Latifi, R., Fabian, T. C., et al. (2003). Multiplicity of solid organ injury: influence on management and outcomes after blunt abdominal trauma. *J Trauma*, 54, 925-9.
- [44] Stone, H. H., Strom, P. R., & Mullins, R. J. (1983). Management of the major coagulopathy with onset during laparotomy. *Ann Surg*, 197, 532-535.
- [45] Burch, J. M., Ortiz, V. B., Richardson, R. J., Martin, R. R., Mattox, K. L., & Jordan, G. L. (1992). Abbreviated laparotomy and planned reoperation for critically injured patients. *Ann Surg*, 215, 476-483.
- [46] Elerding, S. C., Arragon, G. E., & Moore, E. E. (1979). Fatal hepatic hemorrhage after trauma. *Am J Surg*, 138, 883-888.
- [47] Rotondo, M. F., Schwab, C. W., Mc Gonigal, M. D., et al. (1993). Damage control': an approach for improved survival in exsanguinating penetrating abdominal injury. *J Trauma*, 35, 375-383.
- [48] Asensio, J. A., Roldan, G., Petrone, P., et al. (2003). Operative management and outcomes in 103 AAST-OIS grades IV and V complex hepatic injuries: trauma surgeons still need to operate, but angioembolization helps. *J Trauma*, 54, 647-654.
- [49] Hoey, B. A., & Schwab, C. W. (2002). Damage control surgery. *Scand J Surg*, 91, 92-103.
- [50] Parks, R. W., Chrysos, E., & Diamond, T. (1999). Management of liver trauma. *Br J Surg*, 86, 1121-35.
- [51] Aydin, U., Yazici, P., Zeytunlu, M., & Coker, A. (2008). Is it more dangerous to perform inadequate packing?, *World J Emerg Surg*, 3:1.
- [52] Sheridan, R., Driscoll, D., & Felsen, R. (1997). Packing and temporary closure in liver injury. *Injury*, 28, 711-712.

- [53] Cue, J. I., Cryer, H. G., Miller, F. B., et al. (1990). Packing and planned re-exploration for hepatic and retroperitoneal haemorrhage: critical refinements of a useful technique. *J Trauma*, 30, 1007-1013.
- [54] Nicol, A. J., Hommes, M., Primrose, R., et al. (2007). Packing for control of hemorrhage in major liver trauma. *World J Surg*, 31, 569-574.
- [55] Krige, J.E.J. (2000). Liver fracture and bleeding. *Br J Surg*, 87, 1615-1616.
- [56] Moore, F. A., Moore, E. E., & Seagraves, A. (1985). Non-resectional management of major hepatic trauma. *Am J Surg*, 150, 725-729.
- [57] Walt A.J. (1986). Discussion: packing for control of hepatic haemorrhage. *J Trauma*, 26, 741-756.
- [58] Balogh, Z., Mc Kinley, B. A., Cox, C. S., et al. (2003). Abdominal compartment syndrome: the cause or the effect of multiple organ failure? *Shock*, 20, 483-492.
- [59] Meldrum, D. R., Moore, F. A., Moore, E. E., et al. (1997). Prospective characterisation and selective management of the abdominal compartment syndrome. *Am J Surg*, 174, 667-673.
- [60] Dellaportas, D., Nastos, C., Psychogiou, V., Tympa, A., et al. (2011). Iatrogenic liver trauma managed with mesh-wrapping and ligation of portal vein branch: A case report. *Int J Surg Case Rep.*, 2(8), 261-263.
- [61] Fang, J. F., Chen, R. J., Lin, B. C., et al. (2000). Blunt hepatic injury: minimal intervention in the policy of treatment. *J Trauma* 49:722-728.
- [62] Duane, T. M., Como, J. J., Bochichio, G. V., et al. (2004). Re-evaluating the management and outcomes of severe blunt liver injury. *J Trauma*, 57, 494-500.
- [63] Jacobson, L. E., Kirton, O. C., & Gomez, G. A. (1992). The use of an absorbable mesh wrap in the management of major liver injuries. *Surgery* 111:455.
- [64] Poggetti, R. S., & Moore, E. E. (1992). Balloon tamponade for bilobar transfixing hepatic gunshot wounds., *J Trauma*, 33:694.
- [65] Khaneja, S. C., Pizzi, W. F., Barie, P. S., et al. (1997). Management of penetrating juxtahepatic inferior vena cava injuries under total vascular exclusion. *J Am Coll Surg*, 184, 469-474.
- [66] Angstadt, J., Jarrell, B., Moritz, M., et al. (1989). Surgical management of severe liver trauma: a role for liver transplantation., *J Trauma*, 29, 606-8.
- [67] Aldrete, J. S., Halpern, N. B., Ward, S., & Wright, J. O. (1979). Factors determining the mortality and morbidity in hepatic injuries. Analysis of 108 cases., *Ann Surg*, 189, 466-74.
- [68] Degiannis, E., Levy, R. D., Sa, F. C. S., Velmahos, G. C., Mokoena, T., & Daponte, A. (1995). Gunshot injuries of the liver : The Baragwanath experience. *Surgery I*, 359-364.

- [69] Caruso, D. M., Battistella, F. D., Owings, J. T., Lee, S. L., & Samaco, R. C. (1999). Peri-hepatic packing of major liver injuries: complications and mortality. *Arch Surg*, 134:958.
- [70] Donovan, A. J., Michaelian, M. J., & Yellin, A. E. (1973). Anatomical hepatic lobectomy in trauma to the liver. *Surgery* 73:833.
- [71] Fabian, T. C., Croce, M. A., Stanford, G. G., et al. (1991). Factors affecting morbidity after liver trauma. *Ann Surg* 213:540.
- [72] Jurkovich, G. J., Hoyt, D. B., Moore, F. A., et al. (1995). Portal triad injuries: a multi-institutional study: *J trauma* 39:426.
- [73] Sheldon, G. F., Lim, R. C., Yee, E. S., et al. (1985). Management of injuries to the porta hepatis. *Ann Surg* 202: 539.
- [74] Feliciano, D. V., Bitando, C. V., Burch, J. M., et al. (1985). Management of traumatic injuries to the extrahepatic biliary ducts. *Am J Surg* 150:705.
- [75] Bade, P. G., Thomson, S. R., Hirshberg, A., et al. (1989). Surgical options in traumatic injury to the extrahepatic biliary tract. *Br J Surg* 76:256.