

We are IntechOpen, the world's leading publisher of Open Access books Built by scientists, for scientists

6,900

Open access books available

186,000

International authors and editors

200M

Downloads

Our authors are among the

154

Countries delivered to

TOP 1%

most cited scientists

12.2%

Contributors from top 500 universities



WEB OF SCIENCE™

Selection of our books indexed in the Book Citation Index
in Web of Science™ Core Collection (BKCI)

Interested in publishing with us?
Contact book.department@intechopen.com

Numbers displayed above are based on latest data collected.
For more information visit www.intechopen.com



Clinical Application of Photodisruptors in Ophthalmology

Emina Alimanović Halilović

Additional information is available at the end of the chapter

<http://dx.doi.org/10.5772/48625>

1. Introduction

In ophthalmology today, laser photodisruptors are used besides laser photocoagulators. Photocoagulators transform light energy into heat energy, causing microcauterisation of tissue. Photodisruptors act non-thermally by controlled cutting of the unwanted tissue, causing microexplosions. The most frequently used photodisruptors are Neodymium YAG, Holmium YAG and Erbium YAG lasers. They differ by type of the active crystal. The laser beam of these lasers is highly coherent, low-divergent, which enables it a high precision. It is used as a microscalpel to cut optical membranes and tissues.

Meyer-Schwickerath was the first to describe the laser beam transmission through optical media. Photodisruptors such as Nd-YAG laser work by principles of the optical “breakdown”. Laser beam energy is brought to as small focal point as possible, thus achieving a high energy density with a strong destructive effect. In the focal point there occurs a microexplosion with disruption of electrons from their nuclear orbits. This free floater is known as electronic plasma. The electronic plasma is able to absorb any further energy entering the eye in the same focal point. This significant feature of the protective plasma prevents damage to the eye structures beyond the protective plasma formation, i.e., conduction of the destructive effect outside the focus. Inside the protective plasma, the temperature is 15,000 °C with a high pressure, so the plasma expands in concentric waves, “shock waves”. In about 150ns after the “optical breakdown”, it is possible to biomicroscopically see air bubbles as a sign of collapse and pressure equalisation inside the wave with atmospheric pressure. The “shock wave” is accompanied by an acoustic wave that is sometimes audible.

Two methods are used in the Nd-YAG laser beam production: “Q-switched” and “mode-locked”. The former compresses energy in a single „nanosecond” pulse, and the latter produces a series of “picosecond” pulses. In the “mode-locked” method, we have

a low energy power of single pulsations, while in the “Q-switched” method, pulse energy is higher at the same energy level. The “Q-switched” technology produces chiefly pulses whose main effect is mechanical – buckling. This is photodisruption, i.e., tearing of atoms with energy shocks. The effect of this method is creation of energy in the pipe being let through in short impulses, and during the still interval energy is kept, accumulated and enhanced, so that each impulse has a very high performing power.




Figure 1. Q-switched pulse;

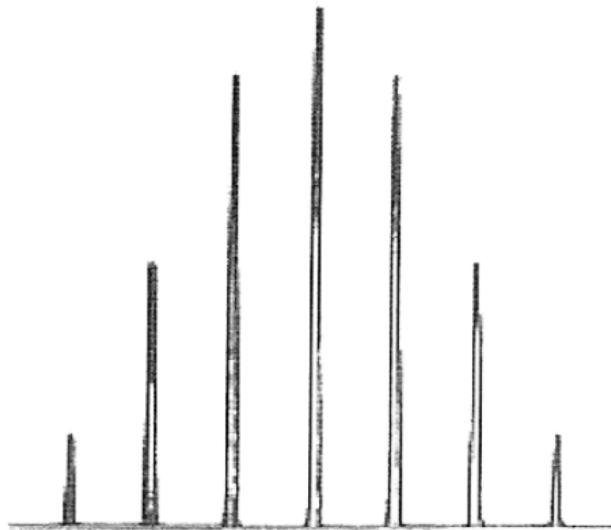


Figure 2. Mode-locked pulse train

The Nd-YAG laser beam causes damage to the tissue in the form of craters in the fields of vaporisation. The crater edges are carbonised, then towards the edges there follows the coagulation necrosis area, and at the far periphery the oedema area.

Erbium-YAG laser has found a broad application in aesthetic plastic microsurgery of eyelids, in blepharochalasis, ectropium, and phthisis. Multifocal Erbium-YAG laser systems have a multiple use in ophthalmology, in the cataract phaco surgery, vitrectomy and sclerectomy.

It is also used in dermatology for dermoabrasion for the skin rejuvenation.

2. Nd-Yag laser in ophthalmology

Modern cataract microsurgery with implantation of intraocular lenses is inseparable from the Nd-YAG laser microsurgery. The microsurgery of glaucoma and problems of the posterior segment also imply the use of Nd-YAG laser. Application of Nd-YAG laser:

with cataract in	anterior capsulotomy posterior capsulotomy removal of pigment from the anterior surface of IOL discission of secondary cataract and membrane synechiolysis cutting of corneal sutures after the cataract surgery or cheratoplastica
with corneal diseases	dendritic ulcers microabscesses
with glaucoma	transscleral cyclophotocoagulation iridectomy sphinterectomy
with the vitreous body	anterior vitreorruption cutting of intravitreal vitreoretinal tractions and membranes

Table 1. Clinical application of Nd-YAG laser in ophthalmology

2.1. Nd-Yag laser posterior capsulotomy

The most frequent practical application of Nd-YAG laser is in posterior capsulotomy and discission of secondary membranes in aphakic (conditions after the cataract surgery), and pseudophakic (conditions after the cataract surgery with implantation of intraocular lens into the anterior or posterior eye chamber) of the eyes.

The surgical technique of intraocular lens placement is important for the development of posterior capsular opacity. The intraocular lens placement itself, manipulation with the iris, and lens contact with the posterior capsule may be a cause of accumulation of pigment on the lens anterior surface and development of opacity. Also, the lens implant size, its shape

and the type of material of which it is made have a significant impact on the development of secondary cataract. Posterior lens capsular opacity develops through the migration of epithelium from the remaining parts of the anterior lens capsule, proliferation of the remaining epithelial cells of the anterior pole of lens and lens fibres. Through their metaplasia, myofibroblasts are developed, forming folds, reticles, uneven membranes which are difficult to see biomicroscopically; they do not significantly affect visual acuity. If epithelial cells accumulate in the form of round, uneven, pearl-shaped opacity - Elschnig's pearls - then such opacity reduces significantly vision. There may be also some other causes of opacity of the posterior lens capsule: remaining parts of the lens cortex intraoperatively and after incomplete aspiration. Masses can incorporate between the implanted lens and posterior capsule. Also, the remaining parts of the lens nucleus, blood cells in hyphema, pigment cells of the iris and ciliary body may accumulate on the lens or posterior capsule. Low-virulent, slow-growing, still bacterial colonies such as *Propionibacterium acnes* may settle in the posterior capsule field and look like ordinary opacity. If we mistake them for normal capsular opacity and perform the laser capsulotomy, we have opened a path for bacteria into the vitreous body, which can result in the occurrence of endophthalmitis.

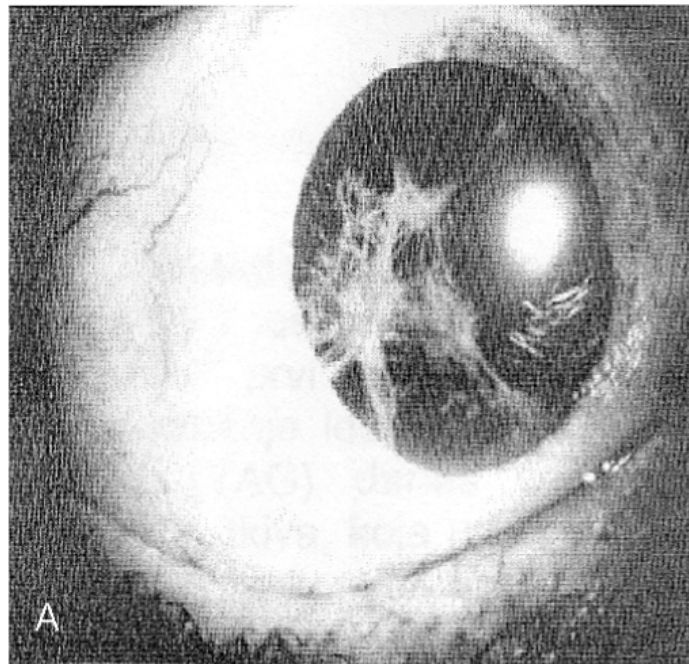


Figure 3. Posterior capsular opacification

Postoperative posterior capsular opacity leads to a fall of visual acuity. Patients complain of blurred images, they see things as if through “gauze or a sieve”. In the first postoperative year, opacity occurs in 83% patients and from the second to the fifth years in 50% cases. The Nd-YAG laser posterior capsulotomy is a routine technique with which we resolve the problem. With the laser beam we make the “fenestra” opening on the posterior capsule through which light beams reach the retina without obstruction and form a clear image of an object.

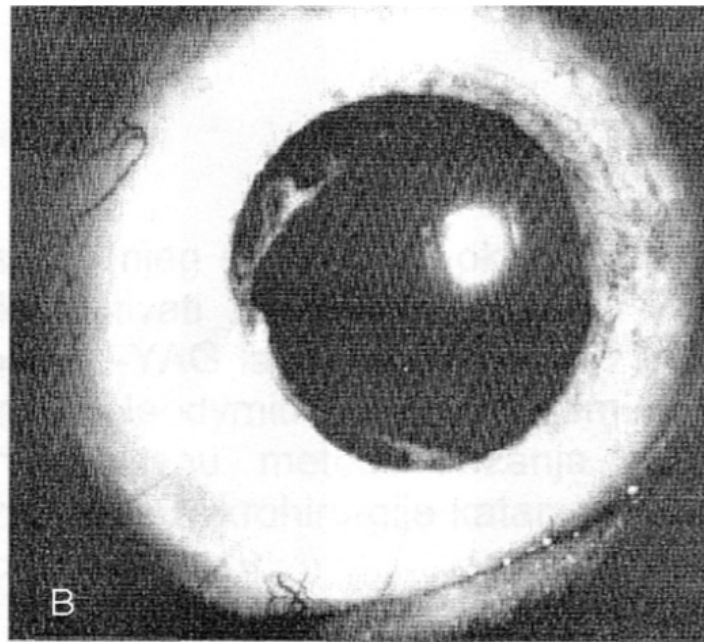


Figure 4. After Nd-YAG capsulotomy

Prior to the intervention itself, it is necessary to examine the patient's visual acuity, take intraocular pressure, examine biomicroscopically capsular opacity, direct and through the procedure of retroillumination of the capsule itself and the retrolental space. Opacity of the posterior lens capsule may be measured echographically, and the quantitative measuring "in vivo" with the Scheimpflug photographic computer system. The intervention is performed on the pupil dilated to the maximum, in the darkroom, with the surgeon's prior adaptation to the dark, with optimal enlargement on the biomicroscope, with the optimal light intensity, on the dilated pupil. The patient has to cooperate with the surgeon, keep still on the apparatus and follow the instructions from the surgeon in moving the eyes. The procedure is performed under local anaesthesia, by means of condensing Abraham or Peyman YAG planconvex contact lens for the posterior capsulotomy. Such lenses concentrate the laser beam to the smallest possible focus. At the same time, they immobilise the eye in restless patients. The angle of the incoming convergent laser beam depends on technical possibilities of the apparatus and it is selected by the surgeon. According to Eisner's discussions, the widest incoming angle, with the smallest focal point (mark), and clear focusing produce the clean beam, with the highest energy concentration in the focus and the smallest energy dispersion in the cornea or retina. The most frequently used capsulotomy techniques are Seaman's, which imply the knowledge of quality and thickness of opacity:

- a. the „vertical opening“ technique from 12 o'clock position to 6 o'clock position is applied in posterior capsular opacity;
- b. the „cross-shaped“ technique when horizontal cutting is performed by vertical opening from 9 o'clock position to 6 o'clock position;

- c. the „concentric spreading“ technique from the periphery to the centre, in abundant secondary;
- d. the „fragmentation“ technique with the widening of opening edges in fibrous membranes.

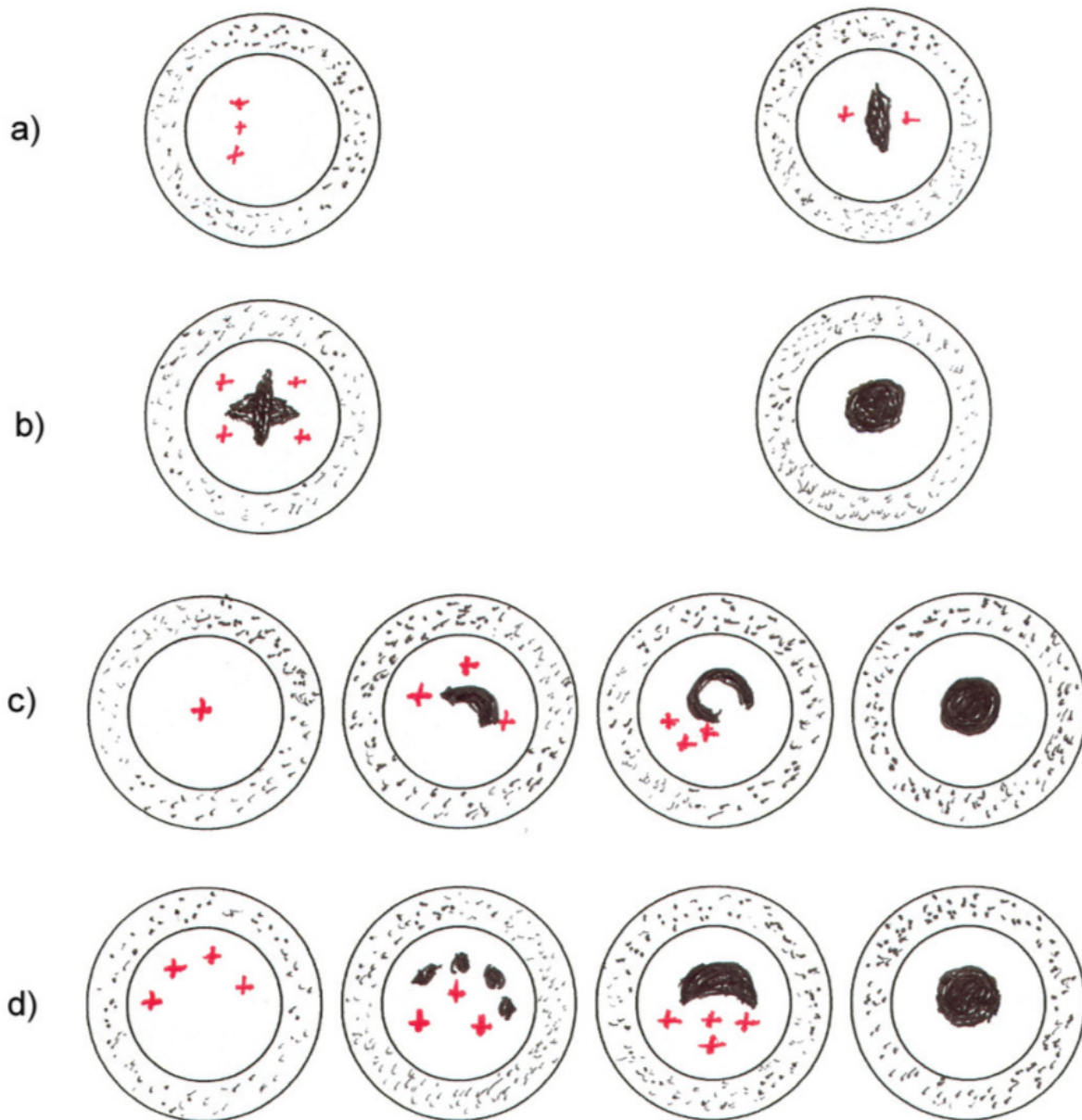


Figure 5. „Seaman's“ capsulotomy techniques

Although the Nd-YAG laser capsulotomy is a non-invasive technique, efficient, painless, practical, easily-applicable, cost-effective, with fast recovery, today the method of choice, it is necessary that the laser surgery be performed by a well-trained, educated and experienced ophthalmologist. Only with the expertise and ethics of the laser surgeon can complications be avoided and reduced. All complications are a result of correlation of the laser action, methodological errors in performance and the condition of the eye. Use of the

Nd-YAG laser beam can lead to certain unwanted complications on the anterior and posterior poles of the eye.

On the anterior segment, we usually have: damage to the corneal epithelium, corneal perforation, damage to the intraocular lens, dislocation of the intraocular lens, changes of intraocular pressure, development of iritis, and hemorrhage into the anterior chamber.

On the posterior eye segment, the following complications can develop: rupture of the anterior hyaloid membrane, prolapse of the vitreous body into the anterior chamber, retinal rupture, cystic macular oedema, retinal detachment, retinal bleeding, macular fibrosis, macular rupture, and rarely endophthalmitis.

2.2. A jump of intraocular pressure

We have transient increase in IOP in 50-97% laser-treated patients after the posterior capsulotomy. Numerous investigations have shown that the highest jump takes place in the first four hours, and in the first 24-48 hours it returns to normal, stays increased by 5 mmHg respectively in the first week. In some cases, the increased IOP may stay on for two or three months. The IOP maximal values after the laser capsulotomy are 50-60 mmHg. Transient IOP increase after the Nd-YAG laser posterior capsulotomy is explained by the mechanical obstruction of the trabecular exhaust system with the posterior capsular residual particles, inflammatory cells, and high-molecular soluble proteins of the lens. An increased secretion of the ciliary epithelium is considered to be a cause of extended intraocular hypertension as a consequence of the "shock" wave effect. Also, according to Terry AC's opinion, there is a significant effect of prostaglandins on the blood-aqueous barrier, which results in increased production of ocular water. The IOP jump is more frequent in the aphakic eye than in the pseudophakic eye. A higher IOP jump was proved in the lens implant into the anterior chamber compared to the eyes with the lens in the posterior chamber, or fixed to the iris. Glaucoma patients have a higher IOP jump compared to non-glaucoma patients.

2.3. Corneal damage

The laser beam, going through the cornea, may cause corneal oedema or perforation, usually unintentionally, due to the bad focusing or use of too much energy. The cornea absorbs 6% Nd-YAG laser energy, lens 15%, the vitreous body 36%. Capsulotomy causes a loss of endothelial cells of the cornea from 0 to 7%, but this loss does not decompensate the cornea.

Corneal damages are a consequence of the mechanical destruction and a heat effect of the linearly and non-linearly absorbed laser energy. Corneal epithelisation is completed in the first 24 hours. Corneal oedema may occur as secondary due to the increased IOP, or may be caused by exacerbation of inflammatory processes of the anterior segment after the YAG laser.

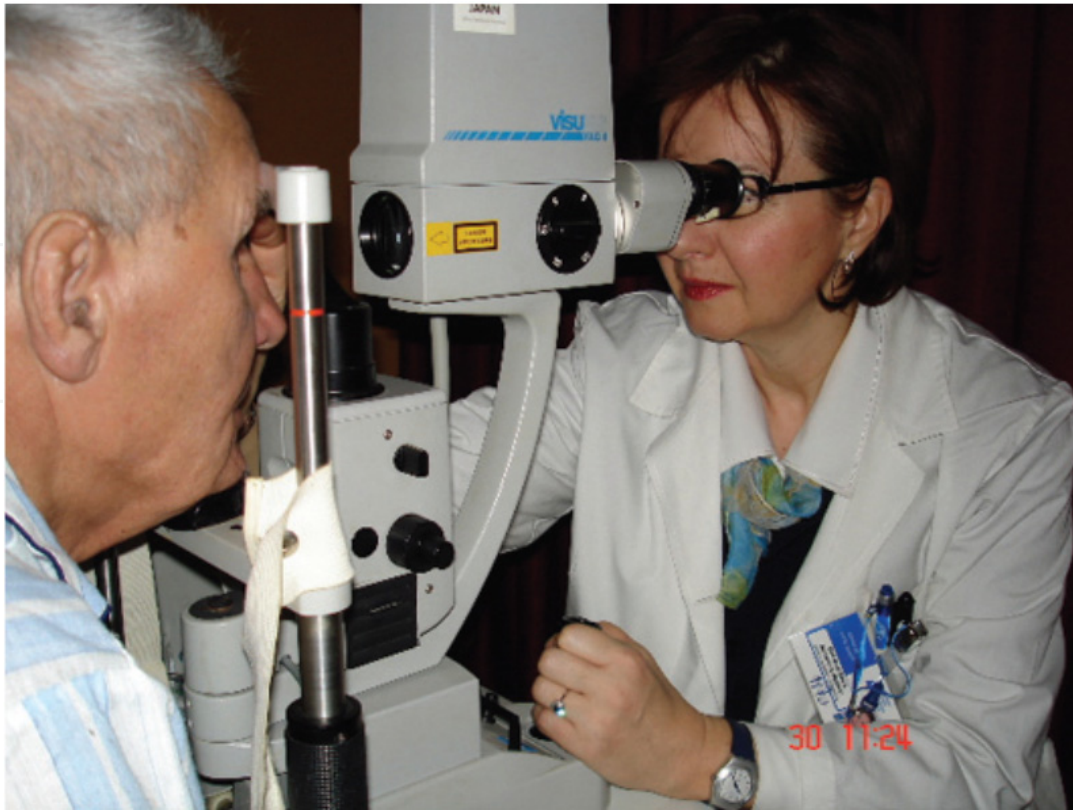


Figure 6. The Nd YAG laser procedure

2.4. Iris haemorrhage

As a consequence of damage to the delicate iris blood vessel by the laser beam during posterior capsulotomy, we can have bleeding in the anterior chamber with a slight pain. Incidence of this complication ranges from 1% to 3%. A slight pressure of the contact lens onto the cornea usually stops bleeding.

2.5. Damage to the intraocular lens

During posterior laser capsulotomy, damage to the intraocular lens may occur in 5% to 40% cases. They are usually recesses, fissures, cracks, lattice, and bursts of stellar shape. These damages affect visual acuity, especially if centrally located. They produce various visual effects, usually in the form of blinding glare, which affects the normal vision. The lens damage depends on individually and totally used energy, impulse duration, number of impulses, and the kind of the IOL material. Polymethylmethacrylate (PMMA) lenses may endure bigger energy without damages, and they are crater-shaped. Silicon lenses have damages in the form of smooth stratification.

2.6. Dislocation of the intraocular lens

Upon the Nd-YAG laser posterior capsulotomy, the IOL shifts to the vitreous body. The implanted lens shifting is monitored by measuring the depth of the anterior chamber with

ultrasound biometry. It is a dislocation of 25 μ m (from 9 to 55 μ m) with SD 13. It is difficult to prove the effect of dislocation on visual acuity as capsulotomy is followed by improvement of visual acuity.

2.7. Rupture of the anterior hyaloid membrane

Rupture of the anterior hyaloids membrane occurs as a complication after the Nd-YAG laser capsulotomy in 19% cases, which enables a prolapse of the vitreous body into the anterior chamber.

2.8. Prolapse of the vitreous body into the anterior chamber

We usually notice this complication three weeks after capsulotomy within the scope from 1.5% to 16%. Herniation of the vitreous body may cause an increased intraocular pressure. There are reports by the authors who, within a four-year period after intervention, do not find an increased IOP. Shifting of the vitreous body forward increases a danger of occurrence of macular oedema, retinal ruptures, and retinal detachment.

2.9. Retinal ruptures

After the laser posterior retinal capsulotomy, the number of retinal ruptures increases. The number, type and location of retinal ruptures are characteristic. They are asymptomatic, round, atrophic retinal ruptures observable usually a month upon capsulotomy, with incidence of 2.3%. The possibility of rupture occurrence is twice as big in laser-treated compared to non-laser treated eyes. Atrophic round retinal ruptures are more numerous than u-shaped ones. They occur in all meridians, including the macula, too. They may be isolated or within peripheral degenerations. They are chiefly localised in the upper temporal and nasal quadrants.

2.10. Retinal detachment

Occurrence of retinal detachment and retinal ruptures is statistically significantly more frequent in the eyes on which laser posterior capsulotomy was performed. Retinal detachment incidence after laser capsulotomy varies from 0.08% to 3.6% or 13% respectively, depending on the sample. Multiple studies have shown that post-laser retinal detachments occur more frequently in younger males. Risk factors, such as myopia, lattice degeneration, anamnesis of existence of retinal detachment on the other eye, and complicated surgeries, demonstrably increase the number of retinal detachments after capsulotomy. Retinal ablation development is influenced by tissue ionization and formation of gaseous "plasma", which then expands accompanied with the "shock and acoustic" wave. After the laser incision of tissue, we have a condition of a latent stress which further disintegrates the structures. All the three mechanisms act simultaneously, and the extent of destruction of the tissue around the optimal "breakdown" area depends on the laser pulse total energy, time of occurrence, and

duration of electronic plasma, and the “shock” wave action. It is believed that the passage of the laser beam through the vitreous body and its “shock” and “acoustic” wave cause significant biochemical changes in the vitreous body. Animal experiments prove penetration of the physiological barrier, processes of depolymerisation of hyaluronic acid, liquefaction and separation of the vitreous body, and all this activates processes of vitreoretinal proliferation; as a consequence we have the occurrence of retinal ruptures and retinal detachment.

2.11. Cystoid macular oedema

Cystoid macular oedema incidence after the Nd-YAG laser capsulotomy varies in different authors from 0.5% to 4.9%. Oedema develops in first six months after the laser capsulotomy. Occurrence of cystoid macular oedema is related to the hyaloid membrane rupture, intraocular lens damage and a short time interval between the cataract surgery and laser intervention. Diagnosis is usually established on the basis of ophthalmoscopic finding and an unexpected fall of vision. Fluorescein angiography shows the flow of the contrast into the macular area. Fine and Brucker proved that cystoid macular oedema is a liquid which from perifoveolar capillaries pours via the damaged endothelium and accumulates in the plexiform, Henle’s layer. The laser beam passing through optical tissues releases prostaglandin and leukotriene from the iris, which triggers a change of permeability of parafoveolar capillaries.

2.12. Macular rupture

After the Nd-YAG laser capsulotomy, we can have macular ruptures as a consequence. They are observable as early as 24 hours upon capsulotomy, and in the period from 10 to 21 days. They occur unilaterally more frequently, but there have been reports about bilateral occurrence as well. Macular rupture is almost always associated with other complications such as: a jump of intraocular pressure, prolapse of the vitreous body into the anterior chamber, macular haemorrhage, and occurrence of cystoid macular oedema. It manifests with a sudden fall of vision, appearance of central black spots and paracentral scotoma. They may create difficulties with recognition of colours.

Post-capsulotomy macular rupture occurs as a consequence of several mechanisms: thermal damages, mechanical disruptions, “optical breakdown” which leads to blood vessel bursts of the retina and chorioidea, thus causing subretinal, intraretinal, and vitreal bleeding. The third mechanism is the “shock wave” responsible for the occurrence of a series of changes in the vitreous body leading to the separation and ablation of the vitreous body. As a secondary effect, there occurs contraction of the perifoveolar vitreous body creating tangent tractions. They are considered to be a cause of macular rupture occurrence.

In most cases the macular rupture closes spontaneously within a period from three weeks to six months, and visual acuity improves significantly. Recently third-degree Gass macular ruptures are resolved surgically by vitrectomy with interior tamponade. After vitrectomy the macular rupture closes and visual acuity improves.

2.13. Macular fibrosis

After the Nd-YAG laser capsulotomy, macula bleeding may follow. Blood resorption is accompanied with formation of preretinal and retinal fibrogliosis bands and membranes which can be filled with abnormal blood vessels. Occurrence of macular fibrosis, after the Nd-YAG laser capsulotomy, is statistically significant. Macular fibrosis significantly reduces visual acuity and it is followed with metamorphopsia. It is confirmed by ophthalmological examination, fluorescein angiography, and fundus microphotography. Histologically, macular fibrosis is made up of: cells of retinal pigment epithelium 51%, astocytes 29%, fibrocytes 14%, and myofibroblasts 7%. With the epiretinal peeling technique within vitrectomy, preretinal membranes are removed. This technique requires the surgeon's enormous experience, and it gives significant results in the sphere of central visual functions.

2.14. Other photomacular damages

After the Nd-YAG laser capsulotomy, photomacular damages have incidence from 7% to 20%. Most photomacular damages appear asymptotically or with a minimal symptomatology due to their frequent extrafoveal location. They may manifest as macular haemorrhage, subretinal, intraretinal, and preretinal bleeding, or as semi-ruptures. Sometimes bleeding may occur in the vitreous body, which significantly reduces vision transiently. Despite big, visible, semi-ruptured macular changes, the condition may be almost fully repaired after the Nd-YAG laser capsulotomy.

2.15. Endophthalmitis

After the Nd-YAG laser capsulotomy, there may develop endophthalmitis. It develops from the fifth day to the sixth week after intervention. Proved causative agents are *Propionibacterium acnes* and *Staphylococcus epidermis* all-present, saprophyte bacteria with a low degree of pathogenicity. They are found in the normal conjunctival flora. *Propionibacterium acnes* is gram-positive, anaerobic, producing lipolytic enzyme which serves as a trigger of inflammatory processes. During the extra-capsular cataract extraction with lens implantation, bacteria are brought into the eye. The Nd-YAG laser capsulotomy is an activating factor, a trigger for the development of the anterior uveitis, which then spreads into panuveitis, endophthalmitis respectively. Formation of the fenestra on the posterior capsule, often on the anterior hyaloid membrane as well, opens the path for bacteria from the anterior to the posterior ocular chamber, i.e., into the middle and posterior parts of the vitreous body. Diagnosis is confirmed by the characteristic ophthalmological picture, i.e., positive cultures of ocular water and vitreous body. The ocular water culture grows in nine days, while the vitreous body culture is earlier and more frequently positive.

Research has shown that the most common complication is a jump of ocular pressure, then damage to the intraocular lens, anterior hyaloid membrane rupture, bleeding in the anterior chamber, retinal rupture, and macular fibrosis.

Development of complications is significantly affected by a total of applied energy, number of pulsations, individual pulse energy, and opening diameter made during capsulotomy.

To prevent complications, the suggested optimal pulse energy is up to 2.0 mJ, total applied energy of 200-300 mJ. The optimal size of the opening made on the posterior capsule is 4 mm.

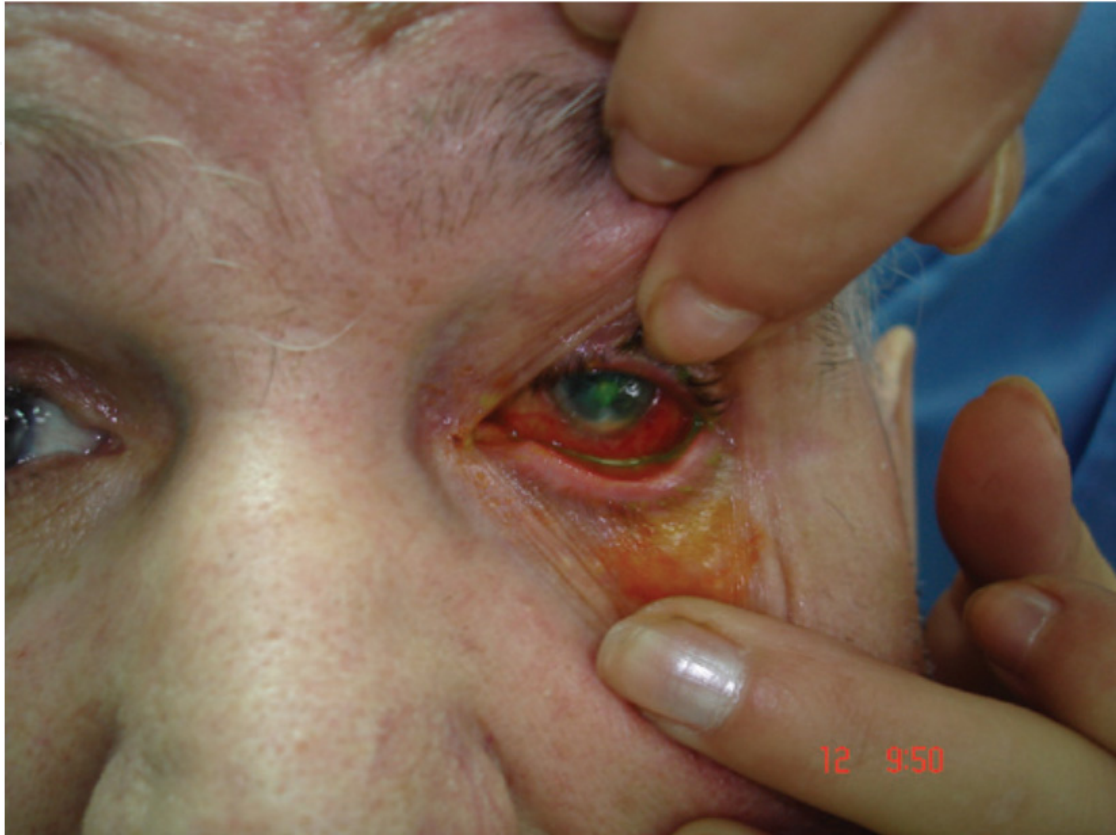

Figure 7. Endophthalmitis after Nd-YAG laser capsulotomy

3. Neodymium Yag laser iridectomy

Nd-YAG laser is used as an alternative treatment to the classic iridectomy in primary glaucoma of the closed angle, pupillary block, and secondary glaucoma of various mechanisms of origin.

Intervention is performed under local anaesthesia, in artificial myosis provoked by 2-4% pilocarpine. Abraham or Goldmann lenses are used. A total to be applied is from 1 to 12 mJ, usually from 3 to 5 mJ through 1-10 applications. The most common location is the central part of the iris on the basis of the iris crypts in the upper nasal quadrant in the 10:30 meridian, or the upper temporal quadrant in the 1:30 meridian. Studies carried out on a larger sample point to a successful iridectomy in 99% cases. After 1-2 hours intraocular pressure falls. The use of corticosteroid drops is suggested in the postoperative period. Upon the Nd-YAG laser iridectomy, there may occur complications described earlier in the chapter on posterior capsulotomy.

4. Nd-Yag laser on the posterior segment

Within diabetic retinopathy, the Valsalva retinopathy, or a sudden rupture of arterial retinal aneurysm, premacular haemorrhage may develop with a sudden loss of vision. According to the accepted opinions, such condition could be observed, waiting for spontaneous haemorrhage resorption. Vitrectomy with premacular haemorrhage aspiration is certainly a more effective method. Today membranectomy with the double-frequency Nd-YAG laser is offered as an alternative therapy.

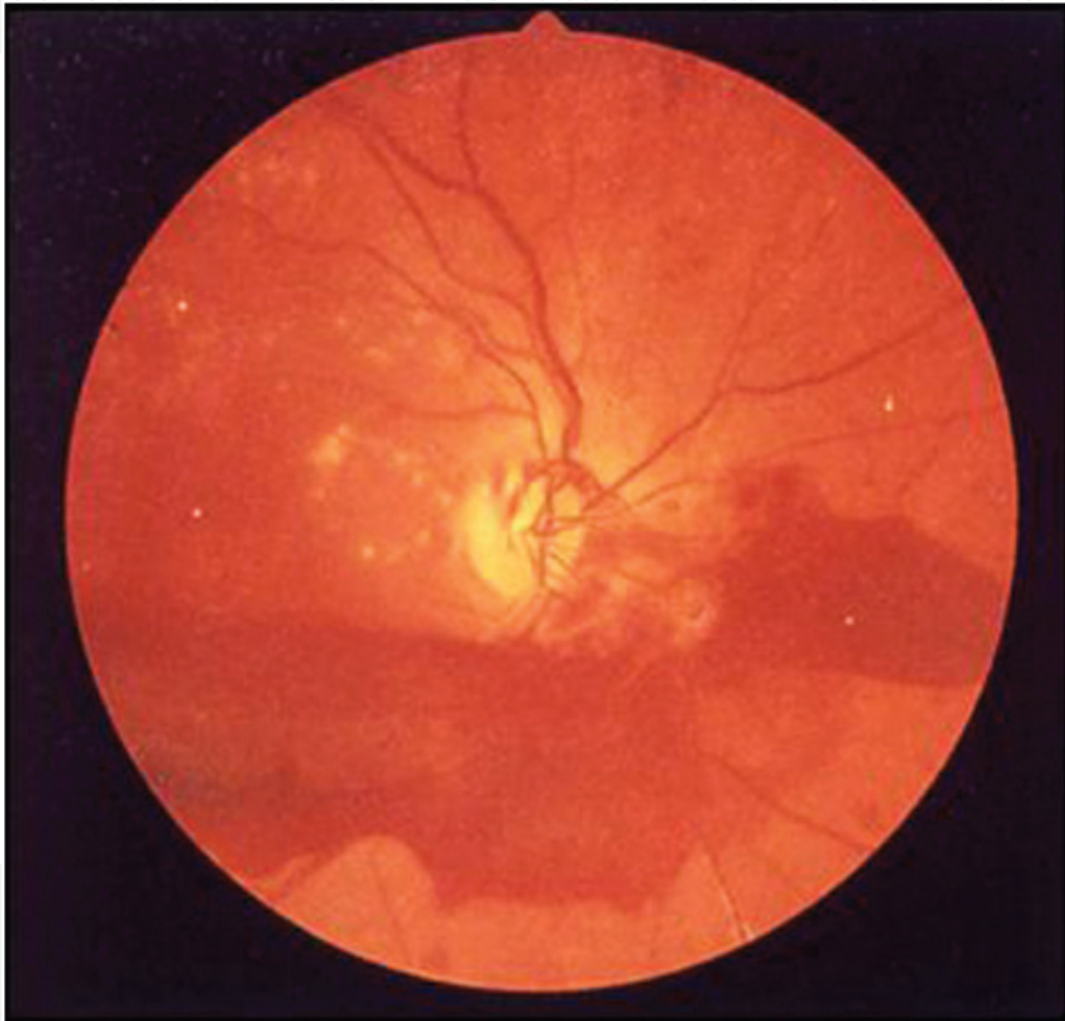


Figure 8. Preretinal haemorrhage

By this intervention, we drain haemorrhage and speed up blood resorption. Immediately upon the laser intervention, vision improves significantly. So today the Nd-YAG laser membranectomy, in premacular haemorrhage, occurs as a non-invasive alternative method to vitrectomy, due to the good results it achieves. Within proliferative diabetic retinopathy with vitreoretinal proliferation, Neodymium-YAG laser may be used to cut adhesions located in the central and posterior vitreous. Prior to that, bases of such proliferations may be ensured by placing argon laser barriers. We can have adhesions in the anterior vitreous body as well; we see them after cataract operations complicated with the vitreous body

prolapse and development of iridocyclitis. In these interventions, special Peyman lenses are used for the middle and posterior vitreous.

5. Erbium-Yag laser

Erbium-YAG laser has also found its application in ophthalmology in phaco surgeries. Micropulse laser waves break up blurred lenses, which is followed with aspiration of the broken up and fragmented masses. The laser beam, in this surgery, is an alternative to the ultrasound wave. Erbium-YAG laser, which is introduced by means of special endo-probes into the bulbus, is used in sclerectomy and vitrectomy.

Author details

Emina Alimanović Halilović

University Clinical Center Sarajevo, Sarajevo, Bosnia and Herzegovina

6. References

- Alimanović-Halilović E. Complications after Neodymium-YAG laser capsulotomy in Phakic and Pseudophakic Eyes : PhD thesis. Sarajevo: Faculty of Medicine, 2001:5-20;78-105.
- Alward WLM. Laser Iridotomy. In: Weingeist TA. Laser Surgery in Ophthalmology Practical Applications. San Mateo California USA: Appleton & Lange, 1992:139-147.
- Aron-Rose DS et al. Rhegmatogenous retinal Detachment After Neodymium-YAG. Laser capsulotomy in Phakic and Pseudophakic Eyes. In Richard R et al. Use of apulsed picosecond Nd-YAG laser. Am J of Ophthalmology 1986;(101):81-9.
- Blacharski AP, Newsome AD. Bilateral macular holes after Nd-YAG laser posterior capsulotomy. American Journal of Ophthalmology 1988:417-8.
- Carstocea B, Pascu RA. Yttrium Aluminium Garnet Crystal (I). Oftalmologia 2005;49(3): 3-9.
- Cinal A. Intraocular lens position after capsulotomy. J Cataract Refract Surg 2000;26:5-6.
- Collins JF, Donnenfeld ED. Ophthalmic Desk Reference. New York: Raven Press, 1991: 456-7.
- Farvadin M, Mehryar M, Maghaddasi H, Farvadin M. Neodymium-YAG laser treatment for macular hemorrhages. Arch Indian Med 2005; 8(1):8-13.
- Georg E. Learning to be a YAG Surgeon. In: March FW. Ophthalmic Laser. 1990; 119-29.
- Glacet-Bernard, Brahim R, Mokhtari et al. Retinal detachment following Nd-YAG capsulotomy. A retrospective study of 144 capsulotomies. J Fr Ophthalmol 1993;16(2):87-94.
- Holweger R, Marefat B. Intraocular pressure change after neodymium-YAG capsulotomy. Journal of Cataract & Refractive Surgery 1997; 23(7):1095-102.
- Hal DB, Wayne FM, James HL. Use of the YAG Laser in Posterior Capsulotomies. In: Wayne FM. Ophthalmic Laser 1990:131-9.

- Hayashi K, Hayashi H, Nakao F, Hayash F. In vivo quantitative measurement of posterior capsule opacification after extracapsular cataract surgery. *Am J of Ophthalmology* 1998;125:837-43.
- Isola V, Spinelli G, Misefari W. Transpupillary retinopexy of chorioretinal lesions predisposing to retinal detachment with the use of diode (810 nm) microlaser. *Retina* 2001;21(5):453-9.
- Javitt et.al In: Ninn-Pedersen K, Bauer B. Cataract patients in a defined Swedish population 1986-1990. Nd-YAG laser capsulotomies in relation to preoperative and surgical conditions. *Act Ophthal Scandinavica* 1996;114:382-86
- Lerman S, Thrasher B, Moran M. Vitreous changes after Neodymium-YAG laser irradiation of the posterior lens capsule or midvitreal. *Am J of Ophthalmology* 1997;470-5.
- Mackool JR. Antiinflammatory regimen for cystoid macular edema after cataract surgery. *J Cataract Refract Surg* 2000;26:474.
- Meisler et al. In: Tetz MR, Apple JD et al. A newly described complication of Nd-YAG laser capsulotomy: Exacerbation of an intraocular infection. *Arch Ophthalmology* 1987;105:1324-5.
- Ranta P, Kivela T. Retinal detachment in pseudophakic eyes with and without Nd-YAG laser posterior capsulotomy. *Ophthalmology* 1998;105(11):2127-33.
- Rennie CA, Newman DK, Snead MP, Flanagan DW. Nd:YAG laser treatment for premacular subhyaloid haemorrhage. *Eye* 2001;15(Pt 4):519-24.
- Rakofsky S, Koch D. et al. Levobunolol 0,5% and Timolol 0,5% to prevent intraocular pressure elevation after Neodymium-YAG laser posterior capsulotomy. *J of Cataract & Refractive Surgery* 1997;23(7):1075-80.
- Sefić S, Firdus H, Alimanović E, Ljaljević S, Sefić M. Oštećenja oka kod pomračenja sunca. *Med Arch* 2000;54(1):41-4.
- Sefić M. Bolesnik sa kataraktom pita: Da li se može poboljšati vid laserom? Sarajevo: KCU, 1999: 10.
- Smith RT, Moscoso WE, Trokel S, Auran J. The barrier function in Neodymium-YAG laser capsulotomy. *Arch Ophthalmol* 1995;113:645-52.
- Stilma JS, Boen-Tan TN. Timolol and intraocular pressure elevation following Neodymium-YAG laser surgery. *Documenta Ophthalmologica* 1986; 64:59-67.
- Sheidow T, Gonder RJ, Merchea MM. Macular hole following Nd-YAG capsulotomy. *Br J of Ophthalmology* 1999;83(6):755.
- Thach AB, Lopez PF, Snady-Mc Coy LC. et al. Accidental Nd-YAG laser injuries to the macula. *Am J of Ophthalmology* 1995; 119(6):767-773.
- Zeyen P, Zeyen T. The long term effect of YAG laser posterior capsulotomy on intraocular pressure after combined glaucoma and cataract surgery. *Belge d Ophthalmologie* 1999; 271:99-103.
- Bhargava R, Kumar P, Prakash A, Chaudhary KP. Estimation of mean ND: Yag laser capsulotomy energy levels for membranous and fibrous posterior capsular opacification. *Nepal J Ophthalmol*. 2012;4(7):108-13.
- Larrañaga-Osuna G, Garza-Cantú D. Intraocular pressure in patients undergoing capsulotomy Nd: YAG laser *Rev Med Inst Mex Seguro Soc*. 2011;49(3):259-66.

Giocanti-Aurégan A, Tilleul J, Rohart C, Touati-Lefloc'h M, Grenet T, Fajnkuchen F, Chaîne G. OCT measurement of the impact of Nd:YAG laser capsulotomy on foveal thickness. J Fr Ophtalmol. 2011;34(9):641-6.

IntechOpen

IntechOpen