

We are IntechOpen, the world's leading publisher of Open Access books Built by scientists, for scientists

6,900

Open access books available

185,000

International authors and editors

200M

Downloads

Our authors are among the

154

Countries delivered to

TOP 1%

most cited scientists

12.2%

Contributors from top 500 universities



WEB OF SCIENCE™

Selection of our books indexed in the Book Citation Index
in Web of Science™ Core Collection (BKCI)

Interested in publishing with us?
Contact book.department@intechopen.com

Numbers displayed above are based on latest data collected.
For more information visit www.intechopen.com



Immunological and Immunogenetic Parameters on the Diversity of Ocular Toxoplasmosis: Evidence to Support Morphological Criteria to Classify Retinal/Retinochoroidal Scar Lesions in Epidemiologic Surveys

Lílian M.G. Bahia-Oliveira, Alba L.P. Rangel, Marcela S.B. Boechat, Bianca M. Mangiavacchi, Livia M. Martins, Francielle B. Ferraz, Maycon B. Almeida, Elisa M. Waked Peixoto, Flavia P. Vieira and Ricardo G. Peixe

Additional information is available at the end of the chapter

<http://dx.doi.org/10.5772/50086>

1. Introduction

Toxoplasmosis is highly prevalent in Brazil, where its prevalence ranks among the highest in the world. However, the prevalence of ocular toxoplasmosis may vary from one region to another within the country, even in the face of seroprevalence of the same magnitude. For over a decade we have been studying toxoplasmosis in Campos dos Goytacazes, which has amongst the highest prevalence of the condition already reported. Local social and environmental peculiarities influence the risk factors and impact the seroprevalence when analyses are performed in local populations stratified by socioeconomic status [1]. Campos dos Goytacazes, usually referred to as Campos, is located in the northern state of Rio de Janeiro in the most important oil-producing region of Brazil. The city is composed of an area equivalent to 4,027 km², and with 463.731 inhabitants, it is the third most economically important city in the state of Rio de Janeiro. Some aspects related to the natural history of toxoplasmosis in Campos are connected to its historic past with respect to economic agricultural and rural activities that were linked to the Sugar Cane economy. Sugar production prevailed as the most important economic activity until the mid-80s, at which point it began gradually giving way to activities related to oil. The city still preserves its spatial organization and cultural points, which are characteristics of a city with strong rural features.

In areas with a high prevalence of infectious and parasitic diseases, such as toxoplasmosis in Campos, several challenges are posed to the health authorities with regard to diagnoses, accurate assessment of incidence and prevalence, and clinical management of disease symptoms. Our studies in toxoplasmosis have focused on the natural history, epidemiology, immune response and immunogenetics of infected individuals in order to better understand the clinical presentation of the disease. In this chapter, we present in four sections, data related to 1) the diversity of presumable toxoplasmic retinal/retinochoroidal scar lesion presentations in comparison to other population-based studies of the same nature in Brazil; 2) the profile of the *in vitro* immune response of patients in the context of the clinical presentation of ocular toxoplasmosis; 3) evidence for candidate genes that are associated with susceptibility for or protection against the development of toxoplasmic retinal lesions; and 4) the association of ocular toxoplasmosis with other infectious diseases.

2. The diversity of retinal/retinochoroidal scar lesions in *T. gondii* hyperendemic areas of Brazil

In the past, most *T. gondii* retinochoroiditis was thought to be of congenital infection origin. However, it is currently accepted that ocular disease is most likely the most common potentially severe symptomatic manifestation in acute, postnatally acquired toxoplasmosis [2, 3]. The epidemiologic studies in Brazil have contributed to changing that traditional belief. In the country, toxoplasmosis is the most frequent cause of infectious uveitis, as in many other nations [4-9,56,57]. The prevalence of ocular toxoplasmosis in areas highly endemic for *T. gondii* in Brazil has an important public health impact and differs among areas of similar seroprevalence. Population-based studies involving people of ages ranging from 10 years to older than 50 years from different regions of the country have shown that the prevalence of retinochoroiditis varies from 2.6% to 17.7% [4-8].

The population-based studies that are used to estimate ocular disease caused by *T. gondii* infection depend on the observation of retinal/retinochoroidal lesion scars via fundoscopic examinations, and as in epidemiologic surveys, it is not common to find patients with active toxoplasmic lesions. The observed difference in ocular prevalence, even in face of similar seroprevalence has oriented studies to better understand and identify the risk factors for infection and for the development of toxoplasmic ocular disease.

Holland and associates in 1996 [3] report the three types of retinochoroidal lesions in otherwise healthy patients, described in 1969 by Friedmann and Knox, which are based on the localization in the retina, size, vitreous inflammatory reaction and probable prognosis in terms of complications or decreased vision. However, for epidemiologic surveys, the lack of a classification system or a consensual proposal to describe scar lesions presumably caused by *T. gondii* infections certainly impacts the final prevalence that is determined in various studies and, perhaps more importantly, fails to describe asymptomatic, less severe scar lesions confined to the retinal pigment epithelium (RPE) that are not commonly seen by ophthalmologists in clinical settings. Such lesions might be important not only from an epidemiological point of view itself, but, if well studied, they could perhaps aid in the

development of new therapeutic approaches that may benefit patients who have more severe forms of disease, especially recurrent forms of ocular toxoplasmosis.

In light of these considerations, subjective criteria certainly influence the clinical diagnosis of ocular toxoplasmosis in population-based studies, which are based on the appearance of inactive retinal/retinochoroidal scar lesions left by presumed toxoplasmic lesions that were previously active. In addition, the ophthalmologists' clinical experience on the resolution of active lesions is important for the recognition of retinal/retinochoroidal toxoplasmic scar lesions.

An important epidemiological study conducted in Brazil by Glasner and associates in 1992 reported a ranking of probability for the classification of retinal scar lesions that are presumably caused by *T. gondii* infection [4]. The system was established by the authors to try to estimate the actual prevalence of ocular toxoplasmosis in a highly endemic area for *T. gondii* infection located in a small village in southern Brazil called Erechim. According to the authors, on the basis of a conservative assessment of ophthalmic findings, 17.7% of the patients (184 out of 1042 examined) were considered to have ocular toxoplasmosis. They categorized the different types of lesions that were identified during the examination of 1042 individuals and organized them into five groups numbered 1 through 5 according to the probability that the lesion was caused by *T. gondii* infection. Those classified from grade one to grade three were considered to be definitively caused by *T. gondii* infection [4]. We found the authors' initiative very important, and with the same objective, we have proposed some descriptive criteria to classify the most commonly found retinal/retinochoroidal lesions from our population-based work in Campos dos Goytacazes [7, 10, 11]. However, as mentioned earlier, the nature of the toxoplasmic retinal/retinochoroidal scar lesions, or even active lesions described during the fundoscopic examination, is subjective. Thus, the decision as to whether a scar lesion was caused by *T. gondii* infection depends, to some extent, on subjective criteria. To minimize the intrinsic characteristic of this decisional process, in population-based studies, a group of ophthalmologists consensually decide which scar lesions have the greatest probability of being caused by toxoplasmic infection. During this process, the ophthalmologists are usually uninformed as to whether the patient serology is positive or negative for *T. gondii*.

There is a type of retinal/retinochoroidal scar lesion that is universally accepted as being healed from active retinal/retinochoroidal inflammation caused by *T. gondii* infection. These scars usually result from the active typically visible yellow-white focus with fluffy borders, which may or may not be accompanied by vitreous inflammation that limits the visualization of the posterior pole [12]. However, there exist other lesions that are equally recognized by specialists as toxoplasmic lesions, termed as "atypical" toxoplasmic lesions, and their active forms have been reviewed [3, 12]. The frequency of scar lesions healed from "atypical" active toxoplasmic lesions in population-based studies is not well known because in previous studies, with the intent of avoiding an over estimation of ocular toxoplasmosis, only scars healed from typical lesions, which are most likely equally typical in terms of toxoplasmic retinochoroidal scar lesion representativeness, have been usually used to infer the ocular prevalence of *T. gondii* infection in epidemiologic surveys. As a consequence,

identifying the actual prevalence of ocular toxoplasmosis in areas highly endemic for *T. gondii* in Brazil constitutes a challenge in practice and may be underestimated. In fact, the existence of retinal/retinochoroidal scars most likely healed from non-typical toxoplasmic retinal/retinochoroidal lesions have been reported in endemic areas [4, 7, 9-11, 13] as discussed later in this section.

Two groups working independently in Rio de Janeiro state, one from the State University of North Fluminense (UENF) at Campos dos Goytacazes and another from the Oswaldo Cruz Foundation, have conducted epidemiological and human immunogenetic studies that can be directly compared because the same criteria for ocular scar lesions classification was adopted for both [9, 11]. The criteria for characterizing scar lesions that were presumably caused by *T. gondii* infection adopted by both groups were based on the morphological aspects of the scars, primarily the pigmentation and the degree of retinal tissue damage. The lesions were termed as type A, type B or type C by the Campos dos Goytacazes group [7, 11] and as type 1, type 2 or type 3, respectively, by the Oswaldo Cruz Foundation group [9]. The Oswaldo Cruz group investigated the retinochoroiditis caused by *T. gondii* infection in a rural area (Santa Rita) of Barra Mansa, located at southern part of the Rio de Janeiro state [9]. Campos dos Goytacazes and Santa Rita are both supplied by the Paraíba do Sul River, which supplies water to approximately 4.8 million persons in Brazil. The cities are located approximately 390 km from each other; Campos at north of the state and Barra Mansa in the south.

In 2005, the Campos group published a proposal (in Portuguese) to categorize/classify the diverse foci of retinochoroiditis scars found in a survey conducted from 1997-1999 on the prevalence and risk factors for *T. gondii* infection. In the proposal, the group termed the toxoplasmic scar lesion foci as type I, type II or type III [10]. In a previous publication of 2001 [7], the Campos group had termed such lesions as type A, type B and type C, respectively. However, because of the possibility of confusion and some relation with the three archetypal *T. gondii* lineages, which are termed type I, II or III based on the genomic sequence associated with their virulence in mice [14, 15], we returned to the original classification nomenclature of type A, type B and type C [7, 11]. The following descriptions in quotes are related to the three classes of retinal/retinochoroidal foci scars found in *T. gondii* seropositive individuals in endemic areas to toxoplasmosis published by both the Campos and Oswaldo Cruz Foundation groups: “class A lesions present well-marked boundaries, usually surrounded by a pigmented halo and extensive destruction of the retina and choroid. Class B lesions are characterized by a surrounding hypopigmented halo and a smaller degree of tissue destruction in comparison to class A. Class C lesions are basically areas of retinal pigment epithelium hyperplasia or atrophy with a smaller degree of tissue destruction compared to class A and B” [11] and “type 1 lesions boundaries are well marked with a halo of hyperpigmentation and central area of retinochoroidal atrophy, type 2 lesions with hypopigmented halo and central hyperpigmented area and type 3 lesions hyperpigmented or hypopigmented consistent with hyperplasia or atrophy of the retinal pigment epithelium”¹ [9].

¹ Translated from the original publication in Portuguese (ref.9)

Figure 1 shows representative type A, B and C scar lesions that appear isolated in one or both eyes as well as multiple lesions of different types (AB, ABC, AC and BC) in one or both eyes. Type A and B scar lesions have a higher probability of being recognized by ophthalmologists as being caused by *T. gondii* infection. Certainly, out of the context of epidemiological surveys to estimate ocular toxoplasmosis, type C scar lesions would, with very low probability, be considered as retinal scars healed from ocular toxoplasmosis. Some aspects intrinsic to this type of scar lesion led us to believe they are caused by *T. gondii* infection; these are i) their high frequency in patients who are seropositive for *T. gondii*; ii) their common association with the more typical type A and B scar lesions; and iii) their differentiated profile of the specific *in vitro* cellular immune response of patients presenting this type of lesion compared to *T. gondii* seropositive patients who present no ocular lesions. We have evidence that the profile of their specific *in vitro* cellular immune response is most likely a result of a very efficient mild to minimal inflammatory intraocular reaction against *T. gondii* that causes only superficial injury to RPE, which can result in pigmented or apigmented scars, as we shall see later in this chapter.

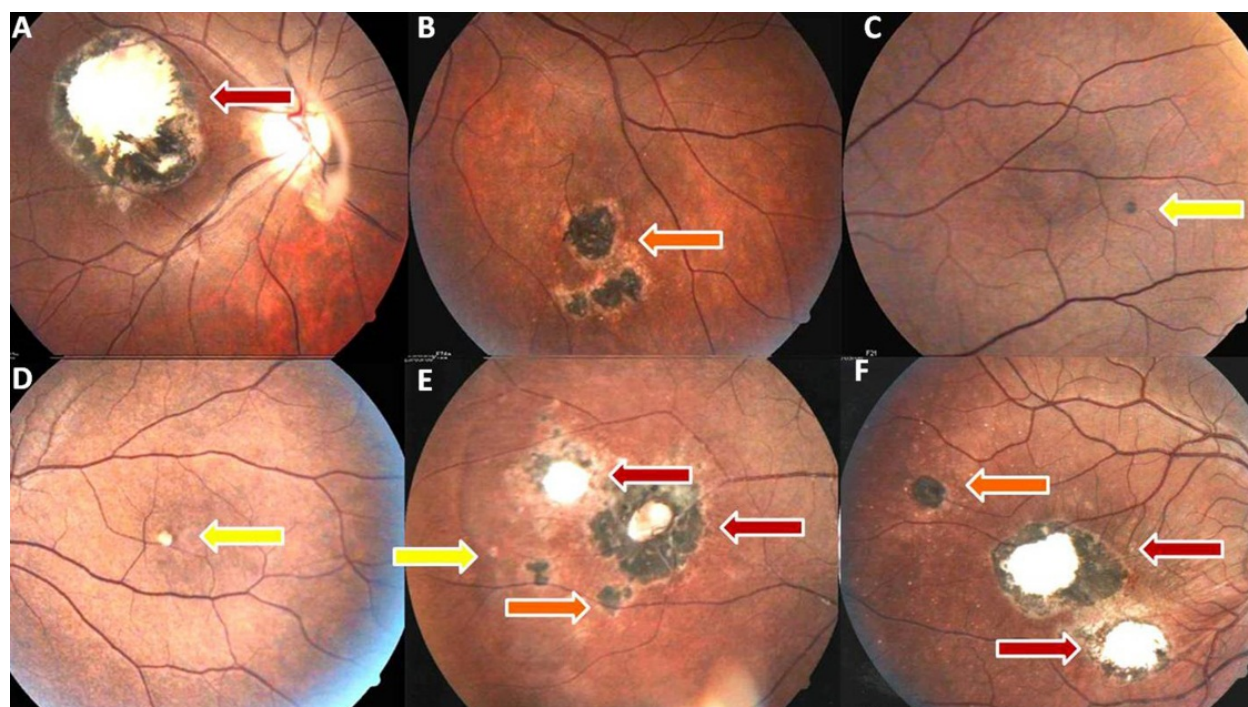


Figure 1. Fundus photograph of representative retinal/retinochoroidal non-active scar lesions. Panel A and panel B represent single type A and B scar lesions, respectively. Panels C and D represent single type C scar lesions that are hyper- and hypopigmented, respectively. The scar lesions by type are indicated by colored arrows: red represents type A scar lesions, orange represents type B scar lesions and yellow indicates type C scar lesions. The two pictures at the bottom (panels E and F) show multiple scar lesions of type ABC (with arrows red, orange and yellow) and a multiple scar lesion of type AB (with arrows red and orange).

In a survey conducted in 1997-1999 to investigate the seroprevalence of toxoplasmosis in Campos [1], during which 1436 persons were investigated and the local waterborne nature of *T. gondii* infection was shown, the study population was divided into three socio-

economic strata. In addition to other factors, the geographic localization of the selected people was important for differential *T. gondii* seroprevalence levels. Then, for the groups living in slums and rural areas from Campos who shared the same lower socio-economic strata termed as population 1 (P1), the *T. gondii* age adjusted seroprevalence was 84% [1]. For the middle and upper socioeconomic groups, termed as population 2 (P2) and population 3 (P3), 62% and 23% of *T. gondii* age adjusted seroprevalence was identified, respectively. However, the lower age adjusted seroprevalence of toxoplasmosis observed for P3 (23%) and P2 (62%) in comparison with P1 (84%) [1] contrasted with the similar overall ocular prevalence found for the three populations namely, P3 (12%), P2 (10%) and P1 (12%) [7]. It is important to mention that for the estimation of ocular disease prevalence caused by *T. gondii* infection in Campos, which was published in 2001, a more conservative basis for diagnose was adopted. The diagnosis considered only the typical appearance of retinochoroidal scar lesions for the prevalence calculation [7]. For the Santa Rita study, which will be compared to the Campos study, only the population living in rural areas was evaluated, and the *T. gondii* seroprevalence was found to be 65.9%; however, no risk factor was reported [7]. For the Campos study, we observed that despite the same seroprevalence among those living in rural areas and those living in slums (both from P1 strata), the prevalence of ocular disease was different. Namely, when the lower socio-economic strata were sub-stratified according to people living in rural areas and those living in slums, we found that the prevalence of ocular disease was 14% for those living in rural areas and 8% for those living in slums [7]. For the Santa Rita study, which involved only the rural community, ocular disease prevalence was reported as 5.8%.

For the past six years, we have conducted randomized samplings of individuals older than 10 years belonging to P1 and P2 (lower and middle socio-economic strata, respectively, from the total Campos population). We have collected peripheral venal blood for *T. gondii* serologic evaluation and patients have been examined by indirect ophthalmoscopy. Some patients who may have participated from the previous survey [1] were re-evaluated clinically and serologically by collecting new blood samples for the immunological and immunogenetic studies. The results of the serologic prevalence and the prevalence of ocular disease from 411 patients that were examined over the past six years are reported in Table 1 to compare our results with the Santa Rita study population.

The frequencies of types of scar lesions, considering the total number of patients who presented scar lesions in each study, are shown in the Table 1. There were 41 persons with scar lesions out of 706 *T. gondii* seropositive individuals from Santa Rita and 94 subjects with scar lesions out 314 *T. gondii* seropositive individuals from Campos. We observed that the frequency of type A (type 1) lesions was much higher in Santa Rita (41.5%) than in Campos (19.1,%) and that the most frequent type of scar lesion per patient from Campos was type C (28.7%); in Santa Rita, the frequency of the type C (Type 3) scar lesion was 12.2%. Curiously, the frequency of type B (type 2) lesions was very similar in both areas: 24.4% in Santa Rita and 24.5% in Campos. The sum of multiple lesions types in both areas was also similar. Namely, the sum of the frequency of individuals who presented AB + ABC + AC + BC as well as 1 and 2 + 1 and 2 and 3 + 1 and 3 + 2 and 3 scar lesions was 27.7% and 22% for Campos and Santa Rita, respectively.

	Santa Rita (Barra Mansa)			Campos dos Goytacazes	
	n	%		n	%
Study population	1071			411	
<i>T. gondii</i> seropositivity	706	65.9		314	76.6
Type of scar lesions	n	%	Type of scar lesions	n	%
1	17	41.5	A	18	19.1
2	10	24.4	B	23	24.5
3	5	12.2	C	27	28.7
1 and 2	2	4.9	AB	9	9.6
1 and 3	4	9.8	AC	2	2.1
2 and 3	2	4.9	BC	7	7.4
1, 2 and 3	1	2.4	ABC	8	8.5
Total	41	5.8%	Total	94	11.7 %*

* The total prevalence of ocular disease in Campos can be expressed in three levels.

1- Considering only the persons who present type A scar lesions, which are those universally recognized as being healed from the typical toxoplasmic retinochoroidal active lesions. This value is calculated as the sum of single type A scar lesions (n=18) plus the multiple type lesions that contain the type A scar lesion, (AB n=9) + (AC n=2) + (ABC n=8), totaling 37 individuals. This gives the prevalence of ocular disease of 11.7%.

2- Considering the individuals who present type A single and multiple type scar lesions plus the individuals presenting type B single (n=23) plus multiple type lesions (BC n=7), which adds up to a total of 67 individuals and gives a prevalence of 21.33%.

3- Considering all the people who present type A and type B single and multiple type lesions and persons who present with type C scar lesions, which totals 94 individuals and gives a prevalence of 29.9%.

Table 1. Comparison Between the *T. gondii* Seroprevalence and Retinal/Retinochoroidal Scar Lesions Prevalence from Campos dos Goytacazes (RJ) and Santa Rita (Barra Mansa-RJ)

Considering that out of 411 clinically and serologically examined patients 314 were seropositive for *T. gondii*, the seroprevalence was estimated at 76.6%. This prevalence represents the intermediate value between the prevalence observed for P1 (84%) and P2 (62%) reported in 2003 [1] and calculated by $P1(84\%) + P2(62\%)/2 = 73\%$. The same was observed for the expected and found toxoplasmic ocular prevalence; i.e., adopting the same highly conservative criteria of 2001 to compute toxoplasmic scar lesions and considering only the individuals who presented typical lesions (type A scar single or multiple lesions, i.e., the sum of type A scar lesions plus scar lesions of type AB, ABC and AC), we found a toxoplasmic ocular prevalence of 11.7% (37 out of 314 individuals). Once again, the prevalence corresponded to that would be expected from that observed in 2001: 10% for P1 and 12% for P2 [7], as $P1(10\%) + P2(12\%)/2 = 11\%$. However, if we consider type B and type BC scar lesions together with type A and type AB, ABC, and AC scar lesions to calculate the toxoplasmic ocular prevalence in Campos, we find 21.33% (67 out of 314). Furthermore, if we additionally consider type C scar lesions to calculate the frequency, the prevalence of toxoplasmic ocular lesions in Campos increases to 29.9% (94 out of 314). It is important to keep in mind that the prevalence values are related to the population extract P1 plus P2 older than 10 years and that it is after the age of 10 that we observe a substantial increase in

T. gondii seroprevalence for P1 and P2, based on previous studies in Campos [1]. Furthermore, it is only after 10 years of age that we observe the elevation of ocular toxoplasmosis prevalence in population-based studies in general [2].

In the context of the diversity of retinal/retinochoroidal scar lesions found in epidemiologic surveys in Brazil, another important report from the Erechim area was conducted by Silveira and associates in 1999 [13], seven years after the study conducted by Glasner and associates in 1992 [4]. A group of patients that were previously examined in 1992 presented a type of hyperpigmented scar lesion presumably caused by *T. gondii* infection and termed as “atypical” in comparison with those were termed as “typical” lesions. Some of those patients had “atypical” scar lesions that evolved to “typical” toxoplasmic retinal lesions in the time frame of 7 years. The description of the hyperpigmented “atypical” lesions from patients of Erechim fulfills all but one of the criteria we have used to classify type B toxoplasmic scar lesions in Campos [13]. The difference between Silveira’s description and our description is that we do not consider size to define the type of scar in any of our classification criteria. Instead, we consider the type of pigment distribution in the scar and the degree of the retinal tissue damage, namely the degree of tissue damage that can be inferred by indirect ophthalmoscopy, considering the natural limitations for this type of examination in terms of tissue evaluation damage. In the referred study from Erechim, Silveira and associates showed that at 7-year follow-up, 3 persons of 13 subjects presented “atypical” scar lesions that evolved to “typical” toxoplasmic retinochoroidal scars. They concluded that the typical new lesions arose from or adjacent to the pre-existing atypical lesions in two of the three patients based on photographs and drawing of atypical scar lesion location seven years prior [13].

As stated earlier, the criteria used to classify scar lesions as type A, B or C are morphological based on the pigment appearance and the degree of retinal damage. However, we believe that information regarding their size and localization could be useful for future comparative studies in other endemic areas of Brazil and abroad. We present the frequency of localization and sizes of 85 scar lesions from 49 patients, some of which were involved in immunological and immunogenetic studies conducted in Campos [16-18]. In Figure 2, a fundoscopy picture from a normal (presenting no retinal damage) individual is shown. The numbers indicate four retinal region (code/index) that are used to compute the scar lesion localization for frequency calculation purposes, as shown in Table 2. Each retinal region shown in Figure 2 is assigned an arbitrary number (index/code) as follows: equatorial (1), macula (2), posterior pole / macula (3), posterior pole (4); the periphery (5) shown in Table 2 does not appear in Figure 2 because it is not usually visible in fundoscopic pictures. Each scar lesion was computed independently if an individual exhibited more than one type of scar lesion in one or both eyes, such as A, B or C or a combination of types, such as AB, AC, ABC, or BC, irrespective of their locations. Thus, from the 49 individuals who presented scar lesions, a total of 15 type A scar lesions, 34 type B scar lesions and 36 type C scar lesions were considered for analysis, totaling 85 scar lesions. The median value of scar from the most severe lesions (type A) that was 2, presents a numeric value (index/code) arbitrarily attributed to denote location on the retina, that was lower compared to values observed for

the locations of type B (median value= 4) and C (median value =5) scar lesions. This fact illustrates that the median locations of type A scar lesions (median value =2) are preferably in regions closer to the macula (see Figure 2), whereas type C lesions are preferentially located in peripheral regions of retina. The statistical comparison among the different types of toxoplasmic scar lesion locations was tested using a Kruskal-Wallis test followed by a Dunns test. A significant difference ($p \leq 0.01$) was found between the localization of type A scars and type C scars. No significant difference between the locations of type A and B scar lesions was found. Between type B and type C scar lesions, a significant difference ($p < 0.01$) was also found.

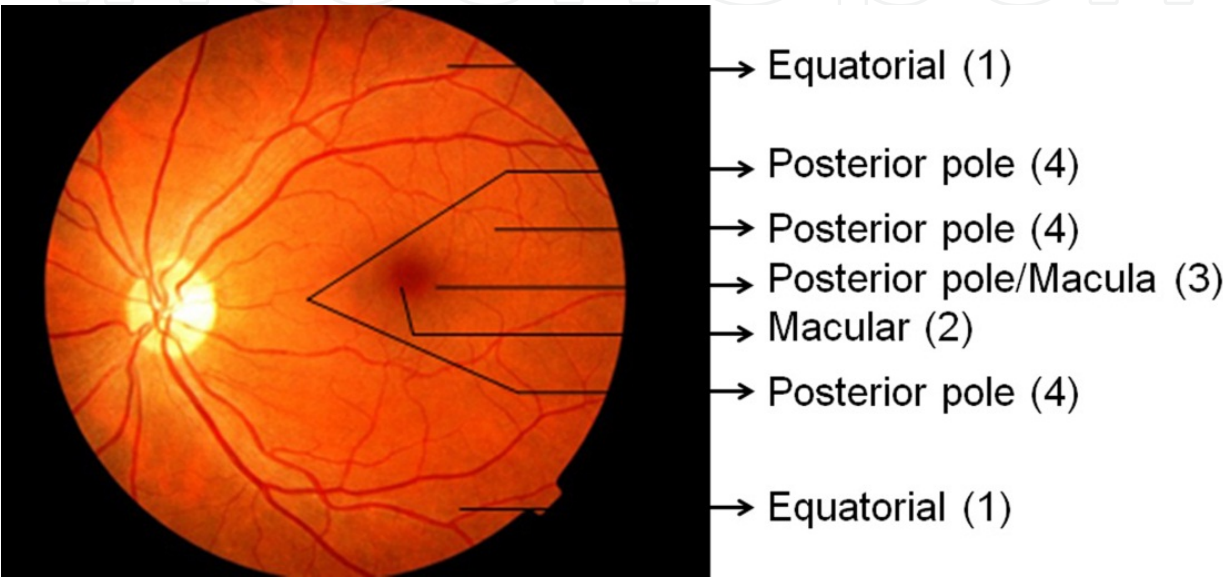


Figure 2. Fundoscopic photograph of a normal retina indicating the regions: equatorial (1) macular (2), posterior pole/macula (3) and posterior pole (4). Region 5, which corresponds to the periphery, is not shown (see text and Table 2).

Lesion localization region	Location Code (Index) of lesion in retina	Frequency of occurrence (n) of each scar type lesion
Equatorial	1	A(6) B (15) C (9)
Macular	2	A(5) B (1) C (0)
Posterior pole/Macula	3	A(1) B (0) C (0)
Posterior pole	4	A(1) B (5) C (2)
Periphery	5	A(2) B (13) C (25)

Table 2. Frequency of the Topographic Location of Retinal/Retinochoroidal Scar Lesions of type A, type B and type C in the retina

The sizes of the same 85 scar lesions were also measured in terms of optic disc size (disc diameter, dd) at the slit lamp with a 78 D lens in a normal clinical ophthalmoscopic

examination.. Table 3 shows the scar lesion types sizes that were categorized in 4 size ranges: 0 to 0.5 dd, 0.6 to 1 dd, 1.1 to 1.5 dd, and 1.6 to 2.0 dd. The four size ranges corresponded to a code/index number from 1 to 4, respectively, for the statistical analysis objective. The diameter of the optical disc of each subject was used as a parameter for determining the size of the scar lesions of the same person. There is no proportional relationship defined between the disc diameter and the arbitrary attributed code/index number. The frequency of occurrence by size of each of the 15 type A scar lesions, 34 type B and 36 type C scar lesions is shown in Table 3, where the three scar type sizes were compared in terms of the relationship between the type and the size range measured for the disc diameter (dd), as explained above. The type A scar lesions (healed from the most severe lesions) exhibited sizes significantly larger (median value = 2.2) $p \leq 0.001$ than the type C scar lesions (median value = 1.0) but not significantly larger than type B scar lesions (median value =1.8), which are of middle severity in terms of retinal damage. A significant difference ($p \leq 0.001$) relative to the size of the type B ocular scar lesions was also observed in comparison with type C scar lesions, which were on average smaller than type B lesions. It is important to mention that the age of the patient can influence the size of the optical nerve (diameter) [19], which can interfere with these types of measurements. However, the average age between groups did not differ statistically, and therefore this factor likely did not affect our evaluation. Nonetheless, the size measurement was not considered in our proposed criteria to classify scar type lesions, and it is discussed here solely to provide a better representation of the diversity of the scar lesions we have found with a reference for the measurement, which can be useful for comparative studies in other areas from Brazil and abroad.

Size of lesion in diameter disk (dd)	Size code (index) of retinal lesion	Frequency of occurrence (n) of each lesion type
0 – 0.5	1	A(3) B (17) C (35)
0.6 – 1	2	A(7) B (9) C (1)
1.1 – 1.5	3	A(2) B (6) C (0)
1.6 – 2.0	4	A(3) B (2) C (0)

Table 3. Frequency of the Size of Retinal/Retinochoroidal Scar Lesions of type A, type B and type C in the Retina

The average age between groups did not differ statistically. The average age of patients presenting scar lesions of type A was 44 yrs and AC 52 yrs which are higher in comparison with the other types of lesions (type B, BC and ABC 29 yrs, type AB 32 yrs and type C 36 yrs) and consistent with previous findings that have shown that age is an important factor for the severity of ocular toxoplasmosis [20]. Nevertheless, if we assume that the “atypical” hypermigrated scar lesions that were described to occur in *T. gondii* seropositive patients from Erechim [13] are the same type of type B scar lesion we describe for patients from

Campos, the data are similar regarding the age of the patients presenting those lesions, which were more common among younger patients (under 17 years of age) compared to older individuals [13]. This fact might indicate that type B scar lesions would be related to more recent infections. Unfortunately, age as a function of the type of scar lesion was not reported in the Santa Rita study [9]. We can conclude from the set of data presented and reported from other studies that the lack of a set of consensual criteria for scar lesions presumably caused by *T. gondii* infection may account, at least partially, for the differences in the reports of categorization/classification of toxoplasmic ocular prevalence observed in Brazil.

3. Immunological parameters in the context of the diversity of retinal/retinochoroidal scar lesions from *T. gondii* seropositive patients

T. gondii infection in both mice and humans is characterized by a host response with high levels of pro-inflammatory cytokines, such as interleukin 12 (IL-12), tumor necrosis factor (TNF)- α and interferon gamma (IFN- γ), all of which have been implicated in both the regulation of parasitic replication in the host as well as in the ocular pathology [11, 16, 21-24]. The importance of the immune response of patients infected with *T. gondii* against the parasite has been recognized, together with other variables comprising the multifactorial nature of ocular toxoplasmosis. In this section, we present results from the *in vitro* parameters of the cellular immune response of *T. gondii* seropositive patients with and without ocular retinal/retinochoroidal scars and control groups of seronegative patients exposed to the same risk of infection, which involved the consumption of untreated water from wells or other natural water sources [1], against soluble antigens from *T. gondii* tachyzoite forms (STAg). Cytokines, chemokines, and isotypes of immunoglobulins have been evaluated in an effort to identify potential predictive factors for the development or prevention of ocular disease. All of the immunological parameters have been analyzed considering different groups of patients arranged according to the similarity in the retinal/retinochoroidal scar lesion group.

A pro-inflammatory specific T helper 1 (Th-1) oriented response is observed mainly in groups of patients presenting retinochoroidal scar healed from severe lesions, which suggests that the exacerbation of the immune response can be related to tissue damage, and its attenuation/regulation may be related to the development of minor retinal damages. The central role of IFN- γ seems to be important in both cases, namely, in exacerbated and in the regulated context of *in vitro* cellular immune response, suggesting that the cellular immune responses against *T. gondii* in the eye should be suitably tailored [11, 16, 21-23], as we shall see later. Other molecules and cells related to the regulation of secretion of IFN- γ include IL-13, chemokines, isotypes of immunoglobulins, NK cells and T CD8 lymphocytes in relation to the development or prevention of development of toxoplasmic ocular pathology have also been investigated [11, 16, 21, 22]. The immunological parameters studied have also made way for the election of candidate genes to be investigated in studies of genetic association with ocular toxoplasmosis, as we shall see in the next section.

However, we have evaluated many immunological parameters we have chosen three to better illustrate the profile of the cellular immune response as a function of the type of scar lesion presented by patients. The first is IFN- γ , the prototype of Th-1 response that has been shown to be of vital importance for inducing anti-*T. gondii* effectors mechanisms to control the parasite replication in the host [25]. The second, IL-13, is a Th-2 cytokine whose functions overlap considerably with those of IL-4, and it is important for the control of the Th-1 response but that has not been well studied in toxoplasmosis. The third chemokine, CXCL 10 (interferon gamma-induced protein 10- IP-10), is secreted in response to IFN- γ stimulation. Recently, it was demonstrated in a murine model that treatment of chronically infected mice with anti-CXCL10 antibodies led to decreases in the numbers of CD3+, CD4+, and CD8+ T cells and the amount of IFN- γ mRNA expression in the retina and an increase in replicating parasites and ocular pathology, which provides evidence that the maintenance of the T-cell response and the control of *T. gondii* in the eye during chronic infection is dependent on CXCL10 [26]. Cytokines and chemokine measurements were carried out using supernatants collected from PBMC cultures stimulated with *T. gondii* antigens. The concentrations were determined by using the BD Cytometric Bead Array (CBA) human chemokine kit and Th1/Th2 cytokine kits and Human IL-13 Flex Set, according to the manufacturer's protocol (BD Pharmingen).

Table 4 summarizes the individuals for which the specific immune response against *T. gondii* has been evaluated. The *T. gondii* serology and age range is provided. All the seronegative (SN) individuals, seropositive (SP) without ocular scar lesions (NL) and individuals with retinal or retinochoroidal scar lesions categorized as type A, type B or type C, as explained above, were sex- and age-matched among the groups. We observed that there was a similarity in terms of the profile of the *in vitro* immune response between patients who presented multiple scar type lesions and patients who presented single type A or B scar lesions, depending on which cytokine had been considered among the groups for comparison. Then immunological analysis, presented in Figure 3 and Figure 4, show the patients presenting multiple type scar lesions (AB, ABC, AC or BC) grouped in two different ways. This optional arrangement of patients, considering the multiple types of scar lesions, has helped us to propose three settings of immune responses that match the clinical presentation of ocular toxoplasmosis, which has been inferred in our studies by the morphological appearance of the retinal/retinochoroidal lesions. The reasoning behind the optional arrangements is related to the common presence of type B and type A scar lesions in two (AB and ABC) out of the four (AB, ABC, AC and BC) multiple type scar lesions. In Figure 3, they were grouped as follows: patients with AB, ABC and AC scar lesions are all included in the type A scar lesion group, which we considered the highest categorization in terms of tissue damage severity of scar lesion, and the patients presenting scar lesions of type BC were included in the group of type B scar lesions. The type C scar lesion group is composed of individuals presenting only type C scar lesions.

Concerning to the cytokine and chemokine production, we observed two levels of production that are termed as high or low levels. As a consequence, individuals producing low or high levels of cytokines or chemokines are termed high or low cytokine/chemokine

producers. To calculate the frequency of high and low levels of production, an arbitrary cutoff value was established for each cytokine and chemokine based on the visual dispersion graphics, where it was possible to determine a dividing line that separated the secretion levels into two scattered clusters, one high and another low. The capability of producing low and high levels of IFN- γ is a phenotypic characteristic that is genetically associated with a single nucleotide polymorphism in the first intron of the human IFN- γ gene, as determined by Pravica and colleagues in 2000 [27]. The capability of producing low and high levels of IFN- γ can be observed in other infectious disease [28, 29]. The levels secreted by each patient that fell above the cutoff values were considered high values, and the levels that fell below the cutoff values were considered low values. The median value of the two cytokines IFN- γ and IL-13 and the chemokine CXCL10 secretion was utilized to help to establish the exact numeric cutoff values to be used for each cytokine and chemokine: 29.58ng./mL, 194.12 pg/mL, and 113.72 ng/mL for IFN- γ , IL-13 and CXCL10, respectively. Those median values refer to patients who presented type C scar lesions. This group was chosen because it exhibited the best spreading profile, producing two very clearly separated clusters corresponding to levels of high and low producers of the two cytokines and the chemokine that were evaluated.

Groups	Toxoplasmosis serology and scar lesion type	n	Mean Age (SE) ¹
1	SN ²	9	29.6 (5.2)
2	SP ³ /NL ⁴	21	28.8 (4.7)
3	SP/type A ⁵⁻⁶	18	35.5 (6.0)
4	SP/type B ⁵⁻⁶	21	27.5 (4.4)
5	SP/type C ⁵	20	31.7 (5.1)

¹ (SE) = standard error
² *T. gondii*-seronegative individuals (SN)
³ *T. gondii*-seropositive individuals (SP) without ocular lesions ⁴(NL)
⁵ *T. gondii*-seropositive individuals (SP) with retinochoroidal/retinal scars lesions categorized as class type A, type B or type C.
⁶ In the group of type A scar lesions, individuals with single type A scar lesions (N=4) and multiple scars lesions type AB (N=5), ABC (N=7) and AC (N=2) were also included, totaling the 18 individuals shown in the table. In the group of type B scar lesions, individuals with single type B lesions (N=14) and individuals with multiple scars lesions type BC (N=7) were included, totaling the 21 individuals shown in the table.

Table 4. Groups of Individuals Involved in Immunological Studies According to *Toxoplasma gondii* Serology, Age and the Presence or Absence of Retinal/Retinochoroidal Scar Lesions.

Figure 3 shows the frequency of IFN- γ , IL-13 and the chemokine CXCL 10 secretion, considering only patients who produced high levels of each cytokine, i.e., the high producers. The lowest frequency of high IFN- γ producers (43%) was observed in the group of patients with type B scar lesions even compared with patients presenting no lesions (SL) (52%), and the highest (61%) was observed in the group that presented type A scar lesions; 50% of the patients with type C lesions presented high levels of IFN- γ production. However, for IL-13 production, we observed that the lowest frequency of high producers was observed among patients with type A (28%) scar lesions, in comparison with patients who presented no lesions (SL) (29%). The highest production levels were observed among

patients who presented type C scar lesions (50%); 30% of the patients with type B scar lesions presented high levels of IL-13 production. Curiously, for the CXCL 10 chemokine, which is inducible in response to IFN- γ , the highest frequency of high producers was observed among patients with type C scar lesions (53%), and the lowest frequency of high producers was observed among patients with type B scar lesions (21%), which is comparable to the frequency of high production observed in patients without ocular lesions (SL) (23%); 38% of patients with type A scar lesions were high producers of CXCL10. These data suggest that CXCL10 in humans can have the same role regarding *T. gondii* infection that it plays in mice: to control the numbers of CD3+, CD4+, and CD8+ T cells and the amount of IFN- γ mRNA expression in the retina and, in consequence, the replication of parasites in the eye during the chronic phase of *T. gondii* infection [26]. In addition, it is evident that patients who present type C scar lesions secrete high levels of IL-13, a cytokine that can control the levels of pro-inflammatory cytokines without affecting IFN- γ secretion within the eye, as shown in experimental models. The role of IL-13 was shown to inhibit pro-inflammatory cytokines, with the exception of IFN- γ , within the eye in a model of endotoxin-induced uveitis (EIU) in the Lewis rats. Intraocular injection of IL-13 significantly inhibited the production of pro-inflammatory cytokines and resulted in less intense ocular inflammation without down-regulating the levels of local IFN- γ [30]. In addition, the induced auto-immune uveitis with human retinal S-antigen in monkeys was treated with human recombinant IL-13 [31]. The injection of IL-13 significantly inhibited the inflammation in the eyes where the disease was present when the treatment was initiated. The beneficial effect of IL-13 extended into the 4-week follow-up period; however, after cessation of therapy, there was a progressive increase of inflammation in the IL-13 treated group. Nevertheless, the authors concluded that attention should be paid to the promising modality of treatment for severe uveitis with IL-13 [31]. The profile of the immune response against *T. gondii* exhibited by patients who presented type C scar lesions is suggestive of a favorable inflammatory environment within the eye for the maintenance of a controlled response to prevent both parasite growth and tissue damage, which could be caused by the parasite growth itself and/or may be a consequence of an exacerbated immune response against the parasite. In this context, it is important to highlight the fundamental importance that has been demonstrated for the role of IFN- γ in toxoplasmosis [25].

IFN- γ can induce tryptophan degradation, which is critical to the parasite's survival [32]. The effects of interferon on multiplication of *T. gondii* in *in vitro* systems seem to be dependent on cell type, and a diversity of molecular mechanisms is evident depending on the cell type or system. It has been shown in neuronal tissues and cells that nitric oxide (NO) production is an important factor for parasite growth inhibition [33]. However, parasite growth inhibition was found to be independent of a nitric oxide-mediated or tryptophan starvation mechanism [34]. The control of parasite interconversion between tachyzoites and bradyzoites in the eye is also fundamentally dependent on IFN- γ [35]. Furthermore, in primary cultures of human retinal pigment cells (HRPE), *T. gondii* replication was inhibited by the induction of indoleamine 2,3-dioxygenase (IDO), which degrades tryptophan to kynurenine. However, nitric oxide production was not detected in this system [36].

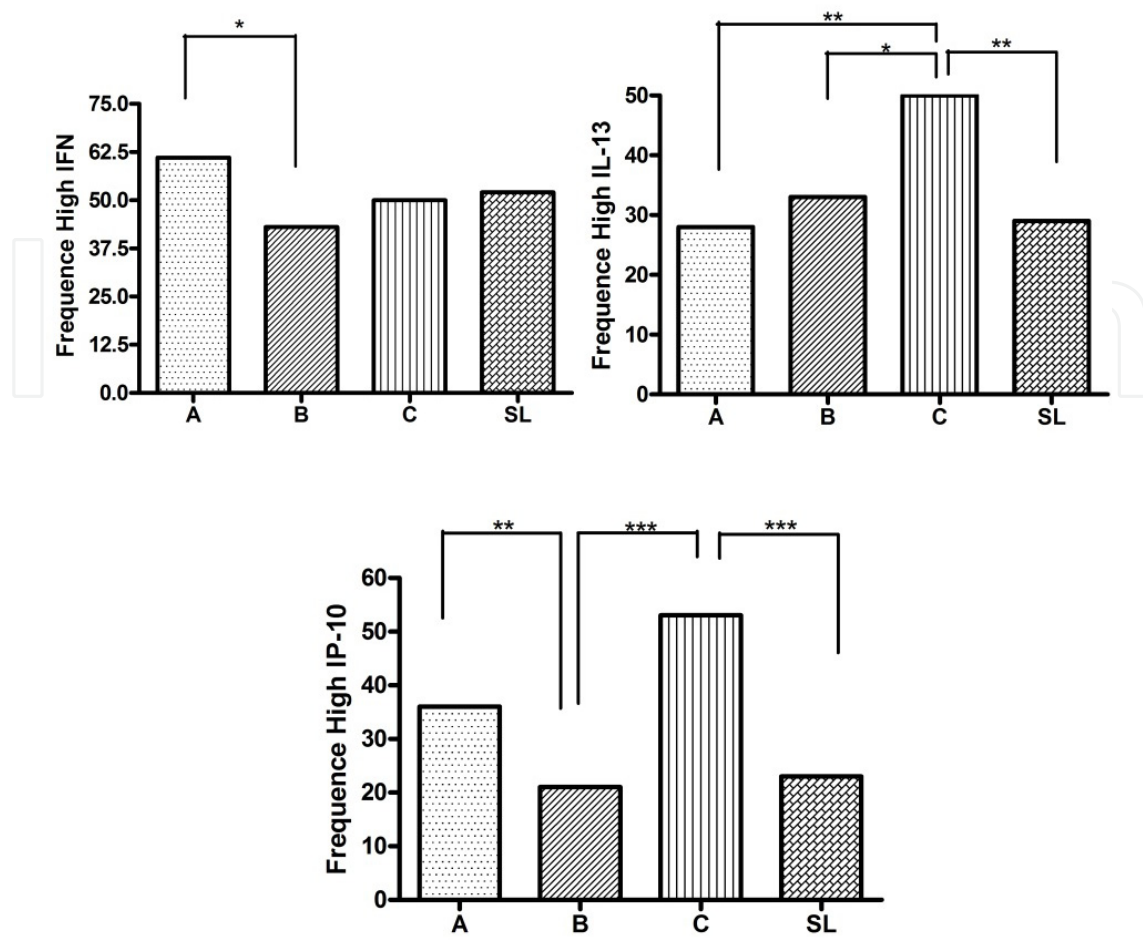


Figure 3. Frequency of high IFN- γ IL-13 and CXCL10 (IP-10) producers, which were grouped according to the type of scar lesion, as shown in Table 4. The frequency of non-infected seronegative individuals (SN) is not shown because in none of them PBMC produced high levels of IFN-gamma, IL-13 and or CXCL10 (IP-10) under stimulation with soluble *T. gondii* antigens (STAg). The exact Fisher's test was used to compare the groups in terms of the differences in the frequencies of high cytokines/chemokine producers. Significances were found at the levels of * $p < 0.05$, ** $p < 0.01$ and *** $p < 0.001$. Significant differences were found between type A and type B scar lesions for IFN- γ production (* $p < 0.05$), between type C and all the other types of scars lesions regarding IL-13 secretion, and between type C and all the other types of scars lesions groups for CXCL10 (IP-10). The data regarding PBMC IFN- γ , IL-13 and CXCL10 from non-infected (SN) individuals in response to *T. gondii* soluble antigens is not shown because none of those patients produced high levels of those cytokines or chemokine.

Based on fundoscopic examinations, type C scar lesions seem to be areas of RPE hyperplasia or atrophy. However, they must to be better characterized by new high-resolution cross-sectional imaging of the retinal tissues (such as using spectral domain optical coherence tomography) in order to better clarify their structural changes in the retinal layers. As mentioned earlier some aspects showed here led us to accept the relationship between type C scar lesions and *T. gondii* infection one of them is the profile of cellular specific immune response of patients who present only type C scar lesions, which is concomitantly abundant for IFN- γ , IL-13 and CXCL10. The reproduction of this type of scar lesion in experimental models would be of value to better understand their meaning in ocular toxoplasmosis. Because we have been working in a highly endemic area to toxoplasmosis and the majority

of the population is *T. gondii* seropositive, we cannot rule out the possibility of an association between the type C scar lesions and other infectious or non-infectious conditions whose natures could be genetically predisposed and prevalent in the Campos population.

As stated previously, patients were grouped in an optional way. Those presenting only type A scar lesions comprised a distinct group, taking into account the possibility that in patients presenting only type A scar lesions, the course of the immune response could be different from that which occurred in patients who presented multiple type scar lesions. There are rational and intuitive aspects to this arrangement that are related to various factors, like the tendency for the production of higher IFN- γ levels of in PBMC cultures of patients who present only type A scar lesions in response to parasitic antigens and the clinical observation that some patients can present type A scar lesions soon after an episode of acute ocular toxoplasmosis without a previous history of ocular toxoplasmosis. However, some patients present a slower evolution, from mild to severe scar lesions, as described by Silveira and associates in a well documented report [13]. As previously stated in this chapter, this observation concerns the evolution of hyperpigmented “atypical” toxoplasmic retinal scar lesions (similar in appearance to the type B toxoplasmic scar lesions that we have described) evolving to “typical” toxoplasmic retinochoroidal lesions (similar in appearance to the type A toxoplasmic scar lesions that we have described). Then for the analysis of the immune response as a function of the clinical presentation of ocular toxoplasmosis inferred by the morphological appearance of the retinal/retinochoroidal scar lesions, the patients were optionally arranged into three groups as follows: i) patients presenting only type A scar lesions; ii) patients presenting only type B scar lesions plus patients presenting all the multiple type scar lesions (AB + ABC + AC + BC); and iii) patients presenting only type C scar lesions. Figure 4 summarizes the *in vitro* parameters of the cellular immune response against *T. gondii* antigens by PBMC of patients in the context of the retinal/retinochoroidal lesions considering the three groups of type A, type C and type B plus the multiple type scar lesions. Similarly, as shown in Figure 3, considering the profiles of the frequency of high IFN- γ , IL-13 and CXCL10 production by PBMC of patients stimulated with *T. gondii* soluble antigens (STAg), we identified three possible settings of the immune response that can be associated with the type of scar lesion. As shown in Figure 4 the Platonic solid octahedron is suitable for representing the diversity of scar lesions as a function of the three settings of immune responses. On the two edges are the polar scar lesions, type A and type C. In the top is the type A scar, which is caused by the most severe type of lesion, and in the bottom is the type C scar that likely resulted from a less severe lesions type. Both types of scar lesions respectively correlate with the setting of an exacerbated and an adequately regulated Th-1 response. In the four central vertices are type B scar lesions and the multiple type scar lesions AB, AC and BC, and in the center of the octahedron is the multiple type scar lesion ABC, all of which correlate with the setting of an immune response characterized by lower levels of Th-1 (IFN- γ and CXCL10) and Th-2 (IL-13) compared with type A and C scar lesions. Taking into account this fact, it is possible that other T cells subtypes, such as Th-17, for instance, can be important in this setting. Reinforcing this supposition is the fact that we have observed recent associations of ocular toxoplasmosis and polymorphisms in the *NOD2* (nucleotide-binding oligomerization domain-containing protein 2) gene and increased IL-

17A production by PBMC under *T. gondii* antigenic stimulation in patients with chronic or active ocular toxoplasmosis [37]. This fact could explain the lower levels of IL-13, IFN- γ and CXCL10 observed for patients who present type B and multiple type scar lesions. However, we have not analyzed patients considering their type of scar lesion groups for the mentioned genetic association study due to sample size restrictions, and the genetic association found for *NOD2* refers to the presence of ocular scar lesions without precisely identifying what type of scar lesion it could be.

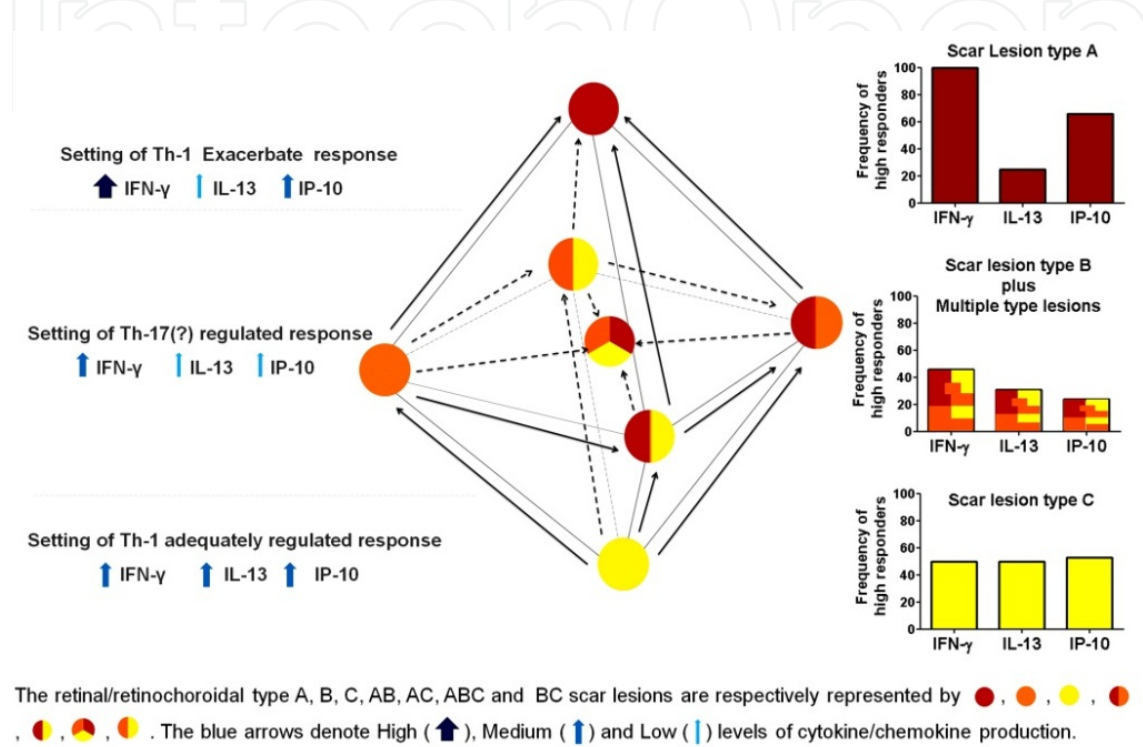


Figure 4. A Diagram representing retinal/retinochoroidal toxoplasmic scar lesions, as a function of three different settings of cellular immune response. The platonic solid octahedron in the center is suitable for representing the diversity of scar lesions as a function of the three settings of immune response. On the two edges are the type A (at the top) and type C (at the bottom) scar lesions. In the four central vertices of octahedron are represented the type B scar lesion and the multiple type scar lesions AB, AC and BC, and in the center is a multiple type scar lesion of type ABC. The dotted and solid arrows denote the possible evolution of one type of scar lesion toward another type of lesion of greater severity. Not all possibilities of evolution are shown in the picture. The frequencies of IFN- γ , IL-13 and CXCL10 (IP-10) high-responders that are shown in the graphics at right define the three settings of the immune response shown at left. Each of the three settings correlates with each of the three groups: with the scar lesions of the type A at the edge, with the scar lesion of type C at the bottom, or with the type B scar lesion plus all the multiple type lesions. The blue arrows shown in the settings denote the levels of cytokines and chemokine, as shown in the figure. The scar lesion types are represented by colored circles, as explained in the figure.

The data regarding PBMC IFN- γ , IL-13 and CXCL10 from non-infected (SN) individuals in response to *T. gondii* soluble antigens is not shown in Figure 3 and Figure 4 because none of those patients produced high levels of the cytokines or chemokine in question. In conclusion, elements from the cellular immune response, evaluated in PBMC cultures of population-based studies evidence that the morphological aspects of retinal/retinochoroidal

scar lesions can be associated with three settings of immune response in areas of high prevalence of ocular toxoplasmosis. The three settings are i) a Th-1 prominent response with high levels of IFN- γ , moderate to low levels of CXCL10 and low levels of IL-13, which relate to single type A scar lesions that are healed from the most severe toxoplasmic ocular lesions; ii) a cellular response with moderate to low levels of IFN- γ and IL-13 and low levels of CXCL10, which relate to multiple type and type B scar lesions; and iii) a sharply regulated Th-1 response with moderate to high levels of CXCL 10 and IL-13 and moderate levels of IFN- γ , which relate to type C scar lesions and could protect against tissue damage due to parasite replication within the eye.

4. Ocular toxoplasmosis in association with other infectious diseases: Could this impact the clinical presentations of toxoplasmic scar lesions in population-based surveys?

The interaction with other pathogens co-infecting *T. gondii* seropositive patients will depend on their exposure to such eventually co-prevalent parasites in the same area and on the type of immune response driven against them. The disease manifestation of *T. gondii* infected patients who become infected with HIV exemplify well this type of interaction and modification on the clinical presentation of ocular toxoplasmosis in the face of concomitant infections [3].

The scar lesions left by healed uveitis caused by *T. gondii* infections result from the previous process of uveal inflammation, which they have in common with other infectious and non-infectious agents that also cause uveitis, the possibility to compromise the iris, the ciliary body, the choroid adjacent structures of the eye including the vitreous, the retina and the optic disc. In this context, the thesis dedicated to this specific issue entitled “Infectious uveitis new developments in etiology and pathogenesis” from De Visser [38] underlines the necessity in clinical practice to have the support of laboratory data for the confirmation of a suspected diagnosis, as similar clinical features may be caused by different pathogens. The prompt identification of infectious uveitis entities is of vital importance for treatment regimens and visual prognoses of intraocular infections, and differ completely from non-infectious disorders treatments.

The thesis also reports on the similarity between retinal/retinochoroidal scar lesions left by Rubella eye infection and those left by ocular toxoplasmosis in a well-documented retrospective study. The clinical presentations of the focal retinal scars in 11 patients with intraocular proof of Rubella virus and in 17 patients with intraocular proof of *T. gondii* infection are compared. Photographic and angiographic records of the 28 patients were masked for identification and for infectious agent and were evaluated by four specialists in the field of ocular toxoplasmosis. It is reported that no differences were observed between the retinochoroidal scar lesions in Rubella virus-positive and *T. gondii*-positive patients. Retinochoroidal scar lesions were considered consistent with the diagnosis of ocular toxoplasmosis in 55% of Rubella virus-positive patients and in 88% of *T. gondii*-positive patients by at least three out of the four experts. According to the author of the thesis, two

experts considered the retinal lesions in *T. gondii*-positive patients more frequently “consistent with the diagnosis of ocular toxoplasmosis” ($P = .010$ and $P = 0.011$). There was a substantial agreement between the four experts (Fleiss’ Kappa = 0.623) [38].

We cannot rule out the fact that none of the patients have been considered as cases of ocular toxoplasmosis in the Campos dos Goytacazes surveys or in surveys from other parts of Brazil, as scar lesions left from Rubella virus infection as opposed to *T. gondii* ocular infection were present in their eyes. However, we have to take into account that Rubella was a highly prevalent virus worldwide, including in Brazil, and it is probable that if ocular lesions left by Rubella infection were as frequent as in toxoplasmosis, such lesions would already have been described as a causative entity of uveitis with epidemiologic importance. Rubella virus-caused lesions currently no longer occur due to the vaccination program against Rubella virus that was undertaken in many countries, including in Brazil where it was introduced 15 years ago. Hence, despite the clinical relevance of the similarity between the Rubella virus- caused lesions and toxoplasma retinal/retinochoroidal scar lesions, we believe that from an epidemiologic perspective, this similarity is not relevant. However, these data reinforce that the search for parameters, other than the morphological and serological, for classifying retinal/retinochoroidal scar lesions presumably caused by *T. gondii* infections should be pursued. Parameters of cellular specific immune response or the genotyping of candidate genes with the potential to differentiate between infectious agents that produce similar ocular lesions could be of help for disease management.

We have reported recently in Campos that the host immune response to *T. gondii* and *Ascaris lumbricoides* evidence co-immune modulation properties that can influence the outcome of both infections. One of the most impressive aspect of the immune response of co-infected individuals is the prominent specific secretion of IL-13 against *Ascaris* and *T. gondii* antigens by PBMC of patients who present type C scar lesions in addition to middle to high secretion levels of IFN- γ [11]. This aspect of the immune response seems to be important for the control of the parasite retinal replication and most likely for the maintenance of an equilibrated *T. gondii* load and the interconversion of tachyzoites and bradyzoites in the eye tissues. *T. gondii* and *A. lumbricoides* are both parasites that infect hosts orally; however, they elicit polar type I or type II host responses, respectively. Because both parasites are endemic in tropical areas, it is likely that co-infections with these organisms have been common throughout human evolution. If this is the case, then the host immune response mounted against both parasites may have adapted to permit such co-parasitism. The possibility of *A. lumbricoides* to produce some type of ocular scar lesion in humans seems not to be of epidemiologic importance, as we have not detected ocular scar lesions in patients seronegative to *T. gondii* and positive to *A. lumbricoides* in our surveys.

The recent adoption of massive anti-helminthic treatments for people living in poor communities as a measure of public health policy has made difficult the research on individuals co-infected with *A. lumbricoides* and *T. gondii* in Campos dos Goytacazes as well as in other parts of Brazil. For this reason, we have begun to work with an experimental model of co-infection with *T. gondii* and *Heligmosomoides polygyrus*, which has been shown as

valid model for studying parasites that evoke polar Th-1 and Th-2 in mice. *H. polygyrus* is a gastrointestinal worm, a natural parasite to mice, which evokes a polarized Th2 response in the host and blocks the type 1 immune response [39, 40]. It has been shown that a previous infection with the helminth can inhibit the development of CD8 T-cell immune response against *T. gondii*, thus compromising long-term protection against a protozoan parasite [41], which illustrates the adequacy of the model for studying the interaction between helminthic and *T. gondii* infections.

5. Immunogenetic studies: Candidate genes on ocular toxoplasmosis

Studies on genetic association in human toxoplasmosis in the past have provided evidence of associations between human leukocyte antigen (HLA) genes with the susceptibility to toxoplasmic encephalitis in AIDS patients [42] and with the outcome of congenital toxoplasmosis [43]. However, no causal relationships have been proven so far. We have conducted genetic association studies of candidate genes which potentially influence the profile of the inflammatory response against *T. gondii* [17, 18, 37] in patients with ocular toxoplasmosis by means of single nucleotide polymorphisms (SNPs) analysis. Significant associations between genetic polymorphisms and ocular disease in family-based studies have been found for Toll-like receptor-9, (*TLR-9*) [17], P2X₇ purinoceptor 7 (*P2RX7*) [18] and nucleotide-binding oligomerization domain-containing protein 2 (*NOD2*) [37] genes. These studies are currently being expanded to be replicated into population n-based investigational projects. All of these genes are related to innate immunity and have been described in processes of inflammasome assembly, which plays an important role in processing IL-1 beta and other IL-1 beta cytokine family member (IL-18, IL-33) precursors in active cytokines, promoting a pro-inflammatory response [44]. The SNPs rs352140 at *TLR-9* and rs3135499 at *NOD2* were statistically significantly associated with the manifestation of ocular toxoplasmosis [17, 37] while the absence of the SNP rs1718119 at *P2RX7* was strongly associated with protection to ocular disease manifestation [18] as we shall see in detail.

The product of the *P2RX7* belongs to the family of purinoceptors for ATP, 595 amino acids in length and highly polymorphic. The relative amount of P2X₇ function varies between human individuals because of the numerous single nucleotide polymorphisms; combinations of these polymorphisms give rise to various haplotypes that can modify P2X₇ function and result in either loss or gain of function [45]. Splice isoforms that can alter receptor expression and function and modify the signaling properties downstream of receptor have also been described [45].

The receptor functions as a ligand-gated ion channel and is responsible for ATP-dependent lysis of macrophages by means of the formation of membrane pores that are permeable to large molecules. The receptor P2X₇ functions as a pro-inflammatory receptor in cells of the monocyte/macrophage lineage and is activated by extracellular ATP released from a variety of cellular sources including platelets and damaged cells [46]. Its expression is up-regulated by IFN- γ and can lead directly to the killing of intracellular pathogens including *T. gondii* [46, 47]. P2X₇ stimulates inflammasome activation and secretion of IL-1 β [48].

Polymorphisms at the *P2RX7* have been investigated in a cooperative immunogenetic study involving patients from United State and Campos dos Goytacazes in Brazil. The studies comprised 149 child in 149 child/parent trios from North America and 60 families with 68 affected with postnatal ocular toxoplasmosis offspring in Brazil [18]. For the United states casuistic, an association between the derived C(+)G(-) allele and a second synonymous variant rs1621388 in linkage disequilibrium with it; and clinical signs of disease *per se*. were observed . Analysis of clinical sub-groups showed associations with retinal disease and brain calcifications (OR=3.0 to 4.25; 0.004<P<0.009). The association with toxoplasmic retinochoroiditis was replicated in a family-based study from Campos dos Goytacazes (60 families; 68 affected offspring), where the ancestral T(+) allele (f= 0.296) at SNP rs1718119 which contains the Ala-348 to Thr polymorphism was strongly protective (OR= 0.27; 95% CI: 0.09–0.80) [18]. This last association at SNP rs1718119 was recently replicated in a case-control study with 361 non-related individuals. The study confirmed the protective association of the T(+) allele (f= 0.296) (OR =0,3; 95% CI: 0,15-0,59 chi-square value = 13,53 *p* corrected for multiple comparisons = 0.0132) for patients with type B scar lesions [49]

The SNPs at the *P2RX7* may be associated with a gain or loss of function of the receptor. Data from Stokes and colleagues [50] showed the gain of function for *P2X₇* haplotypes carrying rs1718119 SNP, which matches our recent case-control data that confirmed a strong protection due to the ancestral allele T(+) for the *P2RX7* associated with the development of ocular disease. Therefore, it is reasonable to speculate that the ancestral allele (that do not carry the rs1718119 SNP and do not contain the Ala-348 to Thr polymorphism) would help to protect against an exacerbated immune response as a consequence of the gain of function conferred by the rs1718119 SNP, which would lead to an immune response with high levels of pro-inflammatory cytokines, such as IL-1 β and IFN- γ , and could contribute to retinal tissue damage. Our data provides evidence that the Th-1 specific immune response is centered in the IFN- γ secretion by PBMC of patients with the different types of retinal/retinochoroidal scar lesions, which also reinforces the supposition that an exacerbated immune response in an environment with prolonged inflammatory mediators can contribute to retinal/retinochoroidal damage.

Albuquerque and colleagues described an association between the IFN- γ +874T/A gene polymorphism with toxoplasmic retinochoroiditis susceptibility [51]. This study is related to the Santa Rita (Barra Mansa) casuistic, as described previously in this chapter. The authors found that AA homozygous individuals showed a 1.62-fold higher risk than other genotypes (AT and TT) for developing toxoplasmic retinochoroiditis [51]. Regarding the IFN- γ +874T/A gene polymorphism, it was demonstrated that the polymorphism is linked to high and low producer phenotypes [27, 28] and the genotype AA is associated with the phenotype for low IFN- γ capacity of production in contrast to the AT or TT genotypes that are linked with a phenotype for a middle and high IFN- γ capacity of production respectively [29]. The T to A polymorphism coincides with a putative NF-kappa B binding site that may have functional consequences for the transcription of the human IFN- γ gene [27]. In the Santa Rita study, the IFN- γ production by PMBC of the patients was not reported. However,

considering that this cytokine is a very important to parasite control replication, the patients presenting the AA genotype for the IFN- γ +874 T/A polymorphism likely have a similar profile of specific cellular immune response with that observed for the group that presented lesions of types B and BC, as shown in Figure 3, and multiple type scar lesions, as shown in Figure 4. Namely, they would tend to produce moderate to low levels of IFN- γ and IL-13 and low levels of CXCL 10, which most likely causes an immune response that is not sufficient to efficiently prevent/control parasite proliferation; as a consequence, retinal/retinochoroidal tissues damage occurs. It is important to note that to determine the frequency of the genotype AA among individuals grouped by the type of scar lesions, in association with phenotypic parameters of the immune response, like cytokines and chemokines, would be of value to improve our understanding of the possible pathological mechanisms that occur in the different types of scar lesions in ocular toxoplasmosis.

Other reports in the literature have described genetic association studies of cytokines with toxoplasmic ocular diseases in Brazil. However, they describe small casuistic related to patients from ophthalmologic reference centers and do not find significant associations [52-54], although one suggests the association of polymorphism at IL-1 alfa gene and the recurrence of ocular toxoplasmosis [54].

6. Conclusion

We have presented data related to a decade of research on a hyperendemic area to *T. gondii* infection, considering aspects linked to the clinical presentation of ocular disease in a population exposed to high risk of waterborne toxoplasmosis, the profile of *in vitro* specific immune response in the function of the disease's clinical presentation, and genetic association studies with candidate genes in ocular toxoplasmosis.

It is important to consider the conclusions and advances that can be derived based on the study of PBMC from patients who exhibit different clinical presentations of ocular toxoplasmosis, stimulated *in vitro* with parasite antigens. One can argue that the study of the specific responses of PBMC *in vitro* does not reflect the eye's immune-privileged environment, for instance. However, the study of PBMC represents is a non-invasive approach that is adequate for population-based studies such that in the genomic medicine era, it will improve our understanding of relevant gene response, i.e., their activation and regulation in inflammatory process within the eye. The associations between phenotype and genotype data from cohorts accelerate our understanding of the molecular mechanisms involved in the disease's pathology. Our data on P2X₇ genotyping genes together with the PBMC immune profile illustrate this aspect. Namely, our initial hypothesis on an exacerbation of the inflammatory response with high levels of pro-inflammatory cytokines, especially IFN- γ secretion, concomitant with relatively low levels of anti-inflammatory cytokines like IL-13 secretion in response to parasite antigens, which was identified by *in vitro* PBMC stimulation experiments and could contribute to the development of ocular disease, is reinforced by the findings on P2RX7 genotyping at the SNP rs1718119. This data showed that the ancestral allele is highly protective for the development of ocular disease. The SNP rs1718119 has been

demonstrated to confer a gain of function to the receptor P2X₇, imbuing it with a more vigorous pro-inflammatory response. Therefore, the presence of the ancestral allele would protect the eye tissues from harmful exacerbations of immune responses, which corroborates our previous interpretations from PBMC experiments, as described above. Furthermore, the similarity of immunologic parameters between the mouse model and human infection, such as that observed for IFN- γ and CXCL10, motivates the development of innovative protocols using PBMC to access the gene response at the patient level. This approach is both feasible and suitable. For instance, in a given patient, it is possible to study PBMC to access the expression of the P2X₇ protein, the product of the same *P2RX7* that is expressed in retinal epithelial cells. Concerning the relevance of this approach, it is worth mentioning that primary cultures of human retinal epithelial cells that express P2X₇ protein [55] are responsive to IFN- γ stimulation leading to *T. gondii* elimination in a pathway independent of nitric oxide (NO) [36].

The interpretations of our data on PBMC *in vitro* stimulation with *T. gondii* antigens together with the candidate genes genotyping relevant to the innate immune response, targeting the parasite, contribute to a better understanding of the immunological pathogenesis of infectious diseases that has been recently achieved. However, many issues remain to be addressed before the clinical exploitation of these findings can be realized. The function of these elements and their interplay with one another and with other components in the immune system are complex, and it is crucial to determine the balance between their beneficial and pathological roles in ocular toxoplasmosis.

Finally, the immune responses of patients from population-based studies who exhibit diverse scar lesions that are likely caused by *T. gondii* infection illustrate the multifactorial nature of ocular toxoplasmosis. Beyond host genetics and interactions with other pathogens that we have mentioned in this chapter, there are many other factors, such as environmental questions, the age at which individuals are infected, the parasitic load in the host, and the parasite genetic background that are equally important for disease manifestation. Therefore, all of these aspects, in addition to those not mentioned here or unknown, that characterize the multifactorial nature of ocular toxoplasmosis cannot be considered separately, and their interaction in and with the host will be expressed by one single feature that represents the profile of the immune response mounted by the host. The immune response will be subject to influences by every factor and will ultimately impact the different clinical presentation of ocular toxoplasmosis.

Author details

Lílian M.G. Bahia-Oliveira*, Alba L.P. Rangel, Marcela S.B. Boechat, Bianca M. Mangiavacchi**, Livia M. Martins**, Francielle B. Ferraz**, Maycon B. Almeida and Flavia P. Vieira

Laboratório de Biologia do Reconhecer (LBR) Centro de Biociências e Biotecnologia (CBB)
Universidade Estadual do Norte Fluminense Darcy Ribeiro (UENF), Campos dos Goytacazes, RJ, Brazil

* Corresponding Author

** Equal Contribution

Elisa M. Waked Peixoto and Ricardo G. Peixe

Laboratório de Biologia do Reconhecer (LBR) Centro de Biociências e Biotecnologia (CBB)

Universidade Estadual do Norte Fluminense Darcy Ribeiro (UENF), Campos dos Goytacazes, RJ, Brazil

Faculdade de Medicina de Campos, Campos dos Goytacazes, RJ, Brazil

Acknowledgement

The following grants supported this work: FAPERJ E-26/112.045/2008; E-26/110.869/2009; E26/111.131/2010; E-26/111.305/2010

We thank Jennifer Blackwell, Ricardo Gazzinelli and Miriam Dutra for their partnership on genetic studies and JP Dubey for research support. We are thank to Fernando Orefice and Wesley Campos for their participation on the fundoscopic examinations of patients in Campos dos Goytacazes and Liliani Souza Elias, Fernando Cesar Lopes and Flavia Rangel for their technical support. We thank Dr. Daíse Malheiros Meira, for her brilliant and original suggestion to propose a classification of the retinal/retinochoroidal scars in terms of the degree of retinal tissues destruction.

7. References

- [1] Bahia-Oliveira LM, Jones JL, Azevedo-Silva J, Alves CC, Orefice F, Addiss DG. Highly endemic, waterborne toxoplasmosis in north Rio de Janeiro state, Brazil. *Emerg Infect Dis.* 2003;9(1):55-62. Epub 2003/01/21.
- [2] Gilbert RE, Stanford MR. Is ocular toxoplasmosis caused by prenatal or postnatal infection? *The British journal of ophthalmology.* 2000;84(2):224-6. Epub 2000/02/03.
- [3] Holland GN, O'Connor GR, Belfort Junior R, al. E. *Toxoplasmosis.* St. Louis: Mosby; 1996.
- [4] Glasner PD, Silveira C, Kruszon-Moran D, Martins MC, Burnier Junior M, Silveira S, et al. An unusually high prevalence of ocular toxoplasmosis in southern Brazil. *American journal of ophthalmology.* 1992;114(2):136-44. Epub 1992/08/15.
- [5] de Abreu MT, Boni D, Belfort Junior R, Passos A, Garcia AR, Muccioli C, et al. Toxoplasmose ocular em Venda Nova do Imigrante, ES, Brasil. *Arquivos Brasileiros de Oftalmologia.* 1998;61:540-5.
- [6] Garcia JL, Navarro IT, Ogawa L, de Oliveira RC, Kobilka E. [Seroprevalence, epidemiology and ocular evaluation of human toxoplasmosis in the rural zone Janguapita (Parana) Brazil]. *Revista panamericana de salud publica = Pan American journal of public health.* 1999;6(3):157-63. Epub 1999/10/12. Soroprevalencia, epidemiologia e avaliacao ocular da toxoplasmose humana na zona rural de Jaguapita (Parana), Brasil.
- [7] Bahia Oliveira LM, Wilken de Abreu AM, Azevedo-Silva J, Orefice F. Toxoplamosis in southeastern Brazil: an alarming situation of highly endemic acquired and congenital

- infection. Recent trends in research on congenital toxoplasmosis: *International Journal for Parasitology*; 2001. p. 133-6.
- [8] Portela RW, Bethony J, Costa MI, Gazzinelli A, Vitor RW, Hermeto FM, et al. A multihousehold study reveals a positive correlation between age, severity of ocular toxoplasmosis, and levels of glycoinositolphospholipid-specific immunoglobulin A. *J Infect Dis.* 2004;190(1):175-83. Epub 2004/06/15.
 - [9] Aleixo AL, Benchimol EI, Neves Ede S, Silva CS, Coura LC, Amendoeira MR. [Frequency of lesions suggestive of ocular toxoplasmosis among a rural population in the State of Rio de Janeiro]. *Revista da Sociedade Brasileira de Medicina Tropical.* 2009;42(2):165-9. Epub 2009/05/19. Frequencia de lesões sugestivas de toxoplasmose ocular em uma população rural do Estado do Rio de Janeiro.
 - [10] Orefice F, Bahia Oliveira LM. Toxoplasmose. In: Médica C, editor. *Uveíte Clínica e cirúrgica.* 2 ed. Rio de Janeiro 2005.
 - [11] Bahia-Oliveira LM, Silva JA, Peixoto-Rangel AL, Boechat MS, Oliveira AM, Massara CL, et al. Host immune response to *Toxoplasma gondii* and *Ascaris lumbricoides* in a highly endemic area: evidence of parasite co-immunomodulation properties influencing the outcome of both infections. *Mem Inst Oswaldo Cruz.* 2009;104(2):273-80. Epub 2009/05/12.
 - [12] Smith JR, Cunningham ET, Jr. Atypical presentations of ocular toxoplasmosis. *Current opinion in ophthalmology.* 2002;13(6):387-92. Epub 2002/11/21.
 - [13] Silveira C, Belfort R, Jr., Muccioli C, Abreu MT, Martins MC, Victora C, et al. A follow-up study of *Toxoplasma gondii* infection in southern Brazil. *American journal of ophthalmology.* 2001;131(3):351-4. Epub 2001/03/10.
 - [14] Sibley LD, Boothroyd JC. Virulent strains of *Toxoplasma gondii* comprise a single clonal lineage. *Nature.* 1992;359(6390):82-5. Epub 1992/09/03.
 - [15] Khan A, Taylor S, Su C, Mackey AJ, Boyle J, Cole R, et al. Composite genome map and recombination parameters derived from three archetypal lineages of *Toxoplasma gondii*. *Nucleic acids research.* 2005;33(9):2980-92. Epub 2005/05/25.
 - [16] Peixoto-Rangel AL. *Investigação de Fatores Imunogenéticos Associados à Manifestação de Retinocoroidites Toxoplásmicas em Área Altamente Endêmica para Toxoplasmose.* [Tese de Doutorado] Campos dos Goytacazes: Universidade Estadual do Norte Fluminense Darcy Ribeiro; 2008.
 - [17] Peixoto-Rangel AL, Miller EN, Castellucci L, Jamieson SE, Peixe RG, Elias LD, et al. Candidate gene analysis of ocular toxoplasmosis in Brazil: evidence for a role for toll-like receptor 9 (TLR9). *Mem I Oswaldo Cruz.* 2009;104(8):1187-90.
 - [18] Jamieson SE, Peixoto-Rangel AL, Hargrave AC, de Roubaix LA, Mui EJ, Boulter NR, et al. Evidence for associations between the purinergic receptor P2X(7) (P2RX7) and toxoplasmosis. *Genes Immun.* 2010;11(5):374-83.
 - [19] Kee C, Koo H, Ji Y, Kim S. Effect of optic disc size or age on evaluation of optic disc variables. *The British journal of ophthalmology.* 1997;81(12):1046-9. Epub 1998/03/14.
 - [20] Holland GN. Ocular toxoplasmosis: the influence of patient age. *Mem Inst Oswaldo Cruz.* 2009;104(2):351-7. Epub 2009/05/12.

- [21] Azevedo-Silva J. Avaliação da Resposta Imunológica contra Antígenos de *Toxoplasma gondii* e *Ascaris lumbricoides* em Pacientes Residentes em Áreas Co-endêmicas para Ambos os Parasitas em Campos dos Goytacazes/RJ. [Dissertação de Mestrado] Campos dos Goytacazes: Universidade Estadual do Norte Fluminense Darcy Ribeiro; 2001.
- [22] Boechat MSB. Perfil de Quimiocinas em Indivíduos Portadores de Lesão Ocular Decorrente da Infecção pelo *Toxoplasma gondii*. [Dissertação de Mestrado] Campos dos Goytacazes: Universidade Estadual do Norte Fluminense Darcy Ribeiro; 2008.
- [23] Garweg JG, Candolfi E. Immunopathology in ocular toxoplasmosis: facts and clues. *Mem Inst Oswaldo Cruz*. 2009;104(2):211-20. Epub 2009/05/12.
- [24] Lahmar I, Abou-Bacar A, Abdelrahman T, Guinard M, Babba H, Ben Yahia S, et al. Cytokine profiles in toxoplasmic and viral uveitis. *J Infect Dis*. 2009;199(8):1239-49. Epub 2009/03/24.
- [25] Suzuki Y, Orellana MA, Schreiber RD, Remington JS. Interferon-gamma: the major mediator of resistance against *Toxoplasma gondii*. *Science*. 1988;240(4851):516-8. Epub 1988/04/22.
- [26] Norose K, Kikumura A, Luster AD, Hunter CA, Harris TH. CXCL10 is required to maintain T-cell populations and to control parasite replication during chronic ocular toxoplasmosis. *Investigative ophthalmology & visual science*. 2011;52(1):389-98. Epub 2010/09/03.
- [27] Pravica V, Perrey C, Stevens A, Lee JH, Hutchinson IV. A single nucleotide polymorphism in the first intron of the human IFN-gamma gene: absolute correlation with a polymorphic CA microsatellite marker of high IFN-gamma production. *Human immunology*. 2000;61(9):863-6. Epub 2000/10/29.
- [28] Gomes JAS, Bahia-Oliveira LMG, Rocha MOC, Martins-Filho OA, Gazzinelli G, Correa-Oliveira R. Evidence that development of severe cardiomyopathy in human Chagas' disease is due to a thl-specific immune response. *Infect Immun*. 2003;71(3):1185-93.
- [29] Ben Selma W, Harizi H, Bougmiza I, Hannachi N, Ben Kahla I, Zaieni R, et al. Interferon gamma +874T/A polymorphism is associated with susceptibility to active pulmonary tuberculosis development in Tunisian patients. *DNA and cell biology*. 2011;30(6):379-87. Epub 2011/02/22.
- [30] Lemaitre C, Thillaye-Goldenberg B, Naud MC, de Kozak Y. The effects of intraocular injection of interleukin-13 on endotoxin-induced uveitis in rats. *Investigative ophthalmology & visual science*. 2001;42(9):2022-30. Epub 2001/08/02.
- [31] Roberge FG, de Smet MD, Benichou J, Kriete MF, Raber J, Hakimi J. Treatment of uveitis with recombinant human interleukin-13. *The British journal of ophthalmology*. 1998;82(10):1195-8. Epub 1999/01/30.
- [32] Pfefferkorn ER. Interferon gamma blocks the growth of *Toxoplasma gondii* in human fibroblasts by inducing the host cells to degrade tryptophan. *Proceedings of the National Academy of Sciences of the United States of America*. 1984;81(3):908-12. Epub 1984/02/01.
- [33] Gazzinelli RT, Eltoun I, Wynn TA, Sher A. Acute cerebral toxoplasmosis is induced by in vivo neutralization of TNF-alpha and correlates with the down-regulated expression

- of inducible nitric oxide synthase and other markers of macrophage activation. *Journal of immunology*. 1993;151(7):3672-81. Epub 1993/10/01.
- [34] Halonen SK, Weiss LM. Investigation into the mechanism of gamma interferon-mediated inhibition of *Toxoplasma gondii* in murine astrocytes. *Infect Immun*. 2000;68(6):3426-30. Epub 2000/05/19.
- [35] Norose K, Mun HS, Aosai F, Chen M, Piao LX, Kobayashi M, et al. IFN-gamma-regulated *Toxoplasma gondii* distribution and load in the murine eye. *Investigative ophthalmology & visual science*. 2003;44(10):4375-81. Epub 2003/09/26.
- [36] Nagineni CN, Pardhasaradhi K, Martins MC, Detrick B, Hooks JJ. Mechanisms of interferon-induced inhibition of *Toxoplasma gondii* replication in human retinal pigment epithelial cells. *Infect Immun*. 1996;64(10):4188-96. Epub 1996/10/01.
- [37] Dutra MS, Béla SR, Peixoto-Rangel AL, Fakiola M, Gazzinelli A, Quites HF, et al. Association of a NOD2 gene polymorphism and responsiveness of Th17 lymphocytes with ocular toxoplasmosis. *The Journal of Infectious Diseases* (accepted for publication).
- [38] de Visser L. Infectious uveitis: New developments in etiology and pathogenesis. [PhD Thesis] Netherlands: Utrecht University 2009.
- [39] Svetic A, Madden KB, Zhou XD, Lu P, Katona IM, Finkelman FD, et al. A primary intestinal helminthic infection rapidly induces a gut-associated elevation of Th2-associated cytokines and IL-3. *Journal of immunology*. 1993;150(8 Pt 1):3434-41. Epub 1993/04/15.
- [40] Setiawan T, Metwali A, Blum AM, Ince MN, Urban JF, Jr., Elliott DE, et al. *Heligmosomoides polygyrus* promotes regulatory T-cell cytokine production in the murine normal distal intestine. *Infect Immun*. 2007;75(9):4655-63. Epub 2007/07/04.
- [41] Khan IA, Hakak R, Eberle K, Sayles P, Weiss LM, Urban JF, Jr. Coinfection with *Heligmosomoides polygyrus* fails to establish CD8+ T-cell immunity against *Toxoplasma gondii*. *Infect Immun*. 2008;76(3):1305-13. Epub 2008/01/16.
- [42] Suzuki Y, Wong SY, Grumet FC, Fessel J, Montoya JG, Zolopa AR, et al. Evidence for genetic regulation of susceptibility to toxoplasmic encephalitis in AIDS patients. *J Infect Dis*. 1996;173(1):265-8. Epub 1996/01/01.
- [43] Mack DG, Johnson JJ, Roberts F, Roberts CW, Estes RG, David C, et al. HLA-class II genes modify outcome of *Toxoplasma gondii* infection. *International journal for parasitology*. 1999;29(9):1351-8. Epub 1999/12/01.
- [44] Stutz A, Golenbock DT, Latz E. Inflammasomes: too big to miss. *The Journal of clinical investigation*. 2009;119(12):3502-11. Epub 2009/12/04.
- [45] Sluyter R, Stokes L. Significance of P2X7 receptor variants to human health and disease. *Recent patents on DNA & gene sequences*. 2011;5(1):41-54. Epub 2011/02/10.
- [46] Correa G, Marques da Silva C, de Abreu Moreira-Souza AC, Vommaro RC, Coutinho-Silva R. Activation of the P2X(7) receptor triggers the elimination of *Toxoplasma gondii* tachyzoites from infected macrophages. *Microbes and infection / Institut Pasteur*. 2010;12(6):497-504. Epub 2010/03/20.
- [47] Lees MP, Fuller SJ, McLeod R, Boulter NR, Miller CM, Zakrzewski AM, et al. P2X7 receptor-mediated killing of an intracellular parasite, *Toxoplasma gondii*, by human

- and murine macrophages. *Journal of immunology*. 2010;184(12):7040-6. Epub 2010/05/22.
- [48] Qu Y, Franchi L, Nunez G, Dubyak GR. Nonclassical IL-1 beta secretion stimulated by P2X7 receptors is dependent on inflammasome activation and correlated with exosome release in murine macrophages. *Journal of immunology*. 2007;179(3):1913-25. Epub 2007/07/21.
- [49] Ferraz FB. Estudo caso-controle e frequências alélicas de SNPs de P2RX7 em coorte de indivíduos com lesão ocular toxoplásmica no norte do estado do Rio de Janeiro. [Dissertação de mestrado] Campos dos Goytacazes: Universidade Estadual do Norte Fluminense Darcy Ribeiro; 2012.
- [50] Stokes L, Fuller SJ, Sluyter R, Skarratt KK, Gu BJ, Wiley JS. Two haplotypes of the P2X(7) receptor containing the Ala-348 to Thr polymorphism exhibit a gain-of-function effect and enhanced interleukin-1beta secretion. *FASEB journal : official publication of the Federation of American Societies for Experimental Biology*. 2010;24(8):2916-27. Epub 2010/04/03.
- [51] Albuquerque MC, Aleixo AL, Benchimol EI, Leandro AC, das Neves LB, Vicente RT, et al. The IFN-gamma +874T/A gene polymorphism is associated with retinochoroiditis toxoplasmosis susceptibility. *Mem Inst Oswaldo Cruz*. 2009;104(3):451-5. Epub 2009/06/24.
- [52] Cordeiro CA, Moreira PR, Costa GC, Dutra WO, Campos WR, Orefice F, et al. TNF-alpha gene polymorphism (-308G/A) and toxoplasmic retinochoroiditis. *The British journal of ophthalmology*. 2008;92(7):986-8. Epub 2008/06/26.
- [53] Cordeiro CA, Moreira PR, Costa GC, Dutra WO, Campos WR, Orefice F, et al. Interleukin-1 gene polymorphisms and toxoplasmic retinochoroiditis. *Molecular vision*. 2008;14:1845-9. Epub 2008/10/23.
- [54] Cordeiro CA, Moreira PR, Andrade MS, Dutra WO, Campos WR, Orefice F, et al. Interleukin-10 gene polymorphism (-1082G/A) is associated with toxoplasmic retinochoroiditis. *Investigative ophthalmology & visual science*. 2008;49(5):1979-82. Epub 2008/04/26.
- [55] Yang D, Elner SG, Clark AJ, Hughes BA, Petty HR, Elner VM. Activation of P2X receptors induces apoptosis in human retinal pigment epithelium. *Investigative ophthalmology & visual science*. 2011;52(3):1522-30. Epub 2010/11/13.
- [56] Melamed J. Contributions to the history of ocular toxoplasmosis in Southern Brazil. *Memórias do Instituto Oswaldo Cruz*. 2009;104(2):358-63.
- [57] Dubey J, Gennari S, Lago E, Su C, Jones J. Toxoplasmosis in humans and animals in Brazil: high prevalence, high burden of disease, and epidemiology. *Parasitology*. 2012. doi:10.1017/S0031182012000765