

We are IntechOpen, the world's leading publisher of Open Access books Built by scientists, for scientists

6,900

Open access books available

186,000

International authors and editors

200M

Downloads

Our authors are among the

154

Countries delivered to

TOP 1%

most cited scientists

12.2%

Contributors from top 500 universities



WEB OF SCIENCE™

Selection of our books indexed in the Book Citation Index
in Web of Science™ Core Collection (BKCI)

Interested in publishing with us?
Contact book.department@intechopen.com

Numbers displayed above are based on latest data collected.
For more information visit www.intechopen.com



Vascular Access for Hemodialysis

Ivica Maleta, Božidar Vujičić, Iva Mesaroš Devčić and Sanjin Rački

Additional information is available at the end of the chapter

<http://dx.doi.org/10.5772/48787>

1. Introduction

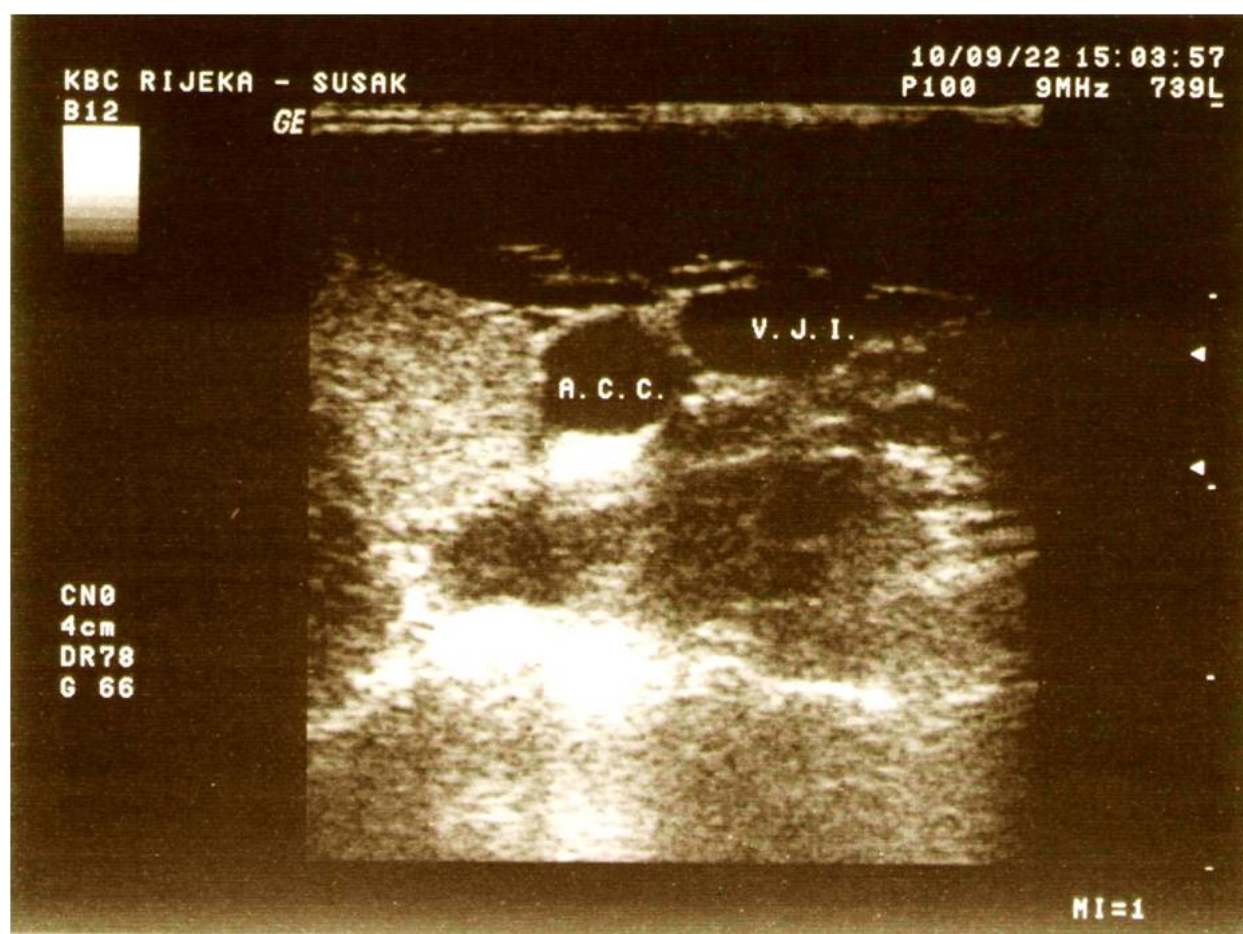
Patients with acute kidney failure (AKF) and chronic kidney failure (CKF) require an appropriate vascular access for hemodialysis [1]. Vascular access is needed to allow blood flow through an extracorporeal circulation system with a blood pump connected to a hemodialysis monitor driving the blood through a dialysis filter (dialysator). Satisfactory levels of blood flow range between 300 and 400 mL/min.

The need for vascular access in patients with kidney failure may be temporary or permanent [2].

2. Temporary hemodialysis vascular access

Temporary hemodialysis access is required in patients scheduled to start hemodialysis treatment in several days to six months. It is mostly needed in patients with AKF of various etiology [3]. For that purpose, a hemodialysis catheter is introduced percutaneously into one of the large central veins (the internal jugular, subclavian or femoral veins) under local anesthesia. Catheters are made of different materials (polyurethane, silicon, and so on). Single-lumen catheters are used less often than double-lumen catheters of different lengths (usually 15 to 24 cm, rarely of other lengths – shorter are for pediatric use, and longer for permanent use) and 11.5-14 F in diameter. They are available in two configurations - straight and curved. A catheter is introduced after the puncture of an appropriate vein performed either in a “blinded” fashion or under ultrasound control [4]. Before the venipuncture, ultrasound should be used to visualize the relative anatomic position of the internal jugular vein and common carotid artery and determine the possible direction of puncture angle and depth in order to avoid the unwanted puncture of the common carotid artery (Figure 1).

After the catheter placement, a control chest x-ray is recommended to confirm the correct position of the catheter and exclude possible complications (Figure 2).



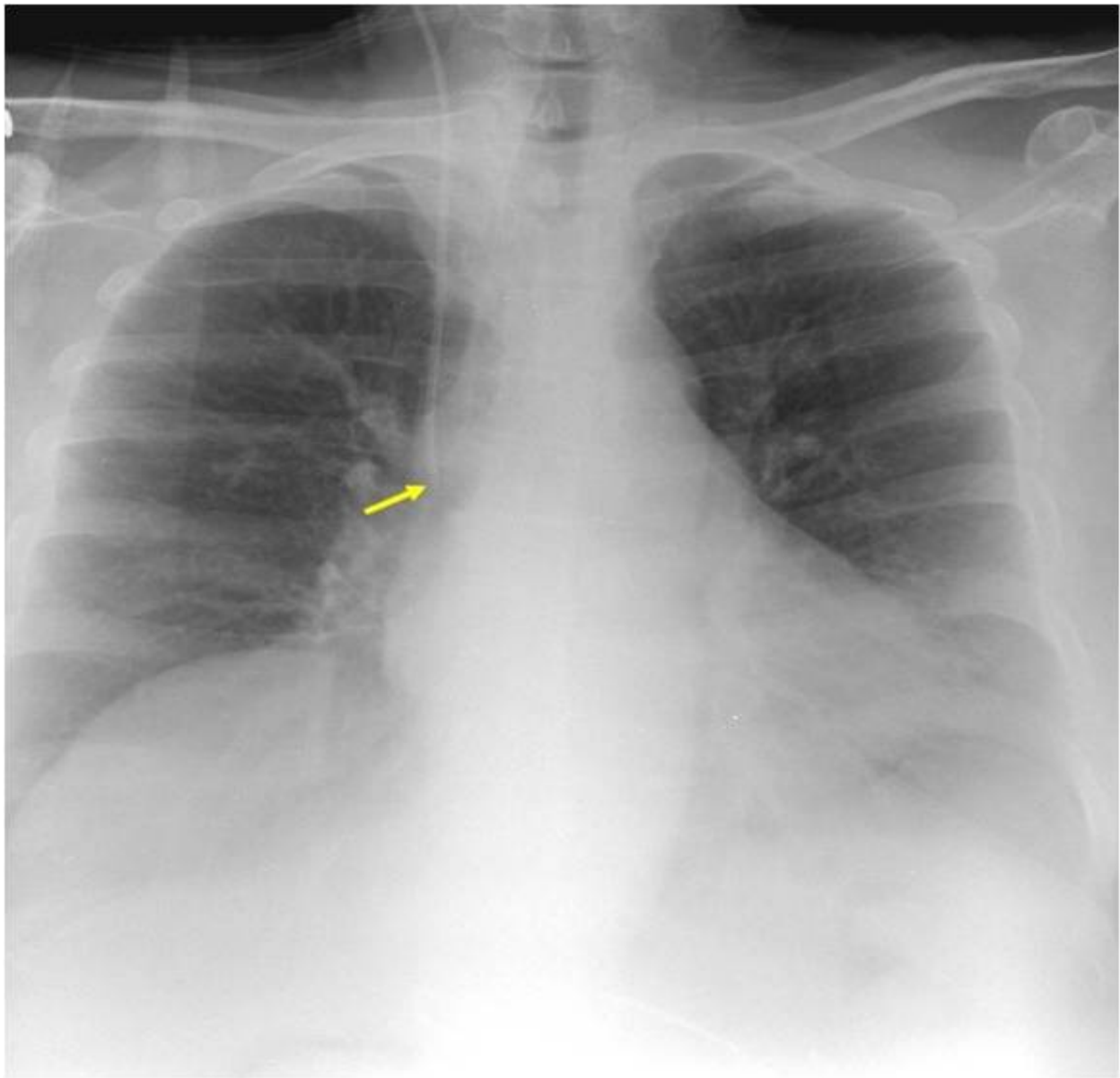
Source: Archive of the Department of Nephrology and Dialysis, University Hospital Rijeka

Figure 1. Ultrasonographic assesment in the B-mode of the internal jugular vein (V.J.I) and common carotid artery (A.C.C.).

Temporary vascular access for hemodialysis is sometimes indicated in patients with CKF stage 5, or end-stage kidney disease (ESKD), who are on regular dialysis, in cases of inadequate function of arteriovenous fistula (AV) or AV graft due to stenosis or thrombosis, and in new hemodialysis patients in whom AV fistula has not been created in a timely manner [5].

3. Permanent hemodialysis vascular access

Permanent vascular access is usually required in patients with CKF stage 4 because of permanent HD treatment [6]. For permanent vascular access, AV shunt (out of clinical use), AV fistula, AF graft or tunneled or non-tunneled hemodialysis catheters may be used. During the pre-dialysis preparation or pre-dialysis education program, the patients should be informed about possible ESKG treatment options, which include HD, peritoneal dialysis (PD), and kidney transplantation.



Source: Archive of the Department of Nephrology and Dialysis, University Hospital Rijeka

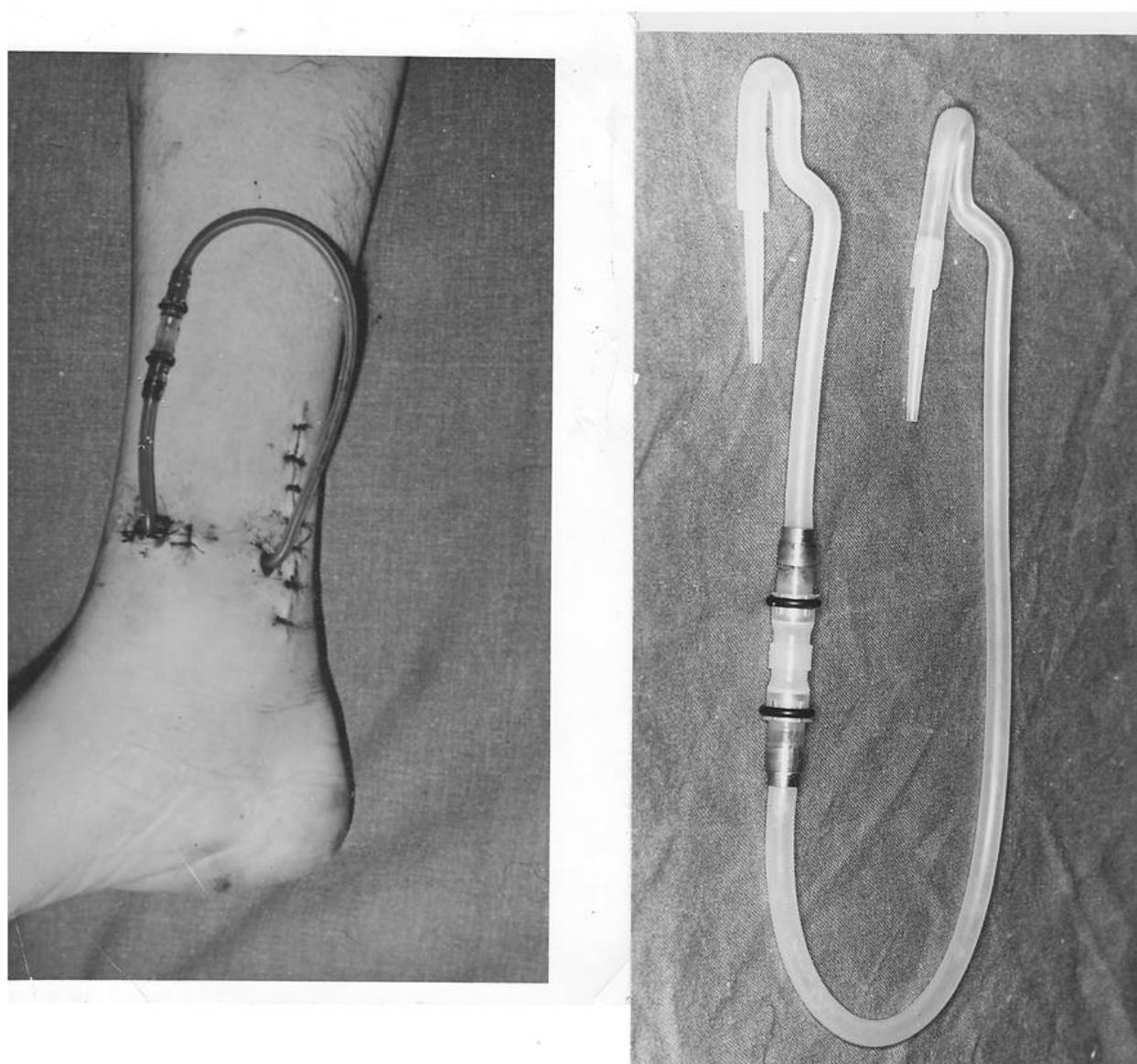
Figure 2. Chest radiogram showing correct position of the jugular catheter in the right atrium.

3.1. Arteriovenous shunt

External AV shunt belongs to history. It was used between 1960 and 1965, before the first AV fistula was created (Kenneth C. Apple), that is, radiocephalic (Brescia–Cimino 1966) (Figure 3).

3.2. Arteriovenous fistula

In patients on chronic hemodialysis, vascular access should be created in a timely fashion. Native AV fistula is the gold standard and the most frequently used type of vascular access in these patients [2]. After examining the patient in CKF stage 4 (GFR 30-15 mL/min/1.73 m²), a



Source: Archive of the Department of Nephrology and Dialysis, University Hospital Rijeka

Figure 3. Quinton-Scribner AV shunt

vascular surgeon makes an assessment of the patient's vascular system in order to plan for the AV fistula construction. In case of progressive kidney failure and/or diabetes mellitus, AV fistula should be created earlier [7]. Before choosing the type of vascular access, peripheral blood vessels (arteries and veins) should be evaluated by clinical examination and ultrasound. If diameters and walls of the blood vessels are satisfactory, AV fistula may be created. It is usually done on the non-dominant arm between the radial artery and cephalic vein as distally as possible. AV fistula is a surgically created subcutaneous anastomosis between an artery and a vein (Figure 4) and it matures by venous dilatation and arterialisation of the vein.

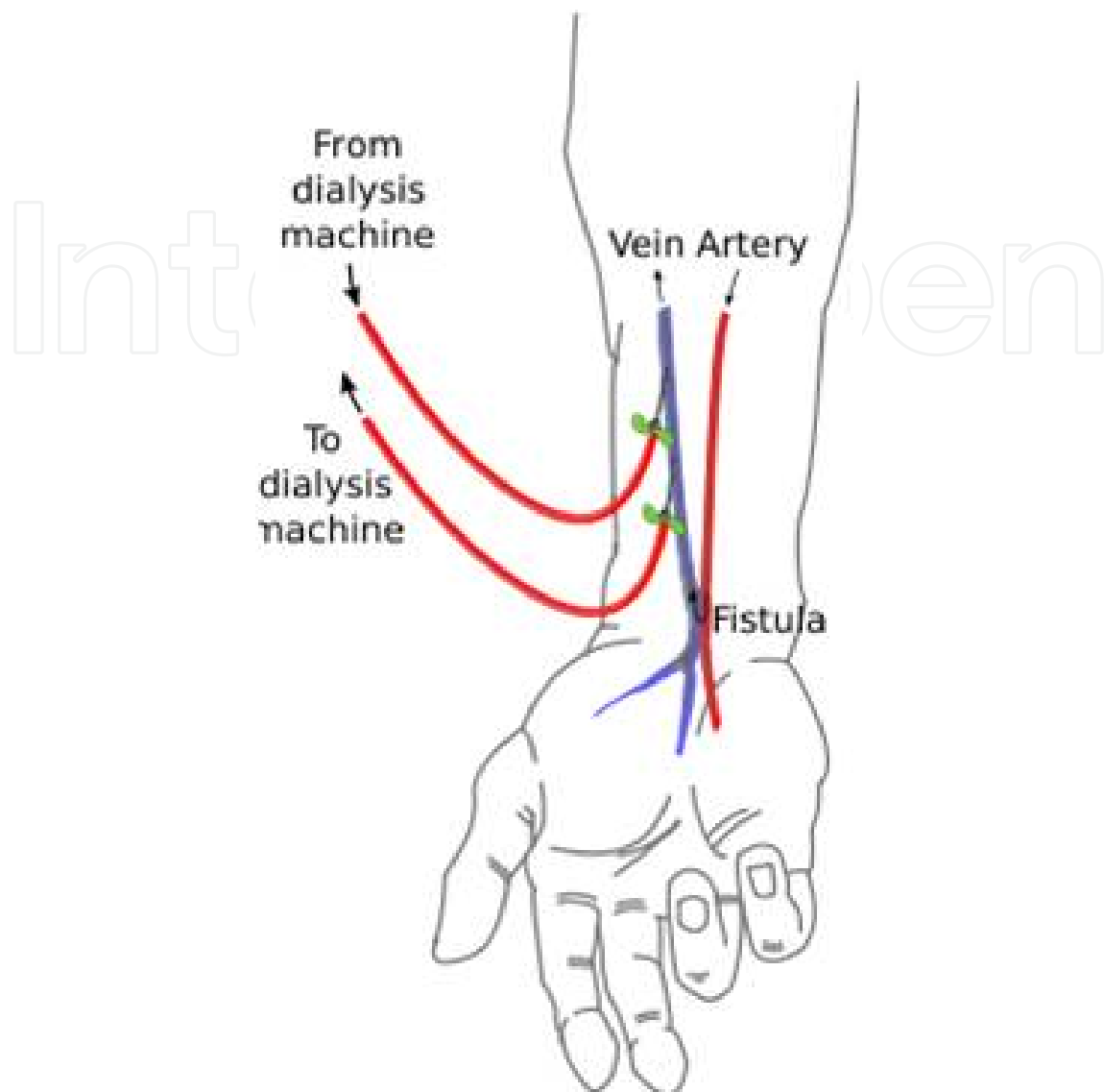


Figure 4. Typical arteriovenous fistula (Brescia-Cimino)

The AV anastomosis redirects arterial blood flow into the vein, which then becomes dilated due to new hemodynamic conditions. Over time, the lumen of the vein widens, the venous blood flow increases, and the vein becomes suitable for puncture and hemodialysis usually after three to five weeks [8].

There two most common types of anastomosis. One is “side-to-side” (a standard anastomosis described by Brescia), where an artery and its neighboring vein are cut longitudinally and sewn or stapled together [9]. This type of anastomosis may lead to the venous hyperemia of the arm (Figure 5).

The other is “end-vein to side-artery” anastomosis, where the cephalic vein is completely severed, its distal part toward the hand is ligated, and the proximal part is sewn to the side of the relevant artery (Figure 6).

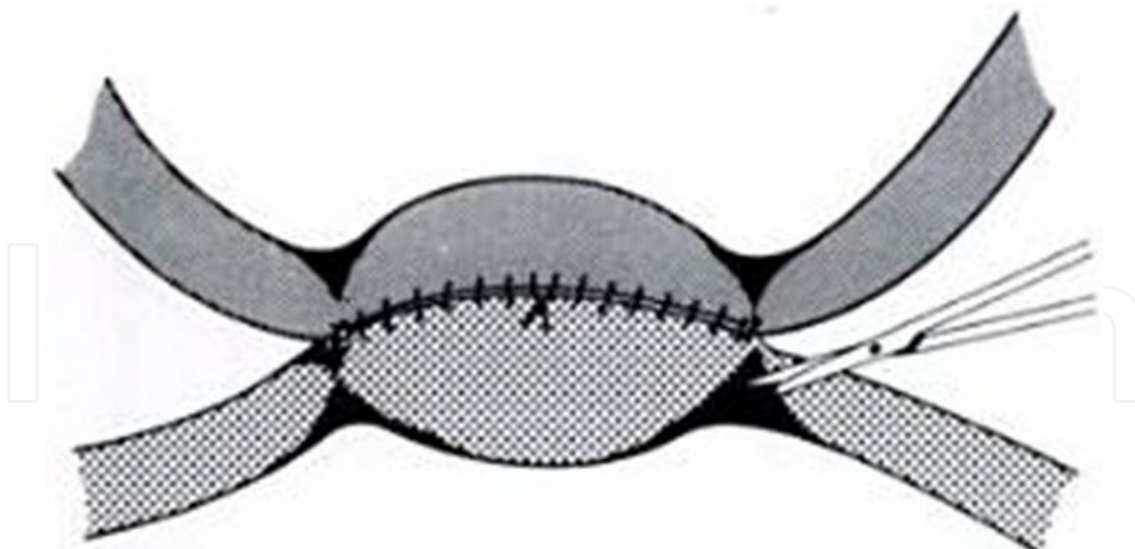


Figure 5. "Side to side" anastomosis of the AV fistula

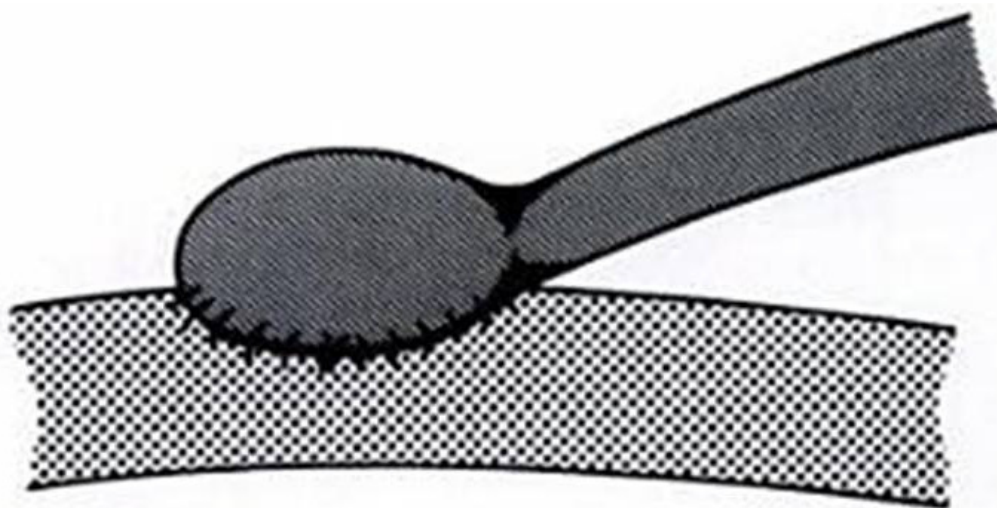


Figure 6. "End to side" anastomosis of the AV fistula

If AV fistula cannot be created at the usual site, i.e., the wrist, it may be created proximally in the middle part of the forearm or cubital fossa. The fistula may also be created between the ulnar artery and the basilic vein.

3.3. AV fistula complications

3.3.1. Thrombosis

AV fistula thrombosis is characterized by a complete cessation of blood flow through the venous part of the AF fistula proximal to the AV anastomosis due to a thrombus, which may develop in any part of the vein (from the anastomosis to the confluence of the subclavian vein into the superior vena cava). Thrombosis may be diagnosed by a standard physical examination. The characteristic sign is the absence of the typical thrill of the fistula on palpation. In some cases, the thrombus in the vein may be palpable. Arterial pulsations may

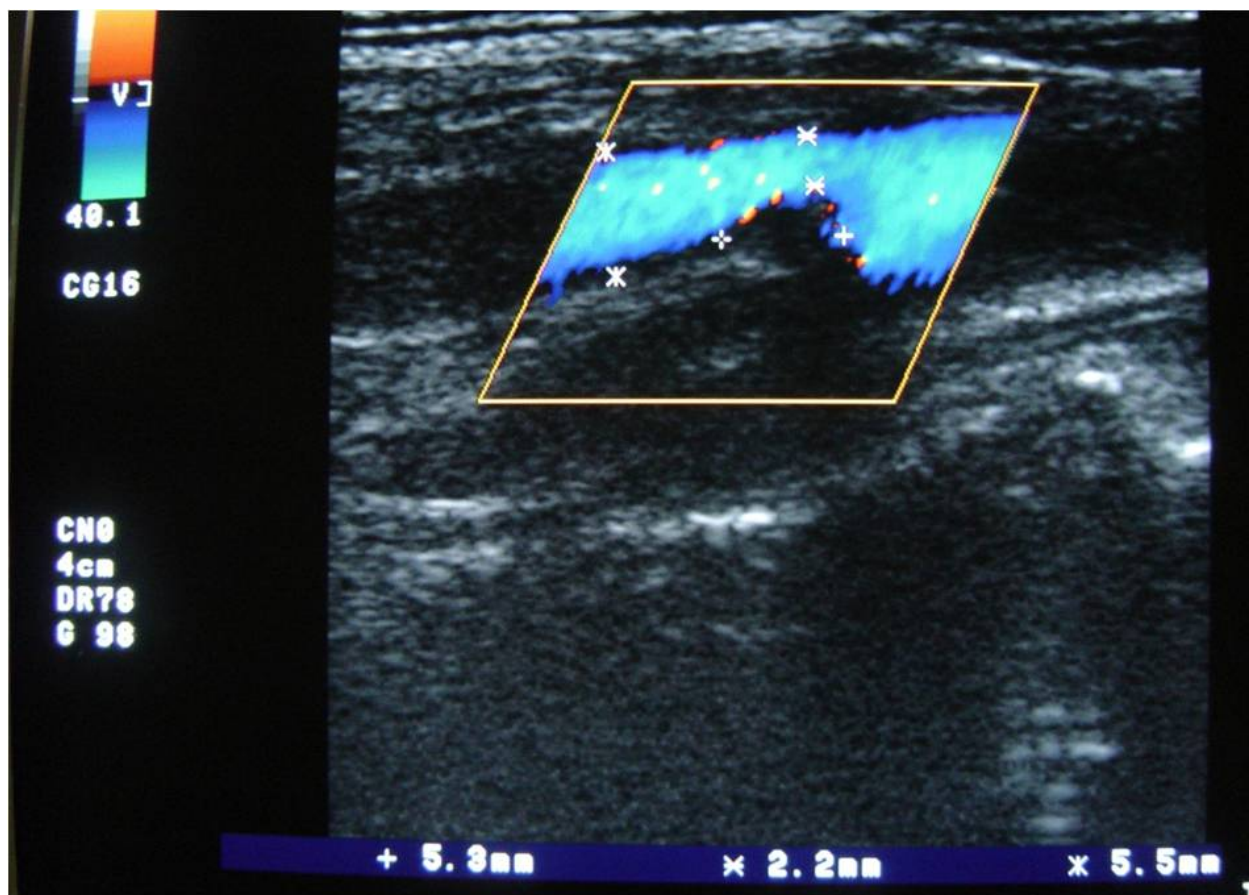
be noticed distal and the absence of blood flow in the empty vein proximal to the site of thrombosis. No AV fistula bruit can be heard with a stethoscope. The findings may be confirmed by ultrasound, i.e. the thrombus may be visualized and measured by B mode ultrasound, and the absence of the circulation proximal to the thrombosis site may be confirmed by Doppler [10].

Thrombosis is the most serious complication leading to the loss of function of the fistula. It is treated surgically by thrombectomy or via endovascular route.

3.3.2. Stenosis

Stenosis is the most frequent complication. It is caused by the luminal narrowing of the vein. Although it may develop in any part of the vein, it is usually found close to the AV anastomosis.

Stenosis leads to AV fistula malfunction characterized by a reduced blood flow through the arterial segment of the fistula in 50% of the cases. Reduced and inadequate blood flow through the AV fistula is registered by the blood pump, which results in inadequate dialysis doses [11]. Stenosis may be suspected if blood flow through a particular segment of the vein



Source: Archive of the Department of Nephrology and Dialysis, University Hospital Rijeka

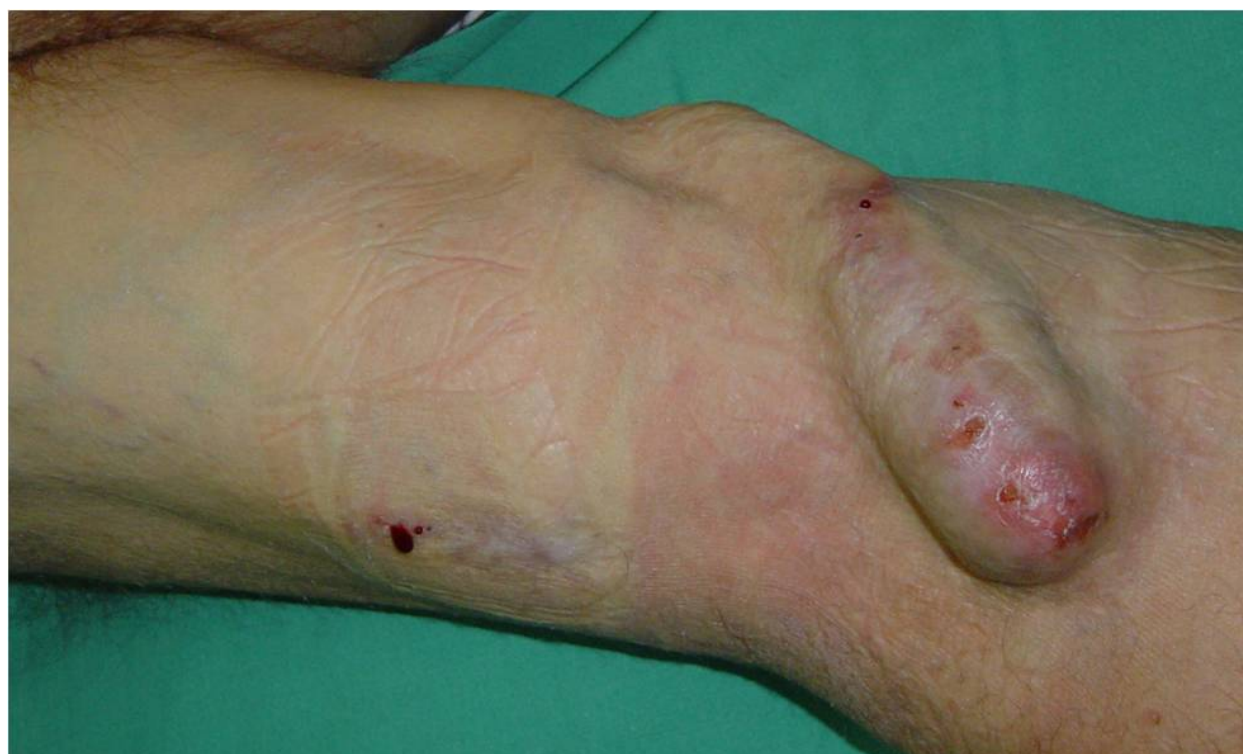Figure 7. Stenosis of the AV fistula as shown using ultrasonography in the B-mode with Doppler visualisation of the missing blood flow on the stenosis site.

is reduced. Frequently, a high-pitched bruit can be heard on auscultation. The diagnosis may be confirmed by ultrasound and phlebography. Priority should be given to B mode ultrasound and Doppler sonography, because these are non-invasive techniques that can precisely determine the location and degree of stenosis (Figure 7).

These methods may be used to determine the length of stenosis and measure the diameter of the vein distal and proximal to the stenotic site. In addition, Doppler can detect higher blood flow velocity at the stenotic site [12]. Depending on the findings, a new anastomosis may be created proximal to the stenosis or a stent may be placed at the site of stenosis by a percutaneous intervention. If stenosis develops in the large veins of the neck (usually the subclavian vein), it leads to the edema of the entire arm and pronounced collateral venous blood flow through the subcutaneous veins. HD is complicated by high percentage of blood recirculation, difficult puncture of the vessel, and high venous resistance. The diagnosis of subclavian stenosis is made on the basis of physical and phlebographic findings; ultrasound may not produce reliable results. This complication is managed by percutaneous dilatation and stenting [13].

3.3.3. Aneurysm

Aneurysm is defined as a localized dilation of the vein, usually proximal to the site of stenosis where the pressure on the vessel wall is increased due to blood turbulence and results in the aneurysmal widening of the vein [14]. Turbulent blood flow in aneurysmal dilatation often leads to AV fistula thrombosis. Aneurysms are diagnosed by inspection, palpation, and ultrasound (Figure 8).



Source: Archive of the Department of Nephrology and Dialysis, University Hospital Rijeka

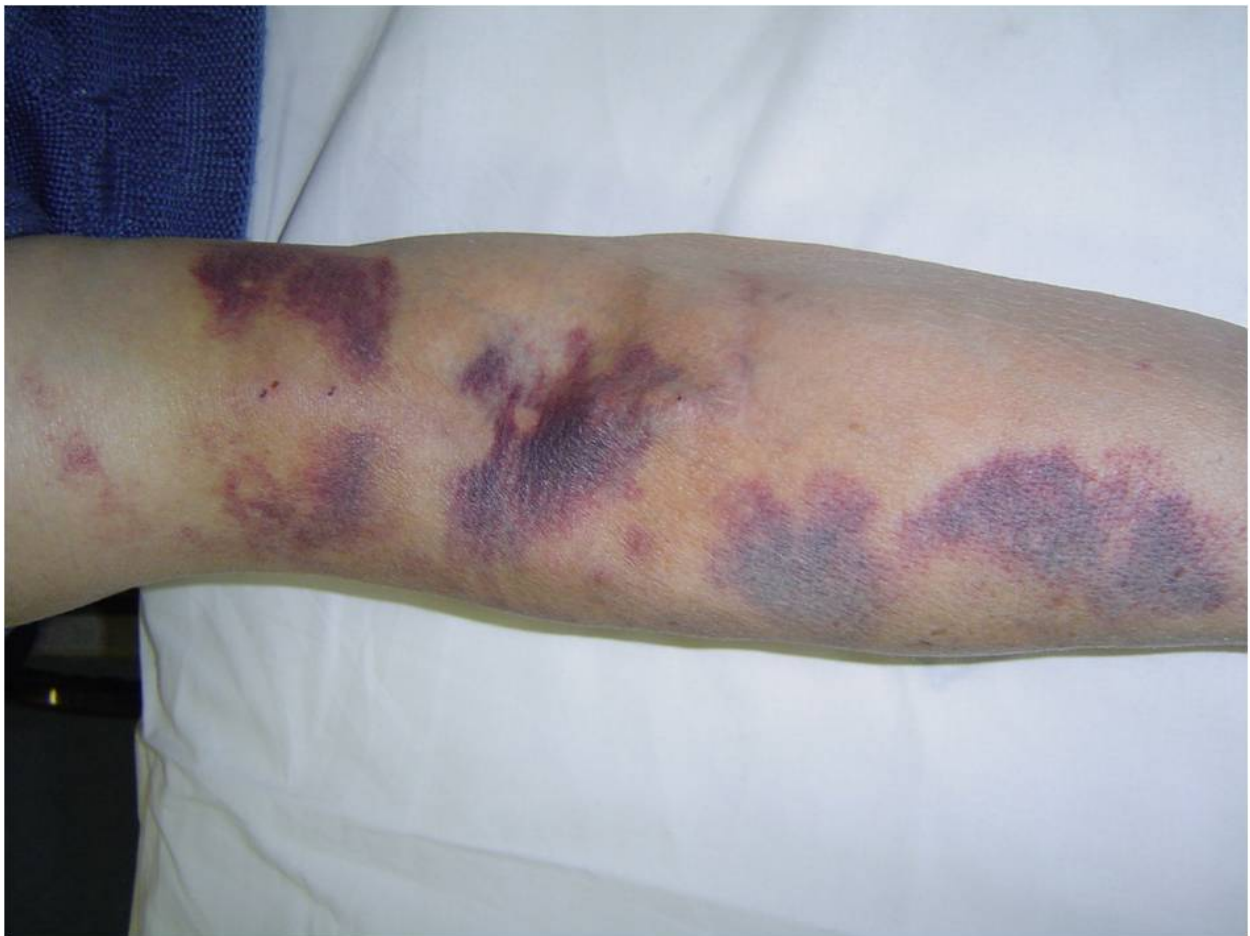Figure 8. Aneurysmatic enlargement of the AV fistula.

3.3.4. Pseudoaneurysm

As opposed to aneurysm, pseudoaneurysm does not contain vessel wall. It expands into the surrounding soft tissue after the destruction of the vessel wall, usually after a careless puncture of the artery or graft. Pseudoaneurysms more often develop as complications of synthetic AV grafts than native fistulas and are diagnosed by ultrasound.

3.3.5. Hematoma

Hematoma most often develops between the venipuncture site and the skin due to inadequate and short compression of the venipuncture site after a dialysis session. It may cause external compression of a segment of a blood vessel and create stenosis. Hematoma is diagnosed by inspection and ultrasound examination (Figure 9).



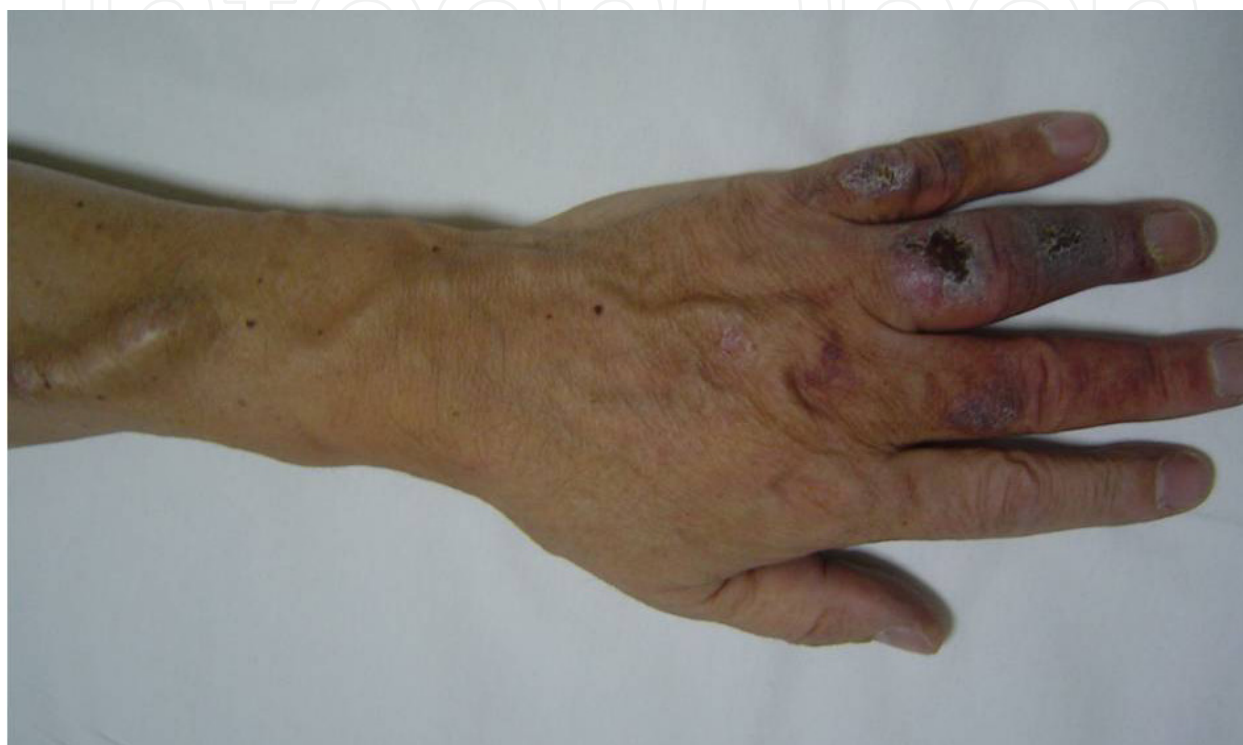Source: Archive of the Department of Nephrology and Dialysis, University Hospital Rijeka

Figure 9. Hematom on the puncture sites of the AV fistula.

3.3.6. Peripheral ischemia

Since blood flow from the radial artery to the palmar arch and fingers is decreased after the creation of an AV fistula, vascular access “steal syndrome” may develop, resulting in

ischemia of the fingers. The thumb, index finger, and middle finger, which are supplied by the radial artery, are most often affected. The syndrome develops mostly in patients with diabetes mellitus and changes on the peripheral arteries (intimal hyperplasia, fibrosis, calcifying plaques, stenoses) due to diabetic angiopathy and reduced peripheral arterial circulation. Therefore, antecubital AV fistulae should be avoided in patients with diabetes mellitus [15]. Patients often complain of cold fingers and pain and they may develop trophic changes on the acral parts, including gangrene (Figure 10).



Source: Archive of the Department of Nephrology and Dialysis, University Hospital Rijeka

Figure 10. Peripheral ischemia caused by “steal syndrome” as a consequence of the insufficient blood flow in the distal part of the arm after AV fistula anastomosis.

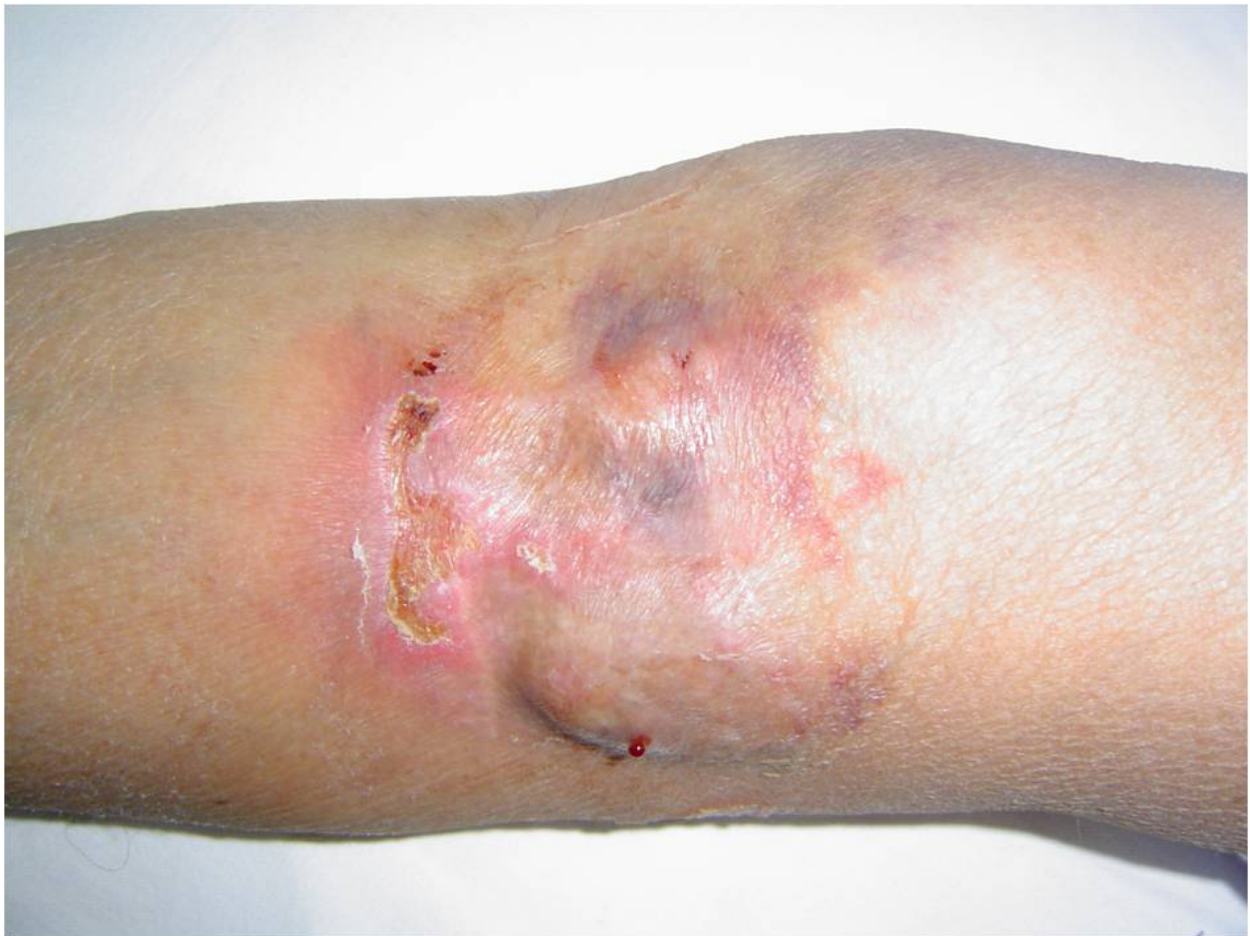3.3.7. Cardiac complications

Cardiac patients may develop additional cardiac complications after the creation of AV fistula, because cardiac output is increased (20–50% of the cardiac volume flows through an AV fistula) [16]. The blood flow through the AV fistula, depending on its location, is 600 - 2000 mL/min.

3.3.8. Infection

Infections most often occur after a non-sterile puncture of AV fistula and are characterized by redness and edema of the skin over the fistula. Due to the inflammatory changes, the blood vessel may be weakened and rupture, especially if the changes affect the aneurysm.

These complications are treated medically with antibiotics or surgically in case of imminent rupture (Figure 11) [17].



Source: Archive of the Department of Nephrology and Dialysis, University Hospital Rijeka

Figure 11. Infection of the AV fistula. Serotic extravasation is present on the puncture site. Crusta formations are sign of the active inflammatory process.

3.4. Arteriovenous graft

If native AV fistula cannot be created due to inadequate blood vessels (poorly developed veins or arterial insufficiency), a synthetic blood vessel may be implanted between the artery and the vein. Such an implanted vessel is called AV graft. A graft is made of biocompatible material, such as polyesther (Dacron), expanded polytetrafluoroethylene (Goretex) or polyurethane (Vectra), in order to avoid allergic reactions, thrombosis, and infection. It is implanted subcutaneously to be available for puncture, mostly on the upper arm between the brachial artery and axillary vein and less often on the forearm or thigh (Figure 12) [20].

3.4.1. Complications

AV graft complications are similar to those described for native AV fistulas and include thrombosis, stenosis, pseudoaneurysm, and infections and are managed in a similar way.

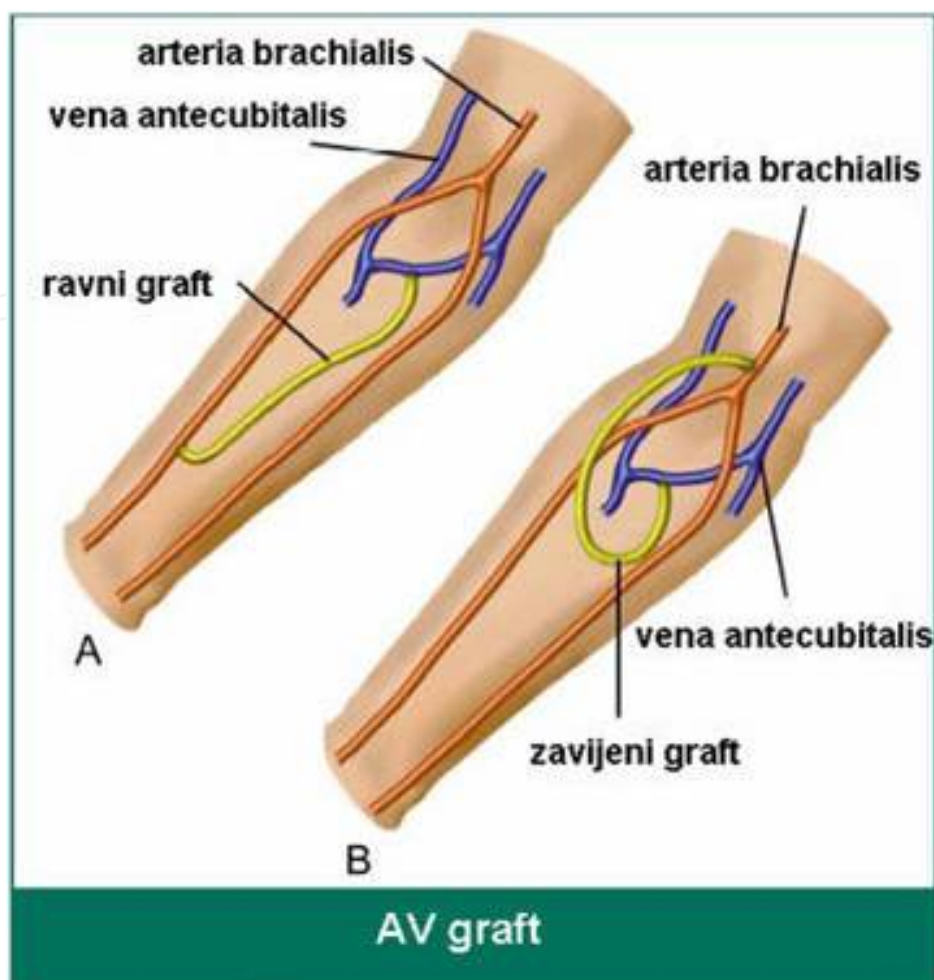
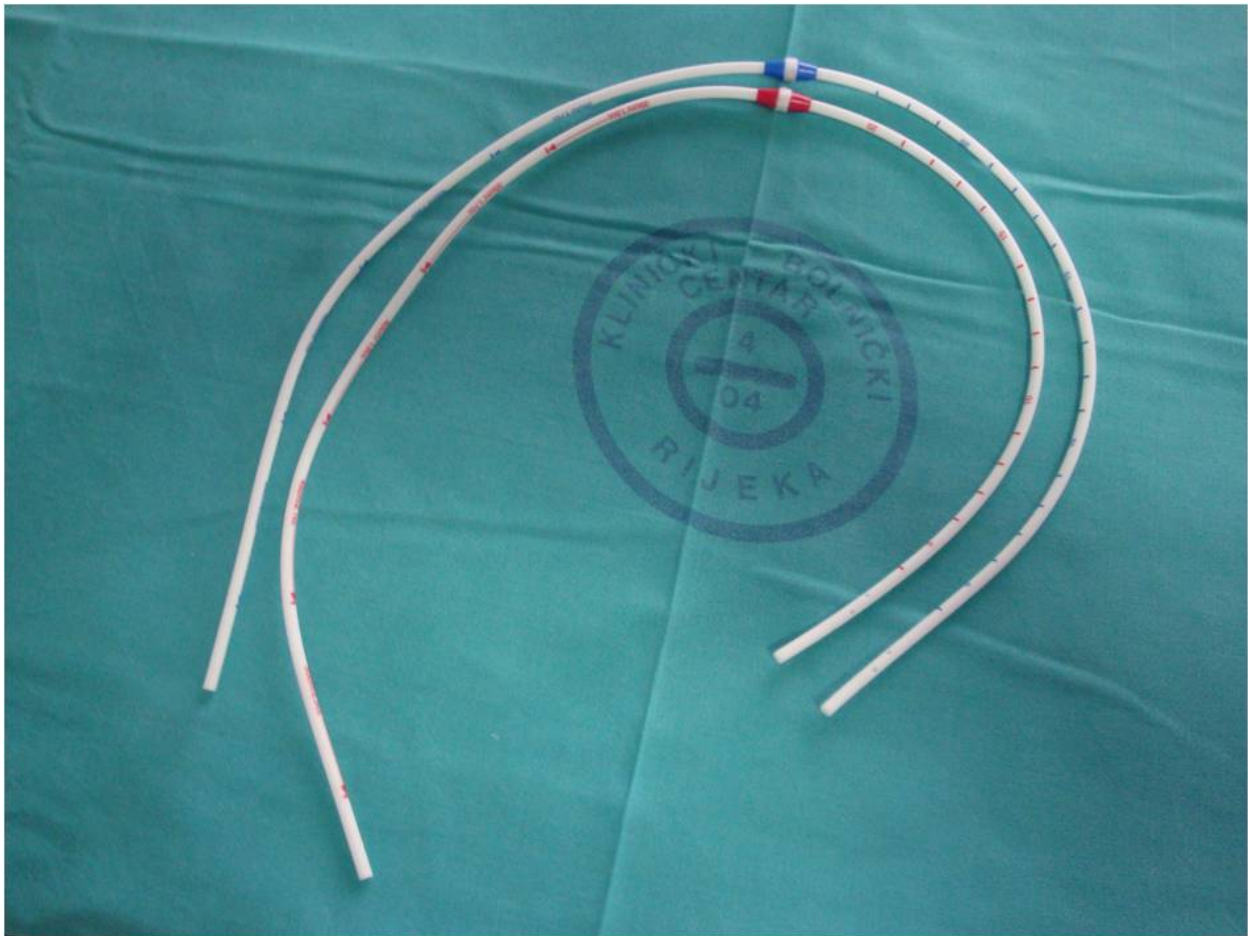


Figure 12. Schematic view of the arteriovenous graft

3.5. Tunneled central venous catheters

In some elderly patients with chronic heart failure syndrome and inadequate peripheral blood vessels, it is not possible to create an AV fistula or implant a synthetic AV graft. Therefore, a permanent tunneled central venous catheter (CVC) with a subcutaneous synthetic cuff is often implanted in these patients [19]. Connective tissue grows into the cuff and anchors the catheter in place, at the same time reducing the possibility of infection (Figure 13).

This approach is used in the treatment of 10–15% patients in the chronic HD program. The patients should be informed about the tunneled CVC-associated complications, which are more frequent than those associated with AV fistulas or AV grafts (thrombosis, bacteremia, sepsis). Double-lumen catheters are introduced through large veins (the internal jugular, subclavian or femoral veins) and connected via tubing with the blood pump, which ensures a sufficient blood flow (300 to 400 mL/min) and is controlled via an HD monitor. The most desirable site for tunneled CVC placement is the right internal jugular vein. Alternative sites include the external jugular vein, subclavian vein, femoral vein, and inferior vena cava. If the vascular access is temporary, it should not be placed on the same side of the body where



Source: Archive of the Department of Nephrology and Dialysis, University Hospital Rijeka

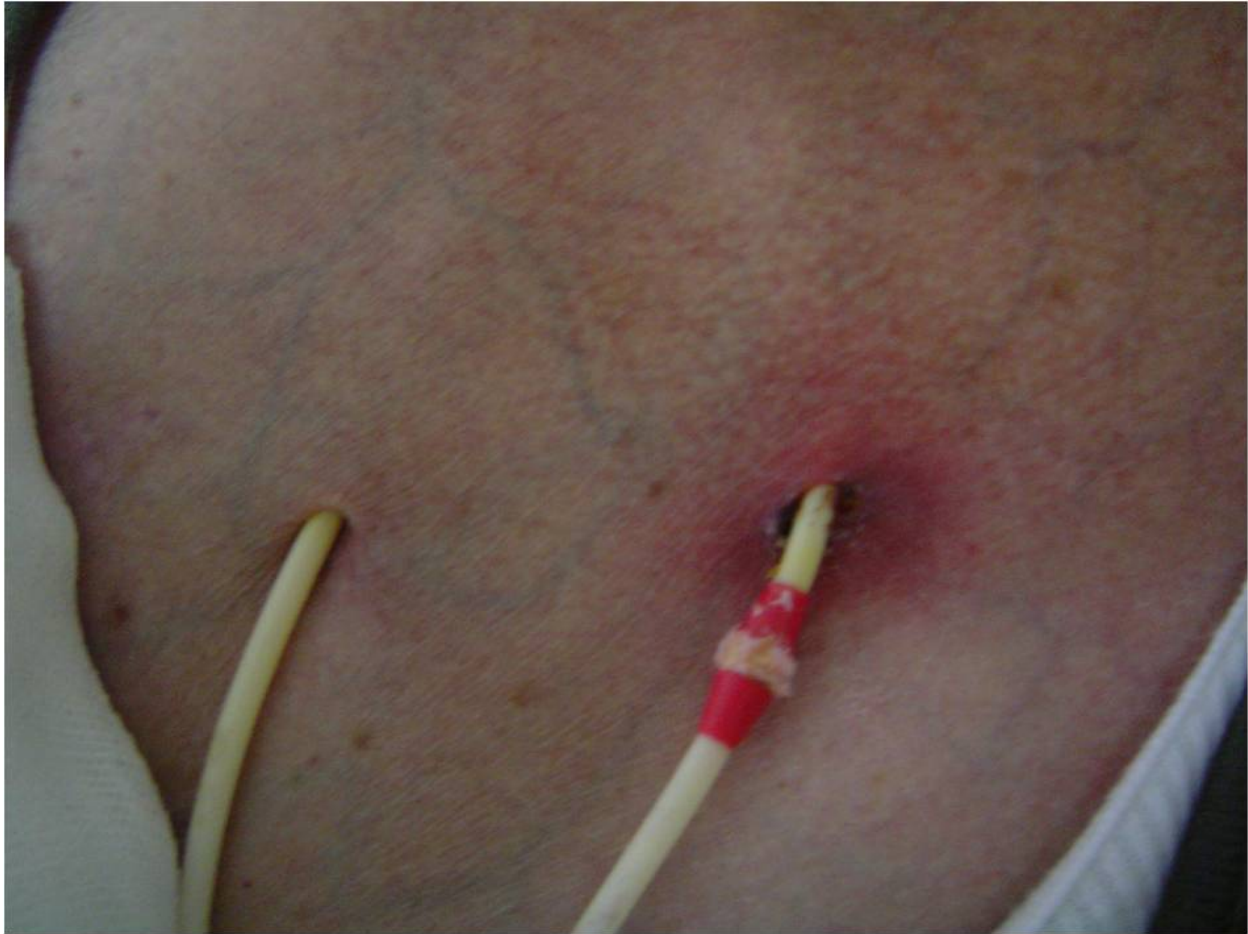Figure 13. Tunneled catheter for hemodialysis, Tesio model. Two separate lumen are suitable for better blood flow and less recirculation.

the creation of fistula is planned. The subclavian vein should be used only if jugular access is not possible. The catheter is inserted using the modified Seldinger technique under ultrasound control. The jugular access is located superior and lateral to the sternal end of the clavicle. After a successful placement, the position of tunneled CVC should be confirmed by x-ray. There are several advantages of tunneled CVC. It may be used immediately after placement, it does not require venipuncture (lower risk of heparin-associated bleeding), and possible thrombotic complications at the access site are easier to manage. Disadvantages of a tunneled CVC include lower blood flow through the dialyzer, possible complications during catheter placement, higher risk of infection, stenosis of the subclavian vein, and cosmetic problems [2].

3.5.1. Complications

Complications related to tunneled hemodialysis catheters may be early and late. Early complications are usually mild, such as hematoma at the puncture site, puncture of the common carotid artery, inadequate catheter position (most often due to stenosis of the brachiocephalic vein), hoarseness, and paresthesia of the limb on the puncture side due to anesthetic infiltration to the innervating area of the recurrent nerve and brachiocephalic

nerve plexus. More severe complications include pneumothorax, hemothorax, and hemopericardium with an imminent cardiac tamponade. Late complications include thrombosis, infection (usually in the subcutaneous tunnel) resulting in bacteremia and, in severe cases, sepsa (Figure 14) [20].



Source: Archive of the Department of Nephrology and Dialysis, University Hospital Rijeka

Figure 14. Infection of the exit-site of the catheter lumen. Complete protrusion of the cuff.

3.5.2. *Thrombosis*

Thrombosis leads to inadequate blood flow through the catheter. It is a relatively frequent complication in dialysis patients with intravenous catheters. Reduced blood flow reduces the delivered dialysis dose. Tunneled catheters normally have a blood flow rate of >300 mL/min. If the blood flow rate is lower, incomplete obstruction caused by endoluminal fibrin deposits may be suspected. In case of complete obstruction, dialysis is not possible; therefore, the non-functional catheter should be replaced by a new one via new subcutaneous tunnel [21].

Fibrinolytic agents (urokinase, tissue plasminogen activator – tPA) may be administered over 3-6 hours. In case of incomplete obstruction, instillation of antithrombotic solutions (standard heparin, low-molecular-weight heparin, sodium citrate) into the lumen of the catheter is recommended [22, 23].

Sodium nitrate has recently been used more often than standard heparin for the prevention of hemodialysis catheter infection and thrombosis. As a polysaccharide, heparin attracts microbes and contributes to the development of biofilm on catheter surfaces. If it enters the systemic circulation, it increases the risk of bleeding. Sodium citrate prevents possible infection by “binding” calcium needed for bacterial growth and prevents the formation of thrombus by blocking calcium. If it enters the systemic circulation, it has no systemic effect because it is rapidly metabolized in the liver and muscle tissue to neutral bicarbonates. The observed adverse reactions (occurring in approximately 10% of the patients) are transitory and include metallic taste and numbness in the fingers and toes while the lumen of the catheter is being filled with the solution. These reactions may be avoided if the volume of the administered solution is tapered in 0.1 ml decrements in each subsequent dialysis session until the symptoms resolve. The concentrations of sodium citrate that are in use include 23%, 30% and 46.7% solutions [24, 25].

3.5.3. Infection

Catheter-associated infections are the most frequent cause of illness in patients with this type of vascular access. Diagnosis is not difficult to make. It is based on increased body temperature and pain and redness around the catheter exit site or subcutaneous tunnel often accompanied by discharge. The diagnosis of silent endoluminal contamination is more difficult to make, especially if the external signs of inflammation are absent. In that case, positive hemoculture or positive bacterial culture from intraluminal thrombus helps the diagnosis.

The most common causative agents (80%) include Gram-positive bacteria (*Staphylococcus epidermidis*, *Staphylococcus aureus*), whereas Gram-negative bacteria and fungi (*Enterococcus*, *Escherichia coli*, *Pseudomonas*, *Candida* species) are less common (20%). Specific blood markers (leukocytosis, increased C-reactive protein, increased procalcitonin) may help in the diagnosis of catheter-associated bacterial infection [26].

Management of known catheter-associated infection

- a. In case of the catheter exit site or tunnel infection with negative hemoculture, toilet of the exit or tunnel should be performed. Exit swabs should be taken for microbiological analysis and a two-week antibiogram-based antibiotic therapy should be administered. Since Gram-positive bacteria are the causative agents in 80% of the cases, treatment with antibiotics to which Gram-positive bacteria are susceptible may be introduced immediately and maintained until the microbiological results become available.
- b. In case of positive hemoculture without any clinical signs of the catheter exit site or tunnel infection, it is advisable to replace the catheter and introduce antibiotic prophylaxis based on the microbial susceptibility test results over the next 4 weeks.
- c. In case of the catheter exit site or tunnel infection and positive hemoculture, the catheter should be immediately removed and antimicrobial treatment should be administered over the next 4 weeks to decrease the risk of catheter-associated sepsis and possible

development of metastatic infection, such as endocarditis, osteomyelitis, and vertebral abscess, which may sometimes develop even after the catheter has been removed

3.5.4. Infection prevention

Strict hygienic measures during dialysis sessions, the use of sodium citrate solution for the maintenance of the catheter patency between dialysis sessions due to its antithrombotic and antiseptic characteristics, and preventive application of protective antimicrobial ointment on the skin around the catheter exit site will reduce the risk of bacteremia [28].

4. Conclusion

Adequate patient preparation for hemodialysis includes AV fistula construction in time. AV fistula is the most appropriate type of vascular access for hemodialysis with less complication in comparison to other vascular access types. Use of endovenous catheters is sometimes needed, but should be limited only for emergency or in the patients with exhausted vessels for AV fistula or AV graft construction.

Author details

Ivica Maleta, Božidar Vujičić* and Sanjin Rački

Department of Nephrology and Dialysis, University Hospital Rijeka, Rijeka, Croatia

Iva Mesaroš Devčić

Polyclinic for Hemodialysis "Fresenius Medical Care", Delnice, Croatia

5. References

- [1] Ortega T, Ortega F, Diaz-Corte C, Rebollo P, Ma Baltar J, Alvarez-Grande J (2005) The timely construction of arteriovenous fistula: a key to reducing morbidity and mortality and to improving cost management. *Nephrol. dial. transplant.* 20:598-603.
- [2] NKF-K/DOQUI Clinical Practice Guidelines for Vascular Access: Update (2000) *Am j. kidney dis.* 37:137-181.
- [3] Weijmer MA, ter Wee PM (2004) Temporary Vascular Access for Hemodialysis treatment. In: Ronco C, Levin NW, editors. *Hemodialysis Vascular Access and Peritoneal Dialysis Access.* Contrib. nephrol. Basel: Karger. pp. 94-111.
- [4] Ash SR (2002) The evolution and function of central venous catheters for dialysis. *Semin.dial.* 14:416-424.
- [5] Mickley V (2002) Central venous catheters: Many questions, few answers. *Nephrol. dial. transplant.* 17:1368-1373.
- [6] Pisoni LR (2002) Vascular Access use and outcomes: Results from DOPPS. *Contrib. nephrol.* 137:13-19.

* Corresponding Author

- [7] Ryner HC, Pisoni RL, Gillespie BW (2003) Creation, cannulation and survival of arteriovenous fistulae: data from DOPPS. *Kidney int.* 63:323.
- [8] Brunori G, Ravani P, Mandolfo S, Imbasciati E, Malberti F, Cancarini G (2005) Fistula maturation: doesn't time matter at all? *Nephrol. dial. transplant.* 20:684-687.
- [9] Corpataux JM, Haesler E, Silacci P, Ris HB, Hayoz D (2002) Low-pressure environment and remodelling of the forearm vein in Brescia-Cimino vascular access. *Nephrol. dial. transplant.* 17:1057-1062.
- [10] Schwab SJ, Raymond JR, Saeed M, Newman GE, Dennis PA, Bollinger RR (1989) Prevention of hemodialysis fistula thrombosis. Early detection of venous stenoses. *Kidney int.* 36:707-711.
- [11] Schwab SJ, Oliver MJ, Suhocki P, McCann R (2001) Hemodialysis arteriovenous access: Detection of stenosis and response to treatment by vascular access blood flow. *Kidney int.* 59:358-362.
- [12] Bay WH, Henry ML, Lazarus JM, Lew NL, Ling J, Lowrie EG (1998) Predicting hemodialysis access failure with color flow Doppler ultrasound. *Am. j. nephrol.* 18:296-304.
- [13] Turmel-Rodrigues L, Pengloan J, Rodrigue H, Brillet G, Lataste A, Pierre D et al. (2000) Treatment of failed native arteriovenous fistulae for hemodialysis by interventional radiology. *Kidney int.* 57:1124-1140.
- [14] Kronung G (1984) Plastic deformation of Cimino fistula by repeated puncture. *Dial. transplant* 13:635-638.
- [15] Miles AM (2000) Upper limb ischaemia after vascular access surgery. Differential diagnosis and management. *Semin. dial.* 13:312-315.
- [16] Foley RN (2003) Clinical epidemiology of cardiac disease in dialysis patients: Left ventricular hypertrophy, ischaemic heart disease, and cardiac failure. *Semin. dial.* 16:111-117.
- [17] Dhingra RK, Young EW, Hulbert-Shearon TE, Leavey SF, Port FK (2001) Type of vascular access and mortality in U.S. hemodialysis patients. *Kidney int.* 60:1443-1451.
- [18] Miller PE, Carlton D, Deierhoi MH, Redden DT, Allon M (2000) Natural history of arteriovenous grafts in hemodialysis patients. *Am. j. kidney dis.* 36:68-74.
- [19] O'Dwyer H, Fotheringham T, O'Kelly P, Doyle S, Haslam P, McGrath F et al. (2005) A prospective comparison of two types of tunneled hemodialysis catheters: The Ash Split versus Perm Cath. *Cardiovascular intervent. radiol.* 28:23-29.
- [20] Capdevila JA, Planes AM, Palomar M, Gasser I, Almirante B, Pahissa A et al. (1992) Value of differential quantitative blood cultures in the diagnosis of catheter related sepsis. *Eur j. clin. microbiol. infect. dis.* 11:403-407.
- [21] McCann M, Moore ZE (2010) Interventions for preventing infectious complications in haemodialysis patients with central venous catheters. *Cochrane database syst. rev.* 20;(1):CD006894
- [22] Rockall AG, Harris A, Wetton CW, Taube D, Gedroyc W, Al-Kutoubi MA (1997) Stripping of failing haemodialysis catheters using the Amplatz gooseneck snare. *Clin. radiol.* 52: 616-620.

- [23] Merport M, Murphy TP, Egglin TK, Dubel GJ (2000) Fibrin sheath stripping versus catheter exchange for the treatment of failed tunneled hemodialysis catheters: randomized clinical trial. *J. vasc. interv. radiol.* 11: 1115–1120.
- [24] Ash SA, Mankus RA, Sutton M (2000) Concentrated Sodium Citrate (23%) for Catheter Lock. *Hemodialysis int.* 4: 22-31.
- [25] Wijmer MC, Debets-Ossenkopp YJ, Van de Vondervoort FJ, Ter Wee PM (2002) Superior antimicrobial activity of trisodium citrate over heparin for catheter locking. *Nephrol. dial. transplant.* 17:2189-2195.
- [26] Tordoir J, Canaud B, Haage P, Konner K, Basci A, Fouque D et al. (2007) EBPG on Vascular Access. *Nephrol. dial. Transplant.* 22: 88-117.