

# We are IntechOpen, the world's leading publisher of Open Access books Built by scientists, for scientists

6,900

Open access books available

185,000

International authors and editors

200M

Downloads

Our authors are among the

154

Countries delivered to

TOP 1%

most cited scientists

12.2%

Contributors from top 500 universities



WEB OF SCIENCE™

Selection of our books indexed in the Book Citation Index  
in Web of Science™ Core Collection (BKCI)

Interested in publishing with us?  
Contact [book.department@intechopen.com](mailto:book.department@intechopen.com)

Numbers displayed above are based on latest data collected.  
For more information visit [www.intechopen.com](http://www.intechopen.com)



---

# **Abdominal Aortic Aneurysms – Actual Therapeutic Strategies**

---

Ionel Droc, Dieter Raithel and Blanca Calinescu

Additional information is available at the end of the chapter

<http://dx.doi.org/10.5772/48596>

---

## **1. Introduction**

AAA is the thirteenth cause of death in UK accounting for 1.2% of male and 0.6 of female mortality, and the third cause of sudden death after coronary artery disease and stroke. [1-3]

Abdominal aortic aneurysms are identified in the elderly population; only a few patients die because of AAA rupture prior to the age of 60. The incidence of the disease in the general population is 60/1000 inhabitants [4] and between 1.8% and 6.6% in autopsies studies. In studies of natural history of AAA the rate of aneurysm rupture and death could exceed 60% within 3 years of the initial diagnosis. [5]

## **2. Pathogenesis**

The pathogenesis of aortic aneurismal disease is multifactorial. There is no consensus as to the cause of aortic aneurysms. Hypertension exists in about half of patients and is obviously an aggravating condition. Tertiary syphilis was once an important cause of aneurysms, particularly of the ascending thoracic aorta, but is a less common cause now.

Genetic components have been identified in Marfan's syndrome and Ehlers Danlos disease. Even in the most common, degenerative, form of aortic aneurysms there is a genetic component. Familial clustering of aortic aneurysms is evident as up to 20% of patients have one or more first-degree relatives who have also suffered from the disease.[6] More studies are clearly needed to establish details of the genetic interplay in aortic aneurysms.

At times, an aneurysm may be caused by an extrinsic factor, such as an infection (mycotic aneurysm) or trauma (pseudoaneurysm).

Traditional views states that most aneurysms were caused by degenerative atherosclerotic disease but it affects different layers of the aortic wall. Atherosclerosis mainly affects the

intima, causing occlusive disease, while aortic aneurysm is a disease of the media and adventitia. They are distinct conditions that nonetheless often occur together.

Histologically, AAAs are characterized by chronic inflammation with destruction of the extracellular matrix, remodelling of the wall layers, and reduction in number of smooth muscle cells. The effectors of destruction are a group of enzymes capable of degrading the major connective tissue components: collagen, elastin, fibronectin, laminin and the proteoglycans.[7] The inflammatory infiltrate consists of macrophages as well as T and B lymphocytes, which excrete proteases and elastases causing wall degradation.[8] The reason for this migration is unclear.

Degradation of elastin has been associated with dilatation while rupture of the wall is related to collagen degradation. Experimental studies of elastase induced aneurysms indicate that an inflammatory reaction within the aortic media is crucial for aortic dilatation.

In both clinical and experimental studies, metalloproteinases (MMP), one of the most prominent group of elastases, have emerged as playing a role in the development of aortic aneurysms. [9,10] The MMPs are inhibited by the family of tissue inhibitors of metalloproteinases (TIMPs), including TIMP-1 and TIMP-2. An imbalance between the activated MMPs and their natural inhibitors may be responsible for the destruction of the aortic wall. Therapeutic trials with doxycycline, a MMP inhibitor, are ongoing and preliminary results are encouraging with less progression of aneurysmal size in treated patients.[11]

Commonly assessed in AAA are also proteins involved in, stimulated by or associated with thrombosis, for example, fibrinogen and D-dimer.[12]

A human biopsy study has confirmed the association between the extent of inflammation of the aortic wall and aortic diameter.[13] Interleukin-6 (IL-6), metalloproteinase-9 (MMP-9-gelatinase B) and C-reactive protein (CRP) are markers of inflammatory processes and have all been associated with AAA pathogenesis [13,14,15] as well as collagen type IV, fibronectin and other matrix proteins. High levels of MMP-9 and MMP-3 have been found in abdominal aortic aneurysmal tissue. Levels of MMP-9 are associated with aneurysmal size. [14,16,17] Hovsepian et al. Reported that MMP-9 plasma levels appeared to directly reflect the amount of MMP-9 produced within aneurysm tissue. MMP-9 plasma levels also decreased substantially after surgical AAA repair.[18]

Circulating concentrations of many kinds of biomarkers have been measured and compared in patients with abdominal aortic aneurysm (AAA) and subjects without AAA to assess their possible role in the pathogenesis or progression of AAA (Table 1). Circulating biomarkers could play a role in the diagnosis of AAA reflecting also the AAA activity in asymptomatic phases and may have a role in predicting subsequent progression and thus the prognosis of AAA.

Most investigated potential biomarkers show either no correlation or a weak correlation with the clinical course of AAA. Few have any potential for clinical use. Another limitation is related to the fact that many biomarkers for AAA are not disease specific; most of them also are markers for atherosclerosis.

Biomarker	Number of patients	Summary of findings	Author, year
MMP-9	36	Plasma MMP-9 may predict the natural history of AAA	Lindholt J. et al. 2000
MMP-9, MMP-2 TIMP-1, TIMP-2	76	Both MMP-2 and 9 failed to show relevance as serum markers for aortic dilatation.	Eugster T et al. 2005
	30 medium-sized ruptured AAA 30 large asymptomatic AAA (aAAA)	AAA rupture is associated with higher levels of MMP-9 in the aortic wall. There is no association to TIMP-1 or TIMP-2 levels. MMP-2 levels are positively, whereas MMP-9 levels are negatively correlated to aAAA. This may indicate that MMP-9 may have a determinant role in the AAA wall for the progression towards rupture, whereas MMP-2 pay a role for expansion.	E. Petersen et al. 2002 [19]
	37	Plasma levels of MMP-9 can accurately discriminate between patients with and without an endoleak with both high sensitivity and specificity. Anterior-posterior aneurysmal diameter (Dmax) was significantly larger in the endoleak group, however, plasma MMP-9 levels were not associated with Dmax or intraluminal thrombus volume.	F.A.M.V.I. Hellenthal et al.2012 [20]
MMP-9, MMP-1	52 non-ruptured AAA 16 ruptured AAA	The concentrations of MMP1 and MMP9 were significantly elevated in the plasma of ruptured AAA compared with non-ruptured AAA. There was no significant correlation between AAA diameter and enzyme concentration within the ruptured and non-ruptured cohorts.	W.R.W Wilson et al. 2008 [21]
P-Elastase	79	P-elastase was positively correlated with the mean annual AAA expansion rate.	Lindholt J. Et al. 2003
IFN-gamma	50	Elevated IFN-gamma concentrations seem to predict an increased rate of expansion in AAA.	Junoven J et al. 1997
TNF-alpha, IL-8	90	IL-8 and TNF-alpha can be used as endogenous markers of the process of AAA development.	Treska V et al. 2000
IL-6	7	In multivariate analysis the level of IL-6 was independently correlated with aortic diameter	Rodhe LE et al 1999
IL-6, MMP-9, CRP	213	No correlation was found between levels of circulating IL-6, MMP-9, CRP and the expansion of small-diameter AAAs, indicating no clinical use of these markers in AAA surveillance.	Karlsson L. Et al.2009 [22]

Biomarker	Number of patients	Summary of findings	Author, year
C-reactive Protein (CRP)	Sympt 52 Ruptured 62	No correlation. A significant elevation of CRP could be found in patients who presented symptoms or rupture of an AAA.	Domanivits H et al.2002
	545	CRP levels are elevated in larger aneurysms but do not appear to be associated with rapid expansion.	Norman P et al. 2004
	151	CRP did not correlate with size or expansion rate of AAA	Lindholt J et al 2001
Serum highly sensitive CRP	39	Serum hsCRP is associated with aneurysmal size.	Vainas T et al. 2003
CRP, alpha 1-antitripsin	35 AAA patients 35 controls	A positive correlation was found between CRP and AAA diameter and alpha 1-antitripsin and AAA growth. Alpha 1-antitripsin may be a promising biomarker of AAA growth.	M. Vega de Ceniga et al.2009 [23]
D-dimer, fibrinogen/fibrin	36	The largest diameter of AAA is correlated with the preoperative levels of D-dimer and FDP	Yamazuni K et al.1998
	834 cases with AAA and 6971 controls for fibrinogen 264 cases with AAA and 403 controls for D-dimer.	Plasma fibrinogen and D-dimer concentrations are likely to be higher in cases with AAA than control subjects. Higher plasma fibrinogen and D-dimer concentrations may be associated with the presence of AAA.	Takagi H. Et al. 2009 [12]
	110 patients with AAA 110- controls	Fibrinogen was positively correlated with AAA size ( $r=0.323$ ; $p<0.01$ ) and the percentage of intra-luminal thrombus occupying the lumen ( $r=0.358$ ; $p<0.05$ ).	Al-Barjas et al. 2006 [24]
Insulin-like Growth Factor 1 (IGF-I)	115 small AAAs	Serum IGF-I, but not IGF-II, correlated positively with AAA size and AAA growth. IGF-I levels may serve as a novel biomarker for the natural history of AAA.	J.S. Lindholt et al. 2011 [25]

**Table 1.** Summary of published studies reporting the role of circulating biomarkers in the growth and rupture of AAA

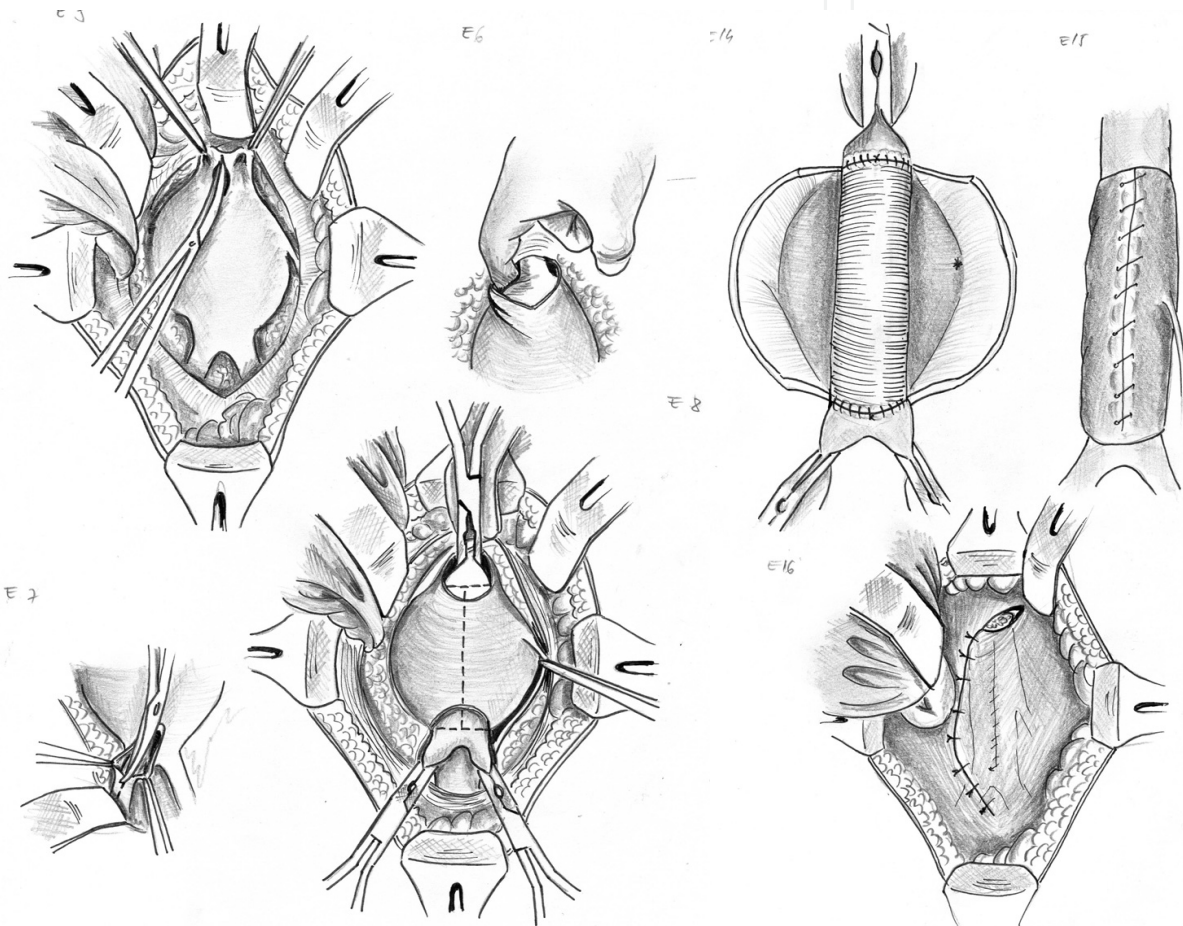
Active investigations continue to identify markers other than size that would predict a risk of rupture. Circulating biomarkers could also indicate optimal intervals between the surveillance intervals. Finally, the identification of biomarkers also may identify potential pathogenic pathways, and thus may open possibilities for pharmacological inhibition of growth, and provide a tool for monitoring this inhibition.[26]



In the future, extended longitudinal studies will be necessary to assess the true potential of matrix-turnover and other biomarkers. New methods, including proteomics and genome wide association studies, may identify new pathways and new potential biomarkers.

### 3. Treatment

Surgical repair was first reported in 1962 and still remains the treatment with the best long-term results. The surgical technique is illustrated in **Figure 1**. It is a major surgical procedure done under general anaesthesia, usually consisting of a midline laparotomy and cross clamping of the aorta and iliac vessels.



**Figure 1.** Open surgery technique for AAA

The mortality of elective surgery is between 3 and 7%. These rates increase significantly in patients with comorbidities, particularly with coronary artery disease and carotid artery disease. Surgical results are impaired by chronic renal failure and COPD.

Increasing age is an important adverse determinant of mortality in both ruptured and intact aneurysms.

In the USA statistics indicate that more than 15000 deaths/year are caused by aneurysm rupture.

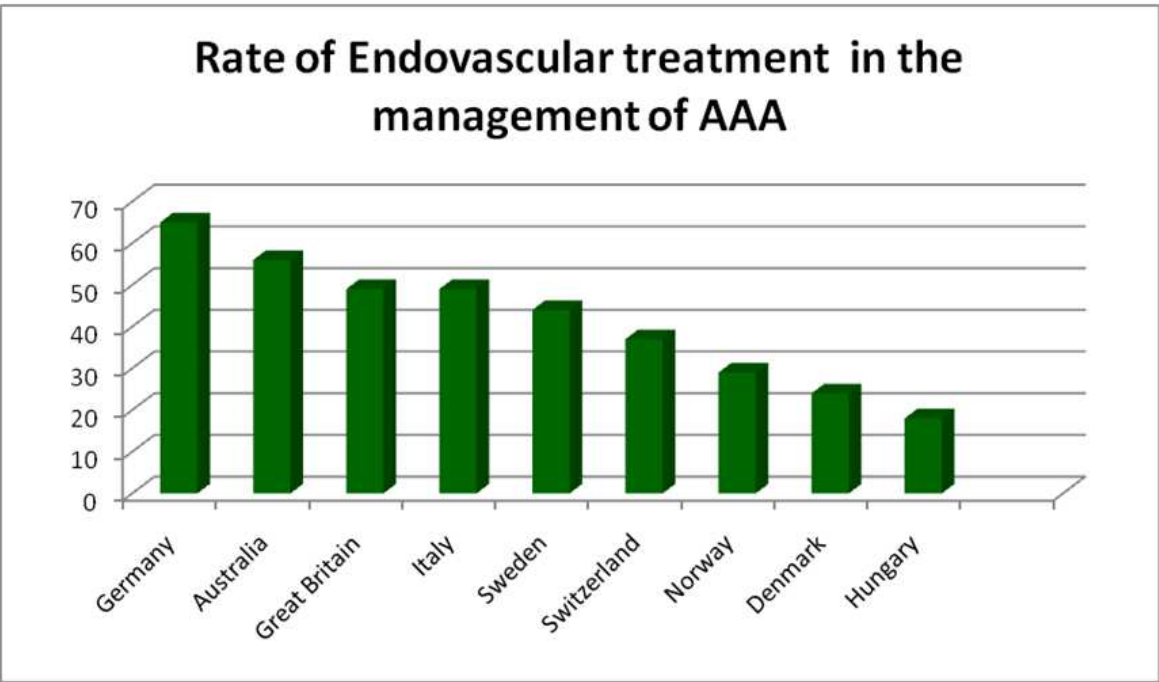
This is the reason why there are screening studies among the target population in order to save lives and decrease health costs. The great interest is to detect and treat the AAA before rupture but the problem is that most of them are asymptomatic.

Because open surgery has non-negligible mortality and postoperative complications associated with a long hospital stay (10.8 days average) scientists tried to develop alternative methods to treat this disease addressing those cases with surgical high risk.

Minimally invasive techniques were developed in order to exclude the aneurysm from the circulation and to provide a new circulator channel towards the legs. Potential applications of endovascular grafts have been found in all areas of vascular surgery but their use for aortic aneurysms was the first to be explored. Endovascular aneurysm repair (EVAR) is an alternative to open surgery in the management of AAA. Juan Parodi and colleagues performed the first endovascular aneurysm repair in Argentina in 1991 [27,28]. Two decades after, the technique has evolved immensely and new devices developed allowing to a greater number of patients to be treated with EVAR. Repair of aortic abdominal aneurysm (AAA) is performed to prevent progressive expansion and rupture. [27, 29 30]

EVAR is progressively replacing open surgery and now accounts for more than half AAA repairs [31] as for example endovascular repair of AAA in Kaiser Hawaii Hospital (USA) was 50% in 2004 of the surgical activity.

A study published in November 2011 identifies the rate of endovascular treatment for AAA in different countries during 2005-2009 (**Figure 2**), whose prospective data were included in



**Figure 2.** Rate of EVAR in the management of AAA in different countries

the VASCUNET database [32]. The study shows a rapid and extensive implementation of the endovascular treatment, with the advent of studies with favourable results in this direction.

EVAR in addition to the advantage of being a minimally invasive method and as such preferred by the patients, has many proven benefits compared with traditional open surgery: low rate of peri- and postoperative mortality and morbidity, shorter hospital stay, significantly reduced intraoperative blood loss and faster recovery. [33, 34, 35] One drawback is the significantly higher reintervention rate compared to open repair.

#### **4. Evidence base for EVAR**

In order to evaluate this new method there are registries [36] (retrospective studies) as: RETA (registry of endovascular treatment for aneurysms) in the UK, started in 1996 [37], EUROSTAR also started in 1996 [38], the Lifeline registry in the USA started in 1998 [39]. There are also randomized, controlled, multicenter trials: EVAR 1 and 2 initiated in 1999 and DREAM (Dutch randomized endovascular aneurysm management) started in 2000.

In RETA, 31 UK centers submitted data. From January 1996 to December 1998 611 cases were enrolled. Four percent received an aortic tube device, 60% an aorto-iliac device and 36% an aorto uni-iliac device with femoro-femoral crossover graft. The objectives were to assess early morbidity and mortality. Conversion to open repair was in 5% of cases. The overall mortality was 7% vs. 12% for open surgery. Endoleaks were more common in larger aneurysms (2% if aneurysm diameter was < 6 cm and 10% if it was > 6 cm) [37].

EUROSTAR (European collaboration on stent graft techniques for aortic aneurysm repair) Registry was established in 1996. The results were published in JVS in October 2000, 88 European centers have contributed, enrolling 2464 patients with a main follow up of 12.19 months. The 30 days mortality was 3.1%. The cumulative risk of late conversion was 2.1%/year and of rupture 1%/year. The significant factors for rupture were: type I endoleak, type III endoleak, graft migration and postoperative kinking of the endograft. The feasibility rate of the procedure was 97% of patients using first and second generation devices. The rate of late failure of the devices was 3%/year.[38,40]

The Lifeline registry was established in 1998 in the USA and the results were published in JVS in July 2005. The end point was to evaluate the long-term outcome of patients treated with EVAR using 5 devices who had FDA approval (Guidant Ancure, Medtronic AneuRx, Gore Excluder, Endologix PowerLink, Cook Zenith). It enrolled 2664 patients with EVAR vs. 334 open repair control patients. The 30 day mortality of EVAR was 1.7% which was not different from surgical control (1.4%), this in spite of the EVAR patients who were significantly older and sicker (more comorbidities). The risk of rupture of the aneurysm after EVAR was 3 times higher (2.1%) in women than in men (0.7%). The risk of rupture of the AAA remained stable over a 6 year period at a level of 1%/year. The surgical conversion rate was 3% at a year and 5% at 6 years (low). All this shows that EVAR is safe and effective in preventing aneurysm rupture and avoiding AAA related death. [39]



The most known and discussed randomized, controlled, multicentre trials are the UK EVAR1 and 2 which were initiated in 1999 and published in "The Lancet" in 2004 [41] and 2005 [42]. EVAR 1 compares endovascular procedures vs. open repair. A great number of patients (2068) were enrolled, aged over 60 years with a non ruptured AAA and who had an aneurysm of more than 5.5 cm in CT scan diameter. Morphological suitability for EVAR [43] and choice of the stent graft was decided by each center (41 centers enrolled). The 30-day mortality rate was 1.7% compared with 4.7% for open surgery. The secondary interventions were 9.8 for EVAR and 5.8 for open repair. Patients unfit for open repair because of significant comorbidities were randomized for EVAR or best medical treatment in the EVAR 2 trial. 338 patients aged 60 years or older with an AAA >5.5 cm in diameter were enrolled. The primary end point was aneurysm related mortality, postoperative complications and hospital costs. The risk of rupture is 25%/year for aneurysms with diameters greater than 6 cm. The 30-day mortality was 9% in EVAR group and in the non intervention group was 9.0 / 100 pers / year. There was no significant difference between the EVAR group and non intervention group for all cause mortality.

The DREAM trial initiated in 2000 enrolled 345 patients considered suitable for both types of treatment. The 30-day mortality after EVAR was 1.2% compared with 4.6% for open surgery. The results were published in 2002 in Journal of Cardiovascular Surgery [44, 45].

The Veteran open vs. endovascular repair (OVER) trial started enrollment in October 2002 in the US. It was design to enroll 5 years followed by a 4 year follow up. In total a 9 years survey. The primary outcome is long-term survival and secondary outcomes included morbidity, procedure failures and need for secondary procedures and costs. 33 centers are participating, 684 patients were enrolled in September 2006 and the investigators expect 900 by the end of the study. Patients enrolled had aneurysms of more than 5cm and were candidates for both procedural types. [46]

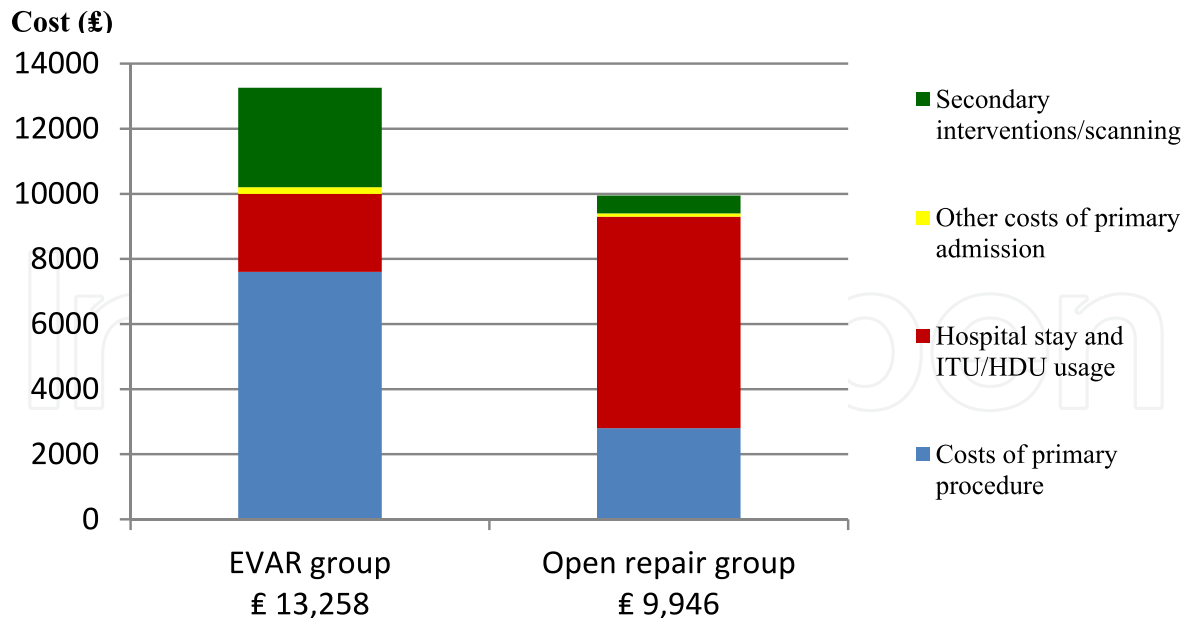
The French trial "*Aneurisme Chirurgie vs Endoprothese*" (ACE) also had the same enrollment conditions and primary and secondary end points.

In OVER and ACE trials were used newer devices for treating AAA than those used in EVAR 1 and DREAM (procedures performed between 1999-2003)[46]. The Gore Excluder and Medtronic AneuRx represent 2/3 from the devices used in OVER compared with only 11% used in EVAR 1.

Speaking about costs the shorter ITU and hospital stay in the EVAR group, with initial comparable costs, the cost per patient over 4 years is higher in EVAR because the cost of the endograft and subsequent of secondary interventions (**Figure 3**)[43].

In summary, EVAR has lower perioperative mortality but there is no difference in long term overall mortality. This procedure is associated with 10% risk of aneurysm related complications/ year, but they can be solved by further endovascular reinterventions [43].

EVAR is a safe, effective and durable treatment for infrarenal aortic aneurysms with suitable anatomy.



**Figure 3.** EVAR costs per patient ( modified after [43])

## 5. Indications and anatomical suitability

Patient selection is an important element of successful EVAR. We should carefully investigate and consider the anatomy of the abdominal aorta, the relationship with the emergence of the renal arteries, the calibre, tortuosity and calcifications of the iliac arteries. The misvaluation of morphological aspects can lead to immediate or late failure of the procedure. With the refinement of medical devices (multislice CT scan with 3D reconstruction, subtraction angiography, sophisticated computer data analysis), we can detect all the morphological modifications in the aneurismal area in segments immediately adjacent.

The Clinical Practice Guidelines of the European Society for Vascular Surgery on the management of AAA, published in April 2011, sets out a series of recommendations in all aspects of diagnosis and management strategies of AAA (Figure 4,5) [47].

There is a consensus that in the case of small aneurysms, with a diameter between 3.0-3.9 cm, the risk of rupture is negligible. Therefore, these aneurysms do not require surgery, supervision by Doppler Ultrasound at regular intervals being sufficient. The management of the AAA with a diameter between 4.0 – 5.5 was determined by two multicenter, randomised, controlled studies, that compared the natural evolution of these aneurysms versus early intervention: UK Small Aneurysm Trial (UKSAT) and American Aneurysm Detection and Management Study (ADAM) respectively [48, 49] and a smaller study, that compared endovascular treatment versus surveillance, the CAESAR study [50]. The PIVOTAL study including aneurysms with diameters between 4.0- 5.0 cm compared the endovascular treatment versus Doppler Ultrasound surveillance [51].

Medium-term results of these studies did not indicate a statistically significant difference in terms of overall mortality at 5 years, the results being similar in the long-term, at 12 years

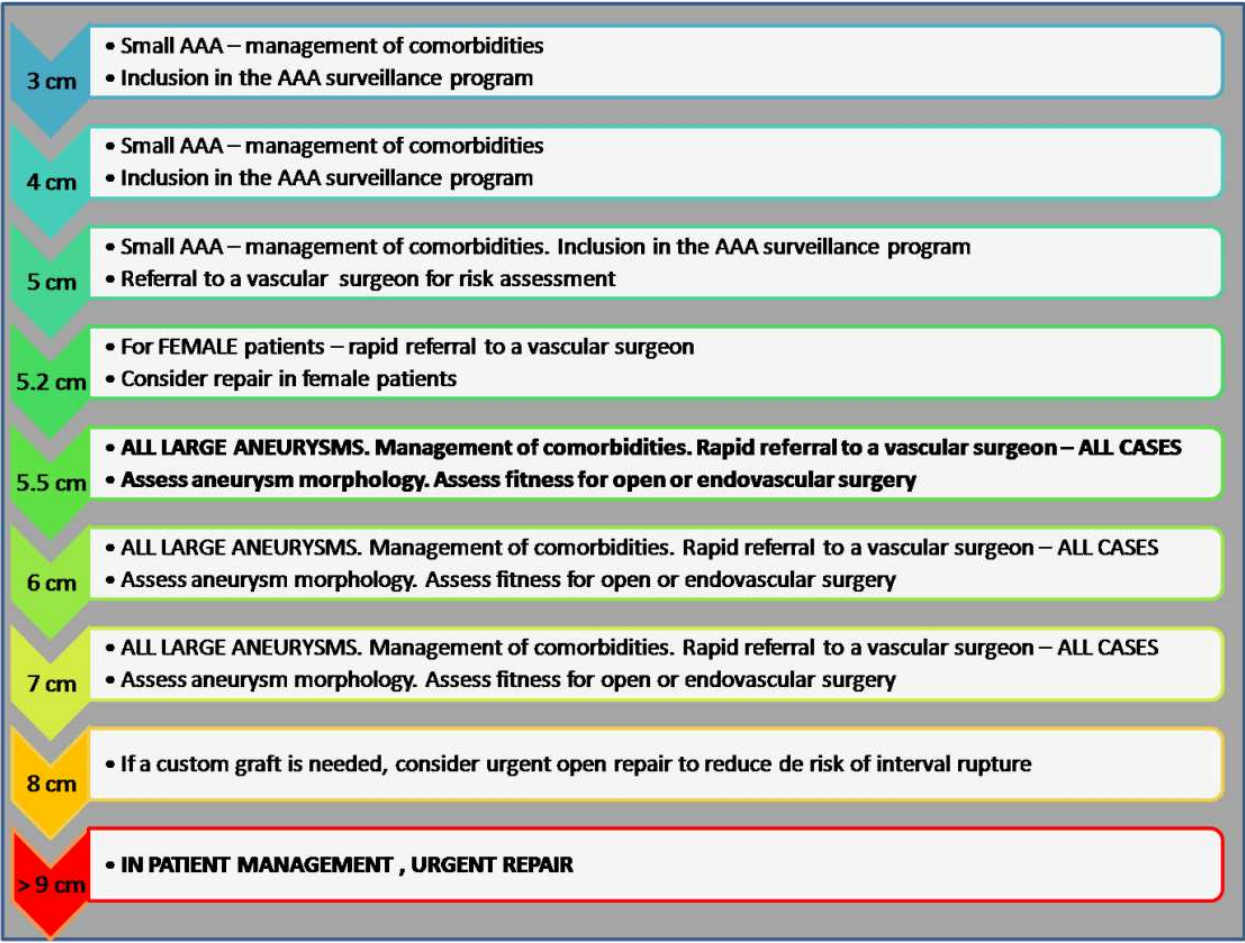


Figure 4. Management strategy of AAA according to the size of the aneurysm (modified after [47])

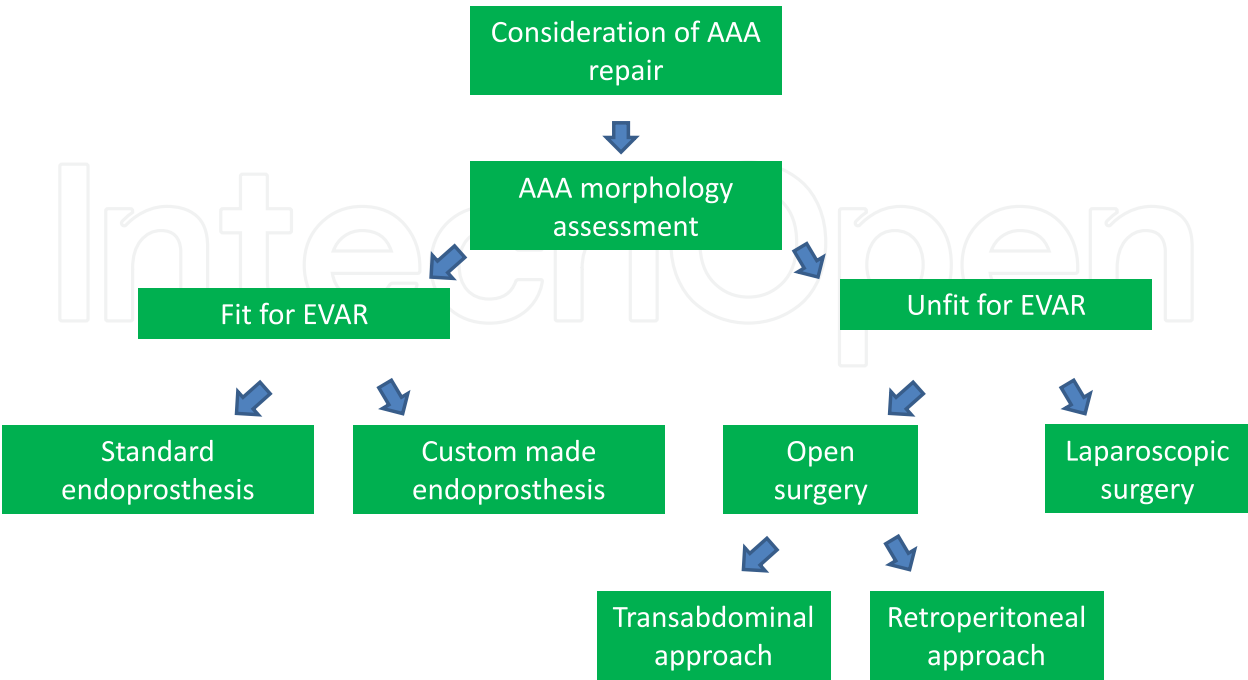


Figure 5. Management of large aneurysms, with a diameter  $\geq 5,5$  cm (modified after [47])

[48, 52]. The rupture rate of the aneurysms was 1% in the surveillance group and the overall mortality rate was 5,6% in the early intervention group.

The results of the above mentioned large studies, UKSAT and ADAM were recently included in the COCHRANE study, that underlines the safety and through this the benefits of the Doppler ultrasound surveillance of the AAA with a diameter between 4.0 and 5.5 cm [53].

Performing Doppler Ultrasound surveillance of small aneurysms (4.0-5.5 cm) is safe and recommended for asymptomatic aneurysms. If the aneurysm reaches the 5.5 cm diameter limit, measured by Doppler ultrasound (in male patients), it becomes symptomatic or there is an annual diameter increase of >1cm/year, the patient must be immediately referred for further investigation to the specialised vascular surgery department.

As highlighted, the diameter of the AAA establishes the moment for intervention, but this criteria alone is not enough to establish the indication for the endovascular treatment of the AAA. With new treatment methods new complications occur, requiring further investigations in order to assess the feasibility of the AAA for EVAR. The morphological criteria of the AAA are the ones that can establish or exclude the indication of EVAR. The failure to comply with these criteria, requested also in the instruction manuals of the endoprotheses currently on the market may lead to the increase of the peri- and postoperative complication, reintervention and post-EVAR mortality rate.

An average 34% of AAA is not eligible for EVAR, most of them because of an adverse morphology. [54]

The universal classification system defines the aneurysm in relation with the origin of renal arteries:

- infrarenal, with a segment of normal (undilated) aorta named neck
- pararenal or juxtarenal, when aneurysm originate just after the renals
- suprarenal, the aneurysm includes the origin of renals or above without involvement of the superior mesenteric artery

Another classification employed for EUROSTAR and DREAM trials is shown in **figure 6**, taking into account the distance from the renals and the bifurcation of the aorta as well as the involvement of iliac arteries (the common iliac artery, arriving or not to the bifurcation of iliac arteries, occlusion or stenosis of the common iliac arteries).

The French system proposed by Kieffer & Chiche (2005) is also based on the distal extension of the aneurysm and is comparable with the EUROSTAR classification (Type I-V).

The proximal neck is by far one of the most important anatomic finding in planning an endovascular procedure. It can be classified as shown in **figure 7**.

The diameter of the neck, its length, shape and angulation are to be considered. Aortic neck angulation is defined as the angle between the axes of the proximal infrarenal aorta and the longitudinal axis of the aneurysm. It is classified as: mild < 40 degrees, moderate < 60dgr, and severe > 60dgr.

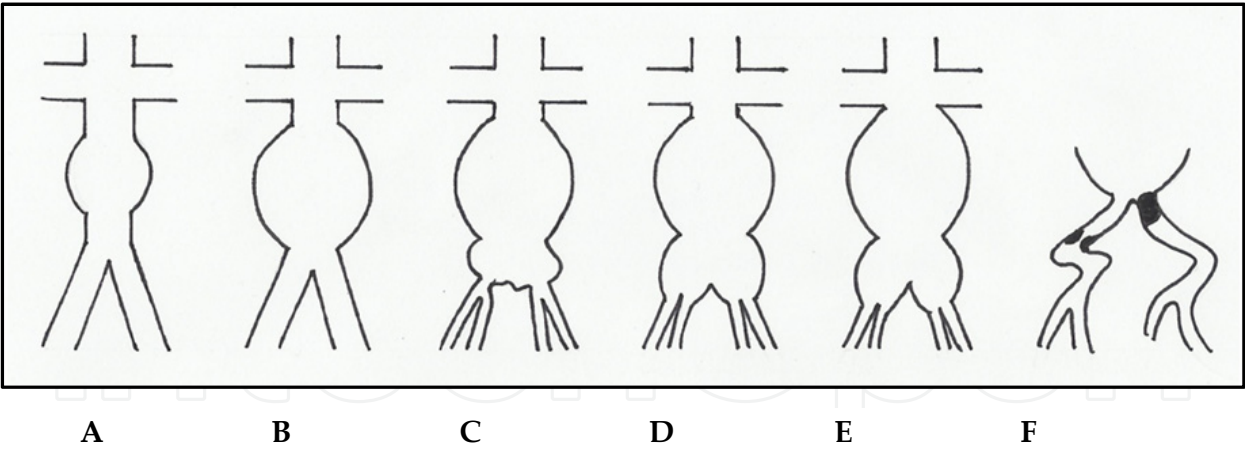


Figure 6. Classification of AAA (modified after [40])

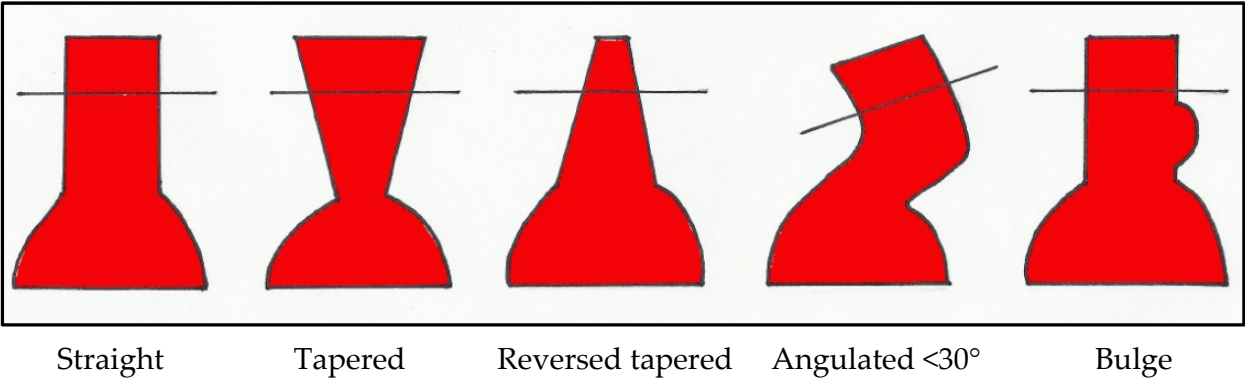


Figure 7. Morphology of the aortic neck (modified after [40])

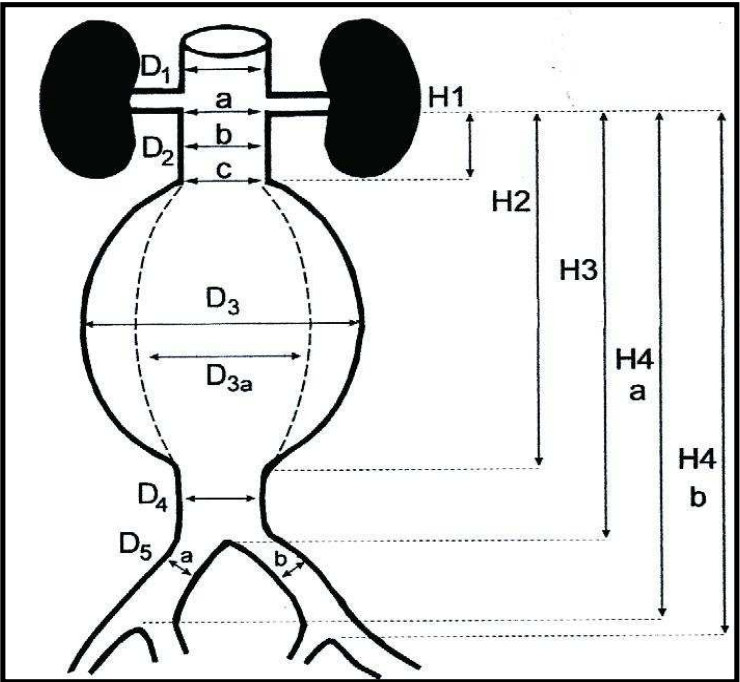


Figure 8. Preoperative measurements (EUROSTAR)



The neck is the place where the endoprotheses are fixed and sealed. Seal is the apposition of the outer surface of the endograft to the luminal surface of the aorta in order to exclude the aneurysm sac from the systemic pressure. Fixation is the counterforce that prevents migration and helps to maintain seal.


Concerning the iliac arteries, the landing zone of the majority of grafts, we are interested in patency and diameter, length of the common iliac artery, shape or aneurismal, angulation or tortuosity and calcifications.

**Figure 8** shows a preoperative scheme for planning an endovascular repair showing all the anatomical features discussed above.(after [40])

## 5. Types of endoprotheses in use

The grafts are classified in different manners. From the anatomic point of view, they can be: bifurcated (Ao bi-iliac), Ao – uni-iliac and tube (for Ao – Aortic – these were the most used, but now they are out of the market). They can be modular (most of them) or unibody (Powerlink).

**Figure 9** shows the images of some endoprosthesis in use today: modular (a,b,c) and unibody (d).



**Figure 9.** Most used endoprosthesis

The modular devices have at least two component grafts. The main body deployed on the neck of the aneurysm (*“hanging from the Aorta”*) and the two legs that arrives on the common iliac arteries. The unibody prostheses build up the endoluminal channel from the bottom to the top, sitting on the aortic bifurcation (concept of anatomical fixation) [55]. This prevents distal migration of the endoprotheses.

The characteristics of the most used endografts [56, 57] are shown in the **table 2**:

Endograft characteristics							
Device	Material	Configuration	Deployment	Fixation	Aortic graft diam.	Iliac graft diam.	Supra-renal stent
<b>Zenith</b> (Cook)	Polyester	Modular	Self-expanding	Compression-fit and barbs	22-36	8-24	Yes
<b>Talent</b> (Medtronic)	Polyester	Modular	Self-expanding	Compression-fit	24-34	8-24	Yes
<b>Excluder</b> (Gore)	ePTFE	Modular	Self-expanding	Compression-fit and anchors	23/26/28.5	12-14.5	No
<b>Anaconda</b> (Terumo)	Twilleave	Modular	Self-expanding	Compression-fit and hooks	19.5-34	9-18	No
<b>Powerlink</b> (Endologix)	ePTFE	One-piece	Self-expanding	Compression-fit	25/28	16	Optional
<b>E-Vita</b> (Jotec)	Polyester	Modular	Self-expanding	Compression-fit	24/34	14-26	yes

**Table 2.** The characteristics of the most used endografts [56, 57]

The characteristics of an ideal stent graft are:

- Low overall cost,
- Stent-graft size ranging,
- Long durability (metallic ultrastructure + graft material),
- Good biocompatibility and sealing capacity,
- Delivery device flexibility, lowest delivery device size,
- Radial force stability,
- Customization

The new results of the endovascular management of AAA (by type of endograft) are shown in **table 3** (retrospective or prospective studies) published in 2010 [58-63].

EVAR is not a procedure without complications[64-66]. One of the most redoubtable are the *endoleak* [67]. They are defined as persistence of the blood flow outside the lumen of the endograft, but within the aneurismal sac [68]. An endoleak may perfuse the aneurysm sac leading to aneurysm expansion and may be rupture. It represents the inability to obtain or maintain secure seal between the aortic wall and the graft [1]. The incidence of endoleaks is in range of 14%. They are classified in four types (from I to IV) [see the **table 4** [1] modified].

The technique of introduction and deployment of the endograft is shown in **figure 10**. The access sites are the two femoral arteries. The anaesthesia required is general anaesthesia or loco-regional (peridural) [69].

Device	Author	Study Type	N° cases	Period	Outcome		Clinical success
					Peri OP mortality	Limb patency 24months	
<b>Anaconda</b> (Terumo)	Freyrie [58]	Prospective single center	127	2005-2009	0	96,7	100
<b>Excluder</b> (Gore)	Ghotbi [59]	Retro-spective	100	2006-2009	0	100	100
<b>Endourant</b> (Medtronic)	Bockler [60]	“Engage” prospective	180	2008-2009	1,7	100	99,4
<b>Zenith</b> (Cook)	Bequemin [61]	Prospective single center	212	2000-2004	0,9		99,5
<b>Powerlink</b> (Endologix)	Krajcer [62]	Prospective single center	50	2008-2010	0	100	98
<b>Evita</b> (Jotec)	Moulakakis [63]	Retro-spective single center	30	2008-2009	0	100	100

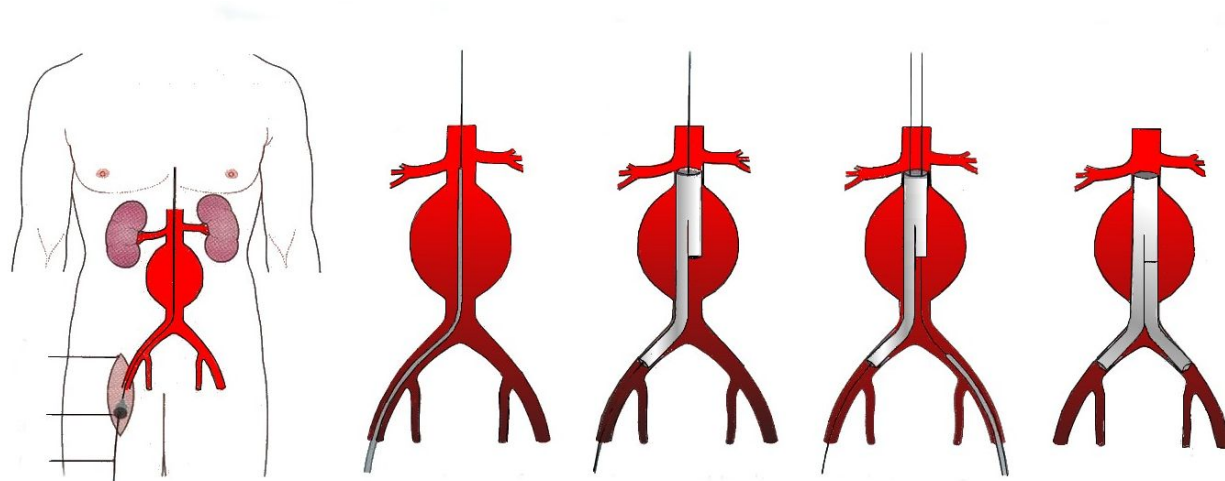
**Table 3.**

<b>I. Attachment site leaks</b>
- Proximal end of endograft
- Distal end of endograft
- Iliac occlude [plug]
<b>II. Branch leaks (collateral back bleeding)</b>
- simple (one)
- complex (two or more branches)
<b>III. Graft defect (modular dissociation)</b>
- minor < 2mm
- major ≥ 2 mm
<b>IV. Graft material porosity</b>

**Table 4.** Classification of Endoleaks [1]

Both types I and III are significant risk factors for late aneurysm rupture and should be treated. Types II are considered benign and type IV usually resolves spontaneously during the post procedure period.

With this procedure, we can reduce blood lost (using also devices like the cell-saver) and consequent transfusion requirement, ITU and hospital stay. More patients can be treated where comorbidity previously excluded them. The follow-up is done by using CT scan exams at 1, 3, 6 and 12 months after the procedure. There are changes in the aneurysm volume after endovascular repair in terms of shrinking [61,70,71].



**Figure 10.** Schema of modular endograft deployment

## 6. Operative data and results (Nürnberg experience and Army's Clinic Center for Cardiovascular Diseases, Bucharest)

We have conducted a prospective, randomized study starting from 1994, including patients diagnosed with infrarenal aortic aneurysm with a diameter  $\geq 5.5$  cm. The purpose of this study was to assess the results of abdominal aortic aneurysm repair of two large volume centers, in terms of perioperative, early and midterm complications, reintervention rate and mortality.

*Exclusion criteria were:* Presence of comorbidities that could affect the postoperative surveillance: Renal insufficiency with serum creatinine level  $> 1.5$  mg/dl, serum urea  $> 50$  mg/dl, mental illnesses, hypersensitivity to the contrast agent, unable to be followed as an outpatient, claustrophobia, the presence of previously implanted metal devices: pace makers, mechanical heart valves etc.

*Collected data:* The collected data was entered in an excel database. Patient demographics and other variables were introduced, like:

- Qualitative variables: endovascular treatment indication, name and type of prosthesis used, vascular access method (percutaneous puncture of the femoral artery, surgical incision, temporary iliac conduit), type of anaesthesia, postoperative complications occurred (endoleak, endograft migration, kinking)
- Continuous quantitative variables: pre- and postoperative data on aneurysm morphology determined by CTA preoperatively and by DUS and CTA postoperatively (maximal anterior-posterior and transverse dimension of the aneurysm sac, length of the aneurysm, size and morphological changes of the aneurysm neck, the distance between the aneurysm and the emergence of the renal arteries, common iliac artery length and diameter) duration of intervention, the amount of blood loss, reinterventions.

In Nürnberg, we started endovascular treatment in 1994 with Ancure stent-graft. In our 14-years experience of 1502 cases (ending dec. 2007) we have used 13 different endografts.

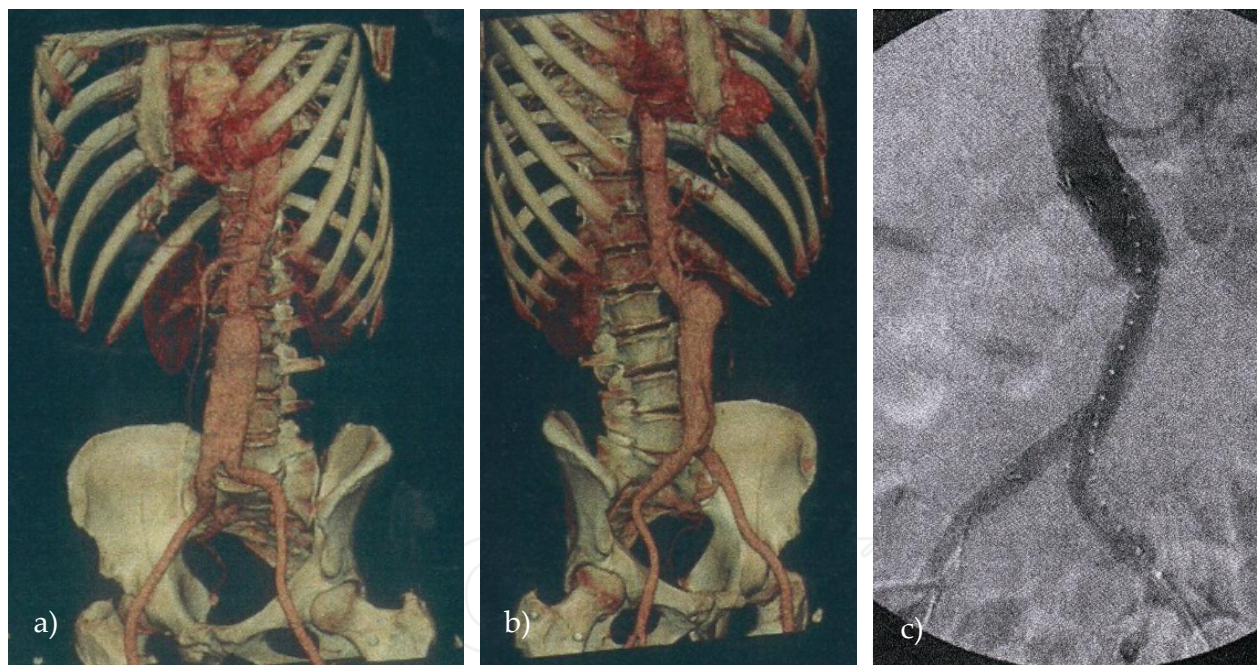


From them, 1391 were men and 111 women, with a mean age of 71.5 years (41-98). The median follow up was 41 months (1.0-98) and the AAA had a mean diameter of 52.4 cm. For short and angulated necks we prefer now the Powerlink (Irvine, CA, USA) device, which we have started in 1999 [72]. Ending Dec. 2007, 519 cases were done using Powerlink grafts.

The 30 day mortality was 1.7%. The total reintervention rate was 5.3%, while no distal migration, conversion or post Evar rupture occurred. Using this device we arrive to treat endovascularly 85-90% of the infrarenal AAAs in our hospital.

At the **Army's Clinic Center for Cardiovascular Diseases**, Bucharest, between July 2008 - December 2010, 17 patients underwent EVAR for Abdominal Aortic Aneurysm (AAA), with age range between 49-82 years and aneurysm mean diameter  $7.1 \pm 0.5$  cm (range: 5.4 – 8.2 cm) [73].

The preoperative assessment was achieved using Doppler Ultrasound (DUS), Multislice CT, and sometimes DSA (Digital Substraction Angiography). The measurements for the graft type and dimensions were done according to the Multislice CT analyzing. (**Figure 11 a, b and c**).



**Figure 11.** a), b) Preoperative multislice CT of a infrarenal AAA, with a suitable anatomy (2.2 cm neck length, no involvement of iliac arteries, 5.3 cm transversal diameter. c) Preoperative subtraction angiography – with a catheter measuring the real length of the Aorta

The EVAR devices used for these patients were:

- Anaconda (Vascutek, Terumo, Inchinnan, Scotland)-1 patient
- Talent (Medtronic, Santa Rosa, CA, USA) -3 patients
- Powerlink (Endologix, Irvine, CA, USA) – 7 patients
- EVITA (Iotec, Hechingen, Germany)- 6 patients.

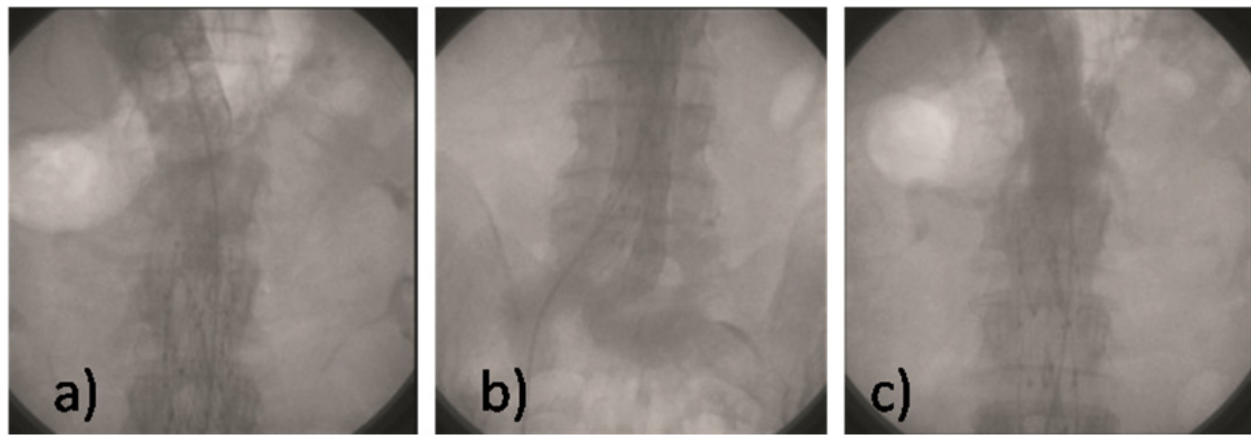


The access was bifemoral, through open femoral incision, with peridural anaesthesia.

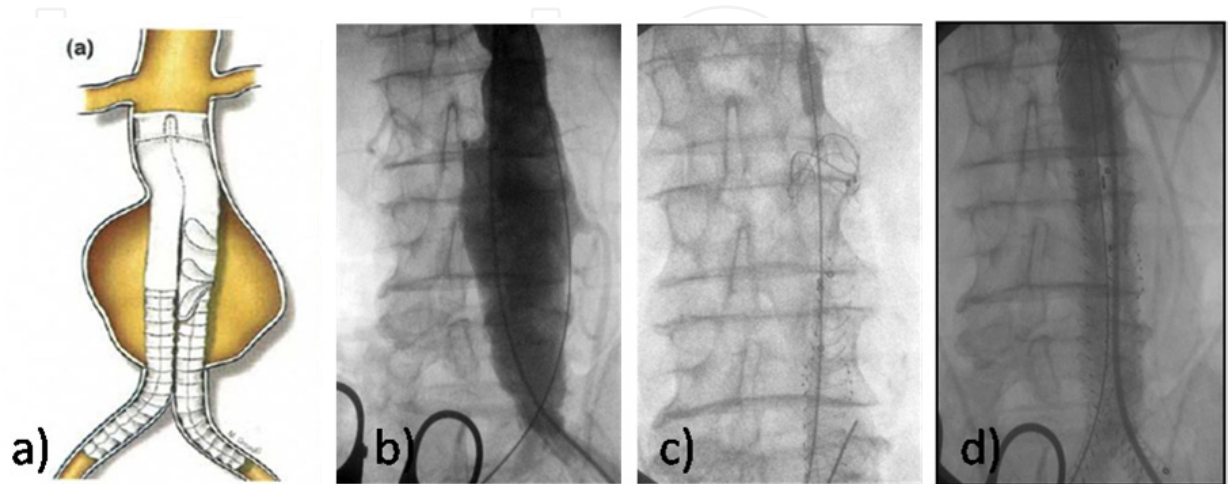
Until present they followed our institutions surveillance protocol, that consisted of both DUS and CTA examination at 1,3,6,12 months and yearly after EVAR. None of them went through all of the surveillance dates (due to high examination costs) but each has at least 3 sets of examinations, one set consisting of both DUS and CTA.

The technical success rate was 100%, with no perioperative and postoperative complications regarding endoleaks, graft migration and graft component failure. 4 patients had access site complications, 3 had groin haematomas that reabsorbed after approximately 1 week and 1 returned with an infection at the level of the inguinal incision, which resolved also with wound care. There were no conversions to open repair up to present. The stent-graft patency rate at this point at these patients is 100%.

**Figures 12 and 13** show two cases of AAAs treated with two different devices and two different strategies: Anaconda (Terumo) device and Powerlink (Endologix) stent graft.



**Figure 12.** AAA treated with Powerlink Endograft **a)** Proximal extension; **b)** Main body of the stent-graft; **c)** The two iliac segments of Powerlink® system



**Figure 13.** **a)** Anaconda endograft for infrarenal abdominal aortic aneurysm therapy; **b)** Angiography at the beginning of the procedure; **c)** The main body of the stent; **d)** The two iliac Anaconda system

## 7. Particular situations

### 7.1. Ruptured AAA

**In open repair of ruptured AAAs the perioperative mortality ranges between 30% and 65%**[74,75]. Emergency EVAR is an alternative in selected patients with RAAA. The first report of emergency repair of an AAA was in 1994. Possible advantages are avoiding general anesthesia and laparotomy. Though a major inconvenient is the need of an endovascular team to be available at all times and to assess the preoperative CT scan in order to choose the size of the device. Following the emergent CT scan the anatomical suitability for EVAR was evaluated, including the access vessels [76]. Several modular or unibody devices can be used but aorto-uniliac devices with subsequent fem-fem crossover bypass and occlusion of contralateral iliac artery could also be used. Veith [77] reported in 2009 a series of 57 patients with R-AAA treated endovascularly. 25 of these patients received the **VI graft** (distributed in Europe by Datascope-Maquet), made of a large Palmaz stent attached to a PTFE graft. This graft is used in aortofemoral configuration. This graft is “a one size fits most” because the proximal diameter can vary from 20 to 27mm depending on the balloon inflation pressure. The periprocedural mortality was only 12,3%, in spite of serious medical comorbidities of the patients.

In the series reported by Kapma in 2005 on 253 patients treated with E-EVAR vs open surgery the perioperative mortality was lower (13%) in the Evar group compared with OR (30%  $p=0,021$ ). According to the SVS practical guidelines [31] E-EVAR should be considered for treatment of a R-AAA, if anatomically feasible, with a **strong** level of recommendation and a **moderate** quality of evidence.

### 7.2. Juxtarenal AAA

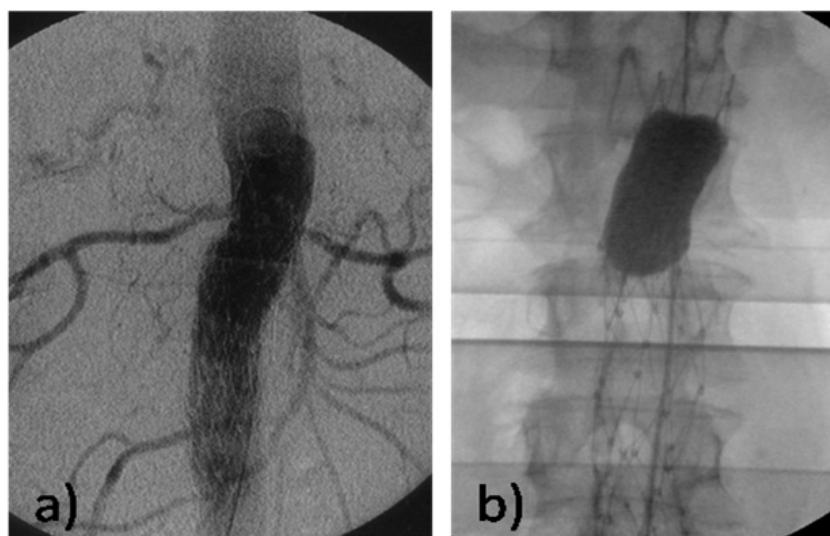
Juxtarenal AAA have short (11-15mm), or very short (< 10mm) necks. The anatomically unsuitable AAAs have short and/or angulated necks. They have a high risk of stent graft distal migration and proximal type I endoleak, because the inability to provide a sufficient proximal landing zone to secure fixation and seal. The strategy for treating this challenging AAAs is to build up the endoluminal exclusion system from the aortic bifurcation to the renal artery level with suprarenal fixation. At Nürnberg Hospital we used the Powerlink unibody bifurcated stent graft with a long suprarenal cuff. A Palmaz stent can be used for proximal fixation in hostile necks (short necks with severe angulation).

Suprarenal fixation does not lead to a significant increase of acute renal events (renal insufficiency, high blood pressure) compared with infrarenal fixation [72]

**Figure 14** shows an angiography of AAA treated with a Powerlink graft with suprarenal fixation; for better sealing a proximal ballooning at the end of the procedure was performed.

### 7.3. AAA with iliac extension

The iliac extension of the AAAs can put technical problems in choosing the graft, especially if the iliac aneurysm reaches the bifurcation of the iliac artery (fig.11a). In this situation, the

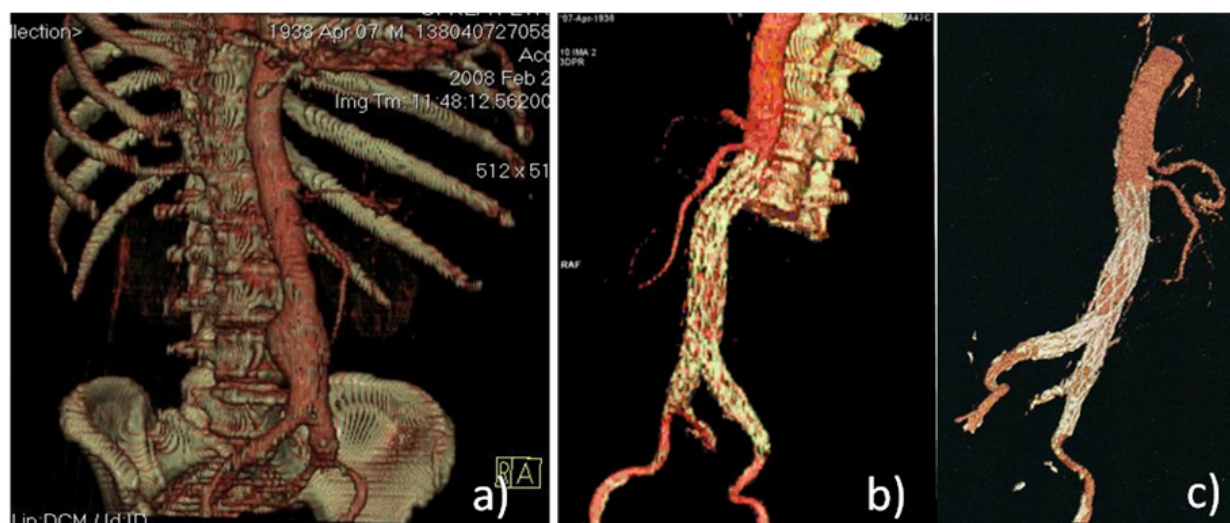

**Figure 14.** a) After supraceliac prox. Cuff; b) Proximal ballooning. Fenestrated grafts are now available to treat juxtarenal AAA [78-80]

leg of the graft should land on the external iliac artery, covering the hypogastric artery (post-operation complications can occur like buttock claudication). In the case of planning to cover one hypogastric artery, we should close the artery (by coiling for ex.) a few days before implanting the endograft, in order to prevent distal type II endoleak.

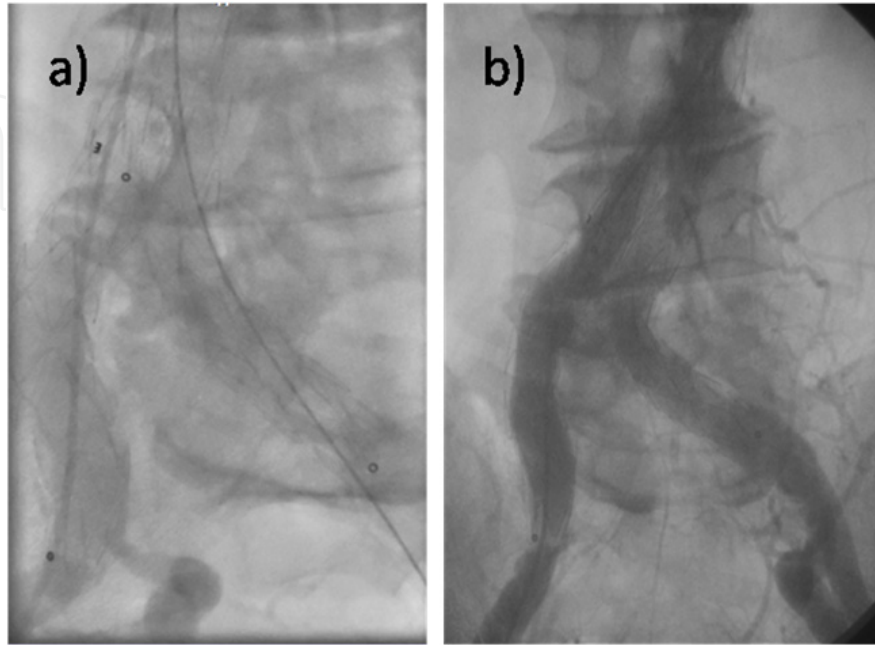
**Figure 15** shows a 72 year old patient treated at the Army's Center for Cardiovascular Diseases, using a Powerlink graft with left iliac graft extension - left hypogastric artery was occluded with coils 24h before the intervention.

In order to preserve the hypogastric artery, custom made, fenestrated or branched endografts can be used. Although this procedure was performed to prevent pelvic ischemia, this is not always the case. **Figure 16** presents a case of a 75 year old male patient with AAA



**Figure 15.** Patient O.P., 72 years old, preoperative multislice CT; a) AAA with left iliac extension; b) multislice CT-Scan at 3 months after EVAR with PowerLink endoprosthesis; c) multislice CT-Scan 2 years after EVAR with PowerLink endoprosthesis.

treated by EVAR with a fenestrated endograft that presented to our department with buttock claudication 6 months after EVAR. The performed angiography evidenced an occluded right hypogastric artery. Conservative treatment with Vasaprostan 20µg was instituted with good results.



**Figure 16.** 75 year old male patient with AAA treated by EVAR Completion angiography after EVAR using a fenestrated endograft for the right hypogastric artery. **b)** Angiography performed 6 months after the intervention showing an occluded right hypogastric artery.

#### **7.4. AAA and comorbidities: Coronary artery disease, carotid stenosis.**

It is well known today that cardiac complications of patients with AAAs treated endovascularly is between 3 to 7%[31]. In order to avoid useless coronarographic investigations, we have to identify clinical parameters to indicate prior myocardial revascularization (surgery or stenting). Kieffer and Coriat, in a study published in 1999, on 270 patients operated for terminal Aorta pathology (aneurismal or stenotic) show an incidence of 55% of coronary stenosis in the AAA population which requires in 25% of cases myocardial revascularization. The risk factors which were identified were age >65 years and history of myocardial infarction. Stable angina with left main disease, or triple-vessel disease, as well as patients with two vessel disease that includes proximal LAD are candidates for preoperative coronary revascularization. The coronary intervention should be done prior to AAA treatment in one month interval. However the perioperative mortality can arrive to 25% (with extracorporeal circulation and cardiac arrest)

**The carotid stenosis with a hemodynamic impact has a prevalence of 10.5% in the AAA patients.**

**Coronary** and/or carotid lesions, treated or not, represent a significant risk factor for postoperative death. For this, systematic preoperative screening is mandatory [81,82].



**Steinmetz** published in 2008 an analysis of outcome after using high risk criteria selection to surgery vs. EVAR [83]. The conclusion was that high risk criteria cannot be decisive in the choice of treatment.

## 8. Future developments

### 8.1. Totally percutaneous procedures

Because local groin wound complications as a result of the exposure of the two common femoral arteries are not negligible [84], surgeons and engineers tried to develop alternative access techniques. One of them is the fully percutaneous procedure. The main device available is Perclose ProstarXL (Abbott). For technical success patient and device selection should be done. Severe femoral artery calcification, scarred groins, femoral artery aneurysms are contraindications for the use of these devices. The overall related complications were 4.4%. Among them infection and artery thrombosis are the most redoubtable. The hospital stay is shorter in patients undergoing P-EVAR (2.7 days vs. 3.5 days) compared with EVAR. In conclusion, P-EVAR appears safe and effective in selected patients.

### 8.2. MRI devices

A new research field in our days is based on the hypotheses that the endografts can be visualized and navigated in vivo solely under Rt-MRI (real time magnetic resonance imaging). MRI can provide immediate assessment of endograft apposition and aneurysm exclusion. MRI offers also better soft tissue visualization, detecting type I endoleaks by depiction of complex 3D anatomy.

The technique is now applicable on murine models of AAA [85]. They have used a passive commercial endograft, image based on metal MRI artefacts, and active homemade endografts incorporating MRI receiver coils (antennae). Active devices proved to be most useful. The MRI images proved graft apposition and aneurysm exclusion. MRI imaging also permits immediate post-procedural anatomical and functional evaluation of the successful procedure.

In conclusion, MRI may be equivalent or superior to computed tomography for procedure planning and surveillance of the endografts. Future development of active devices is required, in order to have a commercial graft that can be used in clinical testing and practice.

## 9. Conclusions

Our results show that in the modern era of abdominal aortic aneurysm treatment EVAR is an appropriate treatment for selected patients, especially those at high risk for open surgical repair.

The future of EVAR as the potential gold standard for aortic aneurysm therapy rests upon the vision and creativity of both surgeons and technology innovators to realize the potential of endovascular interventions, and take them toward a broader and more effective portfolio of techniques and devices that will define the XXI-st Century Endovascular Aortic Surgery.



## Author details

Ionel Droc\* and Blanca Calinescu

*Cardiovascular Surgery Department, Army's Clinic Center for Cardiovascular Diseases, Bucharest, Romania*

Dieter Raithel

*Klinikum Nürnberg Sud, Nürnberg, Germany*

## 10. References

- [1] Jaunoo S (2008) Endovascular aneurysm repair (EVAR). *International Journal of Surgery*. 6:266-269.
- [2] Wyatt M.G (1999) Aneurysmal disease. In: Davies A.H, editor. *Vascular Surgery Highlights 1998-1999*. Oxford: Health Press. pp. 41-48.
- [3] Garcia-Madric C, Josa M, Riambau V, Mestres C.A, Muntana J, Mulet J (2004) Endovascular versus open surgical repair of abdominal aortic aneurysm: a comparison of early and intermediate results in patients suitable for both techniques. *Eur J Vasc Endovasc Surg*. 28:365-372.
- [4] Melton L, Bickerstaff L, Hollier L et al. (1984) Changing incidence of abdominal aortic aneurysms: A population-based study. *Am J Epidemiol*. 120:379-386.
- [5] Reilly J.M, Tilson M.D (1989) Incidence and etiology of abdominal aortic aneurysms. *Surg Clin North Am*. 69:705-711.
- [6] Pannu H, Fadulu V.T, Chang J et al. (2005) Mutations in transforming growth factor-beta receptor type II cause familial thoracic aortic aneurysms and dissections. *Circulation*. 112:513-520.
- [7] Busuttil R.W, Rinderbrieht H, Flesher A et al. (1982) Elastase activity: the role of elastase in aortic aneurysm formation. *J Surg Res*. 32:214-217.
- [8] Safi H.J (2007) Thoracic aortic aneurysms: classification, incidence, etiology, natural history and results. In: Lumsden A.B, Lin P.H, Changyi Chen, Parodi J.C, editors. *Advanced Endovascular Therapy of Aortic Disease*. Malden: Blackwell Publishing. pp. 25-30
- [9] Ailawadi G, Eliason J.L, Upchurch G.R Jr. (2003) Current concepts in the pathogenesis of abdominal aortic aneurysm. *J.Vasc Surg*. 38:584-588.
- [10] Grootenboer N, Bosch J.L, Hendriks J.M, van Sambeek M.R.H.M (2009) Epidemiology, Aetiology, Risk of Rupture and Treatment of Abdominal Aortic Aneurysms: Does Sex Matter?. *Eur J Vasc Endovasc Surg*. 38:278-284.
- [11] Mosorin M, Junoven J, Biancari F, Satta J, Surcel H.M, Leinonen M et al. (2001) Use of doxycycline to decrease the growth rate of abdominal aortic aneurysms: A randomized, double-blind, placebo-controlled pilot study. *J Vasc Surg*. 34:606-610.
- [12] Takagi H, Manabe H, Kawai N, Goto S, Umemoto T (2009) Plasma Fibrinogen and D-dimer Concentrations are Associated with the presence of Abdominal Aortic Aneurysm: A Systematic Review and Meta-analysis. *Eur J Vasc Endovasc Surg*. 38:273-277

---

\* Corresponding Author

- [13] Freestone T, Turner R.J, Coady A, Higman D.J, Greenhalgh R.M, Powell J.T (1995) Inflammation and matrix metalloproteinases in the enlarging abdominal aortic aneurysm. *Arterioscler Thromb Vasc Biol.* 15(8):1145-51.
- [14] McMillan W.D, Tamarina N.A, Cipollone M, Johnson D.A, Parker M.A, Pearce M.A, Pearce W.H (1997) Size matters: the relationship between MMP-9 expression and aortic diameter. *Circulation.* 96(7):2228-32.
- [15] Pyo R, Jason L.K, Shipley M, Curci J.A, Mao D, Ziporin S.J et al. (2000) Targeted disruption of matrix-metalloproteinase-9 (gelatinase B) suppresses development of experimental abdominal aortic aneurysms. *J Clin Invest.* 105:1641-9.
- [16] Thompson R.W, Parks W.C. (1996) Role of matrix metalloproteinases in abdominal aortic aneurysms. *Ann NY Acad Sci.* 800:157-174.
- [17] Newman K.M et al. (1994) Identification of matrix metalloproteinases 3 (stromelysin-1) and 9 (gelatinase B) in abdominal aortic aneurysms. *Arterioscler Thromb.* 14: 1315-1320.
- [18] Hovsepian D.M, Ziporin S.J, Sakurai M.K, Lee J.K, Curci J.A, Thompson R.W (2000) Elevated plasma levels of matrix metalloproteinase-9 in patients with abdominal aortic aneurysms: a circulating marker of degenerative aneurysm disease. *J Vasc Interv Radiol.* 11(10):1345-52
- [19] Petersen E, Wagberg F, Angquist K.A (2002) Proteolysis of the Abdominal Aortic Aneurysm Wall and the Association with Rupture. *Eur J Vasc Endovasc Surg.* 23:153-157.
- [20] Hellenthal F.A.M.V.I et al. (2012) Plasma Levels of Matrix Metalloproteinase-9: A Possible Diagnostic Marker of Successful Endovascular Aneurysm Repair. *Eur J Vasc Endovasc Surg.* 43:171-172.
- [21] Wilson W.R.W, Anderton M, Choke E.C, Dawson J, Loftus I.M, Thompson M.M (2008) Elevated Plasma MMP1 and MMP9 are Associated with Abdominal Aortic Aneurysm Rupture. *Eur J Vasc Endovasc Surg.* 35:580-584.
- [22] Karlsson L, Bergqvist D, Lindback J, Parsson H (2009) Expansion of Small-diameter Abdominal Aortic Aneurysms is Not Reflected by the Release of Inflammatory Mediators IL-6, MMP-9 and CRP in Plasma. *Eur J Vasc Endovasc Surg.* 37:420-424.
- [23] Vega de Ceniga M, Esteban M, Quintana J.M, Barba A, Estallo L, De la Fuente N, Vivians B, Martin-Ventura J.L (2009) Search for Serum Biomarkers Associated with Abdominal Aortic Aneurysm Growth- A Pilot Study. *Eur J Vasc Endovasc Surg.* 37:297-299.
- [24] Al-Barjas H.S, Ariens R, Grant P, Scott J.A (2006) Raised plasma fibrinogen concentration in patients with abdominal aortic aneurysm. *Angiology.* 57:607-14.
- [25] Lindholt J.S et al. (2011) Insulin-like Growth Factor I- A Novel Biomarker of Abdominal Aortic Aneurysms. *Eur J Vasc Endovasc Surg.* 42:560-562.
- [26] Urbonavicius S, Urbonaviciene G, Honore B, Henneberg E.W, Vorum H, Lindholt J.S (2008) Potential Circulating Biomarkers for Abdominal Aortic Aneurysm Expansion and Rupture – a Systematic Review. *Eur J Vasc Endovasc Surg.* 36:273-280.
- [27] Parodi J.C, Palmaz J.C, Barone H.D (1991) Transfemoral intraluminal graft implantation for abdominal aortic aneurysms. *Ann Vasc Surg.* 5:496.
- [28] Parodi J.C (1995) Endovascular repair of abdominal aortic aneurysms. In: Chuter T, Donayre C.E, White R.A, editors. *Endoluminal Vascular Prostheses.* Brown and Company. pp.37-55.

- [29] Matsumura J.S, Brewster D.C, Makaroun M, Naftel D.C (2003) A multicenter controlled clinical trial of open versus endovascular treatment of abdominal aortic aneurysm. *Journal of Vascular Surgery*. 37:262-271.
- [30] Goncalves F.B, Rouwet E.V, Metz R, Hendriks J.M, Vrancken Peeters M.P, Muhs B.E, Verhagen H.J (2010) Device-specific outcomes after endovascular abdominal aortic aneurysm repair. *J Cardiovasc Surg*. 51:515-531.
- [31] Chaikof E.L, Brewster D.C, Dalman R.L, Makaroun M, Illig K.A, Sicard G.A, Timaran C.H, Upchurch Jr G.R, Veith F.J (2009) SVS practice guidelines for the care of patients with abdominal aortic aneurysm: Executive summary. *Journal of Vascular Surgery*. 50:880-896.
- [32] Mani K, Lees T, Beiles B, Jensen L.P, Venermo M, Simo G, Palombo D et al. (2011) Treatment of Abdominal Aortic Aneurysm in Nine Countries 2005-2009: A Vascunet Report. . *Eur J Vasc Endovasc Surg*. 42; 598-607.
- [33] EVAR Trial Participants (2005) Endovascular aneurysm repair versus open repair in patients with abdominal aortic aneurysm (EVAR trial 1): randomised controlled trial. *The Lancet*. 365: 2179-86.
- [34] Prinssen M, Verhoeven E.L, Buth J, Cuypers P.W, van Sambeek M.R, Balm R et al. (2004) A randomised trial comparing conventional and endovascular repair of abdominal aortic aneurysms. *N Engl J Med*. 351:1607-18.
- [35] Aljabri B, Al Wahaibi K, Abner D, Mackenzie K.S, Corriveau M.M, Obrand D.I et al. (2006) Patient-reported quality of life after abdominal aortic aneurysm surgery: a prospective comparison of endovascular and open repair. *J Vasc Surg*. 44(6):1182-7.
- [36] Schroeder T.V (2006) Registries on endovascular aortic aneurysm repair. Pitfalls and benefits. *J Cardiovasc Surg*. 47:55-59.
- [37] Thomas S.M, Gaines P.A, Beard J.D (2001) Short-term (30 day) outcome of endovascular treatment of abdominal aortic aneurysm: results from the prospective Registry of Endovascular Treatment of Abdominal Aortic Aneurysm (RETA). *Eur J Vasc Endovasc Surg*. 21:57-64.
- [38] Harris P.L, Vallabhanemi R, Desgranges P, Becquemin J.P, van Marrewijk C, Laheij R (2000) Incidence and risk factors of late rupture, conversion, and death after endovascular repair of infrarenal aortic aneurysms: The EUROSTAR experience. *Journal of Vascular Surgery*. 32:739-749.
- [39] Lifeline Registry of EVAR Publications Committee (2005) Lifeline registry of endovascular aneurysm repair: Long-term primary outcome measures. *Journal of Vascular Surgery*. 42:1-10.
- [40] Hobo R, Sybrandy J, Harris P.L, Buth J (2008) Endovascular repair of abdominal aortic aneurysms with concomitant common iliac artery aneurysm: outcome analysis of the EUROSTAR experience. *Journal of Endovascular Therapy*. 15:12-22.
- [41] The EVAR trial participants (2004) Comparison of endovascular aneurysm repair with open repair in patients with abdominal aortic aneurysm (EVAR trial 1), 30-day operative mortality results: randomised controlled trial. *The Lancet*. 364:843-848.
- [42] The EVAR trial participants (2005) Endovascular aneurysm repair and outcome in patients unfit for open repair of abdominal aortic aneurysm (EVAR trial 2): randomised controlled trial. *The Lancet*. 365:2187-2192.

- [43] Beard J.D (2006) EVAR for fit patients: evidence from the randomised trials. In: Wyatt M.G, Watkinson A.F, editors. *Endovascular Therapies- Current Evidence*. United Kingdom: Shrewsbury.pp.29-36.
- [44] Prinssen M, Buskens E, Blankensteijn J.D (2002) The Dutch Randomized Endovascular Aneurysm Management (DREAM) trial background, design and methods. *J Cardiovasc Surg*. 43:379-384.
- [45] Blankensteijn J.D, de Jong S.E, Prinssen M, van der Ham A.C, Buth J (2005) Dutch Randomized Endovascular Aneurysm Management (DREAM) trial group: two-year results of a randomized trial comparing conventional and endovascular repair of abdominal aortic aneurysms. *N Engl J Med*. 352:2398-2405.
- [46] Lederle F.A (2007) The veterans open versus endovascular repair (OVER) trial for AAA - what will it add to EVAR 1 and DREAM? In: Becquemin J.P, Alimi Y.S, editors. *Controversies and Updates in Vascular Surgery 2007*. Minerva Medica. pp.101-102.
- [47] Moll F.L, Powell J.T, Fraedrich G, Verzini F, Haulon S, Waltham M , van Herwaarden J.A, Holt P.J.E, van Keulen J.W, Rantner B, Schlosser F.J.V, Setacci F, Ricco J.B (2011) Management of Abdominal Aortic Aneurysms Clinical Practice Guidelines of the European Society for Vascular Surgery. *Eur J Vasc Endovasc Surg*. 41; S1-S58.
- [48] The UK Small Aneurysm Trial Participants (1998) Mortality results for randomised controlled trial of early elective surgery or ultrasonographic surveillance for small abdominal aortic aneurysms. *The Lancet*. 352:1649-55.
- [49] Lederle F.A, Wilson S.E, Johnson G.R, Reinke D.B, Littooy F.N, Acher C.W et al. (2002) Aneurysm Detection and Management Veterans Affairs Cooperative Study Group. Immediate repair compared with surveillance of small abdominal aortic aneurysms. *N Engl J Med*. 346:1437-44.
- [50] Cao P (2005) Comparison of surveillance vs aortic endografting for small aneurysm repair (CAESAR) trial: study design and progress. *Eur J Vasc Endovasc Surg*. 30:245-51.
- [51] Ouriel K (2009) The pivotal study: a randomised comparison of endovascular repair versus surveillance in patients with smaller abdominal aortic aneurysms. *J Vasc Surg*. 49: 266-9.
- [52] Powell J.T, Brown L.C, Forbes J.F, Fowkes F.G, Greenhalgh R.M, Ruckley C.V et al. (2007) Final 12-year follow-up of surgery versus surveillance in the uk small aneurysm trial. *Br J Surg*. 94: 702-8.
- [53] Ballard D.J, Filardo G, Fowkes G, Powell J.T (2008) Surgery for small asymptomatic abdominal aortic aneurysms. *Cochrane Database Syst Rev*. CD001835.
- [54] Argenteri A, Curci R, Bianchi G, Orlandi M, de Amicis P (2009) Morphology and classifications of abdominal aortic aneurysms. In: Setacci C, Gasparini D, Reimers B, Cremonesi A, Rossi P.T, editors. *Aortic Surgery New Developments and Perspectives*. Minerva Medica. pp. 215-225.
- [55] Raithel D, Qu L, Hetzel G (2007) Adapting the graft to the patient's anatomy: is this a way of solving all the problems? In: Becquemin J.P, Alimi Y.S, editors. *Controversies and Updates in Vascular Surgery 2007*. Minerva Medica. pp.150-156.
- [56] Chisci E, De Donato G, Setacci F, Sirignano P, Galzerano G, Cappelli A, Palasciano G, Setacci C (2009) Standard elective endovascular aortic aneurysm repair (EVAR). In: Setacci C, Gasparini D, Reimers B, Cremonesi A, Rossi P.T, editors. *Aortic Surgery New Developments and Perspectives*. Minerva Medica. pp.227-147.



- [57] Brennan J, Gambardella I (2006) Aortic stent grafts: current availability and applicability. In: Wyatt M.G, Watkinson A.F, editors. *Endovascular Therapies*. tfm Publishing Ltd. pp.1-11.
- [58] Freyrie A, Testi G, Faggioli G, Gargiulio M, Giovanetti F, Serra C, Stella A (2010) Ring-stents supported infrarenal aortic endografts fits well in abdominal aortic aneurysms with tortuous anatomy. *J Cardiovasc Surg*. 51:467-474.
- [59] Ghotbi R, Sotiriou A, Mansur R (2010) New results with 100 Excluder cases. *J Cardiovasc Surg*. 51:475-480.
- [60] Bockler D, Fitridge R, Wolf Y, Hayes P, Silveira P.G, Numan F, Riambau V (2010) Rationale and design of the Endurant Stent Graft Natural Selection Global Postmarket Registry (ENGAGE): interim analysis at 30 days of the first 180 patients enrolled. *J Cardiovasc Surg*. 51:481-491.
- [61] Becquemin J.P, Aksoy M, Marzelle J, Roudot-Thoraval F, Desgranges P, Allaire E, Kobeiter H (2008) Abdominal aortic aneurysm sac behavior following Cook Zenith graft implantation: a five-year follow-up assessment of 212 cases. *J Cardiovasc Surg*. 49:199-206.
- [62] Krajcer Z, Gregoric I (2010) Totally percutaneous aortic aneurysm repair: methods and outcomes using the fully integrated IntuiTrak Endovascular System. *J Cardiovasc Surg*. 51:493-501.
- [63] Moulakakis K.G, Avgerinos E.D, Giannakopoulos T, Papapetrou A, Brountzos E.N, Liapis C.D (2010) Current knowledge on E-vita abdominal endograft. *J Cardiovasc Surg*. 51:533-538.
- [64] Stableford J.A, Maldonado T.S, Berland T, Kim B, Adelman M.A, Pachter H.L, Mussa F (2009) Endograft infection after EVAR. *Endovascular Today*. 8:35-38.
- [65] Franks S.C, Sutton A.J, Bown M.J, Sayers R.D (2007) Systematic review and meta-analysis of 12 years of endovascular abdominal aortic aneurysm repair. *Eur J Vasc Endovasc Surg*. 33:154-171.
- [66] Akkersdijk G.J, Prinssen M, Blankensteijn J.D (2004) The impact of endovascular treatment on in-hospital mortality following non-ruptured AAA repair over a decade: a population based study on 16446 patients. *Eur J Vasc Endovasc Surg*. 28:41-46.
- [67] Gleason T.G (2009) Endoleaks after endovascular aortic stent-grafting: impact, diagnosis and management. *Semin Thorac Cardiovasc Surg*. 21:363-372.
- [68] White G.H, Yu W, May J et al. (1997) Endoleak as a complication of endoluminal grafting of abdominal aortic aneurysms: classification, incidence, diagnosis and management. *J Endovasc Surg*. 4:152-168.
- [69] Ricotta II J, Malgor R.D, Oderich G.S (2009) Traitement endovasculaire des anevrysmes de l'aorte abdominale: 1ere partie. *Annales de Chirurgie Vasculaire*. 23:864-878.
- [70] van Keulen J.W, van Prehn J, Prokop M, Moll F.L, van Herwaarden J.A (2009) Potential value of aneurysm sac volume measurements in addition to diameter measurements after endovascular aneurysm repair. *Journal of Endovascular Therapy*. 16:506-513.
- [71] Wolf Y.G, Tillich M, Lee A, Fogarty T.J, Zarins C.K, Rubin G.D (2002) Changes in aneurysm volume after endovascular repair of abdominal aortic aneurysm. *Journal of Vascular Surgery*. 36:305-309.



- [72] Qu L, Raithel D (2008) Experience with the Endologix Powerlink endograft in endovascular repair of abdominal aortic aneurysms with short and angulated necks. *Perspectives in Vascular Surgery and Endovascular Therapy*. 20:158-166.
- [73] Droc I, Raithel D, Pinte F, Nita D, Deaconu S, Popovici A, Molnar F, Finichi R, Candea B, Goleanu V (2008) Abdominal aortic aneurysms treatment - new devices for endovascular treatment. *Romanian Journal of Cardiovascular Surgery*. 7:235-242.
- [74] Harkin D.W, Dillon M, Blair P.H, Ellis P.K, Kee F (2007) Endovascular ruptured abdominal aortic aneurysm repair (EVRAR): a systematic review. *Eur J Vasc Endovasc Surg*. 34:673-681.
- [75] Richards T, Goode S.D, Hinchliffe R, Altaf N, MacSweeney S, Braithwaite B (2009) The importance of anatomical suitability and fitness for the outcome of endovascular repair of ruptured abdominal aortic aneurysm. *Eur J Vasc Endovasc Surg*. 38:285-290.
- [76] Perrott S, Puckridge P.J, Foreman R.K, Russell D.A, Spark J.I (2010) Anatomical suitability for endovascular AAA repair may affect outcomes following rupture. *Eur J Vasc Endovasc Surg*. 40:186-190.
- [77] Veith F.J, Cayne N (2009) Endovascular repair for ruptured abdominal aortic aneurysms: why the results vary. *Vascular Disease Management*. 6:165-170.
- [78] Amiot S, Haulon S, Becquemin J.P, Magnan P.E, Lermusiaux P, Goueffic Y, Jean-Baptiste E, Cochenne F, Favre J.P (2010) Fenestrated endovascular grafting: the french multicentre experience. *Eur J Vasc Endovasc Surg*. 39:537-544.
- [79] Greenberg R.K, Sternbergh W.C, Makaroun M, Ohki T, Chuter T, Bharadwaj P, Saunders A (2009) Intermediate results of a United States multicenter trial of fenestrated endograft repair for juxtarenal abdominal aortic aneurysms. *Journal of Vascular Surgery*. 50:730-737.
- [80] O'Neill S, Greenberg R.K, Haddad F, Resch T, Sereika J, Katz E (2006) A prospective analysis of fenestrated endovascular grafting: intermediate-term outcome. *Eur J Vasc Endovasc Surg*. 32:115-123.
- [81] Budde R.P.J, Huo F, Cramer M.J.M, Doevendans P.A, Bots M.L, Moll F.L, Prokop M (2010) Simultaneous aortic and coronary assessment in abdominal aortic aneurysm patients by thoraco-abdominal 64-detector-row CT angiography: estimate of the impact on preoperative management: a pilot study. *Eur J Vasc Endovasc Surg*. 40:196-201.
- [82] Jean-Baptiste E, Hassen-Khodja R, Bouillanne P.J, Haudebourg P, Declémy S, Batt M (2007) Endovascular repair of infrarenal abdominal aortic aneurysms in high-risk-surgical patients. *Eur J Vasc Endovasc Surg*. 34:145-151.
- [83] Steinmetz E, Abello N, Kretz B, Gauthier E, Bouchot O, Brenot R (2010) Analysis of outcome after using high-risk criteria selection to surgery versus endovascular repair in the modern era of abdominal aortic aneurysm treatment. *Eur J Vasc Endovasc Surg*. 39:403-409.
- [84] Malkawi A.H, Hinchliffe R.J, Holt P.J, Loftus I.M, Thompson M.M (2010) Percutaneous access for endovascular aneurysm repair: a systematic review. *Eur J Vasc Endovasc Surg*. 39:676-682.
- [85] Raman V.K, Karmarkar P.V, Guttman M.A et al. (2005) Real-time magnetic resonance-guided endovascular repair of experimental abdominal aortic aneurysm in swine. *J Am Coll Cardiol*. 45:2069-2077.