

# We are IntechOpen, the world's leading publisher of Open Access books Built by scientists, for scientists

6,900

Open access books available

186,000

International authors and editors

200M

Downloads

Our authors are among the

154

Countries delivered to

TOP 1%

most cited scientists

12.2%

Contributors from top 500 universities



WEB OF SCIENCE™

Selection of our books indexed in the Book Citation Index  
in Web of Science™ Core Collection (BKCI)

Interested in publishing with us?  
Contact [book.department@intechopen.com](mailto:book.department@intechopen.com)

Numbers displayed above are based on latest data collected.  
For more information visit [www.intechopen.com](http://www.intechopen.com)



---

# Soft-tissue Response in Orthognathic Surgery Patients Treated by Bimaxillary Osteotomy – Cephalometry Compared with 2-D Photogrammetry

---

Jan Rustemeyer

Additional information is available at the end of the chapter

<http://dx.doi.org/10.5772/51416>

---

## 1. Introduction

During recent decades, orthognathic surgery has become widely accepted as the preferred method of correcting moderate-to-severe skeletal deformities including facial esthetics. Recognition of esthetic factors and prediction of the final facial profile play an increasingly important role in orthognathic treatment planning, since the facial profile produced by orthognathic surgery is highly significant for patients [1-3]. Many studies have attempted to evaluate the relationship between hard-tissue surgery and its effect on the overlying soft tissue for predicting facial changes [4-6]. Three-dimensional (3-D) imaging techniques, including computer tomography, video imaging, laser scanning, morphanalysis, 3-D sonography, and, recently, 3-D photogrammetry [7-13] have been developed to highlight the relationship between hard- and soft-tissue movements, but details of this relationship, particularly in the vertical direction, have varied and not been fully clarified [14]. However, the assessment of visible volume changes with an optical 3-D sensor can be carried out with considerable accuracy and provides the opportunity to complete cephalometric analysis in cases of midfacial distractions and asymmetric craniofacial situations [15].

For routine orthognathic surgery cases, cephalometry and 2-D photogrammetry are common and less expensive tools that may have the potential to analyze and predict the resulting profile. However, it is remarkable that no recent report offers a comparison between both conventional methods of indirect anthropometry. Therefore, the objective of this study was to assess the facial soft-tissue response in skeletal Class II and III patients treated by bimaxillary orthognathic surgery both cephalometrically and with 2-D photogrammetry and

to compare their ability to predict postoperative outcomes. Hence, the relevant questions were whether both methods have the capacity to complement one another or not and in which cases.

## 2. Patients and methods

### *Patients' sample*

Twenty-eight patients who had undergone bimaxillary surgery for a Class II relationship (mean age,  $24.5 \pm 4.9$  years; 18 females, 10 males) and 33 patients who had undergone bimaxillary surgery for a Class III relationship (mean age,  $23.4 \pm 3.7$  years; 20 females, 13 males) were selected from adult treatment records. Bimaxillary surgery consisted of LeFort I osteotomy with maxillary advancement and/or impaction and bilateral sagittal split ramus osteotomy carried out for mandibular setback or advancement. Setback of the maxilla was not done. No additional surgical procedures were performed on the mid-face or chin, such as infraorbital augmentation, distraction, rhinoplasty, or genioplasty. Exclusion criteria to avoid any bias were patients' findings that exceeded routine orthognathic planning. These were patients with an anterior open bite of more than 1 cm, facial asymmetry with occlusal cants in the frontal plane, midline deviations and mandibular border asymmetry, matured cleft lip and palate, severe congenital facial deformity, and posttraumatic deformity.

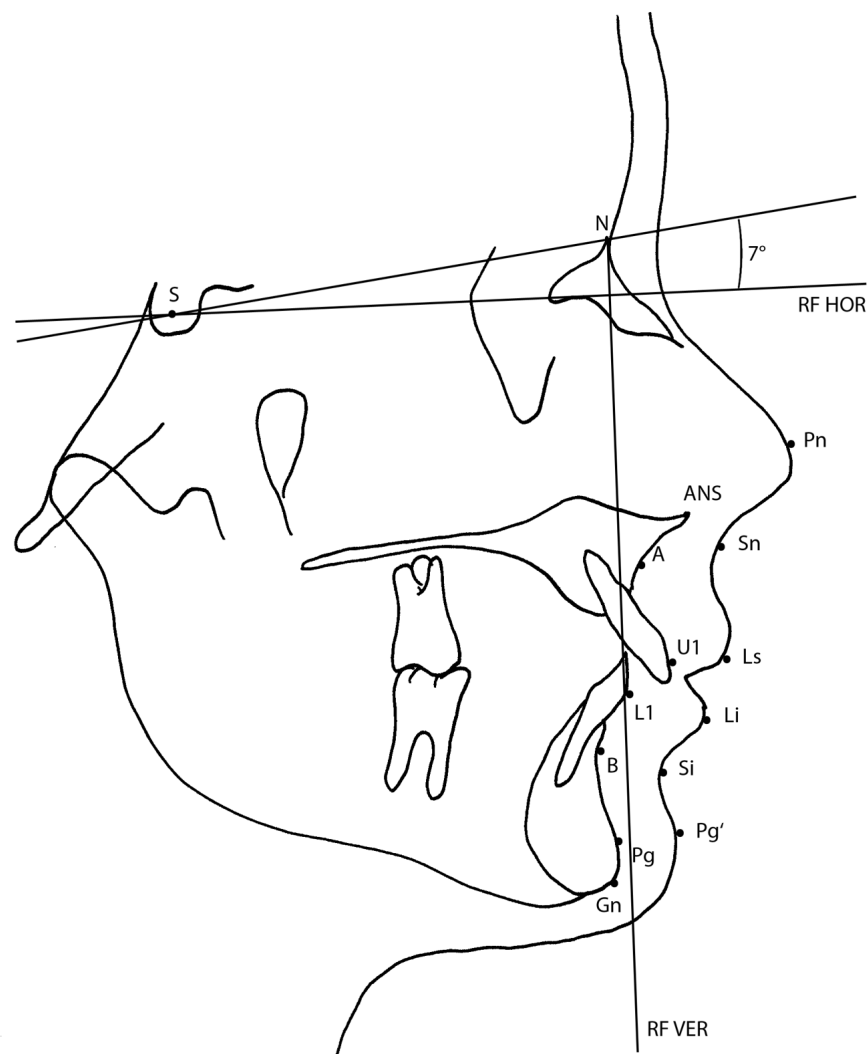
All subjects had available both a lateral cephalogram and a lateral photogram in the natural head position (NHP) taken before orthodontic appliances were applied and nine months postsurgery, after removal of the orthodontic appliances and osteosynthesis materials (median follow-up:  $9.4 \pm 0.6$  month).

### *Lateral cephalometry*

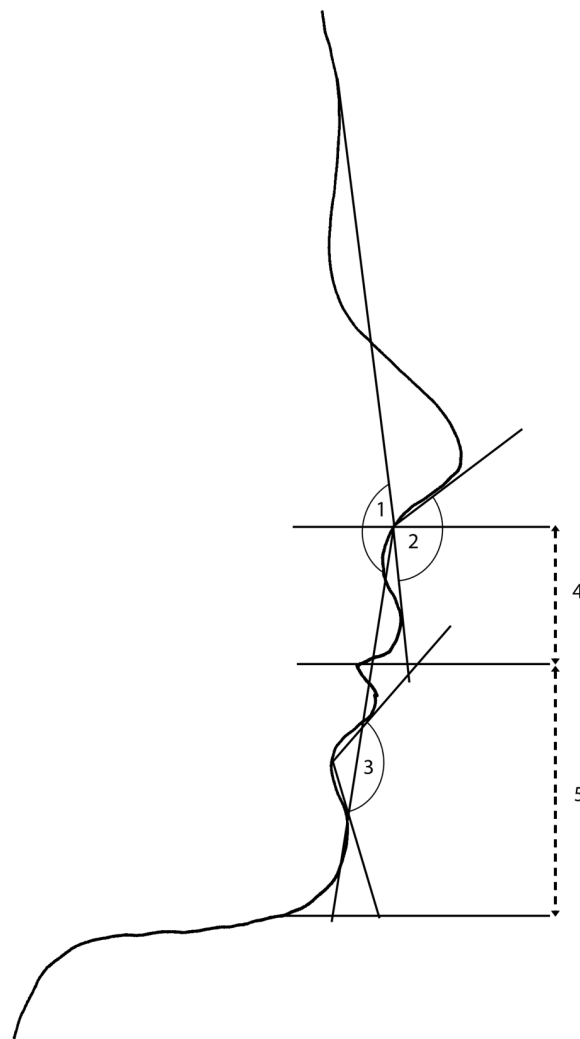
Subjects were positioned in the cephalostat (Orthoceph, Siemens AG, Munich, Germany), and then the head holder was adjusted until the ear rods could be positioned into the ears without moving the patient. All radiographs were taken in the NHP with teeth together and lips in repose and with a metric ruler in front of the midfacial vertical line. No occipital supplement was used. According to cephalometric standards, the film distance to the X-ray tube was fixed at 150 cm and the film distance to the midsagittal plane of the patient's head at 18 cm.

Tracings were done for all cephalograms. After loading the cephalogram into a PC, the ruler was used to size the cephalogram image in the software program (Adobe Photoshop version 7.0, Adobe Systems, San Jose, CA, USA), so that 1 mm on the rule represented 1 mm of actual scale (life-size) in the software program. The landmarks were identified manually by a single examiner using the photographic software. Soft- and hard-tissue landmarks of the cephalograms were traced using a modified version of the analysis of Legan and Burstone [16] and Lew et al [17] (Figs. 1 and 2). Therefore, the horizontal

reference line was constructed by raising a line  $7^\circ$  from sella-nasion, and a line perpendicular to this at nasion was used as the vertical reference line. Movement of hard- and soft-tissue landmarks from pre- to postsurgery was measured in millimeters to the horizontal and vertical reference lines. The corresponding angles were constructed and measured in degrees in the presurgical and postsurgical cephalograms. Differences were recorded as the surgical change.



**Figure 1.** Hard and soft tissue landmarks and reference lines for tracing cephalograms. (N) = Nasion; (S) = Sella; (A) = Point A; (B) = Point B; (L1) = Lower incisor, (U1) = Upper incisor; (Gn) = Gnathion; (Pg) = Pogonion; (ANS) = Anterior nasal spine; (Pn) = Pronasale; (Sn) = Subnasale; (Ls) = Labrale superius; (Li) = Labrale inferius; (Si) = Labiomentale sulcus; (Pg') = Soft tissue pogonion; (RF HOR) = Horizontal reference line; (RF VER) = Vertical reference line.

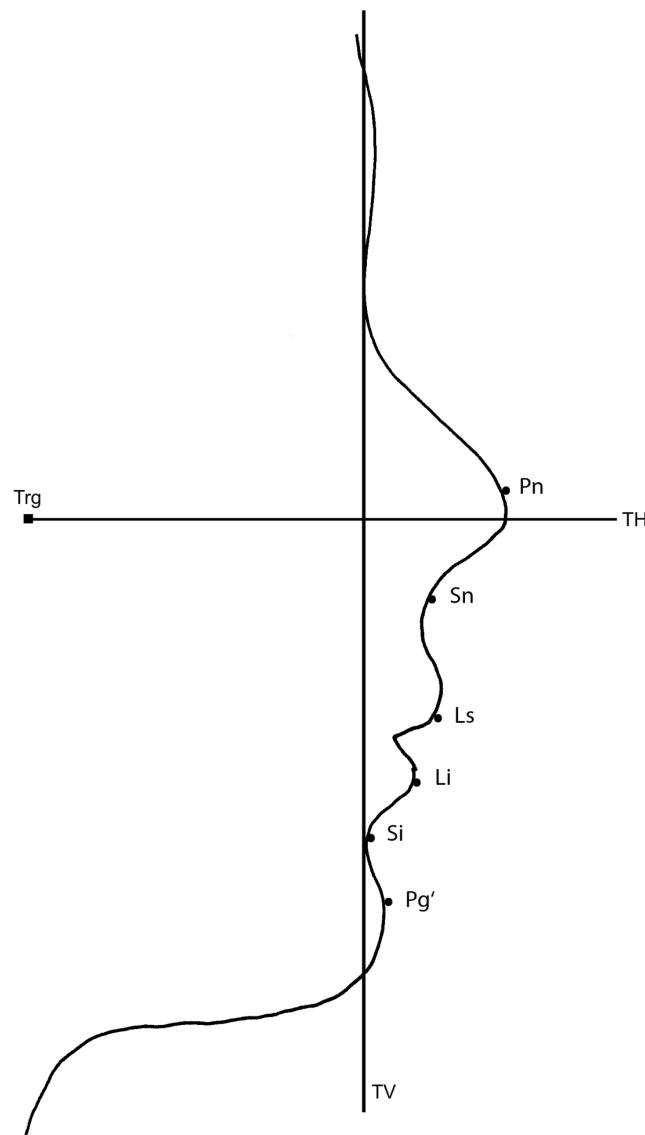


**Figure 2.** Soft-tissue angles and distances for tracing cephalograms and photograms. 1: Facial Convexity; 2: Nasolabial angle; 3: Labiomental angle; 4: Upper lip length; 5: Lower lip length.

### *2-D photogrammetry*

Subjects were asked to sit on a chair in front of a pale blue background, maintain a straight back, and look straight ahead with a relaxed facial expression and eyes fully open, lips gently closed, and not smiling. A neck holder was then adjusted to help the subjects fix their NHP. For reproducibility, a simple, indirect light source on the ceiling was used, consisting of four 60-W fluorescent tubes to eliminate undesirable shadows from the contours of the facial profile. The subjects' faces were photographed in right lateral view, together with a metric scaled ruler in front of the midfacial vertical line (true vertical, TV). A high-resolution digital camera with a flash (Canon 450D, Tokyo, Japan) was firmly mounted on a photo stand 1 m in front of the subject. All photographs were taken at  $2048 \times 1536$  pixels resolution

and saved in JPEG file format. Images were stored on the PC's hard drive and then transferred into the photographic software program. The lateral photographs were adjusted to life-size according to the cephalogram adjustment as above. Soft-tissue landmarks, distances, and angles were traced with the tools of the software. Additionally, TV on nasion and true horizontal (TH, perpendicular to TV through the tragus) were constructed as reference lines for horizontal and vertical landmark movements. Pre- and postsurgical distances of each landmark toward reference lines were measured and differences were recorded as the vertical and horizontal surgical change, respectively (Figs. 2 and 3).



**Figure 3.** Soft- tissue landmarks and reference lines for tracing photograms.

(TV) = True Vertical; (TH) = True Horizontal; (Trg) = Tragus. Further abbreviations as given in Table 1.

#### *Statistics and reliability of measurements*

The collected data were subjected to statistical analysis using the PASW statistical software package, version 18.0 (SPSS, Chicago, IL, USA). Differences between groups were evaluated using the paired *t* test. Results were considered significant if  $p < 0.05$  and highly significant if  $p < 0.01$ . Pearson's correlation analysis was used to assess the degree of correlation between soft- and hard tissue changes. The adjusted coefficient of determination ( $\text{Adj } R^2$ ) was used to assess the predictability of landmark movements (ranging from 0 = no prediction possible to 1 = accurate prediction possible).

Reliability of measurements was determined by randomly selecting 10 cephalograms and 10 lateral photograms to repeat the tracings by a second senior examiner. The method error was calculated using the formula  $\sqrt{\sum (x_1 - x_2)^2 / 2n}$  in which  $X_1$  was the first measurement,  $X_2$  the second measurement, and  $n$ , the number of repeated records. All respective values of method error calculation for the linear measurements ranged between 0.32 and 0.48 mm for cephalometry and between 0.35 and 0.51 mm for 2-D photogrammetry, for angular measurements between  $1.4^\circ$  and  $5.2^\circ$  and between  $1.6^\circ$  and  $4.9^\circ$ , respectively. Significant differences between the reliability of photogrammetry and cephalometry could not be obtained.

### **3. Results**

#### *General findings*

Significant differences between females and males could not be obtained cephalometrically or photogrammetrically, nor with respect to angular or distance measurements, pre- or post-operative, nor landmark movements. Therefore, gender was not considered further.

Hard-tissue angles assessed by cephalometry changed significantly from pre- to postsurgery in Class II and Class III patients (SNA,  $p_{\text{Class II}} = 0.041$ ,  $p_{\text{Class III}} = 0.015$ ; SNB,  $p_{\text{Class II}} = 0.009$ ,  $p_{\text{Class III}} = 0.008$ ; ANB,  $p_{\text{Class II}} = 0.016$ ,  $p_{\text{Class III}} < 0.001$ ; NAPg,  $p_{\text{Class II}} = 0.043$ ,  $p_{\text{Class III}} < 0.001$ ).

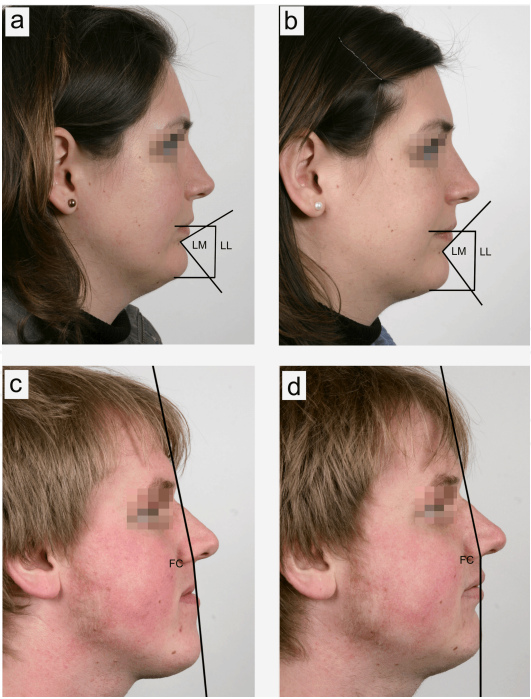
#### *Soft tissue angles and distances*

Significant differences between pre- and postsurgical measurements could be found for facial convexity, labiomental angle, and lower lip length by cephalometric and photogrammetric analyses (Table 1). Pre- to postsurgical changes of facial convexity in Class III patients and changes of lower lip length and labiomental angle in Class II patients revealed high significance ( $p < 0.01$ , Fig. 4). No significant changes from pre- to postsurgery could be found for the nasolabial angle or upper lip length.



Photogrammetry				Cephalometry			
		presurgery	postsurgery			presurgery	postsurgery
Parameter	Class	Mean ± SD	Mean ± SD	p	Mean ± SD	Mean ± SD	p
Facial							
convexity (°)	II	159.1 ± 4.8	165.9 ± 5.1	0.023*	159.8 ± 2.3	163.5 ± 3.4	0.015*
	III	178.8 ± 5.9	172.1 ± 6.1	< 0.001**	178.8 ± 5.9	170.8 ± 7.3	< 0.001**
Nasolabial							
angle (°)	II	111.2 ± 7.4	109.2 ± 9.2	0.671	111.4 ± 10.1	111.2 ± 7.5	0.976
	III	105.4 ± 12.4	104.6 ± 13.3	0.835	102.1 ± 14.2	103.2 ± 14.7	0.804
Labiomental							
angle (°)	II	119.1 ± 11.9	135.9 ± 9.8	0.013*	120.8 ± 7.4	134.2 ± 9.9	0.021*
	III	132.8 ± 14.6	121.1 ± 15.8	0.013*	127.4 ± 12.9	115.5 ± 13.8	0.004**
Upper lip							
length (mm)	II	13.5 ± 1.7	13.9 ± 1.3	0.621	13.9 ± 1.9	13.8 ± 1.9	0.533
	III	12.4 ± 1.6	13.1 ± 1.6	0.134	12.5 ± 2.1	13.1 ± 1.8	0.317
Lower lip							
length (mm)	II	24.7 ± 3.1	30.5 ± 3.3	0.006**	29.9 ± 2.3	29.9 ± 2.3	0.007**
	III	31.2 ± 3.4	28.8 ± 3.9	0.029*	31.6 ± 2.9	28.4 ± 2.7	0.003**

**Table 1.** \*significant at the level  $p < 0.05$ , \*\* significant at the level  $p < 0.01$ . Pre- and postsurgical measurements of soft-tissue angles and distances.



**Figure 4.** Screenshots of traced lateral photograms. Pre- to postsurgical changes of lower lip length (LL) and labio-mental angle (LM) in Class II patients (a = presurgery, b = postsurgery) and changes of facial convexity (FC) in Class III patients (c = presurgery, d = postsurgery) revealed high significance.



*Soft-tissue landmarks*

		Photogrammetry		Cephalometry	p
		Movement		Movement	
Dimension	Landmark	Class	Mean ± SD	Mean ± SD	
Horizontal	Pn	II	0.9 ± 0.8	0.6 ± 0.5	0.251
		III	1.4 ± 2.6	1.1 ± 0.9	0.761
	Sn	II	2.1 ± 0.8	2.2 ± 0.9	0.883
		III	2.4 ± 1.6	1.2 ± 3.1	0.784
	Ls	II	2.5 ± 0.5	2.3 ± 1.7	0.831
		III	2.2 ± 1.6	1.1 ± 2.5	0.874
	Li	II	2.5 ± 0.8	2.2 ± 1.3	0.441
		III	-3.2 ± 2.1	-4.8 ± 3.1	0.376
	Si	II	2.7 ± 0.5	2.3 ± 0.8	0.421
		III	-5.4 ± 2.9	-5.9 ± 3.4	0.776
	PG`	II	2.5 ± 1.1	3.3 ± 1.2	0.232
		III	-6.8 ± 4.1	-6.1 ± 4.3	0.769
Vertical	Pn	II	0.1 ± 0.8	0.3 ± 0.5	0.451
		III	0.6 ± 1.1	0.4 ± 0.5	0.736
	Sn	II	0.2 ± 0.9	-0.2 ± 0.7	0.525
		III	0.6 ± 0.4	0.2 ± 0.4	0.688
	Ls	II	-0.5 ± 1.6	0.2 ± 0.9	0.418
		III	1.2 ± 0.8	1.4 ± 2.5	0.807
	Li	II	-0.6 ± 0.8	0.3 ± 1.2	0.187
		III	1.2 ± 2.1	2.5 ± 2.6	0.411
	Si	II	-1.3 ± 1.6	-0.2 ± 1.3	0.205
		III	1.8 ± 1.9	2.6 ± 1.9	0.283
	PG`	II	-1.2 ± 0.8	-0.7 ± 0.7	0.204
		III	1.4 ± 1.8	1.8 ± 2.3	0.199

**Table 2.** Pre- to postsurgical movements (mm) of soft-tissue landmarks in horizontal and vertical dimensions assessed by photogrammetry and cephalometry.

The measurements of pre- to postsurgical soft-tissue landmark movements did not differ significantly between photogrammetry and cephalometry (Table 2). In Class III patients, the greatest movements were found photogrammetrically and cephalometrically for Pg' in the

horizontal and for Si in the vertical dimension. In Class II patients, Si movements assessed by photogrammetry and Pg' movements assessed by cephalometry revealed the greatest movements in both horizontal and vertical directions.

#### *Correlations between soft- and hard-tissue changes*

Significant correlations between soft- and hard-tissue changes (Table 3) occurred cephalometrically only in Class III patients. Highly significant correlations were found between facial convexity and SNB, ANB, and NAPg and between lower lip length and SNB, ANB, and NAPg. Photogrammetrically significant correlations occurred in Class II patients for labiomental angle and SNB, ANB, and NAPg and in Class III patients for facial convexity and NAPg; for nasolabial angle and SNA; and for lower lip length and NAPg. Significant correlations for both Class II and III patients could be shown between lower lip length and ANB.

	Parameters <sup>a</sup>	Class	SNA	SNB	ANB	NAPg
Cephalometry	Facial convexity	II	ns	ns	ns	ns
		III	ns	0.003**	<0.001**	<0.001**
	Upper lip length	II	ns	ns	ns	ns
		III	ns	ns	0.032*	0.010*
	Lower lip length	II	ns	ns	ns	ns
		III	ns	0.002**	<0.001**	0.003**
Photogrammetry	Facial convexity	II	ns	ns	ns	ns
		III	ns	ns	ns	0.036*
	Nasolabial angle	II	ns	ns	ns	ns
		III	0.034*	ns	ns	ns
	Labiomental angle	II	ns	0.038*	0.037*	0.030*
		III	ns	ns	ns	ns
	Lower lip length	II	ns	ns	0.027*	ns
		III	ns	ns	0.032*	0.047*

**Table 3.** <sup>a</sup> only parameters revealing at least one significance were considered ns: indicates not significant; \* significant at the level  $p < 0.05$ , \*\* significant at the level  $p < 0.01$ . Significance of correlations between soft- and hard-tissue changes

Correlations of hard- and soft-tissue movements between pre- and postoperative corresponding landmarks in the horizontal and vertical planes revealed significance for both cephalometry and 2-D photogrammetry in Class II and III patients (Table 4). Correlations could be found for both methods between Sn and A, Si and B, and Pg' and Pg in the hori-

zontal plane for Class II and III patients. In the vertical plane for Class II patients, correlations could be shown cephalometrically only for Sn and A, and photogrammetrically only for Pg' and Pg. In Class III patients, cephalometry and 2-D photogrammetry revealed both significant correlations between vertical movements of Sn and A, Ls and U1, and Pg' and Pg. In cases of significant correlation, Adj  $R^2$  was above the 0.7 level, representing a satisfactory accuracy for prediction.

Soft tissue parameter <sup>a</sup>	Hard tissue parameter <sup>a</sup>	Class	p <sub>Sceph; H</sub>	Adj. R <sup>2</sup>	p <sub>Sphoto; H</sub>	Adj. R <sup>2</sup>
Horizontal						
Sn	A	II	0.046*	0.717	0.011*	0.792
		III	0.044*	0.718	0.010*	0.891
Si	B	II	0.023*	0.707	0.038*	0.725
		III	0.034*	0.762	0.030*	0.778
Pg`	Pg	II	0.032*	0.752	0.015*	0.757
		III	0.010*	0.894	0.044*	0.720
Vertical						
Sn	A	II	0.036*	0.732	ns	0.121
		III	0.043*	0.721	0.016*	0.821
Ls	U1	II	ns	0.044	ns	0.044
		III	0.044*	0.721	0.018*	0.701
Pg`	Pg	II	ns	0.183	0.041*	0.712
		III	0.010*	0.889	0.030*	0.782

**Table 4.** <sup>a</sup> only parameters revealing at least one significance were considered. p<sub>Sceph; H</sub>: significance of correlation between *cephalometrically* assessed soft-tissue landmark movement and corresponding hard-tissue landmark movement. p<sub>Sphoto; H</sub>: significance of correlation between *photogrammetrically* assessed soft-tissue landmark movement and corresponding hard-tissue landmark movement. Adj. R<sup>2</sup>: adjusted coefficient of determination. ns: indicates not significant; \* significant at the level p < 0.05. Significances between hard- and soft-tissue landmark movement correlations.

#### Soft-to-hard tissue movement ratios

Soft-to-hard tissue movement ratios in the horizontal and vertical planes for corresponding landmarks displayed a soft-tissue response following hard-tissue movement (Table 5). No

significant difference could be obtained between cephalometry and 2-D photogrammetry with respect to the soft- to hard-tissue movement ratios.

Soft- tissue parameter (S)	Hard- tissue parameter (H)	Class	Ratio S(ceph): H	Ratio S(photo): H
Horizontal				
Pn	ANS	II	0.33	0.73
		III	0.25	0.35
Sn	A	II	1.83	1.73
		III	0.39	0.59
Ls	U1	II	1.11	1.76
		III	0.27	0.60
Li	L1	II	0.88	1.09
		III	0.03	0.56
Si	B	II	1.27	1.35
		III	1.20	1.13
Pg`	Pg	II	1.13	1.09
		III	0.98	1.15
Vertical				
Pn	ANS	II	0.33	0.33
		III	0.40	0.60
Sn	A	II	0.06	0.03
		III	0.20	0.80
Ls	U1	II	0.25	0.35
		III	0.60	0.80
Li	L1	II	0.25	0.15
		III	0.33	0.07
Si	B	II	0.25	0.37
		III	1.37	0.83
Pg`	Pg	II	0.33	0.57
		III	1.49	0.57

**Table 5.** Soft-to-hard tissue movement ratios in horizontal and vertical dimensions for corresponding landmarks .

## 4. Discussion

The results of this study showed that maxillary and mandibular movements with bimaxillary osteotomy were effective on soft tissues both in vertical and horizontal directions, and they improved facial convexity to approximate esthetic norms. Arnett and Bergman [18,19] described the facial profile according to the angle of facial convexity in Class I ( $165^{\circ}$ – $175^{\circ}$ ), Class II ( $<165^{\circ}$ ), and Class III profiles ( $> 175^{\circ}$ ). Following this classification, in our study postsurgical Class I facial convexity was achieved in Class II and III patients and was assessed by 2-D photogrammetry as well as by cephalometry. However, cephalometric and photogrammetric changes of the labiomental angle could be obtained only in Class II patients. Fernández-Riveiro et al [20] found that the labiomental angle should be evaluated with caution because of its high method error and variability. In this study as well, photogrammetrically and cephalometrically defined labiomental angle measurements revealed the highest variability of all measurements.

Whereas horizontal movement of soft-tissue landmarks in Class II and III patients—with the exception of labrale superius and inferius—were strongly correlated cephalometrically and 2-D photogrammetrically with hard-tissue landmark movements, vertical movements of landmarks were mostly hard to predict. One reason might be that vertical mandibular movements in our patients were only minimal and beneath the capability of cephalometric and 2-D photogrammetric analyses, since patients with massive vertical deficits were excluded to avoid any bias in this study. Accordingly, Lin and Kerr [21] also found in their cohort that these may account for the increased difficulty in accurately predicting a change in the vertical dimension. In comparison, in the study of Nkenke et al. [15] using optical 3-D images for analysing soft-tissue advancement in patients undergoing midfacial distraction at 6 and 24 months postsurgically, means of vertical advancement of Sn ( $1.0 \pm 1.0$  mm;  $0.4 \pm 0.9$  mm, respectively) and labrale superius ( $0.4 \pm 1.1$  mm;  $-0.2 \pm 0.5$  mm, respectively) were within the scope of the data assessed in this study by 2-D photogrammetry and cephalometry for Class II and III patients. Hence, adequate accuracy of determination of vertical movements could be achieved with both methods in this study and referring to the study of Nkenke et al. [15], the level of validity is acceptable. However, further studies are warranted to evaluate the concept of vertical changes in patients with extensive vertical discrepancies.

Findings in this study suggest that cephalometric and 2-D photogrammetric analyses complement one another in predicting soft-tissue changes in orthodontic surgery patients. For the combination of both methods, at least one parameter for the maxilla (Sn-A) and one for the mandible (Pg'-Pg) became predictable for the vertical dimension with an acceptable adjusted coefficient of determination. Special attention should be given to soft-tissue changes in Class II patients, which cephalometrically revealed no significant correlation with hard-tissue angular changes, whereas correlations could be obtained with 2-D photogrammetry. We therefore recommend supplementary 2-D photogrammetry for evaluating soft- to hard-tissue changes and cephalometric prediction, especially in Class II patients.

Previous cephalometric findings have shown mandibular skeletal movement for the soft-tissue chin at a ratio of between 0.9:1 and 1:1 [22,23]. The results of this study support this his-

torical observations cephalometrically as well as 2-D-photogrammetrically for Class II and Class III patients. However, the labrale inferius (Li) in our study responded at a ratio of 0.88:1 cephalometrically and 1.09:1 photogrammetrically to the corresponding hard-tissue movements in the horizontal plane in Class II patients, but only at ratios of 0.03:1 and 0.56:1 in Class III patients, respectively. This is cephalometrically much lower than the ratio found in other investigations in Class III patients, which ranged from 0.6:1 to 0.75:1 [22, 23]. In comparison, with 2-D photogrammetry the lower border of this range was nearly reached.

Standard-error calculation suggests that standards presented in this study for cephalometry and 2-D photogrammetry set-ups are ready for routine evaluation of soft-tissue changes after orthognathic surgery. However, all ratios presented in this study and in the literature suggest that even a mathematically accurate prediction may involve bias [24]. This means that prediction and soft- to hard-tissue movement ratios must be evaluated on an individual basis and that they depend at least partly on the experience of the surgeon in his or her hand-setting of the maxilla during bimaxillary surgery. Furthermore, various types of operations—as well as the morphology of the anatomic structures—must be considered in predicting the outcome of facial surgery [25]. In comparison to data reported in another study from Nkenke et al. [26] using pre- and postsurgical 3-D facial surface images in patients undergoing LeFort I osteotomy, advancements of Sn and Ls were within the range of the results obtained in this study for horizontal movements of these parameters assessed with cephalometry and 2-D photogrammetry. Furthermore, the ratio of advancement between labrale superius and incision superius reported by Nkenke et al. [26] was  $80 \pm 94$  % and comparable with our findings. In accordance to the ratios of vertical advancement and referring to the method of Nkenke et al. [26] again, validity of at least this ratio of horizontal advancement is adequate in our study. However, the 3-D facial surface images analysis possesses moreover the ability to predict volume increases or decreases especially in the malar- midface region and could therefore improve the predictability of esthetic soft tissue results. Future studies may reveal which orthognathic surgery cases are best suited for 3-D imaging techniques. The data of this study might be helpful.

## 5. Conclusion

This study revealed that cephalometry and 2-D photogrammetry provide the option to complement one another to enhance accuracy in predicting soft-tissue changes in orthodontic surgery, especially in Class II patients.

## Acknowledgements

We gratefully acknowledge Ilknur Tetik, B.A., School of Architecture, Bremen, Germany, for her contribution to photogrammetric set-up.

## Author details

Jan Rustemeyer\*

Address all correspondence to: janrustem@gmx.de

Department of Oral and Maxillofacial Surgery, Klinikum Bremen-Mitte, School of Medicine of the University of Göttingen, Germany

The authors declare they have no conflict of interest.

## References

- [1] Jacobson, A. (1984). Psychological aspects of dentofacial esthetics and orthognathic surgery. *Angle Orthod*, 54, 18-35.
- [2] Kiyak, H. A., West, R. A., Hohl, T., & Mc Neill, R. W. (1982). The psychological impact of orthognathic surgery: a 9-month follow-up. *Am J Orthod*, 81, 404-412.
- [3] Rustemeyer, J., Eke, Z., & Bremerich, A. (2010). Perception of omprovement after orthognathic surgery: the important variables affecting patient satisfaction. *Oral Maxillofac Surg*, 14, 155-162.
- [4] Chou, J. I., Fong, H. J., Kuang, S. H., Gi, L. Y., Hwang, F. Y., Lai, Y. C., Chang, R. C., & Kao, S. Y. (2005). A retrospective analysis of the stability and relapse of soft and hard tissue change after bilateral sagittal split osteotomy for mandibular setback of 64 Taiwanese patients. *J Oral Maxillofac Surg*, 63, 355-361.
- [5] Enacar, A., Taner, T., & Toroglu, S. (1999). Analysis of soft tissue profile changes associated with mandibular setback and double-jaw surgeries. *Int J Adult Orthod Orthognath Surg*, 14, 27-35.
- [6] Koh, C. H., & Chew, M. T. (2004). Predictability of soft tissue profile changes following bimaxillary surgery in skeletal Class III Chinese patients. *J Oral Maxillofac Surg*, 62, 1505-1509.
- [7] McCance, A. M., Moss, J. P., Fright, W. R., & Linney, A. D. (1997). Three-dimensional analysis technique-Part 3: Color-coded system for three-dimensional measurement of bone and ratio of soft tissue to bone: the analysis. *Cleft Palate Craniofac J*, 34, 52-57.
- [8] Nanda, R. S., Ghosh, J., & Bazakidou, E. (1996). Three-dimensional facial analysis using a video imaging system. *Angle Orthod*, 66, 181-188.
- [9] Moss, J. P., Mc Cance, A. M., Fright, W. R., Linney, A. D., & James, D. R. (1994). A three-dimensional soft tissue analysis of fifteen patients with class II, division I malocclusions after bimaxillary surgery. *Am J Orthod Dentofac Orthop*, 105, 430-437.



- [10] Rabey, G. (1971). Craniofacial morphanalysis. *Proc R Soc Med*, 64, 103-111.
- [11] Hell, B. (1995). 3D sonography. *Int J Oral Maxillofac Surg*, 4, 84-89.
- [12] Deli, R., Di Gioia, E., Galantucci, L. M., & Percoco, G. (2010). Automated landmark extraction for orthodontic measurement of faces using the 3-camera photogrammetry methodology. *J Craniofac Surg*, 21, 87-93.
- [13] Plooi, J. M., Swennen, G. R., Rangel, F. A., Maal, T. J., Schutyser, F. A., Bronkhorst, E. M., Kuijpers-Jagtman, A. M., & Bergé, S. J. (2009). Evaluation of reproducibility and reliability of 3D soft tissue analysis using 3D stereophotogrammetry. *Int J Oral Maxillofac Surg*, 38, 267-273.
- [14] Okudaira, M., Kawamoto, T., Ono, T., & Moriyama, K. (2008). Soft-tissue changes in association with anterior maxillary osteotomy: a pilot study. *Oral Maxillofac Surg*, 12, 131-138.
- [15] Nkenke, E., Langer, A., Laboureux, X., Benz, M., Maier, T., Kramer, M., Häusler, G., Kessler, P., Wiltfang, J., & Neukam, F. W. (2003). Validation of in vitro assessment of facial soft-tissue volume changes and clinical application in midfacial distraction: a technical report. *Plast Reconstr Surg*, 112, 367-380.
- [16] Legan, H. L., & Burstone, C. I. (1980). Soft tissue cephalometric analysis for orthognathic surgery. 38, 744-751.
- [17] Lew, K. K., Low, F. C., Yeo, J. F., & Loh, H. S. (1990). Evaluation of soft tissue profile following intraoral ramus osteotomy in Chinese adults with mandibular prognathism. *Int J Adult Orthodon Orthognath Surg*, 5, 189-197.
- [18] Arnett, G. W., & Bergman, R. T. (1993). Facial keys to orthodontic diagnosis and treatment planning. Part I. *Am J Orthod Dentofacial Orthop*, 103, 299-312.
- [19] Arnett, G. W., & Bergman, R. T. (1993). Facial keys to orthodontic diagnosis and treatment planning. Part II. *Am J Orthod Dentofacial Orthop*, 103, 395-411.
- [20] Fernández-Riveiro, P., Smyth-Chamosa, E., Suárez-Quintanilla, A., & Suárez-Cunqueiro, A. (2003). Angular photogrammetric analysis of the soft tissue facial profile. *Eur J Orthod*, 25, 393-399.
- [21] Lin, S. S., & Kerr, W. J. (1998). Soft and hard tissue changes in Class III patients treated by bimaxillary surgery. *Eur J Orthod*, 20, 25-33.
- [22] Hershey, H. G., & Smith, L. H. (1974). Soft-tissue profile change associated with surgical correction of the prognathic mandible. *Am J Orthod*, 65, 483-502.
- [23] Lines, P. A., & Steinhäuser, E. W. (1974). Soft tissue changes in relationship to movement of hard structures in orthognathic surgery: a preliminary report. *J Oral Surg*, 32, 891-896.
- [24] Marşan, G., Cura, N., & Emekli, U. (2009). Soft and hard tissue changes after bimaxillary surgery in Turkish female Class III patients. *J Craniomaxillofac Surg*, 37, 8-17.

- [25] Moss, J. P., Grindrod, S. R., Linney, A. D., Arridge, S. R., & James, D. (1988). A computer system for the interactive planning and prediction of maxillofacial surgery. *Am J Orthod Dentofac Orthop*, 94, 469-475.
- [26] Nkenke, E., Vairaktaris, E., Kramer, M., Schlegel, A., Holst, A., Hirschfelder, U., Wiltfang, J., Neukam, F. W., & Stamminger, M. (2008). Three-dimensional analysis of changes of the malar-midfacial region after LeFort I osteotomy and maxillary advancement. *Oral Maxillofac Surg*, 12, 5-12.