

# We are IntechOpen, the world's leading publisher of Open Access books Built by scientists, for scientists

6,900

Open access books available

186,000

International authors and editors

200M

Downloads

Our authors are among the

154

Countries delivered to

TOP 1%

most cited scientists

12.2%

Contributors from top 500 universities



WEB OF SCIENCE™

Selection of our books indexed in the Book Citation Index  
in Web of Science™ Core Collection (BKCI)

Interested in publishing with us?  
Contact [book.department@intechopen.com](mailto:book.department@intechopen.com)

Numbers displayed above are based on latest data collected.  
For more information visit [www.intechopen.com](http://www.intechopen.com)



# Association of Meconium Stained Amniotic Fluid with Fetal and Neonatal Brain Injury

Zoe Iliodromiti<sup>1</sup>, Charalampos Grigoriadis<sup>2</sup>, Nikolaos Vrachnis<sup>2</sup>,  
Charalampos Siristatidis<sup>3</sup>, Michail Varras<sup>4</sup> and Georgios Creatsas<sup>2</sup>

<sup>1</sup>Neonatal Unit, <sup>2</sup>nd Department of Obstetrics and Gynecology, University of Athens  
Medical School, Aretaieio Hospital, Athens,

<sup>2</sup>nd Department of Obstetrics and Gynecology, University of Athens Medical School,  
Aretaieio Hospital, Athens,

<sup>3</sup>nd Department of Obstetrics and Gynecology, University of Athens Medical School,  
Attiko Hospital, Athens,

<sup>4</sup>Department of Obstetrics and Gynecology, Elena Hospital, Athens,  
Greece

## 1. Introduction

Meconium stained amniotic fluid (MSAF), which occurs in about 10-15% of all pregnancies [Wiswell TE. et al., 1990], is common in term births and especially in post-date deliveries. The etiology and pathophysiology of MSAF is poorly understood. While the more advanced maturation process of the gastrointestinal tract may account for the higher rates of MSAF in post-date deliveries, it is generally believed that the presence of MSAF in other circumstances is a marker of fetal distress and may be associated with adverse fetal and neonatal outcome [Woods JR. et al., 1994; Krebs HB. et al., 1980; Mazor M. et al., 1998].

A relationship of MSAF with stillborn infants, abnormal fetal heart-rate (FHR) tracings, neonatal encephalopathy, respiratory distress (meconium aspiration syndrome, MAS) and abnormal neurologic outcome is reported in the literature. The finding of MSAF is associated with multiple markers of fetal distress, as meconium-stained infants have in general lower scalp pHs and lower umbilical cord artery pHs in comparison with infants born through clear amniotic fluid [Nathan L. et al., 1994; Ramin K. et al., 1994; Starks GD., 1980]. Additionally, infants born through MSAF have lower Apgar scores in the first and fifth minute after delivery [Wiswell TE. et al., 1990; Clifford SH., 1945]. However, in the vast majority of cases, no major problems occur in infants born through MSAF.

The term “meconium aspiration syndrome (MAS)” describes neonates born through MSAF, who present respiratory distress which cannot be otherwise explained. MAS is the most frequent complication diagnosed among infants born through MSAF, with an incidence of about 5% in these cases [Wiswell TE. et al., 1993; Cleary GM. et al., 1998]. Meconium stained infants are considered 100 times more likely to develop MAS, compared with infants born through clear amniotic fluid [Fleischer A., et al., 1992]. The severity of this syndrome is demonstrated by the fact that published data report that about one-third to one-half of

neonates with MAS will require mechanical ventilation, one-quarter will develop pneumothoraxes and one in twenty will die, although the death rate has declined appreciably since the 1990s as a result of successful airway management in the delivery room, better ventilatory techniques and improvement in supportive neonatal care (thermoregulation, parenteral nutrition) [Wiswell TE. et al., 1993; Cleary GM. et al., 1998].

It is noteworthy that the significantly higher rates of admission to newborn intensive care units for neonates born through MSAF in comparison with those born through clear amniotic fluid underlines the strong association between MSAF and fetal distress; the greater experience, moreover, gained in this area has also yielded useful data about the cost-effective management of such cases. It was estimated that approximately 24% of meconium stained neonates were admitted to newborn intensive care units, compared to 7% of those born through clear amniotic fluid [Nathan L. et al., 1994].

Although the incidence of MSAF and MAS is high, there remains a distinct paucity of literature describing the neurological development of either children born through MSAF or those with MAS. The aim of this Chapter is to review studies which examine the potential association of MSAF and MAS with fetal and neonatal brain injury in order to investigate the incidence of this condition, the possible pathogenetic pathways of fetal brain injury in MSAF and the optimal means of recognizing and preventing these complications.

## 1.1 Historical aspects

It was the famous ancient Greek philosopher Aristotle who, first describing meconium stained amniotic fluid, conferred on this condition the name “meconium-arion”, literally meaning “opium-like”. His use of this term may have been due to his belief that MSAF induced fetal sleep and his knowledge that it was also associated with fetal deaths and neonatal depression, or else it may have arisen because meconium resembles the black, tarry consistency of processed opium. Several publications from the 1600s reported MSAF as a sign of death or impending death of the fetus. The first description of in utero aspiration of meconium and MAS was published in 1918 [Reed CB., 1918]. An explanation for the pathogenetic mechanism was based on the hypothesis that in utero anoxia could relax the anal sphincter and result in meconium passage. Other investigators maintained that asphyxia leads to meconium passage because of increased intestinal peristalsis [Brews A., 1948]. The critical point of hypoxia that is needed for meconium passage was first described in a study which found that umbilical venous oxygen saturation levels below 30% were associated with meconium passage [Walker J., 1954]. In 1945, Clifford, in a research study supporting the need for resuscitation in such cases and basing his views on the complications observed in neonates, reported a mortality rate of approximately 6% and a morbidity rate of about 60% among infants born through MSAF [Steer PJ. et al., 1989].

Useful conclusions with regard to MSAF and MAS were disclosed in the National Institute of Neurological and Communicative Disorders and Stroke Collaborative Perinatal Project (CPP) of the late 1950s and 1960s. In this project, more than 42,000 children were followed as from delivery for possible future identification of cerebral palsy (CP), mental retardation (MR) and other abnormal neurologic findings. It was found that 10.3% of all live-born infants in the CPP had had meconium staining. Neonatal mortality rate for the stained group was about 3.3%, compared to 1.7% among infants born through clear amniotic fluid

[Fujikura T., et al., 1975]. The incidence of MAS among infants born through MSAF in the CPP was about 8.7% [Naeye RL., 1992]. In contrast with the extremely decreased mortality rates of this complication in the present day, it was noted that ultimately 63% of neonates who developed MAS in the CPP died. It is notable that from 1957, the hypothesis that meconium stained neonates had a significantly higher risk of developing neurologic disorders in the future was supported in the literature [Brown CA. et al., 1957].

The greatly improved results in mortality and morbidity rates today in cases of infants diagnosed with MAS are attributable to the highly successfully applied aggressive airway management that has been followed by pediatricians in meconium stained neonates since the 1970s [Wiswell TE., et al., 2000]. Although large randomized controlled clinical trials do not support the need for intratracheal intubation and suctioning, the generally followed practice of obstetrical oro- and nasopharyngeal suctioning and postpartum intratracheal suctioning of meconium stained infants in the delivery room plays an important role in prevention of severe complications arising from the meconium aspiration syndrome [Wiswell TE., et al., 2000]. On the other hand, maneuvers like intrapartum oro- and nasopharyngeal suctioning prior to delivery of the baby's shoulders or amnioinfusion of normal saline or lactated Ringer's infusion into the uteri of women with MSAF do not avert the development of MAS [Vain NE. et al., 2004; Fraser WD. et al., 2004].

## 2. Mechanisms of meconium passage

Meconium is a viscous green liquid consisting of gastrointestinal secretions, bile, bile acids, mucus, pancreatic juice, cellular debris, amniotic fluid and swallowed vernix caseosa, lanugo and blood [Wiswell TE. et al., 1993]. Approximately 60-200 gr. of meconium are found in a term infant's intestine. The many possible pathophysiological pathways of intraamniotic meconium passage all have the same origin, which is ante- or intrapartum asphyxia. Several investigators have argued that in utero anoxia could relax the anal sphincter tone of the embryo [Reed CB., 1918], while others have expressed the hypothesis that anoxia could increase intestinal peristalsis [Brews A., 1948]. In any case, both these pathways originate from asphyxia and lead to intraamniotic meconium passage. Additionally, the theory of compression of the fetal head or umbilical cord which produces a vagal response and finally leads to meconium passage is supported in the published literature [Miller FC. et al., 1981]. The important role of hypoxia was well documented after clinical observations that umbilical venous oxygen saturation levels below 30% were associated with meconium passage [Walker J. et al., 1954]. There are also theories which propose a potential pathogenetic role of intrauterine infection leading to meconium passage, as the rate of intraamniotic infection is shown to be significantly higher in women with MSAF [Wen TW. et al., 1993; Vrachnis N. et al., 2010].

On the other hand, in the majority of cases, the presence of meconium is probably a physiologic maturational event. Meconium passage is rare before the 37<sup>th</sup> week of gestation, but may occur in more than 35% of pregnancies after the 42<sup>nd</sup> week of gestation [Nathan L. et al., 1994].

However, how can one make estimates of the amount of time that has passed between fetal defecation and birth? There are clear-cut indications. Freshly passed meconium is a thick, viscous shimmering black-green colored substance. With the progress of time, the color of

MSAF will change to brown and finally to tan or yellow. That is why the yellow-colored appearance of MSAF is synonymous with the term “old” meconium.

Additionally, it is generally believed that the duration between defecation and delivery can be estimated by the color of placental staining. Acute staining is slimy with a dark-green color, chronic staining has a characteristic muddy-brown appearance (over six hours of exposure), while very remotely passed meconium is light tan.

### **3. MSAF and brain injury**

#### **3.1 MSAF and adverse neurodevelopmental outcomes**

Although large prospective epidemiologic studies specifically following a group of neonates born through MSAF for future development of neurologic handicaps are absent from the published literature, there are several reports which link the pathogenetic role of meconium passage with a variety of neurodevelopmental disorders.

A strong relationship between MSAF and symptoms like hypotonia, lethargy and seizures in infants born through MSAF is documented in the literature [Brown CA. et al., 1957]. Additionally, Grafe studied cases of brain injury in 83 stillborns and 13 infants that occurred within one hour from delivery [Grafe MR., 1994]. A higher rate of neurological complications was noted among infants born through MSAF if meconium staining of the placenta was present, while the major neurologic pathological finding was white-matter gliosis or necrosis. The key role of placental meconium staining was also observed in a recent study published in 2005 which stated that meconium-associated vascular necrosis of the placenta is the main etiological factor associated with neurologic impairment in infants [Redline RW., 2005] (Figure 1).

Research studies have also recognized a strong relationship of meconium passage with adverse neurologic outcome, especially in premature labor. Meconium in premature labor is considered to be a higher risk factor for future neurologic disorders compared to term delivery. In a study of Kalis et al., 41% of premature infants born through MSAF were diagnosed as having cerebral palsy (CP), compared to 10% in the same group with clear amniotic fluid. The incidence of CP in term pregnancy when meconium was present was reported as 0.4%, compared to 0.3% in a population without any obstetrical risk [Kalis V. et al., 2001].

Information and data from the CPP were examined by several investigators in order to exclude safe conclusions. A group of 50 children from the CPP diagnosed with neurological disorders, like moderate or severe motor disability and severe MR, was studied and compared to a large control population. Those with severe disorders were more than twice as likely to have been born through MSAF (40.8% vs 19.1%) [Nelson KB. et al., 1977]. The same investigator found that the rate of CP among children with a birthweight over 2500 gr. was about 3/1000 if there was no history of obstetrical problems, while it was 4/1000 when neonates were born through MSAF in the absence of further obstetrical complications [Nelson KB., 1989]. Of particular interest was the increased CP rate (94/1000) when there was a history of MSAF and a 5-minute Apgar score below 3 [Nelson KB., 1989]. In cases of neonates with a birthweight below 2500 gr. born through MSAF, the estimated rate of CP was approximately 15/1000. Additionally, 12/1000 of these low-birthweight meconium stained infants developed seizures in the absence of CP [Nelson KB. et al., 1984].



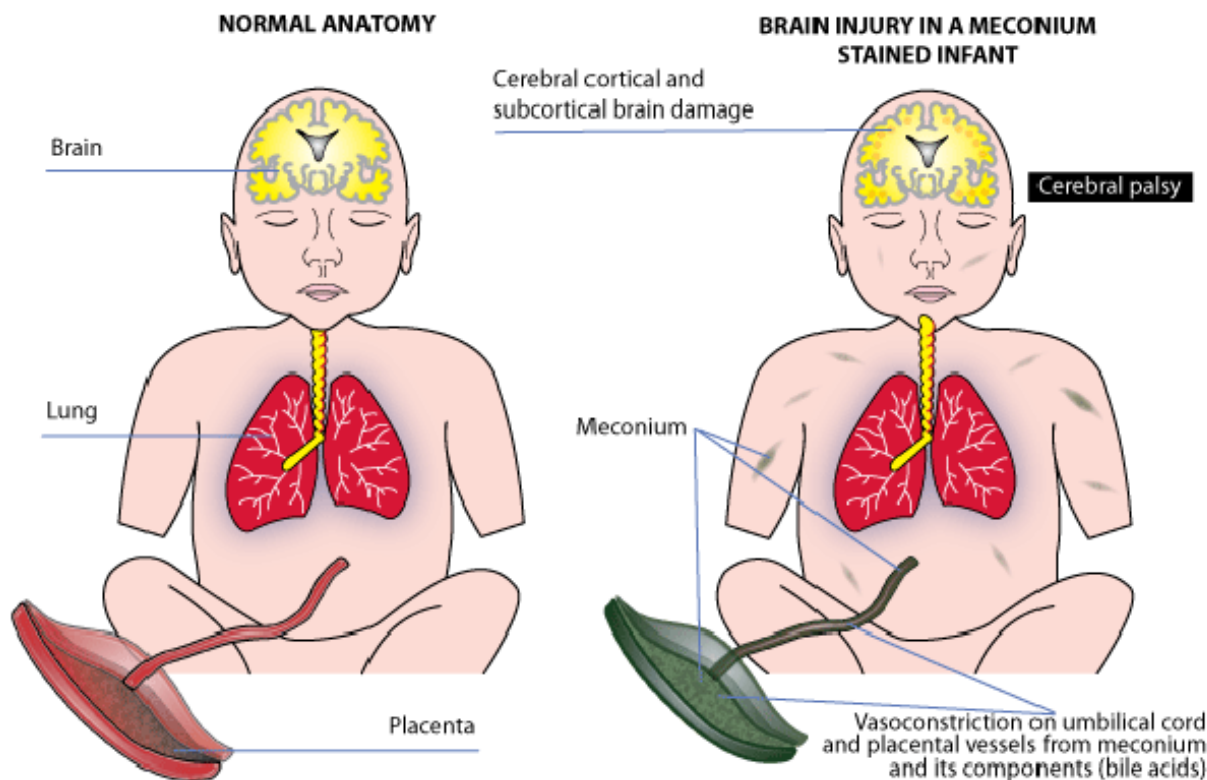


Fig. 1. Pathogenetic pathway of direct in vivo vasoconstriction on umbilical cord and placental vessels from meconium (meconium stained placenta), that leads to cerebral cortical and subcortical brain damage, in comparison with normal neural development in an infant born through clear amniotic fluid without placenta lesions (infarcts or vasoconstriction).

In another study, a group of 75 babies diagnosed with CP was analyzed [Shields JR. et al., 1988]. The aim of this research was to investigate the potential correlation between MSAF/MAS and future development of CP. The results supported this hypothesis, as 41 % of babies with CP had been born through MSAF, while 21% had been affected by MAS. Similar results were reported in several other studies that found an increased rate of CP and periventricular leukomalacia (PVL) among meconium stained premature infants [Gaffney G. et al., 1994; Spinillo A. et al., 1997; Spinillo A. et al., 1998].

An interesting research studied the incidence of autistic disorder in neonatal intensive care unit survivors. Five thousand two hundred seventy-one (5271) children were followed for neurodevelopmental disorders for a five-year period after discharge. Autistic disorder was diagnosed in 18 cases, while 57 developed CP. Obstetrical history of MAS was found significantly higher in the group with autistic disorder (22%) or CP (8.8%), compared with the control population of neonatal care units survivors without MAS [Matsuishi T. et al., 1999].

Several studies have also found an increased rate (up to sevenfold) of seizures during the neonatal period among infants born through MSAF in comparison with cases in which amniotic fluid was clear [Nathan L. et al., 1994; Berkus MD. et al., 1994; Sato S. et al., 2003]. This observation is important as seizures constitute a predictive factor of subsequent neurological adverse outcome. In some of these cases of seizures during the neonatal period,

even in the absence of signs of hypoxic-ischemic encephalopathy, perisagittal cerebral infarcts were present [Sato S. et al., 2003]. A hypothesis that pre-existing neurological injury prior to delivery takes place in the majority of meconium stained infants, rather than intrapartum injury, was supported by a recent research [Blackwell SC. et al., 2001]. In this study, the risk for developing seizures among neonates with severe MAS was found to be independent from pH levels of the umbilical cord artery, which are associated with intrapartum fetal distress. According to these findings, the conclusion that non-hypoxic-ischemic mechanisms may also cause fetal and neonatal brain injury seems correct.

### 3.2 MSAF and pathogenesis of brain injury

Thus, which is the pathogenetic mechanism that leads to brain injury in cases of infants born through MSAF? The pathophysiologic mechanisms that cause CP remain controversial and cannot be associated with birth injury or intrapartum hypoxic-ischemic insults alone [Kuban KCK et al., 1994]. At the present time, several markers are used for prognostic purposes, with fetal heart rate tracing, the Apgar score in the first and fifth minute after delivery or the presence of recurrent neonatal seizures providing means to indicate the potential for CP in the future. In particular, the latter prognostic factor seems to have greater validity than other perinatal characteristics [Nelson KB. et al., 1977; Kuban KCK et al., 1994]. Of course, ultrasonographic appearance of periventricular leukomalacia is the most reliable sign of future CP development [Kalis V. et al., 2001]. Nevertheless, none of these markers explains the pathogenesis of brain injury after meconium passage, since they are considered to be the consequence rather than the cause of the processes leading to CP.

In order to investigate the potential pathogenetic mechanism of fetal and neonatal brain injury due to MSAF it is necessary to emphasize the possible conditions that lead to meconium passage in utero, these conditions being: hypoxia-anoxia status, intrauterine infection or maturation progress. Consequently, meconium staining is strongly correlated with disorders that could affect the fetus: chorioamnionitis, premature rupture of membranes, abruption placentae and large placental infarcts [Naeye RL., 1992]. Some fetuses suffer acute or chronic episodes, severe enough to cause brain injury, but not intrauterine death. If the stress disappears, the fetus can resume its normal status and not present postpartum depression with low Apgar scores or low umbilical cord artery pH. The neonate may seem neurologically healthy for months after delivery; however, severe neurodevelopmental disorders could be diagnosed years after birth. Similarly, the presence of negative prognostic factors, such as abnormal fetal heart rate tracing or low Apgar scores, may reflect an insult that took place long before delivery (hours to days to even weeks or months) rather than of more immediate intrapartum difficulties.

These observations lead to the conclusion that the intrauterine environment and the causes giving rise to intraamniotic meconium passage are also involved in the pathophysiology of fetal brain injury due to MSAF. It is clear that meconium passage could be a major factor in the pathogenesis of neurological disorders.

The main pathogenetic pathways are two:

- i. Meconium and its components (bile acids) may have a direct vasoconstrictive effect on umbilical and placental vessels [Kalis V. et al., 2001] (Figure 1). This hypothesis was

studied in a research seeking to investigate a potential mechanism of fetal ischemia caused by vasoconstriction of placental or umbilical vessels [Altshuler G. et al., 1989; Altshuler G., 1995]. Vasoactive substances of meconium could cross into the fetal circulation and cause ischemia of cerebral vessels or render pulmonary vessels more reactive, resulting in persistent pulmonary hypertension of the newborn. Additionally, an in vitro experiment that was performed exposing excised umbilical venous tissue to meconium showed substantial vasoconstriction. Although the specific constituent was not identified, the hypothesis that MSAF could cause in vivo placental and umbilical cord vasoconstriction was correct, as the agent was found to be heat-labile.

This pathogenetic pathway underlines the major role of meconium-induced placental necrosis, due to vasoconstrictive effects on umbilical and placental vessels, in fetal brain injury. Meconium in the amniotic fluid may sometimes initiate vasoconstriction on umbilical and placental vessels, which leads to cerebral cortical and subcortical brain damage and finally ischemic-hypoxic CP, as it may reduce the venous return of oxygenated blood from the placenta to the fetus [Naeye RL., 1995]. This theory is in agreement with previously mentioned studies which report that a higher rate of neurological complications is noted among infants born through MSAF if meconium staining of the placenta was present, as meconium-associated vascular necrosis of the placenta is thought to be the main etiological factor associated with neurologic impairment in infants [Redline RW., 2005]. As established by Altshuler, with the passage of meconium into the fetal sac, it takes a minimum of four to twelve hours for the meconium to diffuse to and into the lumens of placental and umbilical cord vessels and become pathogenetic, inducing vasoconstriction [Altshuler G., 1995].

- ii. Meconium causes intraamniotic infection and results in a release of fetal cytokines and eicosanoids (tumor necrosis factor alpha-TNF- $\alpha$ -, interleukin 1 beta-IL-1 $\beta$ -, interleukin 6-IL-6-, interleukin 8-IL-8-, leukotriene B<sub>4</sub>, thromboxane B<sub>2</sub>) which can damage myelinogenesis in periventricular white matter and lead to periventricular leukomalacia as shown in Figure 2 [Kalis V. et al., 2001; Le Bouar G. et al., 2002; Malamitsi-Puchner A. et al., 2006]. The increased incidence of intrauterine infections in the presence of MSAF, as well as the frequent findings of inflammatory lesions in the placenta, umbilical cord, fetal membranes and lungs, underscores the major role of inflammation in the pathogenesis of fetal brain injury. It is well known that proinflammatory fetal cytokines, oxidants and eicosanoids produce an oxidant environment with deleterious and ischemic effects on fetal neural tissue [Naeye RL., 1995; Wu JM. et al., 1995].

It is however more likely that the etiology of fetal brain injury in cases of in utero meconium passage is synergic. This means that both above mentioned pathogenetic pathways could play an important role in the development of brain damage, but when there is a combination of the two main factors (both direct vasoconstriction on placental vessels and intrauterine infection), then the result becomes more severe. Highly interesting studies are accordingly being carried out based on both the toxic vasoconstrictive role of meconium and the deleterious effects of fetal cytokines and other infection-related factors in the presence of MSAF in order to elucidate the pathogenetic mechanism of fetal brain injury [Benirschke K., 2001].



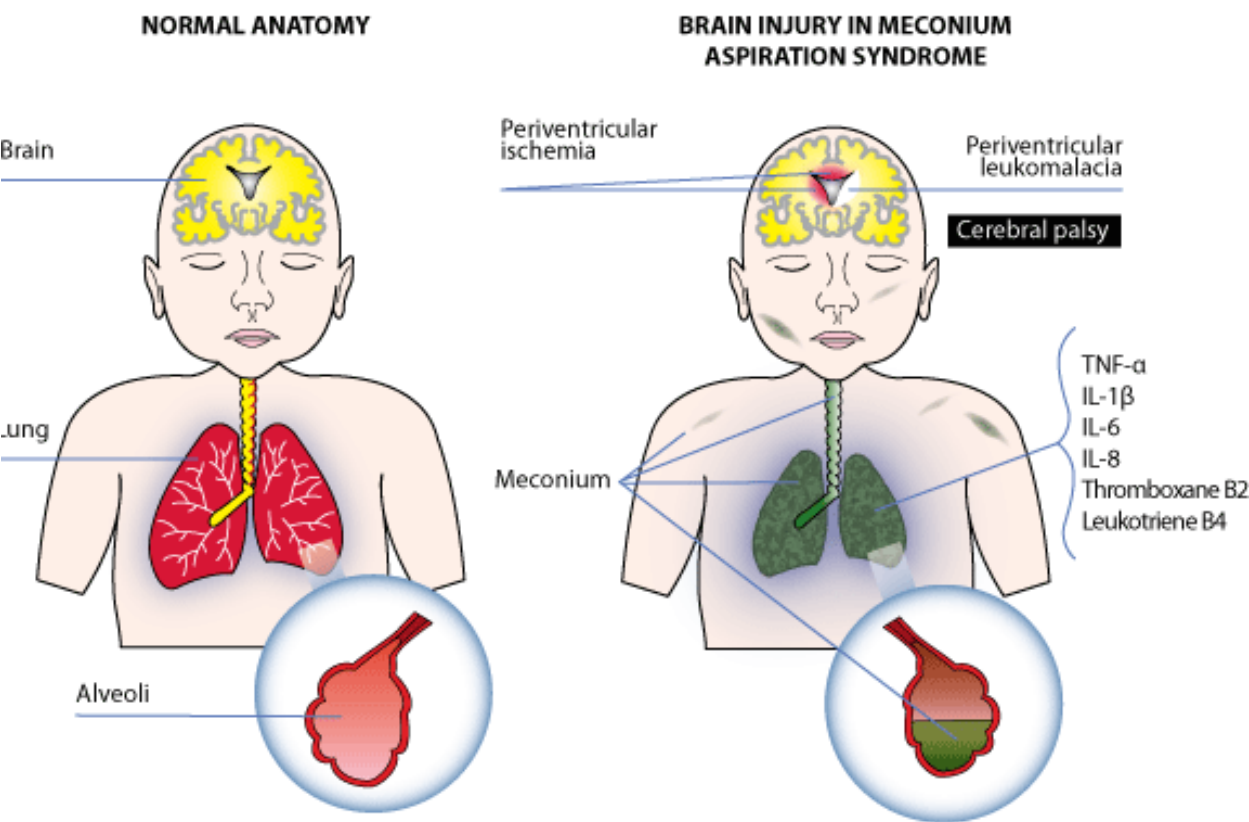


Fig. 2. Pathogenetic pathway of intraamniotic infection due to meconium passage that results in a release of cytokines and eicosanoids from fetal lungs which can damage myelinogenesis and lead to periventricular ischemia and leukomalacia, in comparison with normal neural development in an infant born through clear amniotic fluid without meconium aspiration syndrome.

4. Further neurological abnormalities in children born through MSAF

The vast majority of infants born through MSAF, even after successful management of MAS, do not present symptomatology suggestive of severe neurological disorder due to ante- or intrapartum fetal brain injury. An abnormal fetal heart rate tracing, a low Apgar score in the first and fifth minute after delivery or the presence of recurrent neonatal seizures and symptoms such as hypotonia or lethargy could predict possible CP in future. Nevertheless, even in the absence of these factors during the early postpartum period, an adverse neurodevelopmental outcome, as a result of fetal expose to MSAF, may appear during childhood.

Children born through MSAF present a significantly increased risk for neurologic abnormalities in the 7<sup>th</sup> year of life, including quadriplegic CP, chronic seizures, hyperactivity, moderate or severe motor disability and severe mental retardation (MR) [Naeye RL., 1992].

Additionally, research studies support the existence of a positive correlation between fetal exposure to MSAF and future development of autistic disorder or difficulty with school learning procedures because of concentration deficit.

In conclusion, it is evident that major neurological disorders may arise from fetal or neonate brain injury. It must be the goal of obstetricians to minimize or even eliminate these complications, so catastrophic for the neurological and mental health of children, and to strive for the best perinatal management and thus outcome for both the mother and the neonate.

## 5. Conclusions

It is true that most infants born through MSAF will be neurologically healthy. Nonetheless, there is substantial documentation of the existence of a close relationship between MSAF/MAS and development of future neurological abnormalities, as well ample evidence that meconium passage may be the main etiological factor in the pathogenesis of neurological disorders in a significant percentage of children without other obstetrical complications.

The intrauterine environment and the causes giving rise to intraamniotic meconium passage (i.e. hypoxia-anoxia status, intrauterine infection) are also involved in the pathogenesis of fetal brain injury due to MSAF, this possibly being activated via two as yet hypothesized pathways that may act in an either independent or synergic way. The direct vasoconstrictive and/or deleterious long-term in utero effect of meconium results in severe fetal brain injury due to the reduced venous return of oxygenated blood from the placenta to the fetus and/or the environment produced by proinflammatory fetal cytokines, oxidants and eicosanoids which is highly toxic for the fetal neural tissue.

In the vast majority of cases, severe neurologic handicaps do not appear during the early postpartum period. However, the possibly remains that an adverse neurodevelopmental outcome combined with fetal exposure to MSAF could be diagnosed during childhood, or even in the first years of school, translated as pronounced learning difficulties. Cerebral palsy and severe mental retardation are major neurological disorders which are diagnosed more frequently in cases of children born through MSAF in comparison with those born through clear amniotic fluid. Their pathogenetic pathway is likely to have the same origination, which is severe fetal and neonatal brain injury. Needless to say, perinatal care has progressed vastly in the present day and the rate of these complications as well the mortality and morbidity rate after MSAF or MAS are correspondingly much decreased. However, bearing in mind the potential for these adverse outcomes, catastrophic for the neurological and mental future of the child, an uneventful late pregnancy and labor culminating in the optimal perinatal result for both the mother and the neonate must be the goal of every physician.

## 6. References

- Altshuler G, Hyde S. Meconium-induced vasocontraction: a potential cause of cerebral and other fetal hypoperfusion and of poor pregnancy outcome. *J Child Neurol* 1989;4:137-142
- Altshuler G. Placental insights into neurodevelopmental and other childhood diseases. *Semin Pediatr Neurol* 1995;2:90-99.
- Benirschke K. Fetal consequences of amniotic fluid meconium. *Contemp Obstet Gynecol* 2001;46: 76-83.

- Berkus MD, Langer O, Samueloff A, Xenakis EM, Field NT, Ridgway LE. Meconium-stained amniotic fluid: increased risk for adverse neonatal outcome. *Gynecol* 1994;84:115-120.
- Blackwell SC, Moldenhauer J, Hassan SS, Redman ME, Refuerzo JS, Berry SM, Sorokin Y. Meconium aspiration syndrome in term neonates with normal acid-base status at delivery: is it different? *Am J Obstet Gynecol* 2001;184:1422-1426.
- Brews A. Fetal asphyxia. In Eden Hollands Manual of Obstetrics, 9<sup>th</sup> edn. London: Churchill, 1948:609-612.
- Brown CA, Desmond MM, Lindley JE, Moore J. Meconium staining of the amniotic fluid: a marker of fetal hypoxia. *Obstet Gynecol* 1957;9:91-103.
- Cleary GM, Wiswell TE. Meconium-stained amniotic fluid and the meconium aspiration syndrome: an update. *Pediatr Clin N Am* 1998;45:511-529.
- Clifford SH. Clinical significance of yellow staining of the vernix caseosa, skin, nails, and umbilical cord of the newborn. *Am J Dis Child* 1945;69:327-328.
- Fleischer A, Anyaegbunam A, Guidetti D, Randolph G, Merkatz IR. A persistent clinical problem: profile of the term infant with significant respiratory complications. *Obstet Gynecol* 1992;79:185-190.
- Fraser WD, Hofmeyer J, Lede R, Faron G, Alexander S, Goffinet F, Ohisson A, Goulet C, Turcot-Lemay L, Prendiville W, Marcoux S, Laperriere L, Roy C, Petrou S, Xu HR, Wei B, Amnioinfusion Trial Group. Amnioinfusion for the prevention of the meconium aspiration syndrome. *N Engl J Med* 2004;353:909-917.
- Fujikura T, Klionsky B. The significance of meconum staining. *Am J Obstet Gynecol* 1975;121:45-50.
- Gaffney G, Sellers S, Flavell V, Squier M, Johnson A. Case-control study of intrapartum care, cerebral palsy, and perinatal death. *BMJ* 1994;308:743-750.
- Grafe MR. The correlation of prenatal brain damage with placental pathology. *J Neuropathol Exp Neurol* 1994;53:407-415.
- Kalis V, Turek J, Hudec A, Rokyta Z, Mejchar B. Meconium and postnatal neurologic handicaps. *Ceska Gynecol*. 2001;66(5):369-377.
- Krebs HB, Peters RE, Dunn LJ. Intrapartum fetal heart rate monitoring III. Association of meconium with abnormal fetal heart rate patterns. *Am J Obstet Gynecol* 1980;137:936-943.
- Kuban KCK, Leviton A. Cerebral palsy. *N Engl J Med* 1994;330:188-195.
- Lien JM, Towers CV, Quilligan EJ, de Veciana M, Toohey JS, Morgan MA. Term early-onset neonatal seizures: obstetric characteristics, etiologic classifications, and perinatal care. *Obstet Gynecol* 1995;85:163-169.
- Le Bouar G, Lassel L, Poulain P. Markers of infection and inflammation in the amniotic fluid: Therapeutic contribution of amniocentesis. *J Gynecol Obstet Biol Reprod (Paris)* 2002;31(7 Suppl):5S52-56.
- Malamitsi-Puchner A, Vrachnis N, Samoli E, Baka S, Hassiakos D, Creatsas G. Elevated second trimester amniotic fluid interferon gamma-inducible T-cell alpha chemoattractant concentrations as a possible predictor of preterm birth. *J Soc Gynecol Investig*. 2006; 13(1):25-29.
- Matsuishi T, Yamashita Y, Ohtani Y, Ornitz E, Kuriya N, Murakami Y, Fukuda S, Hashimoto T, Yamashita F. Brief report: incidence of and risk factors for autistic disorder in neonatal intensive care unit survivors. *J Autism Dev Disorders* 1999;29:161-166.

- Mazor M, HersHKovitz R, Bashiri A, Maymon E, Schreiber R, Dukler D, Katz M, Shoham-Vardi I. Meconium stained amniotic fluid in preterm delivery is an independent risk factor for perinatal complications. *Eur J Obstet Gynecol Reprod Biol.* 1998;81:9-13.
- Miller FC, Read JA. Intrapartum assessment of the postdate fetus. *Am J Obstet Gynecol* 1981;141: 516-520.
- Naeye RL. Disorders of the Placenta, Fetus, and Neonate: Diagnosis and Clinical Significance. St.Louis , MO: Mosby Year Book, 1992:257-268, 330-352.
- Naeye RL. Can meconium in the amniotic fluid injure the fetal brain? *Obstet Gynecol* 1995;86(5): 720-724.
- Nathan L, Leveno KJ, Carmody TJ, Kelly MA, Sherman ML. Meconium: a 1990s perspective on an old obstetric hazard. *Obstet Gynecol* 1994;83:329-332.
- Nelson KB, Broman SH. Perinatal risk factors in children with serious motor and mental handicaps. *Ann Neurol* 1977;2:371-377.
- Nelson KB. Perspective on the role of perinatal asphyxia in neurologic outcome: its role in developmental deficits in children. *CMAJ* 1989;141:3-10.
- Nelson KB, Ellenberg JH. Obstetric complications as risk factors for cerebral palsy or seizure Disorders. *JAMA* 1984;251:1843-1848.
- Ramin K, Leveno K, Kelly M. Observations concerning the pathophysiology of meconium aspiration syndrome. *Am J Obstet Gynecol* 1994;170:312 (#124).
- Redline RW. Severe fetal placental vascular lesions in term infants with neurologic impairment. *Am J Obstet Gynecol* 2005;192:452-457.
- Reed CB. Fetal death during labor. *Surg Gynecol Obstet* 1918;26:545-551.
- Sato S, Okumura A, Kato T, Hayakawa F, Kuno K, Watanabe K. Hypoxic ischemic encephalopathy associated with neonatal seizures without other neurological abnormalities. *Brain Dev* 2003;25:215-219.
- Shields JR, Schiffrin BS. Perinatal antecedents of cerebral palsy. *Obstet Gynecol.* 1988;71:899-905.
- Spinillo A, Capuzzo E, Stronati M, Ometto A, De Santolo A, Acciano S. Obstetric risk factors for periventricular leukomalacia among preterm infants. *Br J Obstet Gynaecol* 1998;105:865-871.
- Spinillo A, Fazzi E, Capuzzo E, Stronati M, Piazzzi G, Ferrari A. Meconium-stained amniotic fluid and risk for cerebral palsy in preterm infants. *Obstet Gynecol* 1997;90:519-523.
- Starks GD. Correlation of meconium stained amniotic fluid, early intrapartum fetal pH, and Apgar scores as predictors of perinatal outcome. *Obstet Gynecol* 1980;56:604-609.
- Steer PJ, Eigbe F, Lissauer TJ, Beard RW. Interrelationships among abnormal cardiotocograms in labor, meconium staining of the amniotic fluid, arterial cord blood pH, and Apgar scores. *Obstet Gynecol* 1989;74:715-721.
- Vain NE, Szyld EG, Prudent LM, Wiswell TE, Aquilar AM, Vivas NI. Oropharyngeal and nasopharyngeal suctioning of meconium-stained neonates before delivery of their shoulders: multicentre, randomized controlled trial. *Lancet* 2004;364:597-602.
- Vrachnis N, Vitoratos N, Iliodromiti Z, Sifakis S, Deligeoroglou E, Creatsas G. Intrauterine inflammation and preterm delivery. *Ann N Y Acad Sci.* 2010;1205:118-122.
- Walker J. Foetal anoxia. *J Obstet Gynecol Br Empire* 1954;61:162-180.
- Wen TW, Eriksen NL, Blanco JD, Graham JM, Oshiro BT, Prieto JA. Association of clinical intra-amniotic infection and meconium. *Am J Perinatol* 1993;10:438-440.

- Wiswell TE, Bent RC. Meconium staining and the meconium aspiration syndrome: unresolved issues. *Pediatr Clin N Am* 1993;50:955-981.
- Wiswell TE, Gannon CM, Jacob J, Goldsmith L, Szyld E, Weiss K, Schutzman D, Cleary GM, Filipov P, Kurlat I, Caballero CL, Abassi S, Sprague D, Oltorf C, Padula M. Delivery room management of the apparently vigorous meconium-stained neonate: results of the multicenter, international collaborative trial. *Pediatrics* 2000;105:1-7.
- Wiswell TE, Tuggle JM, Turner BS. Meconium aspiration syndrome: have we made a difference? *Pediatrics* 1990;85:715-721.
- Woods JR, Glantz JC. Significance of amniotic fluid meconium. In: Creasy RK, Resnik R, editors. *Maternal-Fetal Medicine: Principles and Practice*. Philadelphia: WB Saunders, 1994;413-422.
- Wu JM, Yeh TF, Lin YJ. Increases of leukotriene B4 (LTB4) and D4 (LTD4) and cardio-hemodynamic changes in newborn piglets with meconium aspiration (MAS). *Pediatr Res* 1995;37:357A



© 2012 The Author(s). Licensee IntechOpen. This is an open access article distributed under the terms of the [Creative Commons Attribution 3.0 License](https://creativecommons.org/licenses/by/3.0/), which permits unrestricted use, distribution, and reproduction in any medium, provided the original work is properly cited.

IntechOpen

IntechOpen