

We are IntechOpen, the world's leading publisher of Open Access books Built by scientists, for scientists

6,900

Open access books available

186,000

International authors and editors

200M

Downloads

Our authors are among the

154

Countries delivered to

TOP 1%

most cited scientists

12.2%

Contributors from top 500 universities



WEB OF SCIENCE™

Selection of our books indexed in the Book Citation Index
in Web of Science™ Core Collection (BKCI)

Interested in publishing with us?
Contact book.department@intechopen.com

Numbers displayed above are based on latest data collected.
For more information visit www.intechopen.com



Biomechanics of the Fractured Femoral Neck – The New BDSF-Method of Positioning the Implant as a Simple Beam with an Overhanging End

Orlin Filipov

Additional information is available at the end of the chapter

<http://dx.doi.org/10.5772/47839>

1. Introduction

The femoral neck fracture is subjected to powerful shearing forces due to the angular, spiral-like architecture of the proximal femur. Under the conditions of severe *osteoporosis*, the *femoral neck* consists of cortical walls, enveloping soft cancellous bone, having unimportant mechanical significance, and the neck can often be looked at as a hollow cylinder. If the condition of patient is not appropriate for total hip replacement (mental diseases or other risks), and a decision is made for a screw fixation, the implanted screws must be solidly fixed in the distal fragment in at least two points in order to provide resistance to the shearing forces in case of osteoporosis. The traditional screw fixation methods, however, do not meet the above-named requirement. Present-day popular *traditional methods* of femoral neck fixation, which are performed by three cancellous screws, placed parallel to each other and parallel to the femoral neck axis, are associated with poor results in 20 to 42% [1,2,3,4,5]. The high failure rate of traditional screw fixation methods can be explained by the presence of a number of related biomechanical imperfections. (1) *Instability of the construction regarding varus stress*. The entry points of the three screws in traditional screw fixation methods are located at the thin, fragile cortex of the greater trochanter or close to it. The screws are often placed in the soft cancellous bone near the axis of the femoral neck, with no cortical support [6]. Even if one or two of the distal screws are placed close to the distal cortex of the femoral neck, they lack any second solid point of support. A second point of support for them is the thin and fragile lateral cortex of the greater trochanter – their entry point. Such a construction can rely only on the interfragmental compression, generated by the intraoperative tightening of the screws, but the achieving of compression depends on the

solidity of the cancellous bone. This circumstance results in high failure rate in cases of osteoporosis. (2) *Lack of sliding phenomenon*. Upon body weight loading, in the process of the subsequent wedging of the osteoporotic cancellous bone in the fracture site, the screws of traditional methods of fixation, which lack two-point cortical support, cannot effectively slide distally and laterally keeping unchanged their angle towards the axis of diaphysis, and rather have expressed tendency to displace in varus, with fixation failure. (3) *Inability to move the entry point of the screws distally into the solid diaphyseal cortex, and simultaneous placing of three parallel screws*. In 1961 Garden [7], like other authors before, further developed the concept that the implants must have more vertical placement, similar to the direction of the medial compression lamellae of the femoral neck internal trabecular system, in order to provide resistance to the shearing forces. However, when developing this concept, the classic authors used only one implant (a nail). Thus the implant successfully provided resistance to the shearing forces, but it did not create compression between the fragments, because it is not a screw and it is also not able to ensure reliable rotational stability of the head fragment, being only one [8,9,10].

The anatomy of proximal femur does not allow simultaneous placing of three screws, which are parallel to each other, and lie near the cortex in the periphery of the femoral neck and, at the same time, have their entry points positioned distally, in the solid cortex of the diaphysis, in order to avoid the fragile lateral metaphyseal cortex.

When applying the *conventional* methods of positioning three parallel screws, in case movement of the screw entry point distally is attempted, the screws will be placed at a very obtuse angle towards the diaphysis and obliquely to the femoral neck. By increasing the angle of penetration, the surface of the femoral neck cross-section decreases geometrically, and in practice the placement of more than one or two screws is hard to be accomplished. However, a two-screw fixation does not provide reliable stability in all planes [10]. Both problems are resolved by the newly introduced method of *Biplane Double-supported Screw Fixation* through the concept of biplane positioning of the implants.

The *Biplane Double-supported Screw Fixation Method in femoral neck fractures (BDSF-method)*, developed by O. Filipov, is a new method of screw fixation in femoral neck fractures, based to *an original concept of the establishment of two supporting points for the implants and their biplane positioning* in the femoral neck and head. The console-like proximal femur requires the fixation screws to have to support the weight-bearing head fragment, acting like a *beam with an overhanging end*, which must have two points of support in the distal fragment. The concept of the Biplane Double-supported Screw Fixation (BDSF) method is based on this principle. This method is original with the three screws being laid in two planes, which aspect allows the entry points of two of the implants to be placed much more distally, in the solid cortex of the proximal diaphysis, and also to lean onto the strong femoral neck distal cortex. Thus, we establish two points of support. The achieved by this method position of the distal screw and the middle screw as well, in view of statics, turns them into a *simple beam with an overhanging end, loaded by a vertical force*. This beam with an overhanging end successfully supports the head fragment, bearing the body weight and transferring it to the diaphysis.

2. Biplane double-supported screw fixation method - Operative technique

Indications: Fractures of the Garden types from I to IV. The indications and contraindications for application of the BDSF-method are generally the same as of the conventional methods for fixation of the femoral neck fractures. The BDSF-method significantly expands the indications for application of screw fixation in terms of the bone, changed by osteoporosis. The method is most useful and has no reasonable alternative in adult patients above 80 years with a high cardiopulmonary risk, as in patients with severe concomitant diseases, inclusively some mental diseases, patients with senile dementia, and others, for which the primary joint replacement may be contraindicated.

Implants: 7.3 mm self-tapping cannulated screws

Reduction: Mild traction, slight abduction and internal rotation of the limb are applied. Only anatomical reduction is acceptable.

Approach. A straight lateral incision, starting at the level of the lower border of the greater trochanter, with distal length of 6 to 10 cm. A stripping of the periosteum of the lateral diaphysis at 6-7 cm is performed.

Placement of the implants. When applying the BDSF-method, the three cannulated screws are placed in the frontal plane at a highly increased angle. Both the distal and the middle screws touch tangentially on the curve of the distal femoral neck cortex (Fig.1-a.). At internal rotation of the leg, in anteroposterior view, the projection of the distal screw usually crosses the projections of the other two screws, thus forming the letter F (F-technique). Via the concept of *biplane positioning*, developed by the BDSF-method, the three screws are placed in two vertical oblique planes (in lateral view). The two planes diverge towards each other in the direction of the femoral head, and are oblique towards the frontal plane. The distal screw is laid in the dorsal oblique plane. The middle and the proximal screws are placed in the ventral oblique plane (Fig.1-b.).

First of all, we lay the guiding wire for the distal cannulated screw. Its tip is placed at 5-7 cm distally from the lower border of the greater trochanter in the anterior one-third of the surface of the stripped off diaphysis. It is directed proximally at an angle of 150 – 165° towards the diaphyseal axis, with inclination from anterodistally to posteroproximally, so that after it touches tangentially on the curve of the distal femoral neck cortex, the wire goes into the dorsal third of the femoral head.

The middle guiding wire is placed secondly. The entry point is at 2 to 4 cm proximally from the entry point of the distal wire, but in the dorsal one-third of the stripped off surface of the diaphysis. This wire is placed at an angle of 135-140° towards the diaphyseal axis and inclined from posterodistally to anteroproximally, so that after it touches tangentially on the curve of the distal femoral neck cortex, the wire goes into the front one-third of the femoral head. In the frontal plane (anteroposterior view) the tip of this guiding wire goes into the distal one-third of the femoral head.

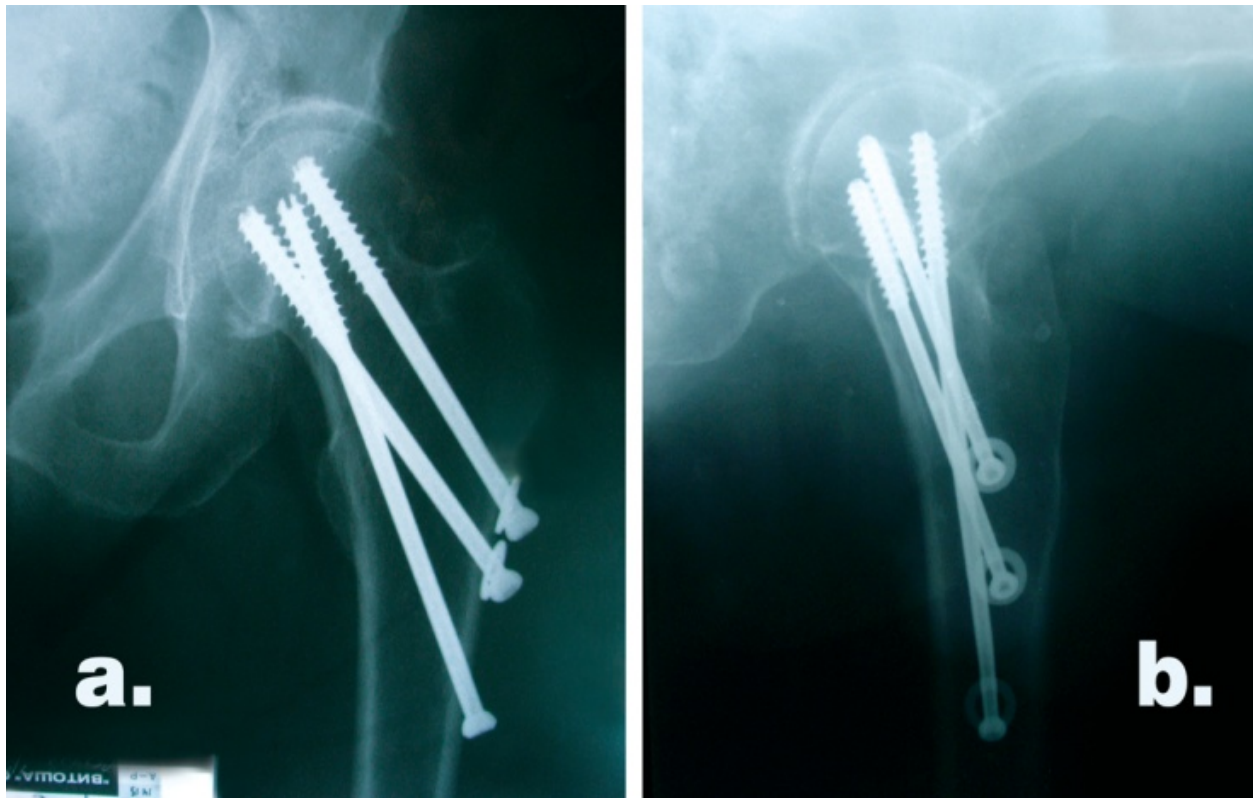


Figure 1. Radiography. a. Anteroposterior view; b. Lateral view.

Last to be laid is the proximal guiding wire, with its entry point at 1-2 cm proximally from the entry point of the middle wire, in the dorsal one-third of the stripped off diaphysis, close to the lower border of the greater trochanter. Placed parallel to the middle wire, the proximal wire also goes into the front one-third and into the proximal one-third of the femoral head.

Afterwards we drill and place the screws one by one. Before placing the middle and distal screws, we overdrill their holes in the thick lateral cortex by using a 7.0 mm cannulated reamer.

The middle and the proximal screws are placed first, because they are perpendicular to the fracture surface. Next we release the foot traction, and a repeated impaction of the fracture with an additional tightening up of the screws follows. We perform the impaction gently by hammering on a plastic impactor on the diaphyseal cortex. Finally, the distal screw is placed.

The guiding wire easily changes its initial direction when passing through the thick diaphyseal cortex, therefore its tip is guided into the necessary direction by the surgeon's free hand with the help of a cannulated instrument.

When we place the two distal guiding wires tangentially over calcar femorale, if we suddenly feel resistance, it indicates that the tip has got into the medial diaphyseal cortex distally from the femoral neck. In such a case we change the direction by increasing the

angle of penetration. For this purpose we use the same hole in the lateral cortex, by taking out the wire completely and after a change in the direction of the wire, we try by the high-speed rotating trocar tip to change the direction of the channel in the cortical hole, in order to achieve the necessary angle of the wire through the bone. Sometimes, it is necessary to leave the old hole and to bore anew next to it. Sometimes, although very rarely, that is not sufficient and release from the thick lateral cortex is required, by reaming around the placed in poor position guiding wire by the 4.5 mm cannulated reamer. Thus the wire is freed from its contact with the lateral cortex in the created opening of 4.5 mm and is easily directed in the necessary direction.

The placing of screws under very oblique angle requires following of the principle for their two-plane positioning and none of the screws must be placed in the central part of the femoral neck and head (in profile projection). If some of the screws are placed in the central part of femoral neck, it will be an obstacle for placing of the other two screws. The distal screw, which is more obliquely placed, must be located in the posterior part of the femoral neck and head. If in violation of BDSF-technique it is placed in the anterior part of the femoral head, then because of the physiological anteversion of the femoral neck, it will be difficult or impossible for the other two screws to be placed in the posterior part of the femoral neck, because there is a tendency to find them too marginally at the cortex of the femoral head.

Radiographic time: from 0.2 to 0.3 minutes

Mean operative time: 39 min (30 to 45 min)

Postoperative period. Limited weight bearing for 4-6 months, by using two crutches would be perfect, if the patient is cooperative.

3. Biomechanical basis of the BDSF-method

This method's innovation is laying of the three screws in two planes, which allows for the entry points of two of the implants to be placed much more distally, in the solid cortex of the proximal diaphysis, and also to lean onto the femoral neck distal cortex. Thus we establish two points of support. The solid distal cortex of the femoral neck acts as a medial supporting point for the screws, which works under pressure - *supporting point A*. The entry points of two of the screws (the distal and the middle one) in the thick cortex of the diaphysis, ensure a second solid supporting point for the screws – a lateral one, which works under tension (or pressure in proximal direction) - *supporting point B*. The position of the distal screw as well as of the middle screw, which are achieved by the method, in terms of the *statics*, turns them into *a simple beam with an overhanging end, loaded by a vertical force*. This beam with an overhanging end successfully supports the head fragment, bearing the body weight and transferring it to the diaphysis. Furthermore, due to the biplane placement, enough space for a third screw is provided, unlike the classic authors' models, where just one or maximum two implants are placed at an obtuse angle [7,11]. Another advantage of the

method is that due to the increase in the distance between the two supporting points, the weight borne by the bone is significantly reduced (*see the static analysis*). An advantage of the BDSF-method is that the entry points of the screws are positioned wide apart from each other, which ensures that upon weight bearing, the tensile forces spread over a greater surface of the lateral cortex and thus the risk of its fracturing decreases significantly. Another advantage with the BDSF is that the screw, placed at a highly increased angle, works in a direction close to the direction of the loading force, which guarantees better results for the screw in its role as a beam because the influence of its sagging decreases.

4. Static analysis

With the *conventional methods* of femoral neck fixation - by three cancellous screws, placed parallel to each other and parallel to the femoral neck axis, the entry points of the three screws are placed at the thin, fragile cortex of the greater trochanter or close to it. The screws are often located near the axis of the femoral neck in the soft cancellous bone, without any cortical support. According to my previous investigations [12], with *conventional methods*, due to the lack of two solid supporting points, the implant acts statically like a *beam on an elastic foundation*. The elastic foundation is implemented by the soft cancellous bone (Fig.2).

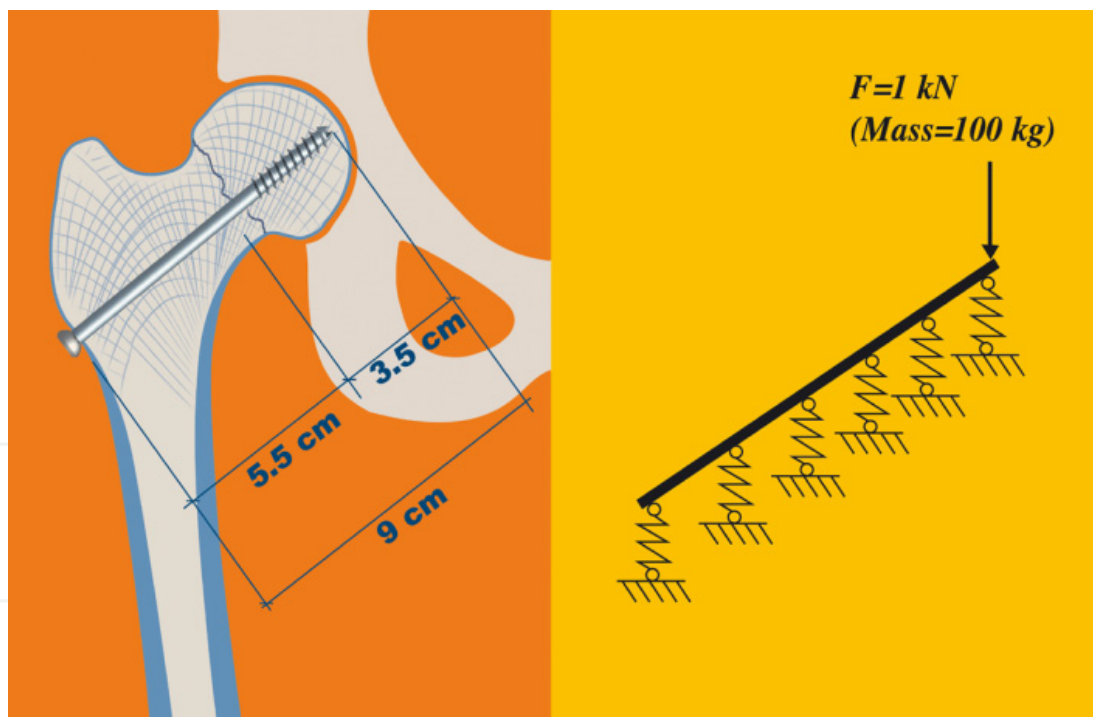


Figure 2. Static model of the conventional methods of fixation – the implant acts statically like a beam on an elastic foundation. $F = \text{load}$;

In contrast to the conventional methods, when the *Biplane double-supported screw fixation - method* is applied, the implant is additionally supported at points **A** and **B** of the cortex. The interaction between the implant and the cancellous bone is neglected, because of the comparatively small stiffness of the cancellous bone. In this way, with enough practical

accuracy, with the BDSF-method, the static model is considered to be *a simple beam with an overhanging end* (Fig.3). This beam is supported at points **A** and **B** only.

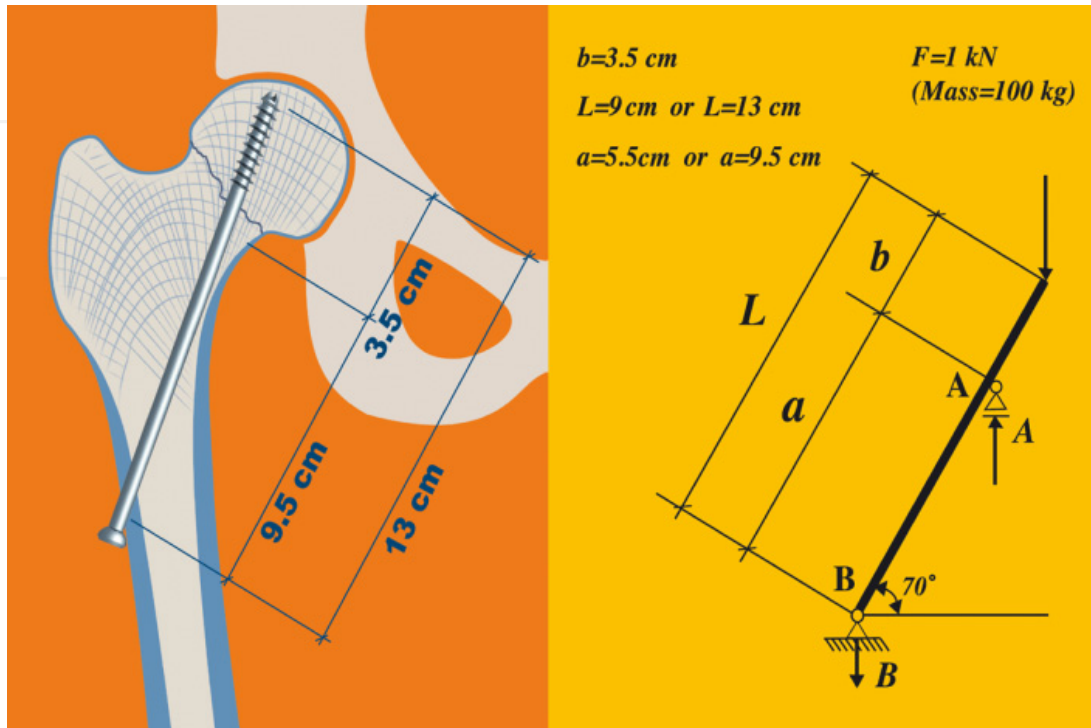


Figure 3. Static model of the new BDSF-method of fixation – the implant acts like a simple beam with an overhanging end. F = load; L = length of beam; a = distance between points **A** and **B**

Applying the well-known equilibrium equations for a beam, we obtain the forces acting on the cortex at supporting points **A** and **B**.

The load acting at point **A** is pressure in a distal direction and it equals to $A = \frac{FL}{a}$;

The load acting at point **B** is pressure in a proximal direction and it equals to $B = A - F$.

At the BDSF-method, due to the increase in the distance between the two supporting points, the weight borne by the bone is reduced. If we look at two cases of equal vertical weight but different distances between the supporting points, we will see that the greater the distance, the smaller the weight at each of the two supporting points.

The average anatomical distance from the tip of the screw to the distal femoral neck cortex curve (**point A**) is 3.5 cm (Fig. 4.).

With *conventional methods (case 1.)* the average distance from **point A** to the entry point of the screws in the lateral cortex (**point B**) is 5.5 cm ($a = 5.5$ cm). In order to make a comparison with the BDSF, when body weight of 100 kg is given, with conventional methods the load acting on the curve of the femoral neck distal cortex (if the screws lean on this support at all) is estimated as

A equal to 1.63 kN (163.63 kg). The load on the fragile lateral cortex (**point B**) is estimated as **B** equal to 0.63 kN (63.63 kg), directed in the opposite direction (proximally).

With the *BDSF method (case 2.)*, with increasing the angle of the implant towards the diaphysis, the distance between points **A** and **B** increases by 4 cm to reach up to 9.5 cm ($a = 9.5$ cm). That is why, the load on the cortex decreases significantly. Given the same body weight of 100 kg, the load acting on the medial supporting point is estimated as **A** equal to 1.36 kN (136.84 kg) or with 16.38% less than conventional methods, and on the lateral supporting point the load is estimated as **B** equal to 0.36 kN (36.84 kg) or with 42.11% less than conventional methods. The distal screw normally applied with the BDSF method has a length of 13 cm.

The lateral cortex stress state around point **B** is complex. It is subjected to compressive stress in a proximal direction, and to horizontal tensile stress as well. In the lower part of the cortex the stress is mainly tensile.

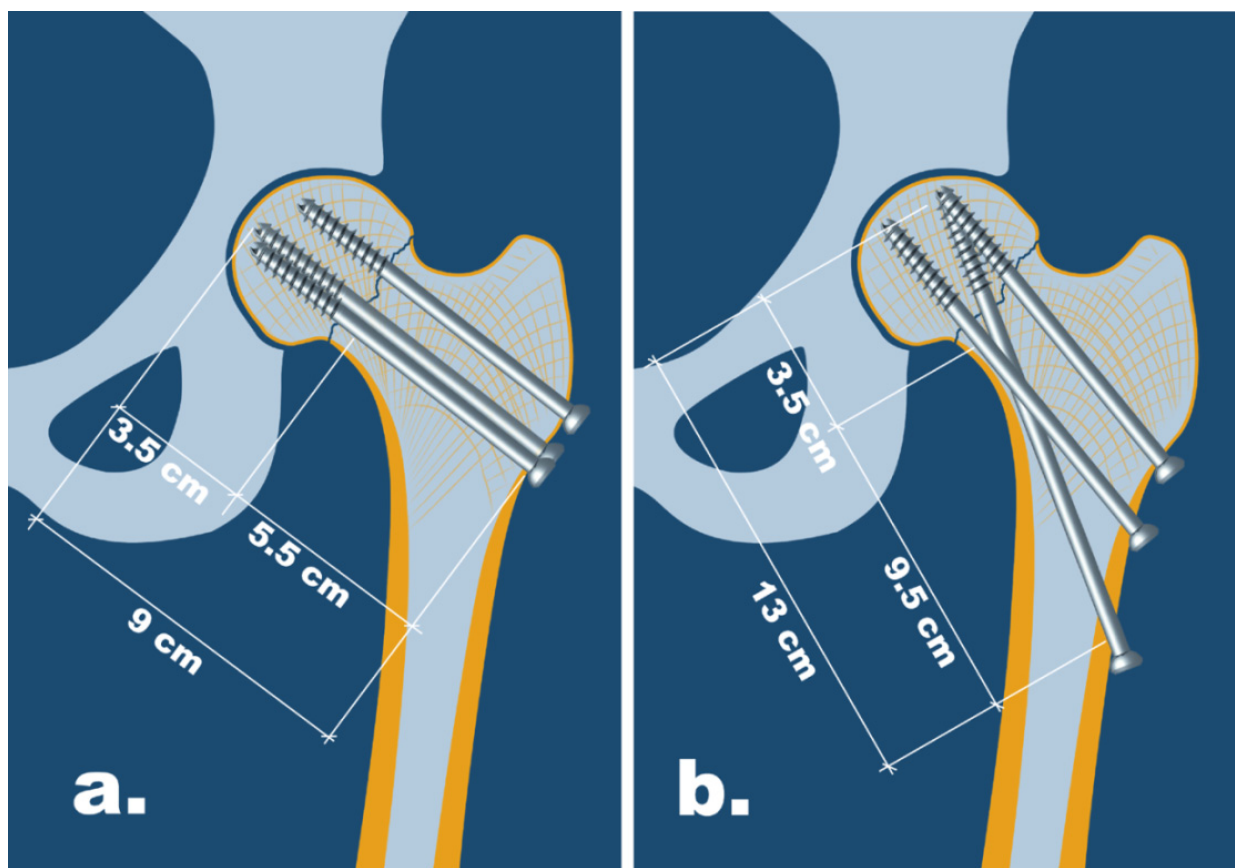


Figure 4. Fixation of the femoral neck: a. Conventional method; b. The BDSF-method. [12]

These forces of tension are responsible for the occurrence of subtrochanteric fracture as a complication of the screw fixation. As it was mentioned, these forces of tension are decreased by 42% with the BDSF-method, compared to the conventional methods of fixation. Besides, with the BDSF-method the entry points of the screws are located wide apart from each other (from 2 to 4 cm), which leads to dispersion of the tension stress on the

lateral cortex over a wide surface and decrease of the fracture risk, contrary to the conventional methods, with which the entry points of the screws are at a distance less than 1 cm from each other and the forces of tension are concentrated over a small surface.

5. Clinical results of the BDSF-method

The BDSF-method was introduced in 2007 and it was applied by different surgeons since then. From a series of 178 patients, who underwent surgical treatment, 88 were studied [12]. Inclusion criteria was having late control x-rays and examinations after discharge with questionnaires filled-in. Out of the 88 studied patients, 27(30.68%) were male and 61(69.31%) - female patients; the average age was 76.9 (with the youngest patient at the age of 38 and the eldest at the age of 99). Grouping patients by age: 18 patients (20.45%) were at the age of under 69; 27 patients (30.68%) were at the age of 70 to 79; 37 patients (42.04%) were at the age of 80 to 89; 5 patients (5.68%) were at the age of 90 to 95 ; 1 patient (1.13%) was aged 95 to 100. More than one concomitant disease, which influences the results of Harris Hip Score, was found in 21 patients (23.86%). The average follow-up period is 8.06 months.

The Garden classification was used for classifying of the fractures as follows:

Garden type I: 3 (3.41%); Garden type II: 1 (1.14%); Garden type III: 9 (10.23%); Garden type IV: 75 (85.02%).

Results. From the studied 88 patients fracture union was registered in 87 patients (98.86%) and failure in 1 patient (1.13%).

Assessment according to the Harris Hip Score (modified): Poor results – in 10 patients (11.36%). Fair results – in 20 patients (22.72%). Good results – in 21 patients (23.86%). Excellent results – in 37 patients (42.04%).

The average Harris Hip Score is 84.26 points [13].

6. Unusual and difficult cases

Difficult for management are the unstable fractures and the fractures with vertical fracture line Pauwels type III.

Unstable fractures. In the elderly patients, at the age above 80, the preoperative reduction is usually achieved easily because of the fact that the fracture occurs upon low-energy trauma and although it seems displaced at a diagnostic X-rays (Garden III and IV), the fracture is usually stable and in the process of reduction there is a good control over the head fragment.

In younger and active patients the fracture usually occurs with more severe traumatic influence, for example falling over slippery surface, falling from a greater height (from stairway or in road accidents). In these cases more severely expressed tearing of soft tissues around the fracture occurs frequently and the fracture is severely displaced. Following the

incident some patients try to get up and step on the limb, thus causing additional displacement of the fracture or additional fragmentation, which turns one banal fracture of the femoral neck into a an unstable fracture. When there is a severe displacement of the fracture, clinically the patients are with more expressed external rotation and shortening of the limb and have a history of more severe traumatic influence, or patients report for attempts of getting up and stepping, followed by repeated falling. At a diagnostic X-ray the usually registered grade according to Garden is type IV+ with severe external rotation of the distal fragment. In these cases frequently is found that the distal fragment “hangs” at the fracture table on the lateral view under its own limb weight. In such cases the reduction and fixation can turn to be extremely difficult and a doubtful prognosis of the femoral head survival can be assessed. It is reasonable in such patients if they are not at a young age a decision to be made for a primary joint replacement. In the presence of contraindications for joint replacement, if, nevertheless, a decision is made for metal fixation, we try the usual preoperative reduction: traction, abduction and internal rotation or sometimes a reposition by Leadbetter. If the preoperative reduction is not successful, we use frequently the intraoperative reduction, as under the conditions of sterility, the hanging distal fragment is lifted by the surgical assistant or by a special attachment of the fracture table. With achieving of reduction we use the guiding wires for temporary fixation of the fracture, followed by screw fixation. The intraoperative reduction is a procedure with a high risk for failure and the beginning of the surgery without a successful preoperative reduction of the femoral neck fracture frequently is followed by an open reduction.

There exists a group of *unstable* fractures, with which the proximal fragment is too rotated and stands in valgus position, with fracture surface directed laterally. A frequent cause for this is the V-shaped fracture surface with presence of a spicule, which is obstructive to the reduction. If after an attempt for reduction on the fracture table by abduction, traction and internal rotation, the fracture reduction remains unsatisfactory, we apply a developed by the author method for reduction by traction, abduction, external rotation, release of traction, internal rotation and adduction.

Filipov's technique: The traction is increased, the limb is abducted and externally rotated in order to wedge away the fragments of the vicious position; next a complete release of the traction is applied and thus the distal fragment skips the obstacle and comes into contact with the head fragment placed in valgus in a new mode. Then internal rotation is applied and adduction of the limb, with the distal fragment reaching the head fragment in anatomical position or achieving reduction.

Sometimes the unstable fractures of the femoral head require open reduction.

The fractures with vertical fracture line (*Pauwels type III*) are difficult for metal fixation. If the patient is with contraindications for primary joint replacement (young age) and it however requires metal fixation, the popular method of choice are the implants with fixed angle [14]. In these fractures the curve of the femoral neck distal cortex is included to the proximal fragment and it makes inefficient the fixation with screws alone. In vertical fracture line a

good fixation is achieved with the 130° blade-plate, placed low in the distal one-third of the femoral neck. In order to be avoided fracture displacement during the placing of the blade of the plate, I recommend, following placing of the guiding wire for the blade of the plate, to be performed preliminary fixation of the fracture with one cannulated 7.3 mm screw, placed in the upper one-third of the femoral neck, parallel to the guiding wire for the blade of the plate. The fixed angle of the blade of the plate successfully counteracts to the shearing forces and its double-L cross-section counteracts to the torsion forces until reaching of healing. An alternative technique is a valgus accomplishing osteotomy at the level of lesser trochanter, with fracture surface placed into more horizontal plane and shearing forces turned into compressive. The fixation is with a DHS-plate or with 130° blade-plate. For the Pauwels type III fractures in the present are used successfully *locking plates*.

7. Other popular methods for fixation of the femoral neck

The present methods for fixation of the femoral neck are two types: fixation with cancellous screws and fixation with massive implants with fixed angle.

Methods for fixation of the femoral neck with cancellous screws. At present different methods for screw fixation are used, with typical for the conventional methods placement of the screws parallel to each other and parallel to the axis of the femoral neck. The most popular are the methods with three parallel screws, placed in a configuration of a triangle – two screws distally and one screw proximally; the inverted triangle configuration; the configuration of four parallel screws, placed with square-like form; configuration of three parallel screws, situated in one plane vertically. The main goal in all of these methods is achievement of compression between the fragments. Besides there is a striving of placing the screws with divergence in the femoral head. It is recommended the screws to be placed as far as possible in the periphery, close to the cortex, in order to be achieved maximum stability of fixation. Fixation with screws is also popular, connected with a small side plate.

The presented new method of *Biplane Double-Supported Screw Fixation* of the femoral neck provides new opportunities in biomechanical and clinical regard, which surpasses all known up to now methods of screw fixation for this fracture.

Alternative implant systems. Massive implants with a fixed angle.

DHS (AMBI)-plate. The fixation with DHS (AMBI)-plate is considered as an alternative method for screw fixation in fractures of the femoral neck. An advantage of the DHS-plate is the fixed angle, which ensures support of the femoral head in regard to the varus stress. Disadvantages of the femoral neck with DHS (AMBI-plate), especially in the presence of osteoporosis are as follow: (1.) The DHS-screw fixes the fracture only in one point and usually requires placing of one additional, antirotational screw, which severely increases the volume of metal, implanted in the femoral neck; (2.) Upon loading, the 135-degree DHS implant not always ensures effective sliding-phenomenon, and with severe osteoporosis the body weight loading

sometimes leads to cutting of the DHS-screw through the soft cancellous bone of the femoral head with migration of the implant in proximal direction, accompanied by displacement in varus of the fracture; (3.) Increase of the percentage of aseptic necrosis with fixation with DHS, compared to the screw fixation. (4.) In the presence of osteoporosis, the compression upon the fracture, created by the DHS-screw is very weak, compared to the three cancellous screws, which fix in the head subchondrally in three different points.

Proximal femoral locking plates. These implants represent a modification of the traditional methods for fixation with cancellous screws, placed almost parallel in the cancellous bone of the femoral neck. Here the screws are fixed in the plate at the level of the lateral cortex, which solves the problem with the fragile lateral cortex of the greater trochanter and creates a stable construction. However it fixes the fracture statically, not allowing creation of compression, because of the locking of the screws and also lacks the sliding-phenomenon, which is helpful for the process of healing.

Intramedullary nails. In the presence of femoral neck fracture, combined with other fracture, located in a lower segment of femur, at present we use different types of intramedullary systems of the type of the reconstructive nail and PFN.

Other alternative types of implants, most of which have only historical significance, are the 130° blade-plates. Their inconvenience is that they cannot create compression as the screw systems and having at the same time imperfections with their outdated surgical technique. However, having a fixed angle the blade-plate ensure excellent fixation of the fracture regarding the varus stress and torsion and combined with one additional screw is probably the most effective method for fixation in fracture with vertical fracture line – type Pauwels III.

8. Conclusion

The provision of two steady supporting points for the implants and the obtuse angle at which they are positioned, allows transferring of the body weight successfully from the head fragment onto the diaphysis, owing to the strength of the screws, with the patient's bone quality being of least significance. The position of the screws allows them to slide under stress at minimum risk of displacement. The achieved results with the BDSF-method in terms of fracture consolidation are far more successful than the results with conventional fixation methods. The BDSF-method ensures reliable fixation, early rehabilitation and excellent long-term outcomes, even in non-cooperative patients. BDSF is mainly addressed to patients, who have contraindications for arthroplasty, as well as for conventional screw fixation.

Author details

Orlin Filipov

Department of Orthopaedics, Vitosha Hospital, Sofia, Bulgaria

9. References

- [1] S.E. Asnis, L. Wanek-Sgaglione (1994) Intracapsular fractures of the femoral neck. Results of cannulated screw fixation. *J Bone Joint Surg.* 76, Vol.12, pp. 1793-1803
- [2] R. Blomfeldt, H. Törnkvist, S. Ponzer, A. Söderqvist, J. Tidermark (2005) Internal fixation versus hemiarthroplasty for displaced fractures of the femoral neck in elderly patients with severe cognitive impairment. *J Bone Joint Surg. Br* 87-B, Vol.4, pp. 523-529
- [3] J.E. Gjertsen, T. Vinje, L.B. Engesaeter, S.A. Lie, L.I. Havelin, O. Furnes, J.M. Fevang (2010) Internal screw fixation compared with bipolar hemiarthroplasty for treatment of displaced femoral neck fractures in elderly patients. *J Bone Joint Surg. Am* 92, pp. 619-628
- [4] G.L. Lu-Yao, R.B. Keller, B. Littenberg, J.E. Wennberg (1994) Outcomes after displaced fractures of the femoral neck. A meta-analysis of one hundred and six published reports. *J Bone Joint Surg. Am* 76, Vol.1, pp.15-25
- [5] J. Tidermark, S. Ponzer, O. Svensson, A. Söderqvist, H. Törnkvist (2003) Internal fixation compared with total hip replacement for displaced femoral neck fractures in the elderly. *J Bone Joint Surg. Br* 85-B, Vol.3, pp. 380-388
- [6] S. Lindequist (1993) Cortical screw support in femoral neck fractures. A radiographic analysis of 87 fractures with a new mensuration technique. *Acta Orthop.* 64, Vol.3, pp. 289-293
- [7] R.S. Garden (1961) Low-angle fixation in fractures of the femoral neck. *J Bone Joint Surg. Br* 43-B, Vol.4, pp. 647-663
- [8] L. Hernefalk, K. Messner (1996) Rigid osteosynthesis decreases the late complication rate after femoral neck fracture. *Archives of Orthopaedic and Trauma Surgery*, 115, pp. 71-74
- [9] V. Selvan, M. Oakley, A. Rangan, M. A-Lami (2004) Optimum configuration of cannulated hip screws for the fixation of intracapsular hip fractures: a biomechanical study. *Injury* 35, Vol.2, pp. 136-141
- [10] E. Walker, D. Mukherjee, A. Ogden, K. Sadasivan, J. Albright (2007) A biomechanical study of simulated femoral neck fracture fixation by cannulated screws: effects of placement angle and number of screws. *Am J Orthop.* 36, Vol.12, pp. 680-684
- [11] J. Dickson (1953) The "unsolved" fracture: a protest against defeatism. *J Bone Joint Surg. Am* 35, pp. 805-822
- [12] O. Filipov (2011) Biplane double-supported screw fixation (F-technique): a method of screw fixation at osteoporotic fractures of the femoral neck. *Eur J Orthop Surg Traumatol* 21, pp. 539-543
- [13] W.H. Harris (1969) Traumatic arthritis of the hip after dislocation and acetabular fractures: treatment by mold arthroplasty. An end-result study using a new method of result evaluation. *J Bone Joint Surg.* 51A, pp. 735-755
- [14] F. Liporace, R. Gaines, C. Collinge, G. Haidukewych (2008) Results of internal fixation of Pauwels type-3 vertical femoral neck fractures. *J Bone Joint Surg. Am* 90, pp. 1654-9

- [15] Tidermark J, Ponzer S, Svensson O, Söderqvist A, Törnkvist H (2003) Internal fixation compared with total hip replacement for displaced femoral neck fractures in the elderly. *J Bone Joint Surg. Br* 85-B(3): 380-388

IntechOpen

IntechOpen