

# We are IntechOpen, the world's leading publisher of Open Access books Built by scientists, for scientists

6,900

Open access books available

186,000

International authors and editors

200M

Downloads

Our authors are among the

154

Countries delivered to

TOP 1%

most cited scientists

12.2%

Contributors from top 500 universities



WEB OF SCIENCE™

Selection of our books indexed in the Book Citation Index  
in Web of Science™ Core Collection (BKCI)

Interested in publishing with us?  
Contact [book.department@intechopen.com](mailto:book.department@intechopen.com)

Numbers displayed above are based on latest data collected.  
For more information visit [www.intechopen.com](http://www.intechopen.com)



---

# **Biologic Therapy in Patients with Juvenile Idiopathic Arthritis – A Unique Single Centre Experience at the Scientific-Research Pediatric Centre in the Russian Federation**

---

A.A. Baranov, E.I. Alexeeva, L.S. Namazova-Baranova,  
T.M. Bzarova, S.I. Valiyeva, R.V. Denisova, K.B. Isayeva,  
A.M. Chomakhidze, E.G. Chistyakova, T.V. Sleptsova,  
E.V. Mitenko, E.I. Zelikovich, G.V. Kurilenko, E.L. Semikina,  
A.V. Anikin, A.M. Stepanchenko, N.I. Taybulatov, A.V. Starikova,  
I.V. Dvoryakovskiy and M.V. Ryazanov

Additional information is available at the end of the chapter

<http://dx.doi.org/10.5772/48761>

---

## **1. Introduction**

In 10-20% of children with JIA, a wide range of extra-articular manifestations such as spiking febrile fever, carditis, pneumonitis and serositis were noted [1]. Despite the advances in modern medicine, treatment of the systemic JIA variant with glucocorticoids and immunosuppressants has not always proved effective [1,2,3]. In 50% of patients, progressively destructive changes in the joints, with recurring extra-articular manifestations, have been steadily increasing the disability level. Most children with systemic JIA take oral, intravenous or intra-articular corticosteroids. However, glucocorticoids do not control the disease, prevent the progression of cartilage bone destruction or reduce disability in patients, and their prolonged use leads to severe irreversible effects, particularly, short stature, delayed puberty, adrenal insufficiency, osteoporosis and corticosteroid dependence [1,2, 3].

Interleukin 6 (IL-6), one of the central cytokines, has been discovered to play a leading role in development of systemic JIA. When excess IL-6 is produced, extra-articular manifestations such as fever and thrombocytosis are noted [4,5]. IL-6 stimulates the production of inflammatory proteins by hepatocytes (CRP, amyloid A, haptoglobin,

fibrinogen), and competitively inhibits synthesis of albumin and transferrin [6]. Anemia is one of extra-articular manifestations of systemic JIA. It develops during IL-6 stimulated secretion of hepcidin by the hepatocytes [7-10]. In normal concentrations, IL-6 enhances the synthesis of the adrenocorticotrophic hormone and cortisol, as well as the production of the growth hormone and prolactin [10,11]. However, at higher concentrations, IL-6 blocks the production of these hormones, which leads to fatigue, sleepiness, depression, cognitive disorders and retarded growth in children with systemic JIA [10,11,12], as the activity of IL-6 is also connected with the development of amyloidosis associated JIA. Thus, inhibition of IL-6 is very important in treatment of systemic JIA. Tocilizumab was synthesized for this purpose. Tocilizumab is a humanized monoclonal antibody to IL-6 receptor [13]. Based on the positive results of clinical studies on the efficacy and safety of Tocilizumab therapy, the drug has been registered for treatment of systemic JIA [16-23].

**The purpose of this study** is to evaluate the efficacy and safety of Tocilizumab treatment in children with the severe refractory systemic JIA.

## 2. Patients and methods

In a retrospective observational study, patients with the systemic JIA, treated with Tocilizumab between June 2009 and October 2011 in the Rheumatology Department, Science Center for Children's Health of RAMS were followed. The use of Tocilizumab in all the cases was approved by the local ethics committee. Prior to treatment, written consent was taken from the parents of the children, children aged 14 and older gave written informed consent themselves.

The results of treatment of 60 children (30 girls and 30 boys) aged 6.5 (4.5; 9) years (Me (25, 75)) were given in this analysis. The mean disease duration before beginning Tocilizumab therapy was 4.5 (2.2; 6.5) years. Diagnosis of systemic JIA was made based on diagnostic ILAR criteria (International League of Associations for Rheumatology). All patients underwent standard clinical and laboratory examination. Control of hemoglobin level, the number of erythrocytes, platelets, leukocytes, ESR, serum concentration of urea, creatinine, uric acid, bilirubin, transaminases, and clinical urinalysis was performed once every two weeks. Blood pressure (BP) was checked on a daily basis.

Number of systemic manifestations, swollen, painful joints, joints with limitation of function, serum CRP level were determined on a monthly basis. Therapy efficacy was evaluated according to the ACR pedi criteria ACR30, ACR50, ACR70. The criteria included a parent's assessment of pain, parent's global evaluation, physician's global assessment of disease status using VAS, the functional ability by CHAQ, number of joints with active arthritis, number of joints with limitation of function and ESR.

The main target of therapy was status of inactive disease and remission. Inactive phase of disease was established in the absence of active synovitis, systemic manifestations, normal ESR and serum CRP level, as well as absence of disease activity on the physician's global assessment (on VAS). At the time of therapy initiation most children

had active polyarthritis (Table 1). All patients revealed extra-articular manifestations of disease: spiking fever in 90% (54), carditis in 3% (2), lymphadenopathy in 86% (36), maculopapular rash in 35% (21), spleno- and hepatomegaly in 45% (27) of the patients. The number of systemic manifestations per patient was 2.5 (Table 1, Fig. 1). High clinical disease activity was accompanied by a general inflammatory reaction: hypochromic anemia in 90% (54), leukocytosis in 75% (45) and thrombocytosis in 80% (48) of patients. The median ESR was more than twice the normal value and serum CRP level increased up to 10 times (Table 1).

Index	Value (Me (25; 75))
number of active joints	8 (4;14)
number of joints with limitation of function	9(3;14)
number of systemic manifestations per patient	2.5 (1.5; 3.5)
ESR, mm/h	28 (18; 55)
platelets, x10 <sup>9</sup> /	490 (480; 640)
hemoglobin, g/L	92 (86; 98)
CRP, mg%	14 (7; 26)

**Table 1.** Clinical characteristic of patients with the systemic JIA included in the study.

Thus, at the beginning of therapy all patients with systemic JIA had active arthritis, severe systemic manifestations and high laboratory parameters of the disease activity with increasing disability.

*Previous therapy:* Prior to the Tocilizumab treatment all patients were treated with antirheumatic drugs, in various modes. In the initial stages of the disease (based on the place of residence in the territorial health care facility) 60% (36) children were prescribed oral prednisolone at a dose of 10 to 30 mg / day. All children received methylprednisolone pulse therapy at a dose of 10-30 mg / kg initially, 47 (78%) - local glucocorticoid therapy from 1 to 10 times a year, 10 (17%) were treated with TNF-blockers and 22 (37%) with anti-B cell therapy with rituximab. All children were treated with antiinflammatory drugs (NSAIDs).

*Background therapy:* Tocilizumab was administered in patients receiving immunosuppressive drugs (Table 2). Doses of antirheumatic drugs were stable within 3 months before Tocilizumab therapy.

Drug	Dose (Me (25; 75))	Number of children
methotrexate, mg/m <sup>2</sup> /week	18 (15; 25)	60
cyclosporine, mg/kg/day	4 (4; 4)	46
prednisolone, mg/day	10.5 (7; 12)	36
NSAIDs	-	60

**Table 2.** Background therapy in patients with the systemic JIA included in the study.

*Tocilizumab treatment:* Tocilizumab was administered intravenously, once every two or four weeks at a dose of 8-10 mg / kg per infusion. All the children within one or two months of receiving the drug every two weeks had the interval increased to four weeks between doses. Infusions were performed for one hour, at the rate of 10 ml / h for the first 15 minutes, and then increased to 130 ml / hour.

Analysis of the efficacy was done after one month. The results indicated improvement in 52 children by 1 month, in 50 children by 3 months, in 40 children by 6 months, in 32 children by 9 months and in 24 children by the end of a year.

Statistical data processing was performed using the program STATISTICA 6.0 (StatSoft Inc., USA). Quantitative characters are shown as median (25, 75 percentiles). Changes in the quantitative traits during the treatment were evaluated using the Wilcoxon test conjugate pairs. Statistically significant differences were considered at  $p < 0.05$ .

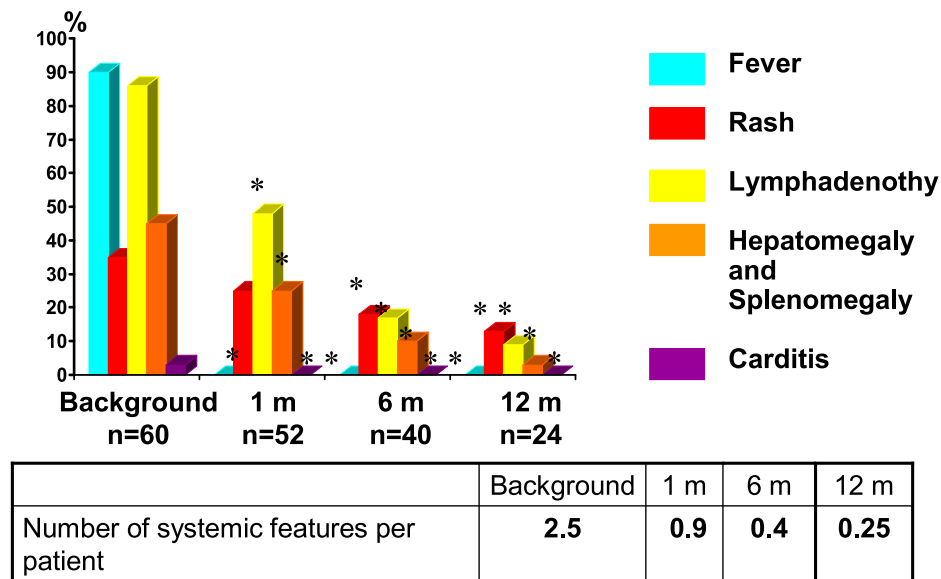
2.1. Results

Tocilizumab treatment ensured reliability and marked improvement of the systemic manifestations, as well as clinical and laboratory parameters of disease activity.

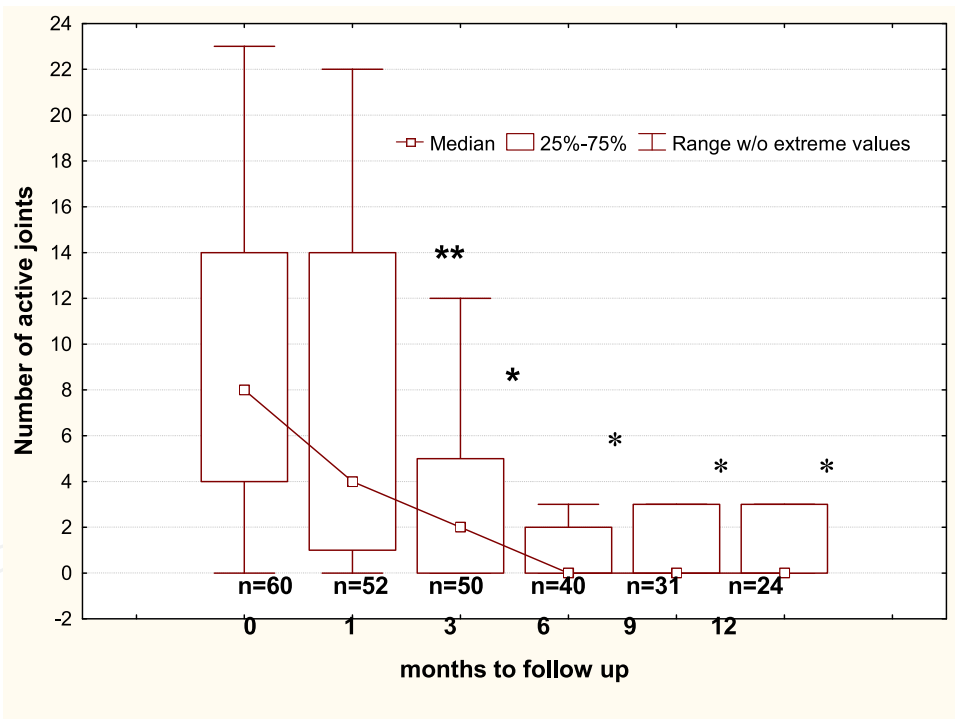
Within one month after initiation of therapy, patients showed a significant decrease in number of systemic manifestations (Fig. 1). Carditis one of the serious extra-articular manifestations of systemic JIA, disappeared in all the patients. Frequency of skin rash also significantly reduced, from 21 (35%) to 13 (25%) of the cases. After the first infusion of Tocilizumab, no spikers of fever were observed in all patients (Fig. 1).

After observation of 24 patients over a year, lymphadenopathy persisted in 3 patients, rash in 2 cases and hepato / splenomegaly in 1 patient. At the end of one year of observation, the number of systemic manifestations per patient was 0.25 (Figs. 1).

In the fourth week of treatment the number of active joints significantly decreased from 8 (4, 14) to 4 (1, 14),  $p < 0.01$ . By the 12th month the rate was 0 ((0, 3),  $p < 0.001$ ) (Fig. 2).



**Figure 1.** Dynamics of Systemic Features in children with systemic JIA treated with Tocilizumab. Hereinafter: \*  $p < 0.001$  – statistically significant difference compared to baseline

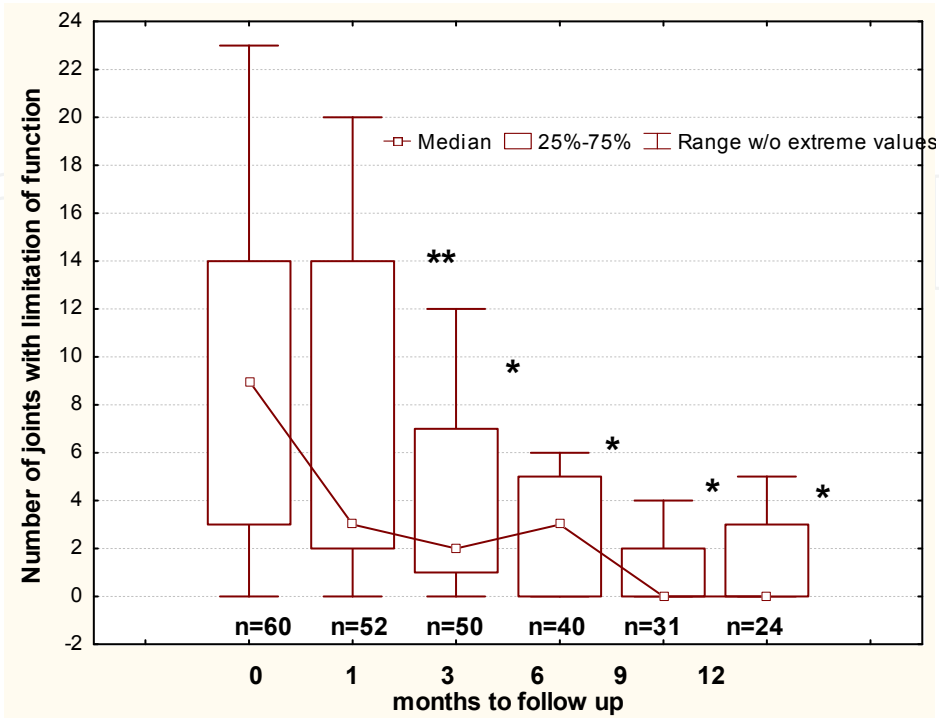


**Figure 2.** Dynamics in number of active joints in children with systemic JIA treated with Tocilizumab. Hereinafter: \*  $p < 0.001$ , \*\*  $p < 0.01$  – statistically significant difference compared to baseline

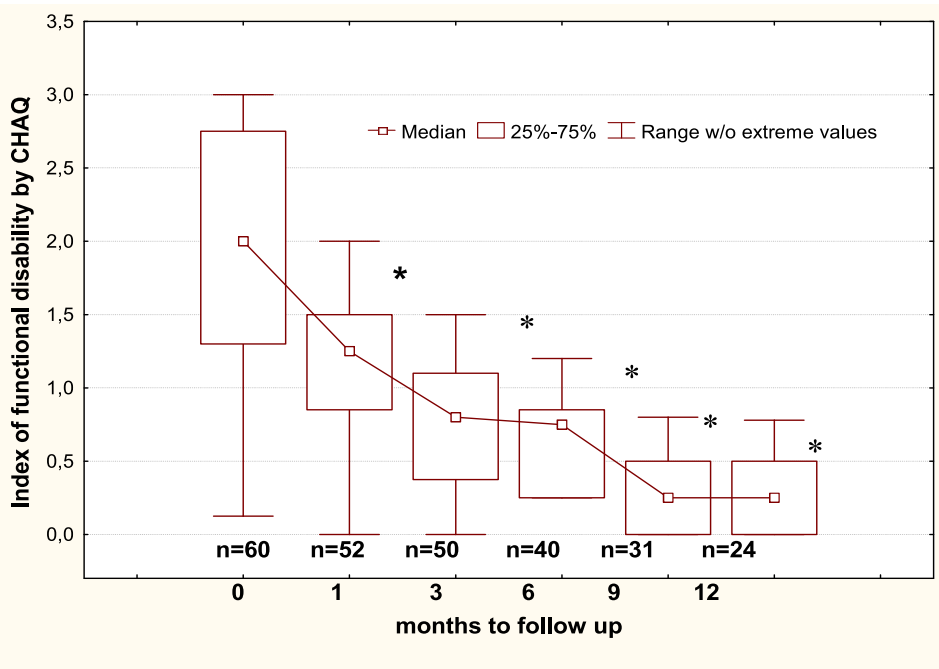
The same trend was observed in the joints with limitation of function. That parameter too significantly dropped after four weeks of treatment (Fig. 3). By the end of one year's observation the median number of joints with limitation of function decreased 9 times ( $p < 0.001$ ).

Along with the decrease in the number of joints with active arthritis, as well as joints with limitation of function, a significant improvement in functional ability of the affected joints was

noted (Fig. 4). After four weeks of Tocilizumab treatment the index of functional disability by CHAQ questionnaire decreased significantly from 2.0 (1.35, 2.7) to 1,3 (0.9; 1.3),  $p < 0.001$ ).

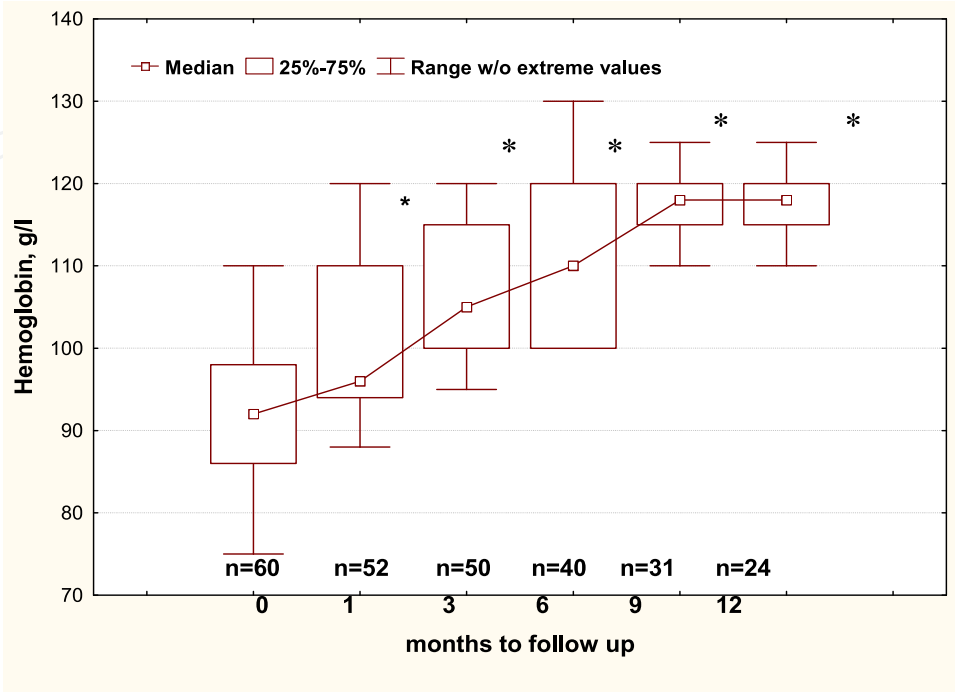


**Figure 3.** Dynamics in number of joints with limitation of function in children with systemic JIA treated with Tocilizumab.  
Hereinafter: \*  $p < 0.001$ , \*\*  $p < 0.01$  – statistically significant difference compared to baseline

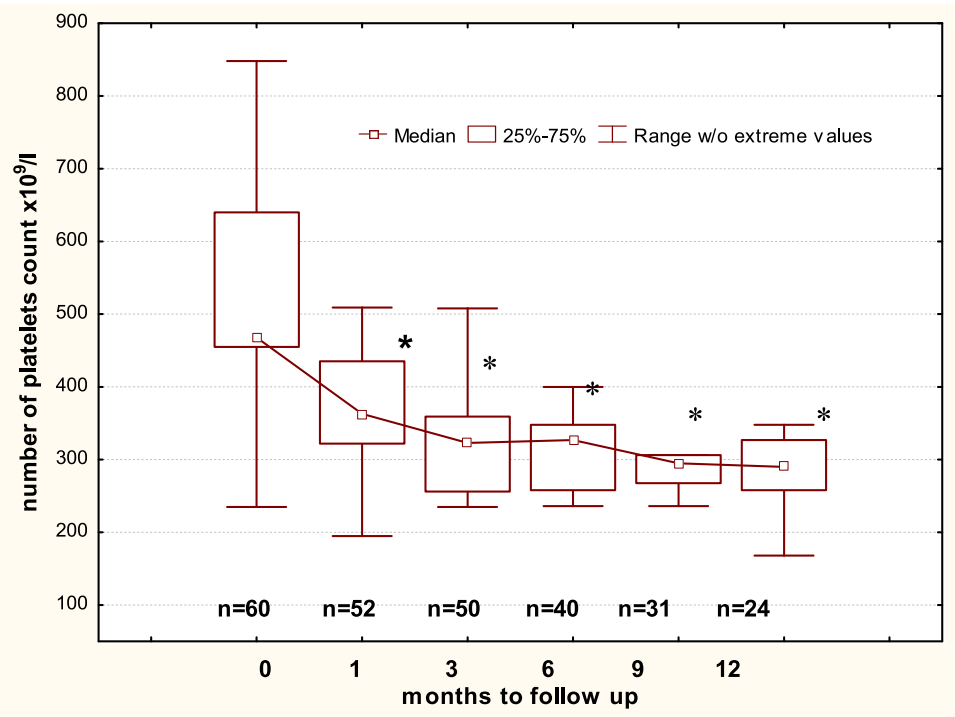


**Figure 4.** Dynamics in index of functional disability in children with systemic JIA treated with Tocilizumab.  
Hereinafter: \*  $p < 0.001$  – statistically significant difference compared to baseline

Tocilizumab therapy also influenced the laboratory parameters of the disease activity, showing significant increase in hemoglobin level (Fig. 5), decrease platelet counts, ESR, serum CRP level and normalization of these parameters by the first month of treatment (Fig. 6, 7, 8).

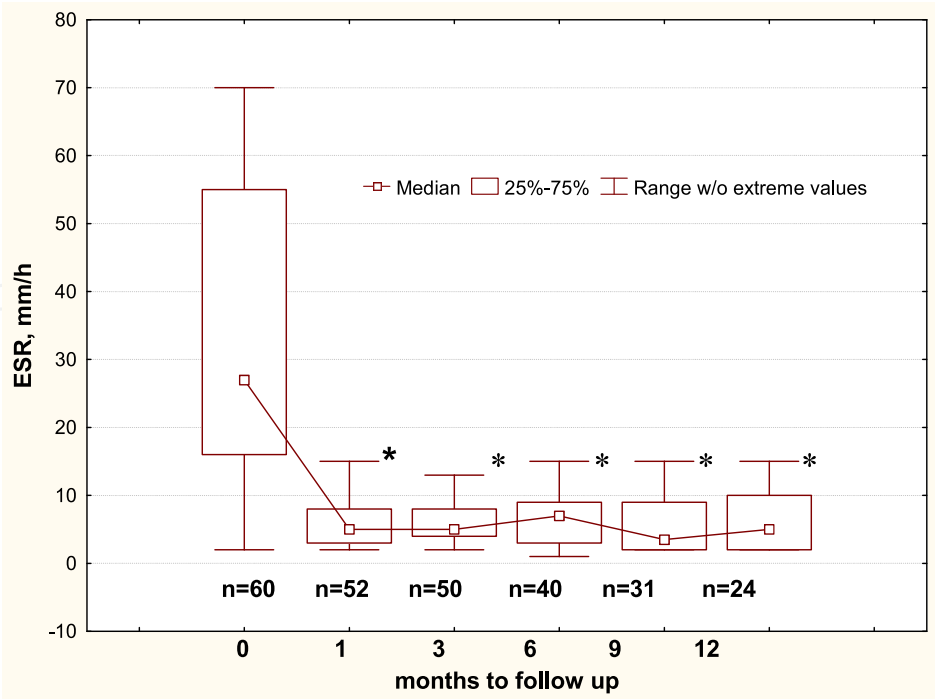


**Figure 5.** Dynamics in hemoglobin level in children with systemic JIA treated with Tocilizumab. Hereinafter: \*  $p < 0.001$  – statistically significant difference compared to baseline

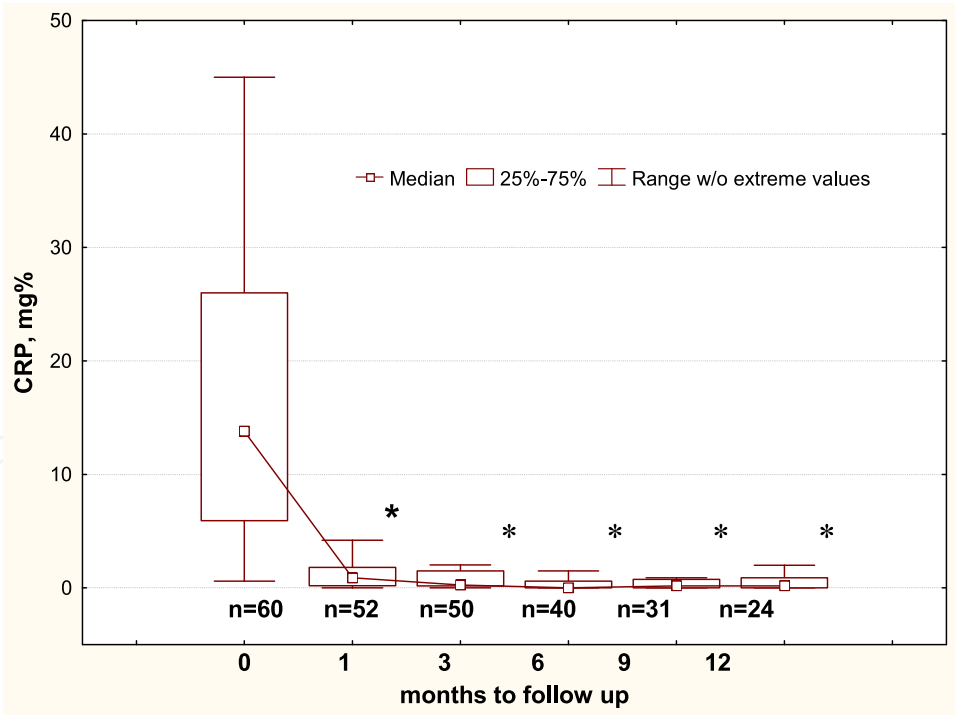


**Figure 6.** Dynamics in the platelets count in children with systemic JIA treated with Tocilizumab. Hereinafter: \*  $p < 0.001$  – statistically significant difference compared to baseline





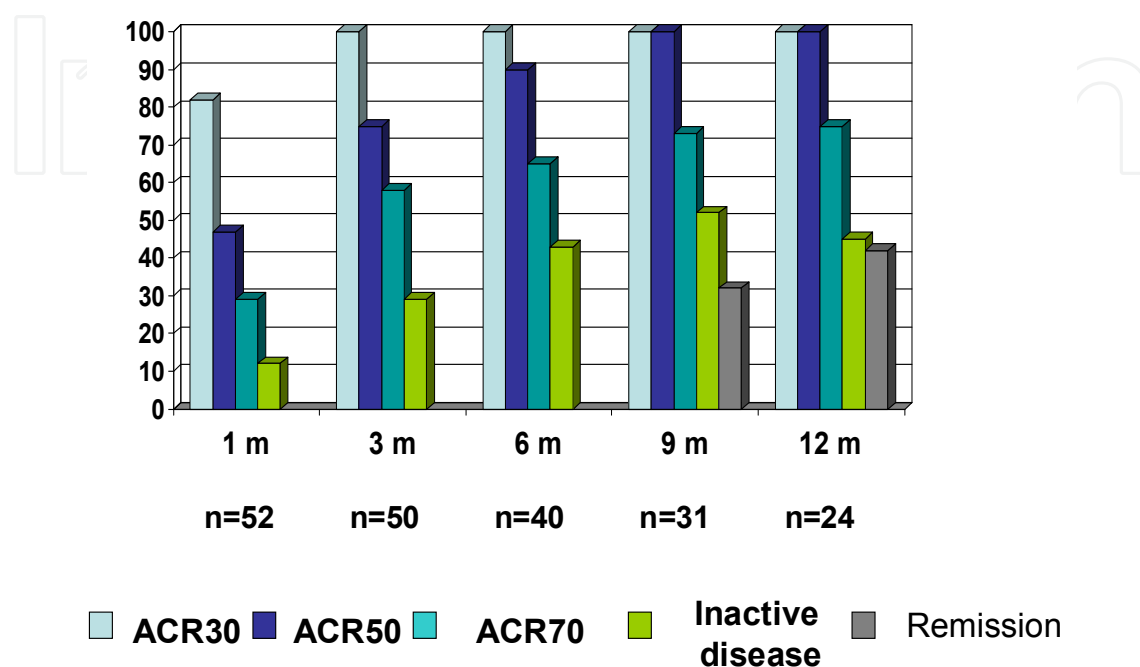
**Figure 7.** Dynamics in the ESR in children with systemic JIA treated with Tocilizumab. Hereinafter: \*  $p<0.001$  – statistically significant difference compared to baseline



**Figure 8.** Dynamics in the serum CRP level in children with systemic JIA treated with Tocilizumab. Hereinafter: \*  $p<0.001$  – statistically significant difference compared to baseline

Assessment of efficacy of Tocilizumab therapy according ACRpedi criteria by one month of Tocilizumab therapy showed 30% improvement in 82% of the patients, 50% improvement in 47% of cases and 70% improvement in 29% of patients. After six months of treatment, all the

children maintained improvement criteria ACR30 while 65% recorded a rate of ACR70. After a year of therapy, 50% and 70% improvement, respectively, was observed in 100% and 75% of patients (Fig. 9). In general, the efficacy of Tocilizumab after more than six months of treatment was characterized by the achievement of inactive disease status in 43% (17 of 40) patients after one year in 45% (11 of 24) patients and remission in 43 % (10 of 24).



**Figure 9.** Response according to ACR pedi criteria in children with systemic JIA treated with Tocilizumab.

Safety assessment of Tocilizumab treatment was performed by registered adverse events (AE), laboratory parameters, based on the results of the physical examination (BP, HR), and EKG. AE were evaluated in all the patients enrolled in the study, who received at least one infusion. Tocilizumab treatment was well tolerated and most AE were mild or moderate, reversible, not limiting the course of the treatment. Infusion reactions were noted. Registered AE were differentiated into two groups, namely infectious disorders and laboratory parameters (Table 3).

Adverse events	Patients n (%)
<i>Laboratory parameters:</i>	
Neutropenia	25 (41%)
Thrombocytopenia	1 (2%)
Increase in alkaline phosphatase	1 (2%)
<i>Infectious disorders:</i>	
Cellulitis	3 (5%)
Herpes infection	4 (8%)
Acute focal pneumonia	2 (3%)

**Table 3.** Adverse events in patients on Tocilizumab therapy

Among the infectious AE reported, cellulitis was seen in 3 patients, exacerbation of herpes infection in 4 cases and acute focal pneumonia in 2 patients. Antibiotic therapy provided complete relief of cellulitis and pneumonia without complications. Aggravation of herpetic infection (4 cases) was not considered serious AE. Among the AE with the laboratory parameters, neutropenia was most frequently observed in the first few days after administration of the Tocilizumab, in 41% (25) of the patients. In 15 patients, the absolute neutrophil count decreased  $<1.000$  in  $1\ \mu\text{L}$ , whereas in 2 patients it was 500 per  $1\mu\text{L}$ . On identifying neutropenia, daily monitoring was conducted until neutrophil recovery occurred within weeks after the infusion. By reducing the number of neutrophils  $<1.0 \times 10^9$  /L patients received the colony-stimulating factor (G-CSF) filgrastim, at a dose of 5 mg / kg, with a positive effect. All cases of neutropenia were associated with Tocilizumab infusion. None of them were accompanied by infection and it was not a cause of treatment discontinuation.

Mild thrombocytopenia was observed in one patient after 11 months of therapy. Two weeks after the regular drug administration, the platelet count decreased to  $156 \times 10^9$  /L. Concomitant therapy included glucocorticoids, cyclosporine, methotrexate, and NSAIDs. Thrombocytopenia was not considered serious AE, and unlikely to be the result of Tocilizumab therapy. Platelet count returned to normal within a week, without reducing the dose or interrupting the treatment. One patient reported a one-time increase in alkaline phosphatase activity to 6200 IU / L after the first injection of Tocilizumab while concomitant therapy included methotrexate and methylprednisolone. This rate returned to normal after eight days without changing the Tocilizumab treatment regimen. The AE were considered to be of no significance, and unlikely to be the result of Tocilizumab therapy.

While observing clinically significant changes in the vital functions namely, BP and HR, the EKG parameters were also observed. Treatment was discontinued in 9 patients (table 4).

Index	Patients n
Remission of disease	1
Inefficacy	1
Relapse of disease	6
Parents' refusal	1

**Table 4.** Causes of discontinuation of Tocilizumab treatment.

Normally, the safety profile of Tocilizumab in children is quite similar to the safety profile described earlier in adults with rheumatoid arthritis. It was within the expected range for a population of patients receiving immunosuppressive drugs. AE were manifested as mild to moderately severe infections, as well as changes in the laboratory parameters. Deaths did not occur during the period of Tocilizumab treatment. No case of discontinuation of therapy was registered due to AE development.

### 3. Clinical case

**Patient's data:** female. Age: 9 years old (born in 2002)

**Diagnosis:** Systemic JIA

#### 3.1. Medical history

The girl has been sick since 2007 when she was 5 years old. Febrile fever, lymphadenopathy, inflammatory changes in the knees and ankles, high laboratory parameters of activity (ESR – 52 mm/h) were observed during the onset. The following diagnosis was set at the local in-patient facility: systemic-onset juvenile arthritis. Treatment with antibiotics, NSAIDs, oral methylprednisolone at a dose of 16 mg/day (1 mg/kg of body weight) was conducted. Fever subsided and inflammatory changes in joints resolved with treatment. Gradual reduction of methylprednisolone dose was initiated. In 6 months the dose was 4 mg per day. However, disease exacerbated again after the insolation, which manifested in febrile fever, high laboratory parameters of disease activity (ESR – 45 mm/h), swelling and pain in the elbows, metacarpophalangeal, interphalangeal joints of hands, knees and ankles. Methylprednisolone pulse therapy at a dose of 500 mg per administration was conducted 3 times at the local in-patient facility; methotrexate at a dose of 10 mg/m<sup>2</sup> of standard body surface area per week and NSAIDs were prescribed. Condition improved, the dose of methylprednisolone was decreased to 2 mg per day. In 6 months condition worsened again: febrile fever, exudative changes in the wrists, knees and ankles appeared. Due to persisting disease activity in 1.5 years from the disease onset, the girl was referred to the rheumatology department of Scientific Center for Children Health, RAMS. On admission to the department the child's condition was assessed as severe. The girl experienced daily febrile fevers; the joint syndrome was polyarticular, affecting wrists, knees, ankles; motions were limited and painful. The child was bothered by morning stiffness for up to 60 minutes. On admission to the department pale skin, "shadows" under the eyes, generalized lymphadenopathy also came under notice. Leukocytosis, thrombocytosis, ESR elevation, hypochromic anemia, increased serum CRP concentration (Table 5) were observed in hematology during examination. Periarticular osteoporosis and single erosions of articular surfaces were revealed according to X-ray examination of the knees. Diagnosis systemic JIA was undoubtful.

Methotrexate dose was increased up to 25 mg/m<sup>2</sup> of standard body surface area per week intramuscularly. 2 injections were conducted with positive effect: fever subsided, intensity of pain syndrome and exudative changes in joints reduced. The child was discharged with recommendations to continue methotrexate treatment at the place of residence. For 6 months the girl's condition remained stable.

In 6 months of methotrexate treatment at a dose of 25 mg/m<sup>2</sup> of standard body surface area per week, the girl started experiencing febrile fever again, duration of morning stiffness increased up to 120 minutes, exudative changes in the wrists, elbows and ankles increased (Figure 10a-d). The child fell behind in physical development, height and

weight scores were below the 10<sup>th</sup> percentile (Table 5). According to hematology and immunologic blood test, activity of rheumatoid process persisted (Table 5). Based on the signs of aggressive disease course (polyarthritis, high immunologic activity, ineffectiveness of methotrexate therapy at a high dose, hormonal dependency, falling behind in physical development), the patient was prescribed treatment with genetically engineered biologic agent – Tocilizumab.



Figure 10.

3.2. Treatment with Tocilizumab

The drug was administered intravenously at a dose of 8 mg/kg of body weight once in 4 weeks. Drug prescription was approved by the Academic Board, Local Ethics Committee and Formulary Committees of Scientific Center for Children Health, RAMS. Child’s parents have signed an informed consent for drug use.



### 3.3. Results of treatment


Analysis of development rate of Tocilizumab therapeutic effect has revealed that right after the first administration the fever subsided, the girl became more active, after 2 week of treatment the morning stiffness resolved (Table 5); exudative changes in the affected joints had completely resolved by the 8<sup>th</sup> week, the range of motions restored (Figure 11 a-e); laboratory parameters of disease activity normalized in 4 weeks (Table 5). Tocilizumab treatment also positively affected patient's quality of life, improved physical activity and emotional condition (Figure 11 a-e). Inactive disease status was observed in the patient in 2 months of treatment, and in 8 months the patient entered systemic JIA remission, which has been maintained for 2 years of Tocilizumab treatment.



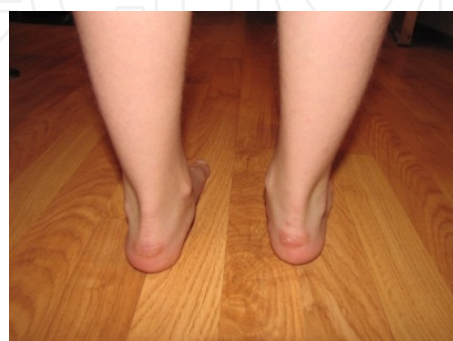a. Functional capabilities of the wrist joints with Tocilizumab therapy at week 104.



b. Functional capabilities of the wrist joints with Tocilizumab therapy at week 104



c and d. Functional capabilities of the elbow joints **with** Tocilizumab therapy at



e. The absence of swelling in the ankle joints **with** Tocilizumab therapy at week

**Figure 11.**

The girl continues receiving intravenous Tocilizumab infusions at a dose of 8 mg/kg of body weight once in 4 weeks in combination with methotrexate (due to height and weight increase, a dose is 18 mg/m<sup>2</sup> of body surface area per week) and methylprednisolone at a dose of 2 mg/day. Child's physical development parameters significantly improved with Tocilizumab therapy: in 2 years the girl has grown by 1 cm and weight gain was 6 kg, height and weight were in the 10<sup>th</sup> – 25<sup>th</sup> percentile range.

### 3.4. Adverse events

No serious adverse events were observed during the follow-up.

Parameters	Prior to the increase of methotrexate dose	Duration of Tocilizumab therapy					
		Background	Day 1	4 weeks	26 weeks	52 weeks	104 weeks
Temperature, °C	38.5	39.0	36.7	36.6	36.6	36.6	36.6
Duration of morning stiffness, minutes	60	120	no	no	no	no	no
The number of active joints	6	6	6	2	0	0	0
CHAQ index of functional disability, score	1.7	1.9	1.7	0.5	0	0	0
ESR (mm/h)	25	70	45	2	7	2	4
Hemoglobin (g/L)	88	110	110	118	120	125	128
Erythrocytes (x10 <sup>12</sup> /L)	3.8	4.7	4.8	5.2	5.25	5.4	5.5
Platelets (x10 <sup>9</sup> /L)	840	654	622	328	335	270	290
Leukocytes (x10 <sup>9</sup> /L)	17	22.7	17.8	7.96	6.7	8.74	7.8
CRP (mg%), normal level up to 0.8	3.85	26	16	<0.8	<0.8	<0.8	<0.8
IgG (g/L), normal range (5.72-14.74)	12.1	17.8	9.0	7.35	6.66	8.67	7.5
Height, cm	112	114	114	115	116	119	125
Weight, kg	16.5	17.5	17.5	18.0	19	20	23.5
Percentage of improvement according to ACR <sub>pediatric</sub> criteria	-	-	-	50%	90% Inactive disease	Disease remission	Disease remission

**Table 5.** Clinical and laboratory parameters of systemic JIA activity with Tocilizumab treatment in patient, 9 years old girl, over time.

## **4. Efficacy and safety of monoclonal human antibodies to TNF $\alpha$ in children with juvenile idiopathic arthritis and uveitis**

### **4.1. Introduction**

Juvenile idiopathic arthritis is a severe disabling disease associated with development of destructive arthritis and uveitis – in some patients.

Treatment with methotrexate (15 mg/m<sup>2</sup> of standard body surface area) provided disease control in many patients with juvenile idiopathic arthritis [26]. However, standard anti-rheumatic treatment is unlikely to provide stable remission in some patients [27-30]. Due to insufficient efficacy of methotrexate, the progression of the disease continues. Treatment of uveitis is the most complicated, because its activity is usually independent on the activity of arthritis.

Biologic drugs produced by the methods of gene engineering provide a good perspective for patients with methotrexate inefficacy. Adalimumab is one of these drugs.

Adalimumab is the recombinant IgG1 human monoclonal antibodies consisting of 1330 amino acids. The drug is manufactured by recombinant DNA technology. It binds to p55 and p75 receptors of soluble and membrane – associated TNF $\alpha$ . Adalimumab can activate the complement system that results in lysis of cells with superficially located TNF $\alpha$ . The drug has no ability to bind to or inhibit the lymphotoxin (TNF $\beta$ ); it alters the levels of adhesion molecules that contribute to leukocytes migration (ELAM-1, VSAM-1, and ICAM-1). Adalimumab is administered subcutaneously once per 2 weeks; the elimination half-life of the drug is 2 weeks [31-34].

The results of controlled clinical trials and open studies demonstrated that subcutaneous administration every two weeks of the drug is safe and effective in adult patients with rheumatoid and psoriatic arthritis [34-48], as well as in children with juvenile idiopathic arthritis and uveitis [49-59].

The purpose of this study was to evaluate safety and efficacy of Adalimumab treatment in children with severe refractory juvenile idiopathic arthritis and uveitis.

### **4.2. Patients and methods**

Enrolled: 104 patients (74 girls and 30 boys) age 10 (3; 17) years (Median (25; 75)) with oligoarticular, polyarticular, enthesitic, systemic arthritis without active systemic manifestation no less within 1 year enthesitic types of juvenile idiopathic arthritis; in 48 patients arthritis was associated with uveitis (Table 6). Mean disease duration prior to Adalimumab administration – was 6 (2; 16) years. The diagnosis of JIA based on ILAR (International League of Associations for Rheumatology) criteria [60].

At baseline, all patients had active arthritis (Table 7). Mean number of joints with active arthritis - 5 (2; 8), mean number of joints with limitation of function – 5 (1; 7.5). High level of clinical activity of the disease was associated with general inflammation reaction. Median



ESR level was 3-fold higher compared to normal; C-reactive protein serum level was 9-fold higher compared to normal (Table 7).

Parameter	Number of patients (n=104)
Boys/girls	74/30
Age, years	10 (3; 17)
Age group 3-13 years	80(73%)
Age group 14-18 years	30(27%)
Duration of the disease, years	5.8 (2; 16)

**Table 6.** Demographic characteristics of patients with JIA and uveitis, included in the study

Parameter – CHAQ and number of patients – 2.0(1.3; 2.75)	Number of patients
Juvenile idiopathic arthritis	104
Oligoarticular	41 (39%)
Polyarticular (RF-)	40 (38.5%)
Polyarticular (RF+)	7 (6.7%)
Enthesitic	11 (11%)
Systemic, without active systemic manifestations	5 (4.8%)
Number of joints with active joints Median (25%;75%)	5(2;8)
Number of joints with limitation of function Me (25%;75%)	5(1;7.5)
Duration of the anti-rheumatic treatment, years	2,7 (1.1;2.9)
Number of children with uveitis	48(46%)
Bilateral uveitis	32(67%)
Unilateral uveitis	16(33%)
Number of affected eyes	80
ESR mm/hour	30 (23; 55)
C-reactive protein, mg/l	9.5 (5; 23)

**Table 7.** Clinical characteristics of patients with JIA included in the study.

Uveitis was reported in 48 (44%) of patients, bilateral – in 32 (67%); unilateral uveitis – in 16 (33%) patients (Table 8).

*Previous therapy.* Prior to Adalimumab treatment all patients received various regimens of anti-rheumatic treatment. Due to active arthritis and uveitis development at the onset of the disease, 66 (58%) of patients had a history of prednisolone treatment (10-20 mg/day); all

patients received pulse-therapy with methylprednisolone (10-20 mg/kg per administration); 86 (83%) – intra-articular (1-10 times per year), 46 (44%) – cyclosporine, 49 patients were treated with TNF $\alpha$  blockers: 47 (45%) with Infliximab, 2 (1.9%) with Etanercept; 5 (4.8%) children received antiB-cells therapy with Rituximab, 1 (1%) patient inhibitor of T-cells co-stimulation Abatacept. All patients were treated with non-steroid anti-inflammation drugs (NSAIDs); 48 (46%) patients with uveitis received local treatment with eye drops containing NSAIDs and glucocorticosteroids, 32(31%) - para-bulbar glucocorticoid injection (1-5 times per year)

Despite treatment, all patients experienced disease progression. At the time of enrollment they had active arthritis, elevated laboratory parameters and progressing disability. Continuous recurrent uveitis was diagnosed in 48 children.

Inclusion criteria: Ineffective treatment with methotrexate (15-25 mg/m<sup>2</sup> of standard body surface area, once per week, intramuscular injections; within 3 month and more) and with other immunosuppressive drugs (leflunomide, sulfasalazine, cyclosporine), progression of arthritis, vision acuity decrease, continuous recurrence of uveitis, high laboratory parameters (ESR, CRP level), and increasing functional disability.

Normal serum levels of urea, creatinine, bilirubin, ALT, AST; no significant acute or chronic infections. Patients with infections were treated with antibiotics. Prior to Adalimumab treatment all patients were examined for presence of tuberculosis – including tuberculin test (PPD test) and the chest CT. Treatment with TNF $\alpha$  antagonists has been recognized as a risk for active tuberculosis; some cases of latent tuberculosis could reactivate soon after treatment initiation. For this reason, worldwide health authorities recommend screening patients for latent tuberculosis and treating them before initiating anti-TNF $\alpha$  treatment [61]. Patients with positive or controversial PPD test (hyperemia, papule size  $\geq 5$  mm) were consulted by the phthisiatrician; and the test with tuberculin dilution was conducted (0.1, 0.1, 0.01 TU). If the tuberculosis infection was excluded, the patients received Adalimumab treatment.

The control of hemogram and serum levels of urea, creatinine, bilirubin, ALT, AST, as well as urinalysis were conducted each 2 weeks.

The following parameters were evaluated during the study: number of Active joints, number of joints with limited function, ESR and serum level of C-reactive protein; the activity of uveitis was evaluated according to criteria developed by M.J. Hogan [36]. Physician's Global Assessment of disease activity (using the 100 mm VAS scale), Parent's global evaluation of well being (using the VAS scale); evaluation of functional abilities using the CHAQ questionnaire. The effect of Adalimumab treatment was evaluated after 4, 12, 24, 36 and 52 weeks of treatment. The efficacy was evaluated according to American College of Rheumatology pediatric criteria (ACRpedi) [62].

The main target of therapy was status of inactive disease and remission [63].

Evaluation of Adalimumab treatment safety was based on the registration of adverse events and regular control of serum levels of urea, creatinine, bilirubin, ALT, AST and hemogram.

All cases of Adalimumab treatment were approved by Local Ethics Committee of the Scientific Center of children's of RAMS. Prior to treatment, children older than 14 years and children's parents were providing the written informed consent.

*Background therapy.* Adalimumab was administered subcutaneously once per 2 weeks; dose – 40 mg per administration; in combination with background immunosuppressive therapy (Table 8). The dose of immunosuppressive drugs remained stable for at least 3 months.

Drug	Dose Me (25;75)	Number of patients n=104
Methotrexate mg/m <sup>2</sup> /week	20 (15; 25)	64
Cyclosporine, mg/kg/day + Methotrexate mg/m <sup>2</sup> /week	4 (4; 4)	38
Prednisolone, mg/day	10 (5; 12)	54
NSAIDs	-	104
Para-bulbar glucocorticoid injections - 32	-	48
Local treatment of uveitis with drops	-	48

**Table 8.** Background therapy in patients with JIA and uveitis included in the study.

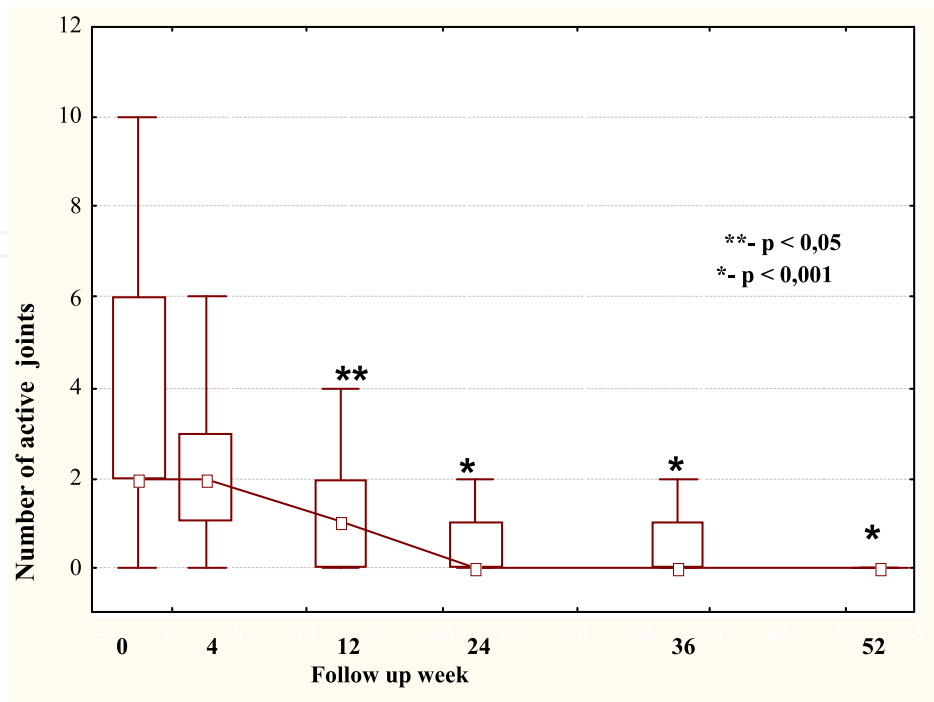
The analysis of treatment efficacy was conducted after 4, 12, 24, 36, 52 weeks of treatment – in 104 of patients, accordingly.

Statistical processing of data was conducted using the STATISTICA 6.0 (StatSoft Inc., USA) program. The quantification parameters were presented as medians (25; 75 percentiles); in some cases data were presented as means  $\pm$  SD. Wilcoxon's criterion was used for paired comparison. Statistically significant difference was considered to be  $p < 0.05$ .

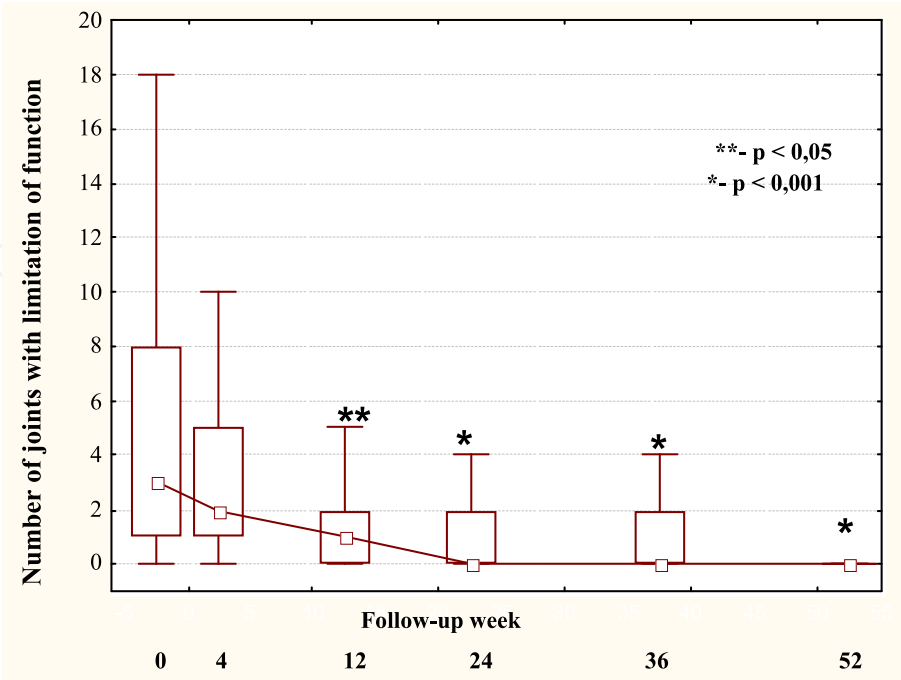
### 4.3. Results

By week 12 of treatment the statistically significant decrease in number of active joints was reported (5 (2; 8); 3 (0; 4) prior to treatment and after 12 weeks of treatment, respectively;  $p < 0.05$ ), by week 52 there were no joints active (Figure 12).

Similar changes were reported for joints with limitation of function – statistically significant decrease in their number was observed by week 12 (5 (1; 7.5); 3 (1; 5) prior to treatment and after 12 weeks of treatment, respectively;  $p < 0.05$ ), by week 52 the 9-fold decrease of the median parameter was reported ( $p < 0.05$ ) (Figure 13).



**Figure 12.** Dynamics in number of active joints in children with JIA treated with Adalimumab (n=104)  
Hereinafter:  
p<0.001, \*\* p<0.05 – statistically significant difference compared to baseline  
by week 52 there were no joints with active arthritis

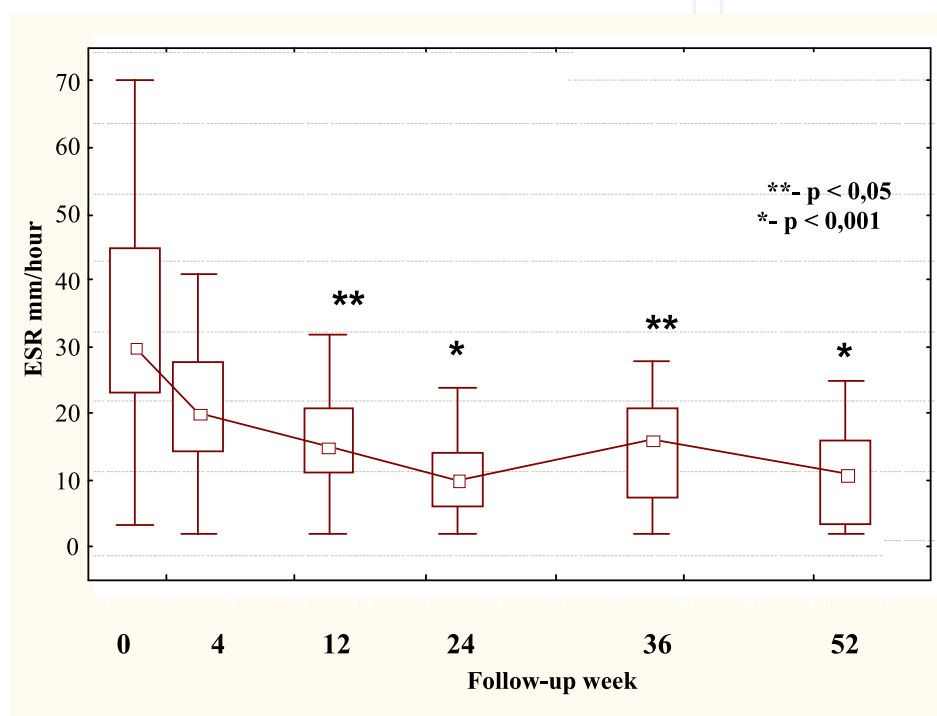


**Figure 13.** Dynamics in number of joints with limitation of function in children with JIA treated with Adalimumab (n=104)

The improvement of functional activity of joints after 4 weeks of Adalimumab treatment was associated with improvement of quality of life; that improvement was confirmed by the decrease in index of functional disability evaluated by CHAQ questionnaire - from 2.0 (1.3; 2.75) to 1.0 (0.6; 1.4),  $p < 0,001$ .

Treatment with Adalimumab affected the laboratory parameters of disease activity.

After 4 weeks of treatment the trend to decrease in ESR was reported. By week 12 the median significantly decreased; by week 52 the median was normal in the most of patients (Figure 14).



**Figure 14.** Dynamics in ESR in children with JIA treated with Adalimumab (n=104)

Significant decrease in the serum C-reactive protein level in all patients was observed after 8 weeks of treatment; the median parameter normalized after 12 weeks of treatment (Figure 15).

Assessment of Adalimumab efficacy according ACRpedi demonstrated that after 4 weeks of treatment the 30% improvement was achieved in 100% of patients, 50% improvement – in 80% (83), 70% improvement – in 55%(57) of patients. After 24 weeks 30% improvement was reported in 100% (104) of patients, 50% improvement – in 91% (95), 70% - in 74% (77) of patients; inactive disease was diagnosed in 55 % (58) of children. Within a year, JIA remission was diagnosed in 55% (58) of patients (Figure 16).

Prior to administration of Adalimumab, injection of conjunctiva, edema of iris, corneal precipitations, areas of inflammation in lens and optical nerve disk edema were found in all children with uveitis (Table 9).

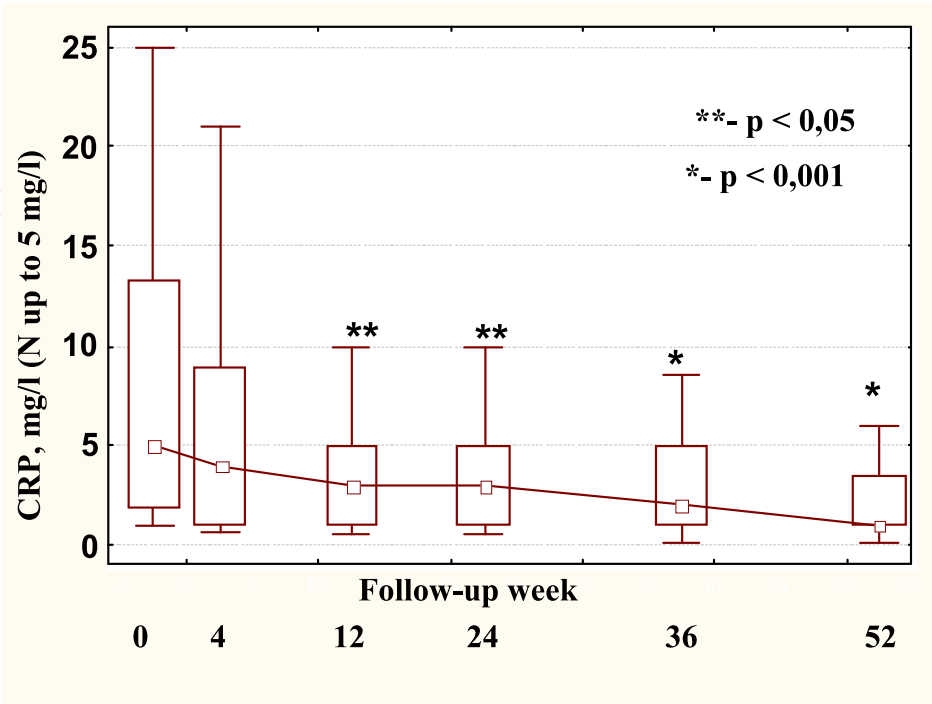


Figure 15. Dynamics in the serum CRP level in children with JIA treated with Adalimumab (n=104)

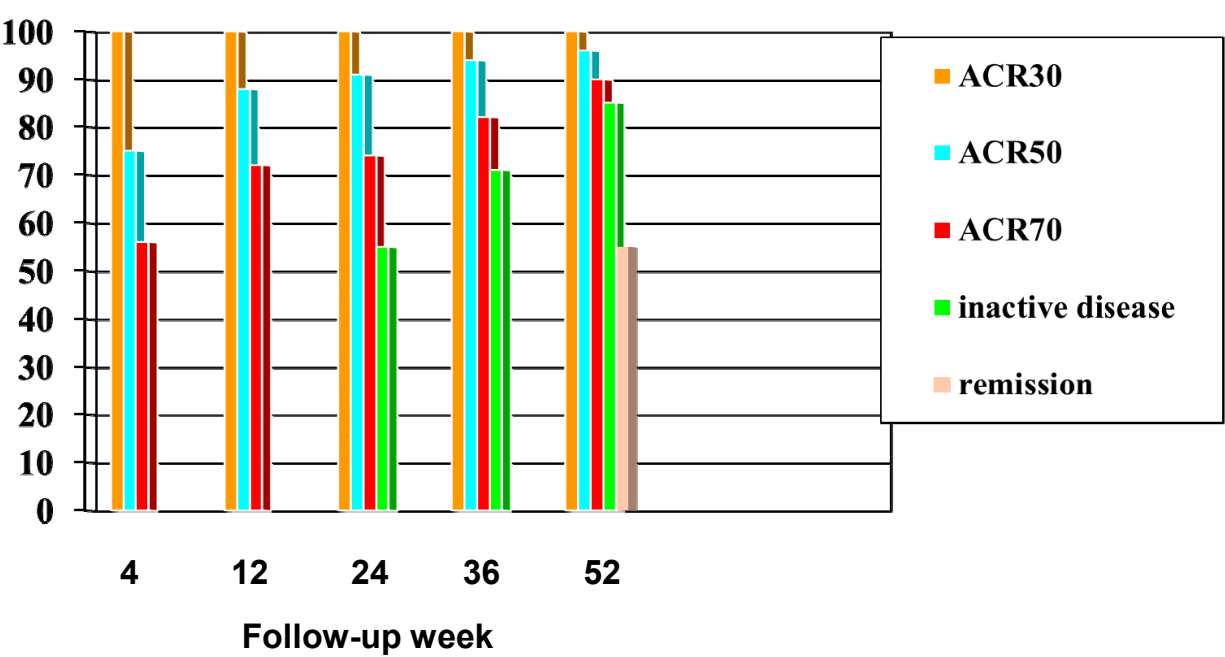
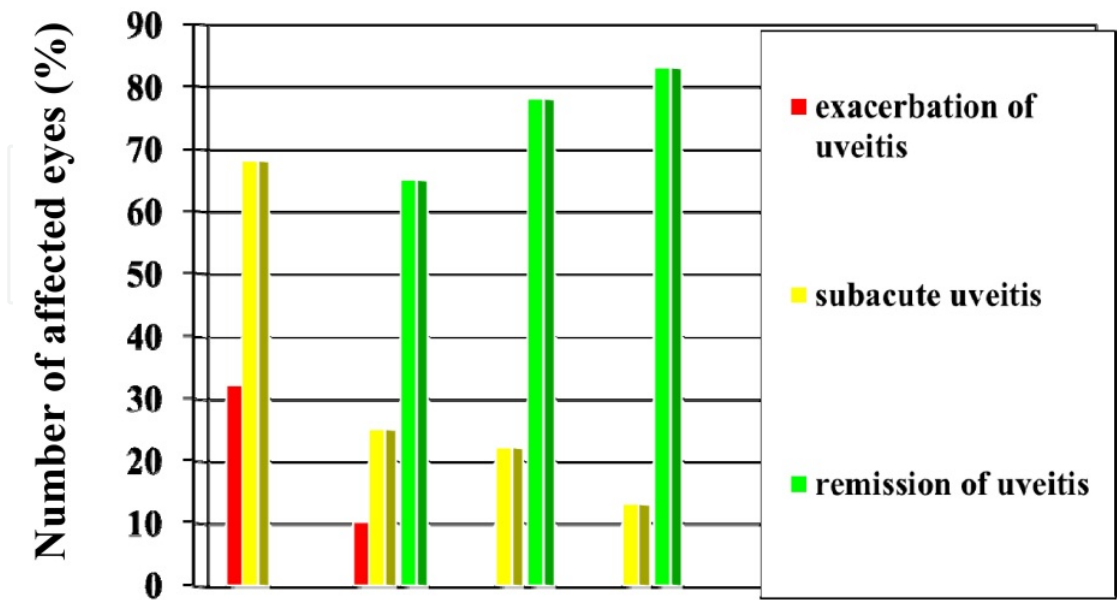


Figure 16. Response according to ACR pedi criteria in children with JIA treated with Adalimumab (n=104)

Parameter	Number of the affected eyes (n=80)
Injections of conjunctiva	85% (68/80)
Edema of iris	46% (37/80)
Corneal precipitations	40% (32/80)
Areas of inflammation in lens	21% (17/80)
Optical nerve disk edema	30% (24/80)

**Table 9.** Clinical manifestations of uveitis in patients with JIA included into the study

After 8 weeks of treatment complete management of conjunctiva injection, iris edema and optical nerve disk edema were reported in 55% (44/80) of the affected eyes - corneal precipitations disappeared in 45% (36/80); inflammation-associated changes of lens – in 18% (14/80) of eyes. Treatment-associated improvement of vision was found in 63 of 80 of the affected eyes; no changes of vision acuity were reported in 33 (41%) of the affected eyes. Dexamethazone eye drops were discontinued in 45% (22/48) of patients, NSAIDs eye drops – in 49% (24/48) of children; the dose of dexamethazone eye drops was reduced in 86% (41/48) of patients. The exacerbation of uveitis was persisting in 10% (8/80) of the affected eyes, subacute uveitis – in 25% (20/80); remission was found in 65% (52/80) of the affected eyes. After 24 weeks of treatment the cases of uveitis were not reported; subacute disease was observed in 22% (18/80) of eyes; remission was diagnosed in 78% (62/80) of the affected eyes. After 52 weeks of treatment remission was diagnosed in 83% of the affected eyes (66/80) (Figure 17).



**Figure 17.** Efficacy of Adalimumab treatment in rheumatoid uveitis (n=48, number of affected eyes = 80)

#### 4.4. Adverse events related to immunosuppressive therapy

Safety evaluation was based on reported adverse events, laboratory parameters, and physical examination (evaluation of vital functions – BP, HR), and the ECG.

Adverse events were evaluated in all enrolled patients that received at least one injection of the study drug.

In general Adalimumab treatment was well-tolerated; most AE's were mild, reversible and would not result in treatment limitations. Injection reactions (occurring during the drug administration or during 24 hours after) included pain at the injection site – in 72.1 % (75) of patients; hyperemia at the injection site was reported in 48 % (50) of patients.

No cases of AE's associated with laboratory values alterations were reported.

No changes of vital functions (diastolic and systolic blood pressure, heart rate) or ECG changes were reported during the treatment course. Cases of Adalimumab discontinuation due to poor therapeutic response were not reported.

Therefore, safety profile of Adalimumab in study patients was satisfactory. Adverse events included local skin reactions at the injection sites. Adalimumab treatment was not associated with any fatal outcomes or cases of drug withdrawal due to adverse events.

One case of treatment discontinuation due to adverse events was reported in patient with suspected regional pulmonary tuberculosis. The patient was admitted to specialized hospital for further examination and development of treatment strategy. However, the diagnosis was not confirmed; the changes in lungs CT were considered to be the post-infection changes. Treatment with Adalimumab was restarted.

### 5. Clinical case

**Patient's data:** female. Age: 15 years old

**Diagnosis:** polyarticular JIA associated uveitis

#### 5.1. Case history

Acute respiratory infections 3-4 times per year, rubella. Parents – practically healthy. Family history: no rheumatoid diseases reported.

Disease onset – February 1997 (age 1.5 years); swelling of the left ankle joint, walk disorders, pain associated with movements in left knee and ankle joints. The local surgeon excluded the diagnosis of acute surgical disease. Local treatment of the affected joints (ointments containing NSAIDs) was prescribed. April 1997, consultation of rheumatologist: diagnosis – juvenile rheumatoid arthritis, oligoarticular type; diclofenac-based treatment was prescribed. Treatment did not result in any decrease in swelling and pain.



Since May 1997, the patient was followed at the Rheumatology Department of one of clinics in Moscow. Disease severity was considered to be moderate. Swelling of knee and ankle joints with pain and limited mobility was reported. Blood analysis: leukocytosis ( $17 \times 10^9/l$ ), ESR increase (up to 62 mm/hour). Blood immunology analysis: positive C-reactive protein test and positive anti-nuclear factor test. Treatment: diclofenac sodium, intra-articular administration of glucocorticoids. Since January 1998 the patient was treated with methotrexate (dose  $7.5 \text{ mg/m}^2$  of body surface/week). Methotrexate treatment was associated with mild improvements; the exacerbations of arthritis became less frequent. The intra-articular administration of glucocorticoids was conducted once per 1-2 months.

2001, spring: rheumatoid uveitis was diagnosed. Local treatment (dexamethasone eye drops, diclofenac eye drops) resulted in management of its manifestations.

Since October 2001, limited mobility of cervical part of the spine was reported; swelling of knee and ankle joints became more severe. The patient started complaining on severe morning stiffness. Only intra-articular administration of glucocorticoids resulted in certain improvements. Methotrexate dose was increased up to  $10 \text{ mg/m}^2$  of body surface per week. July 2004: exposure to sunlight resulted in exacerbation of uveitis; combined immunosuppressive treatment (methotrexate plus cyclosporine,  $3 \text{ mg/kg/day}$ ) was initiated. Combined treatment resulted in management of clinical manifestations of uveitis. Urine analysis: permanent macrohematuria was detected; therefore the immunosuppressive drugs were discontinued. Throughout a year the girl was receiving NSAIDs, with monthly intra-articular administrations of glucocorticosteroids. The treatment was ineffective. By November 2005, the number of joints affected by active arthritis increased; the polyarticular syndrome developed – elbow and radio-metacarpal joints, as well as knee and ankle joints and small joints of palms were involved. The disability was progressing. Oral prednisolone ( $5 \text{ mg/day}$ ) with leflunomide ( $10 \text{ mg/day}$ , with gradual dose increase up to  $20 \text{ mg/day}$ ) were prescribed. Despite the intra-articular administration of glucocorticoids into knee and ankle joints, complete management of the arthritis was not achieved. February 2007: prednisolone was discontinued.

Ineffective treatment with leflunomide, NSAIDs and monthly intra-articular injections of glucocorticoids were the basis for the prescription (January 2008) of anti-cytokine treatment with chimeric monoclonal antibodies to tumor necrosis factor (TNF)  $\alpha$  (Infliximab, dose –  $4.5 \text{ mg/kg}$ ). The first three infusions of Infliximab resulted in improvement; swelling of joints decreased, the duration of morning stiffness was shorter; the laboratory parameters reflecting the disease activity were decreasing. March 2008: metabolic nephropathy was diagnosed. Development of renal calculi was considered the side effect of leflunomide treatment; therefore, the drug was discontinued. March 2008: methotrexate ( $7.5 \text{ mg/m}^2$  of body surface area per week) was restarted. However, after the 4-th administration of Infliximab (same dose) resulted in exacerbation of swelling in the affected joints. The dose of Infliximab was increased up to  $6.6 \text{ mg/kg}$ . This dose of Infliximab was administered 5 times (total number of infliximab infusions – 9). Despite the dose increase, the therapy was not effective; the activity of arthritis was not changed. Therefore, intra-articular betamethasone injections (once per 1-1.5 months) were continued.

In order to develop the treatment strategy, the patient was admitted to the Rheumatology Department of the Scientific Center of Children's Health of RAMS (March 2009). It was 11 years after the onset of the disease. Disease was considered to be severe. Polyarthritis with affection of cervical spine, right shoulder joint, right elbow joint, femoral joints, knee joints, ankle joints, small joints of palms was diagnosed. The patient was unable to perform the full flexion of fingers; the movements in affected joints were limited and associated with pain. The patient complained on morning stiffness lasting up to 120 minutes. Paleness, blackness under the eyes, manifestations of hyper-corticism, associated with continuous intra-articular administration of exogenous glucocorticoids were found. The girl was in emotional depression. Blood analysis: elevated ESR (up to 57 mm/hour); serum level of C-reactive protein (up to 7.6%; normal level – up to 0.8 mg%, see Table). Computer tomography of knee joints: peri-articular osteoporosis, single erosions of bone tissue. Ophthalmologist's consultation: slowly progressing binocular rheumatoid uveitis was diagnosed.

The effect of intra-articular administration of glucocorticoids, associated with complications, and uncontrolled hormone dependency resulted in the decision to discontinue the hormone-based therapy. Analysis of health status demonstrated secondary inefficacy of the treatment with chimeric monoclonal antibodies to TNF $\alpha$  in combination with methotrexate. Infliximab was discontinued due to development of resistance. Despite the severe swelling of joints, glucocorticoids were not administered due to hormone dependency and growth retardation (height of the 13-years old adolescent girl was 146 cm – as of the 11-years old child).

According to the protocol of severe juvenile arthritis treatment, developed by the Scientific Center of Children's Health of RAMS, the girl was treated with pulse-therapy with methotrexate (50 mg/m<sup>2</sup> of body surface area) in combination with cyclosporine (4.4 mg/kg/day) .

The patient received 7 doses of methotrexate intravenously. The treatment resulted in certain improvement: the morning stiffness duration became shorter, and the girl became more active. However, the swelling of knee and ankle joints (Figure 18), limited mobility of the right shoulder joint (Figure 19), right elbow joint (Figure 20), knee joints (Figure 21), femoral joints (Figure 22) and ankle joints remained. Control blood analysis: the laboratory values reflecting the disease activity remained high (Table 10). Repeated ophthalmologic examination: manifestations of slowly progressing uveitis were found. The girl poorly tolerated methotrexate – severe headache and nausea were reported during 3 days after the drug administration. Within 1 month after the last intra-articular administration of betamethasone the withdrawal syndrome developed. It was manifested by myalgia, arthralgia, nausea, vomiting, and depression. Despite the development of the withdrawal syndrome, glucocorticoids were not restarted; active anti-rheumatic treatment was continued. The withdrawal syndrome resolved within 3 weeks.

The inefficacy of combined treatment with methotrexate (50 mg/m<sup>2</sup> of body surface area per week) and cyclosporine (4.4 mg/kg/day) as well as the good initial response to chimeric monoclonal antibodies to TNF $\alpha$  were the basis to prescribe the human antibodies to TNF $\alpha$  – Adalimumab.

## 5.2. Treatment with Adalimumab

Taking into considerations the facts mentioned above, it was decided to prescribe Adalimumab (dose – 40 mg once per 2 weeks) to patient A. The prescription was approved by the Scientific Council and the Ethics and Formulary Committees of Scientific Center for Children Health, RAMS. The parents signed the informed consent form, permitting the administration of drug. In order to exclude the diagnosis of tuberculosis prior to administration of Adalimumab, chest CT and dia-skin test (intra-cutaneous diagnostic test based on intra-cutaneous administration of 2 recombinant proteins of *Mycobacterium tuberculosis*) were conducted. No regional or infiltration changes were found during CT.

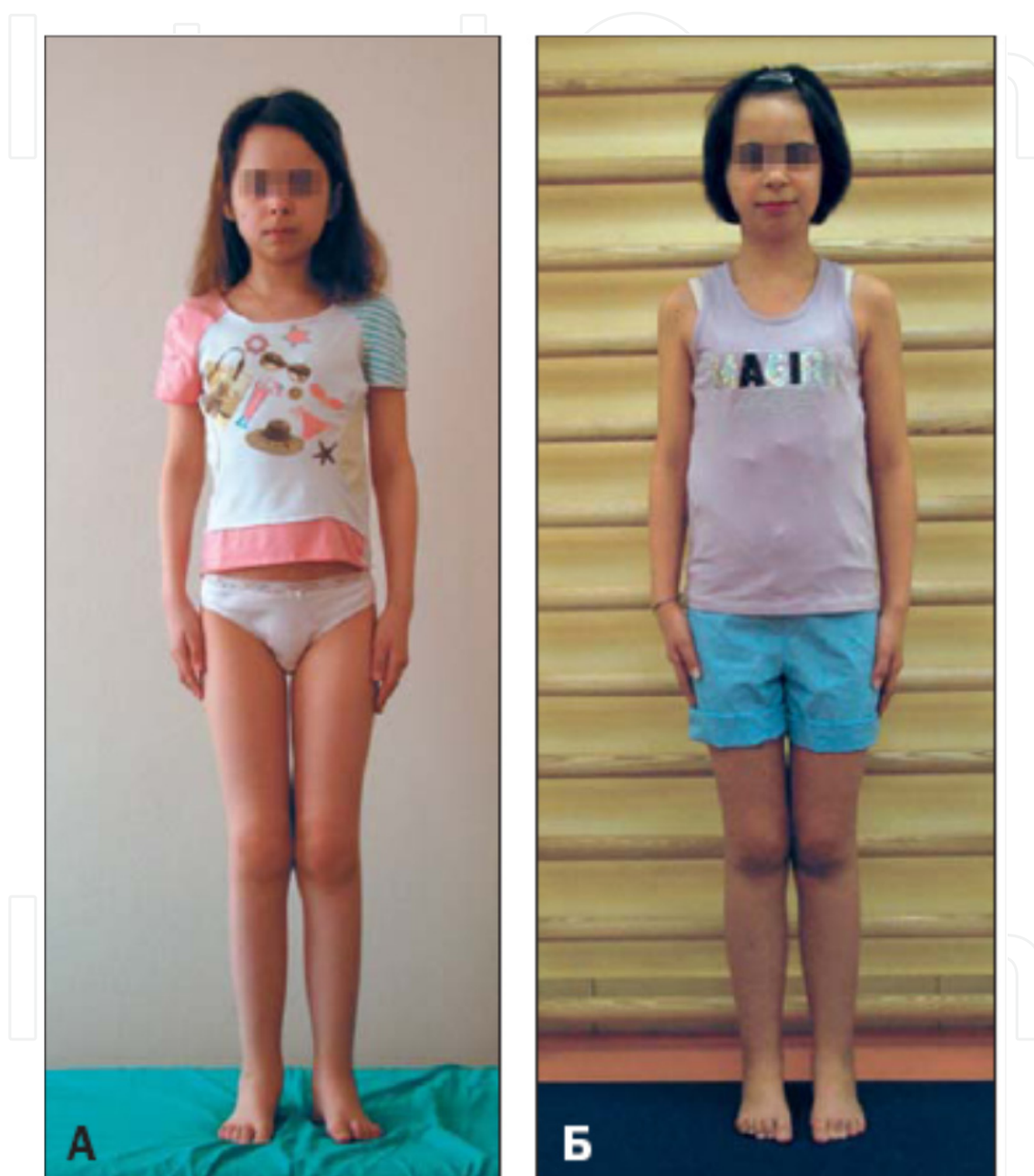## 5.3. Results of treatment

After the exclusion of tuberculosis, Adalimumab treatment was initiated. The girl's activity improved after the first administration of the drug. Morning stiffness resolved within 2 weeks of treatment (Table 10). By the 4-th treatment week, swelling of the affected joints was completely managed; the volume of mobility has improved significantly. Within 6 weeks of Adalimumab treatment, laboratory values reflecting the disease activity returned to normal (Table 10). Control ophthalmological examination: remission of the slowly progressing uveitis was found. The girl continues receiving cyclosporine (total daily dose 4 mg/kg) and methotrexate (25 mg/m<sup>2</sup>/week). At present, the girl has already received 10 doses of Adalimumab (40 mg); treatment was not associated with any adverse events. Treatment is associated with remission of the disease, as evaluated by clinical and laboratory values (Figure 18-22)

Therefore, this clinical report demonstrates a case of long-term juvenile idiopathic arthritis with continuous recurrence, characterized by rapid development of disability, high index of functional failure, poor quality of life, resistant to anti-rheumatic therapy, and secondary inefficacy of the chimeric monoclonal antibodies to TNF $\alpha$ . The Adalimumab treatment managed to overcome the resistance to chimeric antibodies and induced remission of arthritis, restoration of function of the affected joints, normalization of the laboratory values reflecting the activity of the disease. Positive effect of Adalimumab enabled the patient to overcome the severe corticosteroid dependency; the ability to decline the proposed oral prednisolone treatment strategy was achieved. Treatment results demonstrate that Adalimumab is highly effective in children with long-term polyarthritis and uveitis, resistant to various dosage regimens of methotrexate and in combination with cyclosporine, as well as with secondary resistance to chimeric antibodies to TNF $\alpha$ .


## 5.4. Adverse events

No serious adverse events were observed during the follow-up.

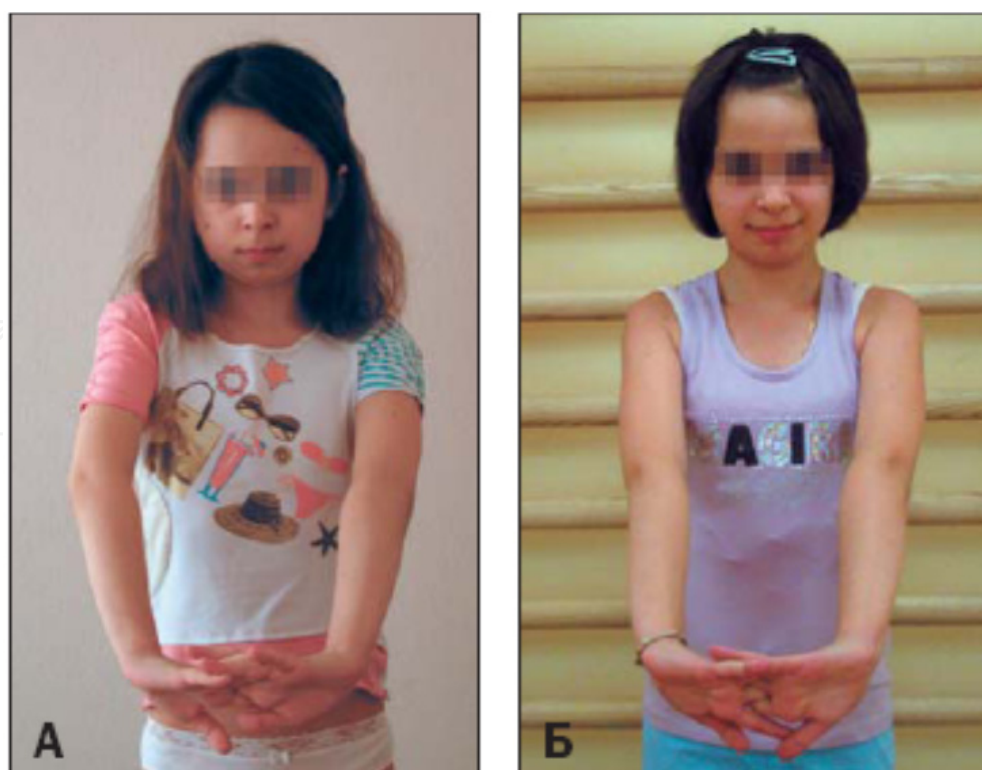

**Figure 18.** Patient A prior (A) and after (B) Adalimumab treatment






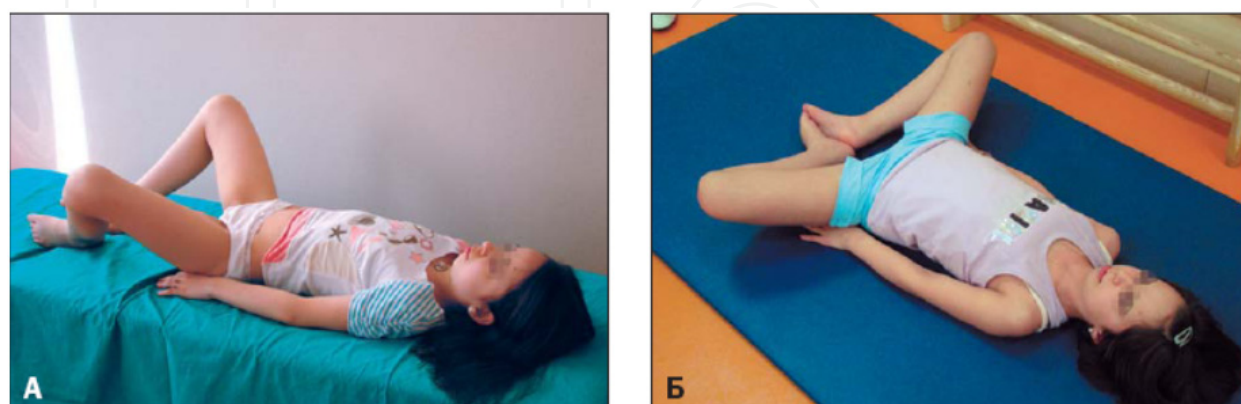
**Figure 19.** Functional ability of shoulder joints prior (A) and during (B) the Adalimumab treatment course



**Figure 20.** Functional ability of elbow joints prior (A) and during (B) Adalimumab treatment course



**Figure 21.** Functional ability of knee joints prior (A) and during (B) Adalimumab treatment course



**Figure 22.** Functional ability of femoral joints prior (A) and during (B) Adalimumab treatment course

Parameters	Prior to pulse-therapy with methotrexate and cyclosporine	Duration of Adalimumab therapy				
		Background	4 weeks	6 weeks	12 weeks	18 weeks
Duration of morning stiffness, min	120	100	0	0	0	0
Number of active joints	19	16	8	6	0	0
Number of joints with limitation of motion	19	15	7	4	0	0
CHAQ index of functional disability, score	1.6	1.7	1.1	0.6	0.5	0.5
Red blood cells $\times 10^{12}/l$	3.98	3.67	4.01	4.33	4.70	4.67
Hemoglobin, g/l	114	102	112	129	140	130
Leukocytes ( $\times 10^9/l$ )	8.	7.4	6.4	5.6	6.4	4.8
Platelets ( $\times 10^9/l$ )	308	426	378	313	359	287
ESR, (mm/h)	57	38	25	3	5	4
C-reactive protein, mg%	7.6	7.25	2.4	0.17	0.1	0.12
Height, cm	146	146	147	148	149	149

**Table 10.** Changes of clinical and laboratory parameters reflecting the activity of disease in association with Adalimumab treatment in patient a

## 6. Conclusion

Thus, the results of 1-year retrospective, observational trials showed high efficacy of Tocilizumab and Adalimumab in children with JIA.

Tocilizumab is effective in patients with the most severe form of juvenile idiopathic arthritis refractory to treatment with glucocorticoids, methotrexate, cyclosporine, combined immunosuppressive therapy and to TNF- $\alpha$  antagonists treatment. The drug induced remission of extra-articular manifestations, arthritis and normalized laboratory parameters of the disease activity without treatment with oral prednisolone, thus avoiding severe irreversible complications of glucocorticoid therapy. Tocilizumab induced disease remission in 43% of patients.

Adalimumab is effective in patients with polyarthritis associated with uveitis. The drug induced disease remission and improved functional activity and quality of life in 55% of patients. Reduction in uveitis activity and remission were reported in 83% of affected eyes. The high efficacy of Adalimumab allowed to avoid oral prednisolone and discontinue topical glucocorticoid therapy in patients with uveitis.

Both agents were well tolerated by patients; no severe serious adverse events were reported throughout the period of observation.

## Author details

T.M. Bzarova, S.I. Valiyeva, R.V. Denisova, K.B. Isayeva,  
A.M. Chomakhidze, T.V. Sleptsova, E.V. Mitenko, I.V. Dvoryakovskiy and M.V. Ryazanov  
*Scientific Center of Children's Health of RAMS, Moscow, Russia*

A.A. Baranov, E.I. Alexeeva, L.S. Namazova-Baranova, E.G. Chistyakova and E.L. Semikina  
*Scientific Center of Children's Health of RAMS, Moscow, Russia*  
*The First Moscow State Medical University I.M. Sechenov, Moscow, Russia*

A.V. Starikova  
*The Helmholtz Moscow Research Institute of Eye Diseases, Moscow, Russia*

## 7. References

- [1] Cassidy J.T., Petty R.E. Juvenile idiopathic arthritis. In Cassidy JT, Petty RE, eds. Textbook of pediatric rheumatology, 6th edn. Philadelphia: WB Saunders. 2011.
- [2] E.I. Alexeeva, S.I. Valeva et al. Efficacy and safety of repeat courses of rituximab treatment in patients with severe refractory juvenile idiopathic arthritis. *Clinical Rheumatology* 2011;(30)9:1163-1172
- [3] Veldhuis G.J., Willemse PH.B., Sleijfer D.T., et al. Toxicity and efficacy of escalating dosages of recombinant human interleukin-6 after chemotherapy in patients with breast cancer or non-small-cell lung cancer // *J. Clin. Oncol.* 1995; 13:2585–2593.
- [4] Rothwell N.J., Busbridge N.J., Lefeuvre R.A., Hardwick A.J. Interleukin-6 is a centrally acting endogenous pyrogen in the rat // *Can. J. Physiol. Pharmacol.* 1991; 69: 1465–1469.
- [5] Castell J.V., Gomez-Lechon M.J., David M., et al. Recombinant human interleukin-6 (IL-6/BSF-2/HSF) regulates the synthesis of acute phase proteins in human hepatocytes // *FEBS Lett.* 1988; 232: 347–350.
- [6] Nemeth E., Rivera S., Gabayan V., et al. IL-6 mediates hypoferremia of inflammation by inducing the synthesis of the iron regulatory hormone hepcidin // *J. Clin. Invest.* 2004; 113: P.1271–1276.
- [7] Ikebuchi K., Wong G.G., Clark S.C., Ihle J.N., Hirai Y., Ogawa M. Interleukin-6 enhancement of interleukin-3-dependent proliferation of multipotential hemopoietic progenitors // *Proc. Natl. Acad. Sci. USA.* 1987; 84: 9035–9039.



- [8] Kimura H., Ishibashi T., Uchida T., Maruyama Y., Friese P., Burstein S.A. Interleukin 6 is a differentiation factor for human megakaryocytes in vitro // *Eur. J. Immunol.* 1990; 20: 1927–1931.
- [9] Tsigos C., Papankolaou D.A., Defensor R., Mitsiadis C.S., Kyrou I., Chrousos G.P. Dose-effects of recombinant human interleukin-6 on pituitary hormone secretion and energy expenditure // *Neuroendocrinology.* 1997; 66: 54–62.
- [10] Heliovaara M.K., Teppo A.M., Karonen S.L., Tuominen J.A., Ebeling P. Plasma IL-6 concentration is inversely related to insulin sensitivity, and acute phase proteins associate with glucose and lipid metabolism in healthy subjects // *Diabetes Obes. Metab.* 2005; 7: 729–736.
- [11] Cutolo M., Straub R.H. Circadian rhythms in arthritis: hormonal effects on the immune/inflammatory reaction // *Autoimmun. Rev.* 2008; 7: P.223–228.
- [12] Nishimoto N. Kishimoto T. Humanized antihuman IL-6 receptor antibody, tocilizumab // *Handb. Exp. Pharmacol.* 2008; 181: 151-160.
- [13] European Medicines Agency. RoActemra (tocilizumab): summary of product characteristics [online]. Available from URL: <http://www.emea.europa.eu/humandoes/PDFs/EPAR/RoActemra/H-955-PI-en.pdf> [accessed 2009 Mar 23].
- [14] Chugai Pharmaceutical Co. Actemra, a humanized antihuman IL-6 receptor monoclonal antibody obtained approval for indications of rheumatoid arthritis, polyarticular-course juvenile idiopathic arthritis and systemic-onset juvenile idiopathic arthritis [media release]. Available from URL: <http://www.chugai-pharm.co.jp> [accessed 2008 Sep 24].
- [15] Imagawa T., Ozawa R., Miyamae T., et al. Efficacy and safety in 48-week treatment of tocilizumab in children with polyarticular course JIA with polyarticular or oligoarticular onset // *Ann. Rheum. Dis.* 2007; 66(Suppl. II): 550.
- [16] Yokota S., Imagawa T., Miyamae T. Safety and efficacy of up to three years of continuous tocilizumab therapy in children with systemic-onset juvenile idiopathic arthritis [SAT0536] // *Ann. Rheum. Dis.* 2009; 68 (Suppl. 3):715.
- [17] Inaba Y., Aoki C., Ozawa R. Radiologic evaluation of large joints during tocilizumab treatment in children with systemic juvenile idiopathic arthritis [SAT0555] // *Ann. Rheum. Dis.* 2009; 68(Suppl. 3):720.
- [18] Yokota S., Imagawa T., Mori M., et al. Efficacy and safety of tocilizumab in patients with systemic-onset juvenile idiopathic arthritis: a randomized, double-blind, placebo-controlled, withdrawal phase III trial // *Lancet.* 2008; 371: 998-1006.
- [19] Yokota S., Miyamae T., Imagawa T., et al.: Therapeutic efficacy of humanized recombinant anti-interleukin-6 receptor antibody in children with systemic-onset juvenile idiopathic arthritis // *Arthritis Rheum.* 2005; 52: 818-825.
- [20] Aoki C., Inaba Y., Ozawa R. Effects of tocilizumab on radiological findings in polyarticular juvenile idiopathic arthritis [OP-0145] // *Ann. Rheum. Dis.* 2009; 68(Suppl. 3):118.
- [21] Quartier P., Maire D., Souabni L. Efficacy and safety of tocilizumab in systemic onset juvenile idiopathic arthritis in french centers [FRI0462] // *Ann. Rheum. Dis.* 2009; 68(Suppl. 3): 506.

- [22] Kaneko U., Imagawa T., Kishi T. Discrepancy between progression of joint damage and improvement of systemic inflammation in patients with systemic-onset juvenile idiopathic arthritis treated with tocilizumab [SAT0548] // Ann. Rheum. Dis. 2009; 68(Suppl.3): 719.
- [23] Yokota S., Imagawa T., Miyamae T. Safety and efficacy of up to three years of continuous tocilizumab therapy in children with systemic-onset juvenile idiopathic arthritis [SAT0536] // Ann. Rheum. Dis. 2009;.68 (Suppl. 3.): 715.
- [24] De Benedetti F., Brunner H., Ruperto N. et al. Efficacy and Safety of Tocilizumab (TCZ) in Patients with Systemic Juvenile Idiopathic Arthritis (sJIA): TENDER 52-Week Data [OP0006] // Ann. Rheum. Dis. 2011;70 (Suppl 3):67
- [25] Furst DE, Schiff MH, Fleischmann RM, Strand V, Birbara CA, Compagnone D, et al. Adalimumab, a fully human anti tumor necrosis factor  $\alpha$  monoclonal antibody, and concomitant standard antirheumatic therapy for the treatment of rheumatoid arthritis results of STAR (Safety Trial of Adalimumab in Rheumatoid Arthritis). // J Rheumatol – 2003. – 30. – P. 2563-2571
- [26] Weinblatt ME, Keystone EC, Furst DE, Moreland LW, Weisman MH, Birbara CA, et al Adalimumab, a fully human anti-tumor necrosis factor  $\alpha$  monoclonal antibody, for the treatment of rheumatoid arthritis in patients taking concomitant methotrexate the ARMADA trial [published erratum appears in Arthritis Rheum 2003;48 855]. Arthritis Rheum - 2003 - 48 – P. 35-45
- [27] Keystone EC, Kavanaugh AF, Sharp JT, Tannenbaum H, Hua Y, Teoh LS, et al Radiographic, clinical, and functional outcomes of treatment with adalimumab (a human anti-tumor necrosis factor monoclonal antibody) in patients with active rheumatoid arthritis receiving concomitant methotrexate therapy a randomized, placebo-controlled, 52-week trial. // Arthritis Rheum - 2004 – 50 – P. 1400-1411
- [28] Van de Putte LB, Atkins C, Malaise M, Sany J, Russell AS, van Riel PL, et al Efficacy and safety of adalimumab as monotherapy in patients with rheumatoid arthritis for whom previous disease modifying antirheumatic drug treatment has failed. // Ann Rheum Dis. – 2004. – 63. – P. 508-516
- [29] Mease PJ, Gladman DD, Ritchhn CT, Ruderman EM, Steinfeld SD, Choy EH, et al, for the ADEPT Study Group Adalimumab for the treatment of patients with moderately to severely active psoratic arthritis results of a double-blind, randomized, placebo-controlled trial. // Arthritis Rheum. - 2005. – 52. – P. 3279-3289.
- [30] Lipsky P.E., van der Heijde D.M.F.M, St Clair E.W. et al. Infliximab and methotrexate in the treatment of rheumatoid arthritis. // N Engl J Med. – 2000. – 343. – P.1594-1602
- [31] Feldman M., Brennan P., Maini R. Role of cytokines in rheumatoid arthritis. Annu. Rev. Immunol., 1996, 14, 397-440
- [32] Beutler B. The rote of tumor necrosis factor in health and disease. J. Rheumatol., 1999. 26 (Supl. 57), 16-21
- [33] Aikawa NE, De Carvalho JF, Silva CA et al Immunogenicity of anti-TNF $\alpha$  agents in autoimmune diseases. Clinic Rev Allerg Immunol, 2010. 38(2–3):82–89

- [34] Moreland LW, Cohen SB, Baumgartner SW, Tindall EA, Bulpitt K, Martin R, et al Long-term safety and efficacy of etanercept in patients with rheumatoid arthritis. // J Rheumatol - 2001. – 28. – P. 1238-44
- [35] Breedveld FC, Weisman MH, Kavanaugh AF, Cohen SB, Pavelka K, van Vollenhoven R, for the PREMIER investigators, et al. The PREMIER study a multicenter, randomized, double blind clinical trial of combination therapy with adalimumab plus methotrexate versus methotrexate alone or adalimumab alone in patients with early, aggressive rheumatoid arthritis who had not had previous methotrexate treatment. // Arthritis Rheum 2006. - 54. - P: 26-37
- [36] Burmester GR, Manette X Montecucco CM et al. Adalimumab alone and in combination with disease-modifying antirheumatic drugs for the treatment of rheumatoid arthritis in clinical practice the Research in Active Rheumatoid Arthritis (ReAct) trial. // Ann Rheum Dis. Published Online First 20 March 2007 doi:10.1136/ard. – 2006 066761
- [37] Bombardieri S., Ruiz A.A., Fardellone P., Geusens P., McKenna F., Unnebrink K., Oezer U., Kary S., Kupper H., Burmester G.R. on behalf of ReAct Study Group. Effectiveness of adalimumab for rheumatoid arthritis in patients with a history of TNF-antagonist therapy in clinical practice. // Rheumatology Advance Access published May 15, 2007 doi:10.1093/rheumatology/kem091
- [38] Nicas SN, Voulgan PV, Alamanos Y *et al.* Efficacy and safety of switching from Infliximab to adalimumab a comparative controlled study. // Ann Rheum Dis. - 2006. - 65. - P: 257-60
- [39] Bennett AN, Peterson P, Zain A, Grumley J, Panayi G, Kirkham B Adalimumab in clinical practice Outcome in 70 rheumatoid arthritis patients, including comparison of patients with and without previous anti-TNF exposure. // Rheumatology. - 2005. - 44. - P. 1026-31
- [40] Bijl AE, Breedveld FC, Antoni CE *et. al.* Adalimumab (HUMIRA®) is effective in treating patients with rheumatoid arthritis who previously failed infliximab [abstract SAT0062]. // Ann Rheum Dis/ - 2005. - 64 (Suppl III) 428
- [41] Wick MC, Ernestam S, Lmdblad S, Bratt J, Klareskog L, van Vollenhoven RF Adalimumab (Humira) restores clinical response in patients with secondary loss of efficacy from infliximab (Remicade) or etanercept (Enbrel) results from the STURE registry at Karolinska University Hospital Scand. // J Rheumatol. - 2005 - 34. – P. 353-8
- [42] Brocq O, Albert C, Roux C, Gerard D, Breuil V, Ziegler LE Adalimumab in rheumatoid arthritis after failed infliximab and/or etanercept therapy experience with 18 patients. // Joint Bone Spine. - 2004. – 71. P. 601-3
- [43] Haibel H, Rudwaleit M, Listing J et al. Efficacy of adalimumab in the treatment of axial spondylarthritis without radiographically defined sacroiliitis: results of a twelve-week randomized, double-blind, placebo-controlled trial followed by an open-label extension up to week fifty-two. Arthritis Rheum. 2008 Jul;58(7):1981-91
- [44] Wijbrandts CA, Klaasen R, Dijkgraaf MG et al. Bone mineral density in rheumatoid arthritis patients 1 year after adalimumab therapy: arrest of bone loss? Ann Rheum Dis., ARD Online First, published on April 13, 2008 as 10.1136/ard.2008.091611

- [45] Kimel M, Cifaldi M, Chen N, Revicki D. Adalimumab plus methotrexate improved SF-36 scores and reduced the effect of rheumatoid arthritis (RA) on work activity for patients with early RA. *J Rheumatol*. 2008 Feb;35(2):206-15
- [46] Лучихина Е.Л., Каратеев Д.Е., Насонов Е.Л. Первый опыт применения адалимумаба в России: предварительные результаты 24 недельного открытого исследования. *Научно-практическая ревматология*. 2008, №5 стр. 59-63
- [47] Lovell D.; Ruperto N.; Reiff A.; Jung Lawrence K.; Higgins G; Koné-Paut I; Jones Olcay Y.; McIlraith Melissa J.; Andhivarothai N.; Kupper H.; Giannini Edward H.; Peterson T; Martini A. Long-Term Efficacy and Safety of Adalimumab for up to 6 Years in Patients with Juvenile Idiopathic Arthritis. Abstract presented at: 75th Annual scientific meeting of the American College of Rheumatology (ACR) and the 46th Annual meeting of the Association of Rheumatology Health Professionals (ARHP); 11/5/2011 Chicago, IL; USA. Abstract MIS (7190791).
- [48] Lovell Daniel J. et al. OLE DE 038 : Long-Term Efficacy and Safety of ADA for up to 6 years in Patients with JIA. *ACR11 – arthritis & rheumatism volume 63, number10 (supplement) october 2011 abstract 265*
- [49] Luciana Breda, Marianna Del Torto, Sara De Sanctis, Francesco Chiarelli Biologics in children's autoimmune disorders: efficacy and safety. *Eur J Pediatr* (2011) 170:157–167
- [50] Dana MR, Merayo-Llodes J, Schaumberg DA, Forster CS. Visual outcomes prognosticators in juvenile rheumatoid arthritis-associated uveitis. *Ophthalmology*. - 1997. - 104. - P.236-44.
- [51] Foster CS. Diagnosis and treatment of juvenile idiopathic arthritis associated uveitis. *Current Opin Ophthalmol*. - 2003. - 14. - P. 395-8.
- [52] BenEzra D, Cohen E, Maftzir G. Uveitis in children and adolescents. *Br J Ophthalmol*. - 2006. - 89. - P. 444-8.
- [53] Tynjala P., Kotaniemi K., Lindahl P., Latva K., Aalto K., Honkanen V., Lahdenne P. Adalimumab in the treatment of Juvenile Idiopathic Arthritis associated Uveitis – A Pilot Study. Abstract presented at: 8th Annual European League Against Rheumatism (EULAR 2007); June 13-16, 2007; Barcelona, Spain. Abstract THU0483.
- [54] G. Schett, L C Coates, Zoe R Ash, S Finzel, P G Conaghan Structural damage in rheumatoid arthritis, psoriatic arthritis, and ankylosing spondylitis: traditional views, novel insights gained from TNF blockade, and concepts for the future. *Arthritis Research & Therapy* 2011, 13(Suppl 1):S4
- [55] Liza B. Vazquez-cobian, MD, Thomas Flynn, MD, and Thomas J. A. Lehman, MD Adalimumab therapy for childhood uveitis. *J Pediatr*. - 2006. -149.- P.572-575.
- [56] Tynjälä P, Kotaniemi K, Lindahl P et. al. Adalimumab in juvenile idiopathic arthritis-associated chronic anterior uveitis. *Rheumatology (Oxford)*. 2008 Mar;47(3):339-44. Epub 2008 Jan 31
- [57] Biester S, Deuter C, Michels H et al. Adalimumab in the therapy of uveitis in childhood. *Br J Ophthalmol*. 2007 Mar; 91(3):274-6
- [58] Heiligenhaus A, Horneff G, Greiner K et al. Inhibitors of tumour necrosis factor-alpha for the treatment of arthritis and uveitis in childhood. *Klin Monatsbl Augenheilkd*. 2007 Jun;224(6):526-31

- [59] Foeldvari I, Nielsen S, Kümmerle-Deschner J et al. Tumor necrosis factor-alpha blocker in treatment of juvenile idiopathic arthritis-associated uveitis refractory to second-line agents: results of a multinational survey. *Nat Clin Pract Rheumatol*. 2007 Nov;3(11):608-9.
- [60] Cassidy JT, Petty RE., Laxer R.M., Lindsley C.B. Textbook of pediatric rheumatology. 6th ed. Philadelphia: Saunders Elsevier; 2010; 794 p.
- [61] Dixon W.G., Watson K., Lunt M. et al. (2006) British Society for Rheumatology Biologics Register. Rates of serious infection, including site-specific and bacterial intracellular infection, in rheumatoid arthritis patients receiving anti-tumor necrosis factor therapy^ results from the British Society for Rheumatology Biologic register. *Arthritis Rheum* 54(8);2368-2376.
- [62] Hogan MJ., Rimura SJ., Thygeson P.. Signs and symptoms of uveitis: I. Anterior uveitis. *Am. J. Ophthalmol.*–1959.–Vol. 47.–P. 155–170.
- [63] C.A., Ruperto N., Gannini E. et al. Preliminary criteria for clinical remission for select categories of juvenile idiopathic arthritis // *J.Rheumatol.* – 2004. – V.31, № 11. – P.2290-2294.