

We are IntechOpen, the world's leading publisher of Open Access books Built by scientists, for scientists

6,900

Open access books available

186,000

International authors and editors

200M

Downloads

Our authors are among the

154

Countries delivered to

TOP 1%

most cited scientists

12.2%

Contributors from top 500 universities



WEB OF SCIENCE™

Selection of our books indexed in the Book Citation Index
in Web of Science™ Core Collection (BKCI)

Interested in publishing with us?
Contact book.department@intechopen.com

Numbers displayed above are based on latest data collected.
For more information visit www.intechopen.com



Thyroid Autoimmunity in Patients with Skin Disorders

Emina Kasumagic-Halilovic and Begler Begovic

Additional information is available at the end of the chapter

<http://dx.doi.org/10.5772/45980>

1. Introduction

Thyroid disorders are known to involve all the organ systems of the body and the skin is no exception. Some dermatological skin findings and diseases may be the first symptoms of thyroid disease [1]. Available data suggest that thyroid hormone plays a pivotal role in embryonic development of mammalian skin as well as in maintenance of normal cutaneous function in adult skin. Thyroid hormone stimulates epidermal oxygen consumption, protein synthesis, mitosis, and determination of epidermal thickness [2]. Thyroid hormone is an important regulator of epidermal homeostasis. In tissue culture studies using surrogates for DNA expression, T_3 has been shown to stimulate growth of both epidermal keratinocytes and dermal fibroblasts [3, 4]. In addition, thyroid hormone appears to be necessary for both the initiation and maintenance of hair growth and normal secretion of sebum.

Both hypothyroidism and hyperthyroidism are known to cause skin change. Hypothyroidism may result from either inadequate circulating levels of thyroid hormone or target cell resistance to hormonal action. Primary hypothyroidism as a result of glandular failure is the most common cause and most frequently result from autoimmune disease [5]. In hypothyroidism, the skin is cold, xerotic and pale. The coldness is due to reduced core temperature and cutaneous vasoconstriction. The decreased skin perfusion has been documented with nail fold capillaroscopy [6]. It has been suggested that the diminished skin perfusion is reflex vasoconstriction compensatory to diminished core temperature. The diminished core temperature itself may be secondary to reduced thermogenesis [7]. Occasionally, purpura may be noted in hypothyroid patients as a result of diminished levels of clotting factors and the loss of vascular support secondary to the dermal mucin [8]. The dryness of hypothyroid skin results from decreased eccrine gland secretion. The mechanism for decreased sweating is not clear although the hypothyroid glands are atrophic on histologic examination [9]. Hypohidrosis, possibly accompanied by diminished epidermal

sterol biosynthesis, may lead to acquired palmoplantar keratoderma. Xerosis is due to a change in skin texture and poor hydration of the stratum corneum. The skin is rough and covered with fine scales. Palms and soles may be quite dry. The epidermis is thin and hyperkeratotic, and there is follicular plugging. Because the changes are generalized, they can be differentiated from similar alterations in the skin of atopic individuals and keratosis pilaris, where the findings are more prominent on the extremities [10]. Hypothyroidism also may affect the development of the lamellar granules (Odland bodies), which are vital in the establishment of a normal stratum corneum [11]. In hypothyroidism, the skin tends to be pale both because of the dermal mucopolysaccharides and dermal water content which alter the refraction of light. The name myxedema refers to the associated skin condition caused by increased glycosaminoglycan deposition in the skin. Generalized myxedema is still the classic cutaneous sign of hypothyroidism. The mucopolysaccharides that accumulate in the dermis are hyaluronic acid and chondroitin sulfate. They appear first in the papillary dermis and are most prominent around hair follicles and vessels. They separate the collagen bundles and there may be some secondary degeneration of collagen [10]. Generally, myxedema is diffuse, but focal mucinous papules have been described. Skin may appear swollen, dry, pale, waxy, and firm to the touch. In addition, increased dermal carotene may appear as a prominent yellowish discoloration on the palms, soles and nasolabial folds. Hypothyroid patients may sometimes suffer *Candida* folliculitis. It has been theorized that because the sebaceous glands of hypothyroid patients secrete decreased sebum relative to those of euthyroid persons, the hair follicles may develop a flora with lipophilic organisms, which are replaced by *Candida albicans* (12). The hypothyroid skin heals slowly, and this tendency is proportional to the degree of hormone deficiency. In hypothyroidism, hair can be dry, coarse, brittle and slow growing. There is both patchy and diffuse loss of scalp hair, a very characteristic loss of the outer third of the eyebrow (madarosis), and diminished body hair. Pubic and axillary hair may be sparse. The alopecia connected to hypothyroidism may be mediated by hormone effects on the initiation as well as the duration of hair growth. Massive telogen effluvium may occur when there is abrupt onset of hypothyroidism, and the percentage of scalp hairs in telogen is generally increased in hypothyroid states [10]. Using DNA flow cytometry, Schell *et al.* observed that cell proliferation indices were reduced in hair bulbs of hypothyroid subjects and increased in hyperthyroidism compared with normal values [13]. Hypothyroid patients, especially children, frequently develop long, lanugo-type hair on the back, shoulders, and extremities [10]. Diminished sebum secretion contributes to the coarse appearance of the hair. Sometimes, hair loss is the only apparent symptom of hypothyroidism and the dermatologist is the first to diagnose and treat the condition. Nails grow slowly and tend to be thickened, striated and brittle. Onycholysis is also associated with hypothyroidism [1].

The specific pathophysiology linking hyperthyroidism to classic cutaneous findings remains to be well explained (5). In hyperthyroidism, the skin is warm, soft, moist and smooth. The epidermis is thin but not atrophic, and the stratum corneum is well hydrated. While the smooth skin is an epidermal finding, the warmth is caused by increased cutaneous blood flow and the moisture is a reflection of the underlying metabolic state [10]. The warmth is

often accompanied by a persistent flush of the face, redness of the elbows, and palmar erythema. Hyperhydrosis, especially on palms and soles may be observed. Scalp hair may be fine and soft, and may be accompanied by a diffuse nonscarring alopecia. *In vitro* studies suggest increased hair growth rate in thyrotoxicosis. L-Triiodothyronine was shown to stimulate proliferation of outer root sheath keratinocytes and dermal papilla cells [14]. Hypertrichosis is can be observed in cases of thyroid dermatopathy and may be related to alterations in the proteoglycans associated with dermal papilla [15]. Sometimes an early symptom of hyperthyroidism is loss of pigment and early gray hair development. Nail changes may also occur, characterized by a concave contour accompanied by distal onycholysis (Plummer's nails). Hyperpigmentation has been described in thyrotoxic patients in both localized and generalized distribution. There is speculation that the hyperpigmentation is due to increased release of pituitary adrenocorticotrophic hormone compensating for accelerated cortisol degradation [16]. Hyperthyroidism may also induce pruritus with or without urticaria [17]. Patients with autoimmune mediated thyrotoxicosis may also have distinct cutaneous manifestations such as pretibial myxedema and acropachy. Pretibial myxedema is the localized thickening of the pretibial skin due to accumulation of acid mukopolysaccharides. It usually present with firm nodules and plaques varying in colour from pink to purple-brown, and sometimes accompanied by woody induration on extensor surfaces. A diffuse brawny edema may be present without nodules. Localized hyperhydrosis has been reported in cases of pretibial myxedema. Less common is an elephantiasis nostras variant in which the extremity becomes enlarged and covered with verrucous nodules [10]. Thickening of the skin of the extensor surface of the forearm (preradial myxedema) has been reported [18]. Excessive amounts of hyaluronic acid and chondriotin are present in lesions as well as in clinically normal skin [19]. The precise pathogenesis of pretibial myxedema remains to be defined. One leading theory is that pretibial fibroblasts are the target for antithyroid antibodies. After stimulation by thyroid autoantibodies, fibroblasts may produce excess glukosaminglycans [5]. Other theories have implicated T cells as the primary effector of dermopathy. T-cells may interact with an autoantigen that is either identical or cross-reactive with a thyroid autoantigen in the dermis. In turn, this may induce secretion of cytokines such as glycosaminoglycan-stimulatory lymphokine, interleukin1, tumor necrosis factor, and gamma interferon, which activate fibroblasts to secrete hyaluronic acid and chondriotin sulfate [20]. Thyroid acropachy consist of the triad of digital clubbing, soft-tissue swelling of the hands and feet, and characteristic periosteal reactions. The vast majority of cases are associated with Graves' disease, although it has been reported to occur in Hashimoto's thyroiditis. Scleromyxedema has been reported in the setting of hyperthyroidism. This rare entity is comprised of numerous firm, white, yellow, or pink papules scattered on the face, trunk, and extremities. Cutaneous lesions are the result of accumulation of acid mucopolysaccharides, mostly hyaluronic acid, in the dermis, accompanied by large fibrocytes [5].

Skin manifestations of thyroid dysfunction may be divided into two main categories: (I) direct action of thyroid hormone on skin tissues, and (II) autoimmune skin disease associated with thyroid dysfunction of autoimmune etiology. Direct thyroid hormone action on skin is mediated through thyroid hormone receptor (TR). All three widely recognized

thyroid hormone binding isoforms of TR have been identified in skin tissues [14, 21]. TRs have been detected in epidermal keratinocytes, skin fibroblasts, hair arrector pili muscle cells, sebaceous gland cells, vascular endothelial cells, and a number of cells types that make up the hair follicle [9]. The demonstration of TR expression in hair follicle cells indicates that thyroid hormone can affect hair growth directly, rather than through an intermediate mechanism such as a general metabolic status [22]. In addition, several thyroid hormone responsive genes have been identified in skin.

When thyroid disease is of autoimmune etiology, additional skin findings may be evident which reflect associated autoimmune disease [9]. Patients with autoimmune thyroid disease are at increased risk for other autoimmune diseases, both tissue-specific and generalized. In autoimmune disease such as Graves' disease and Hashimoto's thyroiditis the skin manifestations may be related to either thyroid hormone levels themselves or to associated T and/or B cell abnormalities [23]. A list of autoimmune conditions apparent when examining the skin includes alopecia areata, vitiligo, chronic urticaria, bullous disorders, connective tissue diseases and palmoplantar pustulosis.

There is convincing evidence of a significant association between thyroid autoimmunity and skin disorders. Most commonly reported cutaneous disorder related with thyroid diseases is alopecia areata, which have especially autoimmune etiology.

2. Thyroid autoimmunity in patients with alopecia areata

2.1. Introduction

Alopecia areata (AA) is a clinical condition characterized by well circumscribed, round, or oval patches of hair loss on the scalp or other parts of the body. Sometimes, alopecia totalis (AT), loss of all scalp hair, or alopecia universalis (AU), loss of all body hair, may develop. This disorder affects both sexes equally and occurs at all ages, although children and young adults are affected most often. The etiopathogenesis of AA is still unclear, but there is evidence that autoimmunity and endocrine dysfunction may be involved [24-26]. The autoimmune etiology has been proposed on the basis of its association with various autoimmune diseases, the presence of autoantibodies and various underlying immune abnormalities in the affected sites of these patients [27, 28]. One of the main associations is with thyroid abnormalities. This association was further supported by an increased incidence of abnormal thyroid structure, function tests and/or presence of thyroid autoantibodies found in many studies [29-32].

The aim of this study was to determine the prevalence of thyroid autoimmunity in patients with AA.

2.2. Patients and methods

The study included 70 patients with AA (40 female and 30 male). A detailed history and examination were taken in all study subjects, including patients age, age at onset, duration of disease, associated diseases, history of thyroid disorders and the extent and severity of

disease. The diagnosis of AA was made on clinical grounds. Skin biopsy was performed in selected cases. No patient was diagnosed before this study as having any type of thyroid dysfunction. The control group consisted of 70 volunteers (40 female and 30 male) who had skin diseases other than AA or autoimmune disorders. Blood samples were taken and a physical examination and thyroid sonography was performed. All subjects gave their informed consent in accordance with the requirements of the institutional Ethics Committee. Thyroid autoantibodies (thyroglobulin antibody, anti-Tg, and thyroid peroxidase antibody, anti-TPO) and thyroid hormones (thyroxine (T4), triiodothyronine (T3) and thyroid stimulating hormone (TSH) were measured in all subjects. Total T4 (normal range: 70-180 nmol/L) and total T3 (normal range: 1.3-3.3 nmol/L) were measured by use of radioimmunoassay (RIA); TSH (normal range: 0.3-4.2 mIU/L) was determined by use of immunoradiometric assay (IRMA) (BRAHMS Aktiengesellschaft, Hennigsdorf, Germany). Serum levels of anti-Tg (threshold value: 115 IU/mL) and anti-TPO (borderline value: 34 IU/mL) were measured by use of electrochemiluminescence immunoassay (ECLIA) according to standard protocols (COBAS, Roche Diagnostics GmbH, Mannheim, Germany).

Baseline clinical characteristics for the two groups were compared with the use of Student's t-test for continuous variables, the chi-square test or Fisher's exact test (two-sided) for categorical variables, as appropriate. Data were considered statistically significant at $P < 0.05$.

Statistical analyses were performed using MedCalc for Windows, version 11.4.1.0 (MedCalc Software, Mariakerke, Belgium).

2.3. Results

We performed a cross-sectional study in 70 consecutive patients with alopecia areata and 70 age- and sex-matched controls. Demographic data of patients and controls are shown in Table 1. The mean (SD) age of the patient and control groups was 40.39 (± 14.39) and 40.71 (± 15.30), respectively ($P = 0.896$). The onset of AA occurred in 14 (20%) of the patients before 16 years of age, 3 (4.28%) patients had AA more than 10 years. The duration of alopecia areata ranged from 1 to 150 months. A family history of the same disease was present in 7 (10%) patients. According to the clinical type of AA, 13 patients had unilocal lesion, 37 patients had multilocal lesions, 12 alopecia totalis and 8 alopecia universalis (Table 2).

Thyroid functional abnormalities were found in 8 (11.43%) patients. In the control group only one patient had abnormalities in hormonal status.

Hypoechogenic thyroid tissue was seen in 7 (10%) patients who all had elevated levels of thyroid autoantibodies. The thyroid gland was enlarged in 5 (7.14%) patients. Goitre was diagnosed in 4 (5.71%) cases. The ultrasound examination of the thyroid gland in control group was interpreted as normal in 64 (91.42%), and 6 (5.45%) volunteers had small simple goiter. Thyroid volume did not differ significantly between the study patients and the controls ($p > 0.05$).

In patients with alopecia areata anti-Tg titers were ranging from 11.10 to 915.30 IU/mL and anti-TPO antibody titers from 5.10 to 714.40 IU/mL. In control group anti-Tg titers were

ranging from 10.00 to 153.00 IU/mL, and anti-TPO antibody titers from 4.40 to 129.00 IU/mL. Anti-Tg antibody in 16 (23%) patients, anti-TPO antibody in 21 (30%) and both anti-Tg and anti-TPO antibodies in 13 (19%) were higher than the normal antibody titres. In the control group, one subject (1%) had positive anti-Tg and one volunteer (1%) had positive anti-TPO. The frequency of thyroid autoantibodies was significantly higher in alopecia areata patients than in control group (Table 3).

A Chi-square test for independence (with Yates Continuity Correction) indicated significant association between higher values of anti-Tg (values more than 115 IU/ml) and alopecia areata, χ^2 (1, n=140)= 13.123, P=0.0003.

A Chi-square test for independence (with Yates Continuity Correction) indicated significant association between higher values of anti-TPO (values more than 34 IU/ml) and alopecia areata, χ^2 (1, n=140)=19.468, P<0.0001.

	Alopecia areata group n (%)	Control group n (%)	P
Men, n (%)	30 (43)	30 (43)	
Women, n (%)	40 (57)	40 (57)	
Age range, years	17-66	16-66	
Age, mean years (SD)	40.39 (14.39)	40.71 (15.30)	0.896

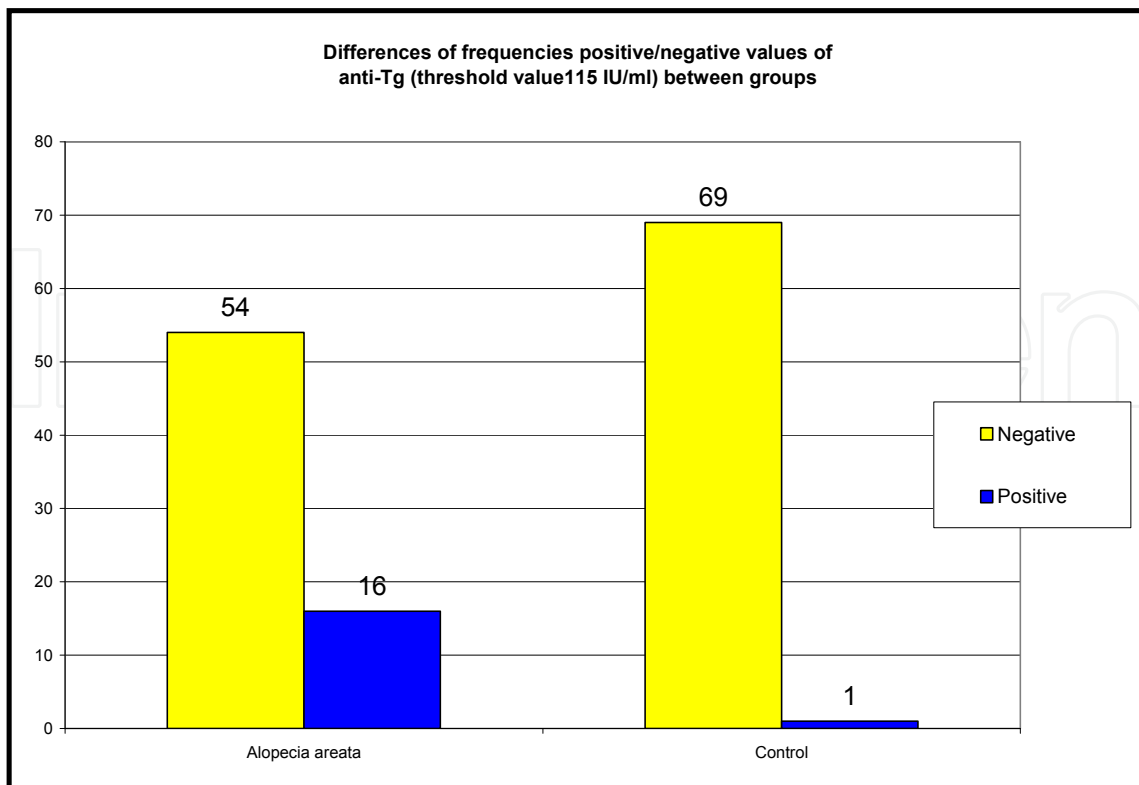
Table 1. Demographic data of patients (Alopecia areata group) and volunteers (Control group)

Mean age of onset (SD) (year)	38.14 (14.61)
Age of onset range (year)	14-65
Mean duration (SD) (month)	21.93 (30.69)
Duration Range (month)	1-150
Type of alopecia areata n, (%)	
Unilocularis 13 (19)	
Multiloculares 37 (53)	
Universalis 8 (11)	
Totalis 12 (17)	

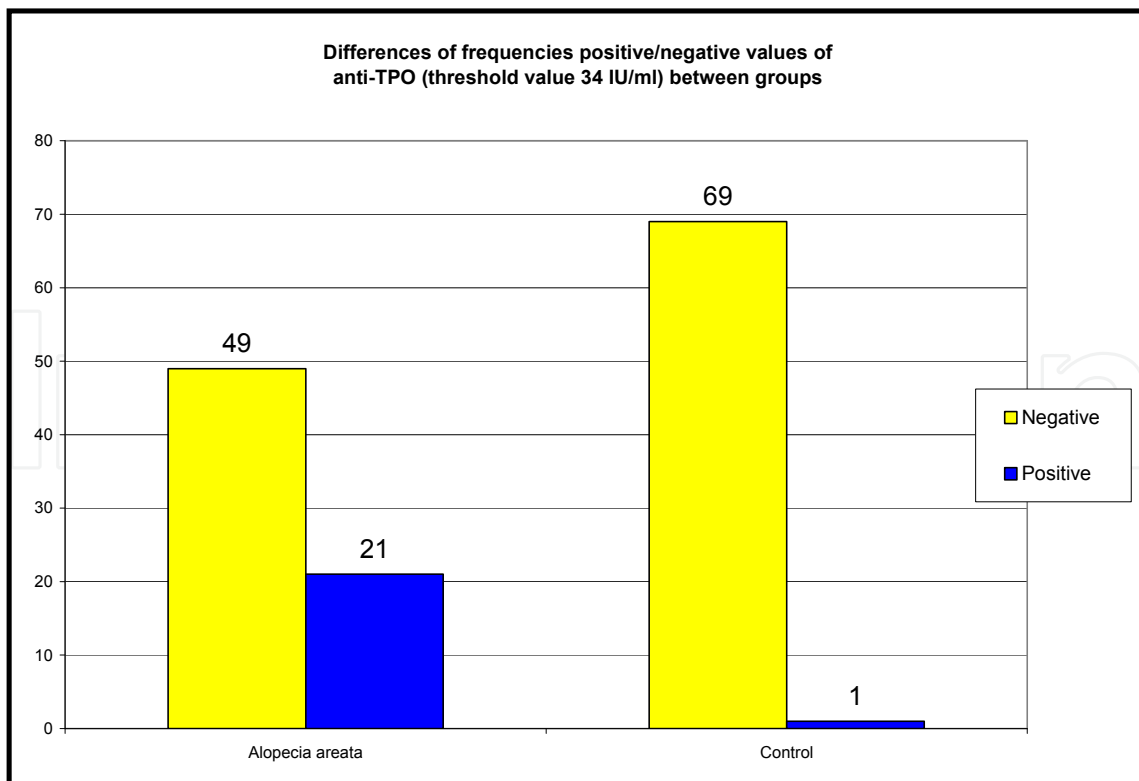
Table 2. Clinical characteristics of alopecia areata patients

	anti-Tg (threshold value 115 IU/ml)		anti-TPO (threshold value 34 IU/ml)	
Group	Negative n(%)	Positive n(%)	Negative n(%)	Positive n(%)
Alopecia areata	54 (77)	16 (23)	49 (70)	21 (30)
Control	69 (99)	1 (1)	69 (99)	1 (1)
Total	123 (88)	17 (12)	118 (84)	22 (16)
Difference n (%)	15 (22)		20 (29)	
χ^2 , P	$\chi^2=13.123$, P=0.0003		$\chi^2=19.468$, P<0.0001	

Table 3. The frequencies of positive detectable thyroid autoantibody (anti-Tg and anti-TPO)



Scheme 1. Differences of frequencies positive/negative values of anti-Tg (threshold value 115 IU/ml) between groups

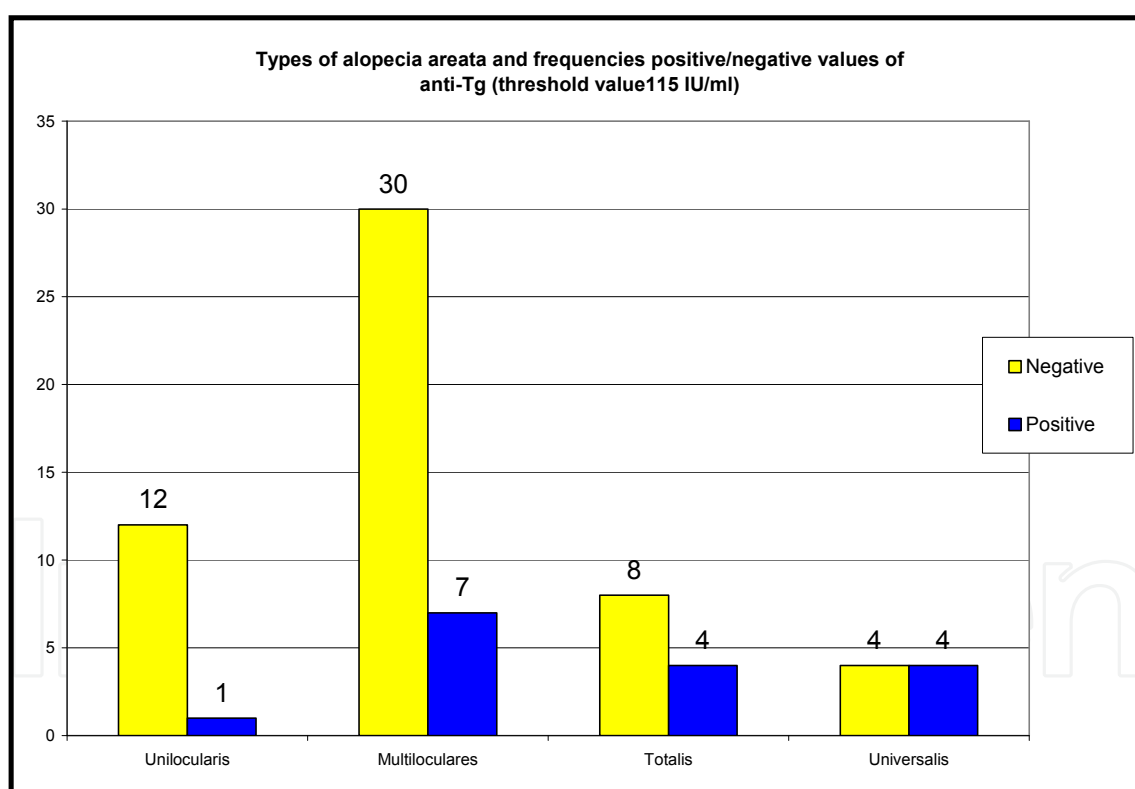


Scheme 2. Differences of frequencies positive/negative values of anti-TPO (threshold value 34 IU/ml) between groups

	anti-Tg (threshold value 115 IU/ml)			Types of alopecia areata (P)		
Type of alopecia areata	Negative n	Positive n	Total	Multiloculares	Totalis	Universalis
Unilocalis	12	1	13	0.662246	0.160248	0.047472*
Multiloculares	30	7	37	N/A	0.426673	0.085080
Totalis	8	4	12	N/A	N/A	0.647916
Universalis	4	4	8	N/A	N/A	N/A
Total	54	16	70			

Table 4. The frequencies of positive detectable thyroid autoantibody (anti-Tg) and differences between types of alopecia areata

A Fisher's exact indicated significant association between higher values of anti-Tg (values more than 115 IU/ml) and some types of alopecia areata, Universalis vs Unilocalis ($P=0.047472$) (Table 4.)

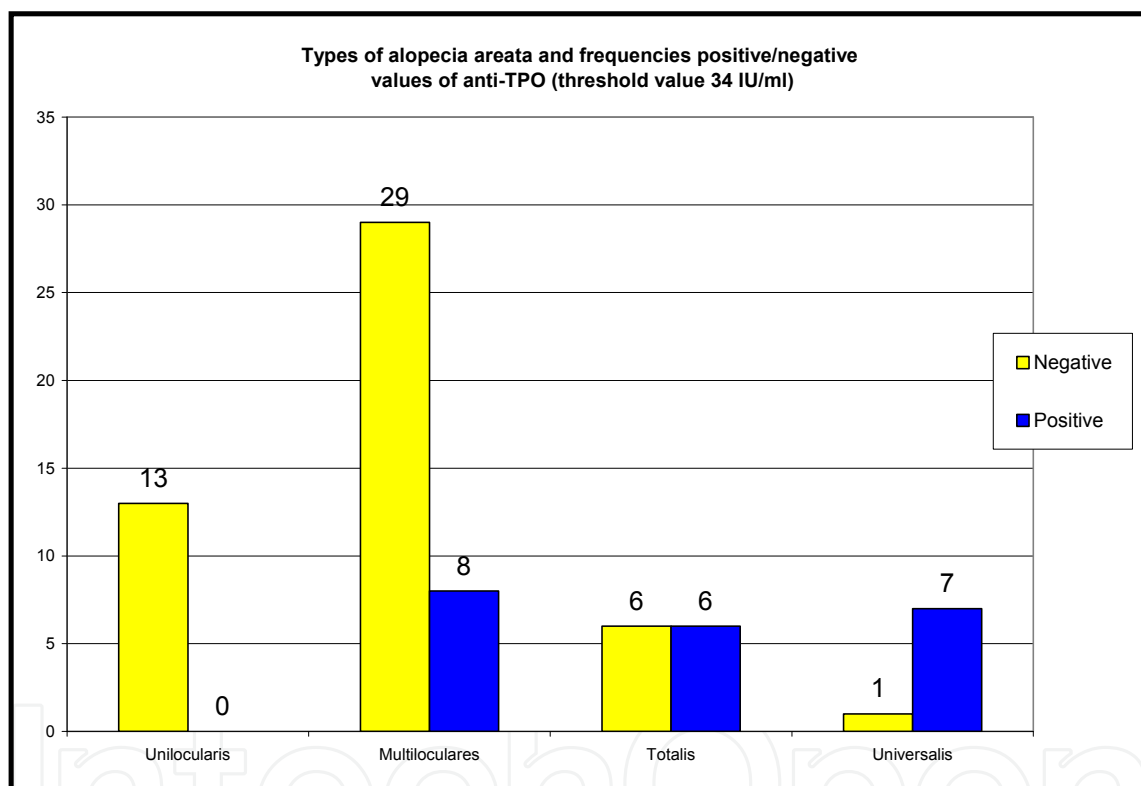


Scheme 3. Types of alopecia areata and frequencies positive/negative values of anti-Tg (threshold value 115 IU/ml)

A Fisher's exact indicated significant association between higher values of anti-TPO (values more than 34 IU/ml) and some types of alopecia areata: Unilocalis vs Totalis ($P=0.005217$), Unilocalis vs Universalis ($P=0.000069$) and Multiloculares vs Universalis ($P=0.000925$) (Table 5).

	anti-TPO (threshold value 34 IU/ml)			Types of alopecia areata (P)		
Type of alopecia areata	Negative n	Positive n	Total	Multiloculares	Totalis	Universalis
Unilocularis	13	0	13	0.092788	0.005217*	0.000069*
Multiloculares	29	8	37	N/A	0.075803	0.000925*
Totalis	6	6	12	N/A	N/A	0.157688
Universalis	1	7	8	N/A	N/A	N/A
Total	49	21	70			

Table 5. The frequencies of positive detectable thyroid autoantibody (anti-TPO) and differences between types of alopecia areata



Scheme 4. Types of alopecia areata and frequencies positive/negative values of anti-TPO (threshold value 34 IU/ml)

2.4. Discussion

Alopecia areata is an ancient disease that was known to Egyptians even in the pre-Christian time [33]. Despite its long history, our knowledge is actually limited. Today, AA is hypothesized to be an autoimmune, organ specific T-cell mediated reaction directed against an unknown autoantigen of the hair follicle. T lymphocytes that have been shown to be oligoclonal and autoreactive are predominantly present in the peribulbous inflammatory infiltrate [34]. Although the skin is the primary location of the clinical phenotype, the determination of disease expression involves a complex interplay between different

inflammatory cell subsets in the skin, skin draining lymphonodes, and spleen of the affected individuals [35].

Clinical association with AA has known for many years. AA frequently occurs in association with other autoimmune disorders such as vitiligo, lupus erythematosus, pernicious anemia and others [34, 36-38]. Among endocrine disorders, thyroid diseases are the commonest that has been described as associated with AA, but the issued values were different. In the greatest study reported till now, Muller and Winkelmann have found the evidences of different types of thyroid disease in 8% of 736 patients in compare to less than 2% of the control population in North America [39]. Broniarczyk-Dyla *et al.* observed abnormalities of thyroid structure and function in even 78% of AA patients [40]. Conversely, Puavilai *et al.* estimated that the prevalence of thyroid disease is relatively low (7.2%) and was not statistically different from the control group [41].

In accordance to previous studies, current study reported a high frequency of thyroid diseases in AA patients. We detected elevated anti-Tg in 16 (23%) and elevated anti-TPO in 21 (30%) of patients with AA. Compared with the control group, the frequency of the both anti-Tg and anti-TPO antibodies was significantly higher in those with AA. Statistically significant difference was also found in values of anti-Tg and anti-TPO between patients with different clinical type of the disease. The highest anti-Tg concentrations were observed in patients with alopecia universalis. Patients with thyroid diseases were on an average older and reported longer duration, but the results were not statistically significant. These results are consistent with a clinical study performed by Seyrafi *et al.* [32]. They analyzed serum TgAb level in 123 Iranian patients with AA and found it to be elevated in 29.3% of study patients. Grandolfo *et al.* observed the presence of thyroid autoantibodies in even 44% of AA patients [42]. Goh *et al.* also confirmed the frequent coexistence of AA and thyroid abnormalities [43]. They found 19% of probands with thyroid disease including simple goitre, Grave's disease and Hashimoto's thyroiditis. Our findings showed that the frequency of anti-TPO was more significant than anti-Tg. This antibody, historically referred to as the antimicrosomal antibody, is established as a sensitive tool for the detection of early subclinical autoimmune thyroid diseases and identification of at-risk cases for autoimmune thyroid diseases [44]. Nordyke *et al.* reported that anti-TPO antibody tends to have more correlation than does the anti-Tg antibody [45].

Alopecia areata offers many benefits as a model for the study of autoimmunity, in that it can be used to identify the contributing roles of immunogenetics and neuroendocrine factors in the initiation and propagation of autoimmune disease [24].

The study revealed a significant association between AA and thyroid disease and showed the tests used to detected thyroid autoantibodies to be relevant in patients with AA. Further exploration of this relationship in clinical setting and at a molecular level may help in the understanding of the pathogenesis of both diseases.

3. Conclusions

Thyroid autoimmunity is the most prevalent autoimmune condition in the general population, and is also associated with various skin diseases. The evidence is strong for the

association with alopecia areata. Although their etiology is still unclear, the autoimmune hypothesis is most commonly accepted.

The nature of the relationship between anti-thyroid autoimmunity and the pathogenesis of autoimmune diseases is presently unknown. Some authors have shown that anti-Tg antibodies can form immune complexes [46], and anti-microsomal antibodies not only bind to thyroid peroxidase but also modulate natural killer cell activity in autoimmune thyroiditis [47]. Possible explanations for the relationship of these autoimmune diseases include: (1) immunomodulatory effects of antithyroid antibodies, (2) molecular mimicry between thyroid and disease-specific epitopes, and (3) genetic link between anti-thyroid autoimmunity and the susceptibility to autoimmune disease [48]. It is a multidisciplinary problem requiring cooperation of specialists in different fields of medicine. Both dermatologists and endocrinologists have to inquire their patients about the family history of autoimmune diseases and to look for associated autoimmune disorders.

This chapter is an attempt to update the current knowledge about the relationship between the thyroid and the skin diseases. Although cutaneous manifestations of autoimmune thyroid diseases are well described and thyroid hormone is known to regulate the development and function of skin, a better understanding of these processes is needed.

Author details

Emina Kasumagic-Halilovic*

Department of Dermatovenereology, Sarajevo University Clinical Center, Sarajevo, Bosnia and Herzegovina

Begler Begovic

Department of Clinical Pharmacology, Sarajevo University Clinical Center, Sarajevo, Bosnia and Herzegovina

4. References

- [1] Mullin GE, Eastern JS (1986) Cutaneous signs of thyroid disease. *Am Fam Physican.* 34: 93-98.
- [2] Mullin GE, Eastern JS (1986) Cutaneous consequences of accelerated thyroid function. *Cutis.* 37: 109-114.
- [3] Safer JD, Crawford TM, Fraser LM, Hoa M, Ray S, Chen TC et al. (2003) Thyroid hormone action on skin: Diverging effects of topical versus intraperitoneal administration. *Thyroid.* 13: 159-165.
- [4] Holt PJA (1978) In vivo responses of the epidermis to triiodothyronine. *J Invest Derm.* 71: 202-204.
- [5] Leonhardt JM, Heyman WR (2002) Thyroid disease and the skin. *Dermatol Clin.* 20:473-481.

* Corresponding Author

- [6] Pazos-Moura CC, Moura EG, Breitenbach MMD et al. (1998) Nailfold capillaroscopy in hypothyroidism: blood flow velocity during rest and postocclusive reactive hyperemia. *Angiology*. 49: 471
- [7] Silva JE (2003) The termogenic effect of thyroid hormone and its clinical implications. *Annals of Internal Medicine*. 139: 205-213.
- [8] Christianson HB (1976) Cutaneous manifestations of hypothyroidism including purpura and ecchymoses. *Cutis*. 17: 45.
- [9] Safer JD (2011) Thyroid hormone action on skin. *Dermato Endocrinology* 3: 211-215.
- [10] Freinkel RK (1993) Cutaneous manifestations of endocrine disease. In: Fitzpatrick TB, Eisen AZ, Wolff K, Freedberg IM, Austen KF, editors. *Dermatology in general medicine*. McGraw-Hill, Inc. pp 2113-2131.
- [11] Hanley K, Devaskar UP, Hicks SJ et al. (1997) Hypothyroidism delays fetal stratum corneum development in mice. *Pediatr Res*. 42: 610.
- [12] Dekio S, Imaoka C, Jidoi J (1987) Candida folliculitis associated with hypothyroidism. *Br J Dermatol*. 117: 663.
- [13] Schell H, Kiesewetter F, Seidel C et al. (1991) Cell cycle kinetics of human anagen scalp hair bulbs in thyroid disorders determined by DNA flow cytometry. *Dermatologica*. 182: 23-26.
- [14] Ahsan MK, Urano J, Kato S, Oura H, Arase S (1998) Immunohistochemical localization of thyroid hormone nuclear receptors in human hair follicles and in vitro effect of L-triiodothyronine on cultured cells of hair follicles and skin. *J Med Invest*. 44: 179-184.
- [15] Westgate GE, Messenger AG, Watson LP, et al. (1991) Distribution of proteoglycans during the hair growth cycle in human skin. *J Invest Dermatol*. 96: 191.
- [16] Diven DG, Gwinup G, Newton RC (1989) The thyroid. *Dermatol Clin*. 7: 547-557.
- [17] Ai J, Leonhardt JM, Heymann WR (2003) Autoimmune thyroid diseases: etiology, pathogenesis, and dermatologic manifestations. *J Am Acad Dermatol*. 48: 641-659.
- [18] Wortsman J, Dietrich J, Traycoff RB, Stone S (1981) Preradial myxedema in thyroid disease. *Arch Dermatol*. 117: 635-638.
- [19] Bierewaltes WH, Bollet AJ (1959) Mucopolysaccharide content of skin in patients with pretibial myxedema. *J Clin Invest*. 38: 945
- [20] Weetman AP (2001) Determinants of autoimmune thyroid disease. *Nat Immunol*. 2: 769-770.
- [21] Billoni N, Buan B, Gautier B, Gaillard O, Mahe YF, Bernhard BA (2000) Thyroid hormone receptor beta-1 is expressed in the human hair follicle. *Br J Dermatol*. 142: 645-652.
- [22] Messenger AG (2000) Thyroid hormone and hair growth. *Br J Dermatol*. 142: 631-635.
- [23] Burman KD, McKinley-Grant L (2006) Dermatologic aspects of thyroid disease. *Clin Dermatol*. 24: 247-255.
- [24] Gilhar A, Paus R, Kalish R (2007) Lymphocytes, neuropeptides, and genes involved in alopecia areata. *J Clin Invest*. 117: 2019-27.
- [25] Alexis AF, Dudda-Subramanya R, Sinha AA (2004) Alopecia areata: autoimmune basis of hair loss. *Eur J Dermatol*. 14(6): 364-70.

- [26] Milgraum SS, Mitchell AJ, Bacon GE, Rasmusen JE (1987) Alopecia areata, endocrine function, and antibodies in patients 16 years of age or younger. *J Am Acad Dermatol.* 17: 57-61.
- [27] McDonagh AJG, Messenger AG (1996) The pathogenesis of alopecia areata. *Dermatol Clin.* 14: 661-70.
- [28] Tobin DJ, Orentreich N, Fenton DA, Bystrin JC (1994) Antibodies to hair follicles in alopecia areata. *J Invest Dermatol.* 102: 721-4.
- [29] Lewinski A, Broniarczyk-Dyla G, Sewerynek E, Zerek-Melen G, Szkudlinski M (1990) Abnormalities in structure and function of thyroid gland in patients with alopecia areata. *J Am Acad Dermatol.* 23: 768-9.
- [30] Kasumagic-Halilovic E (2008) Thyroid autoimmunity in alopecia areata. *Acta dermatovenerol Croat.* 16(3): 123-25.
- [31] Kurtev A, Ilev E (2005) Thyroid autoimmunity in children and adolescents with alopecia areata. *Int J Dermatol.* 44: 457-61.
- [32] Seyrafi H, Akhiani M, Abbasi H, Mirpour S, Gholamrezanezhad A (2005) Evaluation of the profile of alopecia areata and the prevalence of thyroid function test abnormalities and serum autoantibodies in Iranian patients. *BMC Dermatol.* 5: 11-6.
- [33] Ebel B (1937) *The papyrus Ebers: The greatest Egyptian document.* Copenhagen: Levin and Munksgaard.
- [34] Hordinsky M, Ericson M (2004) Autoimmunity: Alopecia areata. *J Invest Dermatol Symp Proc.* 9: 73-8.
- [35] McElwee KJ, Hoffman R, Freyschmidt-Paul P, Wenzel E, Kissling S, Sundberg JP (2002) Resistance to alopecia areata in C3H/HeJ mice is associated with increased expression of regulatory cytokines and failure recruit CD4⁺ and CD8⁺ cells. *J Invest Dermatol.* 119: 1426-33.
- [36] Gopal KV, Rama Rao GR, Kumar YH, Appa Rao MV, Vasudev P, Strikant (2007) Vitiligo: A part of a systemic autoimmune process. *Indian J Dermatol Venereol Leprol.* 73(3): 162-65.
- [37] Werth VP, White WL, Sauchez MR, Franks AG (1992) Incidence of alopecia areata in lupus erythematosus. *Arch Dermatol.* 128(3): 368-71.
- [38] Madani S, Shapiro J (2000) Alopecia areata update. *J Am Acad Dermatol.* 549-66.
- [39] Muller SA, Winkelmann RK (1963) Alopecia areata. *Arch Dermatol.* 88: 290-97.
- [40] Broniarczyk-Dyla G, Lewinski A, Zerek-Melen G, Sewerynek E, Wozniacka A (1989) Abnormalities of structure and function of the thyroid in patients with alopecia areata *Przegl Dermatol.* 76: 416-21.
- [41] Puavilai S, Puavilai G, Charuwichitratana S, Sakuntabhai A, Sriprachya-Anunt S. Prevalence of thyroid diseases in patients with alopecia areata. *Int J Dermatol* 1994; 33(9): 632-3.
- [42] Gandoldolfo M, Biscazzi AM, Pipoli M (2008) Alopecia areata and autoimmunity. *G Ital Dermatol Venereol.* 143(5): 277-81.
- [43] Goh C, Finkel M, Christos PJ, Sinha AA (2006) Profile of 513 patients with alopecia areata: association of disease subtypes with atopy, autoimmune disease and positive family history. *J Eur Acad Dermatol Venereol.* 20: 1055-60.

- [44] Kemp EH (2004) Autoantibodies as diagnostic and predictive markers of vitiligo. *Autoimmunity*. 37:287-90.
- [45] Nordyke RA, Gilbert FI Jr, Miyamoto LA, Fleury KA (1993) The superiority of antimicrosomal over antithyreoglobulin antibodies for detecting Hashimoto's thyroiditis. *Arch Intern Med*. 153(7): 862-65.
- [46] Dawe K, Hutchings P, Champion B, Cook A, Roitt I (1993) Autoantigens in thyroid diseases. *Springer Semin Immunopathol*. 14: 285-307.
- [47] Robert DU (1991) The pathogenesis of autoimmune thyroiditis. *N Engl J Med*. 324: 278-279.
- [48] Szyper-Kravitz M, Marai I, Shoenfeld Y (2005) Coexistence of thyroid autoimmunity with other autoimmune diseases: friend or foe? Additional aspects on the mosaic of autoimmunity. *Autoimmunity*. 38: 247-255.