

We are IntechOpen, the world's leading publisher of Open Access books Built by scientists, for scientists

6,900

Open access books available

185,000

International authors and editors

200M

Downloads

Our authors are among the

154

Countries delivered to

TOP 1%

most cited scientists

12.2%

Contributors from top 500 universities



WEB OF SCIENCE™

Selection of our books indexed in the Book Citation Index
in Web of Science™ Core Collection (BKCI)

Interested in publishing with us?
Contact book.department@intechopen.com

Numbers displayed above are based on latest data collected.
For more information visit www.intechopen.com



Management of Early Gastric Cancer

Takehiro Okabayashi and Yasuo Shima

Additional information is available at the end of the chapter

<http://dx.doi.org/10.5772/50781>

1. Introduction

Gastric carcinoma is the second most common malignancy worldwide and surgical treatment remains the only curative management option. Early gastric carcinoma (EGC) is defined as a lesion of the stomach confined to the mucosa and/or submucosa, regardless of the lymph node metastatic status. The incidence of EGC has gradually increased with advances in diagnostic techniques and equipment [1-3]. In the West, EGC accounts for 4 - 16% of all gastric carcinoma cases [4,5], whereas the proportion of EGC in Japan is approximately 30 - 50% [4-6].

The presence of a lymph node metastasis is one of the most important prognostic indicators for EGC. Lymph node metastases occur during the early stage of gastric carcinoma, and regional lymphadenectomy is the recommended surgical treatment of this disease. Excellent curative outcomes for patients with EGC have been obtained with regional lymphadenectomy [4,7].

In this article, the basic concept of EGC is revisited and recent published articles on both new diagnostic and treatment modalities are reviewed.

2. Classification of EGC

2.1. Macroscopic classification

The Japanese “gastric cancer” classification groups all gastric cancers into types 1 to 4 according to their morphological appearance [8]. EGC has been added as type 0, which is subdivided according to the macroscopic appearance of the lesion: 0-I, protruded or polypoid; 0-II, superficial; 0-III, excavated lesion characterized by a deep ulcer-like excavation that can resemble benign ulceration. Type 0-II lesions are most prevalent and are further subdivided into IIa (elevated), IIb (superficial spread), and IIc (depressed).

2.2. Microscopic classification

There has been considerable controversy between Japanese and Western pathologists regarding the histological reporting of mucosal lesions. Some observers have suggested that the reported incidence of EGC in Japan could be attributed to the over-diagnosis of dysplastic lesions as invasive cancer. Japanese pathologists often use the term, gastric cancer, whereas western pathologists use the term, dysplasia. Western pathologists require evidence of cellular invasion into the lamina propria before they consider that the basement membrane has been breached and can make a diagnosis of invasive cancer. Japanese pathologists have traditionally relied on nuclear features such as enlargement, pleomorphism, prominent nucleoli, and loss of polarity along with glandular architectural cancer diagnosis.

In 1965, Lauren described two histological subtypes of gastric cancer: intestinal and diffuse [9]. Since that time the Lauren classification scheme has been used worldwide. The intestinal-type gastric cancer consists of a cohesive group of neoplastic cells that form distinct well-defined tubular structures. In contrast, cell cohesion is lost in diffuse-type gastric cancer and individual cells infiltrate the gastric wall without a glandular structure. This description closely resembles the Japanese classification of differentiated (papillary, well-differentiated adenocarcinoma or moderately-differentiated adenocarcinoma) and undifferentiated types (poorly-differentiated adenocarcinoma, signet ring cell carcinoma, mucinous carcinoma).

3. Diagnostic challenges for early gastric cancer

Double contrast barium meal studies have been employed for more than 40 years in Japan, but endoscopy shows higher sensitivity in EGC detection.

3.1. Indigo carmine chromoendoscopy

To achieve a successful outcome, it is very important to accurately determine the lateral extent of a tumor. Traditionally, this has been done with conventional endoscopy and chromoendoscopy using indigo carmine dye [3]. However, it is sometimes difficult to identify the margins of the tumors, especially those of superficial or flat-type tumors. Chromoendoscopy with indigo carmine dye added to acetic acid (AI chromoendoscopy) has been recently reported to improve the diagnostic yield by aiding the recognition of the tumor borders in patients with EGC [10].

Chromoendoscopy of a differentiated adenocarcinoma is shown in Fig. 1. A combined flat and elevated lesion with an unclear border is located at the middle of the stomach (Fig. 1a). The borders of the lesion becomes distinct with high image clarity in an endoscopic view after indigo carmine was sprinkled onto the lesion (Fig. 1b). The lesion was resected by endoscopic submucosal dissection (ESD) and was shown to be a differentiated adenocarcinoma.

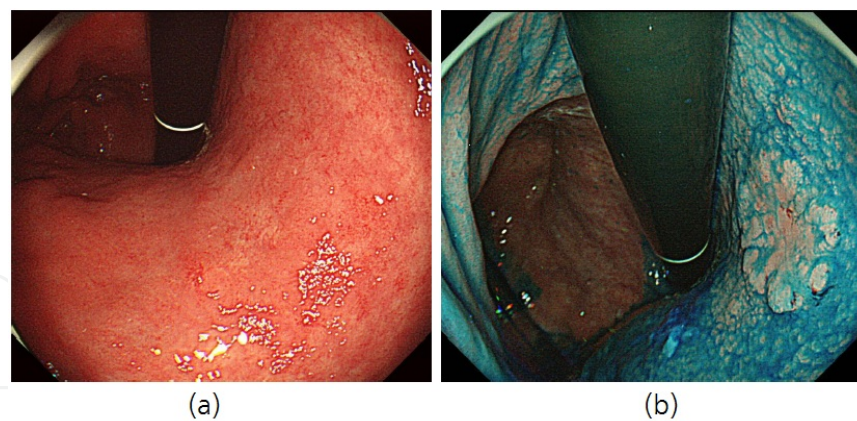


Figure 1. Chromoendoscopic imaging. (a) A combined flat and elevated lesion with an unclear border at the middle of the stomach is shown. (b) Endoscopic view of the lesion after indigo carmine was sprinkled onto it. The borders of the lesion became distinct with high clarity images after chromoendoscopy with indigo carmine dye.

3.2. Magnifying narrow-band imaging endoscopy

The survival rate for patients who were treated for EGC is excellent, but the prognosis for advanced gastric cancer is very poor. Therefore, an early diagnosis of gastric cancer is very important but diagnosis is difficult because most patients with EGC do not have specific symptoms and it is difficult to distinguish EGC from a benign peptic ulcer or gastritis. Technological developments have enabled novel endoscopic imaging modalities such as magnifying narrow-band imaging (NBI) endoscopy to be used recently for the diagnosis of early gastric cancer [11,12].

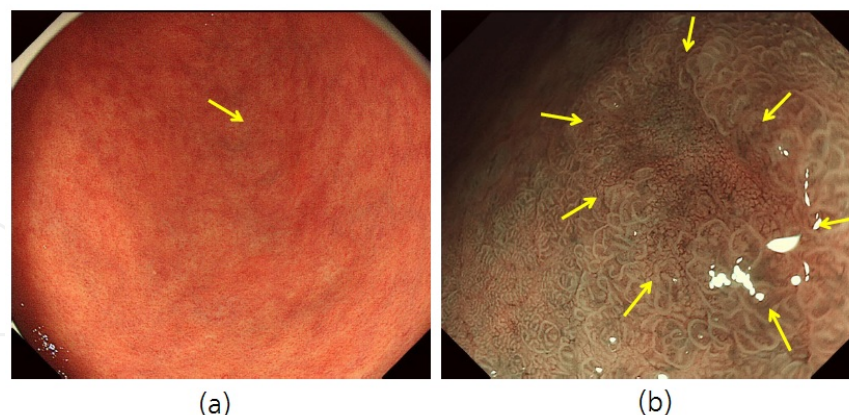


Figure 2. Magnifying endoscopy with narrow-band imaging findings. (a) Conventional endoscopy with white light imaging demonstrates that this lesion (arrow) should be classified as a pale lesion rather than a red-colored lesion. (b) Magnifying endoscopy with narrow-band imaging findings (arrows) showed that this lesion should be diagnosed as cancer by the presence of an irregular microvascular pattern plus an irregular microsurface pattern using the vessel plus surface classification system.

A representative case of EGC is shown in Fig. 2. Conventional endoscopy with white light imaging demonstrated that this lesion (arrow) should be classified as a pale lesion rather

than a red-colored lesion (Fig. 2a). Magnifying endoscopy with narrow-band imaging was used to diagnose the lesion as cancerous. The vessel plus surface classification system was used to identify features including the presence of an irregular microvascular pattern together with an irregular microsurface pattern (Fig. 2b). The histopathological diagnosis of the resected specimen was EGC.

4. Management of early gastric cancer

4.1. Endoscopic mucosal resection (EMR)

EMR has been used as the standard treatment of EGC because there is no risk of lymph node metastasis, and it is a minimally invasive, safe, convenient, and efficacious procedure. In order for EMR to be considered potentially curative, there are two important conditions that should be met: complete en-bloc removal with a clear margin around the primary tumor, and zero or extremely low possibility of lymph node metastasis. The Japanese Gastric Cancer Association has proposed the following indications for curative EMR: (a) invasion is clinically confined to the mucosa, (b) tumor size of 2 cm or smaller, (c) histologically differentiated type, (d) no ulcer or ulcer scar in the lesion [13]. A tumor that satisfies all of these indications can be safely removed by EMR but if the tumor depth is histologically diagnosed as mucosal, then lymph node metastasis should be absent.

Endoscopic submucosal dissection (ESD) is a newly developed technique in the field of endoscopic treatments for EGC in Japan. This technique uses specialized devices, including an insulation-tipped diathermy knife (IT knife), to dissect directly along the submucosal layer. Although the drawbacks of ESD include its technical difficulty and a higher risk of procedure-related complications, it has replaced EMR in Japan, and it has been introduced in Korea and Europe. Large numbers of ESD procedures are promising with high rates of both en-bloc resection and curative resection. The risk factors associated with the resectability and curability of ESD have been recently reported [14].

EGCs without any lymph node metastasis were treated with ESD using an IT knife (Fig. 3a). Briefly, the markings along the presumed cutting line were first defined relative to the normal mucosa that surrounded the lesion. This was performed with a standard needle knife at least 5 mm away from the tumor (Fig. 3b). An epinephrine solution (0.025 mg/mL in saline solution) was injected into the submucosa along the presumed cutting line and a standard needle-knife was used to make a pre-cut outside the indicated area. The IT knife was inserted into the incision, and an electrosurgical current was applied by a standard electrosurgical generator to complete the incision around the lesion (Fig. 3c). After the circumferential cut was completed, a solution of epinephrine was injected into the submucosa below the lesion when needed. The IT knife was then used to dissect the submucosa. If the tissue did not lift during or after injection, the IT knife or the standard needle-knife was used to carefully dissect the tissue along the plane of the submucosa (Fig. 3d).

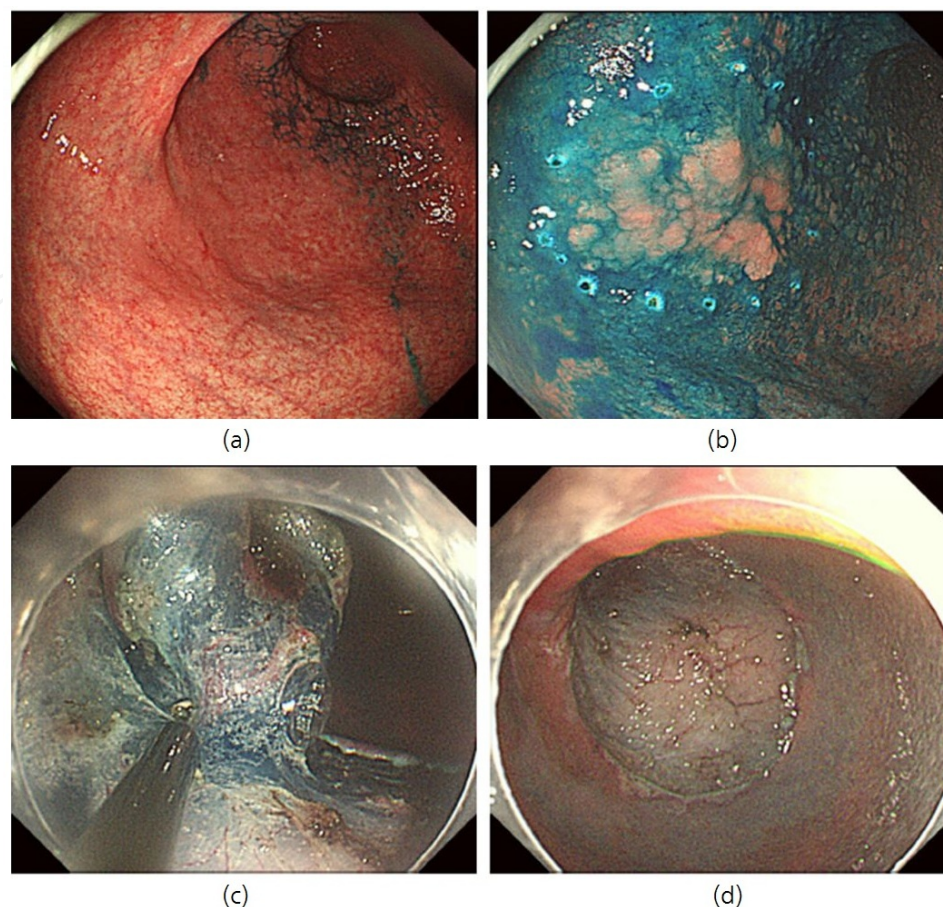


Figure 3. ESD technique. (a) EGCs that were diagnosed with no lymph node metastasis were treated with ESD with an IT knife. (b) Electrocautery marking surrounding the target lesion. (c) Submucosal injection of diluted epinephrine with indigo carmine, and circumferential cutting around the lesion. (d) Completion of resection. ESD was performed by an experienced gastrointestinal endoscopist (Dr. Hajime Yamaoka at Kochi Medical School, JAPAN).

4.2. Gastric surgery

Subtotal or total gastrectomy with regional lymphadenectomy is the standard treatment for resectable gastric cancer in Japan and Korea as well as high-volume centers in other countries. Less invasive gastrectomy with limited lymphadenectomy, such as pylorus-preserving gastrectomy and proximal gastrectomy, has been proposed for EGC that has a low possibility of nodal metastasis and a high probability of cure [15].

A typical gastrectomy with regional lymphadenectomy is shown in Fig. 4. After division of the left gastric artery, the lymphatic and connective tissue was removed from the surface of diaphragmatic crus that covers the aorta and the posterior aspect of the esophageal hiatus was exposed (Fig. 4a). Immediate inspection of the resected stomach revealed a tumor of the distal stomach, and the lymphadenectomy of supramesenteric vein was performed (Fig. 4b).

Laparoscopic-assisted gastrectomy (LAG) has been used to treat EGC, which requires less extensive lymph node dissection. The use of LAG for EGC was first reported in 1994 [16] and many studies have since reported on the benefits of the technique, which include reduced

blood loss, decreased pain, early recovery of bowel movements, and a short hospital stay [17]. Other studies have focused on its oncologic equivalency to open gastrectomy but the technique does involve a steep surgical learning curve [18]. Recently, the indication for LAG in some high-volume centers has been extended to include advanced gastric cancer [19].

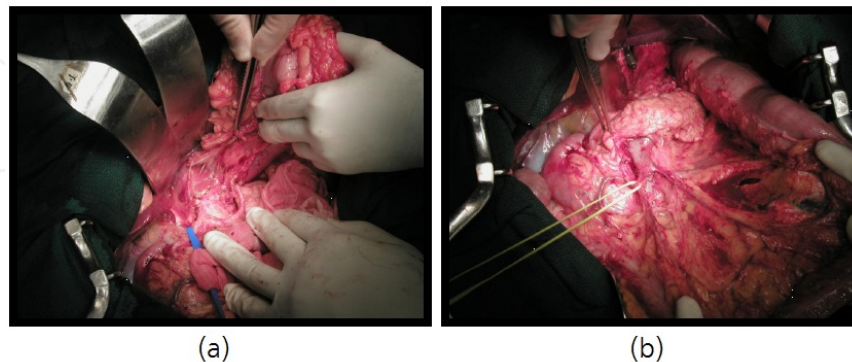


Figure 4. Standard gastrectomy. (a) The lymphatic and connective tissue was removed from the surface of diaphragmatic crus that covers the aorta after division of the left gastric artery. The posterior aspect of the esophageal hiatus was exposed. (b) Immediate inspection of the resected stomach revealed a tumor of the distal stomach, and the lymphadenectomy of supramesenteric vein was added. Total gastrectomy was performed by Dr. Takeshi Sano (Cancer Institute Hospital, JAPAN).

4.3. Reconstruction after gastric resection

Various reconstructive procedures have been proposed for patients undergoing distal gastrectomy for gastric cancer. In general, Billroth I (BI) reconstruction is the most common technique used clinically because it involves relatively simple reconstruction. However, bile reflux resulting in remnant gastritis and gastroesophageal reflux disease (GERD) has been noted as a problem associated with BI reconstruction after distal gastrectomy. Some studies have indicated that Roux-en-Y (RY) reconstruction following distal gastrectomy is superior to BI reconstruction in preventing remnant gastritis and reflux esophagitis because it reduces duodenogastric and gastroesophageal reflux [20]. The disadvantages of RY reconstruction include the possible development of stomal ulcers, increased probability of cholelithiasis, increased difficulty with an endoscopic approach to the papilla of Vater, and the possibility of Roux stasis syndrome. Furthermore, the RY reconstruction technique has a different route of reconstruction whereby all food passes through the jejunum and bypasses the duodenum, which causes one of the disadvantages of this procedure. An additional problem caused by RY reconstruction is the considerable difficulty with endoscopic access to the papilla of Vater for the diagnosis or treatment of pancreatobiliary disorders that may develop after the distal gastrectomy. Recently, double tract reconstruction (DT) after either total or subtotal gastrectomy have been introduced to remove the disadvantage of RY reconstruction [21]. DT reconstruction is as simple as RY reconstruction and can be performed safely after distal gastrectomy with regional lymphadenectomy. The advantages of DT reconstruction following both total and distal gastrectomy include maintaining the physiological passage of food and allowing future diagnostic and therapeutic endoscopic interventions

to be safely performed. The technique chosen for surgical reconstruction of the gastrointestinal tract to perform gastrojejunostomy should take potential future endoscopic requirements into account (Fig. 5).

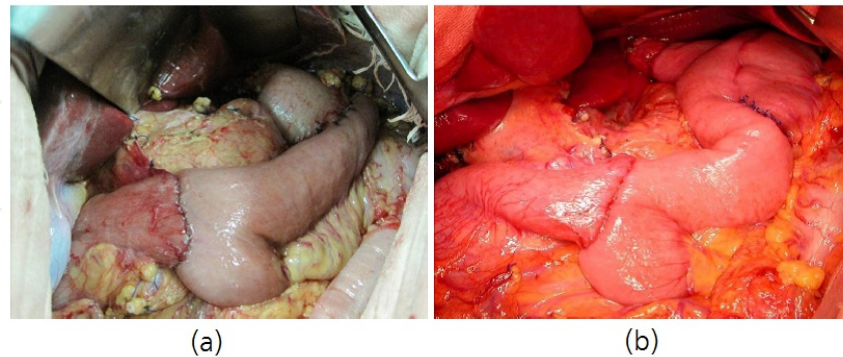


Figure 5. Double tract reconstruction after gastrectomy. (a) Double tract reconstruction (DT) after subtotal gastrectomy. (b) DT after total gastrectomy. Gastrectomy was performed by Dr. Tsutomu Namikawa and Dr. Michiya Kobayashi (Kochi Medical School, JAPAN).

5. Prognosis of EGC

The incidence of lymph node metastasis has been reported to be 5.7 - 20% and it is one of the most important factors in determining the prognosis of patients with EGC [22-24]. Excellent curative treatment for patients with EGC has been obtained with regional lymphadenectomy [25]. Less invasive treatments, including EMR and ESD, have been performed recently for EGC and these options should be considered when deciding on a treatment method [26-29].

Experienced endoscopists are able to accurately evaluate the extent of lesions in gastric carcinoma and therefore, less invasive treatments such as EMR or ESD, may become possible for EGC with tumors less than 2 cm in diameter [30]. Use of the endoscopic scale for measuring the size of the EGC and endoscopic ultrasonography can be effective because the exact tumor diameter is not always easy to determine endoscopically. The use of EMR and/or ESD has become a reasonable and convenient diagnostic and treatment modality, because histological information about the whole tumor can be obtained. Furthermore, a curative treatment is achieved in the case of localized tumors without lymph node metastasis, which preserves the whole stomach. In recent years, the use of EMR and/or ESD has become safe and effective curative treatment option with feasible clinical outcomes in patients with EGC. As a result, the use of EMR and/or ESD has ensured an excellent prognosis, and should be the first choice of treatment in patients with EGC, although careful histological examination and long-term endoscopic surveillance remain important. When lymphatic permeation or vascular invasion is recognized in post-resection specimens, additional surgical resection of the stomach with lymphadenectomy is recommended [31,32]. Further prospective studies are warranted to evaluate the efficacy of this therapeutic strategy.

6. Conclusion

EGC is a curable disease in many cases, and a variety of less invasive, function-preserving treatments have been proposed. The use of EMR and/or ESD has ensured an excellent prognosis for patients who were suffering from EGC with no lymph node metastasis. Lymph node metastasis was one of the most important factors in determining the prognosis of patients with EGC. Therefore, when lymphatic permeation or vascular invasion is recognized in post-resection specimens of either EMR or ESD, additional surgical resection of the stomach with lymphadenectomy is recommended.

Author details

Takehiro Okabayashi* and Yasuo Shima

*Address all correspondence to: tokabaya@kochi-u.ac.jp

Department of Surgery, Kochi Health Sciences Center, Japan

References

- [1] Huguier, M., Ferro, L., & Barrier, A. (2002). Early gastric carcinoma: spread and multicentricity. . *Gastric Cancer* , 5, 125-128.
- [2] Seto, Y., Shimoyama, S., Kitayama, J., Mafune, K., Kaminishi, M., Aikou, T., Arai, K., Ohta, K., Nashimoto, A., Honda, I., Yamagishi, H., & Yamamura, Y. (2001). Lymph node metastasis and preoperative diagnosis of depth of invasion in early gastric cancer. *Gastric Cancer*, 4, 34-38.
- [3] Okabayashi, T., Gotoda, T., Kondo, H., Ono, H., Oda, I., Fujishiro, M., & Yachida, S. (2000). Usefulness of indigo carmine chromoendoscopy and endoscopic clipping for accurate preoperative assessment of proximal gastric cancer. *Endoscopy*, 32, S62.
- [4] Piso, P., Werner, U., Benten, D., Bektas, H., Meuer, U., & Klempnauer, J. (2001). Early gastric cancer- excellent prognosis after curative resection in 87 patients irrespective of submucosal infiltration, lymph-node metastases or tumor size. *Langenbecks Arch Surg.*, 386, 26-30.
- [5] Borie, F., Millat, B., Fingerhut, A., Hay, J. M., Fagniez, P. L., & De Saxce, B. (2000). Lymphatic involvement in early gastric cancer. *Arch Surg.*, 135, 1218-1223.
- [6] Folli, S., Morgagni, P., Roviello, F., De Manzoni, G., Marrelli, D., Saragoni, L., Di Leo, A., Gaudio, M., Nanni, O., Carli, A., Cordiano, C., Dell'Amore, D., & Vio, A. (2001). Risk factors for lymph node metastases and their prognostic significance in early gas-

tric cancer (EGC) for the Italian Research Group for Gastric Cancer (IRGGC). *Jpn J Clin Oncol.*, 31, 495-499.

- [7] Popiela, T., Kulig, J., Kolodziejczyk, P., & Sierzega, M. (2002). Long-term results of surgery for early gastric cancer. *Br J Surg.*, 89, 1035-1042.
- [8] Japanese classification of gastric carcinoma-2nd English edition Gastric Cancer. (1998)., 1, 10-24.
- [9] Lauren, P. (1965). The two histological main types of gastric carcinoma. *Acta Pathol Microbiol Scand.*, 64, 31-49.
- [10] Zhang, J., Guo, S. B., & Duan, Z. J. (2011). Application of magnifying narrow-band imaging endoscopy for diagnosis of early gastric cancer and precancerous lesion. *BMC Gastroenterol.*, 11, 135.
- [11] Maki, S., Yao, K., Nagahama, T., Beppu, T., Hisabe, T., Takaki, Y., Hirai, F., Matsui, T., Tanabe, H., & Iwashita, A. (2012). Magnifying endoscopy with narrow-band imaging is useful in the differential diagnosis between low-grade adenoma and early cancer of superficial elevated gastric lesions. *Gastric Cancer (in press)*.
- [12] Nagahama, T., Yao, K., Maki, S., Yasaka, M., Takaki, Y., Matsui, T., Tanabe, H., Iwashita, A., & Ota, A. (2011). Usefulness of magnifying endoscopy with narrow-band imaging for determining the horizontal extent of early gastric cancer when there is an unclear margin by chromoendoscopy (with video). *Gastrointest Endosc.*, 74, 1259-1267.
- [13] Nakajima, T. (2002). Gastric cancer treatment guidelines in Japan. *Gastric Cancer*, 5, 1-5.
- [14] Hirasawa, K., Kokawa, A., Oka, H., Yahara, S., Sasaki, T., Nozawa, A., Morimoto, M., Numata, K., Taguri, M., Morita, S., Maeda, S., & Tanaka, K. (2011). Risk assessment chart for curability of early gastric cancer with endoscopic submucosal dissection. *Gastrointest Endosc.*, 74, 1268-1275.
- [15] Sano, T., & Hollowood, A. (2006). Early gastric cancer: diagnosis and less invasive treatments. *Scand J Surg.*, 95, 249-255.
- [16] Kitano, S., Iso, Y., Moriyama, M., & Sugimachi, K. (1994). Laparoscopy-assisted Billroth I gastrectomy. *Surg Laparosc Endosc.*, 4, 146-148.
- [17] Lee, J. H., Han, H. S., & Lee, J. H. (2005). A prospective randomized study comparing open vs laparoscopy-assisted distal gastrectomy in early gastric cancer: early results. *Surg Endosc.*, 19, 168-173.
- [18] Kunisaki, C., Makino, H., Yamamoto, N., Sato, T., Oshima, T., Nagano, Y., Fujii, S., Akiyama, H., Otsuka, Y., Ono, H. A., Kosaka, T., Takagawa, R., & Shimada, H. (2008). Learning curve for laparoscopy-assisted distal gastrectomy with regional lymph node dissection for early gastric cancer. *Surg Laparosc Endosc Percutan Tech.*, 18, 236-241.

- [19] Kunisaki, C., Makino, H., Kosaka, T., Oshima, T., Fujii, S., Takagawa, R., Kimura, J., Ono, H. A., Akiyama, H., Taguri, M., Morita, S., & Endo, I. (2012). Surgical outcomes of laparoscopy-assisted gastrectomy versus open gastrectomy for gastric cancer: a case-control study. *Surg Endosc.*, 26, 804-810.
- [20] Namikawa, T., Kitagawa, H., Okabayashi, T., Sugimoto, T., Kobayashi, M., & Hana-zaki, K. (2010). Roux-en-Y reconstruction is superior to billroth I reconstruction in reducing reflux esophagitis after distal gastrectomy: special relationship with the angle of his. *World J Surg.*, 34, 1022-1027.
- [21] Namikawa, T., Kitagawa, H., Okabayashi, T., Sugimoto, T., Kobayashi, M., & Hana-zaki, K. (2011). Double tract reconstruction after distal gastrectomy for gastric cancer is effective in reducing reflux esophagitis and remnant gastritis with duodenal pas-sage preservation. *Langenbecks Arch Surg.*, 396, 769-776.
- [22] Wu, C. Y., Chen, J. T., Chen, G. H., & Yeh, H. Z. (2002). Lymph node metastasis in early gastric cancer: clinicopathological analysis. *Hepato-gastroenterology*, 49, 1465-1468.
- [23] Arai, K., Iwasaki, Y., & Takahashi, T. (2002). Clinicopathological analysis of early gastric cancer with solitary lymph node metastasis. *Br J Surg.*, 89, 1435-1437.
- [24] Choi, H. J., Kim, Y. H., Kim, S. S., & Hong, S. H. (2002). Occurrence and prognostic implications of micrometastases in lymph nodes from patients with submucosal gas-tric carcinoma. *Ann Surg Oncol.*, 9, 13-9.
- [25] Okabayashi, T., Gotoda, T., Kondo, H., Inui, T., Ono, H., Saito, D., Yoshida, S., Sasa-ko, M., & Shimoda, T. (2000). Early carcinoma of the gastric cardia in Japan: is it dif-ferent from that in the West? *Cancer*, 89, 2555-2559.
- [26] Tsujitani, S., Oka, S., Saito, H., Kondo, A., Ikeguchi, M., Maeta, M., et al. (1999). Less invasive surgery for early gastric cancer based on the low probability of lymph node metastasis. *Surgery*, 125, 148-154.
- [27] Kunisaki, C., Shimada, H., Nomura, M., & Akiyama, H. (2001). Appropriate lymph node dissection for early gastric cancer based on lymph node metastases. *Surgery*, 129, 153-157.
- [28] Noguchi, Y., Morinaga, S., Yamamoto, Y., & Yoshikawa, T. (2002). Is there a role for nontraditional resection of early gastric cancer? *Surg Oncol Clin N Am.*, 11, 387-403.
- [29] Yoshikawa, T., Tsuburaya, A., Kobayashi, O., Sairenji, M., Motohashi, H., & Noguchi, Y. (2002). Is D2 lymph node dissection necessary for early gastric cancer? *Ann Surg Oncol.*, 9, 401-405.
- [30] Gotoda, T., Sasako, M., Ono, H., Katai, H., Sano, T., & Shimoda, T. (2001). Evaluation of the necessity for gastrectomy with lymph node dissection for patients with sub-mucosal invasive gastric cancer. *Br J Surg.*, 88, 444-449.

- [31] Okabayashi, T., Kobayashi, M., Nishimori, I., Sugimoto, T., Namikawa, T., Onishi, S., & Hanazaki, K. (2008). Clinicopathological features and medical management of early gastric cancer. *Am J Surg.*, 195, 229-232.
- [32] Okabayashi, T., Kobayashi, M., Sugimoto, T., Okamoto, K., Hokimoto, N., & Araki, K. (2007). Clinicopathological investigation of early gastric carcinoma; is less invasive surgery right for early gastric carcinoma? *Hepatogastroenterology*, 54, 609-612.

