

We are IntechOpen, the world's leading publisher of Open Access books Built by scientists, for scientists

6,900

Open access books available

186,000

International authors and editors

200M

Downloads

Our authors are among the

154

Countries delivered to

TOP 1%

most cited scientists

12.2%

Contributors from top 500 universities



WEB OF SCIENCE™

Selection of our books indexed in the Book Citation Index
in Web of Science™ Core Collection (BKCI)

Interested in publishing with us?
Contact book.department@intechopen.com

Numbers displayed above are based on latest data collected.
For more information visit www.intechopen.com



Prenatal Diagnosis of Severe Perinatal (Lethal) Hypophosphatasia

Atsushi Watanabe, Hideo Orimo,
Toshiyuki Takeshita and Takashi Shimada

*Department of Biochemistry and Molecular Biology, Nippon Medical School
Division of Clinical Genetics, Nippon Medical School Hospital
Department of Obstetrics and Gynecology, Nippon Medical School
Japan*

1. Introduction

Hypophosphatasia (HPP) is an inherited disorder characterized by defective mineralization of the bone and low activity of alkaline phosphatase (ALP; EC 3.1.3.1) (Mornet, 2008). Screening for mutations in the *ALPL* gene allows genetic counseling and prenatal diagnosis of the disease in families with severe forms of HPP.

2. Hypophosphatasia

HPP is a clinically heterogeneous disease and classified into at least six forms according to severity and age of onset: perinatal (lethal), perinatal (benign), infantile (MIM [Mendelian Inheritance in Man] # 241500), childhood (MIM# 241510), adult (MIM# 146300), and odontohypophosphatasia (Mornet, 2008) (Table 1). All forms of HPP display reduced activity of unfractionated serum ALP and the presence of either one or two pathologic mutations in the liver/bone/kidney alkaline phosphatase gene (*ALPL*, MIM# 171760), the gene encoding ALP, the tissue-nonspecific isozyme (TNSALP). There is no curative treatment for HPP to date.

2.1 *ALPL* gene

ALPL is the only gene known to be associated with HPP. *ALPL* consists of 12 exons: 11 coding exons and one untranslated exon. More than 250 *ALPL* mutations have been described in persons from North America, Japan, and Europe (The Tissue Nonspecific Alkaline Phosphatase Gene Mutations Database). HPP is frequently caused by p.E191K and p.D378V in Caucasian, whereas p.F327L and c.1559delT are more common in Japanese (the first nucleotide (+1) corresponds to the A of the ATG initiation codon using the *ALPL* cDNA number of the standard nomenclature). This variety of mutations in *ALPL* results in highly variable clinical expression and in a great number of compound heterozygous genotypes.

2.2 Perinatal (lethal) form of hypophosphatasia

The perinatal (lethal) form of HPP (pl-HPP) is the most severe HPP with an autosomal recessive mode of inheritance (Gehring et al., 1999). In the lethal perinatal form, the patients

show markedly impaired mineralization *in utero* (Fig.1). Pregnancies may end in stillbirth. Some infants survive a few days with pulmonary complication due to hypoplastic lungs and rachitic deformities of the chest. Hypercalcemia is common and may be associated with apnea or seizures.

Type	Inheritance	MIM	Symptoms
Perinatal (lethal)	AR		Hypomineralization, osteochondral spurs
Perinatal (benign)	AR or AD		Long-bone bowing, benign postnatal course
Infantile	AR	241500	Craniosynostosis, Hypomineralization, rachitic ribs, hypercalciuria, Premature loss, deciduous teeth
Childhood	AR or AD	241510	Short stature, skeletal deformity, bone pain/fractures, Premature loss, deciduous teeth
Adult	AR or AD	146300	Stress fractures: metatarsal, tibia; chondrocalcinosis
Odontohypophosphatasia	AR or AD		Exfoliation (incisors), dental caries , Alveolar bone loss

Table 1. Clinical Features of Hypophosphatasia by Type. AD; autosomal dominant, AR; autosomal recessive

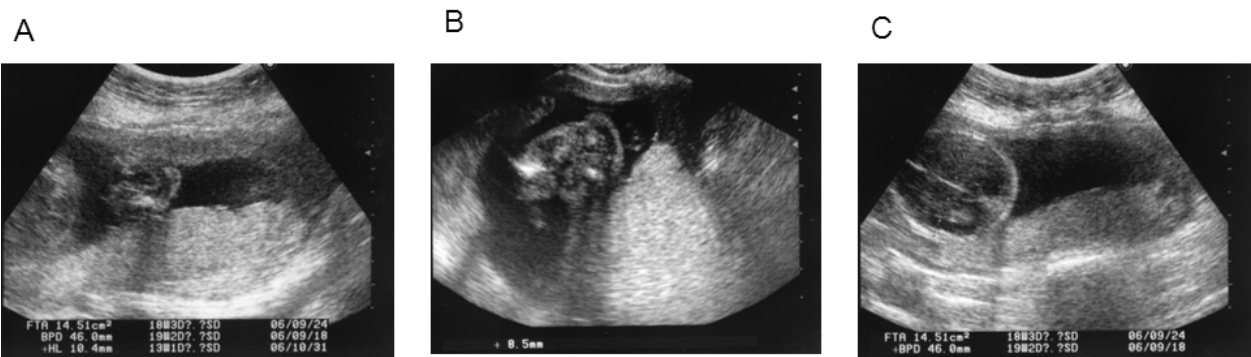

Fig. 1. Ultrasonography examination at 19 weeks’ gestation of pl-HPP fetus
The upper limb(A) femur(B) at 19 weeks’ gestation was shortened with no evidence of fractures. The cranium(C) at 19 weeks’ gestation was thin with marked hypomineralization.

pl-HPP is more common in Japan than in other countries (Satoh et al. 2009). Parents of pl-HPP are heterozygous carriers of *ALPL* mutations. They show no clinical symptoms, but have reduced serum ALP activity and increased urinary phosphoethanolamine (PEA).

2.3 c.1559delT in *ALPL*, a common mutation resulting in the perinatal (lethal) form of hypophosphatasia in Japan

c.1559delT in *ALPL* is a common mutation resulting in pl-HPP in Japan and has only been found in Japanese to date (Orimo et al., 2002; Michigami et al., 2005). Symptoms caused by

deletions and insertions of nucleotides that change the reading frame will be highly deleterious. Some patients with pl-HPP are homozygous for c.1559delT, with parents who are heterozygous carriers for the mutation but with no evidence of consanguinity (Fig. 2) (Sawai et al. 2003). Patients who are homozygous for the c.1559delT mutation differed in the severity of HPP, including both their symptoms and serum ALP activity. In the c.1559delT mutation, the symptom in HPP of homozygous mutation is responsible for a severe phenotype, but that of compound hetero varies from severe to mild that depends on mutation position in other allele.

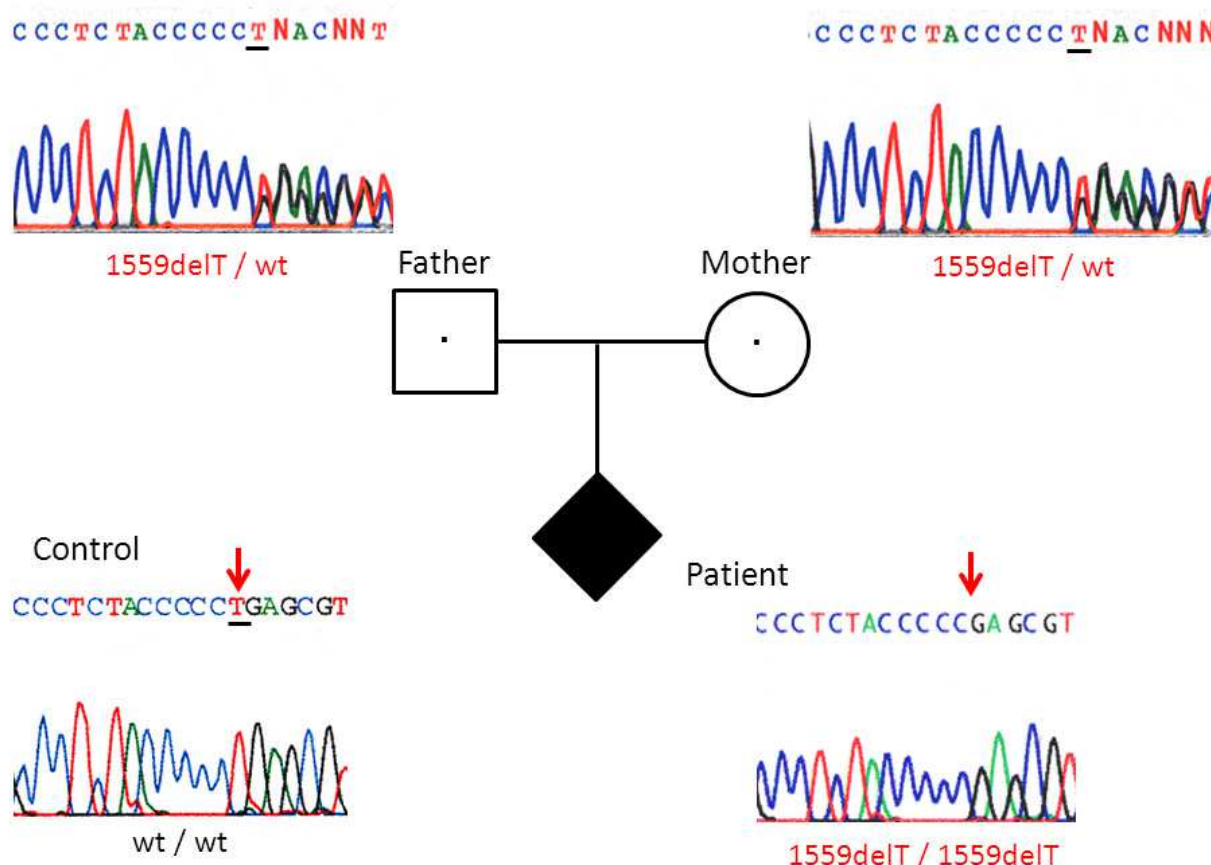


Fig. 2. Direct sequencing results around 1559delT in *ALPL* from a pl-HPP patient both parents, and healthy control. The sequence of the parents could not be determined in progress at cDNA number 1559 of the *ALPL* and these results indicate both parents were heterogenous carriers for 1559delT. The sequence of the pl-HPP patient could be determined in progress containing the deletion of T at nucleotide 1559, which was different from that of a healthy control and indicates that the fetus is homozygous for a 1559delT of the *ALPL*.

c.1559delT, a deletion of T at 1559, which caused a frameshift downstream from leucine (Leu) at codon 503, resulted in the elimination of the termination codon at 508 and the addition of 80 amino acid residues at the C-terminus. The mutant protein caused by 1559delT formed an aggregate, was polyubiquitinated, and was then degraded in the proteome (Komaru et al., 2005), thus allowing us to directly correlate the phenotype (perinatal type) and the genotype (1559delT).

The c.1559delT carrier frequency is 1/480 (95% confidence interval, 1/1,562-1/284) in Japanese (Watanabe et al. 2011). This indicates that approximately 1 in 900,000 individuals to have pl-HPP caused by a homozygous c.1559delT mutation. The majority of c.1559delT carriers had normal values of HPP biochemical markers, such as serum ALP and urine PEA. The only way to reliably detect the pl-HPP carriers is to perform the *ALPL* mutation analysis.

2.4 Prenatal diagnosis for perinatal (lethal) form of hypophosphatasia

pl-HPP has been diagnosed in *utero* by ultrasonography performed with careful attention to marked hypomineralization of the limbs and the skull (Fig.1) (Tongsong & Pongsatha, 2000). The differential diagnosis of HPP depends on the age at which the diagnosis is considered. Ultrasonography examination in prenatal stage may lead to a consideration of osteogenesis imperfecta type II, campomelic dysplasia, and chondrodysplasias with defects in bone mineralization, as well as pl-HPP. Experienced sonographers usually have little difficulty in distinguishing among these disorders. However, pl-HPP is occasionally not diagnosed with sonographic examination in the first trimester because incomplete ossification is a normal finding at this stage of development (Zankl, 2008).

Prenatal assessment for pregnancies at increased risk of severe HPP by mutation analysis is possible if two HPP causing *ALPL* mutations of an affected family member are identified (Watanabe et al., 2007). Most of pl-HPPs are related to c.1559delT in Japan (Watanabe et al., 2011), but to usually compound heterozygotes, carrying two distinct mutations in US and France (Simon-Bouy et al., 2008). In Japan, screening of c.1559delT is important to diagnose pl-HPPs. In out of Japan, mutations occur throughout the entire gene without hot spots. To detect different mutations, all exon screening of *ALPL* is needed. In prenatal genetic diagnosis, fetal genomic DNA was extracted from chorionic villus at approximately ten to 12 weeks' gestation or cultured cells of amniotic fluid at approximately 15 to 18 weeks' gestation.

A prenatal genetic diagnosis for HPP gives a couple important information about the fetus. Prenatal genetic diagnosis for HPP in combination with ultrasonography is thus considered useful for confirming a diagnosis of HPP, which presents with a wide variety of phenotypes.

2.5 Genetic counseling for perinatal (lethal) form of hypophosphatasia

Genetic counseling for pl-HPP has two situations, family with an affected first child (index case) or fortuitous prenatal skeletal dysplasia in a family without history of HP (no index case) (Fig. 3) (Simon-Bouy et al., 2008). First, a couple with an index case with recessive form of pl-HPP will have in subsequent pregnancies affected children similar to the index case with a 25% chance of recurrence. However, the severity of symptoms in HPP may differ from one child to another even in the same mutation (Nakamura-Utsunomiya, 2010). Second, in pl-HPP, pregnancies with clinical symptoms could be detected by ultrasound with no familial history of pl-HPP (no index case). The screening for c.1559delT in *ALPL* may be useful for diagnosis of pl-HPP in Japanese. Detection of 1559delT mutation confirms the diagnosis of severe HPP, and an attempt to predict the severity of the disease. Postnatal molecular genetic analysis using the cord tissue can provide a diagnosis of pl-HPP allows time for parental counseling and delivery planning. In addition, Enzyme replacement therapy (Millán JL et al., 2008) and gene therapy (Yamamoto et al., 2011) will be certainly the most promising challenge. Confirmation of the diagnosis of HPP by *ALPL* genetic testing

will be indispensable before starting the treatment, and perhaps the characterization of the mutations will orient and personalize the treatment in future.

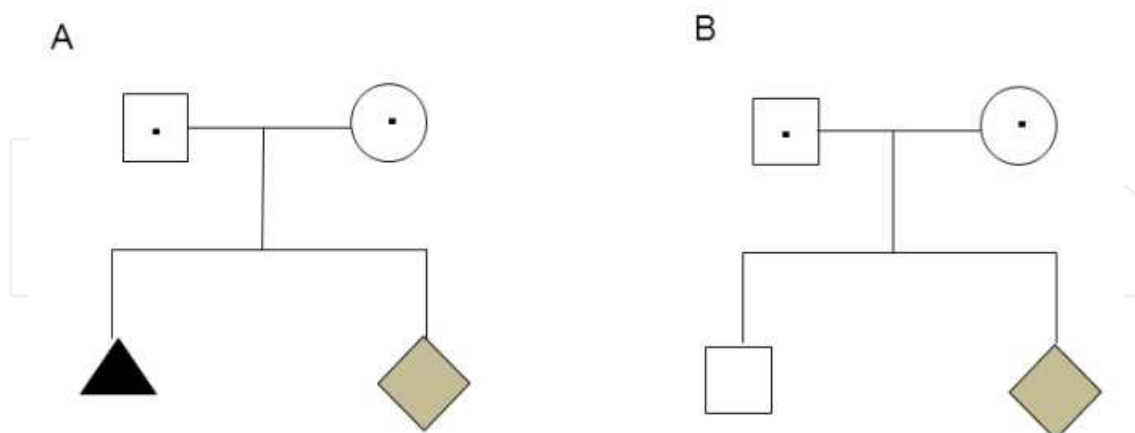


Fig. 3. Pedigree examples of two situations in genetic counseling for pl-HPP: A) family with an affected first child (index case) or B) fortuitous prenatal skeletal dysplasia in a family without history of HP (no index case)

A prenatal diagnosis should be provided in a supportive, noncoercive atmosphere that allows the couple to make informed choices regarding what is best for them in view of their values and parenting goals. Genetic counseling is particularly important before prenatal diagnosis to enable parents to make an informed choice. Counseling before testing makes counseling after testing (for those with an affected fetus) less difficult because prospective parents are better prepared. Careful counseling regarding if and how to inform the parents about the child can help to overcome this potential problem. A prenatal genetic diagnosis may also help the professional team to prepare for a difficult delivery.

3. Conclusion

To diagnose pl-HPP in prenatal stage, collaborations between obstetricians and clinical geneticists are important and could provide support for parents of prenatal patients suspected of having skeletal dysplasia.

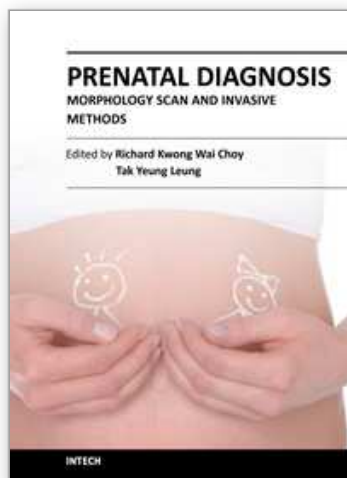
4. Acknowledgment

This work was supported in part by grants from the Ministry of Health and Welfare of Japan.

5. References

- Gehring B., Mornet E., Plath H., Hansmann M., Bartmann P. & Brenner R. E. (1999). Perinatal hypophosphatasia: diagnosis and detection of heterozygote carriers within the family. *Clin. Genet.* 56, 313–317.
- Komaru K., Ishida Y., Amaya Y., Goseki-Sone M., Orimo H. & Oda K. (2005). Novel aggregate formation of a frame-shift mutant protein of tissue-nonspecific alkaline phosphatase is ascribed to three cysteine residues in the C-terminal extension. Retarded secretion and proteasomal degradation. *FEBS J.* 272, 1704–1717.

- Michigami T., Uchihashi T., Suzuki A., Tachikawa K., Nakajima S. & Ozono K. (2005). Common mutations F310L and T1559del in the tissue-nonspecific alkaline phosphatase gene are related to distinct phenotypes in Japanese patients with hypophosphatasia. *Eur. J. Pediatr.* 164, 277-282.
- Mornet E. (2008). Hypophosphatasia. *Best Pract. Res. Clin. Rheumatol.* 22, 113-127.
- Millán JL, Narisawa S, Lemire I, Loisel TP, Boileau G, Leonard P, Gramatikova S, Terkeltaub R, Camacho NP, McKee MD, Crine P, Whyte MP. (2008) Enzyme replacement therapy for murine hypophosphatasia. *J Bone Miner Res.* 23, 777-87.
- Nakamura-Utsunomiya A, Okada S, Hara K, Miyagawa S, Takeda K, Fukuhara R, Nakata Y, Hayashidani M, Tachikawa K, Michigami T, Ozono K, Kobayashi M. (2010). Clinical characteristics of perinatal lethal hypophosphatasia: a report of 6 cases. *Clin. Pediatr. Endocrinol.* 19, 7-13.
- Orimo, H., Goseki-Sone, M., Inoue, M., Tsubakio, Y., Sakiyama, T. & Shimada, T. (2002) Importance of deletion of T at nucleotide 1559 in the tissue-nonspecific alkaline phosphatase gene in Japanese patients with hypophosphatasia. *J. Bone Miner. Metab.* 20, 28-33.
- Sawai H, Kanazawa N, Tsukahara Y, Koike K, Udagawa H, Koyama K, Mornet E. (2003). Severe perinatal hypophosphatasia due to homozygous deletion of T at nucleotide 1559 in the tissue nonspecific alkaline phosphatase gene. *Prenat. Diagn.* 23, 743-746.
- Satoh N., Murotsuki A, & Sawai H. The birth prevalence rates for skeletal dysplasia in the registration system of the Japan Forum of Fetal Skeletal Dysplasia. *J. Jan. Perinat. Neonat. Med.* 45, 1005-1007 (2009). (Japanese)
- Simon-Bou B, Taillandier A, Fauvert D, Brun-Heath I, Serre JL, Armengod CG, Bialer MG, Mathieu M, Cousin J, Chitayat D, Liebelt J, Feldman B, Gérard-Blanluet M, Körtge-Jung S, King C, Laivuori H, Le Merrer M, Mehta S, Jern C, Sharif S, Prieur F, Gillesen-Kaesbach G, Zankl A, Mornet E. (2008). Hypophosphatasia: molecular testing of 19 prenatal cases and discussion about genetic counseling. *Prenat Diagn.* 28 993-8.
- The Tissue Nonspecific Alkaline Phosphatase Gene Mutations Database
http://www.sesep.uvsq.fr/03_hypo_mutations.php#mutations
- Tongsong T. & Pongsatha S. (2000). Early prenatal sonographic diagnosis of congenital hypophosphatasia. *Ultrasound Obstet. Gynecol.* 15, 252-255.
- Zankl A., Morne, E. & Wong, S. (2008). Specific ultrasonographic features of perinatal lethal hypophosphatasia. *Am. J. Med. Genet.* 146A, 1200-1204.
- Watanabe A., Yamamasu S., Shinagawa T., Suzuki Y., Takeshita T., Orimo H. Shimada T. (2007). Prenatal genetic diagnosis of severe perinatal (lethal) hypophosphatasia. *J. Nippon Med. Sch.* 74, 65-69
- Watanabe A, Karasugi T, Sawai H, Naing BT, Ikegawa S, Orimo H, Shimada T. (2011). Prevalence of c.1559delT in ALPL, a common mutation resulting in the perinatal (lethal) form of hypophosphatasia in Japanese and effects of the mutation on heterozygous carriers. *J Hum Genet.* 56, 166-8.
- Yamamoto S, Orimo H, Matsumoto T, Iijima O, Narisawa S, Maeda T, Millán JL, Shimada T. (2011) Prolonged survival and phenotypic correction of Akp2(-/-) hypophosphatasia mice by lentiviral gene therapy. *J Bone Miner Res.* 26,135-142.



Prenatal Diagnosis - Morphology Scan and Invasive Methods

Edited by Dr. Richard Choy

ISBN 978-953-51-0614-2

Hard cover, 210 pages

Publisher InTech

Published online 29, June, 2012

Published in print edition June, 2012

This book provides detailed and comprehensive coverage on various aspects of prenatal diagnosis-with particular emphasis on sonographic and molecular diagnostic issues. It features sections dedicated to fundamentals of clinical, ultrasound and genetics diagnosis of human diseases, as well as current and future health strategies related to prenatal diagnosis. This book highlights the importance of utilizing fetal ultrasound/clinical/genetics knowledge to promote and achieve optimal health in fetal medicine. It will be a very useful resource to practitioners and scientists in fetal medicine.

How to reference

In order to correctly reference this scholarly work, feel free to copy and paste the following:

Atsushi Watanabe, Hideo Orimo, Toshiyuki Takeshita and Takashi Shimada (2012). Prenatal Diagnosis of Severe Perinatal (Lethal) Hypophosphatasia, Prenatal Diagnosis - Morphology Scan and Invasive Methods, Dr. Richard Choy (Ed.), ISBN: 978-953-51-0614-2, InTech, Available from:
<http://www.intechopen.com/books/prenatal-diagnosis-morphology-scan-and-invasive-methods/prenatal-diagnosis-for-severe-perinatal-lethal-form-of-hypophosphatasia>

INTech
open science | open minds

InTech Europe

University Campus STeP Ri
Slavka Krautzeka 83/A
51000 Rijeka, Croatia
Phone: +385 (51) 770 447
Fax: +385 (51) 686 166
www.intechopen.com

InTech China

Unit 405, Office Block, Hotel Equatorial Shanghai
No.65, Yan An Road (West), Shanghai, 200040, China
中国上海市延安西路65号上海国际贵都大饭店办公楼405单元
Phone: +86-21-62489820
Fax: +86-21-62489821

© 2012 The Author(s). Licensee IntechOpen. This is an open access article distributed under the terms of the [Creative Commons Attribution 3.0 License](https://creativecommons.org/licenses/by/3.0/), which permits unrestricted use, distribution, and reproduction in any medium, provided the original work is properly cited.

IntechOpen

IntechOpen