

We are IntechOpen, the world's leading publisher of Open Access books Built by scientists, for scientists

6,900

Open access books available

185,000

International authors and editors

200M

Downloads

Our authors are among the

154

Countries delivered to

TOP 1%

most cited scientists

12.2%

Contributors from top 500 universities



WEB OF SCIENCE™

Selection of our books indexed in the Book Citation Index
in Web of Science™ Core Collection (BKCI)

Interested in publishing with us?
Contact book.department@intechopen.com

Numbers displayed above are based on latest data collected.
For more information visit www.intechopen.com



Prenatal Evaluation of Fetuses Presenting with Short Femurs

Funda Gungor Ugurlucan¹, Hülya Kayserili² and Atil Yuksel¹

¹Department of Obstetrics and Gynecology, Istanbul Medical Faculty Istanbul University

²Department of Medical Genetics, Istanbul Medical Faculty Istanbul University
Turkey

1. Introduction

Femur length (FL) is the measurement between the distal and proximal ossification centers of the femoral diaphysis. FL is one of the fetal biometry measurements which is measured ordinarily during the routine second trimester scanning and onwards in determining the gestational age and growth between ultrasound examinations.

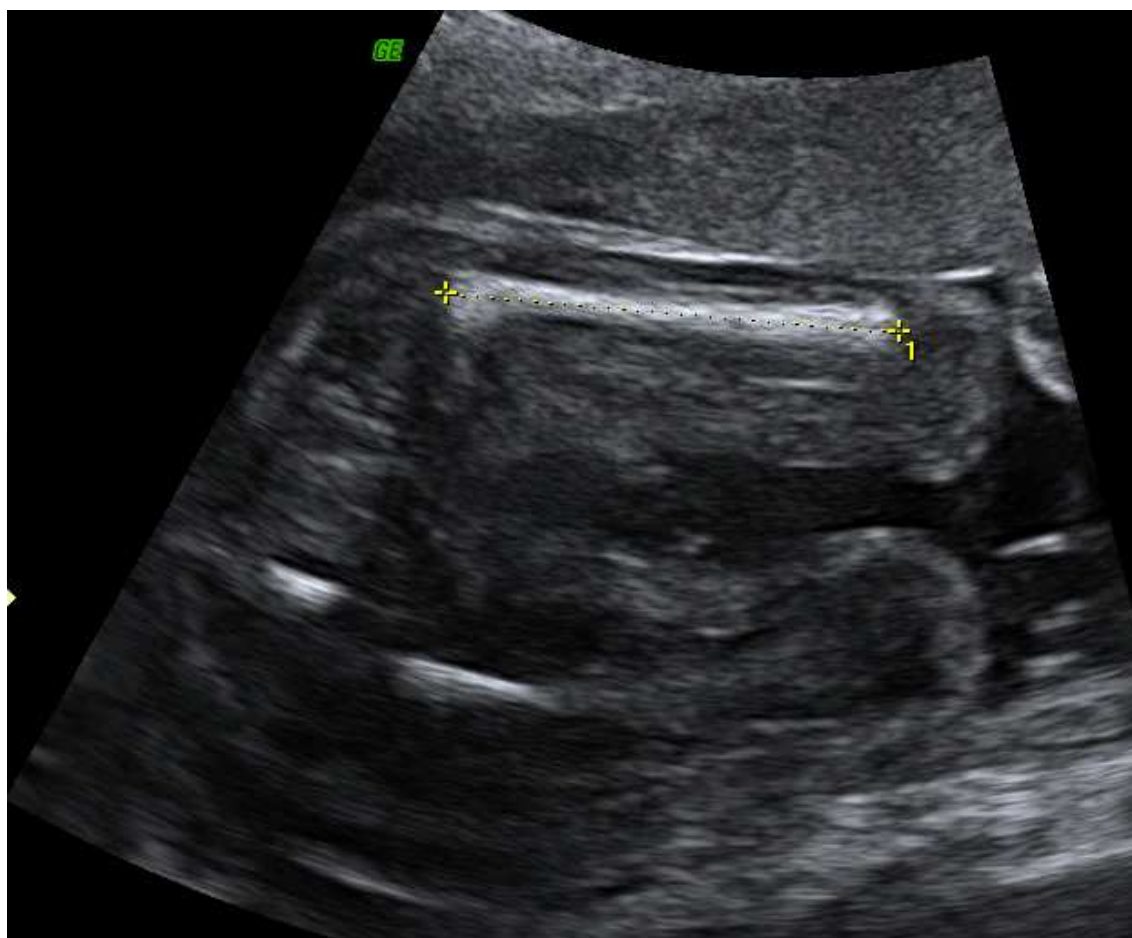

Fig. 1. The scan showing the correct FL measurement

Short FL is defined as below the 5th percentile or -2 standard deviations (SD) appropriate for gestational age at the ultrasound examination. FL measurement is one of the easiest fetal biometry measurements. However; careful ultrasonographic measurement of only the ossified portions of the diaphysis is needed to obtain accurate measurements. The ossified portion of the femur is measured from the major trochanter to the distal end of the femoral shaft; the distal and proximal epiphyses are not included in the measurement. Oblique planes must be avoided and the femur closer to the transducer must be measured while the transducer is aligned parallel to the long axis of the bone. (*Figure 1*)

In most cases, short FL may be measured inaccurately or may be a variant of normal, especially if present as an isolated finding. However; short FL might be a diagnostic challenge for the examiner with various differential diagnoses. Short FL may be a part of a malformation such as a skeletal dysplasia or aneuploidies such as Trisomy 21 (Down Syndrome) or Monosomy X, and metabolic syndromes. (Kurtz et al.1990; Vergani et al. 2000; Bromley et al. 2002) Some studies have also suggested that a short FL is a feature of intrauterine growth restriction (IUGR) and small-for-gestational age (SGA) babies. (Todros et al. 1996; Zalel et al. 2002) Short FL may be associated with uteroplacental insufficiency and altered biochemical markers. (Weisz et al. 2008)

In this chapter, the abnormalities that might present with a short FL will be described in detail and then the management of short FL will be discussed.

2. Femur length and aneuploidies

The antepartum detection of fetal aneuploidy is one of the major goals of prenatal screening programs and aneuploidies are the most common genetic abnormalities detected by prenatal diagnosis. (Nyberg et al. 2008) The major screening method for aneuploidies in the antenatal period is detection of abnormalities during ultrasonography in addition to biochemical markers, maternal age, and genetic risk. However, for definitive diagnosis, karyotype analysis by amniocentesis or chorionic villus biopsy is needed.

Trisomy 21 (Down's syndrome) is an aneuploidy characterized by presence of an extra chromosome 21. It is named after John Langdon Down who first described the syndrome in 1866. (Down JLH; 1866) The condition was identified as an extra chromosome 21 in 1959 by Jerome Lejeune. (Lejeune et al. 1959) Characteristic dysmorphic features of trisomy 21 predominantly affect the head and neck and the extremities. Changes in the extremities include short broad hands, hypoplastic mid phalanx of fifth finger, incurved fifth finger, transverse palmar crease, space between the first and second toes (sandal gap deformity), hyperflexibility of joints. In addition, fetuses with trisomy 21 have slightly shorter long-bones than their normal counterparts. Actually, the mean length at birth is approximately 0.5 standard deviations (SD) less than normal babies in addition to decrease in birthweight and head circumference are less in babies with trisomy 21 when compared with normal counterparts. (Cronk CE; 1978)

In 1987, Lockwood et al and Benacerraf et al were the first ones to show that short FL was associated with increased risk of trisomy 21. (Lockwood et al. 1987; Benacerraf et al. 1987) The other biometric parameters were also evaluated, but the most significant changes were observed in the length of the extremities. (Barr Jr M.; 1994) Various criteria have been described for the determination of short FL. Lockwood and Brumfield used the biparietal

diameter (BPD) to FL ratio in order to evaluate the risk of Down syndrome. (Lockwood et al. 1987; Brumsfield et al. 1989) Lockwood chose an upper limit of 1.5 standard deviations above the mean. This led to a sensitivity of 50% and false-positive rate of 7% for identifying fetuses with Down syndrome. Brumsfield suggested a sensitivity of 40% and false positive rate of 2.2% using a BPD: FL ratio of ≥ 1.8 in the second trimester. (Brumsfield et al. 1989) But, it must be kept in mind that the BPD: FL ratio might differ depending on the gestational age of the fetus; second trimester seems to be the best time for evaluation. On the other hand, Grist used the measured-to-expected FL ratio and identified fetuses with Down syndrome with a sensitivity of 50% and false positive rate of 6.5%. (Grist et al. 1990)

It seems that most of the studies suggest that fetuses with trisomy 21 have slightly short FL. However the change in FL is only slight and therefore it is regarded as a soft marker for trisomy 21. Soft markers of trisomy 21 are ultrasonographic findings with the possibility of association with chromosomal abnormalities such as choroid plexus cysts, echogenic bowel, short FL, short humerus length (HL), pyelectasis. They are insufficient to be used as an isolated marker, but rather they are more likely to be useful when combined with each other. (Bethune, 2007) It must be remembered that isolated soft markers are identified in 11-17% of normal fetuses; however the prevalence is much higher in trisomy 21 and the risk of trisomy 21 increases more especially if there is more than one marker. (Breathnach et al., 2007) So a detailed fetal anatomy scanning should be performed to search for other markers when a short FL is encountered and if there is more than one marker a karyotype analysis should be obtained. Increased nuchal fold thickness, hypoplastic nasal bone and aberrant right subclavian artery are more powerful markers for Down Syndrome, and fetal chromosomal analysis might be offered in most cases with these findings even if they were isolated.

Short HL is also associated with trisomy 21 and it is suggested that the risk of trisomy 21 is higher with a short HL than a short FL. (Bethune, 2007) Therefore measurement of HL should be part of the routine whenever a short FL is measured.

Turner Syndrome (Monosomy X) is the only monosomy that is compatible with life. Turner syndrome was first described by Henry Turner in 1938 and was recognized to be secondary to karyotypic variation of 45,X in 1959. (Turner, 1938; Ford et al., 1959; Wiedemann & Glatz, 1991) Although most conceptions with Turner syndrome die, 1% survive until term. (Cockwell et al., 1991) Its incidence is 1 in 2500 to 3000 live-born girls. Approximately half have monosomy X (45,X), and 5 to 10% have a duplication (isochromosome) of the long arm of one X (46,X,i(Xq)). (Sybert & McCauley, 2004) It is characterized by large cystic hygromata and fetal hydrops at the early stages of gestation in addition to short FL and short HL. (Chen & Chien, 2007) Live born fetuses may have minor problems such as short stature, widely spaced nipples, congenital lymphedema, webbed neck, and minor bone and cartilage abnormalities. Prenatal sonographic diagnosis is usually established in the late first and early second trimesters, secondary to cystic hygroma formation. (Weisz et al., 2008) One study evaluated the clustered ultrasonography findings in fetuses with Turner syndrome. (FitzSimmons et al., 1994) Thirteen fetuses with Turner syndrome were observed among 9348 early pregnancies (1/3086). Huge septated cystic hygroma, subcutaneous edema, and hydrops were observed in all cases. Short FL was detected in 12 of the 13 (92%) fetuses. Papp et al reported seven fetuses (10.1%) with short FL in 69 fetuses with Turner syndrome. The authors concluded that the addition of the soft marker of short FL to the second-trimester sonographic survey may increase the detection rate of Turner syndrome. (Papp et al., 2006)

Todros et al evaluated the outcome of pregnancy in 86 fetuses diagnosed with short FL in the second trimester ultrasonography scanning. (Todros et al., 2004) Twenty-eight of the fetuses (32.5%) were normal, 40 (46.5%) were structurally abnormal and 18 (21%) were small for gestational age. Of the 40 malformed fetuses, 16 (40%) were aneuploid. The structural malformations associated with aneuploidy included 10 cases of congenital heart disease with trisomy 21, three cases of multiple malformations with trisomy 18, one case of multiple malformations with trisomy 13 and two cases of Turner syndrome with aortic coarctation. None of the fetuses with isolated short FL was aneuploid. Therefore the authors suggested that short FL is not considered as an indication for karyotype analysis unless associated with other sonographic markers.

3. Femur length, skeletal dysplasias and other malformations

The skeletal dysplasias account for about 5% of the genetic disorders seen in the newborn period. (Orioli et al., 1986) They represent a significant burden to many families because of potential lethality, and short- and long-term medical complications, and recurrence risk. The fetal skeleton is easily visualized by ultrasound, however most series note a diagnostic accuracy for the skeletal dysplasias at less than 50%. (Doray et al., 2000; Parilla et al., 2003; Krakow et al., 2008)

Shortening of the FL is referred to as rhizomelia. When a short FL is identified before 24 weeks gestation, skeletal dysplasias must be considered and all long bones (each femur, humerus, radius, ulna, tibia, and fibula) must be measured to determine the relative length against normal values. In addition to measurement of the length, the long bones should be evaluated regarding changes in shape, mineralization, bowing, angulation, and metaphyseal flare. Although there is severe shortening of all limbs in the majority of skeletal dysplasias, the foot length is relatively normal. The normal FL: foot length ratio is 1.0 throughout the pregnancy, thus a ratio of less than 1 is useful in distinguishing skeletal dysplasia from other causes of short FL, such as IUGR or aneuploidy. (Campbell et al., 32)

Many skeletal dysplasias and specific syndromes are associated with short FL. These are listed in *Table 1*; however in most of these, it is possible to detect several additional ultrasonographic markers in a detailed ultrasonography scan.

Achondroplasia (OMIM Entry # 100800) is the most frequent form of short-limb dwarfism and most common form of skeletal dysplasia. (Horton et al., 2007) It occurs in one in 15,000 to one in 40,000 live births.

It is caused by mutation in the fibroblast growth factor receptor-3 gene (*FGFR3*), which is located at chromosome 4p16.3 and is inherited as an autosomal dominant fashion with essentially complete penetrance. (Superti-Furga & Unger, 2007) More than 99% of individuals with achondroplasia have one of two mutations in *FGFR3*. Over 80% of individuals with achondroplasia have parents with normal stature and have achondroplasia as the result of a *de novo* gene mutation. Affected individuals exhibit short stature caused by rhizomelic shortening of the limbs, characteristic face with frontal bossing and midface hypoplasia, exaggerated lumbar lordosis, limitation of elbow extension, bowed legs, and trident hand. (Nyberg, 2003) Head and abdominal circumference may be normal, but are often enlarged. But these signs are not specific. Prenatal sonographic diagnosis is often not possible as the length of long bones is well preserved until around 22 weeks' gestation, the time of the routine fetal anomaly scan. (Goncalves & Jeanty, 1994; Chitty et al., 2011) The FL is at the fifth percentile at this time and

then below the first percentile at about 30 weeks. (Nyberg, 2003) Presentation and diagnosis of *de novo* cases often occurs at this period when the short limbs, frontal bossing and trident hand may be evident. Even then, misdiagnosis is common. (Modaff et al., 1996)

Alkyldihydroxacetonephosphate synthase deficiency
Atelosteogenesis type III
Barrow (1984)- short-limbed dwarfism; congenital heart defect
Baxova (1993)- micromelic bone dysplasia-humerus, femur, tibia type
Brachydactyl-type A1
Chondrodysplasia punctata-tibia metacarpal type
De la Chapelle-neonatal osseous dysplasia
Dysspondylochondromatosis
Gracile bone dysplasia
Hypochondroplasia
Hypochondroplasia (autosomal recessive)
Kyphomelic dysplasia
Metaphyseal acroscyphodysplasia
Metaphyseal chondrodysplasia- cone-shaped epiphyses
Omodysplasia
Omodysplasia type II
Patterson (1975)-rhizomelic dysplasia
Proximal femoral focal deficiency
Pseudoachondroplasia-like syndrome
Slaney (1999)- spondyloepimetaphyseal dysplasia-hypogammaglobulinaemia
Spondyloepimetaphyseal dysplasia-type Genevieve
Spondylometaphyseal dysplasia-type Borochowitz
Spondylometaphyseal dysplasia-type Sutcliffe
Silver-Russell syndrome

Table 1. The list of skeletal dysplasias and syndromes that might present prenatally with isolated short FL

Bowing of the femora have been reported in some cases. One study suggested that all the fetuses with achondroplasia had rounded metaphyseal–epiphyseal interface, with an angle connexion to diaphysis wider than expected at the ultrasonography scan. (Boulet et al., 2009)

Routine prenatal ultrasound examination may identify short FL and raise the possibility of achondroplasia in a fetus not known to be at increased risk. Krakow et al described the use of 3D ultrasonography in pregnancies from 16 to 28 weeks' gestation to enhance appreciation of the facial features and relative proportions of the appendicular skeleton and limbs for the diagnosis of achondroplasia. (Krakow et al., 2009) Ruano et al used a combination of 3D ultrasonography and intrauterine 3D helical computer tomography to enhance the diagnostic accuracy for intrauterine skeletal dysplasias. (Ruano et al., 2004)

Molecular testing can confirm the diagnosis in achondroplasia. DNA extracted from fetal cells obtained by amniocentesis or fetal cord blood sampling can be analyzed for *FGFR3* mutations if achondroplasia is suspected. (Francomano et al., 1993a)

Hypochondroplasia (OMIM Entry #146000) is also inherited in an autosomal dominant pattern and caused by mutation in the gene for *FGFR3* located on 4p, which is 98-99% mutated in achondroplasia. (Francomano et al., 1993b) The majority of the cases result from spontaneous mutations and that the unaffected parents of a child with hypochondroplasia have an extremely low risk (<0.01%) of having another affected child. Its prevalence is 1 in 50,000 births. (Hicks, 2003) The molecular testing strategies can detect only % 70 of the cases.

Not all patients with presumed hypochondroplasia have demonstrable mutations in the *FGFR3* gene, suggesting genetic heterogeneity. It is characterized by short stature, short arms and legs, and macrocephaly. The skeletal features are very similar to achondroplasia but usually tend to be milder. (Spranger, 1988) Shortening of long bones with mild metaphyseal flare is observed. The hands are relatively short but do not exhibit the "trident" appearance that is typical in achondroplasia. Facial features are usually normal and the classic facial features of achondroplasia (e.g., midface hypoplasia, frontal bossing) are not generally seen. Head size may be large without significant disproportion.

Hypochondroplasia shows some resemblance to achondroplasia, but is much milder and can be distinguished on clinical and radiographic grounds. Unlike achondroplasia, motor milestones are usually not significantly delayed and symptoms resulting from spinal cord compression (e.g., apnea, neuropathy) are less common. (Wyne-Davies et al., 1981)

The antenatal diagnosis is difficult as skeletal disproportion tends to be mild and the ultrasonography findings nonspecific. Prenatal molecular genetic testing is available if the mutations in the parents with hypochondroplasia have been identified. If the mutation causing hypochondroplasia cannot be identified, ultrasound examination is the only method of prenatal testing. It is often possible to detect an affected fetus early in the pregnancy if the fetus is at risk of being a heterozygote with another dominantly inherited skeletal dysplasia. (Francomano et al., 1993b) However, it is currently difficult to detect heterozygous hypochondroplasia or other milder phenotypes using ultrasonography. Signs of disproportionate growth may suggest the diagnosis of hypochondroplasia, but a "normal" third trimester ultrasound examination is not sufficient to rule out a diagnosis of hypochondroplasia. DNA banking may be offered to the family for future analysis. DNA-based diagnosis (*FGFR3* N540K and G380R mutation analysis) via chorion villus sampling, amniocentesis or fetal cord blood sampling may be helpful in ruling out lethal forms of skeletal dysplasia and establishing a more favorable prognosis for the fetus. (Francomano et al., 1993b)

Leroy I-cell disease is an autosomal recessive disorder first described in 1967 by Leroy and Demars and called I-cell disease due to the presence of phase dense intracytoplasmic inclusions in fibroblasts which were termed I cells. (Leroy et al., 1969) There is a biochemical defect in uridine diphospho-N-acetylglucosamine-1-phosphotransferase, which is the enzyme that catalyses addition of a mannose phosphate residue for lysosomal trafficking. (Wenger et al., 2002) Death from pneumonia or congestive heart failure usually occurs within the first decade of life. The most severely affected system is the skeletal system. Bone changes are similar to those observed in mucopolysaccharidoses. The classic finding is dysostosis multiplex, with a cloaking appearance of the long tubular bones due to periosteal new bone formation, anterior beaking and wedging of the vertebral bodies, widening of the ribs, proximal pointing of the metacarpals, and bullet shaped phalanges. Other findings are coarse facial features, developmental delay, growth failure, umbilical and inguinal hernias, hepatomegaly, and hypotonia. (Benacerraf, 1998) Lees et al have described polyhydramnios

and short femurs in a case of Leroy I-cell disease that was diagnosed in the postnatal period. (Lees et al., 2001) The family had a history of Leroy I-cell disease. Yuksel et al reported two cases that both had short femurs and in one femoral bowing was additionally detected in the late second trimester and both were diagnosed as Leroy I-cell disease by enzyme analysis in the postnatal period. (Yuksel et al., 2007) None of the two families had a history of Leroy I-cell disease. Invasive prenatal diagnosis is possible by analysis of enzyme activity in chorionic villi or cultured amniocytes, but it is offered to families only known to be at risk for the metabolic disease.

For most of the other skeletal dysplasias presenting with short FL, other associated ultrasound findings such as bell-shaped thorax, protuberant abdomen, and polydactyl are present. (Nyberg, 2003)

Femoral-facial syndrome (FFS), also known as *femoral hypoplasia-unusual facies syndrome (FHUFS)* (MIM 134780), first described by Daentl et al, is a rare and sporadic multiple congenital anomaly syndrome comprising bilateral femoral hypoplasia and characteristic facial features, such as long philtrum, thin upper lip, micrognathia with or without cleft palate, and a short nose with broad tip. (Daentl et al., 1975; Nowaczyk et al., 2003) Nowaczyk et al reported an infant born with the disorder whose ultrasonography scan at 19 weeks was reported as normal. Review of the prenatal radiographs showed no diagnostic features in this child. These authors underlined the difficulties in identifying femoral abnormalities on 2D imaging and suggested that 3D imaging would be more effective for prenatal diagnosis. (Nowaczyk et al., 2003)

Acampomelic campomelic dysplasia (MIM 114290) is referred to cases without campomelia which is the bowing of the legs, especially the tibias. (Macpherson et al., 1989) However the other features of the syndrome such as ovarian dysgenesis, craniofacial changes, and defective tracheal bronchial cartilage are observed. (Rodriguez, 1993) Mutations in SOX-9 gene have been observed, 46, XY sex reversal is common. (Kwok et al., 1995)

Shprintzen syndrome (MIM 182212) is also associated with short FL. It is characterized by short stature, mild mental retardation, ear and hearing abnormalities, microcephaly, micrognathia, and cardiac and limb defects. The syndrome is autosomal dominantly inherited and is caused by mutations in the *fibrillin 1* gene, which cannot be tested easily in the antenatal period due to its size. (Biery et al., 1999)

The most important point in the antenatal diagnosis of skeletal dysplasias is the prediction of lethal disorders. It is crucial to measure the thoracic circumference and warn the parents when the thoracic circumference is well below the fifth centile. Multidisciplinary approach is necessary in the diagnosis and counselling of these cases. After delivery or termination of the pregnancy, the diagnosis should be confirmed by clinical, radiographic, and histopathological analysis and also by molecular testing strategies when available. Cell cultures and DNA should be banked to be used for future diagnostic molecular testing.

4. Femur length and intrauterine growth restriction

Several case series have shown an association between short FL and IUGR. Bromley et al, reported four fetuses with short femurs measuring more than 2 SD below the mean compared with the biparietal diameter. (Bromley et al., 1993) These fetuses were subsequently found to have severe IUGR with no evidence of skeletal dysplasia. Two other studies have described a short FL in cases with IUGR. (O'Brien et al., 1982)

In one study, 18 of the 86 fetuses (21%) referred for FL below the 10th percentile had SGA. (Todros et al., 2004) The diagnosis of SGA in fetuses was confirmed about 9 weeks after the initial finding of short FL. In another study short FL was associated with low birth weight and SGA, but not with gestational hypertension. These cases of isolated short FL were associated with significantly lower levels of pregnancy associated plasma protein- A (PAPP-A), but similar β -hCG, inhibin-A, and alpha-fetoprotein (AFP) when compared to fetuses with normal FL. (Qin et al., 2006)

Fetuses with short FL at the second trimester scanning might be considered as having an increased risk of IUGR. Maternal evaluation regarding blood pressure monitorization and follow-up for development of preeclampsia, ultrasonographic evaluation of the placenta, and Doppler analysis should be offered in this situation. In one study 50% of the women developed preeclampsia while undergoing follow-up for short FL and IUGR. (Todros et al., 2004)

The association between short FL and IUGR is unclear. It might be explained by the brain sparing effect with decreased flow to the lower body. It is likely that IUGR and short FL are linked to preeclampsia by the common mechanism of placental insufficiency. (Weisz et al., 2008)

Silver-Russell syndrome (SRS, MIM 180860) is a syndrome characterized by severe asymmetric IUGR, poor postnatal growth, craniofacial features such as a triangular shaped face and a broad forehead, body asymmetry, and a variety of minor malformations. It was reported independently by Silver et al. and Russell. (Silver et al., 1953; Russell, 1954) The long bones are short whereas the head measurements are within the normal range. The hallmark for the diagnosis of Silver-Russell syndrome is the demonstration of limb length asymmetry, which is unusual in other conditions. Yet there is no specific testing to confirm the diagnosis in the prenatal period. (Nyberg, 2003) In very near future testing strategies like chip-based next generation sequencing and methylation testing assays will be available for definitive diagnosis of SRS cases and many other syndromes having short femurs as the only clinical sign will be thoroughly evaluated during the antenatal period.

5. Femur length and normal variants

It must be considered that most of the fetuses presenting with isolated short FL are clinically normal. A short FL is defined as below the 5th percentile or below two standard deviations from the mean for the gestational age. That results in a pickup rate that exceeds the expected frequency of skeletal dysplasias. Various criteria have been published for the determination of short FL and HL. (Lockwood et al., 1987; Benacerraf et al., 1992) These criteria overlap the range observed in unaffected fetuses and vary widely among different populations; therefore, it would be prudent to develop standards for each population. Some authors have advocated the use of ethnic-specific FL growth charts. FL is observed to be shorter in Asian and oriental populations. (Nyberg, 2003; Down, 1866; Bromley et al., 1993; Shipp et al., 2001; Kovac et al., 2002a; Drooger et al., 2005) A significant difference in the mean expected FL among fetuses in the second trimester with regard to ethnicity was observed. It was stated that using ethnic-specific formulas for expected FL can have a considerable impact on the use of sonographic risk factors for trisomy 21 screening. (Kovac et al., 2002b) In another study, it was reported that short stature increased a woman's risk of having an abnormal BPD:FL ratio at the second trimester. They indicated that risk assessment for fetal trisomy 21 for such patients might be inaccurate. (Drooger et al., 2005) At 18 and 19 weeks' gestation, women shorter than one SD below the mean were twice as likely to have an abnormal BPD:

FL ratio compared with women taller than one SD above the mean (relative risk 2.38; 95% confidence interval 1.21, 4.69). (Drooger et al., 2005)

6. Management of short femur length

The differential diagnoses of short FL include normal variation, a false-positive measurement, IUGR, aneuploidy, and skeletal dysplasias. Very short FL is suggestive for skeletal dysplasias and other syndromes. (Table 2)

Diagnosis	Down Syndrome	Achondroplasia	Skeletal Dysplasias/Syndromes	Intrauterine Growth Restriction	Constitutional
Detailed anomaly scan	Markers of aneuploidy (echogenic intracardiac focus, pyelectasis, choroid plexus cysts, duodenal atresia, nuchal translucency, etc)	Frontal bossing, short fingers, trident hand short arms, narrow chest, macrocephaly	Abnormalities of other tubular bones, bowing, metaphyseal changes, abnormal posture/movements, thoracic circumference important	Small biometric measurements, possible abnormal Doppler findings	No obvious changes
Femur growth pattern	Often about 5th centile from early pregnancy on	Normal until 25 weeks, then falls in centiles	Severely short at second trimester or before	Variable onset, might begin with short FL weeks before small abdominal circumference	Often near 5th percentile, growth velocity is normal
Diagnosis	Down syndrome screening tests, karyotype analysis if > 1 soft marker	Molecular testing (Family history may be positive, <i>de novo</i> mutations common)	Depends on diagnosis and inheritance pattern. Postnatal diagnosis is possible. . Cell culture and DNA banking must be offered.	Karyotype analysis if > 1 soft marker, growth restriction develops during follow-up	Mother and/or father has short stature. History of short stature

Table 2. Differential Diagnosis of short femur length

Detailed ultrasonography scanning should be performed in patients presenting with short FL to exclude fetal malformations. Other tubular bones should be evaluated in addition to FL.

It must be remembered that the majority of isolated short FL are normal or constitutionally short and 13-61% of the fetuses diagnosed with isolated short FL at the second trimester scanning are classified as normal eventually on the follow-up. (Todros et al., 2004; Papageorgiou et al., 2008) In contrast, severely shortened (<5th percentile) or abnormal appearing long bones may be a sign of a skeletal dysplasia or early onset fetal growth restriction. (Weisz et al., 2008)

Counselling should be given to cases with isolated short FL; however a more conservative approach is more appropriate. Serial ultrasonography examinations should be performed in order to exclude skeletal dysplasias, IUGR, and uteroplacental insufficiency. Karyotype analysis should be offered if there are other sonographic markers suggesting aneuploidies. In cases where the karyotype analysis is normal, it is wise to store the DNA for future analysis in cases of sporadic skeletal dysplasias and syndromes. Isolated short FL cases should be followed up. Short FL due to IUGR should be suspected if during follow-up a small abdominal circumference, or abnormal Doppler parameters develop. If the FL falls further from the mean in the three-four weeks of follow-up skeletal dysplasia or severe IUGR should be suspected. (Kurtz et al., 1990)

Mild shortening of FL may suggest chromosomal abnormality or a syndrome. (Benacerraf et al., 1987; LaFollette et al., 1989; Perella et al., 1988; Nyberg et al., 1990) If mildly short FL (defined as length < 90% of the predicted FL) is present, there is a 1% risk of trisomy 21 in a high risk population (1/250 trisomy 21) and 3% risk of trisomy 21 in a low risk population (1/700 trisomy 21). (Nyberg et al., 1990) Short HL is even more specific than short FL in predicting trisomy 21. If short HL (defined as length < 90% of the predicted HL) is identified, there is a 3% risk of trisomy 21 in a high-risk population and a 1-2% risk of trisomy 21 in a low-risk population. (Benacerraf et al., 2001)

In the third trimester, one should remember that the FL is subject to the same 'biologic variability' as other biometric markers. It is not unusual for the FL measurement to be slightly less than other biometric markers in the absence of morphologic abnormality. This is particularly true if the remainder of the sonographic evaluation of the fetus is normal.

Evaluation of fetal posture and fetal movements are very important in prenatal ultrasound. Abnormal posture or movement may be the first clues to either focal or generalized musculoskeletal abnormality. Some skeletal dysplasias may develop additional features during the follow-up. The family must be clarified about the fact that some of the syndromes cannot be ruled out despite detailed sonographic evaluation.

7. Key points

1. Most of the fetuses with isolated short FL are normal or constitutionally short.
2. Detailed sonographic evaluation regarding additional markers for aneuploidy, measurement of other tubular bones, Doppler analysis should be performed.
3. If there are additional markers, karyotype analysis should be performed. The DNA may be banked for future analysis.
4. If the fetal karyotype analysis is normal, serial follow-up scans should be scheduled.
5. If, during follow-up the FL falls more from the mean, skeletal dysplasias or severe IUGR should be suspected. Molecular analysis must be performed for the diagnosis of

skeletal dysplasias with known molecular teiology, such as achondroplasia and hypochondroplasia . Preeclampsia must be ruled out.

6. Findings more suggestive for skeletal dysplasias include FL 2 SD below the mean for gestational age; FL/ foot length <1; and FL/ abdominal circumference < 0.16 .
7. Despite detailed sonographic evaluation, some of the syndromes cannot be ruled out and postnatal clinical genetic evaluation of fetuses or newborns should be considered.

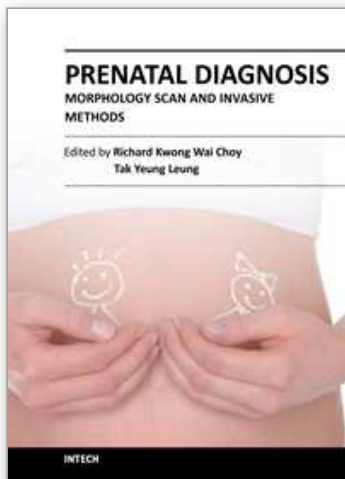
8. References

- Barr Jr M. Growth profiles of human autosomal trisomies at midgestation. *Teratology* 1994; 50:395.
- Benacerraf B, Gelman R, Frigoletto F. Sonographic identification of second trimester fetuses with Down's syndrome. *N Engl J Med* 1987; 317: 1371.
- Benacerraf BR, Neuberg D, Frigoletto FD Jr. Humeral shortening in second trimester fetuses with Down syndrome. *Obstet Gynecol* 1991; 77: 223.
- Benacerraf BR, Neuberg D, Bromley B, Frigoletto FD Jr. Sonographic scoring index for prenatal detection of chromosomal abnormalities. *J Ultrasound Med* 1992;11(9):449.
- Benacerraf BR: *Ultrasound of Fetal Syndromes*. New York, Churchill Livingstone, 1998.
- Bethune M. Literature review and suggested protocol for managing ultrasound soft markers for Down syndrome: thickened nuchal fold, echogenic bowel, shortened femur, shortened humerus, pyelectasis and absent or hypoplastic nasal bone. *Australas Radiol*. 2007; 51(3):218.
- Biery NJ, Eldadah ZA, Moore CS, Stetten G, Spencer F, Dietz HC: Revised genomic organization of FBN1 and significance for regulated gene expression. *Genomics* 1999; 56: 70-77.
- Boulet S, Althuser M, Nuges F, Schaal J-P, Jouk PS. Prenatal diagnosis of achondroplasia: new specific signs. *Prenat Diagn* 2009; 29: 697-702.
- Breathnach FM, Fleming A, Malone AD. The second trimester genetic sonogram. *Am J Med Genet C Semin Med Genet* 2007; 145C (1): 62.
- Bromley B, Brown DL, Benacerraf BR. Short femur length associated with severe intrauterine growth retardation. *Prenat Diagn* 1993; 13: 449-452.
- Bromley B, Lieberman E, Shipp TD, Benacerraf BR. The genetic sonogram: a method of risk assessment for Down syndrome in the second trimester. *J Ultrasound Med* 2002;21:1087- 1096.
- Bronshtein M, Zimmer EZ, Blazer S. A characteristic cluster of fetal sonographic markers that are predictive of fetal Turner syndrome in early pregnancy. *Am J Obstet Gynecol* 2003; 188(4): 1016- 1020.
- Brumsfield CG, Hauth JC, Cloud GA et al. Sonographic measurement and ratios in fetuses with Down syndrome. *Obstet Gynecol* 1989; 73: 644
- Campbell J, Henderson A, Campbell S. The fetal femur/ foot length ratio: a new parameter to assess dysplastic limb reduction. *Obstet Gynecol* 1988; 72 (2): 181
- Chen CP, Chien SC. Prenatal sonographic features of Turner syndrome. *J Med Ultrasound* 2007;15(4):251-257
- Chitty LS, Griffin DR, Meaney C, Barrett A, Khalil A, Pajkrt E, Cole TJ. New aids for the non-invasive prenatal diagnosis of achondroplasia: dysmorphic features, charts of fetal size and molecular confirmation using cell-free fetal DNA in maternal plasma. *Ultrasound Obstet Gynecol* 2011; 37(3): 283-289.

- Cockwell A, MacKenzie M, Youings S, et al. A cytogenetic and molecular study of a series of 45,X fetuses and their parents. *J Med Genet* 1991;28:151-5.
- Cronk CE. Growth of children with Down's syndrome: birth to age 3 years. *Pediatrics* 1978; 61(4): 564.
- Daentl, D. L., Smith, D. W., Scott, C. I., Hall, B. D., Gooding, C. A. Femoral hypoplasia--unusual facies syndrome. *J. Pediat* 1975; 86: 107-111.
- Doray B, Favre R, Viville B, Langer B, Dreyfus M, Stoll C. Prenatal sonographic diagnosis of skeletal dysplasias. A report of 47 cases. *Ann Genet* 2000;43:163-169.
- Down J. L. H. Observations on an ethnic classification of idiots. *London Hosp Clin Lect Rep* 1866; 3: 259.
- Drooger JC, Troe JW, Borsboom GJ, Hofman A, Mackenbach JP, Moll HA, Snijders RJ, Verhulst FC, Witteman JC, Steegers EA, Joung IM. Ethnic differences in prenatal growth and the association with maternal and fetal characteristics. *Ultrasound Obstet Gynecol* 2005; 26: 115-122.
- FitzSimmons J, Fantel A, Shepard TH. Growth parameters in mid-trimester fetal Turner syndrome. *Early Hum Dev* 1994; 38(2): 121-129.
- Ford CE, Jones KW, Polani PE, et al. A sex-chromosome anomaly in a case of gonadal dysgenesis (Turner's syndrome). *Lancet* 1959;1:711-3.
- Francomano CA. Achondroplasia. In: Pagon RA, Bird TD, Dolan CR, Stephens K, editors. *GeneReviews* [Internet]. Seattle (WA): University of Washington, Seattle; 1993-. 1998 Oct 12 [updated 2006 Jan 09].
- Francomano CA. Hypochondroplasia. Pagon RA, Bird TD, Dolan CR, et al., editors. *GeneReviews* [Internet]. Seattle (WA): University of Washington, Seattle; 1993-1998.
- Goncalves L, Jeanty P. Fetal biometry of skeletal dysplasias: a multicentric study. *J Ultrasound Med* 1994; 13: 977-985.
- Grist TM, Fuller RW, Albiez KL et al. Femur length in ultrasound prediction of trisomy 21 and other chromosome abnormalities. *Radiology* 1990; 174: 837.
- Horton WA, Hall JG, Hecht JT. Achondroplasia. *Lancet* 2007; 370(9582): 162-172.
- Hicks J. 2003. Achondroplasia family of skeletal dysplasias. In: The National Organisation for Rare Disorders, Inc., editors. *NORD guide to rare disorders*. Philadelphia: Lippincott Williams & Wilkins. 144 p.
- Kovac CM, Brown JA, Apodaca CC, Napolitano PG, Pierce B, Patience T, Hume RF, Jr, Calhoun BC. Maternal ethnicity and variation of fetal femur length calculations when screening for Down syndrome. *J Ultrasound Med* 2002; 21: 719-722.
- Kovac CM, Brown JA, Apodaca CC, Napolitano PG, Pierce B, Patience T, Hume RF Jr, Calhoun BC. Maternal ethnicity and variation of fetal femur length calculations when screening for Down syndrome. *J Ultrasound Med* 2002; 21(7):724-5.
- Krakow D, Williams J, Poehl M, Rimoin DL, Platt LD. Use of three-dimensional ultrasound imaging in the diagnosis of prenatal-onset skeletal dysplasias. *Ultrasound Obstet Gynecol* 2003;21:467-72.
- Krakow D, Alanay Y, Rimoin LP, Lin V, Wilcox WR, Lachman RS, Rimoin DL. Evaluation of Prenatal Onset Osteochondrodysplasias by Ultrasonography: A Retrospective and Prospective Analysis. *Am J Med Genet A* 2008; 146A(15): 1917-1924.
- Kurtz AB, Needleman L, Wapner RJ, et al. Usefulness of a short femur in the in utero detection of skeletal dysplasias. *Radiology* 1990; 177:197- 200.

- Kwok, C., Weller, P. A., Guioli, S., Foster, J. W., Mansour, S., Zuffardi, O., Punnett, H. H., Dominguez-Steglich, M. A., Brook, J. D., Young, I. D., Goodfellow, P. N., Schafer, A. J. Mutations in SOX9, the gene responsible for campomelic dysplasia and autosomal sex reversal. *Am J Hum Genet* 1995; 57: 1028-1036.
- LaFollette L, Filly RA, Anderson R et al. Fetal femur length to detect trisomy 21. *J Ultrasound Med* 1989; 8: 657.
- Lees C, Homfray T, Nicolaides KH: Prenatal ultrasound diagnosis of Leroy I cell disease. *Ultrasound Obstet Gynecol* 2001; 18: 275-276.
- Lejeune J, Gautier M, Turpin R. Etude des chromosomes somatiques de neuf enfants mongoliens. *C R Acad Sci* 1959; 248: 1721-1722.
- Leroy JG, Demars RI, Opitz JMI: Cell disease. *Birth Defects Orig Artic Ser* 1969; 5:174-184.
- Lockwood C, Benacerraf B, Krinsky A, et al. A sonographic screening method for Down syndrome. *Am J Obstet Gynecol* 1987; 157:803.
- Macpherson, R. I., Skinner, S. A., Donnenfeld, A. E. Acampomelic campomelic dysplasia. *Pediatr Radiol* 1989; 20: 90-93.
- Modaff P, Horton VK, Pauli RM. Errors in the prenatal diagnosis of children with achondroplasia. *Prenat Diagn* 1996;16: 525-530.
- Nowaczyk, M. J., Huggins, M. J., Fleming, A., Mohide, P. T. Femoral-facial syndrome: prenatal diagnosis and clinical features. Report of three cases. *Am J Med Genet* 2010. 152A: 2029-2033.
- Nyberg DA, Resta RG, Hickok DE et al. Femur length shortening in the detection of Down syndrome: Is prenatal screening feasible? *Am J Obstet Gynecol* 1990; 162: 1247.
- Nyberg DA, McGahan JP, Pretorius DH, Pilu G. Diagnostic imaging of fetal anomalies. Lippincott Williams& Wilkins, Philadelphia 2003.
- O'Brien GD, Queenan JT. Ultrasound fetal femur length in relation to intrauterine growth retardation. Part II. *Am J Obstet Gynecol* 1982; 144: 35-39.
- Orioli IM, Castilla EE, Barbosa-Neto JG. The birth prevalence rates for the skeletal dysplasias. *J Med Genet* 1986;23:328-332.
- Papageorgiou AT, Fratelli N, Leslie K, Bhide A, Thilaganathan B. Outcome of fetuses with antenatally diagnosed short femur. *Ultrasound Obstet Gynecol* 2008; 31(5):507.
- Papp C, Beke A, Mezei G, et al. Prenatal diagnosis of Turner syndrome: report on 69 cases. *J Ultrasound Med* 2006;25:711-7.
- Parilla BV, Leeth EA, Kambich MP, Chilis P, MacGregor SN. Antenatal detection of skeletal dysplasias. *J Ultrasound Med* 2003;22:255-258.
- Perella R, Duerinckx AJ, Grant EG et al. Second-trimester sonographic diagnosis of Down syndrome: Role of femur-length shortening and nuchal fold thickening. *AJR Am J Roentgenol* 1988; 151: 981
- Pierce BT, Hancock EG, Kovac CM, Napolitano PG, Hume RF Jr, Calhoun BC. Influence of gestational age and maternal height on fetal femur length calculations. *Obstet Gynecol* 2001; 97(5 Pt 1):742-6.
- Qin X, Wergedal JE, Rehage M, Tran K, Newton J, Lam P, Baylink DJ, Mohan S. Pregnancy-associated plasma protein-A increases osteoblast proliferation in vitro and bone formation in vivo. *Endocrinology* 2006; 147: 5653-5661.
- Rodriguez, J. I. Vascular anomalies in campomelic syndrome. *Am J Med Genet* 1993; 46: 185-192.

- Ruano R, Molho M, Roume J, Ville Y. Prenatal diagnosis of fetal skeletal dysplasias by combining two-dimensional and three-dimensional ultrasound and intrauterine three-dimensional helical computer tomography. *Ultrasound Obstet Gynecol.* 2004; 24:134-40.
- Russell, A. A syndrome of intra-uterine-dwarfism recognizable at birth with cranio-facial dysostosis, disproportionate short arms, and other anomalies (5 examples). *Proc Roy Soc Med* 1954; 47: 1040-1044.
- Shipp TD, Bromley B, Mascola M, Benacerraf B. Variation in fetal femur length with respect to maternal race. *J Ultrasound Med* 2001; 20: 141-144. 11.
- Silver, H. K., Kiyasu, W., George, J., Deamer, W. C. Syndrome of congenital hemihypertrophy, shortness of stature, and elevated urinary gonadotropins. *Pediatrics* 1953; 12: 368-376.
- Spranger J. Bone dysplasia families. *Pathol Immunopathol Res.* 1988;7:76-80.
- Superti-Furga A, Unger S. Nosology and classification of genetic skeletal disorders: 2006 revision. *Am J Med Genet A* 2007; 143(1):1-18.
- Sybert VP, McCauley E. Turner's syndrome. *N Engl J Med* 2004; 351:1227.
- Todros T, Plazzotta C, Pastorin L. Body proportionality of the small-for-date fetus: is it related to aetiological factors? *Early Hum Dev* 1996; 45:1- 9.
- Todros T, Massarenti I, Gaglioti P, Biolcati M, Botta G, De Felice C. Fetal short femur length in the second trimester and the outcome of pregnancy. *BJOG* 2004; 111: 83-85.
- Turner HH. A syndrome of infantilism, congenital webbed neck, and cubitus valgus. *Endocrinology* 1938; 23:566-74.
- Vergani P, Locatelli A, Piccoli MG, et al. Critical reappraisal of the utility of sonographic fetal femur length in the prediction of trisomy 21. *Prenat Diagn* 2000;20:210- 214.
- Wenger DA, et al: Lysosomal storage disorders:diagnostic dilemmas and prospects for therapy. *Genet Med* 2002; 4: 412-419
- Weisz B, David AL, Chitty L, Peebles D, Pandya P, Patel P, Rodeck CH. Association of isolated short femur in the midtrimester fetus with perinatal outcome. *Ultrasound Obstet Gynecol* 2008; 31: 512-516.
- Wiedemann HR, Glatzl J. Follow-up of Ullrich's original patient with "Ullrich-Turner" syndrome. *Am J Med Genet* 1991;41:134-6.
- Wynne-Davies R, Walsh WK, Gormley J. 1981. Achondroplasia and hypochondroplasia. Clinical variation and spinal stenosis. *J Bone Joint Surg Br* 63B:508-515.
- Woo JS, Wan CW, Fang A, Au KL, Tang LC, Ghosh A. Is fetal femur length a better indicator of gestational age in the growth-retarded fetus as compared with biparietal diameter? *J Ultrasound Med* 1985; 4: 139-142.
- Yuksel A, Kayserili H, Gungor F. Short femurs detected at 25 and 31 weeks of gestation diagnosed as Leroy I-cell Disease in the Postnatal Period: A Report of Two Cases. *Fetal Diagn Ther* 2007; 22: 198-202.
- Zalel Y, Lehavi O, Schiff E, et al. Shortened fetal long bones: a possible in utero manifestation of placental function. *Prenat Diagn* 2002; 22:553- 557.



Prenatal Diagnosis - Morphology Scan and Invasive Methods

Edited by Dr. Richard Choy

ISBN 978-953-51-0614-2

Hard cover, 210 pages

Publisher InTech

Published online 29, June, 2012

Published in print edition June, 2012

This book provides detailed and comprehensive coverage on various aspects of prenatal diagnosis-with particular emphasis on sonographic and molecular diagnostic issues. It features sections dedicated to fundamentals of clinical, ultrasound and genetics diagnosis of human diseases, as well as current and future health strategies related to prenatal diagnosis. This book highlights the importance of utilizing fetal ultrasound/clinical/genetics knowledge to promote and achieve optimal health in fetal medicine. It will be a very useful resource to practitioners and scientists in fetal medicine.

How to reference

In order to correctly reference this scholarly work, feel free to copy and paste the following:

Funda Gungor Ugurlucan, Hülya Kayserili and Atıl Yüksel (2012). Prenatal Evaluation of Fetuses Presenting with Short Femurs, Prenatal Diagnosis - Morphology Scan and Invasive Methods, Dr. Richard Choy (Ed.), ISBN: 978-953-51-0614-2, InTech, Available from: <http://www.intechopen.com/books/prenatal-diagnosis-morphology-scan-and-invasive-methods/prenatal-evaluation-of-fetuses-presenting-with-short-femurs>

INTech
open science | open minds

InTech Europe

University Campus STeP Ri
Slavka Krautzeka 83/A
51000 Rijeka, Croatia
Phone: +385 (51) 770 447
Fax: +385 (51) 686 166
www.intechopen.com

InTech China

Unit 405, Office Block, Hotel Equatorial Shanghai
No.65, Yan An Road (West), Shanghai, 200040, China
中国上海市延安西路65号上海国际贵都大饭店办公楼405单元
Phone: +86-21-62489820
Fax: +86-21-62489821

© 2012 The Author(s). Licensee IntechOpen. This is an open access article distributed under the terms of the [Creative Commons Attribution 3.0 License](#), which permits unrestricted use, distribution, and reproduction in any medium, provided the original work is properly cited.

IntechOpen

IntechOpen