

# We are IntechOpen, the world's leading publisher of Open Access books Built by scientists, for scientists

6,900

Open access books available

186,000

International authors and editors

200M

Downloads

Our authors are among the

154

Countries delivered to

TOP 1%

most cited scientists

12.2%

Contributors from top 500 universities



WEB OF SCIENCE™

Selection of our books indexed in the Book Citation Index  
in Web of Science™ Core Collection (BKCI)

Interested in publishing with us?  
Contact [book.department@intechopen.com](mailto:book.department@intechopen.com)

Numbers displayed above are based on latest data collected.  
For more information visit [www.intechopen.com](http://www.intechopen.com)



# Role of Flexible-Bronchoscopy in Pulmonary and Critical Care Practice

Gilda Diaz-Fuentes and Sindhaghatta K. Venkatram  
*Division of Pulmonary and Critical Care Medicine,  
 Bronx Lebanon Hospital Center, Bronx, New York  
 USA*

## 1. Introduction

The introduction of the flexible bronchoscope by Dr. Ikeda in 1968 revolutionized bronchoscopy around the world. Initially, bronchoscopy was performed by surgical specialists with a rigid scope only in highly specialized centers, and the main indication was for therapeutic purposes. In the 1970s, flexible fiberoptic bronchoscopy (FFB) was learned by pulmonologists and surgical specialists and proved itself as a safe and useful technique for diagnostic and therapeutic purposes. The results have been a rapid proliferation of FFB inside and outside of the academic institutions.

In the armamentarium of the pulmonary physician, FFB assumes a central position that is somewhere between the noninvasive diagnostic maneuvers such as physical examination, laboratory study, pulmonary function testing and radiologic diagnostics on one side and invasive surgical procedures such as mediastinoscopy and diagnostic thoracotomy on the other side.

A recent trend has been the emergence of “interventional bronchoscopy” and the “interventional bronchoscopist”. These phrases denote a two-tier system in which one group of bronchoscopists perform “routine bronchoscopy” and the other performs special bronchoscopic procedures. Disease processes encompassed within this discipline include complex airway management problems, benign and malignant central airway obstruction, pleural diseases, and pulmonary vascular procedures. Diagnostic and therapeutic procedures pertaining to these areas include, but are not limited to, rigid bronchoscopy, transbronchial needle aspiration (TBNA), auto fluorescence bronchoscopy, endobronchial ultrasound (EBUS), transthoracic needle aspiration (TTNA) and biopsy, laser bronchoscopy, endobronchial electrocautery, argon-plasma coagulation, cryotherapy, airway stent insertion, balloon bronchoplasty and dilatation techniques, endobronchial radiation, photodynamic therapy, percutaneous dilatational tracheotomy, transtracheal oxygen catheter insertion, medical thoracoscopy, and imaging-guided thoracic interventions. (Anders et al. 1988)

Considering the prominence of FFB in the procedural armamentarium of pulmonary physicians (among other specialties) and the new developments of interventional bronchoscopy, it is important for the non-interventional pulmonologist and physician in pulmonary training to have a clear understanding of the role of FFB.

The objective of this review is to describe the place of non-interventional FFB in the practice of modern pulmonary and critical care medicine, to review the indications, contraindications and limitations of the procedure and to discuss the role of FFB in modern intensive care units (ICUs). The versatility of the flexible bronchoscope, combined with its portability, allows one to perform the technique at the bedside, and this is of major importance in the unstable patient, who is often unable to be transported safely to the bronchoscopy suite.

## **2. Facilities, personnel, pre-procedure investigation and monitoring**

In order to perform a FFB, a well-equipped facility, trained personnel, pre-procedure evaluation, and monitoring is highly recommended. Bronchoscopies can be performed in a bronchoscopy suite, operating room, at the bedside and in the outpatient setting. The planned bronchoscopic procedures, the availability of equipment and ancillary personnel and resources will dictate the best and safe place for the FFB.

Prior to the procedure, the patient's history must be taken and a thorough physical examination must be given. The physician must obtain information on previous therapies and current performance status. Laboratory tests (e.g. complete blood count, coagulation profile and renal function) are usually obtained despite routine preoperative coagulation screening not being recommended in patients with no risk factors for complications. (Kozak & Brath, 1994)

A minimum requirement is the availability of cardiorespiratory monitoring and oxygen and resuscitation equipment. The bronchoscopist and nursing staff should have appropriate training for the procedure to be performed. Conscious sedation can be administered by a skilled bronchoscopist or anesthesiologist. If procedures are performed under general anesthesia, the presence of an anesthesiologist and specialist nurse should be added. (European Respiratory Society/American Thoracic Society [ERS/ATS], 2002; Becker et al. 1991)

## **3. Fiberoptic bronchoscopic techniques**

Flexible bronchoscopy is preferably performed via the transnasal approach by many bronchoscopists after appropriate topical anesthesia and conscious sedation. A complete inspection of all segments of both lungs is carried out to exclude significant endobronchial abnormalities. The following section will describe the most common bronchoscopic techniques used by the non-interventional pulmonologist.

### **Bronchial washings**

Bronchial washings are the secretions aspirated back through the bronchoscope channel after instillation of saline into a major airway. Secretions obtained by this method do not represent material from the bronchiolar or alveolar level and in non-intubated patients they may be contaminated by secretions from the upper airway.

The main use of bronchial washings is for diagnosing pneumonia caused by strictly pathogenic organisms, such as *Mycobacterium tuberculosis* and endemic systemic fungi. In addition, bronchial washing can be used to collect specimens for cytology in suspected malignancy.

**Protected-specimen brushing (PSB)**

Protected-specimen brushing is a telescoping plugged catheter passed through the suction channel of the bronchoscope. Once beyond the tip of the scope, the internal sheath is extended, its gelatin plug expelled, and the sterile brush is dipped into either the visible airway secretions or passed more distally into the involved pulmonary segment. The brush is retrieved by reversal of the process, and then cut into a sterile container with 1mL of buffer or broth. In the microbiology laboratory, the sample is quantitatively cultured. Most investigators use the cutoff of  $10^3$  cfu/ml for differentiation of infection from contamination. The main value of PSB is for the diagnosis of bacterial pneumonia; therefore, only quantitative culture and possibly Gram stain of the secretions obtained by the brushing justify its use.

**Bronchial brushings**

The bronchial brush catheter is inserted in a similar way as the PSB. The cytology brush is stiffer than the PSB, so it makes it easier to obtain cellular material from the airway wall. The main indication for bronchial brushes is for the cytologic diagnosis of malignancies or viral inclusion bodies in airway cells. There is a slight increase in mucosal bleeding.

**Bronchoalveolar lavage (BAL)**

In comparison to bronchial washing, BAL samples a much larger airway and alveolar area. It is estimated that approximately 1 million alveoli (1% of the lung surface) are sampled, with approximately 1 ml of actual lung secretions returned in the total lavage fluid. Bronchoalveolar lavage requires careful wedging of the tip of the bronchoscope into the desired airway lumen, isolating that airway from the rest of the central airways. Wedging is defined as the position where the scope cannot be advanced while the distal lumen is still visible. Then, normal saline in 30 to 60 ml aliquots are instilled two or three times and after 2 respiratory cycles the fluid is intermittently suctioned out to a trap with low suction. The first 20 ml which are secretions found in the subsegmental bronchus is usually discarded as this is not representative of alveolar lavage. The returned volume varies with the amount instilled but is generally 10 to 100 ml. The number of lavages needed is based on return and the number of tests ordered. In our institution the bronchoscopy nurse informs us of the adequacy of the sample.

Bronchoalveolar lavage has been proven to be very safe and can be done without fluoroscopy. The diagnostic threshold for BAL fluid has been reported to be  $10^4$  cfu/ml for quantitative and  $10^5$  for non-quantitative cultures. Bronchoalveolar lavage is the mainstay of bronchoscopic diagnosis in the immunosuppressed patient when looking for an infectious process. In addition, BAL has diagnostic utility in eosinophilic pneumonias, pulmonary alveolar proteinosis, and pulmonary malignancies especially lymphangitic carcinomatosis. (Baughman, 2007)

**Transbronchial biopsy (TBBx)**

This technique is performed wedging the scope in the segmental bronchus of interest, and then passing the biopsy forceps through the working channel of the scope. Fluoroscopy can assist to visualize the forceps entering the pulmonary sub segment. The biopsy forceps is advanced to the periphery of the diseased region until resistance is met. Placement of the biopsy forceps near, but not at the lung surface minimizes the risk of pneumothorax. Subsequently, the forceps is withdrawn approximately 1 cm, and the jaws are opened and

advanced slightly to obtain the sample of the lung. The forceps is then advanced close to the area where resistance was encountered, and the jaws are closed. In case the patient reports pain at this point, the forceps is opened and withdrawn; only the visceral pleura is pain-sensitive.

The biopsy forceps is firmly retracted to obtain the sample which is placed in formalin and sent for histopathologic evaluation.

Ideally, 4 to 6 transbronchial biopsy specimens should be obtained, with at least 1 sample containing full-thickness bronchial mucosa and some alveolar parenchyma. The number of biopsy specimens required for optimal diagnostic yield has been reported to be 4 to 10; BTS guidelines recommend 4–6 samples in diffuse lung disease and 7–8 samples in focal lung disease. (British Thoracic Society Bronchoscopy [BTS], 2001)

We routinely disconnect the patient from the respirator for a couple of seconds during the initial part of forceps withdrawal. If there is any bleeding the scope is wedged to allow for clot formation. Other options include instillation of cold saline or topical epinephrine.

Transbronchial biopsy specimens are examined by histological techniques to exclude infections, malignancies or other disorders. Specimens can also be placed in sterile saline and cultured. TBBx have been shown to increase the diagnosis of PCP in AIDS patients by 15 %. The most important role for TBBx is probably the documentation of noninfectious etiologies. (Prakash et al., 1991; American Thoracic Society [ATS], 1987)

A comparison of the yield of transbronchial biopsy specimen between standard-sized forceps and large forceps found no significant differences in the size of the biopsies or in the amount of alveolar tissue collected. (Wang et al., 1980; Loube et al., 1993)

The tissue samples obtained by means of TBBx forceps are small, approximately 3 mm in size. Therefore, this procedure is not useful in diagnosing heterogeneous lung diseases such as idiopathic lung diseases.

### **Transbronchial needle aspiration (TBNA)**

Transbronchial needle aspiration through the flexible bronchoscope was developed in the early 1980s for the diagnosis and staging of lung cancer. The most important indication for transbronchial needle aspiration is the mediastinal staging of lung cancer. The lymph node stations as defined by the TNM system are easily accessible with TBNA, which is cost-effective and reduces the need for exploratory surgery. TBNA have been incorporated in the training of basic bronchoscopic skills. For a detailed review, the reader is directed to some excellent reviews on the topic. (ERS/ATS, 2002; Dasgupta & Mehta, 1999)

To obtain a specimen, the needle assembly is introduced through the working channel of the bronchoscope with the needle retracted within the metal hub of the catheter. The scope is kept as straight as possible, with its distal tip in the neutral position. These precautions are necessary to prevent damaging the working channel of the scope. Once the metal hub is visible at the distal end of the scope, the needle is advanced and locked in place. The catheter is retracted until only the tip of the needle is visible at the end of the scope. The scope is advanced to the target, and the tip of the needle is anchored into the intercartilaginous space. At this stage, the goal is to penetrate the tracheobronchial wall at an angle as close to perpendicular as possible.



For peripheral lesions, TBNA should be performed with fluoroscopic guidance.

The diagnostic yield of transbronchial needle aspiration for staging of lung cancer varies between 15- 83%, with a positive predictive values of 90-100%. In evaluating peripheral lung nodules, TBNA increases the diagnostic yield of bronchoscopy by 20-25% by facilitating the sampling of lesions that are inaccessible with the forceps or brush. Transbronchial needle aspiration has also been shown to improve the yield in the evaluation of submucosal disease, sarcoidosis, and mediastinal lymphadenopathy in acquired immune deficiency syndrome (AIDS) patients. (ERS/ATS, 2002; Dasgupta &Mehta, 1999; Wang et al., 1983; Ceron et al., 2007)

In the last decades we have seen the introduction of several bronchoscopic diagnostic techniques which include, among others, endobronchial ultrasound, auto fluorescence bronchoscopy and electromagnetic navigation. The aim of these modalities is to increase the diagnostic yield of bronchoscopy and minimize the need for more invasive procedures.

However, such specialized innovations are limited to specialized centers and in general do not reflect the application of this technique in routine clinical practice. In recent years, TBNA has been incorporated as a routine in the bronchoscopy suite and is part of the routine training of pulmonary fellows.

The use of endobronchial ultrasound –transbronchial needle aspiration (EBUS-TBNA) is a relatively new, minimally invasive and an emerging diagnostic modality that has proven utility in the evaluation of patients with lung cancer for the assessment of mediastinal and hilar lymph nodes, and diagnosis of lung and mediastinal tumors. (Herth et al., 2006)

#### **4. Indications for flexible bronchoscopy**

The traditional and newer indications for diagnostic and therapeutic bronchoscopies permit greater latitude in the application of the procedure. Several reports including the North American survey on bronchoscopy reveals that the most common indications for bronchoscopy are the evaluation of suspicious lesions (nodules and masses), hemoptysis, pneumonia and infections, diffuse pulmonary process, and therapeutic. (Prakash et al., 1991; ATS,1987; Alamoudi et al., 2000) A study looking at 124 consecutive bronchoscopies, showed that suspicion of pulmonary tuberculosis (31%), lung mass (19%) and hemoptysis (18%) were the most common indications for the procedure. (Alamoudi et al., 2000) Although the availability of flexible bronchoscopy has been a major advance in adult pulmonary medicine, its role in pediatrics has remained less well defined. The most common indications for the procedure in the pediatric literature included stridor, abnormal chest roentgenogram and airway evaluation. (Brown et al., 1983; Nicolai, 2001)

It is not uncommon to perform diagnostic and therapeutic bronchoscopies simultaneously. In one study of 198 bronchoscopies performed in critical care units, 47% were done for therapeutic reasons, 44% for diagnostic reasons, and 9% for both. (Bellomo et al., 1992)

The major indications for diagnostic bronchoscopy are listed in Table 1. The overall yield of diagnostic bronchoscopy depends on the indication and the techniques used during the procedure and vary from 45% to 80%. The most common indication for diagnostic FFB is suspected malignancy, infection or tuberculosis. (Prakash et al., 1991; Joos et al., 2006)

Mass/nodule/ suspicious lesion/cancer
Hemoptysis
Pneumonia/infection
Diffuse/interstitial disease in a non-immunocompromised patient
Diffuse infiltrative pulmonary disorders in immunocompromised patients
Unexplained cough or wheezing
Persistent purulent sputum of unknown etiology
Trachea/ stridor/ vocal cord paralysis/hoarseness
Superior vena cava syndrome
Extrapulmonary symptoms with frequent pulmonary and bronchial involvement
Thermal/chemical injury
Suspected tracheo-esophageal fistula
Abnormal radiographic findings
Evaluation of abnormal pulmonary function testing like central airway stenosis
To evaluate complications of artificial airway
Tracheobronchial obstruction
Progressive or non- resolving pneumonias.
Complications in lung transplant recipients
<b>Specific Indication in the ICU</b>
Ventilator associated Pneumonia
Endotracheal tube placement confirmation
Airway trauma, Bronchial stump dehiscence
Smoke and Inhalational injury
Double lumen intubation for independent lung ventilation

Table 1. Indications for Diagnostic Bronchoscopy

Indications for therapeutic bronchoscopy are listed in Table 2. Often, bronchoscopy is done for diagnostic and therapeutic purposes- for example patients with airway obstruction with placement of stent, or hemoptysis. No indication is absolutely restricted to a specific location; with the current portability of the bronchoscope and the advances in monitoring and bedside care, many hospitals provide ventilator care or advanced care to patients in areas other than the intensive care unit.

Difficult intubation of airway and assessment of tube placement
Retained secretions and atelectasis
Foreign body in the tracheobronchial tree
Atelectasis/lobar collapse
Debridement of necrotic tracheobronchial mucosa
Dilatation of strictures and stenosis
Pneumothorax (fibrin glue therapy)
Delivery of brachytherapy
Percutaneous tracheostomy
Drainage of lung abscess/bronchogenic cysts
Thoracic trauma
Laser bronchoscopy
Photodynamic therapy
Electrocautery / Cryotherapy

Table 2. Indications for Therapeutic Bronchoscopy

## 4.1 Most common indications for bronchoscopy

### 4.1.1 Lung cancer

The flexible bronchoscope has become the main diagnostic tool in the evaluation of patients suspected of lung cancer, with more than 70% of lung carcinomas being approachable via bronchoscopy. Additionally, bronchoscopy plays an important role in the disease staging and an extended role in delivering therapeutic modalities. Regarding staging of the malignancy, bronchoscopy may help to determine the extension of the tumor. Bronchoscopic findings of vocal cord paralysis, tumor to the level of the right tracheobronchial junction or within 2 cm of the left tracheobronchial junction, and carinal or tracheal involvement are evidence of advanced stages of the malignancy.

An advantage of flexible bronchoscopy is that it is safe, well tolerated and readily available in most places. The flexibility of the bronchoscope allows the inspection of most of the fourth order and often up to sixth order bronchi and the direct assessment of the color and vascularity of the mucosa.

Routine bronchoscopic techniques include bronchial washings and lavage, brushings, and transbronchial biopsies. These may be augmented by the use of needle aspiration with or without the use of endobronchial ultrasound. It is still unclear if the combination of cytologic and histologic procedures provides the best diagnostic yield for lung cancer, but probably depends on the local expertise. (Alamoudi et al., 2000; Garg et al., 2007)

The diagnostic yield of bronchoscopy for malignancy depends on the location and the size of the lesion as well as the experience of the bronchoscopist.

Central endobronchial lesions carry the highest diagnostic yield of more than >90%, whereas small peripheral lesions have lower yield and usually require additional time and techniques. In visible, but intramural rather than endobronchial tumors, the diagnostic yield decreases to around 55% and is reduced further when the tumor lies beyond the bronchoscopist's vision. (Mazzone et al., 2002; El-Bayoumi & Silvestri, 2008; Gasparini et al., 1995)

The presentation of central tumors varies from an exophytic lesion, with partial or total occlusion of the bronchial lumen, to peribronchial tumors with extrinsic compression of the airway, or with submucosal infiltration of tumor. Peribronchial tumors or lesions with submucosal infiltration produce subtle changes in the mucosa that includes changes in mucosal color and vascularity, loss of bronchial markings, and nodularity of the mucosal surface. The yield of endobronchial biopsies is highest for exophytic lesions, with a diagnostic yield of approximately 90%. Central lesions are best approached with a combination of bronchial washes and brushings, and at least three to five endobronchial biopsies.

The addition of transbronchial needle aspiration may improve the yield and should be considered in submucosal lesions and peribronchial disease and extrinsic compression. The TBNA needle should be inserted into the submucosal plane at an oblique angle, and in patients with peribronchial disease and extrinsic compression, the needle should be passed through the bronchial wall into the lesion. Occasionally, the presence of crush artifact or surface necrosis will give a low yield of endobronchial biopsies for this kind of lesion. (Schreiber & McCrery, 2003; Dasgupta & Mehta, 1999) In general, the diagnostic yield is increased with the use of multiple bronchoscopic techniques.



Peripheral lesions are usually approached with a combination of bronchoscopic techniques like bronchial wash, brushes, biopsies and needle aspiration. The main determinants for the bronchoscopic diagnostic yield for peripheral lesions include:

- the size of the lesion: the diagnostic yield of bronchoscopy for lesions smaller than 3 cm varies from 14% to 50% compared with a yield of 46% to 80% for lesions larger than 3 cm.
- the distance of the lesion from the hilum and the relationship between the lesion and bronchus; a chest computed tomogram showing the presence of a bronchus sign predicts a higher yield of bronchoscopy for peripheral lung lesions.

The use of fluoroscopy increases the diagnostic yield from bronchoscopy in focal lung lesions. Fluoroscopy carries the limitation of being time consuming, requires some experience, and is not readily available in all centers. A lesion that is too small and not visible by fluoroscopy during the bronchoscopy poses a diagnostic challenge and often times require further surgical biopsy procedures. Endobronchial ultrasound and electromagnetic navigation are exciting new technologies that could help to increase the diagnostic yield in those cases. (Gasparini, 1997; Cortese & McDougall 1979; Yung, 2003; Liam et al., 2007)

The diagnostic yield of the TBBx can be significantly increased up to 73% by combining bronchoscopy with computed tomogram (CT) guidance in a dedicated low-dose protocol. The sensitivity of transbronchial biopsy for a solitary pulmonary nodule with multislice CT guidance has been reported to be 62.2% compared with 52.6% with fluoroscopic guidance. (Tsushima et al., 2006; Hautmann et al., 2010) The diagnostic yield of bronchoalveolar lavage alone for primary lung cancer is in the lower 30% for peripheral lung lesions. (De Gracia et al. 1993; Fabin et al., 1975; Fedullo & Ettensohn, 1985; Semenzato et al., 1990)

In a study of 162 patients with malignant lung infiltrates the BAL showed increased sensitivity in cases of bronchoalveolar cell carcinoma (93%) and lymphangitic carcinomatosis (83%). (Rennard, 1990)

The objective of staging for non-small cell lung cancer in the absence of distant metastases is the evaluation of mediastinal lymph node involvement. This is decisive to determine the prognosis and treatment plan for the patient. Nonsurgical staging includes minimally invasive needle biopsy techniques such as transbronchial or transthoracic needle aspiration and esophageal or endobronchial endoscopic ultrasound-guided fine-needle aspiration.

The reported diagnostic yield for EBUS-TBNA of lymph nodes is as high as 93% with a sensitivity, specificity, and accuracy of 94%, 100%, and 94%, respectively; positive predictive value of 100% and negative predictive value of 11%. (Herth et al., 2006)

A detailed discussion of EBUS is beyond the scope of this review, but the bronchoscopist must be aware that for those patients with known or suspected lung cancer, EBUS alone or in combination with EUS-FNA could likely replace more invasive and expensive surgical techniques. (Spiro & Porter, 2002; Gomez & Silvestri, 2009)

The use of Rapid On-site Evaluation (ROSE) has been shown to reduce the incidence of inadequate specimens which is an important cause of non-diagnostic TBNA aspirates. Several studies showed an increase of 15 to 25% in the diagnostic yield for malignancy and a

decrease in the number of inadequate specimens. The overall reported diagnostic yield when ROSE is used is up to 80% when compared with a 50% yield when specimens are processed in the usual manner. The concordance between the preliminary diagnosis made in the bronchoscopy suite and the final diagnosis after subsequent review of material in the cytopathology laboratory was 87%, suggesting that ROSE of needle aspirate is fairly accurate but not perfect. Disadvantage of ROSE is the requirement of an expert and readily available cytopathologist in the bronchoscopy suite which involves extra time and effort. (Baram et al., 2005; Davenport, 1990; Uchida et al., 2006)

#### **4.1.2 Pulmonary infections**

The clinical-radiological and routine laboratory features of pulmonary infections often offer clues to the microbial cause of the infection, but the specific etiologic diagnosis usually requires the assistance of the microbiology laboratory.

Fiberoptic bronchoscopy is frequently used as part of the diagnostic investigation of suspected pulmonary infections in those cases where noninvasive tests have been non-diagnostic. The various methods used are bronchoscopic lavage, brushing, biopsies and occasionally TBNA which frequently are performed together to identify potential pathogens. Quantitative cultures of the specimen collected are performed to differentiate colonization from real pathogens. Rapid diagnosis is important, especially in immunocompromised patients.

In the past, bronchoscopy has been used to obtain specimens for the identification of pathogenic organisms, such as tuberculosis, in otherwise smear-negative cases, but its role in the diagnosis of lung infections in general has been limited. As a consequence of the rapid increase in the population of immunocompromised patients due to organ transplantation, human immunodeficiency virus (HIV) infection and increased use of chemotherapeutic agents, the last decade has seen an increase in the number of patients with life-threatening pneumonia or resistant microorganisms.

#### **Community acquired pneumonia**

The role of bronchoscopy for community acquired pneumonia (CAP) is not clearly defined. Bronchoscopy help to retrieve specimens from the lower airway in those patients not able to produce sputum and, in addition, can identify endobronchial obstructions and other processes mimicking pneumonia. (Gross et al., 1991; Lynch & Sitrin, 1993; Wintrobauer, 1995)

In community acquired pneumonia the causative organism is not identified in more than 40% of cases despite an aggressive search. The use of early bronchoscopy, especially prior to the initiation of antibiotics, has been shown to increase the identification of a specific microorganism. One study reported a yield of 54% to 85% with PSB for potential pathogens. (Jimenez et al., 1993) The use of BAL may be useful in the evaluation of pneumonia with quantitative cultures of specimens correlating well with PSB results. However, a more accurate diagnosis may not significantly change antibiotic or clinical management.

Patients who present with severe pneumonia or who fail to improve or worsen during their hospitalization despite treatment with antibiotics may require further testing with bronchoscopy. Delayed resolution of pneumonia or suspicion of neoplasm should prompt the physician to perform a FFB. (Jimenez et al., 1993; Bates et al., 1992; Torres et al., 1991)

### **Progressive or non-resolving pneumonias**

Majority of patients with CAP recover after appropriate antimicrobial therapy with about 10-15% of cases having no clinical improvement and they are categorized as non-responding or progressive pneumonia. (Arancibia et al., 2000)

Progressive pneumonias are defined as actual clinical deterioration, with acute respiratory failure requiring ventilatory support and/or septic shock, usually occurring within the first 72 h of hospital admission. Non-resolving pneumonias refer to absence of clinical stability after 3 days of antibiotics. (Mandell et al., 2007)

Causes include host factors, inappropriate microbiological therapy (uncommon pathogens) and non infective causes mimicking pneumonia. Non infective differential diagnosis includes acute eosinophilic pneumonia, acute cryptogenic organizing pneumonia, acute sarcoidosis, acute hypersensitivity pneumonitis, pulmonary alveolar proteinosis and others. (Gross et al., 1991; Lynch & Sitrin, 1993; Wintbauer, 1995) Bronchoscopy can establish the diagnosis in many of the infections as well as in non-infectious etiologies like acute eosinophilic pneumonia, diffuse alveolar hemorrhage or damage, pulmonary alveolar proteinosis, lipoid pneumonia, eosinophilic granulomas, and rarely rapidly progressing neoplasms. The use of TBBx can add additional diagnosis in selected patients. (Bulpa et al., 2003)

### **Ventilator associated pneumonia**

Ventilator associated pneumonia (VAP) is a common health care associated infection, that develops in patients on mechanical ventilation and complicates the hospital course in 8-28% of patients on mechanical ventilation. (Haley et al., 1981; Pennington, 1990; Chastre & Fagon, 1994; Centers for Disease Control and Prevention [CDC] MMWR 2000; National Nosocomial Infections Surveillance [NNIS] System, 1999)

The crude mortality ranges from 30 to 50%; however attributable mortality ranges widely from 5.8% to 18.8%. (Esperatti et al., 2010; Nguile-Makao et al., 2010; Muscedere et al., 2008)

Early and appropriate antimicrobial therapy has been advocated to decrease complication rates and mortality. (Celis et al., 1988; Luna et al., 1997; Kollef & Ward 1998)

Chest radiographic abnormalities are common in ventilated patients and some of the differential diagnosis includes atelectasis, pneumonia, drug reactions, and pulmonary embolism. Diagnosis of VAP remains a diagnostic challenge with a potential for overuse of antibiotics. To aid in decision making, Pugin et al. suggested the clinical pulmonary infection score (CPIS); a score higher than 6 having a high predictive value for the diagnosis of VAP. (Pugin et al., 1991; Alvarez-Lerma, 1996; Fabregas et al., 1999; Fischer et al., 1998; Flanagan et al., 2000; Singh et al., 2000) A subsequent trial comparing inter observer variability of CPIS score for the diagnosis of VAP, revealed a sensitivity of 83% and specificity of 17% with a area under receiver operating characteristic (AROC) of 0.55, when CPIS score was compared with qualitative BAL fluid cultures. (Schurink et al., 2004)

Fagon et al. reported reduced 14-day mortality with the use of a bronchoscopic bacteriologic strategy compared with a clinical strategy alone. (Fagon et al., 2000)

The use of TBBx could increase the diagnostic yield especially in patients with unexplained pulmonary infiltrates. Bronchoscopy can aid to distinguish between colonization and infection in those patients. (Pechkam & Elliott, 2002)

### **Aspiration pneumonia**

Aspiration of stomach contents is a major cause of morbidity and mortality in adults and is a risk factor for acute respiratory distress syndrome. Bronchoscopy is indicated in patients with chemical pneumonia and when aspiration of a foreign body or food material is suspected. Aspirated material is frequently liquid in nature and disperses rapidly. Hence, routine FFB with lavage is not indicated. However, in the event that the aspirate is predominantly particulate in nature with radiographic evidence of lobar collapse or major atelectasis, therapeutic bronchoscopy is helpful.

Bronchoscopy has an important role in diagnosing airway injury and confirming tracheobronchial damage secondary to orally aspirated caustic material. Bronchoscopy may be helpful in guiding antibiotic therapy. This procedure is useful when ruling out the presence of an obstructing neoplasm in anaerobic bacterial pneumonia with lung abscess; however, bronchoscopy is not useful in the treatment of community-acquired aspiration pneumonia. (Kollef et al., 1995; Raghavendran et al., 2011)

### **Tuberculosis**

Tuberculosis (TB) remains a threat with the increased traveling, globalization, HIV epidemic, and immigration. Those patients suspected to have TB and who have no sputum or sputum smear negative for acid fast bacilli seem to benefit the most from bronchoscopy.

Comparison of various bronchoscopic techniques showed that the yield of bronchoalveolar lavage for tuberculosis is superior to bronchial washings. Transbronchial biopsy and bronchial brushing cultures provided little additional diagnostic yield. Bronchoscopy can give immediate diagnosis when there is a positive smear from BAL fluid or caseating granulomas in the TBBx. Occasionally an alternative diagnosis can be found. (Venkateshiah & Mehta, 2003; Kobashi et al., 2007)

### **Fungal infections**

Fungal infections contribute to significant morbidity and mortality in immunocompromised patients and bronchoscopy is useful in the diagnosis of these infections. PJP is a common infection in the immunocompromised and the diagnostic yield for BAL is up to 98 %. (Huang et al., 2006)

*Aspergillus* is a colonizer of the tracheobronchial tree and tissue diagnosis is necessary for the diagnosis. BAL fluid may suggest the development of invasive disease (Cahill et al., 1997), but does not establish the diagnosis. Newer techniques like BAL galactomannan levels which have a good sensitivity and specificity for the detection of invasive disease could be promising for the diagnosis (Meersseman et al., 2008; Hsu et al., 2010; Maertens et al., 2009); however, false-positive results are seen. (Digby et al., 2003)

*Candida* is a frequent colonizer and their presence in BAL fluid may represent colonization rather than infection in the immunocompetent host. (el-Ebiary et al., 1997)

In patients with non-resolving pneumonias in endemic areas, morphological and cytological analysis may aid in therapy of endemic mycoses like histoplasmosis, blastomycosis, coccidioidomycosis and paracoccidioidomycosis; however culture is diagnostic.

### **4.1.3 Diffuse lung diseases**

#### **Interstitial lung diseases**

The interstitial lung diseases (ILDs), are a diverse group of pulmonary disorders classified together because of similar clinical, radiological, physiologic, or pathologic characteristics. The patient with suspected ILD presents a diagnostic challenge to physicians.

The role of bronchoscopy for the diagnosis of ILD's is limited due to the small size of the biopsies. Several studies have shown that the accuracy of TBBx for the diagnosis of ILD's is only 7 to 37% in immunocompetent patients. (Wall et al., 1981)

The role of FFB with BAL and TBBX in patients with diffuse lung disease is limited to the exclusion of infections, malignancy, sarcoidosis, eosinophilic pneumonias and occasionally cryptogenic organizing pneumonia. Analysis of BAL fluid can show certain cellular profiles that suggest specific disease processes; for example, sarcoidosis has lymphocytosis characterized by an increase in T-helper cells and a high CD4/CD8 ratio; hypersensitivity pneumonitis has T lymphocytosis, with predominance of the suppressor subset CD8; and idiopathic pulmonary fibrosis is characterized by increases in neutrophils and eosinophils. Unfortunately, the BAL findings have limited clinical utility for the diagnosis, prognosis or as a guide to therapy in patients with ILD's. Using TBBx to diagnose idiopathic ILD's is not recommended. Surgical lung biopsy remains the investigation with the greatest overall diagnostic sensitivity for ILD's. (ATS/ERS, 2002; Talmadge, 2005)

#### **Diffuse infiltrative pulmonary disorders in immunocompromised patients**

Immunocompromised hosts include patients with AIDS, bone marrow and other transplant recipients, patients on chemo or radiation therapy, and patients on immunosuppressive therapy. These patients can be acutely ill and present often with progressive hypoxia. (Pechkam & Elliott, 2002). Differential diagnosis in this group includes both infective and non infective causes. Infective causes are viral and PJP infections, atypical pathogens, fungal and parasitic infections. Non-infective causes include graft rejection, toxicity secondary to radiation or chemotherapy, diffuse alveolar damage and diffuse alveolar hemorrhage. Rapid progression of the illness is not uncommon with the need for mechanical ventilation. Diagnostic delay in this group increases mortality and bronchoscopy can be very useful in the early diagnosis and management of these patients.

#### **Lung transplant recipients**

The number of transplant patients continues to grow and their care is not limited to specialized centers. They can present with a wide range of pulmonary disorders and causes of respiratory deterioration in transplant patients include rejection or infections. Bronchoscopy remains a valuable tool in this setting. FFB with BAL and TBBx has high sensitivity for the diagnosis of PJP, CMV and rejection. (Bulpa et al., 2003) The presence of *Aspergillus* in BAL fluid though non-diagnostic is predictive of development of invasive disease. (Cahill et al., 1997) Therapeutic bronchoscopic interventions include dilatation and stenting of stenotic lesions and laser ablation of granulation tissue. (Wahidi & Ernst, 2004)



#### **4.1.4 Miscellaneous**

##### **Retained secretions and atelectasis**

Atelectasis is a frequent complication seen in the ICU and retained secretions and atelectasis remains a common therapeutic indication for bronchoscopy. Although the use of FFB in situations of whole lung collapse associated with hypoxia is well established, there are no definitive guidelines in other situations. Bronchoscopy is usually performed when suctioning and chest physiotherapy fails to result in aeration of involved lungs. Stevens et al reported that 93 (79 %) of 118 bronchoscopies performed for atelectasis resulted in improvement compared with 31 (44%) of 70 patients with retained secretions. (Stevens et al., 1981) Other studies have reported a success rate between 19% to 81%. (Weinstein et al., 1977; Lindholm et al., 1974; Snow & Lucas, 1984)

In a prospective study Marini et al reported that the presence of air bronchograms on the initial chest roentgenogram predicted delayed resolution of atelectasis. (Marini et al., 1979). In this situation bronchoscopy may not be beneficial.

Bronchoalveolar lavage may aid in the resolution of atelectasis and identify some pathogenic microorganisms. In addition, bronchoscopy allows the instillation of mucolytic agents. We suggest bronchoscopy in critically ill patients with lobar or whole lung collapse without air bronchograms if chest physiotherapy is unsuccessful.

##### **Removal of foreign bodies**

Foreign body (FB) aspiration is frequently suspected in children with acute or recurrent pulmonary symptoms, but it is rarely considered in adults with acute or chronic respiratory symptoms unless a clear history of aspiration can be obtained. Food items are the most common aspirated FB with peanuts and animal or fish bones being the most common ones. The most common presentation is chronic cough, hemoptysis, dyspnea, and fever. If the FB is not removed, then more persistent findings may be seen such as atelectasis, post obstructive pneumonia, bronchiectasis, or lung abscess, and/or emphysema. The exact incidence of FB aspiration in adults is not known. Some studies report that only 7% of patients present with a history of choking (Chen et al., 1997).

Any condition leading to diminished swallowing reflex places the patients at risk for FB aspiration. Bronchoscopy is a valuable tool for the diagnosis and retrieval of the FB. Instruments used in retrieval include alligator and biopsy forceps, wire baskets and retrieval forceps. Overall success rates for retrieval of FBs ranges from 61 to 89% for both flexible and rigid bronchoscopies. (Limper & Prakash, 1990; Debeljak et al., 1999; Cunanan, 1978; Lan et al., 1989) FFB is probably more useful for FB in distal segments beyond the reach of rigid bronchoscope. In some cases, flexible and rigid bronchoscopy are complementary, with FFB assisting in the localization of the FB and then retrieval done with the rigid bronchoscope. Significant tissue reaction with inflammation is commonly seen in the delayed cases at bronchoscopy. Innovative anecdotal use of cryotherapy instruments to remove some foreign bodies have also been described.

##### **Difficult intubation**

Approximately 1% to 3% of tracheal intubations prove to be difficult with standard techniques. This is especially true as all invasive airway maneuvers can be considered difficult in a critically ill patient, either in the ICU or other setting. (Schwartz et al., 1995)



Fiberoptic intubation is a key aspect in the management of difficult intubations and forms part of several difficult airway algorithms (Benumof, 1991; American Society of Anesthesiologists, 2003; Crosby et al., 1998; Henderson et al., 2004) Intubation in these instances is performed using the bronchoscope as an obturator. Care must be taken to use a bite guard or an oral airway as damage to the scope by patient bites should be avoided.

### **Hemoptysis**

Massive hemoptysis, defined as the volume of expectorated blood that is life-threatening due to hypoxia from airway obstruction or hemodynamic instability from blood loss, accounts for 4.8% to 14% of all patients with hemoptysis. (Dweik & Stoller, 1999)

Massive hemoptysis remains an emergent indication for bronchoscopy. The primary intention is to locate the source of bleeding and if possible to control it by use of topical or endobronchial tamponade. Control of bleeding can be achieved by topical application of cold saline or diluted 1: 1000 epinephrine; other agents include application of thrombin or fibrinogen-thrombin combination. (Tsukamoto et al., 1989)

Endobronchial tamponade can be achieved using a Fogarty balloon or rarely a pulmonary artery catheter. In rare instances bronchoscopic guided contralateral lung intubation is life saving. Localization of the bleed helps in the planning of bronchial artery embolization or thoracotomy.

### **Bronchopleural fistula**

In patients with persistent air leaks and suspected broncho-pleural fistula (BPF), bronchoscopy can help define the extent of the broncho-pleural fistula and differentiate between stump dehiscence and a distal parenchymal leak. In addition, BPF associated with pneumonectomy or lobectomy can be directly visualized. In patients with suspected distal BPF a careful sequential inspection of each bronchopulmonary segment should be performed; this usually requires the use of balloons to occlude the bronchial segments to locate the one leading to the fistula and then apply sealants. (Lan et al., 1987; Regel et al. 1989; Lois & Noppen, 2005; Oren et al., 2011)

Other indications include confirmation of endotracheal tube (ETT) placement, double lumen ETT placement, diagnosis of bronchial rupture or bronchial stump dehiscence. Less common indications include inspection of upper airway prior to extubation when edema or other anatomical problems are expected in an intubated patient. In such instances, extubation can be attempted under bronchoscopic guidance and reintubation if necessary can be easily done using the bronchoscope as a guide wire. Bronchoscopy is indicated in patients with smoke inhalation to categorize the extent of injury and the need for intubation and in the presence of glottic and subglottic edema, intubation can be performed safely under bronchoscopic guidance.

## **4.1.5 Bronchoscopy in special circumstances**

### **Bronchoscopy in patients with renal impairment**

Uremia has been reported to be associated with an increased risk of bleeding, mainly due to platelet dysfunction. (Cordasco et al., 1991) A 45% incidence of pulmonary hemorrhage after bronchoscopic lung biopsy was documented in immunosuppressed uremic

patients.(Cunningham et al., 1977) A more recent study looking at 72 patients with renal insufficiency reported a much lower rate of bleeding complications with TBBx. There were no complications in the hemodialysis (HD) group and only one of 25 (4%) patients not on HD had a bleeding complication. (Mehta et al., 2005)

These findings suggest the possibility that the risk of bleeding in patients with renal insufficiency undergoing TBBx is lower than initially reported. Those patients should be screened for coagulation abnormalities and, if receiving HD, the TBBx should be done after HD with pre-bronchoscopy administration of 1-deamino-8-D-arginine vasopressin (DDAVP).Platelet transfusions, infusion of cryoprecipitate or DDAVP, administration of analogues or derivatives of vasopressin and administration of estrogen are some of the strategies implemented to decrease bleeding complications during FFB. (Cordasco et al., 1991)

### **Bronchoscopy in patients with cardiac ischemia**

Hypoxia is a relatively common complication of FFB, which may predispose to cardiac arrhythmias. (Katz et al., 1981) Cardiovascular stress and hypertension are common and can result in cardiovascular changes during bronchoscopy especially if they have cardiac risk factors.( Davies et al.,1997) Acute myocardial infarction (AMI) is generally considered to increase the risk of FFB. A retrospective study concluded that bronchoscopy is safe in the immediate post-AMI period as long as the patient does not have active ischemia at the time of the procedure; the mean period between the AMI and FFB was 11.7 days. The risks of bronchoscopy are thought to be reduced 4–6 weeks after myocardial infarction. (Dweik et al., 1996; Kvale, 1996; American College of Cardiology and American Heart Association Taskforce, 1996; Dunagan et al., 1998; Bein &Pfeifer, 1997)

### **Bronchoscopy in patients with obstructive airway disease**

Asthma has been associated with laryngospasm or bronchospasm complicating bronchoscopy. The reported incidence of bronchoscopy induced bronchospasm ranges from 0.02% to 8%. Decrease in FEV<sub>1</sub> is seen during FFB and this is more pronounced in asthmatics compared to non asthmatics. In patients with mild asthma, pre procedure use of bronchodilator has not been associated with a decrease in the postoperative FEV<sub>1</sub>, however, the use of pre-bronchoscopy bronchodilator is associated with blunting of the post bronchoscopy decrease in FEV<sub>1</sub> in asthmatics with more severe disease.( Fish & Peterman 1979; Djukanovic et al., 1991;Van Vyve et al., 1992; Rankin et al., 1984; Mavritsyn & Lifshits, 1980) In a large multicenter study of over 20,000 bronchoscopies, bronchospasm was reported in 0.004% of all the procedures.(Facciolongo et al., 2009) In general, it is recommended that patients with asthma receive bronchodilator nebulizers before the procedure; taking in consideration that the benefit have been reported mainly in the most severe asthmatic.

The presence of severe chronic obstructive pulmonary disease (COPD) has been shown to increase the complication rate of bronchoscopy. The complication rate is as high as 3% to 5% in severe COPD (FEV<sub>1</sub> /FVC <50% or FEV<sub>1</sub> <1.2 L) when compared with 0.6% of patients with normal lung function. An arterial blood gas should be considered prior to bronchoscopy for those patients with severe COPD. The judicious use of sedation and monitoring of oxygenation and ventilation permit the safe performance of FFB in selected patients with COPD.( BTS, 2001; Peacock et al., 1994; Hattotuwa et al., 2002) Although there is no data regarding the use of pre-procedure bronchodilators in COPD, we routinely use

bronchodilators prior to the bronchoscopy and monitoring is done with pulse oximetry and end tidal CO<sub>2</sub> (ETCO<sub>2</sub>).

### **Bronchoscopy in the elderly**

Epidemiologic studies have shown a trend in the increase of the “oldest old” or those 85 years of age or older from the absolute number of 3.5 million as measured in 1990 to approximately 15.3 million persons in the year 2050. Proportionately to this trend, this age group might comprise a portion of the population that could need diagnostic and therapeutic bronchoscopy.

A study of FFB in 107 octogenarians revealed no difference in procedural indications, complication rates, or diagnostic yield between octogenarians and non-octogenarians. Despite a significantly lower doses of sedation used in octogenarians, they experienced a predominant complication of oversedation. (Patrick et al., 2003; Knox et al., 1988)

### **Raised intracranial pressure**

In patients with head injuries, brain tumor or massive stroke, the increase in the intracranial pressure (ICP) can be significant; (Snow& Lucas, 1984, Lee, 1994; Peerless et al., 1995) raising concerns about the safety of bronchoscopy in this setting. A potential complication of bronchoscopy includes an increase in the ICP due to the manipulation of the airways especially during suctioning and excessive coughing. (Rudy et al., 1991) Kerwin et al reported an increase in ICP during bronchoscopy, the concomitant increase in MAP maintained CPP but the increase in MAP was not linear and there was no persistent increase in ICP after the procedure. (Kerwin et al 2000) They suggested that pharmacologic paralysis and heavy sedation should be used and that the bronchoscopy should be performed in the minimum amount of time possible. In general, bronchoscopy carries a low risk in patients with raised ICP in patients with intracranial space occupying lesions. (Bajwa et al., 1993)

### **Bronchoscopy in pediatric population**

Although the availability of bronchoscopy has been a major advance in adult pulmonary medicine, the role of FFB in pediatrics has remained less well defined. The last 20 years has seen an increase in the use of FFB for the evaluation of respiratory disorders in children. (Nicolai, 2001; Barbato et al., 1997) The main indications for bronchoscopy in children includes the evaluation of stridor, persistent wheezing, or a suspected foreign body, abnormal chest roentgenogram, airway evaluation in patients with tracheostomy, airway obstruction, hoarseness, recurrent pneumonia, chronic cough and hemoptysis.

Overall, the diagnostic yield in this population has been reported in the range of 75% to 88% of cases. (Brown et al., 1983; Wood, 1985; Martinot et al., 1997)

Several studies looking at the safety of bronchoscopy in the pediatric population have reported a low complication rate of less than 2%. De Blic study in 1328 children that underwent FFB under conscious sedation reported 5.2% of minor complications which included moderate and transient episodes of desaturation, excessive coughing and nausea, transient laryngospasm and epistaxis. Major complications were seen in 1.7% of cases and included oxygen desaturation to less than 90%, laryngospasm and bronchospasm, and pneumothorax. (J. de Blic et al 2002) The high diagnostic yield and low complication rate strongly support the use of the FFB in the diagnostic evaluation of infants and children who have a variety of pulmonary problems. (Wood, 1984, 1985)

## 5. Bronchoscopy in the intensive care unit

Respiratory involvement is common in the critically ill patient in the intensive care unit (ICU) with 30 to 50% of the admissions requiring the use of mechanical ventilation. Fiberoptic bronchoscopy remains a very valuable tool in the evaluation and management of these patients as well as to evaluate complications of mechanical ventilation especially atelectasis and ventilator associated pneumonias (VAP). Bronchoscopy in the ICU plays a role as a diagnostic and therapeutic tool. Many of the indications for bronchoscopy in the ICU overlap with the general indications for the procedure as discussed above.

### Bronchoscopy on patients on mechanical ventilation

The routine FFB with BAL is frequently performed in patients on mechanical ventilation (MV). Use of transbronchial biopsy in this group of patient's remains low and underutilized probably due to the lack of fluoroscopy in the ICU setting.

In a non intubated patient a regular 5.7 mm bronchoscope usually occupies 10 % of the tracheal cross sectional area and is of no physiological consequence. The consequences on the respiratory mechanics have been described in detail by Jollier and Chevrolet. (Jolliet & Chevrolet 1992) . A 5.7 mm internal diameter bronchoscope occupies 40% of the total cross-section of a 9 mm internal diameter ETT, 51 % of an 8 mm ETT, and 66% of a 7 mm ETT. This results in the development of intrinsic PEEP and as described, smaller the tube, higher the development of PEEP with the consequent increase in airway pressures. Additionally, functional residual capacity increases by 30% and forced expiratory volume in one second (FEV<sub>1</sub>) decreases by 40%. ( Matsushima et al.,1984) The decrease in the delivered tidal volume leads to hypoventilation and gas exchange abnormalities resulting in hypoxia and hypercapnea. Suctioning during bronchoscopy limits the delivered tidal volume further and up to 200 to 300 ml of delivered volume can be removed with each suctioning. It is therefore recommended that an ETT of at least size 8 or 8.5 mm be used when performing bronchoscopy in intubated patients. (Grossman& Jacobi, 1974; Jolliet & Chevrolet 1992))

Cardiovascular consequences of bronchoscopy include arrhythmias secondary to vagotonic effects, hypoxia or hypercapnea. Increased intrinsic PEEP can result in impaired preload and hypotension. Adjustments needed prior to bronchoscopy in a patient on MV include preoxygenation with 100% oxygen and increase in the tidal volume by 30%. Bronchoscopy should be performed on 100% FIO<sub>2</sub> and this should be continued into the post bronchoscopy period. Peak airway pressure alarm limit should be increased before the procedure to account for the increase in pressure on introduction of the scope and ensure delivery of adequate tidal volume and adequate ventilation. It is our personal experience to withdraw the scope and allow for ventilation when the SpO<sub>2</sub> reaches 90%. In patients who have acute or chronic pre-procedure hypercapnia, the use of ETCO<sub>2</sub> monitoring is helpful.

Bronchoscopic techniques used for procedures done at the bedside of the patient in the ICU are similar to the ones done in the bronchoscopy suite.

### Bronchoscopy in mechanically ventilated patients – A bed side approach

1. Review the indication for bronchoscopy and review imaging before the procedure
2. Obtain informed consent



3. Inspect the ETT or tracheostomy size. If  $\geq 8\text{mm}$  then a standard 5.7mm outer diameter bronchoscope can be used. If the artificial airway tube is smaller, then a smaller size scope is needed. Shorten the ETT by cutting the distal end to facilitate inspection of the distal tracheobronchial tree. Attach Portex adapter to facilitate ventilation during bronchoscopy. Oral airway or bite guard is recommended to prevent trauma to the scope.
4. Increase  $\text{FiO}_2$  to 100 percent 15 minutes before the procedure and make ventilator adjustments. In volume assist modes the peak pressure limit is increased and in pressure control assist mode the pressure control needs to be increased to compensate for the increased resistance generated due to the insertion of the scope.
5. Time out and sedation as per hospital policies. On patients with sedative infusion drips, an initial bolus is recommended
6. Document peak air way pressure before procedure
7. Patient should be monitored with continuous EKG,  $\text{SpO}_2$  and  $\text{ETCO}_2$  for those with hypercapnea. Blood pressure should be monitored every 5 minutes during the procedure
8. Lubricate bronchoscope and insert into the ETT/tracheostomy via the adapter. Topical anesthesia is achieved with topical lidocaine application into the trachea, carinal and main stem bronchi. Recommended maximal dose of lidocaine is 4-5 ml/kg ideal body weight or 300 mg per procedure. Minimal use of suction to prevent loss of tidal volume. Restrict suctioning to less than 3 seconds.
9. After inspection of the tracheobronchial tree, BAL is performed. The exception to this rule is suspected infection, in which case locate the bronchopulmonary segment of interest and perform lavage. This decreases the chances of contamination of the specimen.
10. The BAL is performed as described under bronchoscopic techniques.
11. To perform the TBBx, apply topical lidocaine to the segment of interest and perform biopsy as described under techniques. We take special care that the patient is well sedated and not fighting the ventilator or coughing excessively. We routinely disconnect patient from the respirator for a couple of seconds during initial part of forceps withdrawal. If there is any instability pull out the scope and ventilate patient. Bronchoscopy can be continued after the situation resolves.
12. Post procedure check peak airway and plateau pressure and obtain a chest roentgenogram to evaluate for complications.

### **Diagnostic yield of bronchoscopy in mechanically ventilated patients**

The diagnostic yield of FFB depends on the indication and the comorbid clinical status. Different bronchoscopic techniques are associated with different diagnostic yield in this group of patients.

### **Protected brush**

Pooled results of 18 studies of PSB technique was evaluated in a total of 795 critically ill patients. The overall accuracy of this diagnostic method for diagnosing health care associated pneumonia (HCAP) was high, with a sensitivity of 89% and a specificity of 94%. Prior anti microbial therapy decreases the diagnostic yield. (Chastre & Fagon, 2002)

**BAL**

Torres & el-Ebiary reviewed 23 studies that evaluated the accuracy of BAL to diagnose VAP in a total of 957 patients. In this review, BAL had a mean sensitivity of 73% (range 22 to 100%) and mean specificity of 82%. The presence of intracellular organisms in BAL was specific for VAP. (Torres & El-Ebiary 2000)

In patients with AIDS, BAL had a diagnostic accuracy of 89 to 98% in the diagnosis of PJP. (Huang et al., 2006) In a prospective multicentre trial in hematology and oncology patients there was no difference between bronchoscopic BAL versus other strategies in establishing diagnosis. (Azoulay et al., 2008) However, FFB-BAL was the only conclusive investigation in a third of patients and induced respiratory deterioration in about half of these cases. A subsequent study by the same investigators showed that noninvasive testing alone was not inferior to noninvasive testing plus FFB-BAL within 24 hours of admission for the identification of the cause for acute respiratory failure. (Azoulay et al., 2010)

In neutropenic patients with pulmonary infiltrates, the diagnostic yield of BAL was 49% with low complication rates; there were infrequent treatment changes and there was improved survival. (Gruson et al., 2000)

**TBBx**

In patients with diffuse unexplained pulmonary infiltrates, combined BAL and TBBx resulted in diagnosis in 74% of patients and the authors concluded that the benefits of the procedure exceeded the risks. (Bulpa et al 2003) TBBx is useful in distinguishing infections from rejection in lung transplant patients.

Management of critically ill patient on mechanical ventilation with unclear lung findings represents a challenge to the clinician. In cases where FFB-BAL and all noninvasive studies have been non diagnostics, TBBx or surgical lung biopsy is recommended. This is compounded by the fact that there are few studies looking into the role of TBBx in ventilated patients. (Papazian et al., 1998)

**6. Safety and contraindications of bronchoscopy**

Flexible bronchoscopy is an extremely safe procedure with a low incidence of complications. (Dweik et al., 1996; BTS, 2001; Prakash et al., 1991; ATS, 1987) One study reported a mortality rate of 0.01% and a major complication rate of 0.08% in a series of 24521 procedures, and another a mortality of 0.02% and a 0.3% rate of major complications in a series of around 48 000 cases. (Kvale, 1996; Zavala, 1975; Credle et al., 1974; Pue & Pacht, 1995; Surrat et al., 1979)

A multicenter, prospective study describing the practice of bronchoscopy in the United States revealed adverse events in 35% of cases, most of them mild (sore throat 10%, hemoptysis 8%, bleeding 4%, cough 3%). Severe adverse events occurred in 10% and included hospitalizations for cardiac arrhythmias, exacerbation of chronic obstructive pulmonary disease, and hypoxia. The mortality rate was 2% , a rate higher than previously reported. (Bechara et al., 2005)

Major life threatening complications include respiratory depression, pneumonia, pneumothorax, airway obstruction, cardio-respiratory arrest, arrhythmias, and pulmonary



edema. Major complications are partly because of the cardiovascular effects of bronchoscopy, leading to an increase in blood pressure and heart rate causing arrhythmias and cardiovascular ischemia. Oxygen desaturation can occur because of the procedure itself or respiratory depression by sedative drugs leading to hypoxemia and increased risk of arrhythmias and ischemia. Bronchoscopy is performed in different settings, varying from local to general anesthesia with intubation; the choice of the way in which the bronchoscopy is performed is more a matter of personal experience and choice than of evidence-based medicine. Comparison of rigid bronchoscopy under general anesthesia and flexible fiberoptic bronchoscopy reveals that FFB with topical anesthesia has a safer profile than rigid bronchoscopy. (BTS, 2001; Hattotuwa et al., 2002; Surrat et al., 1979; Pereira et al., 1978; Lundgren et al., 1982; Davies et al., 1997)

Minor non-life threatening complications include, in order of frequency, vasovagal reactions, fever, cardiac arrhythmias, hemorrhage, nausea and vomiting. Post-bronchoscopy fever occurs in approximately 5% to 16% of the patients, with pulmonary infiltrate occurring in 0.6% of all cases. The self-limiting fever is usually not indicative of pneumonia and may be due to transient bacteremia, translocation of endotoxins or release of inflammatory mediators. (BTS, 2001; Pereira et al., 1978; de Castro & Violan, 1996)

Complication rates that are related specifically to the procedure of transbronchial biopsies are higher, with pneumothorax reported in 1 to 5% of cases and mild hemorrhage in 9%. (Bechara et al., 2005; Zavala, 1978; Hanson et al., 1976)

### 6.1 Pneumothorax

Pneumothorax is very uncommon after FFB; however, a major pneumothorax requiring drainage has been reported to occur in 3.5% of FFB with TBBx. The incidence of pneumothorax with TBBx is as high as 14% for patients on mechanical ventilation. Symptoms and/or signs of a pneumothorax may be delayed after TBBx but it is very uncommon for a pneumothorax to develop after an hour of TBBx. (Lindholm et al., 1974) About 50% of patients who develop pneumothorax will require drainage.

### 6.2 Fluoroscopy for bronchoscopy

The use of fluoroscopy does not appear to reduce the frequency of pneumothorax, especially in non-mechanically ventilated patients. (Zink et al., 2007; O'Brien et al., 1997; Milman et al., 1993) Literature regarding non fluoroscopy guided transbronchial biopsy in patients on mechanical ventilation is scarce. In most of the ICU's fluoroscopy is not available which limits the use of TBBx in mechanically ventilated patients. In smaller series, the rate of pneumothorax varies from 12 to 27% (Bulpa et al., 2003; Pincus et al., 1987;) and 10.4% in larger series (O'Brien et al., 1997). Risk of pneumothorax is directly proportional to the number of biopsies attempted; Descombes et al reported 38% and 69% yields with 1-3, and 6-10 specimens, respectively. (Descombes et al., 1997)

At our institution, we perform 1-3 biopsies on patients on mechanical ventilation without the use of fluoroscopy; otherwise, to obtain more biopsies we do the procedure in the operating room under fluoroscopic guidance.

In general, the use of fluoroscopy increases the diagnostic yield from TBBx in focal lung lesions. Fluoroscopy carries the limitation of being time consuming, requires some

experience, and is not readily available in all centers. (Gasparini, 1997; Cortese & McDougall 1979; Yung, 2003; Liam et al., 2007)

### 6.3 Bleeding complications

Several studies have shown that patients with uremia, immunosuppression, pulmonary hypertension, liver disease, coagulation disorders, or thrombocytopenia have a higher risk for hemorrhage with transbronchial biopsy (TBBx). (Papin et al., 1985; Zavala, 1976; Borchers & Beamis 1996)

The risk of bleeding during TBBx seems to be unrelated to the size of forceps and is slightly higher in those being mechanically ventilated. (Loube et al., 1993; O'Brien et al., 1997)

In patients with a potential increased risk of bleeding, coagulation profile should be checked before bronchoscopy. There is no information about what constitutes a "safe" level for clotting in this context. Transfusion guidelines and expert opinions recommend platelet counts of 20,000–50,000/mm<sup>3</sup> for FFB with BAL and greater than 50,000/mm<sup>3</sup> for TBBx. It is recommended that platelets be transfused following those guidelines. (Rebulla, 2001)

Thrombocytopenia (platelet count <150,000/mm<sup>3</sup>) is seen in 35 to 40% of critically ill medical patients (Vanderschueren et al., 2000; Strauss et al., 2002), with surgical and trauma patients having a higher incidence of thrombocytopenia. ((Stephan et al., 1999)

Patients with coagulopathy are at a high risk for bleeding with brushings and biopsy; Weiss et al., reported 12% of complications in patients with significant thrombocytopenia after bronchoscopy with BAL, but serious complications were rare. (Weiss et al., 1993)

In patient taking oral anticoagulants, published guidelines for managing anticoagulation in the perioperative period are relevant. These state that "the short term risk of thromboembolism in patients with mechanical heart valves when not anticoagulated is very small". (Brickey & Lawlor, 1999; British Committee for Standards in Haematology, 1998)

In patients on anticoagulation undergoing transbronchial biopsy, unfractionated heparin drips should be stopped 6 hours prior and low molecular weight heparin should be held the evening prior and on the day of the procedure

The use of aspirin alone in humans has not been associated with an increase in bleeding complications from TBBx and therefore there are no recommendations to stop the medication before this procedure. (Herth et al., 2002)

The data from aspirin cannot be generalized to clopidogrel use because its mechanism of action differs from that of aspirin. Several studies indicate an increased risk of bleeding when clopidogrel is combined with other antiplatelet drugs. (Hongo et al., 2002; Yende & Wunderink, 2001) A study in 604 patients without underlying coagulation problems who underwent TBBx while on clopidogrel with or without aspirin revealed an increased risk of bleeding after the lung biopsy. Marked bleeding was observed in most patients receiving clopidogrel and in all patients receiving clopidogrel combined with aspirin. On the basis of these results, it is recommended that clopidogrel should be stopped 5 to 7 days before TBBx to ensure patient safety. The indications for TBBx need to be clearly defined, as it means stopping a beneficial medication for patients with cardiovascular diseases. (Ernst et al., 2006)

## 6.4 Contraindications

The contraindications to bronchoscopy must always be considered in relationship to the expected benefits and clinical consequences. The determining factors are, in addition to the clinical status and prognosis of the patient, the technical difficulties of the procedure, and the skills and experience of the endoscopist. There are no controlled studies of the factors which may make a patient totally unfit for the procedure, so a decision to perform a bronchoscopy is a balance between the likely benefit of obtaining diagnostic material (including therapeutic benefit) and an assessment of the likely risk for complications in that individual patient. (BTS, 2001; ATS, 1987; Ernst et al., 2003; Wood-Baker et al., 2001)

Relative contraindications to bronchoscopy include severe respiratory insufficiency when bronchoscopy will be non-therapeutic, inability to maintain a patent airway and severe cardiovascular instability. Coagulopathy when biopsy is considered and severe generalized debilitated status are other relative factors to be considered prior to bronchoscopy.

Careful planning and taking all appropriate precautions prior to the bronchoscopy cannot be overemphasized in those patients with myocardial infarction within the last 4 weeks and patients with severe hypoxemia who could benefit from intubation prior to the bronchoscopy.

For those patients with severe renal or coagulation impairment, transmissible infection (e.g. active pulmonary tuberculosis) and the very uncooperative patient the benefit of the procedure must be weighed carefully.

Additionally caution is advised in patients on mechanical ventilation with high PEEP, hypoxia requiring high supplemental oxygen and electrolyte abnormalities. In unstable patients it is recommended to stabilize the respiratory status before FFB and this may include intubation and mechanical ventilation. (Crosby et al., 1998; Henderson et al., 2004; Alamoudi et al., 2000; Becker et al., 1991)

## 7. Conclusion

The development of flexible bronchoscopy in the late 1960s revolutionized the care of patients with lung and airway problems. The flexible bronchoscope has almost completely supplanted the rigid scope for the routine diagnostic evaluation of lung diseases. The technique is acceptable to the patient, is safe and allows a more complete examination of the bronchial tree and is ideal for a variety of other diagnostic procedures such as transbronchial biopsy, bronchial lavage and needle aspiration. Bronchoscopy remains a very valuable tool for both diagnostic and therapeutic procedures for a variety of respiratory conditions encountered in clinical practice including in critically ill patients. Bronchoscopy has a definite diagnostic role in those patients suspected of having pulmonary malignancy or some diffuse lung diseases like sarcoidosis and infections in the immunosuppressed host. In experienced hands, the bronchoscope is an invaluable diagnostic and therapeutic tool in the ICU that at present is probably underused.

Appropriate indication, experience of the bronchoscopist and careful attention to detail results in a high diagnostic yield with a low complication rate even with the inclusion of needle aspiration and biopsies. The current advances in technology, imaging and information processing continue to improve the ability to perform minimally invasive,

accurate evaluations of the tracheobronchial tree and to perform an ever-increasing array of diagnostic, staging, therapeutic, and palliative interventions.

We believe that a well trained pulmonologist should continue using the bronchoscope in order to diagnose the most commonly encountered pulmonary conditions. The idea of having an “optimal bronchoscopist” who is highly skilled in all the bronchoscopic techniques and able to handle flexible and rigid scope in adults and pediatric population as Prakash and Stubbs discussed in their 1994 publication is probably not feasible at this point on time. (Prakash & Stubbs 1994) Pulmonologists need to be able to identify those patients that could benefit from more invasive or sophisticated bronchoscopic procedures and refer them to centers of excellence with an interventional pulmonologist.

## 8. References

- Alamoudi OS, Attar SM, Ghabrah TM & Kassimi MA. (2000). Bronchoscopy, indications, safety and complications. *Saudi Med J*. 2000 Nov; 21(11):1043-7
- Alvarez-Lerma F. (1996). Modification of empiric antibiotic treatment in patients with pneumonia acquired in the intensive care unit. ICU-acquired Pneumonia Study Group. *Intensive Care Med* 1996; 22:387-394.
- American College of Cardiology and American Heart Association Taskforce. Guidelines for peri-operative cardiovascular evaluation for non cardiac surgery. (1996). *Circulation* 1996; 93:1278-317.
- American Society of Anesthesiologists Task Force on Management of the Difficult Airway. (2003). Practice guidelines for management of the difficult airway. An updated report. (2003). *Anesthesiology* 2003; 95: 1269-77.
- American Thoracic Society/European Respiratory Society international multidisciplinary consensus classification of the idiopathic interstitial pneumonias. (2002) *Am J Respir Crit Care Med* 2002; 165:277-304.
- Anders GT, Johnson JE, Bush BA & Matthew JI. Transbronchial biopsy without fluoroscopy. (1998). A seven year perspective. *Chest* 1988; 94:557-560
- Arancibia F, Ewing S, Martinez JA, Ruiz M, Bauer T, Angeles Marcos M, Mensa J, & Torres A. (2000). Antimicrobial treatment failures in patients with community-acquired pneumonia. Causes and prognostic implications. *Am J Respir Crit Care Med* 2000; 162:154-60.
- Azoulay E, Mokart D, Lambert J, Lemiale V, Rabbat A, Kouatchet A, Vincent F, Gruson D, Bruneel F, Epinette-Branche G, Lafabrie A, Hamidfar-Roy R, Cracco C, Renard B, Tonnelier JM, Blot F, Chevret S, & Schlemmer B. (2010). Diagnostic strategy for hematology and oncology patients with acute respiratory failure: randomized controlled trial. *Am J Respir Crit Care Med* 2010; 182:1038-1046
- Bajwa MK, Henein S, & Kamholz SL. (1993). Fiberoptic bronchoscopy in the presence of space-occupying intracranial lesions. *Chest*. 1993;104:101-103
- Barbato A, Magarotto M, Crivellaro M, Novello Jr A, Cracco A, de Blic J, Scheinmann P, Warner JO & Zach M. (1997). Use of the paediatric bronchoscope, flexible and rigid, in 51 European centers. *Eur Respir J* 1997; 10: 1761-1766.
- Bates, J. H. , G. D. Campbell, A. L. Barron, G. A. McCracken, P. N. Morgan, E. B. Moses & C. M. Davis. (1992). Microbial etiology of acute pneumonia in hospitalized patients. *Chest* 1992. 101:1005-1112.



- Baughman R. P. (2007) Technical Aspects of Bronchoalveolar Lavage: Recommendations for a Standard Procedure. *Semin Respir Crit Care Med* 2007; 28: 475–485.
- Bechara R, Beamis J, Simoff M, Mathur P, Yung R, Feller-Kopman D & Ernst A. (2005). Practice and Complications of Flexible Bronchoscopy with Biopsy Procedures. *J Bronchol* 2005; 12:139–142
- Becker H. D, Kayser K, Schulz V, Tuengerthal S & Vollhaber HH. (1991). Atlas of Bronchoscopy. B. C. Decker Inc. 1991
- Bein T & Pfeifer M. (1997) Fiberoptic bronchoscopy after recent acute myocardial infarction. Stress for the heart? *Chest* 1997; 112:295.
- Bellomo R, Tai E & Parkin G. (1992) Fiberoptic bronchoscopy in the critically ill: A prospective study of its diagnostic and therapeutic value. *Anaesth Intensive Care* 1992; 20:464–469.
- Benumof JL. (1991). Management of the difficult adult airway with special emphasis on awake tracheal intubation. *Anesthesiology* 1991; 75: 1087–110.
- Borchers S & Beamis J. (1996). Flexible bronchoscopy. *Chest Surg Clin North Am* 1996; 6:169–92.
- Brickey DA & Lawlor DP. (1999). Transbronchial biopsy in the presence of profound elevation of the international normalized ratio (INR). *Chest* 1999; 115:1667–71.
- British Committee for Standards in Haematology. Guidelines on oral anticoagulation: third edition. (1998). *Br J Haematol* 1998; 101:374–87
- British Thoracic Society Bronchoscopy Guidelines Committee. BTS guidelines on diagnostic flexible bronchoscopy. (2001). *Thorax*. 2001; 56 (suppl I):i1–i2.
- Brown Fitzpatrick S, Marsh B, Stokes D & Wang KP. (1983). Indications for Flexible Fiberoptic Bronchoscopy in Pediatric Patients. *Am J Dis Child*. 1983; 137(6):595–597.
- Bulpa PA, Dive AM, Mertens L, Delos MA, Jamart J, Evrard PA, Gonzalez MR & Installe EJ. (2003). Combined bronchoalveolar lavage and transbronchial lung biopsy: Safety and yield in ventilated patients. *Eur Respir J* 2003; 21:489–494.
- Cahill BC, Hibbs JR, Savik K, Juni BA, Dosland BM, Edin-Stibbe C & Hertz MI. (1997). Aspergillus airway colonization and invasive disease after lung transplantation. *Chest* 1997; 112(5):1160–4
- Celis R, Torres A, Gatell JM, Almela M, Rodriguez-Roisin R & Agustí- Vidal A. (1998). Nosocomial pneumonia: a multivariate analysis of risk and prognosis. *Chest* 1988; 93:318–324.
- Centers for Disease Control and Prevention. Monitoring hospital acquired infections to promote patient safety: United States, (2000). 1990– 999. *MMWR* 2000; 49:149–153.
- Ceron L, Michieletto L, Pagan V & Zamperlin A. (2007). Transbronchial Needle Aspiration in Patients With Mediastinal and Hilar Disease. *J Bronchol* 2007; 14:6–9
- Chastre J & Fagon JY. (1994). Pneumonia in the ventilator-dependent patient. Editor -Tobin MJ : Principles and practice of mechanical ventilation. New York: McGraw-Hill; 1994. p. 857–890.
- Chastre J & Fagon JY. (2002) Ventilator-associated pneumonia. *Am J Respir Crit Care Med* 2002; 165(7):867– 903
- Chen CH, Lai CL, Tsai TT, Lee YC & Perng RP. (1997). Foreign body aspiration into the lower airways in Chinese adults. *Chest* 1997; 112:129–33
- Cordasco E M Jr, Mehta A C & Ahmad M. (1991). Bronchoscopically Induced Bleeding. A Summary of Nine Years' Cleveland Clinic Experience and Review of the literature. *Chest* 1991; 100:1141–114

- Cortese DA & McDougall JC. (1979) Biopsy and brushing of peripheral lung cancers with fluoroscopic guidance. *Chest* 1979; 75:141-5.
- Credle W, Smiddy J & Elliott R. (1974). Complications of fiberoptic bronchoscopy. *Am Rev Respir Dis* 1974; 109:67-72.
- Crosby ET, Cooper RM, Douglas MJ, Doyle JD, Hung OR, Labrecque P, Muir H, Murphy MF, Preston RP, Rose DK & Roy L. (1998). The unanticipated difficult airway with recommendations for management. *Can J Anaesth* 1998; 45: 757-76.
- Cunanan OS. (1978) The flexible fiberoptic bronchoscope in foreign body removal. Experience in 300 cases. *Chest* 1978; 73:725-6.
- Cunningham JH, Zavala DC, Corry RJ, & Keim LW. (1977). Trepine air drill, bronchial brush, and fiberoptic transbronchial lung biopsies in immunosuppressed patients. *Am Rev Respir Dis*. 1977; 115:213-220.
- Dasgupta A & Mehta AC. (1999). Flexible Bronchoscopy in the 21<sup>st</sup> Century. Transbronchial Needle Aspiration An Underused Diagnostic Technique. *Clin Chest Med* 1999; Volume 20, Issue 1: 39-51
- Davies L, Mister R, Spence DP, Calverley PMA, Earis JE & Pearson MG. (1997). Cardiovascular consequences of fiberoptic bronchoscopy. *Eur Respir J*. 1997; 10:695-698.
- Davenport RD. (1990). Rapid on-site evaluation of transbronchial aspirates. *Chest* 1990; 98:59-61.
- de Blic J, Marchac V & Scheinmann P. (2002). Complications of flexible bronchoscopy in children: prospective study of 1,328 procedures. *Eur Respir J* 2002; 20: 1271-1276
- De Castro F R & Violan J S. (1996). Flexible bronchoscopy in mechanically ventilated patients. *J Bronchol* 1996; 3:64-8.
- de Gracia J, Bravo C, Miravittles M, Tallada N, Orriols R, Bellmunt J, Vendrell M, & Morell F. (1993). Diagnostic value of bronchoalveolar lavage in peripheral lung cancer. *Am Rev Respir Dis* 1993; 147:649-52.
- Debeljak A, Sorli J, Music E & Kecelj P. (1974). Bronchoscopic removal of foreign bodies in adults: experience with 62 patients from 1974-1998. *Eur Respir J* 1999; 14:792-5.
- Descombes E, Gardiol D & Leuenberger P: Transbronchial lung biopsy: An analysis of 530 cases with reference to the number of samples. *Monaldi Arch Chest Dis* 1997; 52:324-329.
- Digby J, Kalbfleisch J, Glenn A, Larsen A, Browder W & Williams D. Serum glucan levels are not specific for presence of fungal infections in intensive care unit patients. *Clin Diagn Lab Immunol* 2003; 10: 882-5
- Djukanovic R, Wilson J, Lai C, Holgate ST & Howarth PH. (1991). The safety aspects of fiberoptic bronchoscopy, bronchoalveolar lavage, and endobronchial biopsy in asthma. *Am Rev Respir Dis* 1991; 143:772-7.
- Dunagan DP, Burke HL, Aquino SL, Chin R Jr, Adair NE & Haponik EF. (1998). Fiberoptic bronchoscopy in coronary care unit patients. *Chest* 1998; 114: 1660-7.
- Dweik RA, Mehta A. C. , Meeker D. P & Arroliga A. C. (1996). Analysis of the Safety of Bronchoscopy After Recent Acute Myocardial Infarction. *Chest* 1996; 110:825-28)
- Dweik RA & Stoller JK. Role of bronchoscopy in massive hemoptysis. (1999). *Clin Chest Med* 1999; 20:89-105.
- El-Ebiary M, Torres A, Fabregas N, de la Bellacasa JP, González J, Ramirez J, del Baño D, Hernández C & Jiménez de Anta M. (1997). Significance of the isolation of *Candida* species from respiratory samples in critically ill, non-neutropenic patients. *An*



- immediate postmortem histologic study. *Am J Respir Crit Care Med* 1997; 156:583–90
- El-Bayoumi E & Silvestri GA. (2008). Bronchoscopy for the diagnosis and staging of lung cancer. *Semin Respir Crit Care Med* 2008;29(3):261–70.
- Esperatti M, Ferrer M, Theessen A, Liapikou A, Valencia M, Saucedo LM, Zavala E, Welte T & Torres A. (2010). Nosocomial pneumonia in the intensive care unit acquired by mechanically ventilated versus nonventilated patients. *Am J Respir Crit Care Med* 2010; 182:1533–9.
- Ernst A, Eberhardt R, Wahidi M, Becker H D & Herth FJF. (2006). Effect of Routine Clopidogrel Use on Bleeding Complications after Transbronchial Biopsy in Humans. *Chest* 2006; 129; 734–737.
- Ernst, A, Silvestri, GA & Johnstone, D. (2003). Interventional pulmonary procedures. Guidelines from the American College of Chest Physicians. *Chest* 2003; 123, 1693–1717
- ERS/ATS statement on interventional pulmonology. (2002). *Eur Respir J* 2002; 19: 356–373
- Fabregas N, Ewig S, Torres A, El-Ebiary M, Ramirez J, de La Bellacasa JP, Bauer T & Cabello H. (1999) . Clinical diagnosis of ventilator-associated pneumonia revisited: comparative validation using immediate post-mortem lung biopsies. *Thorax* 54:867–873
- Fabin E, Nagy M & Meszaros G. (1975). Experiences with bronchial brushing method. *Acta Cytol* 1975;19: 320–1.
- Facciolongo N, Patelli M, Gasparini S, Lazzari Agli L, Salio M, Simonassi C, Del Prato B & Zanoni P. (2009). Incidence of complications in bronchoscopy. Multicentre prospective study of 20,986 bronchoscopies. *Monaldi Arch Chest Dis* 2009; 71: 8–14
- Fagon JY, Chastre J, Wolff M, Gervais C, Parer-Aubas S, Stephan F, Similowski T, Mercat A, Diehl JL, Sollet JP & Tenaillon A. (2000). Invasive and noninvasive strategies for management of suspected ventilator-associated pneumonia: a randomized trial. *Ann Intern Med* 2000; 132:621–630.
- Fedullo AJ & Ettensohn DB. (1986). Bronchoalveolar lavage in the lymphangitic spread of adenocarcinoma to the lung. *Chest* 1985;87:129–31.
- Fish JE and Peterman VI. (1979). Effects of inhaled lidocaine on airway function in asthmatic subjects. *Respiration* 1979; 37:201–7.
- Fischer JE, Janousek M, Nadal D & Fanconi S (1998) Diagnostic techniques for ventilator associated pneumonia. *Lancet* 1988; 352:1066–1067
- Flanagan PG, Findlay GP, Magee JT, Ionescu A, Barnes RA & Smithies M (2000) The diagnosis of ventilator-associated pneumonia using non- bronchoscopic, non-directed lung lavages. *Intensive Care Med* 2000; 26:20–30.
- Garg S, Handa U, Mohan H & Janmeja AK. (2007). Comparative analysis of various cytohistological techniques in diagnosis of lung diseases. *Diagn Cytopathol* 2007; 35(1):26–31.
- Gasparini S. (1997). Bronchoscopic biopsy techniques in the diagnosis and staging of lung cancer. *Monaldi Arch Chest Dis* 1997; 4:392–8.
- Gasparini S, Ferretty M, Such E, Baldelli S, Zuccatosta L & Gusella P. (1995). Integration of transbronchial and percutaneous approach in the diagnosis of peripheral pulmonary nodules or masses: experience with 1027 consecutive cases. *Chest* 1995;108:131–7

- Gomez M & Silvestri G. A. (2009) Endobronchial Ultrasound for the Diagnosis and Staging of Lung Cancer. *Proc Am Thorac Soc* 2009; Vol 6. pp 180-186.
- Gross TJ, Chavis AD & Lynch JP III. (1991). Non-infectious pulmonary diseases masquerading as community-acquired pneumonia. *Clin Chest Med* 1991;12:363-93.
- Grossman E & Jacobi AM. (1974) Minimal optimal endotracheal tube size for fiberoptic bronchoscopy. *Anesth Analg* 53:475-76, 1974.
- Gruson, D. , Hilbert, G. , Valentino, R. , Vargas, F. , Chene, G. , Bebear, C. , Allery, A. , Pigneux, A. , Gbikpi-Benissan, G. & Cardinaud, J. P. (2000) Utility of fiberoptic bronchoscopy in neutropenic patients admitted to the intensive care unit with pulmonary infiltrates. *Crit Care Med* 2000; 28, 2224-2230
- Guidelines for fiberoptic bronchoscopy in adults. American Thoracic Society. Medical Section of the American Lung Association. (1987) *Am. Rev Respir Dis* 1987; 136:1066
- Haley RW, Hooton TM, Culver DH, Stanley RC, Emori TG, Hardison CD, Quade D, Shachtman RH, Schaberg DR, Shah BV & Schatz GD. (1981). Nosocomia infections in US hospitals, 1975-1976: estimated frequency by selected characteristics of patients. *Am J Med* 1981; 70:947-959.
- Hanson RR, Zavala DC, Rhodes ML, Keim LW & Smith JD. (1976). Transbronchial biopsy via flexible fiberoptic bronchoscope: results in 164 patients. *Am Rev Respir Dis* 1976; 114:67-72.
- Hattotuwa K, Gamble E, O'Shaughnessy T, Jeffery PK & Barnes NC. (2006). Safety of bronchoscopy, biopsy and BAL in research patients with COPD. *Chest* 2002; 122:1909-1912.
- Hautmann H, Henke MO & Bitterling H. (2010). High diagnostic yield from transbronchial biopsy of solitary pulmonary nodules using low-dose CT-guidance. *Respirology*. May 2010; 15(4):677-82.
- Henderson JJ, Popat MT, Latto IP & Pearce AC. (2004). Difficult Airway Society. Difficult Airway Society guidelines for management of the unanticipated difficult intubation. *Anaesthesia* 2004; 59: 675-94.
- Herth FJ, Becker HD & Ernst A. (2002) Aspirin does not increase bleeding complications after transbronchial biopsy. *Chest* 2002; 122:1461-1464
- Herth FJ, Eberhardt R, Vilmann P, Krasnik M & Ernst A. (2006). Real-time endobronchial ultrasound guided transbronchial needle aspiration for sampling mediastinal lymph nodes. *Thorax*. 2006; 61: 795-798.
- Hongo RH, Ley J, Dick SE & Yee RR. (2002). The effect of clopidogrel in combination with aspirin when given before coronary artery bypasses grafting. *J Am Coll Cardiol* 2002; 40:231-237
- Hsu LY, Ding Y, Phua J, Koh LP, Chan DS, Khoo KL & Tambyah PA. (2010). Galactomannan testing of bronchoalveolar lavage fluid is useful for diagnosis of invasive pulmonary aspergillosis in hematology patients. *BMC Infect Dis*. 2010; 10:44.
- Huang L, Morris A, Limper AH, Beck JM & ATS Pneumocystis Workshop Participants. (2006). An Official ATS workshop summary: recent advances and future directions in *Pneumocystis pneumonia* (PCP). *Proc Am Thorac Soc* 2006; 3:655-64.
- Jimenez, P. , F. Saldias, M. Meneses, M. E. Silva, M. G. Wilson & L. Otth. (1993). Diagnostic fiberoptic bronchoscopy in patients with community-acquired pneumonia. *Chest* 1993. 103:1023-1027.
- Jolliet P & Chevrolet JC. (1992). Bronchoscopy in the intensive care unit. *Intensive Care Med* 1992; 18:160-69

- Joos L, Patuto N, Chhajed P. N & Tamm M. (2006). Diagnostic yield of flexible bronchoscopy in current clinical practice. *Swiss Med Wkly* 2006; 136:155-159
- Katz AS, Michelson MD, Stawicki J & Holford FD. (1981). Cardiac arrhythmias: frequency during bronchoscopy and correlation with hypoxemia. *Arch Intern Med* 1981; 141: 603-606
- Kerwin AJ, Croce MA, Timmons SD, Maxwell RA, Malhotra AK & Fabian TC. (2000). Effects of fiberoptic bronchoscopy on intracranial pressure in patients with brain injury: A prospective clinical study. *J Trauma* 2000; 48:878-83
- Knox AJ, Mascie-Taylor BH & Page RL. (1988). Fiberoptic bronchoscopy in the elderly: four years' experience. *Br J Dis Chest*. 1988; 82:290-3.
- Kobashi Y, Mouri K, Fukuda M, Yoshida K & Oka M. (2007). The Usefulness of Bronchoscopy for the Diagnosis of Pulmonary Tuberculosis. *J Bronchol* 2007; 14:22-25
- Kollef MH, Bock KR, Richards RD & Hearn ML (1995). The safety and diagnostic accuracy of minibronchoalveolar lavage in patients with suspected ventilator-associated pneumonia. *Ann Intern Med* 1995; 122:743-748
- Kollef MH & Ward S. (1998). The influence of mini-BAL cultures on patient outcomes: implications for the antibiotic management of ventilator associated pneumonia. *Chest* 1998; 113:412-420.
- Kozak E & Brath L. (1994). Do "screening" coagulation tests predict bleeding in patients undergoing fiberoptic bronchoscopy with biopsy? *Chest* 1994;106:703-5.
- Kvale P. (1996). Is it really safe to perform bronchoscopy after a recent acute myocardial infarct? *Chest* 1996; 110:591-2.
- Lan RS, Lee CH, Tsai YH, Wang WJ & Chang CH. (1987). Fiberoptic bronchial blockade in a small bronchopleural fistula. *Chest* 1987; 92:944-946
- Lan RS, Lee CH, Chiang YC & Wang WJ. (1989). Use of fiberoptic bronchoscopy to retrieve bronchial foreign bodies in adults. *Am Rev Respir Dis* 1989;140:1734-7.
- Lee T. (1994). Fiberoptic bronchoscopy and intracranial pressure. *Chest*. 1994; 105:1909.
- Limper AH & Prakash UB. (1990). Tracheobronchial foreign bodies in adults. *Ann Intern Med* 1990;112:604-9.
- Liam CK, Pang YK & Poosparajah S. (2007). Diagnostic yield of flexible bronchoscopic procedures in lung cancer patients according to tumour location. *Singapore Med J* 2007;48(7):625-31.
- Lindholm CE, Ollman B, Snyder J, Millen E & Grenvik A. (1974). Flexible fiberoptic bronchoscopy in critical care medicine: diagnosis, therapy, and complications. *Crit Care Med* 1974; 2:250-261
- Lois M & Noppen M. (2005). Bronchopleural fistulas: an overview of the problem with special focus on endoscopic management. *Chest*. 2005 ; 128 ( 6 ): 3955-3965
- Loube D, Johnson J, Wiener D, Anders GT, Blanton HM & Hayes JA. (1993). The effect of forceps size on the adequacy of specimens obtained by transbronchial biopsy. *Respir Dis* 1993; 148:1411-3.
- Luna CM, Vujacich P, Niederman MS, Vay C, Gherardi C, Matera J & Jolly EC. (1997). Impact of BAL data on therapy and outcome of ventilator associated pneumonia. *Chest* 1997; 111:676-687
- Lundgren R, Haggmark S & Reiz S. (1982). Hemodynamic effects of flexible fiberoptic bronchoscopy performed under topical anaesthesia. *Chest* 1982; 82:295-299.

- Lynch JP III & Sitrin RG. (1993). Noninfectious mimics of community acquired pneumonia. *Semin Respir Infect* 1993;8:14-45.
- Maertens J, Maertens V, Theunissen K, Meersseman W, Meersseman P, Meers S, Verbeken E, Verhoef G, Van Eldere J & Lagrou K. (2009): Bronchoalveolar lavage fluid galactomannan for the diagnosis of invasive pulmonary aspergillosis in patients with hematologic diseases. *Clin Infect Dis* 2009, 49:1688-93
- Mandell LA, Wunderink RG, Anzueto A, Bartlett JG, Campbell GD, Dean NC, Dowell SF, File TM Jr, Musher DM, Niederman MS, Torres A & Whitney CG. (2007). Infectious Diseases Society of America/American Thoracic Society consensus guidelines on the management of community-acquired pneumonia in adults. *Clin Infect Dis* 2007;44 (Suppl 2):S27-72
- Marini JJ, Pierson DJ & Hudson LD. (1979) Acute lobar atelectasis: a prospective comparison of fiberoptic bronchoscopy and respiratory therapy. *Am Rev Respir Dis* 1979, 119:971-978.
- Martinot A, Closset M, Marquette C H, Hue V, Deschildre A, Ramon P, Remy J & Leclerc F. (1997). Indications for flexible versus rigid bronchoscopy in children with suspected foreign-body aspiration *Am. J. Respir. Crit. Care Med* 1997; 155:1676-1679.
- Matsushima Y, Jones R, King E, Moysa G & Alton J. (1984) . Alterations in pulmonary mechanics and gas exchange during routine fiberoptic bronchoscopy. *Chest* 86:184-188
- Mavritsyn LE & Lifshits NA. (1980). Complications in the fiber bronchoscopy of bronchial asthma patients. *Klinicheskaia Meditsina* 1980;58:37-40.
- Mazzone P, Jain P, Arroliga AC & Matthay RA. (2002). Bronchoscopy and needle biopsy techniques for diagnosing and staging of lung cancer. *Clin Chest Med* 2002; 23(1):137-58.
- Meersseman W, Lagrou K, Maertens J, Wilmer A, Hermans G, Vanderschueren S, Spriet I, Verbeken E & Van Wijngaerden E. (2008). Galactomannanin bronchoalveolar lavagefluid:a tool for diagnosing aspergillosis in intensive care unit patients. *Am J Respir Crit Care Med* 2008;177(1):27-34.
- Mehta NL, Harkin TJ, Rom WN, Graap W, Addrizzo-Harris & Doreen J. (2005). Should Renal Insufficiency Be a Relative Contraindication to Bronchoscopic Biopsy? *J Bronchol* 2005; 12:81-83
- Milman N, Munch E, Faurschou P, Grode G, Peterson BN, Struve-Christensen E & Svendsen UG. (1993). Fiberoptic bronchoscopy in local anaesthesia. Indications, results and complications in 1323 examinations. *Acta Endosc* 1993;23:151-62
- Muscledere JG, Martin CM & Heyland DK. (2008). The impact of ventilator-associated pneumonia on the Canadian health care system. *J. Crit. Care* 2008; 23(1), 5-10.
- National Nosocomial Infections Surveillance (NNIS) System. National Nosocomial Infections Surveillance (NNIS) System report, data summary from January 1990-May 1999, issued June 1999. *Am J Infect Control* 1999; 27:520-532.
- Nicolai T. (2001). Pediatric bronchoscopy. *Pediatr Pulmonol* 2001; 31: 150-164.
- Nguile-Makao M, Zahar JR, Français A, Tabah A, Garrouste-Orgeas M, Allaouchiche B, Goldgran-Toledano D, Azoulay E, Adrie C, Jamali S, Clec'h C, Souweine B & Timsit JF (2010): Attributable mortality of ventilator-associated pneumonia: respective impact of main characteristics at ICU admission and VAP onset using

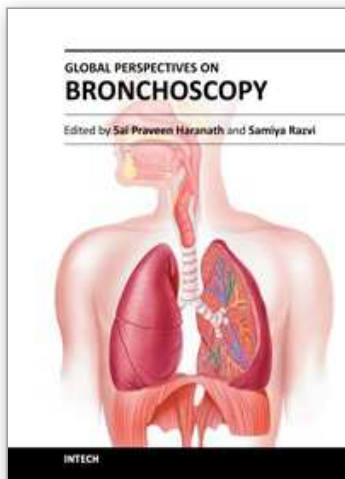


- conditional logistic regression and multi-state models. *Intensive Care Med* 2010, 36:781-789.
- O'Brien JD, Ettinger NA, Shevlin D, & Kollef MH. (1997). Safety and yield of transbronchial biopsy in mechanically ventilated patients. *Crit Care Med* 1997; 25:440-6.
- Oren Fruchter, Mordechai R. Kramer & Tamir Dagan. (2011). Endobronchial Closure of Bronchopleural Fistulae Using Amplatzer Devices Our Experience and Literature Review. *Chest* 2011;139:682-687
- Papazian L, Thomas P, Bregeon F, Garbe L, Zandotti C, Saux P, Gaillat F, Drancourt M, Auffray JP & Gouin F. (1998). Open-lung biopsy in patients with acute respiratory distress syndrome. *Anesthesiology* 1998; 88: 935-94
- Papin T, Lynch J & Weg J. (1985). Transbronchial biopsy in the thrombocytopenic patient. *Chest* 1985; 88:549-52.
- Patrick F. Allan PF & Ouellette D. (2003). Bronchoscopic Procedures in Octogenarians. *J Bronchol* . 10:112-117, 2003.
- Peacock M, Johnson J & Blanton H. (1994). Complications of flexible bronchoscopy in patients with severe obstructive pulmonary disease. *J Bronchol* 1994; 1:181-6.
- Pechkam D & Elliott MW. (2002). Pulmonary infiltrates in the immunocompromised: Diagnosis and management. *Thorax* 2002;57(suppl 2):II3- II7
- Peerless JR, Snow N, Likavec MJ, Pinchak AC & Malangoni MA. (1995). The effect of fiberoptic bronchoscopy on cerebral hemodynamics in patients with severe head injury. *Chest*. 1995;108:962-965.
- Pennington JE. (1990). Nosocomial respiratory infection. : Editors - Mandell GL, Douglas RG Jr, Bennet JE : Principles and practice of infectious diseases. St. Louis, MO: Churchill Livingstone; 1990. p. 2199-2205.
- Pereira W, Kovnat D & Snider G. (1978). A prospective cooperative study of complications following flexible fiberoptic bronchoscopy. *Chest* 1978; 73:813-6.
- Pincus P S, Kallenbach J M, Hurwitz M D, Clinton C, Feldman C, Abramowitz J A, & Zwi S. (1987). Transbronchial biopsy during mechanical ventilation. *Crit Care Med* 1987; 15:1136-9.
- Prakash UBS, Stubbs SE. Optimal Bronchoscopy. *Journal of Bronchology*. 1994; 1; 44-62
- Prakash UBS, Offord KP & Stubbs SE. (1991). Bronchoscopy in North America: The ACCP Survey. *Chest* 1991; 100:1668-75
- Pue C & Pacht E. (1995). Complications of fiberoptic bronchoscopy at a university hospital. *Chest* 1995; 107:430-2.
- Pugin J, Auckenthaler R, Mili N, Janssens JP, Lew PD, Suter PM (1991) Diagnosis of ventilator-associated pneumonia by bacteriologic analysis of bronchoscopic and nonbronchoscopic "blind" bronchoalveolar lavage fluid. *Am Rev Respir Dis* 143:1121-1129
- Raghavendran K, Nemzek J, Napolitano LM & Knight PR. (2011). Aspiration-induced lung injury. *Crit Care Med* 2011; 39:818-826
- Rankin J, Snyder P, Schachter E & Matthay RA. (1984). Bronchoalveolar lavage. Its safety in subjects with mild asthma. *Chest* 1984; 85: 723-8.
- Rebulla P: (2001). Platelet transfusion trigger in difficult patients. *Transfus Clin Biol* 2001;8:249- 254.
- Regel G, Sturm JA, Neumann C, Schueler S & Tscherne H. (1989). Occlusion of bronchopleural fistula after lung injury: a new treatment by bronchoscopy. *J Trauma* 1989; 29:223-226

- Rennard SI. (1990). Bronchoalveolar lavage in the diagnosis of cancer. *Lung* 1990;168:1035–40.
- Rudy EB, Turner BS, Baun M, Stone KS & Brucia J. (1991). Endotracheal suctioning in adults with head injury. *Heart Lung*. 1991;20:667– 674.
- Schreiber G & McCrory DC. (2003). Performance characteristics of different modalities for diagnosis of suspected lung cancer: summary of published evidence. *Chest* 2003; 123(Suppl 1):115S–28S.
- Schurink CA, Van Nieuwenhoven CA, Jacobs JA, Rozenberg-Arska M, Joore HC, Buskens E, Hoepelman AI & Bonten MJ (2004) Clinical pulmonary infection score for ventilator-associated pneumonia: accuracy and inter-observer variability. *Intensive Care Med* 2004; 30:217–224
- Schwartz DE, Matthay MA & Cohen NH. (1995). Death and other complications of emergency airway management in critically ill adults. A prospective investigation of 297 tracheal intubations. *Anesthesiology*. 1995;82:367–376. .
- Semenzato G, Spatafora M, Feruglio C, Pace E & Dipietro V. (1990). Bronchoalveolar lavage and the immunology of lung cancer. *Lung* 1990;168:1041–9.
- Singh N, Rogers P, Atwood CW, Wagener MM & Yu VL. (2000). Shortcourse empiric antibiotic therapy for patients with pulmonary infiltrates in the intensive care unit. A proposed solution for indiscriminate antibiotic prescription. *Am J Respir Crit Care Med* 2000;162:505–511
- Snow N & Lucas A. (1984). Bronchoscopy in the critically ill surgical patient. *Am Surg* 1984; 50:441–445
- Spiro S. G & Porter J. C. (2002). Lung Cancer—Where Are We Today? Current Advances in Staging and Nonsurgical Treatment *Am J Respir Crit Care Med* Vol 166. pp 1166–1196, 2002
- Stephan F, Hollande J, Richard O, Cheffi A, Maier-Redelsperger M & Flahault A. (1999). : Thrombocytopenia in a surgical ICU. *Chest* 1999, 115:1363-1370.
- Stevens RP, Lillington GA & Parsons G. (1981) Fiberoptic bronchoscopy in the intensive care unit. *Heart Lung* 1981; 10:1037– 1045
- Strauss R, Wehler M, Mehler K, Kreutzer D, Koebnick C & Hahn EG. (2002). Thrombocytopenia in patients in the medical intensive care unit: bleeding prevalence, transfusion requirements, and outcome. *Crit Care Med* 2002, 30:1765-1771.
- Surat PM, Smiddy JF & Gruber B. (1979). Death and complications associated with fiberoptic bronchoscopy. *Chest*. 1979; 69:747–751.
- Talmadge E. King, Jr. (2005). Clinical Advances in the Diagnosis and Therapy of the Interstitial Lung Diseases. *Am J Respir Crit Care Med* 2005;Vol 172. pp 268–279
- Torres A & El-Ebiary M. (2000). Bronchoscopic BAL in the diagnosis of ventilator-associated pneumonia. *Chest* 2000;117(4 Suppl 2):198S– 202.
- Torres, A. , Serra-Batlles J, Ferrer A, Jimenez P, Celis R, Cobo E & Rodriguez-Roisin R. (1991). Severe community-acquired pneumonia: epidemiology and prognostic factors. *Am. Rev. Respir. Dis*. 1991. 144:312-318
- Tsushima K, Sone S, Hanaoka T, Takayama F, Honda T & Kubo K. (2006). Comparison of bronchoscopic diagnosis for peripheral pulmonary nodule under fluoroscopic guidance with CT guidance. *Respir Med*. Apr 2006;100(4):737-45.
- Tsukamoto T, Sasaki H & Nakamura H: (1989). Treatment of hemoptysis patients by thrombin and fibrinogen-thrombin infusion therapy using a fiberoptic bronchoscope. *Chest* 96:473–476, 1989



- Uchida J, Imamura F, Takenaka A, Yoshimura M, Ueno K, Oda K, Nakayama T, Tsukamoto Y, Higashiyama M & Kusunoki Y. (2006). Improved diagnostic efficacy by rapid cytology test in fluoroscopy- guided bronchoscopy. *J Thorac Oncol* 2006; 1(4):314-8.
- Van Vyve T, Chanez P, Bousquet J, Lacoste JY, Michel FB & Godard P. (1992). Safety of bronchoalveolar lavage and bronchial biopsies in patients with asthma of variable severity. *Am Rev Respir Dis* 1992; 146: 116-21.
- Vanderschueren S, De Weerd A, Malbrain M, Vankersschaever D, Frans E, Wilmer A & Bobbaers H. (2000). Thrombocytopenia and prognosis in intensive care. *Crit Care Med* 2000, 28:1871-1876.
- Venkateshiah S. B & Mehta A. C. (2003). Role of Flexible Bronchoscopy in the Diagnosis of Pulmonary Tuberculosis in Immunocompetent Individuals. *J Bronchol* 2003;10: 300-308
- Wahidi MM & Ernst A. (2004). The role of bronchoscopy in the management of lung transplant recipients. *Respir Care Clin* 2004;10: 549-562
- Wall CP, Gaensler EA, Carrington CB & Hayes JA. (1981). Comparison of Transbronchial and open biopsies in chronic infiltrative lung diseases. *Am Rev Respir Dis* 1981; 123:280-285.
- Wang KP, Brower R, Haponik EF & Siegelman S. (1983). Flexible Transbronchial needle aspiration for staging of bronchogenic carcinoma. *Chest* 1983; 84:571-576
- Wang KP, Wise RA, Terry PB, Kaplan J, Britt EJ, Haponik EF, Summer WR & Marsh B. (1980). Comparison of standard and large forceps for transbronchial lung biopsy in the diagnosis of lung infiltrates. *Endoscopy*. Jul 1980;12(4):151-4.
- Weinstein HJ, Bone RC & Ruth WE. (1977). Pulmonary lavage in patients treated with mechanical ventilation. *Chest* 1977; 72:583-587
- Weiss SM, Hert RC, Gianola FJ, Clark JG & Crawford SW: Complications of fiberoptic bronchoscopy in thrombocytopenic patients. *Chest* 1993, 104: 4. 1025-1028.
- Wintrobauer RH. (1995). Mimics of pneumonia. *Semin Respir Infect* 1995;10:63-120.
- Wood RE. (1984). Spelunking in the pediatric airways: explorations with the flexible fiberoptic bronchoscope. *Pediatr Clin North Am* 1984; 31: 785-799.
- Wood RE. (1985). The diagnostic effectiveness of the flexible bronchoscope in children *Pediatric Pulmonology*. 1985; 1:188-192 DOI: 10. 1002/ppul. 1950010404
- Wood-Baker R, Burdon J, McGregor A, Robinson P & Seal P. (2001). Fiber-optic bronchoscopy in adults: a position paper of The Thoracic Society of Australia and New Zealand. *Intern Med J* 2001;31:479-87
- Yende S & Wunderink RG. (2001). Effect of clopidogrel on bleeding after coronary artery bypass surgery. *Crit Care Med* 2001; 29:2271-2275
- Yung RC. (2003). Tissue diagnosis of suspected lungcancer: selecting between bronchoscopy, transthoracic needle aspiration, and resectional biopsy. *Respir Care Clin N Am* 2003;9(1):51-76.
- Zavala DC. (1975). Diagnostic fiberoptic bronchoscopy: techniques and results of biopsy in 600 patients. *Chest* 1975; 68:12-9.
- Zavala DC. (1976). Pulmonary hemorrhage in fiberoptic transbronchial biopsy. *Chest* 1976; 70:584-8.
- Zavala DC. (1978). Complications following fiberoptic bronchoscopy. *Chest* 1978; 73:783-5.
- Zink A, Fritsch K, Eich C & Thurnheer R. (2007). Pneumothorax after Transbronchial Biopsy or Fine Needle Aspiration: Can it be Predicted? A Prospective Study of 94 Cases. *J Bronchol* 2007; 14:162-164.



## **Global Perspectives on Bronchoscopy**

Edited by Dr. Sai P. Haranath

ISBN 978-953-51-0642-5

Hard cover, 240 pages

**Publisher** InTech

**Published online** 13, June, 2012

**Published in print edition** June, 2012

Bronchoscopy has become an essential part of modern medicine . Recent advances in technology have allowed integration of ultrasound with this tool. The use of lasers along with bronchoscopes has increased the therapeutic utility of this device. Globally an increasing number of pulmonary specialists, anaesthesiologists and thoracic surgeons are using the bronchoscope to expedite diagnosis and treatment. The current volume on bronchoscopy adds to the vast body of knowledge on this topic. The democratic online access to this body of knowledge will greatly increase the ease with which both trainees and expert bronchoscopists can learn more .The contributions from around the world cover the breadth of this field and includes cutting edge uses as well as a section on pediatric bronchoscopy . The book has been an effort by excellent authors and editors and will surely be a often reviewed addition to your digital bookshelf. . In summary, this book is a great testament to the power of collaboration and is a superb resource for doctors in training, ancillary team members as well as practicing healthcare providers who have to perform or arrange for bronchoscopy or the associated procedures.

### **How to reference**

In order to correctly reference this scholarly work, feel free to copy and paste the following:

Gilda Diaz-Fuentes and Sindhaghatta K. Venkatram (2012). Role of Flexible-Bronchoscopy in Pulmonary and Critical Care Practice, Global Perspectives on Bronchoscopy, Dr. Sai P. Haranath (Ed.), ISBN: 978-953-51-0642-5, InTech, Available from: <http://www.intechopen.com/books/global-perspectives-on-bronchoscopy/role-of-flexible-bronchoscopy-in-pulmonary-and-critical-care-practice>

**INTech**  
open science | open minds

#### **InTech Europe**

University Campus STeP Ri  
Slavka Krautzeka 83/A  
51000 Rijeka, Croatia  
Phone: +385 (51) 770 447  
Fax: +385 (51) 686 166  
[www.intechopen.com](http://www.intechopen.com)

#### **InTech China**

Unit 405, Office Block, Hotel Equatorial Shanghai  
No.65, Yan An Road (West), Shanghai, 200040, China  
中国上海市延安西路65号上海国际贵都大饭店办公楼405单元  
Phone: +86-21-62489820  
Fax: +86-21-62489821

© 2012 The Author(s). Licensee IntechOpen. This is an open access article distributed under the terms of the [Creative Commons Attribution 3.0 License](https://creativecommons.org/licenses/by/3.0/), which permits unrestricted use, distribution, and reproduction in any medium, provided the original work is properly cited.

IntechOpen

IntechOpen