

We are IntechOpen, the world's leading publisher of Open Access books Built by scientists, for scientists

6,900

Open access books available

186,000

International authors and editors

200M

Downloads

Our authors are among the

154

Countries delivered to

TOP 1%

most cited scientists

12.2%

Contributors from top 500 universities



WEB OF SCIENCE™

Selection of our books indexed in the Book Citation Index
in Web of Science™ Core Collection (BKCI)

Interested in publishing with us?
Contact book.department@intechopen.com

Numbers displayed above are based on latest data collected.
For more information visit www.intechopen.com



Mandibular Condylar Hiperplasia

Everton Da Rosa, Júlio Evangelista De Souza Júnior and
Melina Spinosa Tiussi
*Hospital de Base do Distrito Federal
Brazil*

1. Introduction

1.1 Asymmetry

The term symmetry was defined as the mathematical identity between the mirror images of the right and left halves of an object. However, it is rare for humans to have such mathematical symmetry in the craniofacial skeleton¹. Robinson et al reported that a beautiful face should be harmonious with comparable size and position of the skeletal structures and soft tissues². They stated that a favorable face can be shown by the soft tissues². For patients with maxillofacial deformity, facial asymmetry is a common chief complaint, although patients might have other sagittal or vertical jaw imbalances concomitantly¹. In contrast, facial asymmetry might be masked by severe facial skeletal imbalance, dental malalignment, soft tissue compensation, or tilting of head posture¹. The documented prevalence of facial asymmetry ranges from 21% to 85%¹. Usually the structures of the lower face are more asymmetric than those of the upper face¹.

Bishara et al, 1994, in a review of dental and facial asymmetries, showed that many factors are implicated in asymmetry: genetic or congenital malformations such as hemifacial microsomia, environmental factors such as habits and trauma, functional deviations, and so on³. Asymmetry can have different characteristics even with the same etiology because it can be influenced by other factors such as onset, individual growth, and compensation³.

Although the nature of asymmetry is complex and its characteristics are diverse, approaches to systematic classification of facial asymmetry have been few⁴. Hinds et al, 1960, classified mandibular asymmetry into 2 categories: unilateral condylar hyperplasia and deviation prognathism⁵. Rowe, 1960 classified asymmetry into 3 groups: unilateral condylar hyperplasia, unilateral macrognathia confined to the skeletal element only, and unilateral macrognathia of both osseous and muscular components⁶. Bruce and Hayward, in 1968, classified mandibular asymmetry into deviation prognathism, unilateral condylar hyperplasia and unilateral macrognathia⁷. Obwegeser, 1986, suggested classifying asymmetries as either a hemimandibular elongation or a hemimandibular hyperplasia⁸. Bishara et al, 1994, classified dentofacial asymmetry into dental, skeletal, muscular, and functional³.

Asymmetries can be assessed by clinical evaluation, photographs, posteroanterior (PA) cephalograms and 3D computed tomography (CT) scans. On physical examination,

asymmetries becomes most apparent when the patient smiles⁹. At rest, however, the presence of an elevated labial commissure or alar base on one side is often an indication of vertical skeletal asymmetry⁹. This should be documented during routine evaluation of patients for orthodontic or orthognathic surgical treatment. To measure occlusal canting, a wooden tongue depressor can be placed across the right and left posterior teeth, and the parallelism or the angle of the tongue depressor to the interpupillary plane can be documented⁹. Alternatively, the vertical distance between the maxillary canines and the medial canthi of the eyes can be measured⁹.

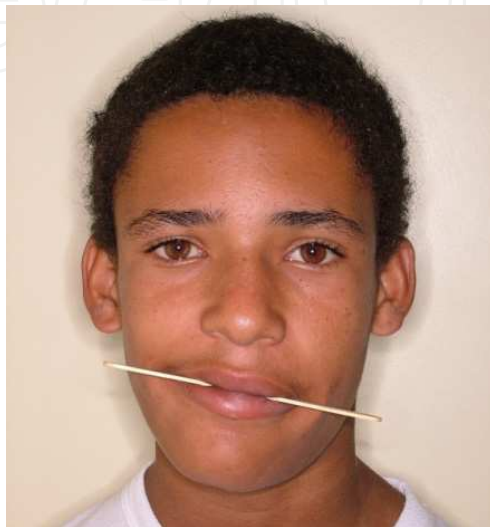

Fig. 1. Measuring occlusal canting

Other important tools for objective evaluation of face symmetry are photographs. Ferrario et al used digitized photographic analysis to determine angulation of the occlusal plane¹. A mean angulation from 2.15° to 2.90° was found in healthy normal patients¹. For evaluation of skeletal and dental structures, posteroanterior (PA) cephalogram is commonly used as an effective tool to quantify asymmetry. By identifying the horizontal and midsagittal reference planes, the difference in the distance of the counterpart land-marks on each half of the skeleton can be measured and calculated¹. Analysis of the PA cephalogram also can be used to determine occlusal cant⁹. A line is drawn connecting the occlusal surfaces of the left and right maxillary first molars. The angle of this plane relative to the transverse axis of the skull, that is, the angle of occlusal cant, is measured⁹.

On last decades, 3D computed tomography (CT) scans has helped surgeons to improve evaluation, planning and accuracy of orthognathic surgery. With this new technology, it is possible to create 3D models of the face that incorporate accurate renditions of the teeth, skeleton, and soft tissues. These techniques are more important in the assessment of asymmetries, since in PA cephalograms all facial structures are projected onto a single sagittal plane¹⁰.

The decision of surgical correction of facial asymmetry might depend on patients awareness of the esthetic problem, extent of occlusal deterioration, and concomitant sagittal or vertical jaw imbalance¹. It has been suggested that a level occlusal plane is a prerequisite for success in all orthognathic surgeries¹. Two-jaw orthognathic surgery might be necessary in cases with obvious cant of the frontal occlusal plane¹. Treatment goals of orthognathic correction

in facial asymmetry should consist of correlated maxillary midline to facial midline, level oral commissures, symmetric appearance of bilateral maxillary canines and correlated chin point to facial midline. Ideally the planned surgical prediction of the frontal occlusal plane should be parallel to the orbital plane on PA cephalograms; the central contact of maxillary incisors and chin point (menton) should be in the mid-sagittal plane; and the axis of the front teeth should parallel the midsagittal plane¹.

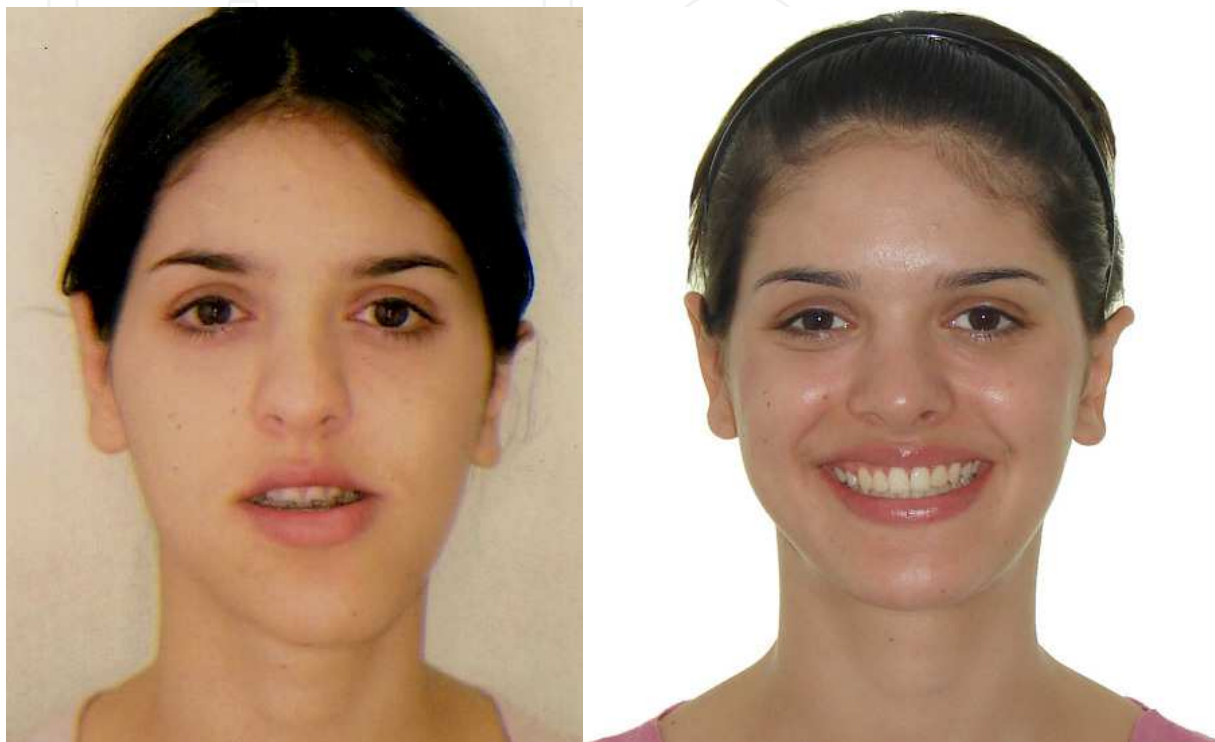

Fig. 2. Face balance after orthognathic surgery with high condylectomy in treatment of condylar hiperplasia

2. Mandibular condylar hyperplasia (CH)

Mandibular condylar hyperplasia (CH) is a non-neoplastic rare malformation that changes morphology and size of mandibular condyles¹¹. It was first described by Robert Adams in 1836 as a condition that causes overdevelopment of the mandible, creating functional and esthetic problems¹². The excessive unilateral growth of the mandibular condyle can lead to facial asymmetry, occlusal disturbance, and joint dysfunction¹³. It represents a challenge to both surgeons and orthodontists and because of the severe dentofacial deformity it can create¹⁴. A complete understanding of the nature of the deformity, etiology, clinical presentation, options for treatment, and timing of treatment is required in order to achieve optimal treatment outcomes¹⁴.

2.1 Etiology and diagnosis

The etiology of condylar hyperplasia is controversial and not well understood¹⁵. CH usually develops during puberty and rarely begins after the age of 20¹⁴. The identification of sex hormone receptors in and around the temporomandibular joint (TMJ) and the pubertal

onset of CH strongly suggest a hormonal influence in the etiology¹⁴. Suggested theories include trauma followed by excessive proliferation in repair, infection, hormonal influences, arthrosis, hypervascularity, and a possible ge-netic role¹⁶. Obwegeser and Makek suggested that different growth factors individually controlling generalized hypertrophy and elongation might be responsible for the deformities⁸. Another possible cause being taken into consideration, but thus far not substantiated, is an increase in functional loading of the TMJ¹⁶.

CH occurs with equal frequency in males and females, as well as unilaterally and bilaterally¹⁴. These patients usually demonstrate a Class I or mild Class III skeletal and occlusal relationship before the onset of CH and develop into a Class III or severe Class III relationship as their growth accelerates¹⁴. CH usually begins during the second decade of life around the pubertal growth phase and can continue into the middle or late 20s¹⁴. The condyles growth pattern, in terms of magnitude, rate, and direction, can influence the timing of surgery and the types of corrective surgical procedures necessary¹⁴. Ninety-eight percent of facial growth is completed by age 15 in females and by age 17 or 18 in males¹⁹. During the pubertal growth, the mandible grows and lengthens from condylion to point B at a yearly growth rate of 1.6 mm for females and 2.2 mm for males¹⁹. Growth at a significantly accelerated rate or for a prolonged postpubertal time interval usually indicates active CH¹⁹.

The diagnosis of CH may be achieved by a combination of clinical and radiologic findings. Various methods have been used, including radiographic studies, bone scintigraphy, and histopathologic assessment. Panoramic and postero-anterior (PA) radiographs are useful for surveying the shapes of the mandibular condyles on both sides because the midlines of the face and dentition can be recorded and evaluated¹⁵. The lateral radiograph provides useful information, such as ramal height and mandibular condyle length. CT can also provide a three-dimensional rendition of both the soft tissue of the face and the underlying bone. TMJ radiographs may show abnormalities in the size and morphology of the condylar head and/or neck regions.

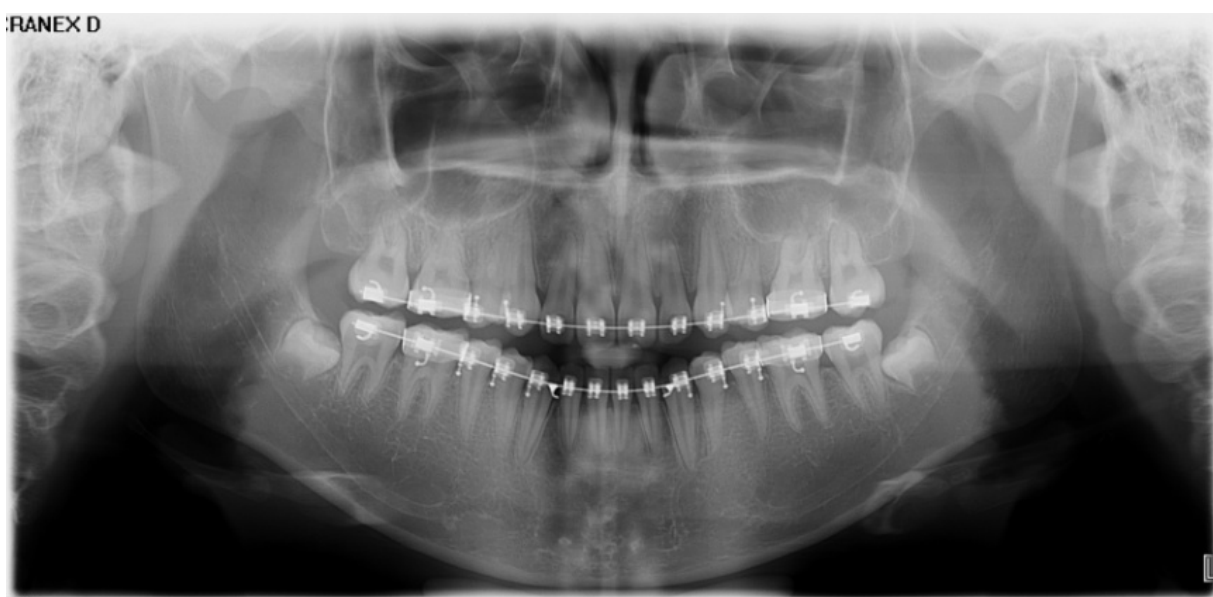

Fig. 3. Panoramic radiograph showing elongation of left condyle

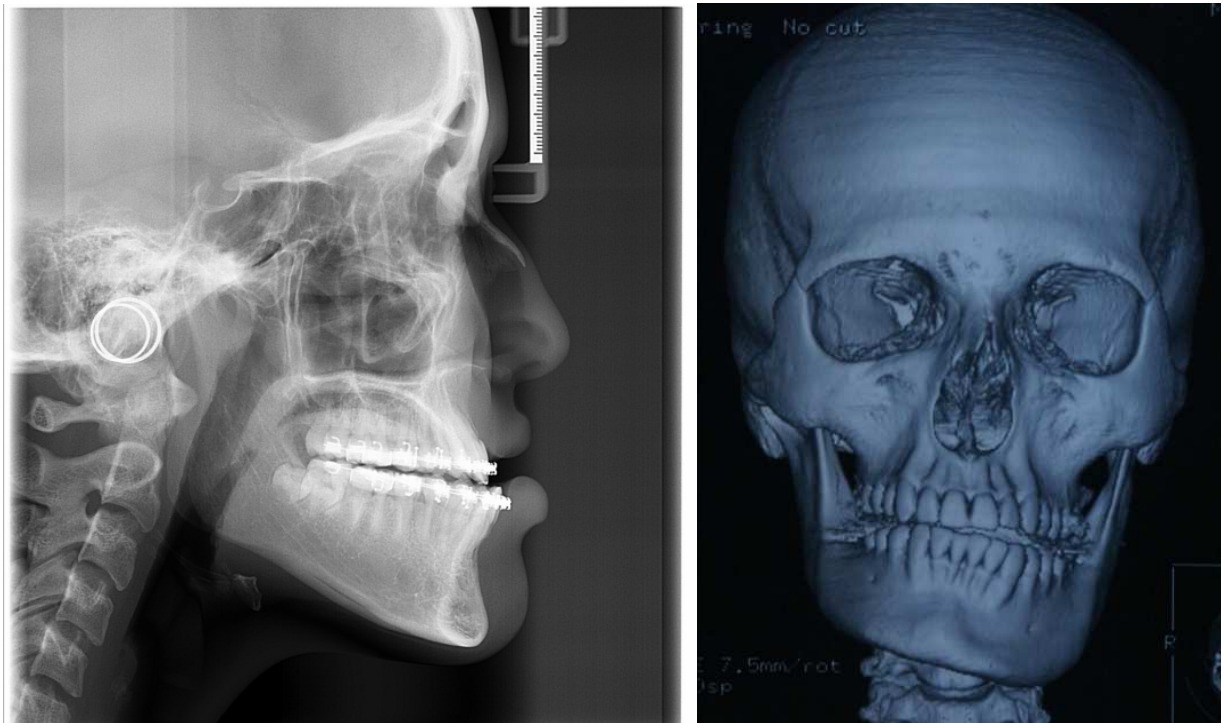


Fig. 4. Cephalogram radiograph and ct with three dimensional reconstruction

In order to develop the correct surgical plan, it is essential to distinguish active from inactive forms. Active CH growth can be determined by worsening functional and esthetic changes in time and might be detected by serial assessments consisting of clinical evaluation; dental model analysis and radiographic evaluation. Bone single photon emission computed tomography (SPECT) scan is an essential diagnostic tool for visualizing hyperactivity in the condyle¹⁶, especially in unilateral cases. Various studies have shown the clinical significance of this technique in such patients because this method identifies those with persistent unilateral condylar activity¹⁶. The radioactive isotope is technetium 99 methylene bisphosphonate. Increased radionuclide uptake by the hyperplastic condyle can be an indication of continued abnormal growth¹⁶. It has been reported that when there is a difference in activity of 10 % or more between the two condyles, it can be indicative of CH¹⁶. SPECT may be most effective in unilateral cases, especially if applied after the normal growing years, when condylar growth should have ceased. It might be inconclusive in younger patients, bilateral cases and those with slow growing CH. It is important to emphasize that SPECT results should be interpreted associated with clinical, radiographic, and cephalometric evaluation¹⁶. It should be borne in mind that this method of bone scanning, though highly sensitive, is nonspecific and does not necessarily correlate with active growth because it can also be the result of inflammatory conditions, infection, healing after traumatic injuries, and neoplastic lesions¹⁶. Bone SPECT scintigraphy should not be used as the only determinant for surgical treatment¹⁶.

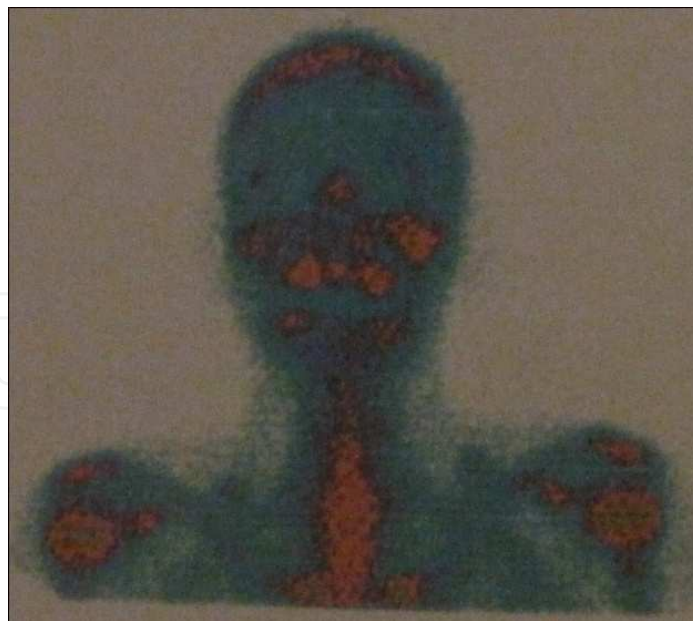


Fig. 5. Bone spect scintigraphy showing increased radionuclide uptake on left condyle

2.2 Classification and characteristics

Since 1836, when was first described by Adams¹², many cases of CH have been reported in the literature, but the key to understanding this clinical condition is attributed to Obwegeser and Makek, 1986⁸. They classified the asymmetry associated with CH into 3 categories: hemimandibular hyperplasia, causing asymmetry in the vertical plane; hemimandibular elongation, resulting in asymmetry in the transverse plane; and a combination of the 2 entities⁸. The first type is caused by unilateral growth in the vertical plane and is characterized by increased height of the maxillary alveolar bone and downward deviation of the occlusal plane in the ipsilateral side with almost no deviation of the chin⁸. If the maxillary plane fails to follow the mandibular plane, then an open bite may develop on the same side⁸. Most commonly, the mandibular midline is straight, but it may shift ipsilaterally⁸. Radiologically, Obwegeser and Makek reported that the condyle appears enlarged and that its head is usually irregular and deformed and its neck thickened and elongated, with coarse trabeculae filling the condyle⁸. Hemimandibular elongation, the second type of CH, is associated with chin deviation toward the contralateral side with no vertical asymmetry⁸. Intraorally, the mandibular midline deviates to the un-affected side, while the contralateral mandibular molars deviate lingually in attempt to remain in occlusion; however, cross-bite may develop in the contralateral side⁸. The occlusal plane is maintained with no deviation⁸. The condyle is of normal shape and size, but its neck can be either slender or normal, with an elongated ascending ramus⁸. The third type of CH is a combination of the first 2 types⁸.

Wolford et. al, in 2002 and 2009, proposed a simple classification to identify the various types of CH based on the frequency of occurrence, the types of jaw deformity created, and the surgical procedures necessary to get the best treatment outcomes^{14, 19}. This new classification seems to fit better the clinical findings in CH and can be correlated with planning treatment and prognosis.

The CH can be classified in two types:

- CH type 1 is the most frequently occurring form and involves an accelerated growth rate of the mandibular condyle with relatively normal architecture but elongation of the condylar head, neck, and mandibular body. It has a predominant horizontal growth vector, causing a Class III occlusal and skeletal relationship, although occasionally a vertical growth vector may occur. Type 1A is the bilateral form of CH with symmetric growth or asymmetric growth. Type 1B involves only one condyle, creating a progressively worsening facial asymmetry as the condyle grows. The accelerated mandibular growth usually occurs during puberty, and the mandibular growth can continue into the mid 20s but is self-limiting. The prevalence ratio between types 1 and 2 is approximately 15:1.
- CH type 2 occurs unilaterally and involves enlargement of the condylar head. Usually the condylar neck increases in thickness and the vertical height of the mandibular ramus and body increases on the ipsilateral side, often accompanied by a compensatory downward growth of the ipsilateral maxilla. CH type 2 can occur at any age and is not self-limiting. It can be caused by an osteochondroma, osteoma, or other rare forms of condylar enlargement.

Clinical and radiographic characteristics in CH type 1 ¹⁹
1. Increased length of the condylar head and neck, with normal architecture.
2. Accelerated rate of mandibular growth, beyond normal growth years.
3. Worsening Class III skeletal and occlusal relationship
4. Worsening aesthetics.
5. Obtuse gonial angles
6. Decreased angulation of lower incisors and increased angulation of upper incisors (dental compensations)
7. Decreased vertical height of the posterior mandibular body
8. High mandibular plane angle
Additional clinical and radiographic characteristics in CH type 1B ¹⁹
1. TMJ articular disc displacement on the contralateral side as a result of increased loading of that joint caused by the condylar hyperplasia on the opposite side
2. Worsening facial and occlusal asymmetry, with the mandible progressively shifting toward the contralateral side
3. Unilateral posterior cross-bite on the contralateral side
4. Transverse bowing of the mandibular body on the ipsilateral side
5. Transverse flattening of the mandibular body on the contralateral side
Clinical and radiographic characteristics in CH type 2 ¹⁴
1. Unilateral elongation of the face, causing facial asymmetry and worsening esthetics
2. Increased length, size, and diameter of the condylar head and neck
3. Increased vertical height of the entire mandible on the involved side (except for the coronoid process)
4. Open bite on the involved side
5. Compensatory vertical overdevelopment of the maxilla on the involved side
6. Dental compensations.

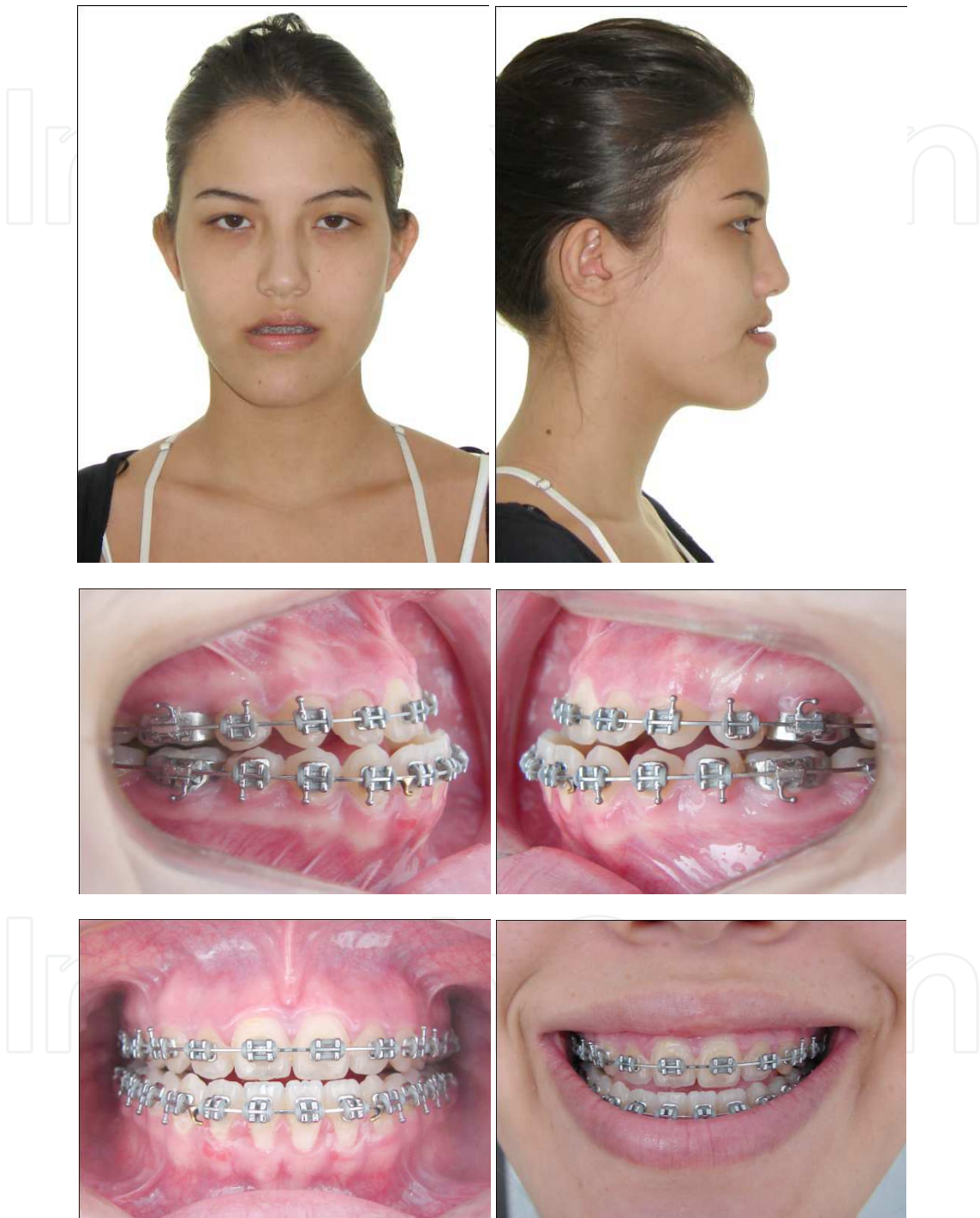
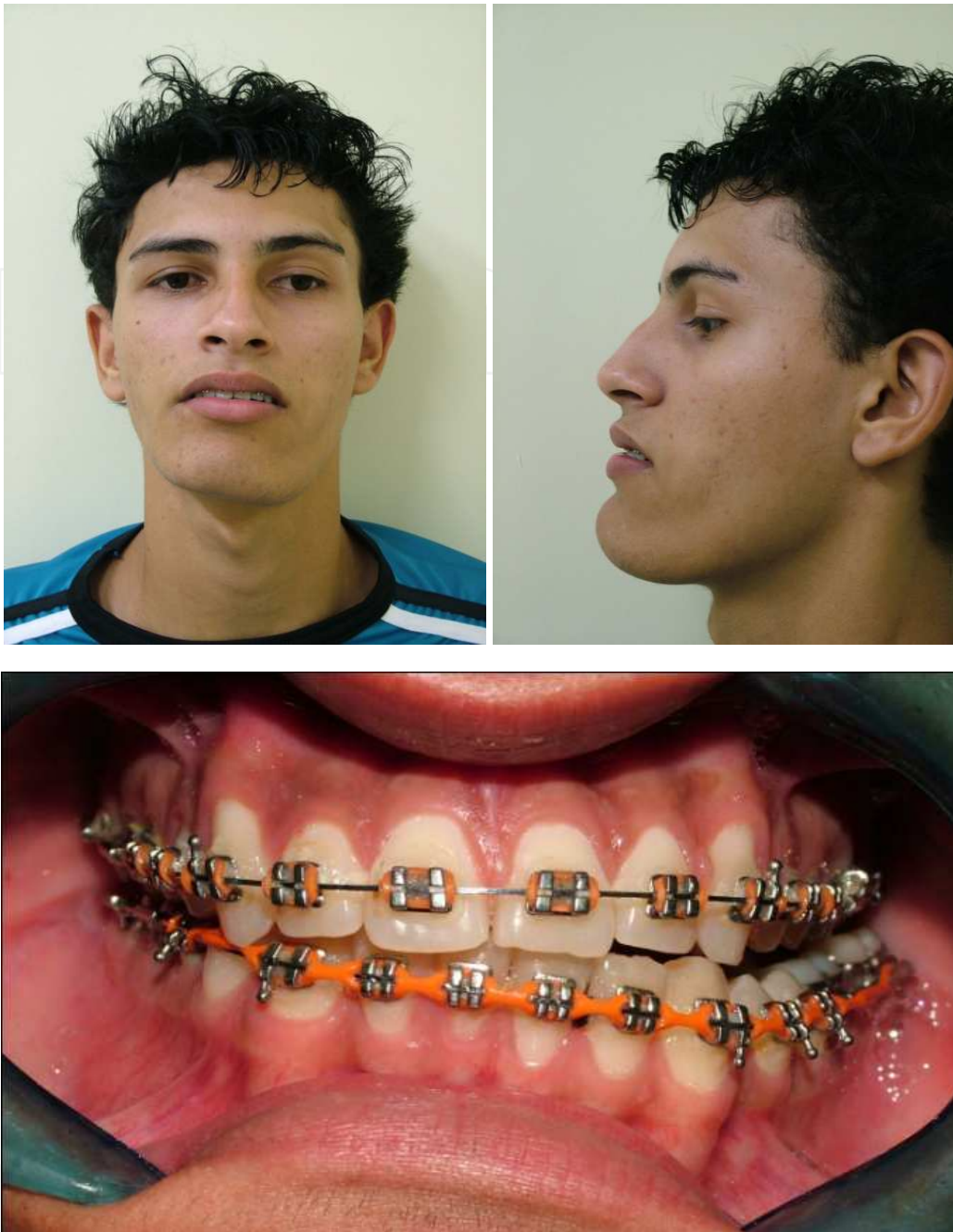

Fig. 6. CH type 1 on left condyle with facial assymetry, presenting mandibular midline deviation toward right side and right cross bite.



* Case provided by Dr. Elvidio de Paula e Silva

Fig. 7. CH type 2 on left condyle, presenting left elongation of mandible, left open bite and maxillary canting on left side.

2.3 Treatment planning

The treatment of CH is directly related to its activity. Patients with arrested CH (the abnormal condylar growth has stopped and become stable) can usually be treated with routine orthodontics and orthognathic surgery¹⁴. Treatment of active CH is primarily surgical, with or without orthodontics, and depends on the degree of severity and the status of condylar growth¹⁶. Different surgical options have been proposed for treating this entity,

ranging from high condylectomy to orthognathic surgery or a combination of both¹⁶. The high condylectomy arrests the excessive and disproportionate growth of the mandible by surgically removing one of the important mandibular growth sites and the site responsible for the CH pathological growth process¹⁹. The high condylectomy stops forward growth of the mandible, with only normal appositional growth remaining at pogonion and vertical alveolar growth if the surgery is performed before normal facial growth is completed²⁰. There is also controversy with respect to the time of surgery, with some authors preferring to perform surgery as soon as possible and others waiting for cessation of excessive activity to perform any intervention¹⁶.

The aim in immature patients is prevention of the progression of deformities and the spontaneous normalization of facial asymmetry and occlusion. The one surgical procedure that is able to stop disease progression and allow spontaneous resolution of dento-alveolar problems is condylectomy, if performed early (10 to 12 years old). This procedure leads to the removal of the hyperactive growth center, with physiological mandibular and dento-alveolar reshaping, and consequent normalization of the face and occlusion.

In adults, most dental compensations, functional problems and facial deformities are already in development. There are some options of treatment that have been reported. Previously, some authors advocated that corrective surgery could be deferred until growth was complete; this often means waiting until the middle or late 20s²². In these cases, the patient might suffer from functional problems (mastication and speech), worsening esthetic disfigurement, pain, and psychosocial stigmata associated with a severe facial deformity. Additionally, the magnitude of the deformity, if allowed to fully manifest by this delay in treatment, may preclude an ideal result later. This hyperplastic condylar growth may result in severe deformation of the mandible. Compensatory changes will occur in the maxilla, dentoalveolar structures, and associated soft tissue structures, significantly compromising the clinical treatment outcome. This treatment has been advocated by many surgeons in previous reports. However, with the full comprehensive of progression of CH and its consequences, it doesn't seem to be a good choice. Other authors have reported that orthognathic surgery could be performed during active CH growth, with consideration for overcorrection of the mandible. The accelerated mandibular condylar growth will continue after surgery, and repeat surgery will be needed if the estimated overcorrection is greater or lesser than necessary.

Based on surgical results of previous reports^{14,19} and many reports of bad results with other techniques¹⁴, it is believed that the two best treatment options for achieving favorable functional and esthetics results, with long-term stability are as follows:

1. The high condylectomy with disc repositioning is performed as soon as possible to arrest condyle and mandibular growth. Then, the orthodontic treatment aims to align and level the teeth over the basal bone and to remove dental compensations, regardless of the magnitude of skeletal and dental malalignment. In a second staged surgery, the conventional orthognathic surgery is performed. Usually, due to severe skeletal and dental deformity, bimaxillary surgery is necessary to achieve both functional and esthetic results. This treatment might be the choice when the orthodontic treatment will delay the condylectomy, with worsening of face and dental deformity.

2. The high condylectomy with disc repositioning is performed with simultaneous orthognathic surgery. This technique is helpful when patients have passed through orthodontic treatment previously and would be benefit with on staged surgery. The benefits of concomitant surgery provided to patients with coexisting TMJ pathology and dentofacial deformities include the following: 1) that it requires one operation and general anesthetic; 2) that it balances occlusion, TMJs, jaws, and neuromuscular structures, at the same time; 3) that it decreases overall treatment time; 4) that it eliminates unfavorable TMJ sequelae that can occur when performing orthognathic surgery only; and 5) that it avoids iatrogenic malocclusion that can occur when performing open TMJ surgery only²¹.

In CH type 2, the treatment is similar as described above. However, in cases of condylar enlargement by ostoeocondromas or other benign tumors, it might be necessary a more aggressive approach, with total resection of the tumor and reconstruction with autogenous grafts or total joint prosthesis. Traditional treatment of almost all reported cases of osteochondroma has included radical resection of the tumor, including the complete condylar process^{23,24,25}. Free autogenous bone grafts, costochondral grafts, prosthetic devices, or local pedicled osseous grafts have been used to reconstruct the TMJ region²⁶. Wolford et. al, 2002, proposed a conservative condylectomy below the head but high in the neck of the condyle, to entirely remove the lesion²⁷. The remaining condylar stump is recontoured to function as a “new” condylar head. The articular disc is then repositioned onto the “new” condyle and stabilized²⁷. Additional orthognathic procedures, if indicated, can be performed concomitantly for the correction of associated facial deformities²⁷.

Classification	Treatment
Arrested CH	Orthodontics and orthognathic surgery
Active CH in infants	High condylectomy and observation
Active CH in adults	High condylectomy and orthognathic surgery in one or two stages
CH type 2	Condylectomy and orthognathic surgery OR Condylar resection and total joint reconstruction*.

* in cases of large osteocondromas or other benign tumors.

Table 1. Surgical techinque

The surgical approach to TMJ structures is pre-auricular approach. The incision is marked on intersection of pre-auricular facial skin and ear helix. After preoperative drawing and landmark placement, a cutaneous incision is performed and deepened until reaching the deep temporal fascia. The superficial layer of the deep fascia is cut, reaching the fat tissue between the two layers of the temporal fascia²⁸. The dissection is proceeded deeper to the superficial layer of the fascia and reached the TMJ capsule caudal to the zygomatic arch. This is opened with a “T” incision, which identify the condylar head and disc. The condylar head is gently split from the articular disc, and condylar protectors are set medially to the head. A horizontal osteotomy line is drawn 4 e 5 mm caudal to the edge of the condylar head. The osteotomy is completed with chisel, the resected part is removed and the surface of the condylar head reshaped. Then, the articular disc is repositioned on condylar surface and attached with mini anchors or mini screws.

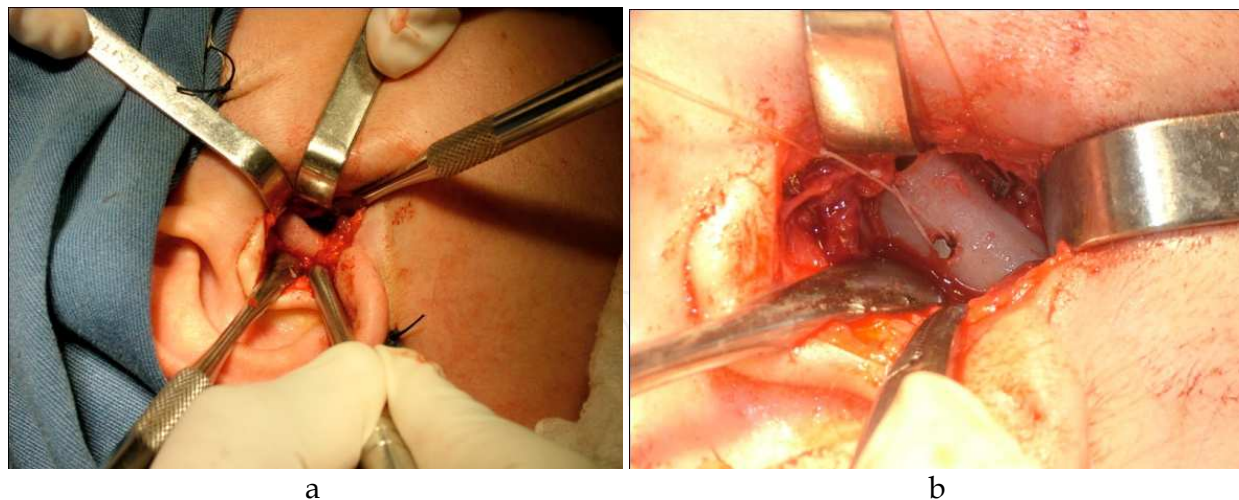


Fig. 8. Surgical exposure of right condyle (a) and high condylectomy with disc repositioning with mini-anchors (b).

If bimaxillary orthognathic surgery is planned to be performed concomitant with TMJ surgery, 2 choices of sequencing are possible. The first sequence will follow maxilla repositioning first, TMJ surgery, and then the mandibular osteotomy. The second sequence would be to first perform the TMJ surgery, then the mandibular osteotomy, and then to reposition the maxilla. Both techniques can provide the same results³⁰. However, the first sequence would make it much more difficult to maintain sterility during the TMJ surgery³⁰. One would have to try and maintain separate surgical fields (TMJ and oral cavity) and have a second set of sterile instruments available for the TMJ surgery³⁰. When performing TMJ surgery first, the same set of instruments used for the TMJ can be used for the mandibular and, subsequently, maxillary surgery³⁰.

2.4 3-Dimensional (3D) surgical planning and use of navigation

To facilitate the estimation of condylectomy and other mandibular contouring surgeries, 3-dimensional (3D) surgical planning by use of computed tomography (CT) data is now available and can be extremely helpful³¹. Surgical planning can be performed either with a stereolithographic or a virtual model generated by commercial softwares³¹. Surgical navigation is preferred as data export, because the surgical splint is considered bulky for precise placement during condylectomy and contouring surgeries³¹. Although various options are available for surgical planning and simulation, a precise data transfer to the real surgical environment still appears to be challenging to surgeons³¹. Currently, there are 2 approaches available for such a transfer: 1) surgical locating splint and; 2) real-time surgical navigation.

The surgical splint can be generated either from 1) a stereolithographic model planning with the help from laboratory technicians or 2) a virtual model planning by use of computer-aided design/computer-aided manufacturing technology³¹. The stereolithographic model planning is a relatively straightforward approach³¹. However, the seating of a surgical splint is highly dependent on sound anatomic structure with well-defined surface geometry for its fitting³¹. In situations such as condylectomy and mandibuloplasty, splint placement may be complicated because of limited surgery access³⁰. Although surgical navigation allows location of the drilling path under standard surgical exposure, the use in the mandible is

handicapped because of its mobile nature³⁰. By combining the merits of surgical navigation and stereolithographic model planning, Xia et. al (2010) have formulated a new treatment strategy, which involves correction of occlusal disharmony and skeletal deformity in one operation with a shorter time³¹. In the appropriate delegation of responsibility, surgeons need to prepare the model surgery planning and the transfer of the model surgery data to the surgical navigation system.

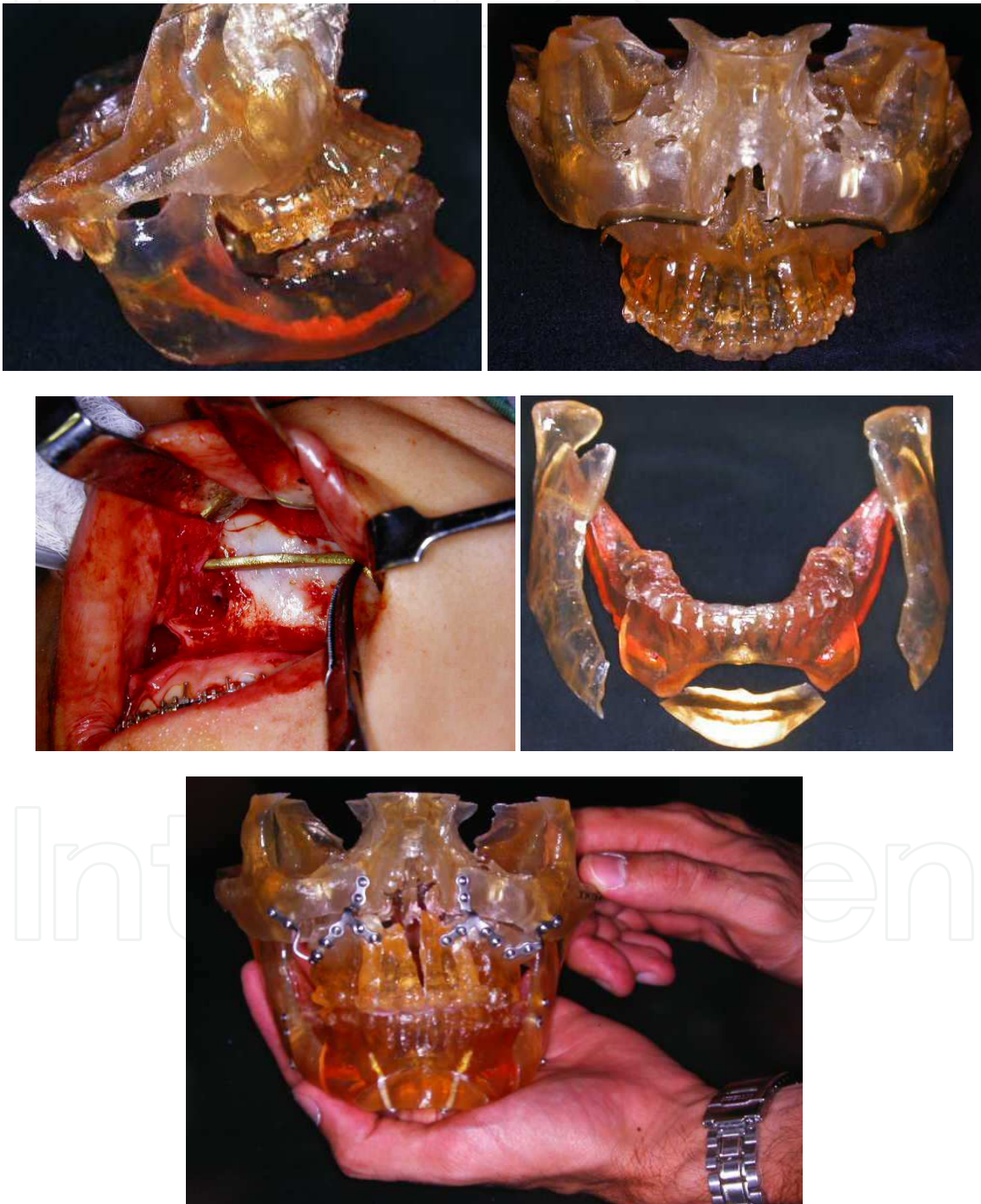

Fig. 9. Treatment planning using surgical simulation on a stereolithographic provided by Dr. Cesar Oleskovicz.

3. Case presentation

3.1 Case 1

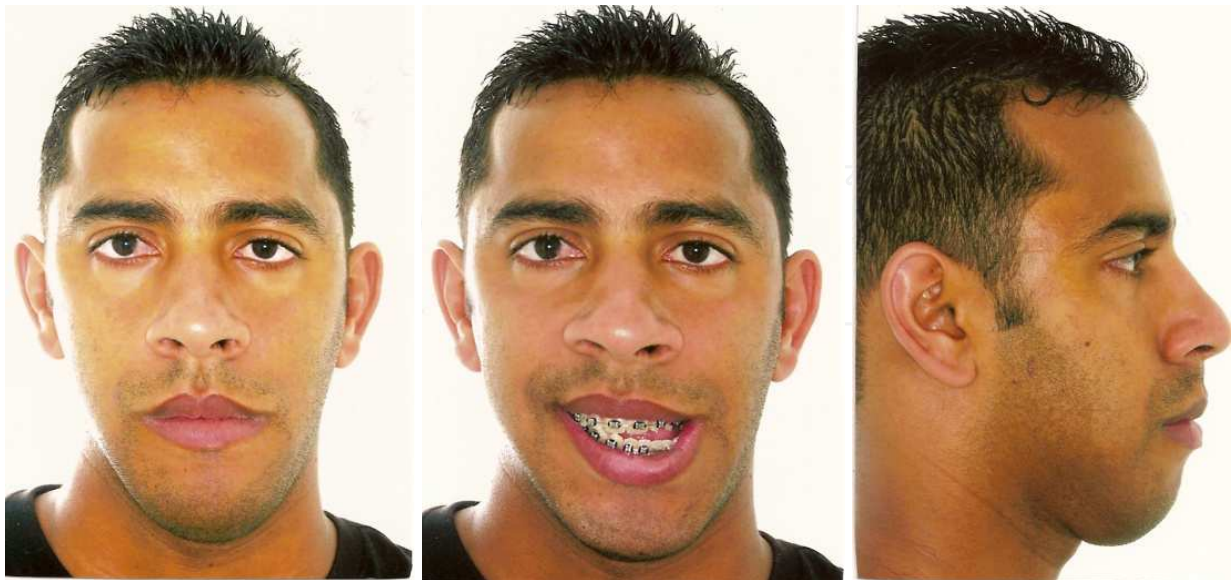

Fig. 10. Initial front and profile view

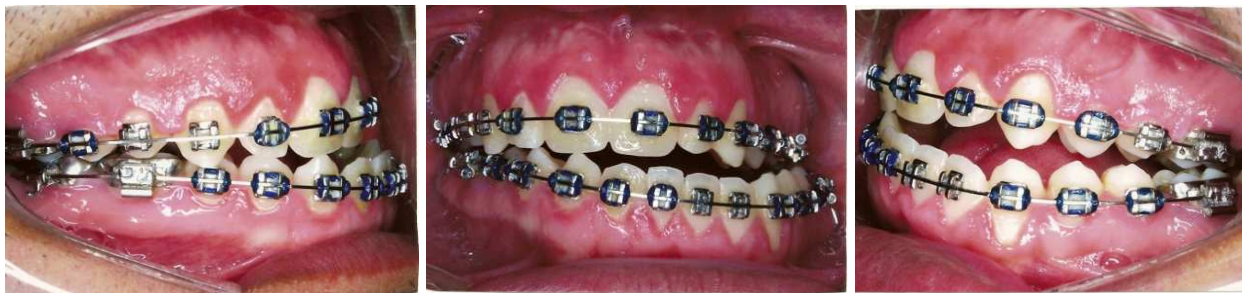

Fig. 11. Presurgical occlusion

LIST OF PROBLEMS	TREATMENT PLAN
Facial asymmetry	Surgically assisted rapid palatal expansion (SARME) - First surgery
Class III malocclusion	Presurgical orthodontic treatment
CH type 1 on right side with horizontal and vertical growth vector	High condylectomy with orthognathic surgery
Transverse maxillary deficiency and canting on left side	Le Fort I osteotomy with superior repositioning and maxillary advancement and leveling.
Open bite	Mandibular advancement with superior and forward repositioning genioplasty.
Cross bite on left side	
Vertical excess of lower face	

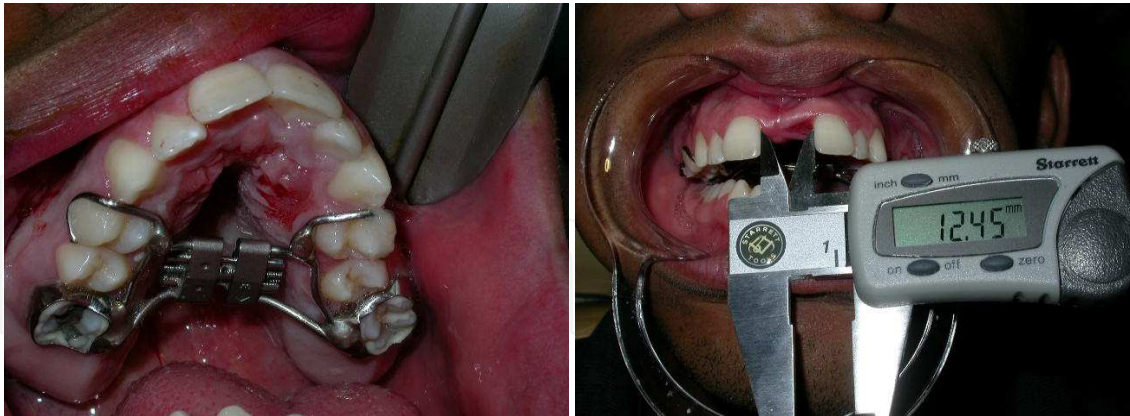

Fig. 12. First surgery - surgically assisted rapid palatal expansion (sarme)



Fig. 13. Final frontal and profile view

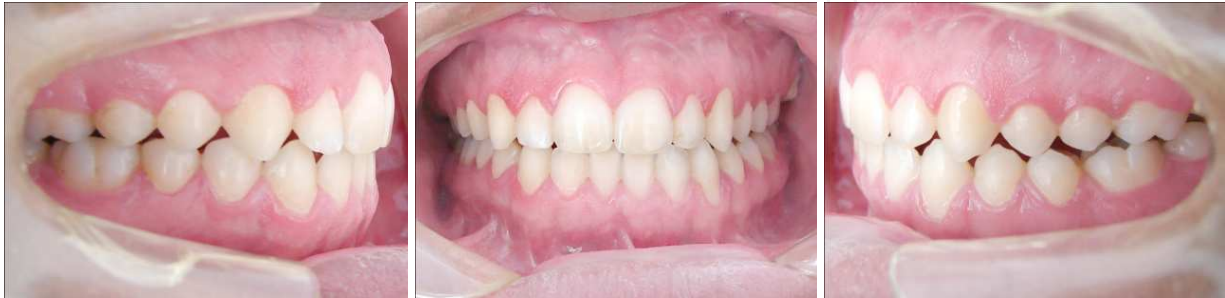

Fig. 14. Final occlusion

3.2 Case 2

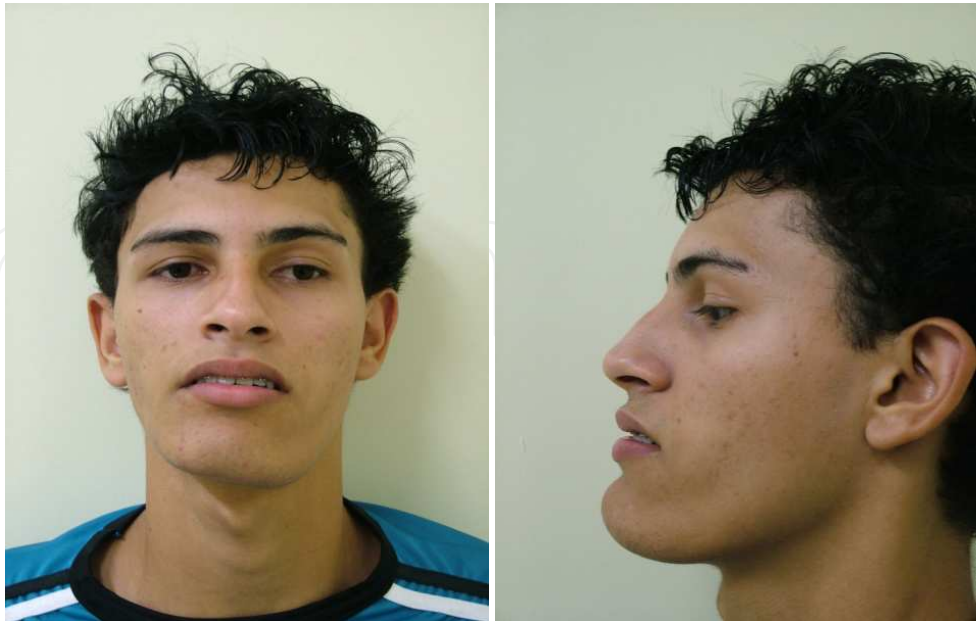

Fig. 15. Inicial frontal and profile view

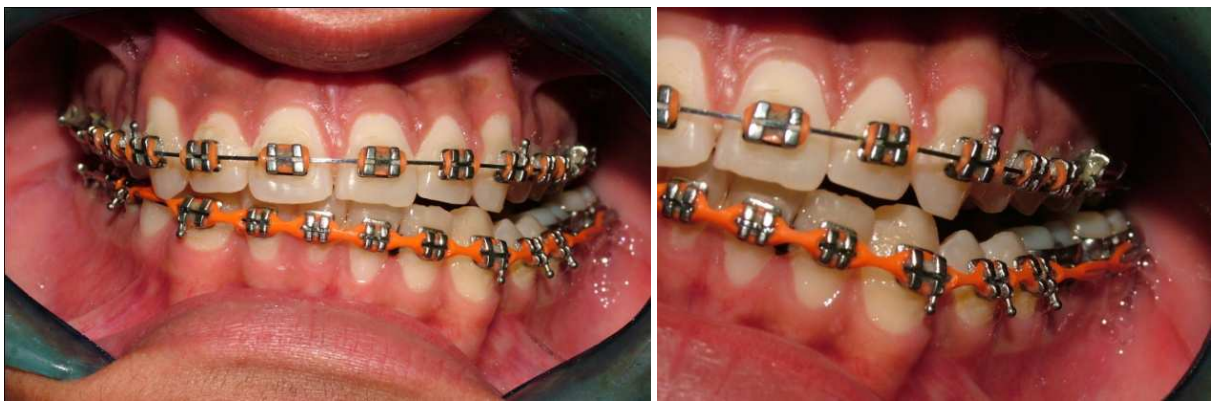

Fig. 16. Pretreatment occlusion

LIST OF PROBLEMS	TREATMENT PLAN
Facial asymmetry	High condylectomy and mandibular osteoplasty on left body and chin
Class III malocclusion	Presurgical othodontic treatment
CH type 2 on left side with mandibular midline deviation towards left side	Le Fort I osteotomy with maxillary advancement and leveling
Maxillary canting on left side	Mandibular setback with superior repositioning and setback genioplasty
Cross bite on left side	
Vertical excess of chin	

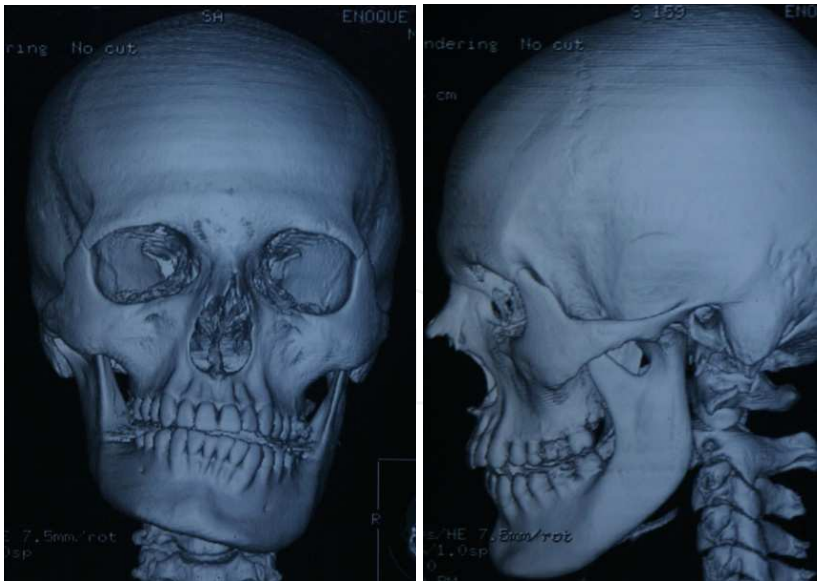


Fig. 17. CT images showing left condyle enlargement

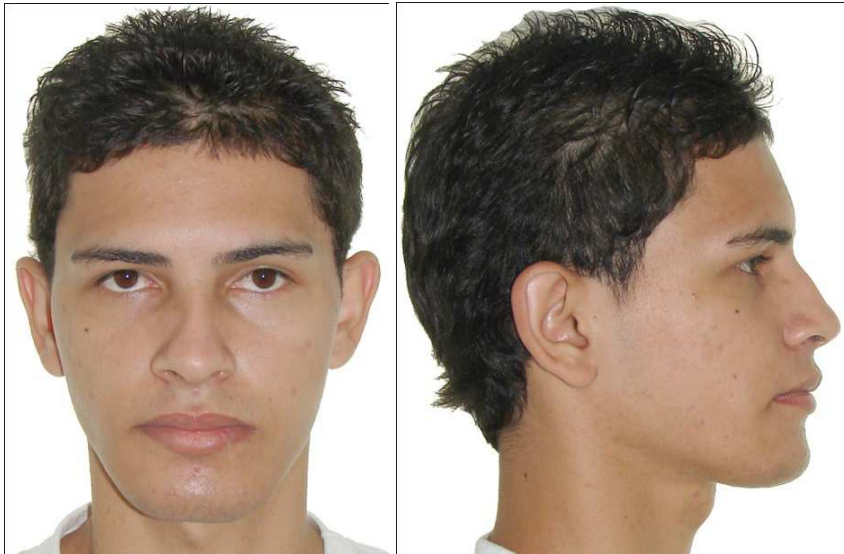
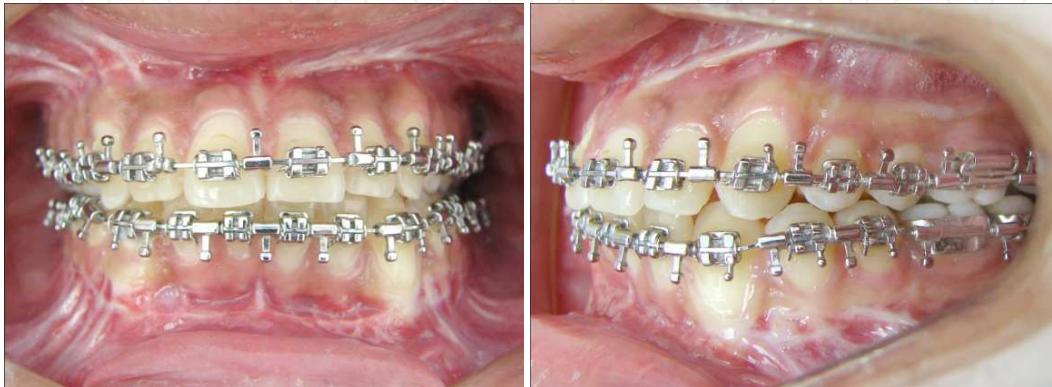
Fig. 18. Final front and profile view



* Case provided by Dr. Elvidio de Paula e Silva

Fig. 19. Final occlusion

3.3 Case 3

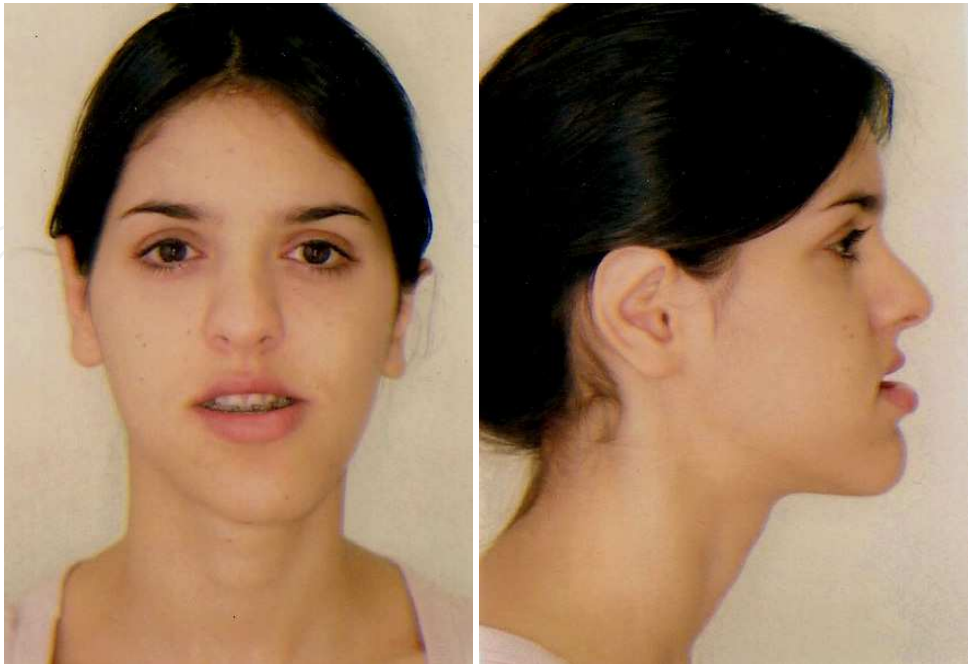

Fig. 20. Initial front and profile view

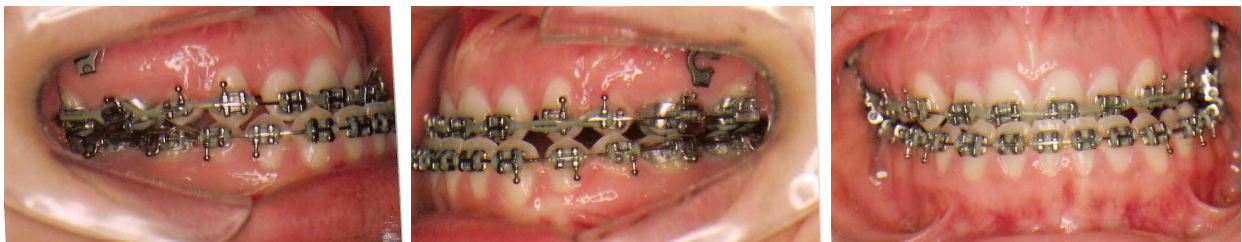


Fig. 21. Initial occlusion

LIST OF PROBLEMS	TREATMENT PLAN
Facial asymmetry	Presurgical orthodontic treatment
Class III malocclusion	High condilectomy with orthognathic surgery
CH type 1 on right side with midline deviation towards left side	Le Fort I osteotomy with superior repositioning and maxillary advancement and leveling.
Anterior cross bite	Mandibular setback with superior and forward repositioning genioplasty.
Cross bite on left side	
Vertical excess of chin	

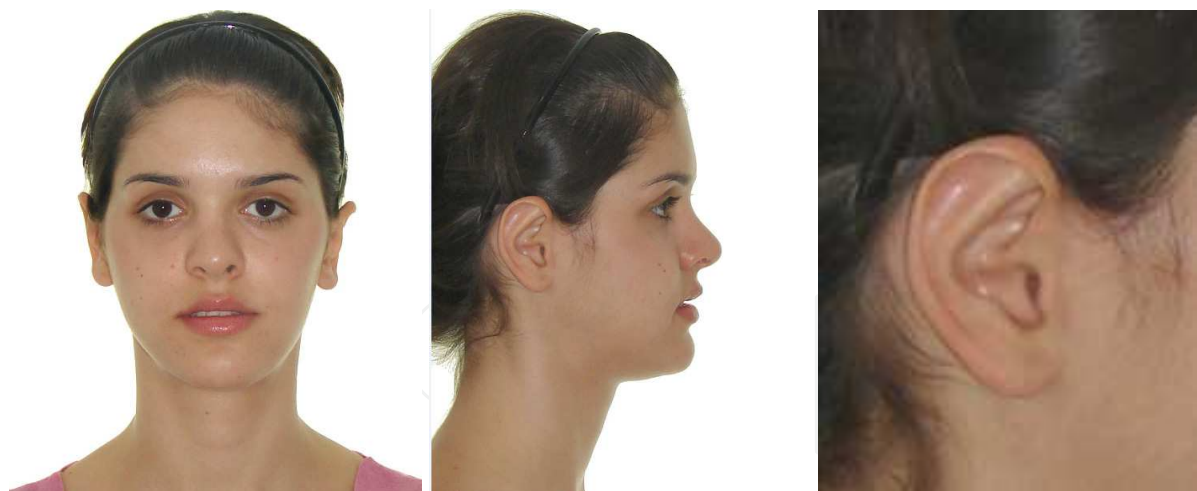

Fig. 22. Final front and profile view and preauricular region showing small residual scar

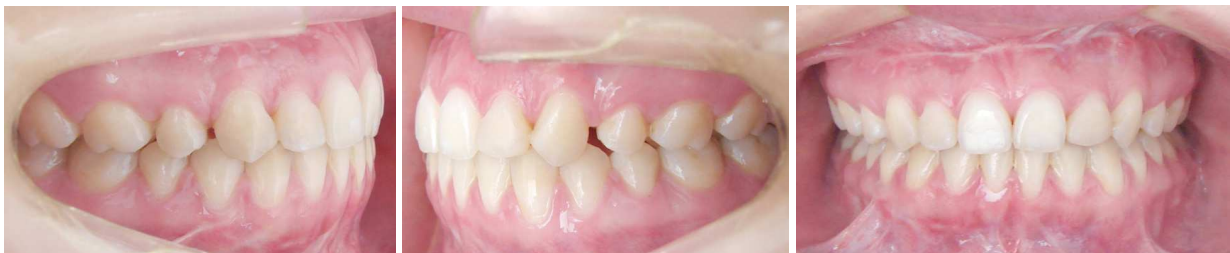

Fig. 23. Final occlusion

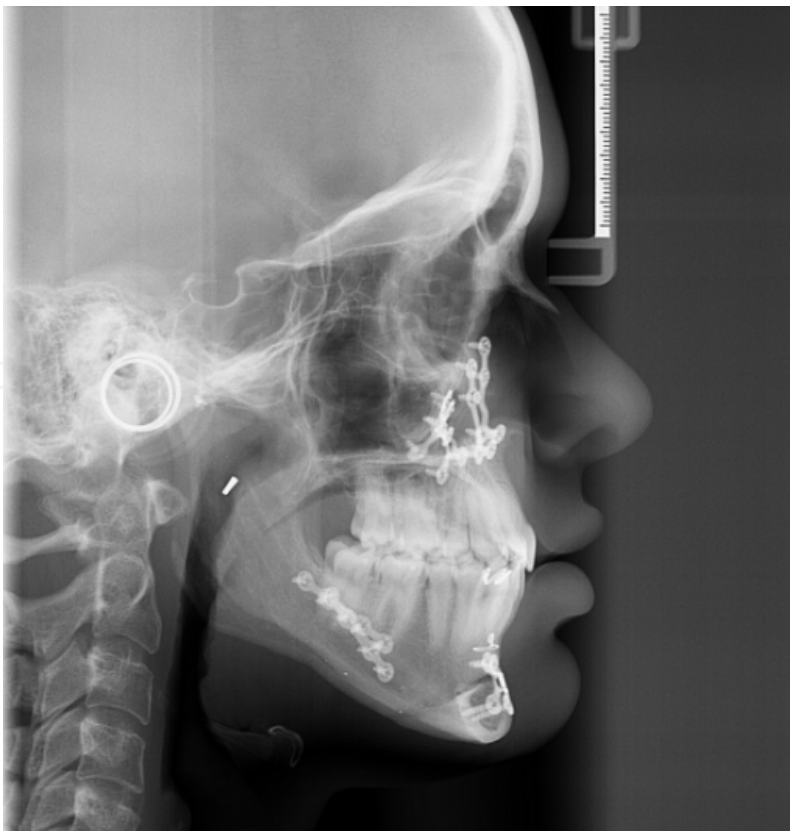
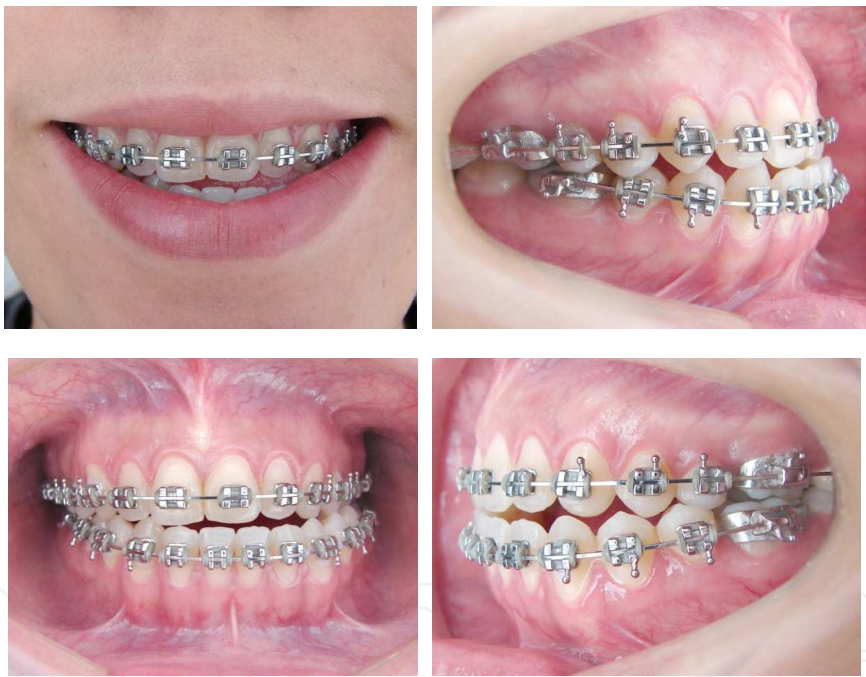

Fig. 24. Final cephalogram radiographs

3.4 Case 4




Fig. 25. Initial front and profile view (above) and initial occlusal (bellow)



LIST OF PROBLEMS	TREATMENT PLAN
Facial asymmetry	Presurgical orthodontic treatment
Class III malocclusion	High condilectomy with orthognathic surgery
CH type 1 on right side with mandibular midline deviation towards left side	Le Fort I osteotomy with superior repositioning and maxillary advancement and leveling.
Maxillary midline deviation towards right side	Mandibular setback with superior and forward repositioning genioplasty.
Cross bite on left side	Augmentation of left mandibular angle with a high-density polyethylene implant (MEDPOR®)
Vertical excess of chin	
Flattening of left mandibular angle	

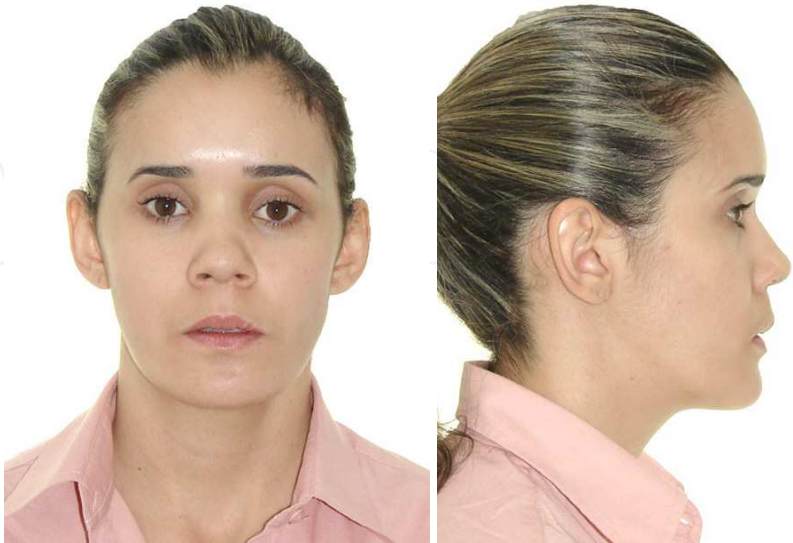

Fig. 26. Final frontal and profile view one year after surgery

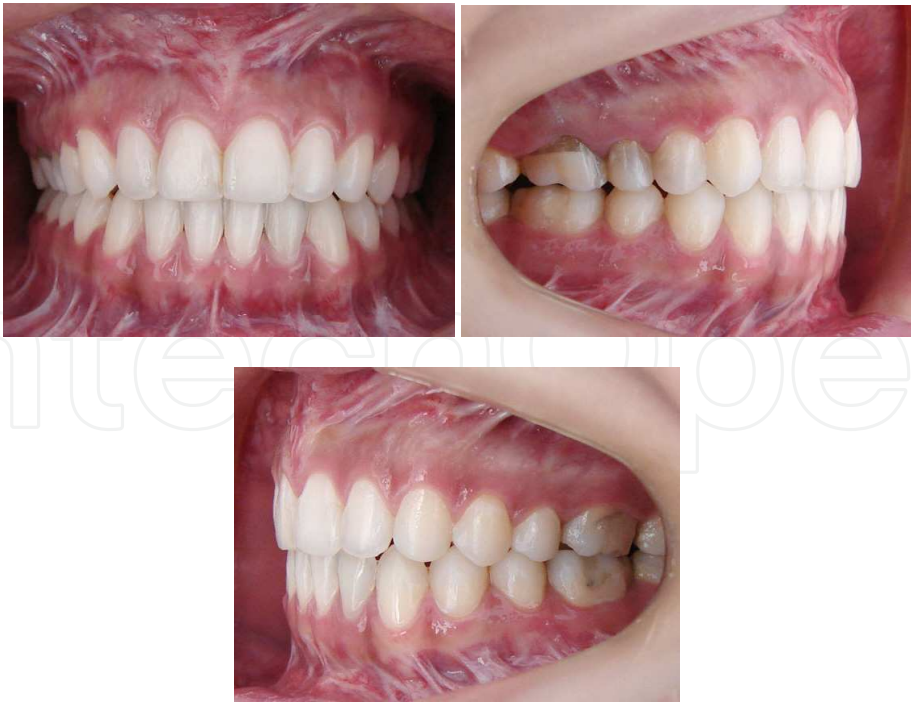

Fig. 27. Final occlusion

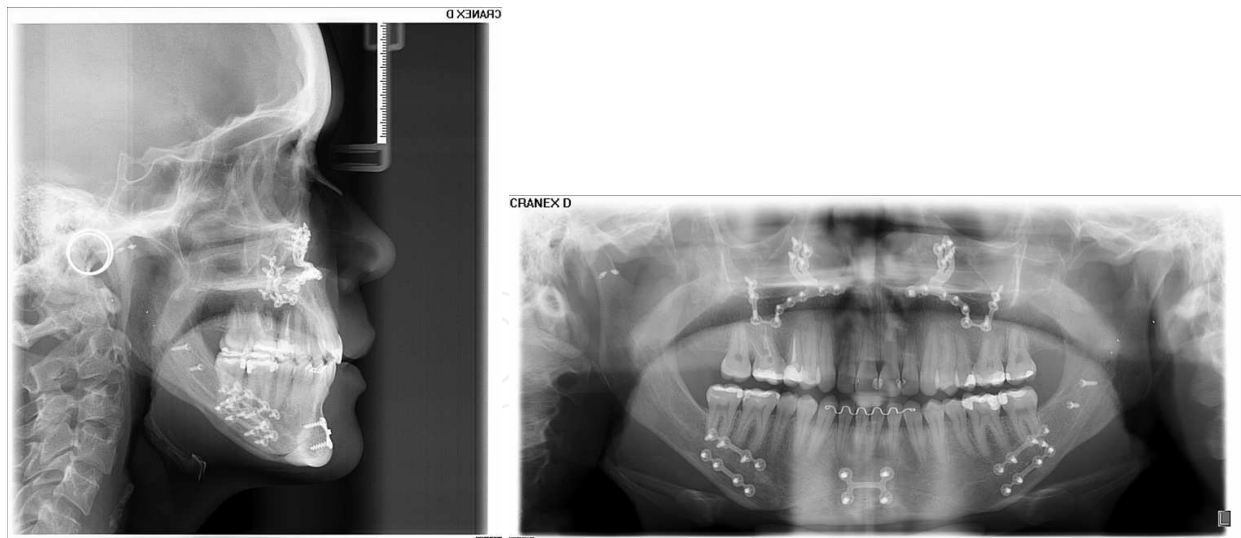


Fig. 28. Final cephalogram and panoramic radiographs showing mini-anchors on right condyle

4. Conclusions

Treatment of facial asymmetry can be challenging for both orthodontists and oral and maxillofacial surgeons. They can be assessed by photographs, posteroanterior cephalograms and 3D computed tomography (CT) scans, but clinical examinations is mandatory in order to obtain optimal functional and aesthetics results.

Mandibular condylar hiperplasia with active growth represents an important role in facial asymmetry and its treatment can be achieved by correct diagnosis, orthodontic treatment associated with correct surgical techniques.

5. References

- [1] Ko,E.W.C; Huang,C.S.; Chen, Y.R.J. Characteristics and Corrective Outcome of Face Asymmetry by Orthognathic Surgery. J Oral Maxillofac Surg 67:2201-2209, 2009.
- [2] Lee, M.; Chung, D.H; Lee, J.; Cha, K. Assessing soft-tissue characteristics of facial asymmetry with photographs. Am J Orthod Dentofacial Orthop; 138:23-31, 2010.
- [3] Bishara SE, Burkey PS, Kharouf JG. Dental and facial asymmetries: a review. Angle Orthod 1994;64:89-98.
- [4] Hwang, H-S; Youn, S.; Lee, K-H; Lim, H-J. Classification of facial asymmetry by cluster analysis. Am J Orthod Dentofacial Orthop; 132:279.e1-279.e6; 2007.
- [5] Hinds EC, Reid LC, Burch RJ. Classification and management of mandibular asymmetry. Am J Surg 1960;100:825-34.
- [6] Rowe NL. Aetiology, clinical features, and treatment of mandib-ular deformity. Br Dent J 1960;108:64-96.
- [7] Bruce RA, Hayward JR. Condylar hyperplasia and mandibular asymmetry: a review. J Oral Surg 1968;26:281-90.
- [8] Obwegeser HL, Makek MS. Hemimandibular hyperplasia – hemimandibular elongation. J Maxillofac Surg 1986;14:183-208;

- [9] Padwa, B.L.; Kaiser, M.O; Kaban, L.B. Occlusal Cant in the Frontal Plane as a Reflection of Facial Asymmetry. *J Oral Maxillofac Surg*, 55:811-816, 1997.
- [10] New Clinical Protocol to Evaluate Craniomaxillofacial Deformity and Plan Surgical Correction. Xia, J.J; Gateno, J.; Teichgraeber, J.F. *J Oral Maxillofac Surg*, 67:2093-2106, 2009.
- [11] Iannetti, G.; Cascone, P.; Belli, E.; Cordaro, L. Condylar hiperplasia: Cephalometric study, treatment plannin, and surgical correction (our experience). *Oral Surg Olar Med Oral Pathol*; 68:673-81, 1989.
- [12] Adams R. The disease in the temporomandibular articulation or joint of the lower jaw. In *A Treatise on Rheumatic Gout or Chronic Rheumatic Arthritis of All the Joints*, 2nd ed. London: Churchill, 1873:271.
- [13] Nitzan, D.W.; Katsnelson, A.; Bermanis, I.; Brin, I; Casap, N. The Clinical Characteristics of Condylar Hyperplasia: Experience With 61 Patients. *J Oral Maxillofac Surg* 66:312-318, 2008
- [14] Wolford LM, Mehra P, Reiche-Fischel O, Morales-Ryan CA, Garcia-Mo-roles P. Efficacy of high condylectomy for management of condylar hyper-plasia. *Am J Orthod Dentofacial Orthop* 2002;121(2):136-150
- [15] Kaneyama, K.; Segami, N.; Hatta, N. Congenital deformities and developmental abnormalities of the mandibular condyle in the temporomandibular joint *Congenital Anomalies* 2008; 48, 118-125.
- [16] Villanueva-Alcojol, L.; Monje, F.; González-García, R. Hyperplasia of the Mandibular Condyle: Clinical, Histopathologic, and Treatment Considerations in a Series of 36 Patients *J Oral Maxillofac Surg* 69:447-455, 2011
- [17] Norman JE, Painter DM: Hyperplasia of the mandibular condyle: A historical review of important early cases with a presentation and analysis of twelve patients. *J Maxillofac Surg* 8:161, 1980.
- [18] Saridin, C.P; Raijmakers, P.G.H.M.; Slootweg, P.J; Tuinzing, D.B.; Becking, A.G.; van der Waa, I. Unilateral Condylar Hyperactivity: A Histopathologic Analysis of 47 Patients *J Oral Maxillofac Surg* 68:47-53, 2010.
- [19] Surgical management of mandibular condylar hyperplasia type 1. Wolford LM, Morales-Ryan CA, García-Morales P, Perez D. *Proc (Bayl Univ Med Cent)*. 2009 Oct;22(4):321-9.
- [20] Brusati, R.; Pedrazzo, M.; Colletti, G. Functional results after condylectomy in active laterognathia. *Journal of Cranio-Maxillo-Facial Surgery* (2010) 38 , 179e184
- [21] Wolford, L.M. Concomitant Temporomandibular Joint and Orthognathic Surgery. *J Oral Maxillofac Surg* 61:1198-1204, 2003.
- [22] Marchetti C, Cocchi R, Gentile L, Bianchi A: Hemimandibular hyperplasia: treatment strategies. *J Craniofac Surg* 11: 46e 53, 2000
- [23] Karras SC, Wolford LM, Cottrell DA: Concurrent osteochon-droma of the mandibular condyle and ipsilateral cranial base resulting in TMJ ankylosis: Report of a case and review of the literature. *J Oral Maxillofac Surg* 54:640, 1996
- [24] Schajowicz F, Ackerman LV, Sissons HA: International Histo-logical Classification of Tumors. No. 6. Histological Typing of Bone Tumors. Geneva, Switzerland, World Health Organiza-tion, 1972
- [25] Koga K, Toyama M, Kurita K: Osteochondroma of the mandib-ular angle: Report of a case. *J Oral Maxillofac Surg* 54:510, 1996

- [26] Iizuka T, Schroth G, Laeng RH, et al: Osteochondroma of the mandibular condyle. J Oral Maxillofac Surg 54:495, 1996
- [27] Wolford, L.M.; Mehra, P.; Franco, P. Use of Conservative Condylectomy for Treatment of Osteochondroma of the Mandibular Condyle. J Oral Maxillofac Surg 60:262-268, 2002
- [28] Al-Kayat A, Bramley P: A modified pre-auricular approach to the temporomandibular joint and malar arch. Br J Oral Surg 17(2):91e103, 1979
- [29] Perez, D.; Ellis III, E. Sequencing Bimaxillary Surgery: Mandible First. J Oral Maxillofac Surg. Article in press.
- [30] Lo, J.; Xia, J.J.; Zwahlen, R.A.; Cheung, L.K. Surgical Navigation in Correction of Hemimandibular Hyperplasia: A New Treatment Strategy. J Oral Maxillofac Surg 68:1444-1450, 2010

IntechOpen



Maxillofacial Surgery

Edited by Prof. Leon Assael

ISBN 978-953-51-0627-2

Hard cover, 86 pages

Publisher InTech

Published online 23, May, 2012

Published in print edition May, 2012

How to reference

In order to correctly reference this scholarly work, feel free to copy and paste the following:

Everton Da Rosa, Júlio Evangelista De Souza Júnior and Melina Spinosa Tiussi (2012). Mandibular Condylar Hiperplasia, Maxillofacial Surgery, Prof. Leon Assael (Ed.), ISBN: 978-953-51-0627-2, InTech, Available from: <http://www.intechopen.com/books/maxillofacial-surgery/mandibular-condylar-hyperplasia>

INTech
open science | open minds

InTech Europe

University Campus STeP Ri
Slavka Krautzeka 83/A
51000 Rijeka, Croatia
Phone: +385 (51) 770 447
Fax: +385 (51) 686 166
www.intechopen.com

InTech China

Unit 405, Office Block, Hotel Equatorial Shanghai
No.65, Yan An Road (West), Shanghai, 200040, China
中国上海市延安西路65号上海国际贵都大饭店办公楼405单元
Phone: +86-21-62489820
Fax: +86-21-62489821

IntechOpen

© 2012 The Author(s). Licensee IntechOpen. This is an open access article distributed under the terms of the [Creative Commons Attribution 3.0 License](https://creativecommons.org/licenses/by/3.0/), which permits unrestricted use, distribution, and reproduction in any medium, provided the original work is properly cited.

IntechOpen

IntechOpen